This is a digital copy of a book that was preserved for generations on library shelves before it was carefully scanned by Google as part of a project to make the world's books discoverable online.

It has survived long enough for the copyright to expire and the book to enter the public domain. A public domain book is one that was never subject to copyright or whose legal copyright term has expired. Whether a book is in the public domain may vary country to country. Public domain books are our gateways to the past, representing a wealth of history, culture and knowledge that's often difficult to discover.

Marks, notations and other marginalia present in the original volume will appear in this file - a reminder of this book's long journey from the publisher to a library and finally to you.

Usage guidelines

Google is proud to partner with libraries to digitize public domain materials and make them widely accessible. Public domain books belong to the public and we are merely their custodians. Nevertheless, this work is expensive, so in order to keep providing this resource, we have taken steps to prevent abuse by commercial parties, including placing technical restrictions on automated querying.

We also ask that you:

+ *Make non-commercial use of the files* We designed Google Book Search for use by individuals, and we request that you use these files for personal, non-commercial purposes.

+ *Refrain from automated querying* Do not send automated queries of any sort to Google's system: If you are conducting research on machine translation, optical character recognition or other areas where access to a large amount of text is helpful, please contact us. We encourage the use of public domain materials for these purposes and may be able to help.

+ *Maintain attribution* The Google "watermark" you see on each file is essential for informing people about this project and helping them find additional materials through Google Book Search. Please do not remove it.

+ *Keep it legal* Whatever your use, remember that you are responsible for ensuring that what you are doing is legal. Do not assume that just because we believe a book is in the public domain for users in the United States, that the work is also in the public domain for users in other countries. Whether a book is still in copyright varies from country to country, and we can't offer guidance on whether any specific use of any specific book is allowed. Please do not assume that a book's appearance in Google Book Search means it can be used in any manner anywhere in the world. Copyright infringement liability can be quite severe.

About Google Book Search

Google's mission is to organize the world's information and to make it universally accessible and useful. Google Book Search helps readers discover the world's books while helping authors and publishers reach new audiences. You can search through the full text of this book on the web at `http://books.google.com/`

COUNTWAY LIBRARY
HC 2M1C N

BOSTON
MEDICAL LIBRARY
8 THE FENWAY

TEXT-BOOK

OF

GENERAL AND SPECIAL

PATHOLOGY

FOR

STUDENTS AND PRACTITIONERS

BY

HENRY T. BROOKS, M.D.

Formerly Professor of Pathology at the New York Post-Graduate Medical School and Hospital; Consulting Pathologist to Beth-Israel, New York City, and New Rochelle, N. Y., Hospitals; Bacteriologist to St. Mark's Hospital, N. Y.; Member of the New York Academy of Medicine, the New York State, and West Chester County Medical Societies, etc., etc.

Illustrated with 525 Half-tone and Other Text Engravings (110 in Colors), also 15 Full-page Plates in Colors, Containing 40 Figures

APR 1 1927

SECOND REVISED EDITION

PHILADELPHIA

F. A. DAVIS COMPANY, PUBLISHERS

ENGLISH DEPOT

STANLEY PHILLIPS, LONDON

1915

COPYRIGHT, 1912
COPYRIGHT, 1915
BY
F. A. DAVIS COMPANY

F. A. 478.

Philadelphia, Pa., U. S. A.
Press of F. A. Davis Company
1914-1916 Cherry Street

TO

STEPHEN SMITH BURT, A.M., M.D.

MEMBER OF THE NEW YORK ACADEMY OF MEDICINE; EMERITUS PROFESSOR OF MEDICINE AT THE NEW YORK POST-GRADUATE MEDICAL SCHOOL AND HOSPITAL, ETC.; ACCOMPLISHED CLINICIAN AND SCHOLAR, THIS VOLUME IS AFFECTIONATELY DEDICATED.

PREFACE TO SECOND EDITION.

ADVANTAGE is taken of the call for a second edition of this work to make corrections and additions demanded since the first issue. In meeting these demands an effort has been made to confine revision to practical and accepted advances in pathologico-anatomic knowledge revealed by new investigations of the last few years. The arrangement of the matter has remained the same. Among the changes may be mentioned those made to the sections upon Beriberi, Pellagra, Cerebrospinal Meningitis, Rabies, Infantile Paralysis, Landry's Paralysis, and a new section devoted to Growths of the Carotid Gland.

In this place attention may be drawn to the arrangement of the text into sections printed in large and small type; the larger presenting the essential features, the smaller being devoted to detail description or elaboration of the various subjects. This, it is believed, will enable the busy practitioner or student readily to gain access to one or the other. To further facilitate hasty consultation, each subject has been indexed with page number and not by cross-reference. It must further be noted that the terminology employed in the text—*i.e.*, the use of Latin and Greek terms in addition to English equivalents—is intended to familiarize the reader with the etymology; for it is only by knowledge of the derivation of the terms that memory of their meaning can be retained.

H. T. BROOKS.

PREFACE.

ORIGINALLY, it was intended by both the publishers and the writer of these lines to issue, with notes and additions, a translation of the third edition of "Grundriss der Pathologischen Anatomie," published in 1904, by Professor Robert Langerhans, of Berlin. The important and rapid advancements made since that time and the death shortly thereafter of the author of that classic handbook made it necessary not only to recast and greatly augment the subject-matter to meet existing requirements, but to more fully adapt it to the needs of the undergraduate student and practitioner. The result was a new treatise, which now is presented as an independent volume. Most of the excellent illustrations, and available portions of the German text, were freely employed, indebtedness to which source is hereby publicly acknowledged. Admission is made also of indebtedness to the well-known works of Virchow ("Die Krankhafte Geschwülste," "Die Cellular Pathologie," etc.), and the authoritative textbooks of Klebs, Birch-Hirschfeld, von Recklinghausen, Orth, Cornil and Ranvier, Ziegler, Cohnheim, Rindfleisch, Kaufmann, Smaus, Aschoff, Krehl and Marchand, and others, as well as to the current medical literature. The work can neither compete with the exhaustive treatises above mentioned nor take the place of pathologicoanatomic instruction, since the indispensable training of the senses of sight and touch can be acquired only by the study of fresh organs under competent guidance.

Owing to lack of space, it was necessary to give only the essentials and to present views more or less generally accepted in as concise a form as possible; hence, many topics could be only very briefly discussed. For the same reason references to authors and literature have been omitted, except when of historic interest or to support statements in the text which may be at variance with prevailing conceptions.

While the work is intended chiefly to serve the undergraduate student as an introduction to the difficult and intricate study of pathologic anatomy, both gross and microscopic, it is believed the most frequent

and important processes are so presented as to appeal also to the practitioner and enable him, by application of the knowledge obtained from description of the various pathologic states, to interpret clinical symptoms. In this particular the requirements of the practitioner have constantly been kept in mind and, wherever practicable, questions of diagnostic importance have been considered.

Especial thanks are due to Professor Allan J. Smith, of the University of Pennsylvania, for the admirable and comprehensive section on Immunity, which is almost entirely from his pen, and to Dr. Edward L. Oatman, Surgeon and Pathologist to the New York Manhattan Eye, Ear, Nose and Throat Hospital, for thorough revision and elaboration of the section on the Pathology of the Eye.

In conclusion, most cordial thanks are due to the F. A. Davis Company for the courtesy and consideration they have shown during the mechanic execution of the work, and to Drs. Herman B. Sheffield, T. Homer Coffin, and Wesley G. Vincent, for assistance and suggestions in the preparation of certain portions of the text.

H. T. B.

40 East Forty-first Street,
New York City.

CONTENTS.

	PAGE
The Province of Pathology	1
The Nature of Disease	1
General Etiology	6
Causæ Externæ	6
Causæ Internæ	6
Heredity	8
Immunity	12
Disturbances of the Circulation	34
Hyperemia	34
Fluxion	36
Congestion	40
Local Congestion	40
General Congestion	42
Anemia	46
General Anemia or Oligemia	47
Local Anemia or Ischemia	49
Distribution of the Blood after Death	51
Hemorrhage	54
Internal Causes of Hemorrhage	57
Sequelæ of Hemorrhages	68
Restoration of Blood	69
Stasis	71
Thrombosis	72
Embolism	81
Metastasis	93
Dropsy	95
Disturbances of Nutrition	104
General Remarks on Nutrition	104
Metaplasia	105
Hypertrophy	109
Atrophy	113
Simple and Brown Atrophy	114
Necrobiosis	116
Gangrene	123
Pigmentations	130
Hematogenous Pigments	132
Metabolic Pigments	136
Foreign Pigments	138
Degeneration	139
Calcification: Petrification, Ossification, Lithiasis	140
Amyloid Degeneration	144
Hyaline Degeneration	150
Waxy Degeneration	150
Colloid Degeneration	151
Mucoid Degeneration	151
Albuminous or Parenchymatous Degeneration	154
Fatty Degeneration	155
Regeneration	158
Transplantation	162
Inflammation	163
Parenchymatous Inflammation	172
Exudative Inflammations	172
Sequelæ of Inflammations	179

PAGE

Interstitial Inflammation 180
Acute Interstitial Inflammation 173
Chronic Interstitial or Productive Inflammation 180
Fever 181
Malformations 186
Monstra per Defectum 186
Simple Defective Formations 186
Arrested Development by Transformation of the Primary Anlage 193
Arrested Development in the Embryonal Stage 195
Monstra per Excessum 201
Excessive Development 201
Multiple Formation 201
Monstra per Fabricam Alienam 205
Tumors 207
General Remarks 207
Extravasation and Exudation Tumors 211
Hematomata 212
Dilation and Retention Tumors 215
Proliferation Tumors 215
I. The Histoid Tumors 216
Fibroma 216
Lipoma 224
Myxoma 226
Chondroma 229
Osteoma 235
Psammoma 239
Melanoma 240
Glioma 241
Sarcoma 243
Lymphatic Tumors 254
Myoma 256
Neuroma 261
Angioma 262
Lymphangioma 268
II. The Organoid Tumors 268
Carcinoma, Margaritoma 268
Endothelioma 303
Adenoma, Adenocarcinoma 307
Cystoma 309
III. The Teratoid Tumors 311
Poisoning 313
Blood Poisons 313
Caustic Poisons 316
Animal Poisons 320
Nerve and Heart Poisons 332
Toxins and Toxalbumins 338
Autointoxication 339
Alterations Caused by the Animal and Vegetable Organisms, Including the Infectious Diseases 348
I. Alterations Caused by Animal Parasites 348
Arthropoda (Insects and Arachnoidea) 349
Insects (Flea, Louse, etc.) 349
Arachnoidea (Itch Mite, Hair-sac Mite, Pentastomum) 352
Vermes (Nematelminthes and Platyelminthes) 356
Nematelminthes (Nematodes, Oxyurus, Ascaris, Filaria, Trichina, Trichocephalus, Anchylostomum) 356
Platyelminthes (Trematodes and Cestodes) 371
Trematodes (Distomum) 371
Cestodes (Tapeworms, Cysticercus, Echinococcus) 377
Protozoa (Rhizopoda, Sporozoa, Infusoria) 392
Rhizopoda (Amebæ) 393
Trypanosomata 394

PAGE

Sporozoa (Coccidia, Gregarina, Hemosporidia, Acystosporidia) 397
Hemosporidia; Malaria 398
Summary of Animal Parasites 413
Infusoria 414
II. Alterations Produced by Vegetable Parasites, Including the Infectious Diseases 414
General Remarks on the Vegetable Parasites (Fungi) 414
Molds 415
Budding Fungi and Yeasts 423
Fission Fungi (Bacteria) 423
General Remarks on the Infectious Diseases 435
Tuberculosis, Scrofulosis, Lupus 436
Actinomycosis 483
Mycetoma 485
Sporotrichosis 486
Anthrax 488
Glanders 490
Foot and Mouth Disease 492
Tetanus 492
Erysipelas 493
Gonorrhea 495
Bubonic Plague 497
Purulent and Putrid Processes and the Pyogenic Bacteria 498
Recurrent Fever 502
Asiatic Cholera 505
Typhoid Fever 507
Paratyphoid Fever 518
Colon Bacillus Infection 519
Dysentery 520
Malta Fever 521
Dengue or Dandy Fever 521
Influenza 522
Diphtheria 523
Spirobacillary Angina 529
Leprosy 530
Fibrinous Pneumonia 532
Syphilis 543
Variola (Small-pox) 558
Varicella 560
Scarlatina 561
Morbilli (Measles) 563
Rötheln (German Measles) 564
Pertussis (Whooping-cough) 564
Typhus Fever 565
Rocky Mountain Fever 565
Epidemic Cerebrospinal Meningitis 568
Cholera Nostras 568
Hydrophobia (Rabies, Lyssa) 569
Emphysematous Gangrene 570
Hospital Gangrene 572
Rhinoscleroma 573
Malignant Edema 573
Epidemic Parotitis 574
Coryza 575
Pellagra 576
Beriberi 581
Yellow Fever 586
Yaws 588
Nervous System 589
Cerebral and Spinal Meninges 589
Brain and Spinal Cord 597

PAGE

Peripheral Nerves 618
Suprarenal Capsules 619
Vascular System 622
Heart 622
Pericardium 622
Myocardium 625
Endocardium 638
Arteries and Veins 650
Lymphatic Vessels 659
Blood and Lymph 661
Blood 661
Alterations of the Normal Constituents of 661
Foreign Substances in 684
Lymph 686
Hematopoietic Organs 688
Spleen 688
Lymphatic Glands 694
Thymus 698
Respiratory System 701
Thyroid Gland 737
Digestive Canal and Peritoneum 749
Digestive Canal 749
Peritoneum 779
Liver and Salivary Glands 787
Liver 787
Salivary Glands 810
Pancreas 810
Parotid, Submaxillary, Sublingual 813
Uropoietic System 815
Kidneys 815
Urinary Tract 853
Male and Female Sexual Organs 865
Common Origin and Differentiation 865
Male Sexual Organs 866
Testes 866
Seminal Duct and Seminal Vesicle 869
Prostate 869
Penis 874
Female Sexual Organs 877
Bones, Cartilages, Joints 902
Muscles, Tendons, Tendon-sheaths, and Bursæ 935
Muscles 935
Tendon-sheaths 938
Bursæ 938
Skin 941
Eye 953
Conjunctiva 953
Lachrymal Glands 974
Cornea 977
Sclera 999
Lens 1005
Vitreous 1012
Uveal Tract 1014
Retina and Optic Nerve 1051
Orbit 1073
Eyelids 1080
Organs of Hearing 1088
External Ear 1088
Middle Ear 1091
Internal Ear 1096

LIST OF ILLUSTRATIONS.

FIG.		PAGE
1	The toxin molecule, showing the haptophore. (After Ehrlich.)	23
2	The combining groups of the cell. (After Ehrlich.)	23
3	Haptophores and toxophores. (After Ehrlich.)	23
4	First stage of antitoxin formation. (After Ehrlich.)	24
5	Second stage; reproduction of receptors. (After Ehrlich.)	24
6	Third stage; receptors leaving the cell. (After Ehrlich.)	24
7	Fourth stage; receptors free in blood-plasma. (After Ehrlich.)	25
8	Neutralization of toxin by antitoxin. (After Ehrlich.)	25
9	Heart-lesion cells (Plate III)	57
10	Table of the bleeder family Mampel. (After Lossen.)	64
11	Hematoidin crystals. (Highly magnified.)	70
12	Thrombosis. (After Smaus.)	75
13	Plate thrombus. (After Smaus.)	76
14	Valvular thrombus. (After Langerhans.)	78
15	Fat embolism. (After Langerhans.)	84
16	Multiple embolism. (After Langerhans.)	86
17	Schema of vascular branches with anastomoses. (After Smaus.)	87
18	Schema of arteries with few anastomoses	88
19	Atrophy of muscle with lipomatosis. (After Smaus.)	107
20 and 21	Hypertrophy of the right lung. (After Langerhans.)	111, 112
22	Muscle-fibers in simple atrophy. (After Smaus.)	115
23	Atrophy of a muscle. (After Smaus.)	115
24	Fat-granule spherules in pulmonary carcinoma	117
25	Cholesterin plates. Crush preparation	118
26	Heart muscle in fatty metamorphosis. (After Langerhans.)	119
27	Slightly curved acid crystals. (After Langerhans.)	129
28	Brown atrophy of the heart. (After Langerhans.)	138
29	Pulmonary calculus, natural size. (After Langerhans.)	141
30	Vesical calculus formed around hairpin. Slightly reduced	144
31	A portion of the soleus muscle. (After Green.)	151
32	Mucoid degeneration. (After Langerhans.)	153
33	Fatty infiltration of connective tissue. (Rindfleisch.)	156
34	Formation of capillary vessels. (After Arnold.)	161
35	Leucocytes of man, showing ameboid movement. (Landois.)	165
36	Granulation tissue from the peritoneum. (Smaus.)	166
37	Stenosis of the conus pulmonalis. (After Langerhans.)	191
38	Four pulmonary valves of a 55-year-old man. (After Langerhans.)	193
39	Pseudohermaphroditismus masculinus externus. (After Langerhans.)	194
40	Uterus bicornis. (After Langerhans.)	195
41	Vagina septa et uterus septus. (After Langerhans.)	196
42	Abnormal length of the uvula. (After Langerhans.)	201
43	Clitoris hypertrophy and precocious hirsuteness. (After Langerhans.)	202
44	Dicephalus. (Leishman.)	203
45	Thoracoabdominopagus. (Leishman.)	203
46	Thoracoabdominopagus, with ectopia viscerum. (Sheffield.)	204
47	Adenoma mammæ acinosum. (After Ziegler.)	218
48	Papilloma (acuminate condyloma). (Smaus.)	219
49	Benign papilloma of the bladder. (After Kaufmann.)	220
50	Intracanalicular fibroma. (After Zeigler.)	221
51	Intracanalicular fibroma of breast. (After Kaufmann.)	222
52	Condyloma acuminatum. (After Ziegler.)	223
53	Papillary cystocarcinoma of the breast. (After Zeigler.)	228
54	Chronic arthritis deformans. (After Langerhans.)	230
55	Carcinoma fibrochondrosarcomatodes. (After Langerhans.)	231
56	Exostosis of the inferior maxilla. (After Langerhans.)	235
57	Pelvic exostosis	236
58	Supracartilaginous exostoses of vertebræ. (After Langerhans.)	237
59 and 60	Psammoma duræ matris. (After Langerhans.)	240, 241
61	Myxomatous glioma of the left frontal lobe. (After Langerhans.)	242
62	Glioma with stellate cells. (After Smaus.)	243
63	Myeloid sarcoma. (After Ziegler.)	245
64	Spindle-celled sarcoma. (After Langerhans.)	246
65	Myeloid or giant-celled sarcoma. (Virchow.)	247
66	Alveolar sarcoma of the lymph-glands. (After Ziegler.)	248
67	Melanosarcoma of the choroid	249
68	Epulis. (After Langerhans.)	250
69	Section through a myxosarcoma. (After Ziegler.)	251
70	Lymphosarcoma of lymph-glands. (After Dietrich.)	252
71	Leukemic infiltration of the renal cortex. (After Ziegler.)	254
72	Hypertrophy of prostate	258
73	Myoma of the uterus. (After Langerhans.)	259

FIG.		PAGE
74	Hemangioma with hypertrophic endothelia. (After Ziegler.)	265
75	Section through a nodular angiosarcoma. (After Ziegler.)	266
76	Extirpated lymphangioma of the hand. (After Langerhans.)	267
77	Part of Fig. 76 strongly magnified. (After Langerhans.)	267
78	Carcinoma stroma	269
79	Extirpated carcinoma of the parotid. (Langerhans.)	269
80	Slant section through a regular gland. (After Amann.)	270
81	Section through roots and soil in direction *a* to *b*. (After Oestreich.)	271
82	Stroma of cancer. (After Cornil and Ranvier.)	272
83	Cells from a scirrhus of the mamma. (After Green.)	274
84	Perforation carcinoma. (After Langerhans.)	275
85	Same as Fig. 84. (After Langerhans.)	276
86	Gastric carcinoma in an old woman. (After Langerhans.)	277
87	Isolated cells from epithelioma of parotid. (After Langerhans.)	278
88	Section from epithelioma of uterus. (After Langerhans.)	279
89	Metastatic epitheliomatous nodules. (After Langerhans.)	280
90	Multiple pearl tumors. (After Langerhans.)	280
91	Section from Fig. 90. (After Langerhans.)	281
92	Squamous epithelioma of lip. (Gray.)	282
93	Hornified squamous-celled carcinoma. (After Kaufmann.)	283
94	Adenocarcinoma of breast	284
95	Adenocarcinoma of rectum. (After Ziegler.)	285
96	Colloid carcinoma. (After Langerhans.)	286
97	Carcinoma gelatinosum. (After Langerhans.)	286
98	Colloid carcinoma of the pylorus. (After Langerhans.)	287
99	Section from enlarged axillary lymph-gland. (After Ziegler.)	288
100	Section from carcinoma of stomach. (After Langerhans.)	289
101	Metastatic carcinoma of liver. (After Langerhans.)	289
102	Carcinomatous ulcer of esophagus. (After Langerhans.)	291
103	Carcinoma of stomach. (After Langerhans.)	291
104	Adenocarcinoma of stomach. (After Ziegler.)	292
105	Bean-sized adenocarcinoma of breast. (After Zeigler.)	293
106	A breast in section. (After Bland-Sutton.)	294
107	A breast with duct cancer. (After Bland-Sutton.)	294
108	Papillary cystocarcinoma of breast. (After Ziegler.)	295
109	A cancerous breast in section. (After Bland-Sutton.)	296
110	Carcinomatous ulcer of the body of the uterus. (After Langerhans.)	297
111	Epithelioma of vagina	298
112	Papillary epithelioma of larynx. (After Ziegler.)	299
113	Carcinoma of larynx. (After Ziegler.)	299
114	Metastatic lymph-vessel carcinoma. (After Ziegler.)	301
115	Bone resorption and apposition. (After Ziegler.)	302
116	Endothelioma of dura mater. (After Ziegler.)	303
117	Endothelioma of pleura. (After Ziegler.)	305
118	Perithelioma of choroid and ciliary body	306
119	Tubular adenoma of the stomach. (After Ziegler.)	307
120	Adenocarcinoma of the stomach. (After Ziegler.)	308
121	Papillary adenocarcinoma of bile-ducts. (After Ziegler.)	309
122	Papillary cystadenoma of the ovary	310
123	Teratoma of kidney. (After Ziegler.)	311
124	Gastric mucosa strongly swollen and folded. (After Langerhans.)	319
125	Principle of complement fixation. (After H. Fox.)	321
126	Atropa belladonna (nightshade)	334
127	Amanita bulbosa	336
128	Auchmeromyia luteola, Fabr.	350
129	Phthirius pubis (crab-louse). (After Landois.)	351
130	Sarcoptes scabiei. (After Gudden.)	352
131	Acarus folliculorum with low magnification	353
132	The same with high magnification	353
133	Argas reflexus. (After Alt.)	354
134	Oxyuris vermicularis. (After Langerhans.)	356
135	Two eggs of Oxyuris vermicularis. (After Langerhans.)	356
136	Oxyuris vermicularis (female and male). (After Leuckart.)	356
137	Two eggs of Ascaris lumbricoides. (After Langerhans.)	357
138	Eggs and embryos of animal parasites	359
139	Filaria sanguinis hominis in human blood	360
140	Trichina spiralis. (After Claus.)	361
141	Diagram of the hosts of trichina. (After Bollinger.)	361
142	Trichina capsule with living trichina. (After Langerhans.)	362
143	Calcified trichina. (After Langerhans.)	362
144	Trichina capsule with fragments of calcified trichina. (After Langerhans.)	362
145	Empty, slightly calcified trichina capsule. (After Langerhans.)	363
146	Trichina capsule filled with adipose tissue. (After Langerhans.)	364
147	Trichina capsule almost completely resorbed. (After Langerhans.)	364
148	Trichocephalus dispar. (After Leuckart.)	366
149	Eggs of nematodes. (After Leuckart.)	366
150	Agchylostoma duodenale. (After Leuckart.)	367
151	Embryology of Old World hook-worm. (After Perroncito.)	368
152	Head of Necator americanus. (After Daniels.)	369
153	Eggs of New World hook-worm. (After Stiles.)	369
154	Strongyloides intestinalis in feces	370
155	Fasciola hepatica (Lank.). (After Claus.)	371

FIG.		PAGE
156	Fasciolopsis buski (Lank.). (After Odhner.)	372
157	Fasciolopsis rathouisi (Poir.). (After Claus.)	372
158	Paragonimus westermani. (After Looss.)	374
159	Schistosomum hæmatobium. (After Looss.)	374
160	Schistosomum hæmatobium. (After C. W. Daniels.)	375
161	Eggs of distoma from urinary sediment. (After Purdy.)	375
162	Schistosomum (?) hæmatobium. (After C. W. Daniels.)	377
163	Schistosomum japonicum. (After Fulleborn.)	378
164	Tænia nana. (After Leuckart.)	380
165	Egg of dwarf tape-worm. (After B. H. Ransom.)	380
166	Plan of alternation of hosts with Tænia solium. (After Bollinger.)	380
167	Head of Cysticercus cellulosæ. (After Langerhans.)	381
168	Diagram of the hosts of echinococcus. (After Bollinger.)	381
169	Proglottides of Tænia solium. (After C. W. Daniels.)	382
170	Tænia solium. (After Leuckart.)	382
171	Tænia saginata. (Partly after Leuckart.)	383
172	Proglottis of Tænia saginata. (After C. W. Daniels.)	384
173	Two ova of Tænia saginata. (After Langerhans.)	384
174	Diagram of the hosts of Tænia saginata. (After Bollinger.)	384
175	Tænia echinococcus of the dog. (After Leuckart.)	385
176	Lamellated echinococcus membrane. (After Langerhans.)	385
177	From an echinococcic cyst. (After Lenhartz.)	386
178	Echinococcus heads from a brood-capsule. (After Langerhans.)	387
179	Developed echinococcus head. (After Langerhans.)	387
180, 181, and 182	Echinococcus head. (After Langerhans.)	387
183	Young tape-worm head. (After Langerhans.)	388
184	Two echinococcus heads united. (After Langerhans.)	389
185	Anterior portion of echinococcus head. (After Langerhans.)	389
186	Echinococcus hooklets. (After Langerhans.)	390
187	Lime-corpuscles from echinococcus head. (After Langerhans.)	390
188	Proglottides of Dibothriocephalus latus. (After Langerhans.)	391
189	Two ova of Dibothriocephalus latus. (After Langerhans.)	391
190	Dibothriocephalus latus. (After Leuckart.)	392
191	Diagram of hosts of Dibothriocephalus latus. (After Bollinger.)	393
192	Amœba coli. (After Lösch.)	394
193	Trypanosomes (Plate IV, Fig. 4)	409
194	Glossina morsitans. (After Daniels.)	395
195	Coccidia. (After Daniels.)	398
196	Development of Plasmodium vivax. (After Doflein.)	400
197	Culex at rest; Anopheles at rest	402
198	Wing of female Anopheles maculipennis	403
199	Sporogony and schizogomy	404
200	Plasmodium præcox. (After Mannaberg.)	406
201	Sexual forms of Plasmodium præcox. (After Mannaberg.)	406
202	Plasmodium vivax. (After Reinhardt.)	408
203	Asexual development of Plasmodium malariæ. (After Golgi.)	409
204	Miescher's sac. (After Leuckart.)	412
205	Balantidium coli. (After Lehmann.)	412
206	Penicillium glaucum	416
207	Mucor	416
208	Aspergillus	416
209	Mucor corymbifer. (After Lenhartz.)	417
210	Aspergillus fumigatus. (After Lenhartz.)	417
211	Achorion schönleinii. (After Bizzozero.)	418
212	Trichophyton tonsurans. (After Bizzozero.)	419
213	Microsporon furfur. (After Lenhartz.)	420
214	Soor (thrush) fungus (Oidium albicans). (After Lenhartz.)	421
215	Mycosis uteri. (After Langerhans.)	422
216	Forms of bacteria. (From Schenk.)	424
217	Forms of bacilli, showing spores. (From Oertel.)	425
218	Tubercle of the liver. (After Langerhans.)	437
219	Tubercular bronchopneumonia. (After Smaus.)	445
220 and 221	Tubercles	446
222	Tuberculous large-celled hyperplasia. (After Ziegler.)	447
223	Acute miliary tuberculosis. (After Smaus.)	451
224	Eruption of new tubercles	452
225	Schematic drawing of caseous bronchitis. (After Langerhans.)	453
226	Bronchitis fibrosa obliterans multiplex. (After Langerhans.)	454
227	Acute pulmonary miliary tuberculosis. (After Langerhans.)	455
228	Tuberculosis. (Ziegler)	457
229	Tuberculous intestinal ulcer. (After Ziegler.)	460
230	Tuberculosis of colon. (After Ziegler.)	461
231	Secondary tuberculous lymphangitis. (After Langerhans.)	463
232	Two tubercles in an atrophic omentum. (After Langerhans.)	464
233	Chronic tuberculous pericarditis. (After Langerhans.)	465
234	Fibrinous hepatization. (After Langerhans.)	466
235	Section from lung, Fig. 227. *t*, tubercles	467
236	Chronic tuberculosis. (After Ziegler.)	469
237	Two small tubercles of the liver. (After Langerhans.)	470
238	Liver tubercle. (After Langerhans.)	471
239	Tuberculosis of the left kidney. (After Ziegler.)	472
240	Tuberculous nephrophthisis and chronic ureteritis. (After Langerhans.)	473

FIG.		PAGE
241	Preparation from culture of tubercle bacillus. (After von Jaksch.)	474
242	Cystoscopic view of base of bladder. (After Wyatt.)	475
243	Caseous cavernous tuberculosis of the epididymis	476
244	Rare tuberculosis of epididymis and testis. (After Kaufmann.)	476
245	Pott's disease. (After Langerhans.)	479
246	Spina ventosa. (Sheffield.)	481
247	Lupus of the skin. (After Ziegler.)	482
248	Actinomyces hominis (lung). (Lenhartz-Brooks.)	483
249	Actinomyces drusen in sputum	484
250	Same as Fig. 249; greater magnification	485
251	Colony of anthrax bacilli, slightly magnified. (After Flügge.)	489
252	Glanders nodule. (After Langerhans.)	492
253	Bacillus tetani. (After Fränkel and Pfeiffer.)	493
254	Ectogenous streptococcus infection. (Ziegler.)	494
255	Tyrosin. (After Langerhans.)	502
256	Spirochæta obermeieri. (After von Jaksch.)	503
257	Typhoid bacilli (pure culture). (After Schenk.)	508
258	Typhoid bacilli (spider cells). (After Löffler.)	509
259	Typhoid swelling. (After Green.)	509
260	and 261 Medullary swelling	509
262	Medullary follicle	510
263	Follicle; sphacelus; dissection space	510
264	Typhoid ulcer	510
265	A typhoid ulcer of the intestine. (After Green.)	511
266	Ulcus depuratum; overhanging margins. (After Langerhans.)	511
267	Swelling of peritoneum. (After Langerhans.)	511
268	Typhoid infantum. (Langerhans.)	512
269	Medullary swollen follicles. (After Langerhans.)	512
270	Stages in Widal reaction. (After Robin.)	517
271	Transverse section of colon	524
272	and 273 Aphthous eruptions	525
274	Croupous enteritis, diphtheritic colitis. (Langerhans.)	526
275	Colon laid open. (After Langerhans.)	527
276	Bacillus diphtheriæ. (Drawing by E. L. Oatman, M.D.)	528
277	Friedlaender's pneumobacillus. (After Fraenkel and Pfeiffer.)	533
278	Diplococcus pneumoniæ. (After Fraenkel and Pfeiffer.)	534
279	Croupous pneumonia. (Ziegler.)	536
280	Delicate fibrin coagulum. (After Lenhartz-Brooks.)	537
281	Fibrinous hepatization. (After Langerhans.)	538
282	Isolated fibrin plugs from a fibrinous hepatization. (After Langerhans.)	539
283	Syphilitic hyperostosis of left femur. (After Ziegler.)	546
284	Syphilitic osteochondritis. (After Langerhans.)	547
285	Condyloma latum ani. (After Langerhans.)	548
286	Section from Fig. 285. (After Langerhans.)	548
287	Syphilitic cicatrices. (After Langerhans.)	549
288	Condyloma latum of the anus. (After Ziegler.)	550
289	and 290 Hepar lobatum. (After Langerhans.)	551
291	Syphilitic hepatitis in the newborn. (After Ziegler.)	552
292	Syphilitic arteritis. (After Ziegler.)	553
293	Interstitial interlobular fibrous pneumonia. (After Langerhans.)	555
294	Interstitial pneumonia and gummatous nodules. (After Langerhans.)	556
295	Alterations of the lungs in congenital syphilis. (After Ziegler.)	557
296	Mild discrete small-pox. (After J. F. Schamberg.)	559
297	Dermacentor occidentalis. Male. (Castellani and Chalmers.)	566
298	Dermacentor occidentalis. Female. (Castellani and Chalmers.)	567
299	Vincent's bacilli fusiformes and spirilla	572
300	Mild erythema. (From Bull. Ill. State Board of Health.)	579
301	Arachnoid and gyri. (After Langerhans.)	593
302	Calcified cerebral vessels. (After Langerhans.)	597
303	Sections of the cord at different levels. (Quain.)	601
304	Poliomyelitis. (After Ziegler.)	602
305	Miliary aneurisms in a cerebral vessel. (After Löwenfeld.)	609
306	Dissecting aneurisms on a cerebral artery. (After Löwenfeld.)	609
307	and 308 Calcified ganglion cells. (After Langerhans.)	613
309	and 310 Motor centers. (After Langerhans.)	617
311	and 312 Vertic section of suprarenal body. (After Eberth.)	620
313	Amyloid degeneration. (After Langerhans.)	621
314	Fibrinous pericarditis. (Orth.)	623
315	Fatty degeneration of the heart. (After Langerhans.)	626
316	Pigment atrophy of the heart. (After Langerhans.)	626
317	Fragments of the heart muscle. (After Langerhans.)	627
318	Striate fatty metamorphosis. (After Langerhans.)	628
319	Fragmentatio myocardii. (After Langerhans.)	628
320	Calcification of the heart muscle. (After Langerhans.)	632
321	Altered muscle	632
322	Myocarditic induration. (After Langerhans.)	632
323	Aneurism; myocarditis fibrosa; intact musculature	633
324	Aneurism of base of left ventricle. (After Langerhans.)	633
325	Carcinomatous embolus. (After Coffin.)	636
326	Embolus of epithelial cells in the coronary artery	637
327	Chronic fibrous aortic endocarditis. (After Langerhans.)	639
328	Incontinence of the aortic orifice. (After Langerhans.)	640

FIG.		PAGE
329	Marked stenosis of aortic orifice. (After Langerhans.)	641
330	Stenosis of aortic orifice. (After Langerhans.)	642
331	Thrombi	645
332	Endocarditis mitralis verrucosa. (After Langerhans.)	645
333	Dilation of the left ventricle. (After Langerhans.)	646
334	Aneurism of aortic valve	647
335	Endocarditis chordalis ulcerosa. (After Langerhans.)	647
336 and 337	Endocarditis mitralis traumatica. (After Langerhans.)	647, 648
338	Aneurisms of the aortic and mitral orifices. (After Langerhans.)	649
339	Epithelial layer lining posterior tibial artery. (After Schaefer.)	650
340	Transverse section of wall of posterior tibial artery. (After Schaefer.)	651
341	Fatty stellate cells from the aortic intima. (After Smaus.)	653
342	Endoaortitis chronica deformans	653
343	Endoaortitis chronica deformans. (After Langerhans.)	655
344	Endoaortitis chronica deformans gravis. (After Langerhans.)	656
345	Endoarteritis obliterans prolifera	657
346	Arneth theory	668
347	Superficial portion of human spleen. (After Kölliker.)	689
348	Thin section of spleen-pulp. (After Schaefer.)	689
349	Diagrammatic section of lymphatic gland. (After Sharpey.)	695
350	Medullary substance of lymphatic gland. (After Recklinghausen.)	696
351	Lobule of thymus of a child	698
352	Ciliated epithelium	701
353	Ending of bronchial tube in sacculated infundibula. (After Schaefer.)	702
354	Human respiratory apparatus. (After Duval.)	703
355	Emphysema. (After Langerhans.)	705
356	Interlobular interstitial emphysema. (After Langerhans.)	705
357	Emphysema of the lung. (After Smaus.)	707
358	Red induration of the lung. (After Langerhans.)	710
359	Coagulum in croupous bronchitis. (After Lenhartz.)	714
360	Curschmann's spiral with central thread. (After Lenhartz.)	715
361	Curschmann's spiral. (After Lenhartz.)	716
362	Spiral and Charcot-Leyden crystals. (After Lenhartz.)	717
363	Catarrhal pneumonia. (After Smaus.)	718
364	Purulent bronchitis and bronchopneumonia. (After Ziegler.)	719
365	Central hepatization of lobuli; bronchi	720
366	Central hepatization; atelectatic periphery; granular nodular surface	720
367	Pneumonia interstitialis fibrosa; lobuli	721
368	Pleuritis retrahens deformans; curled margin; basis of the lung	722
369	Pleuritis fibrosa; incision	722
370	Section of Fig. 369	722
371	Corpora amylacea. (After Smaus.)	723
372	Bronchiectasia multiplex congenita. (After Langerhans.)	726
373	Fat embolism of lung after fracture of bone. (After Langerhans.)	730
374	Fat-crystal needles, rosettes, and masses of cocci	731
375	Fat-crystal rosette	732
376	Focal pneumonia. (After Ziegler.)	733
377	Section of thyroid gland of a child. (After Schaefer.)	738
378	Basedow's disease. (After Beck.)	741
379	Tetany. (After Sheffield.)	747
380	Chronic catarrhal cystic gastritis. (After Langerhans.)	750
381 and 382	Faucial tonsils	757
383	Section through crypt of tonsil. (After Stöhr.)	758
384	Leptothrix and cercomonas. (After Lenhartz.)	759
385	Closed follicular abscess; burst follicular abscess; sinuous follicular ulcer	760
386	Follicle; polypus	760
387	Chronic proliferative gastritis. (After Langerhans.)	764
388	Invaginatio ilei in cecum. (After Langerhans.)	771
389	Stenosis carcinomatosa recti. (After Langerhans.)	775
390	Glandular polypus of the intestine. (After Ziegler.)	777
391	Villous papillary fibroadenoma of rectum. (After Kaufmann.)	778
392	Enterolith	785
393	Lobule of rabbit's liver. (After Cadiat.)	788
394	Section of a portal canal. (After Schaefer.)	789
395	Brown atrophy of liver. (After Langerhans.)	790
396	Two liver-cells with brown pigment. (After Langerhans.)	790
397	Marked congestion of liver. (After Langerhans.)	791
398	Section of liver with peripheral tubercles. (After Langerhans.)	793
399	Liver-cells with fatty infiltration and metamorphosis. (After Langerhans.)	793
400	Cirrhosis of the liver. (After Langerhans.)	795
401	Liver cirrhosis. (After Langerhans.)	796
402	Vena hepatica; central zone; intermediary zone; peripheral zone	800
403	Primary carcinoma of liver from bile ducts	801
404	Primary carcinoma of liver from parenchyma cells	803
405	Section from liver shown in Fig. 404	805
406	Same as Fig. 404, external surface	806
407	Cholesterin plates	807
408, 409, 410	Section of solitary cholesterin-stone. (After Langerhans.)	808
411	Polyhedral cholesterin-stones	809
412	Serrated pigment-stones	809
413	Solitary pigment-stone of morning-star form	809
414	Section of pancreas of dog. (After Klein.)	810

FIG.		PAGE
415	Pancreatic calculus. (After Langerhans.)	812
416	Section of kidney. (After Landois.)	815
417	Diagram of course of two uriniferous tubules. (After Klein.)	817
418	Epithelium from urinary tract	818
419	Blood-vessels and uriniferous tubules of kidney. (After Landois.)	819
420	Termination of parenchymatous nephritis. (After Langerhans.)	822
421	Pyelonephritis. (Case of Dr. F. M. Barden.)	828
422	and 423 Chronic interstitial nephritis. (After Langerhans.)	829, 830
424	Congenital cystic kidney. (After Langerhans.)	831
425	and 426 Renal concretions. (After Langerhans.)	832, 833
427	Hydronephrosis. (After Langerhans.)	836
428	Longitudinal and cross-section of renal tubule	837
429	Narrow hyaline casts. (After Peyer.)	838
430	Severe acute nephritis	839
431	Chronic Bright's disease	840
432	Epithelial casts. (After Peyer.)	841
433	Acute hemorrhagic nephritis	842
434	Large white kidney	843
435	Nephritis hæmorrhagica gravis. (After Langerhans.)	844
436	Uric acid infarct in a gouty subject. (After Langerhans.)	845
437	Hippuric acid, sodium urate, and uric acid	846
438	Displacement of the left kidney. (After Langerhans.)	850
439	Papillary adenocystoma of the kidney	851
440	Papillary cystadenoma of the kidney. (After Ziegler.)	851
441	Hypernephroma of the kidney. (After Ziegler.)	852
442	Oxalate calculi	855
443	Vesic calculus. (After Langerhans.)	855
444	Calcium oxalate crystals in urine	856
445	Crystals of triple phosphate	857
446	Feathery crystals of triple phosphate. (After Tyson.)	857
447	Ammonium urate processes	858
448	Hypertrophia trabecularis vesicæ. (After Langerhans.)	859
449	Renal tuberculosis. (After Burkhardt and Polano.)	860
450	Papillary epithelioma of urinary bladder. (After Ziegler.)	861
451	Papillary fibroma of bladder. (After Langerhans.)	862
452	Epithelial cells. (After Ziegler.)	863
453	Spermatorrhea and prostatorrhea. (From Lenhartz-Brooks.)	871
454	Hypertrophied prostate with concretions. (After Ziegler.)	872
455	Section of erectile tissue. (After Cadiat.)	876
456	Papillary erosion of portio vaginalis uteri. (After Ziegler.)	878
457	Section across the Fallopian tube. (After Schaefer.)	880
458	Section of ovary of newly born child. (After Waldeyer.)	881
459	Carcinoma of the ovary. (After Ziegler.)	882
460	Cystocarcinoma ovarii	883
461	Carcinomatous structure of tissue	884
462	Cystic degeneration of fibroid uterus	885
463	Papillary cystadenoma of the ovary	886
464	Same as Fig. 463. More highly magnified	887
465	Hyperplasia of the uterine mucous membrane. (After Ziegler.)	888
466	Proliferative villous endometritis. (After Langerhans.)	889
467	Hypertrophy of uterine muscle-fiber cells; degeneration of fiber cells	889
468	Successive stages of inversio uteri. (After Leishman.)	890
469	Tubal pregnancy	895
470	Beginning epithelioma of cervix uteri. (After Ziegler.)	897
471	Carcinoma corpus uteri. (After C. Keller.)	898
472	Placental polypus six weeks old. (After Ziegler.)	899
473	Section from a placental carcinoma. (After Ziegler.)	900
474	Section of human red marrow. (After Böhm-Davidoff.)	903
475	Fracture of the right humerus. (After Langerhans.)	906
476	Fracture of left femur and trochanter major. (After Langerhans.)	907
477	Connective tissue, nonbony union. (After Langerhans.)	908
478	Cartilaginous intervertebral fracture. (After Langerhans.)	908
479	Rickets. (After Ziegler.)	909
480	Normal and rachitic rib. (After Smaus.)	910
481	Rachitis. (After Langerhans.)	911
482	Rachitic costal cartilage. (After Langerhans.)	912
483	Lateral spinal curvature. (After Sheffield.)	913
484	Incurvation of the ribs. (After Langerhans.)	914
485	Rachitic scoliotic skeleton. (Grandin, Jarman, and Marx.)	915
486	Flat rachitic pelvis (mild grade)	916
487	Obliquely distorted pelvis of Naegele	917
488	Kyphosis of thoracic vertebral column. (After Langerhans.)	918
489	Gibbus from chronic caseous spondylitis. (After Langerhans.)	919
490	Top view of the fetal skull. (Grandin, Jarman, and Marx.)	922
491	Hydrocephalic skull. (After Langerhans.)	923
492	Malacosteon pelvis. (After Leishman.)	924
493	Right femur sawed through the middle. (After Langerhans.)	925
494	Beginning asbestoid degeneration. (After Langerhans.)	927
495	Arthritis deformans. (After Langerhans.)	929
496	Osseous ankylosis of the right knee. (After Langerhans.)	933
497	Zenker's waxy degeneration of musculature. (After Langerhans.)	935
498	Section through human epidermis. (After Böhm-Davidoff.)	941

FIG.		PAGE
499	Sweat-gland. (After Hedon.)	943
500	Acne rosacea. (After Ziegler.)	945
501	Epithelioma contagiosum in long diameter. (After Ziegler.)	950
502	Fatal fetal ichthyosis. (After Fischer.)	951
503	Granular ophthalmia. (After T. W. Jones.)	957
504	Trachoma. Frequent type seen in children	959
505	Pterygium tenue. (After Guthrie.)	965
506	Pterygium crassum. (After Guthrie.)	965
507	Symblepharon. (After Mackenzie.)	966
508	Congenital dermoid. (After Taliaferro.)	971
509	Congenital dermoid, showing hairs. (After Taliaferro.)	971
510	Epithelial cystoma of conjunctiva. (After Oatman.)	973
511	Arcus senilis. (After Canton.)	978
512	Hypopyon	984
513	Keratoconus	989
514 and 515	Annular scleritis. (After Oatman.)	1001, 1002
516	Posterior edge of scleral deposit. (After Oatman.)	1003
517	Relations of cornea, sclerotic, and iris. (After Waldeyer.)	1015
518	Perithelioma of choroid and ciliary body	1041
519 and 520	Metastatic carcinoma of choroid. (From Oatman.)	1042
521	Papillary cystadenocarcinoma of choroid. (From Oatman.)	1044
522	Atrophy of right optic nerve	1053
523	Carcinoma of optic nerve and retina. (From Oatman.)	1057
524	Diagrammatic section of human retina. (After M. Schultze.)	1060
525	Perpendicular section through upper lid. (After Fuchs.)	1081

LIST OF FULL-PAGE PLATES.

PLATE		FACE PAGE
I.	Intraphagocytic destruction of bacteria. (After Metchnikoff, in Annales de l'Institut Pasteur.) (From Sajous's "Internal Secretions.")	28
II.	Pernicious anemia	48
III.	Heart-lesion cells; fresh sputum preparation	56
IV.	1. Malaria plasmodia, tertian type. (After Lenhartz-Brooks.) 2. Malaria plasmodia, tropic form. (After Lenhartz-Brooks.) 3. Malaria plasmodia, tropic form; rings and crescents. (After Lenhartz.) 4. Trypanosomes. (After Lenhartz.)	408
V.	Cutaneous reaction, showing the various results with concentrated and diluted tuberculin. (After Fischer.)	438
VI.	1. Tubercle bacilli and Micrococcus tetragenus in sputum. (After Lenhartz-Brooks.) 2. Tubercle bacilli in spinal fluid of tuberculous meningitis. (After Lenhartz-Brooks.) 3 and 4. Actinomyces from abscess pus. (After Lenhartz.) 5. Anthrax bacilli, bacilli culture. (After Lenhartz-Brooks.) 6. Glanders bacilli in pus. (After Lenhartz-Brooks.)	484
VII.	1. Gonococcus in urethral discharge. (After Lenhartz-Brooks.) 2. Streptococcus and staphylococcus in pus. (After Lenhartz-Brooks.) 3. Cholera bacilli. (After C. Fraenkel.) 4. Influenza bacilli. (After Lenhartz-Brooks.) 5. Diphtheria bacilli. (After Lenhartz-Brooks.) 6. Pneumococci. (After Lenhartz-Brooks.)	522
VIII.	A. Common type of diphtheria. (After Fischer.) B. Follicular type of diphtheria. (After Fischer.) C. Hemorrhagic type of diphtheria. (After Fischer.) D. Septic type of diphtheria. (After Fischer.)	524
IX.	1. Spirochætæ pallida in smear from secretion of a fresh hard chancre. (After Lenhartz.) 2. Skin of a congenital syphilitic child, with Spirochæta pallida. (After Buschke.)	542
X.	Severe case of scarlet fever, showing eruption at its height. (After Fischer.)	560
XI.	Spinal fluid in alcoholic polyneuritis and progressive paralysis	594
XII.	1. Progressive pernicious anemia. (After Lenhartz-Brooks.) 2. Splenomyelogenous leukemia; enormous spleen tumor. (After Lenhartz-Brooks.) 3. Splenomyelogenous leukemia; marked spleen tumor. (After Lenhartz-Brooks.) 4. Acute leukemia. (After Lenhartz-Brooks.) 5. Myeloid leukemia. (After Lenhartz.) 6. Hemin crystals from dried blood-spots. (After Lenhartz-Brooks.)	676
XIII.	1. Myelogenous leukemia. 2. Lymphatic leukemia	680
XIV.	1. Uric acid crystals. (After Peyer.) 2. Uric acid crystals with amorphous urates. (After Peyer.)	846
XV.	1. Sediment of alkaline fermentation. (After Hoffman and Ultzmann.) 2. Ammonium urate, showing spherules and thorn-apple-shaped crystals. (After Peyer.)	858

BOSTON MEDICAL
APR 28 1927
LIBRARY

PATHOLOGY.

Pathology begins with the advent of abnormalities or deviations from physiologic processes, while normal (or natural conditions, functions, or) processes belong in the domain of physiology. The dividing line between physiology and pathology, however, is by no means sharply defined. The same process may be physiologic as well as pathologic. The difference between physiologic and pathologic processes is only quantitative. (See page 4.) Pathology (*πάθος*, *passio*[1]), as now understood, includes not only the domain of diseases (*νόσος*, *morbus*) properly speaking, but also the whole series of disturbances (*læsiones*), defects (*vitia*), the domain of etiology (*causæ*), and the regulatory, benign, salutary processes. **Nosology**[2] constitutes only a part of pathology;[3] it deals with that part of pathology in which the health of the individual is disturbed. For example, a stone in the gall-bladder unaccompanied by any symptoms or disturbances in health is simply a pathologic state and does not belong in the realm of nosology; if, however, the stone excites inflammation followed by violent pain and other subjective symptoms, the condition is both pathologic and nosologic.

General pathologic anatomy deals with the general laws of the pathologic processes occurring in all or most of the organs and tissues of the body, and offers a basis for general pathology.

Special pathologic anatomy gives a description of the deviations and structural alterations occurring in the individual organs.

Symptomatology. — The term symptom (*σύμπιπτω* = coincidence, to fall in with) signifies a phenomenon, a functional disturbance dependent upon, occurring synchronously with, and pointing to, disease. Symptomatology is the knowledge and interpretation of symptoms.

Diathesis (*διαθέναι*, arrangement, state; Latin, *constitutio*) signifies a pathologic state of the body; disease already is present in the body, but

---

[1] Suffering.

[2] *νόσος*, disease; *λόγος*, a discourse.

[3] According to the definition of ancient writers and also of the modern Greeks, pathology is the science of anatomic abnormalities or deviations from natural conditions and forms; nosology the science of morbid conditions or processes in the body, and physiology, as the name implies, the science of natural conditions and processes. Modern medicine has abandoned this distinction between the terms pathology and nosology, and the result has been much confusion.

need not necessarily be permanently manifest. Repeated marriages between relatives may bring certain diseases to a high state of development. In order to avoid progressive degeneration, crossing of the stock is necessary.[1]

Idiosyncrasy (ἴδιος, own; σύγκρασις, temperament) is a peculiar susceptibility manifested by certain individuals to influences which are innocuous or inactive in other persons. Examples of this are disorders following the ingestion of certain drugs (*e.g.*, morphine), shellfish (crabs), strawberries, etc.; hay fever; influence of certain odors (perfumes), etc. (See Anaphylaxis.)

NATURE OF DISEASE.

Disease is always something developing, something pursuing a certain course, embodying a series of symptoms, a sequence of conditions (*status*). Every disease, whether chronic or acute, continues for a certain length of time. *Status,* in contradistinction to *morbus,* is simply a state (*e.g.*, blindness) which ceases to be when the condition ceases, *i.e.*, no longer exists, no new condition resulting therefrom.[2]

The variable duration of certain diseases has given rise to the designations **acute** and **chronic.** It is impossible to say, however, what number of days, weeks, or months are to be assigned to the former or the latter. For example, typhoid is generally regarded as an acute disease, yet its duration is usually longer than a month. Therefore, the ordinary duration or the course of the disease in question must be considered. Diseases which, in duration, lie between the acute and chronic, are called **subacute** or **subchronic.** In certain instances

[1] Diathesis should not be confused with "disposition," which indicates the tendency to reception: the body is still free, though, as soon as opportunity offers, it very readily is attacked by disease.

[2] By *status* is understood the condition of the disease or of the individual at a certain time, for instance, *status præsens,* the present condition, or *status gastricus,* the condition of the stomach or abdomen. While the disease lasts, conditions may change from day to day or from time to time, as when one condition develops from a preceding one, or when one condition is the sequel of a favoring condition. There are certain laws under which these changes take place, and in such cases we speak of typical processes or symptoms or developments of disease. Typical means according to canons or laws; atypical is the opposite, *i.e.*, the sequence of conditions or symptoms contrary to rules, canons, or laws. Just as disease can never be separated from the diseased individual, *i.e.*, from the organism as a whole, so also a *status (vitium, malum,* etc.) should not be separated from the organism as a whole. Hence, the relation of blindness to the blind is thought of here in this connection. If, then, the "condition ceases," this signifies as much as "the blind ceases to be blind," in that he either dies or is made to see again, *e.g.*, by a cataract operation. Neither death nor the operation is a further condition proceeding from blindness, but both are something new which is independently added.

the separation into acute and chronic diseases is purposeless, because an acute disease may become chronic and *vice versâ*. The duration of a disease frequently depends upon the etiology; if the cause is not removed, the disease cannot subside.

Recidive is a recurrence or reappearance of a disease which had already subsided. It does not necessarily belong to the course of the disease. When it is the nature of the disease to recur, this phenomenon is called **relapse.** Examples are relapsing fever and malaria.

Under certain conditions diseases may pursue an **abortive** course, characterized by a shorter duration than usual and by less pronounced development of symptoms. Various infectious diseases may present an abortive course, *e.g.*, typhoid fever.

Prognosis is the foretelling, the prediction of the course or the event (termination) of a disease. Prognosis is possible only (*a*) by an exact knowledge of the disease itself; (*b*) by a thorough estimation of the state of the diseased body, and (*c*) consideration of the influence of treatment. Every prognosis is based upon an exact diagnosis; but as the diagnostic basis is sometimes erroneous, prognosis also may be incorrect.

Conditions which originate from, and merge into, each other follow certain laws. They are termed typical the more they are subject to fixed laws. Type is the general law (rule) derived from the totality. There may be deviations from the type.

There are three principal groups of elementary activity which are peculiar to life: 1, the nutritive; 2, the formative, and, 3, the functional processes.

1. Essential for the maintenance, the self-preservation, of the cells is nutrition, *endosmosis* (a nutritive, trophic, chemic process), upon suspension of which death occurs. The simple interchange of material does not, however, suffice for the support of nutrition. On the contrary, the process of self-maintenance, the replacement of waste, occurs only within the cells by the formation there of the characteristic tissue substance: assimilation. The elimination of used material is designated as *exosmosis*. There are also brought to the cells materials which are not assimilated, and others used which are not eliminated, but retained.

2. The constructive processes (formative, plastic, anatomic) depend upon proliferation—new formation—in that two new young cells originate, as a rule by division, from a pre-existing mother cell, nothing remaining over.

3. Function (physiologic process) is always an exteriorly directed activity which is influenced from without.

The whole domain of vital activity is divided into these three groups of elementary activity. They also form the basis for the consideration of general pathology and therapy.

If a disturbance occurs, *i.e.*, a disease condition or an abnormal process, it relates either to a negation of one of the three just-named vital activities (*signa mortis*) or to quantitative alterations of the same. Thus, in nutrition an increase or a decrease (excess, defect) may appear. Likewise, in regard to function, a part either ceases (temporarily or permanently) to functionate (*e.g.*, paralysis) or the function is diminished (paresis) or increased (convulsions). The body cannot perform its functions in a foreign or heterologous manner. The same holds good for the formative processes. In a strict sense, therefore, there is nothing heterologous: All pathologic processes are homologous to the physiologic; the difference between the former and the latter is only quantitative.[1] Disease, therefore, is nothing *sui generis.*

From this a very simple classification of the elementary processes follows. There may be: 1, absolute deficiency; 2, relative deficiency, and, 3, an excess. Those processes in which a deficiency (a minus, defect) exists constitute the passive processes in a strict sense; those in which a plus of normal activity (a diseased action) is present form the active processes. Notwithstanding this distinction, the same diseases may originate as the result of active and passive events. The differentiation of these processes depends, first of all, upon the cause.

For a vital activity (*actio*) to become manifest, certain excitation[2] is required. This is produced by an external action, an irritation, *i.e.*, by an irritant element (*corpus alienum, irritans*) of a chemic, physic, or organic nature, which first causes an altered state, a more negative, passive state of excitation (*irritamentum*) of the living parts. This is followed by a more active process,[3] a positive participation of continuous parts, which is designated as irritation (*actio, irritatio*). Irritation, then, is only the result of the action of the *irritamentum, i.e.,* of the altered state of the parts of the body which, until then, were either normal or in a disease-predisposed state (*locus minoris resistentiæ*). It consists in an increased activity, in a more intense intrinsic disturbance, excitation of the living parts. No *actio* occurs, therefore, without preceding *irritamentum,* and, hence, every *actio* can be called irritative.

In the elementary processes various *stadia* are differentiated. In

[1] These remarks refer only to the elements. The processes as a whole are mostly very complicated, because a large number of elements (and not in like manner) are concerned.

[2] In contradistinction to dead parts, only living parts are excitable.

[3] The active processes only are caused by an irritant; not the passive. Therefore, the *principium dividendi* for active and passive processes is "irritation."

the active processes the *stadium invasionis,* the stage in which the *corpus alienum* attacks the body, is followed by a *stadium latentiæ,* and following this the *stadium incrementi* (the rise), which continues to the acme (in the passive processes there is no *stadium incrementi,* but only a prolonged depression); in the acme the process can last for a variable length of time. Following this is the *stadium decrementi:* the decline. This, strictly speaking, is not a part of disease, although it is reckoned, along with the combined processes, as belonging to the terminations (*exitus morbi*).

Disease, in a practical sense, is more than one elementary process; it is usually a sum of such. According as the elements are similar or dissimilar, the process is a *morbus simplex* or a *morbus compositus.* If, for example, all cells of the neuroglia undergo fatty metamorphosis, we obtain a *morbus simplex:* the yellow softening of the brain; summing up the elements, the whole process can be more readily recognized. If, however, dissimilar parts near each other are affected, then the different varieties of tissue must be examined. If, for example, in the liver, in addition to the liver-cells, the connective tissue or the vascular system also is morbidly altered, this is a *morbus compositus.*

Morbus multiplex is somewhat different. By this is meant that the same affection occurs in several distantly removed parts of the body. A *morbus multiplex,* therefore, can be a *morbus simplex* as well as a *morbus compositus.* All diseases have one focus (*locus*) or several foci (*morbus multiplex*). Except these foci, the remaining parts of the body are in a relatively normal condition.

By *morbus complicatus* (complication) is meant the coexistence of two diseases. Complication is not a necessity, but only an *accidens* added to an already existing disease. Many diseases, however, predispose in a higher degree to other affections than do the remaining disorders. Measles and typhoid fever may be complicated with pneumonia; tuberculosis with amyloid degeneration of certain organs; cirrhosis of the liver with gastric carcinoma, etc. Practically, it is not always possible to separate complications from sequelæ, since the latter not infrequently develop from the former.

Sequelæ are diseases which become manifest after the subsidence of, but often possess a connection with, the primary affection. Examples are paralyses and cardiac failure after diphtheria, endocarditis after articular rheumatism,[1] tracheal stenosis after cicatrization of syphilitic ulcer of the trachea.

The termination of a disease may be death (*exitus letalis*), healing (*sanatio*), or secondary diseases (*sequelæ*).

[1] Endocarditis may be also a complication of articular rheumatism.

The term **healing** is an exceedingly broad one. The majority of healings are defective (*sanatio incompleta*), and may finally be the cause of death. Therefore, the case as a whole must always be differentiated from the condition in the individual parts. Of the latter a great deal can be destroyed and still the case as a whole may be looked upon as healed. This explains, for example, the expression: "healing by retrogressive metamorphosis," in which the retrograde metamorphosis or, in other words, "death" relates only to certain parts, while healing relates to the organism as a whole.

GENERAL ETIOLOGY (CAUSÆ).

In considering etiology, it is necessary to take cognizance not only of the acting element, but also of the body upon which the *corpus alienum* exerts its action; for the same cause, *e.g.*, a "cold" excites entirely different diseases in different individuals. Therefore, the external cause (*causa externa*) must be distinguished from the internal cause (*causa interna*); togther they constitute the causal relation. The various relations are distinguished by the fact that the *causa interna*—*i.e.*, the condition or state of the affected organism—as opposed to the *causa externa* (*e.g.*, gunshot wounds) is occasionally pushed into the background, and *vice versâ*.

Within the organism there is a certain ordering (constitution) which reacts more to certain, otherwise indifferent, external influences than to others. This diversity in the intrinsic ordering of parts is the basis of the whole organization of the higher animals.

For example, not every individual endures change of climate: many succumb; some become acclimated. Change of climate is always a considerable strain upon the organism and renders it more susceptible to a number of diseases. Constitution alone explains the variable behavior of the body toward climatic changes.

Causa externa, therefore, frequently is an exciting cause—*causa occasionalis*—while *causa interna*, which is correlated with the intrinsic constitution of a cell or a sum of cells, is manifested as the *causa prædisponens* (predisposition, weakness, tendency, susceptibility to external influences, pathologic predisposition, or *Anlage*).

The relation between *causa externa* and *causa interna* may be thought of as purely mechanic (traumatic, physic, dynamic), chemic, thermic, electric, or physiologic.

The point of action of invasion (*locus invasionis*) constitutes the *atrium* of the disease. This may be also the seat of the disease (*sedes morbi*), or serve only as a portal of entry.

The **causæ externæ** are divided into two great groups:—

I. Living causes (*causæ vivæ*):—

1. Animal organisms.

2. Vegetable organisms.

II. Inanimate causes:—

1. Physic (or mechanic) causes: The coarser actions (injuries, wounds, pressure of clothing, etc.)—the mechanic causes in a true sense—are differentiated from the actions of a more delicate nature, which are called dynamic (*e.g.*, change of air pressure in caisson workers on rapid passage from a chamber containing compressed air under a pressure of about 2½ atmospheres into a chamber with a pressure of 1 atmosphere, or in aëronauts at high altitudes, in *commotio cerebri*, etc.).

2. Chemic causes: These act by atoms leaving their combinations and uniting with other atoms to form new combinations. The extreme cases of this nature have received special names. For example, the local action of certain chemic substances upon the tissues is called corrosion. On the other hand, if a chemic substance enters the circulation and exerts its action at a place remote from the original point of contact, this is called poisoning, intoxication. These terms have little significance, since corrosion also, especially when it threatens life, is frequently called intoxication. Potassium and sodium hydrate, mineral acids, arsenic, lead, chlorine, phosphorus, corrosive sublimate, alcohol, ether, aniline, hydrocyanic acid, carbolic acid, chloroform, iodoform, atropine, ergotine, cocaine, morphine, and others act as poisons. To these may be added the products of bacteria, injurious gases (pit-gas or mine-gas, carbon monoxide, carbon dioxide), and deficiency of oxygen.

The same chemic substances may be in one case a poison, in another case a therapeutic agent. The greater the absolute quantity or the more concentrated the solution in general, the more intense, as a rule, are the toxic effects.

We have but little positive knowledge of the specific action of poisons. Probably they are taken up by those tissues upon which they act, by entering into chemic union with them. Thus, silver nitrate, used externally, is a caustic; administered internally in small and long-continued doses it causes argyria, being deposited in the rete Malpighii, etc. Since poisons circulate in the blood throughout the body, their action, however, being exerted only upon specific parts, it is assumed that for certain substances there are organs of predilection which are designated as *loci minoris resistentiæ*. Upon these premises, namely, that different substances do not act in the same manner upon all parts of the body, but stand in intimate relation to individual organs, also rests the employment of remedies.

3. Thermic causes: Action of high and very low temperatures: burns by steam, boiling liquids, glowing heat, flame; further, sunstroke and heatstroke, chilling by intense cooling of the body or individual (usually tapering) parts. In sunstroke, irritation of the cerebral meninges with hyperemia and edema occur as the result of direct action of the sun's rays upon the head. Heatstroke occurs as the result of overheating of the body, particularly because the regulation of the body heat by evaporation (sweating), by lack of water, inappropriate clothing, marching in closed columns, etc., is disturbed or prevented.

General or local action of **cold** (chilling) produces an increased disposition to certain affections, especially rheumatic, catarrhal, and other inflammations. The effects of chilling, exerted principally upon the external skin and respiratory organs (also the digestive organs), are often manifest in parts entirely different from those parts of the body directly affected by the cold, and occur especially in localities with a *locus minoris resistentiæ*. A certain personal disposition also plays an important rôle. For example, in one individual, catarrh of the respiratory passages readily develops, in another intestinal affections, and in others articular affections or muscular rheumatism. They probably are in great part due to reflex circulatory disturbances, which produce a disposition to these affections. In many infectious diseases the connection with chilling has so frequently been demonstrated that the disposing influence of cold, especially as regards the action of already present, but previously non-pathogenic bacteria, cannot be doubted.

4. Electric causes: Lightning and high-tension electric currents. Alternating currents are more dangerous than direct currents of the same intensity and tension. In very intense action death may occur suddenly or within a few minutes. Usually, though not always, death is preceded by unconsciousness. The final cause of death is paralysis of respiration. If death does not occur, nervous disturbances persist for some time, but these usually finally disappear. At the point of contact (point of entrance) of the current with the body, the same phenomena as in burns are usually observed.

5. Physiologic (or biologic) causes: Here belongs, *e.g.*, overexertion—fatigue—which may attack every organ and reduce or even paralyze its function, and, furthermore, a great number of mental diseases.

Internal Causes (*causæ interna s. prædisponentes*). — The susceptibility to disease is either originally present in the body (congenital predisposition) or acquired later in the course of life (acquired predisposition). The congenital are either inherited: hereditary, or such as the individual has acquired during the embryonal

period: intra-uterine acquired, *e.g., endocarditis fœtalis.* These two groups are to be sharply separated.

Hereditary predisposition is called **constitution,** inasmuch as it is assumed that individual differences exist in the intrinsic adjustment of cells. If an individual is insusceptible to certain diseases, this state is called immunity. (See Infection.) This may be either hereditary or acquired. Certain domestic animals (*e.g.*, the horse) possess an hereditary immunity to tuberculosis, while others (cats, cattle, rabbits, guinea-pigs) always manifest an extreme susceptibility (hereditary predisposition). Certain classes of animals, *e.g.*, rats, manifest, like man, a relative immunity to tuberculosis, *i.e.*, some appear predisposed; others, more or less immune. In many cases immunity, especially relative immunity, may be reduced or abolished by unfavorable conditions (faulty nutrition, insanitary surroundings, diseases, etc.): acquired disposition.

Immunity to a particular disease may be acquired after recovery from a single attack of this disease. Thus, one attack of certain infectious diseases (scarlatina, measles, variola) generally (not invariably!) confers a certain degree of protection against subsequent attacks. On the other hand, the disposition is in many instances increased by one attack (diphtheria, *intermittens,*[1] etc.).

In contrast to general disposition stands local disposition, *i.e.*, the tendency of certain organs to become affected in a specific manner in different diseases (organ disposition). For example, in scarlatina the kidneys are frequently very seriously altered (*nephritis parenchymatosa hæmorrhagica*), while in other acute exanthemata they appear to be either unaltered or affected only to a very slight degree. In malarial diseases the spleen is chiefly and often exclusively the seat of anatomic deviations (spleen tumor). The alterations in typhus abdominalis involve especially the follicular apparatus, principally the follicles of the intestine; in lesser degree those of the spleen, mesenteric glands, and often the remaining follicular apparatus, *e.g.*, of the tongue, tonsils, etc.

Analogous to this local predisposition there is also a local immunity, which, however, is more frequently relative than absolute. Experience has shown that, for example, tubercles are very rarely observed in the *panniculus adiposus,* and that in the liver, where

[1] The colored races possess a certain degree of immunity against *intermittens,* while the white races in general are very greatly disposed to it. Plehn distinguishes in the natives of Africa "absolute" and "relative" immunity. The latter can be secured by Europeans by systematic use of quinine ("artificial immunity"). In this event the malarial parasite, as in (naturally immune) natives, is sometimes found in the blood without the occurrence of fever. (See Malaria.)

they frequently are found, they are almost always extremely minute, generally invisible to the naked eye, and undergo but slight retrogressive metamorphosis.

The cause of local predisposition is in many instances still wholly obscure. The advances in bacteriologic research, however, justify to a certain extent the assumption that in affections induced by bacteria the local chemic state of the tissues exerts a determinative influence. The tissues furnish nourishment to the bacteria, *i.e.*, offer a more or less appropriate soil for the different bacteria. If the tissues offer a soil favorable for this or that species of bacteria, the latter are then capable of multiplying and exciting organic alterations; if, on the other hand, the tissues present a more or less unfavorable soil, then either no or only slight organic alterations occur. In some cases these organic alterations are preceded by slight lesions which weaken the tissues and render them less resistant. This relation between internal and external noxious influences, in other words, between *causa interna* and *externa*, is especially prominent in syphilis. The specific changes caused by syphilis (gumma) occur principally in those parts (tibia, forehead, *lig. suspensorium hepatitis*, etc.) which, in consequence of an injury (blow), have suffered alteration or enfeeblement of the tissues.

HEREDITY.

Those tendencies, qualities, or peculiarities transmitted by parents to their children and grandchildren are present in the spermatozoid or ovulum before conception. Heredity, therefore, is the transmission of certain peculiarities present at the time of fecundation.

On the other hand, all anomalies traceable to influences exerted at a period subsequent to union of sperma and ovulum, *i.e.*, during intra-uterine life, belong to the group of intra-uterine acquired or congenital alterations. (See p. 9.)

In heredity the question is one either of conditions which are visible at birth (*e.g., vitia primæ formationis:* supernumerary fingers) or of peculiarities recognizable very soon after birth (pigmentation of the skin in the colored races), or, finally, of tendencies or anomalies which become manifest only in later life. In the latter category belongs the phenomenon that in some families certain talents (*e.g.*, for music, etc.) are inherited or totally lacking, and here also belong the so-called hereditary diseases. The latter designation is not quite correct, since not the disease, but only the disposition of the tissue or cells for certain affections (*e.g.*, tuberculosis) is inherited (hereditary predisposition, see p. 9).

Hereditary transmission may extend either to all offspring and unlimited to many successive generations (*e.g.*, racial peculiarities which constitute the type of the race[1]), or there is no definite law, so that only certain descendants and occasionally only the males or the females—and these not uniformly—possess the same peculiarities or anomalies as their progenitors. Heredity is sometimes manifested by skipping of several generations—a phenomenon which suggests atavism.[2]

Hereditary racial peculiarities are, *e.g.*, the color of the skin (accordingly are distinguished a black, brown, yellow, or white race); the character and color of the hair (black, curly, wooly hair of the negro; blond, flowing hair of the white race); form and color of the eyes ("slit-eyes" of the yellow race); shape and aspect of certain parts (*e.g.*, of parts of the face: straight nose of the Greeks; arched nose of the Romans; flat nose of the negro; low forehead and thick, prominent lips of the negro); size and form of the body; proportions of the limbs, etc.[3] Inherited also are malformations: excessive and defective formations (atrixia, hypertrichiasis, nevi, polydactylia, and others). Finally, many diseases or the predisposition to these diseases are inherited, especially mental diseases, hemophilia, tuberculosis, gout; less frequently and constantly color-blindness (Daltonism),[4] cataract, myopia, arteriosclerosis, progressive muscular atrophy, polyuria; probably also tumors and rachitis. On the other hand, syphilis does not belong to these so-called hereditary diseases, for congenital syphilis is in every instance the result of intra-uterine infection.[5]

---

[1] Exceptions occur here also.

[2] By atavism is understood discontinuous transmission, *i.e.*, the reappearance of anomalies or traits manifested by more or less remote ancestors, especially in animal descendency. Examples of atavism in man are the occurrence of supernumerary mammary glands (*polymastia*), nipples (*polythelia*), ribs, etc.

[3] In the determination of racial peculiarities it is often difficult to decide whether some of the characteristics attributed to the race, such as the hair, color of the skin, form of the facial bones, belong to it originally and under all conditions, or whether they have developed only under external conditions under which, through centuries and millenniums, the generations were perpetuated and now appear as racial peculiarities.

[4] This affection, as in hemophilia, is observed chiefly in males. It is transmitted also through daughters who are not color-blind. Dalton, an Englishman, was color-blind.

[5] On the basis of investigations upon 100 children and 100 placentas in which serologic examinations had been made, J. Trinchese (*Münch. med. Woch.*, 1910, No. 11, p. 570) states that the spirochætæ of syphilis occur most abundantly in the suprarenals, then in the liver, lungs, ovaries, testes, spleen, the fetal end of the funis, and also with relative frequency in the blood. They are relatively rare in the placenta, which they enter through the blood-vessels of the villi. They readily penetrate the walls of these vessels without producing coarse alterations of the tissues, enter the stroma of the villi, and may migrate even to the surface of the villi. They produce decided tissue changes in the syncytium, manifested by displacement of nuclei and nodular thickenings. This migratory process of the spirochætæ from the vessels of the fetal villi through the villi stroma to the surface of the villi and into the intervillous spaces is regarded by Trinchese as normal.

IMMUNITY.

The relation of a living being to the various elements of its environment, which may in one or other way be regarded as harmful, is invariably one of resistance; and where this resistance is of relatively high grade it is spoken of as immunity. Where, however, the degree of resistance is relatively low, the term susceptibility is used; and as an expression of extremely low ability to resist a given harmful influence, it is frequently said that the individual manifests an idiosyncrasy toward such influence. There is thus clearly rather a quantitative than an essential qualitative difference between the conditions—a matter of how much resistance can be opposed to the noxious agency. Immunity or susceptibility is to be understood as prevailing in relation to any sort of agency, and the terms may with no impropriety be applied to physic or chemic influences, to animate or inanimate pathogenic causes. A man may possess a high immunity toward the harmful effects of electricity or of heat, a susceptibility to some drug, an immunity to the microbic cause of a given infection, an idiosyncrasy to the influences of dust particles inhaled. But in a more particular sense, which, unless otherwise explained, is here to be understood in the employment of these terms, immunity and susceptibility are applied to the grade of resistance which an individual is capable of manifesting toward animate agents or their products concerned in infectious diseases.

It has long been known that an efficience of resistance may characterize the individual naturally (natural immunity), the factors granting such immunity being inherent and not the result of intravital acquirement; and, on the other hand, that, although not existing *ab initio,* a capable degree of resistance may in one or other way be acquired (acquired immunity). Immunity is spoken of as absolute (complete) where a given infection is not acquired even under optimum conditions; or as relative (partial) where it is not acquired

---

It is remarkable, however, that the placenta of live-born children contain much fewer spirochætæ than those of macerated children. On the other hand, it is a noteworthy fact that the detection of spirochætæ in the blood of adult syphilitics is very difficult. Finally, it is an open question whence the spirochætæ so abundantly present in the organism of the child originate. An overwhelming by the spirochætæ of the ovulum to be fertilized is regarded as impossible, because of its size. Pure paternal transmission without infection of the mother is also to be excluded; for the spirochætæ must be either located in the heads of the spermatozoids—then the latter would die; or only mixed with the sperma and enter the germinal cells—then either the germinal Anlage would be entirely destroyed or only malformations would result. Accordingly, it must be assumed that in paternal syphilis the mother also is infected at the time of fructification and from this source infection of the fetus results.

with the usual facility by the individual in question, or where, if acquired, it does not manifest the intensity of effect usually characterizing the particular micro-organisms. From the standpoint of temporal duration of immunity it may be met as p e r m a n e n t, lasting throughout life; or t r a n s i e n t, enduring only for a mediate period. We are accustomed to recognize, particularly in connection with natural immunity (without exclusion, however, of all manifestations of acquired forms of resistance), r a c i a l (s p e c i f i c) immunity, f a m i l i a l immunity, and i n d i v i d u a l immunity, as the special resistance to a given infection characterizes races (species), families, or individuals. Probably no better example of the first could be adduced than the immunity enjoyed against anthrax by Algerian sheep, while among other ovine species a high susceptibility prevails to the same infection; and the difficulty commonly met in transmitting a number of diseases of man to the lower animals, and the frequently seen immunity of man to infections common to the latter are, of course, illustrative of the same idea. In a general way, racial immunity in naturally allied species is apt to be but relative, as may be appreciated in the fact that in reality the negro race, certainly at least in early life, is frequently infected by malaria, although popularly supposed to be highly immune. (See Malaria.) Familial immunity is much more difficult of exemplification, since family strains are subject to constant modification by marital laws and customs, and it is more easily appreciated by contrasting the more frequent evidence of family susceptibility to given infections, as tuberculosis, with the less frequent occurrence of the same affection in other picked family groups (although such illustration is by no means satisfactory, because of the numerous chances for confusion, from the particular proximity of the source of infection in the diseased member of the family to the rest of the group, and similar elements of chance). It has been proved, too, by experimentation that an immunity acquired by a mother may, in at least some degree and duration, be transmitted to her offspring, although the grade of immunity is by no means uniform in the latter. Individual acquired immunity is common, but there is, too, as just indicated, an individual natural immunity.

Members of the same family, not appreciably differing in other respects, may show a very marked difference in their ability to resist a given infection to which they have been exposed in common and apparently equally. So, too, in a series of inoculations in animals one not infrequently meets with refractory individuals whose resistance cannot be certainly explained by the presumption of acquirement.

While immunity in reality rests upon the possible co-operation of a large number of factors, recent studies have been especially directed

toward certain internal cellular and humoral phases; and in this relation particularly, the terms active and passive immunity have been introduced. The first is characterized by the active production of immunizing substances in the body of the individual; a production which is often permanently manifested, although not necessarily. The second may depend upon a number of inherent physical characteristics of the body, or may be dependent upon the artificial introduction into the subject of efficient immunizing substances elaborated elsewhere, these inducing some grade of protection during the period of their retention, but not reproduced. This last is, therefore, characteristicly of but transient value.

In infection and subsequent pathogenesis the specific micro-organism must have in some way gained access to the tissues in a susceptible individual, and in some cases at least must, in one or other way, find in such individual a proper habitat, in which situation it must develop, and by its presence and activities induce the changes which become manifest as the symptoms of the disease. Theoreticly, these effects may depend upon one or all of the following items: Just as any nonvital particle by its presence may induce mechanicly some degree of irritation and thus cause an inflammatory reaction, a similar influence may be presumed as existing from the presence of animate micro-organisms, and this may vary in importance and intensity with the distribution and number of the microbes.

In occasional instances—as in anthrax embolism of the smaller blood-channels—occlusion of more or less important passages may be determined. Whether there is ever an abstraction by the invading microbes in their life activities of matter essential to the host, is doubtless usually negligible; but possibly, also in such a disease as anthrax, where the blood contains large numbers of bacteria with aërobic requirements, it may be granted that some effect is brought about by the abstraction by the bacteria of some of the oxygen needed by the tissues for proper metabolism.

By far the most important pathogenic item of infection, however, is the effect of the poisons or toxins elaborated by the pathogenic micro-organisms or produced under their influences from the body substance of the host. (See Infection.)

In interception or antagonism of any of these features, the factors of immunity manifest themselves; these possibly constituted of simple provisions, perhaps of ordinary structure or function, or in more intricate way involving the biochemic problems of life.

The following table, while incomplete, gives a general idea of the different kinds of immunity:—

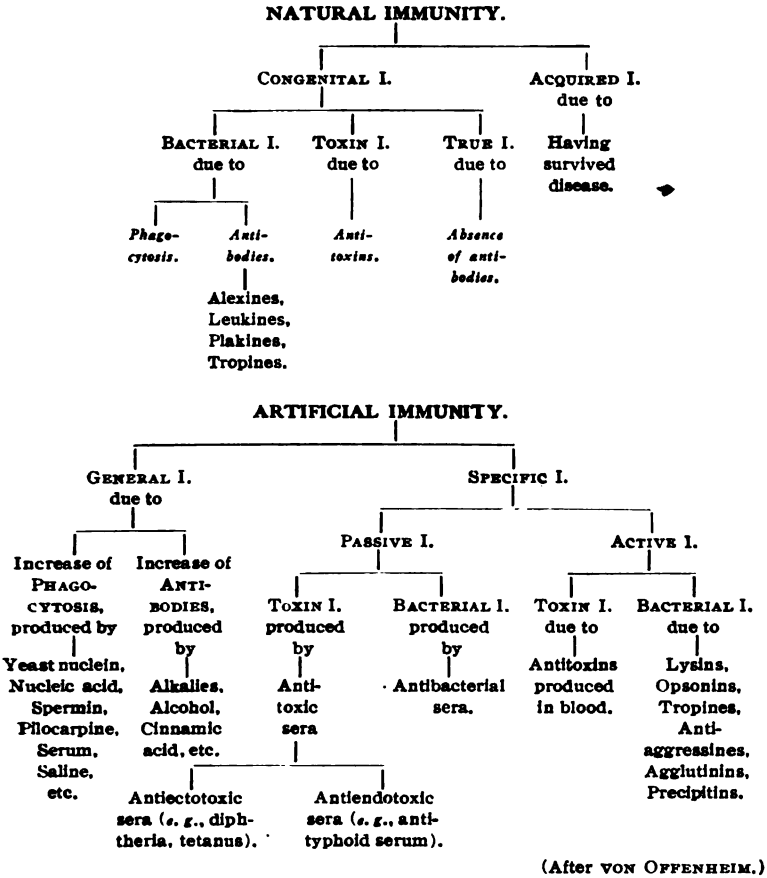

(After VON OFFENHEIM.)

Simple factors in the protective mechanism of the body against infectious diseases. While at present the attention of experimenters is particularly directed along lines of theories explanatory of discovered cellulohumoral phenomena in connection with immunity, there should not be overlooked another series of factors which, undoubtedly, are widely operative in securing to this or that individual or species protection against the invasion of microbes or their products. These, in their entirety, constitute a wide group which it is undesirable in the scope of this volume fully to develop, but brief reference to some should be made with a view of fixing the need of their recognition as often of fundamental value.

Primarily, there can be no doubt of the relative efficiency of the skin and various membranous coverings of the tissues to protect against the invasion of microbes into the interior structures. The

danger of infection through lesions of the skin, from the merest abrasions to grosser wounds, is well understood, and no one who works in the autopsy room fails to appreciate the aid afforded by proper rubber gloves in lessening the danger of infection through unappreciated points of break of the epidermal covering of the hands. It is true that infection through the skin often follows exposure even when no recognizable lesion exists in the cuticle, probably mainly because of the retention of germs in such natural places of accommodation as the hair-sheaths and ducts of the skin-glands and their subsequent growth, invasion, or penetration into the subepithelial tissues. Even though, without known lesion, the possibility of the passage of bacteria through the mucosa and, in fact, the entire wall of the alimentary tube be freely admitted, and at the same time the existence of other than the purely mechanic barrier offered by the lining membrane of the tube be recognized, it is impossible to ignore the fact that, as yet, no such special antimicrobic substance has been demonstrated in the mucosa of the intestine in sufficient amount to explain the necessarily high immunity of the wall to the hordes of bacteria present in the lumen of the tract, and we are forced to regard the lining membrane, for the time at least, as mechanicly interfering with the penetration of the organisms into the tissues.

While, on the one hand, the effectiveness of these protective membranes may in a variety of ways (existence of hyperemia as favoring phagocytic convection of organisms from the surface into the deeper tissues, or the existence of special irregularities of the surface affording crypt-like positions for special lodgment and development of germs) be depressed, there equally exist in normal life a number of factors which may be thought of as augmenting their protective value. The constant shedding of epithelial scales from the surface of the epiderm not only rids the cuticle of its dead elements, but insures the removal of such micro-organisms as may be attached to these separating cells. The secretion which bathes the mucous membranes may be thought of in this connection: the hydrochloric acid of the gastric secretion, for example, serving as a more or less efficient antimicrobic agent, and destroying many of the organisms which are constantly being conveyed into the stomach; antibacterial power is known in the case of the urine, and doubtless an analogous influence is possessed in at least a low degree by other secretions. The prevalence of definite currents over surfaces exposed to microbic contact must be reckoned as no mean factor in dislodging the microbes and relieving the part threatened by their presence. Thus, the lachrymal secretion flowing over the conjunctival surface carries along not only particles of dust which have come into contact, but living germs as well, and the movement of the intestinal contents by

peristaltic activity leads to the complete discharge from the body of vast numbers of bacteria, indefinite retention of which within the bowel might well lead to harmful results. The protection which nature has provided for the lower respiratory passages and pulmonary structures includes a series of more or less effective arrangements for the prevention of convection of bacteria and other particles by inhalation to the air-vesicles. Over the surfaces of the passages there is constantly at least a thin layer of viscid mucus, by which microbes may be fixed when thrown in contact in inspiration, and, charged with such adherent harmful agents, this mucus may, from time to time, be dislodged and carried away, as by blowing the nose, coughing and expectorating, or by swallowing. The arrangement of these mucus-covered surfaces by foldings (turbinate bones), by anatomic adjustment (as in the obtusely angulated relation of the broad pharyngeal surface to the relatively horizontal plane of air inhaled through the nose), and by branching (the branching of the bronchial tubes) bespeaks an almost certain impact of these particles in inhalation upon the mucus, and insures the detention of the vast bulk of them and an equivalent purification of the air thereby. The special provision of ciliated epithelium in the bronchial tubes and trachea, with the well-known upward current of the mucinous moisture on the surface induced by the sweep of the cilia, adds to the probability of expulsion of these foreign elements by bringing them with the mucus in which they are imbedded to a level where cough and expectoration become effective. The loss of current of the air as it approaches the vesicles allows the settling by gravity of the germs upon the mucous membrane of the tubules, and the current of mucinous material just referred to tends to their removal.

So, in various parts of the body, mechanisms of more or less analogous type exist in the anatomic structure and adjustment of our parts, bearing upon this primary exclusion of bacteria and other harmful particulate agents, and thus constituting an elementary protective factor. This phase of the subject is almost axiomatic; and, clinically, a close relation between the augmented chance of infection with fault of these provisions is frequently demonstrable, and is essentially to be reckoned as increasing in important grade the ports of entry for infections.

It is well known that not every micro-organism may find, after introduction into an animal body, its requisite habitat and the optimum conditions for its development. Were this not true it might logically be supposed that many species of animal life would be equally susceptible to the known pathogenic germs, and that in fact the range of infection would be vastly increased by the probability of saprophytes and saprozoa frequently assuming parasitic rôles. For a number of microbes there is an optimum location within the susceptible host, which should be reached

before the chain of events known as infection is complete; a location in which the conditions appropriate for their development and for the operation of their harmful products prevail. There are many instances in which the bite of a rabid dog is not followed by rabies in the victim, without remedial vaccination or special treatment of the original wound. It is true that there may be exceptionally active resistive power to explain such examples, but whatever the cause there is at least equal reason to presume that the infectious agents may not be conveyed from the site of inoculation to the neural cells. That tetanus bacilli are more likely to produce tetanus when introduced into deep penetrative wounds than when brought into contact with the tissues in superficial and open lesions; that the cocci of meningitis may be found in the nasal secretion when there is no evidence of their presence in the cerebral meninges, as well as other similar examples, bear out such a supposition.

It may well be that at the site of inoculation, in relatively unimportant locations, the organism may find conditions sufficient for its needs and live, but that its dissemination to a more vulnerable situation may be prevented by the inflammatory encapsulation which it has induced at its primary position. In a given animal a microbe of definite parasitic demands may fail to receive the optimum temperature for its development—a feature which Pasteur called out in his experiments in inoculating hens with anthrax, or which probably, in some measure, is explanatory of the differences seen in the inoculability of different animals with piscian, mammalian, and avian strains of the tubercle bacilli. The availability of aërobic or relatively anaërobic conditions in different sites of inoculation may similarly be appealed to, and just as there is demanded for special micro-organisms a fair nicety in the composition and reaction of culture media in the laboratory, there is equal probability that the composition of the pabulum afforded by different species may, in important measure, determine the susceptibility or non-susceptibility of a given animal to a special type of microbe proved to be virulent at least to some group of animals. Failure of appropriate conditions in any such mode, whether of location in suitable position or in important part of the system, or in obtaining favorable circumstance of temperature, oxygen requirements, or a proper pabulum, may materially interfere with the reality of infection, or with the relative grade of effect, if actually established.

These latter items are not far removed from the biochemic features of immunity and susceptibility, and too dogmatic conclusions as to their precise part in the result are not advisable; but, however interlinked with more clearly appreciated factors in the establishment of resistance, they cannot be refused at least scant mention.

Biochemic Factors in Immunity.—It is well known that in addition to natural resistance against infection, upon which the previously considered factors bear the more appropriately, an immunity of varying completeness and duration may be acquired by an individual either as a postinfectious protection (natural acquired immunity) from the same infection or as the result of inducement by one or other of a number of purposefully directed measures (artificial acquired immunity). It is similarly recognized that a natural resistance is, by a variety of circumstances, liable to reduction to a grade where the potency of resistance becomes susceptibility. These phenomena constitute the more striking features of the subject, and are underlaid by active physiologic reaction, and the processes concerned make up true immunization in contrast to mere protection by physical construction. They concern not only the freedom from infection seen in selected individuals, but are the potent factors in the limitation of infectious diseases. Through their intervention, in spite of the failures which are constantly possible in the protection afforded by the physical means thus far discussed, implanted pathogenic micro-organisms may be destroyed early enough after introduction into the system to prevent their development and their influences, or by the same mechanism the severity of their effects may materially be reduced and their duration in the body be limited ("self-limitation of infectious diseases").

For the explanation of the phenomena common to the infective diseases and of the limitation of the malady and the acquirement of postinfectious resistance, there are at least two modes of resistance which may be considered: chemic and cellular.

A. Chemic Factors in Immunity.—1. Of the older theories attempted for acquired immunity, the so-called "abstraction theory" supposed that each type of pathogenic germ required for its growth some special material which it found in the makeup of the susceptible individual, and that in the course of the disease this specific material was completely used, so that continuance of the special microbic growth necessarily came to an end because of this deficiency, and that, at least in some instances, such special pabulum was never re-formed and, consequently, the same host could no longer support the particular type of microbe should it subsequently be introduced. Natural immunity was thought due to the natural absence of such special pabulum from the constitution of the immune race or individual. The clear lack of support and the introduction of proven foundations for other speculations have caused the complete relegation of this idea.

A second of the older theories offered the idea that each type of pathogenic micro-organism during its active growth and persistence in the body of its host produced some substance which is essentially antagonistic to the microbe itself; that this material by its accumulation restricted the duration of the microbes, and if retained inhibited growth upon subsequent introduction. There may be claimed a thread of continuity from this older suggestion to our own present views.

2. It has been known from of old that an attack of one or other of the infectious diseases successfully withstood may confer upon the subject an immunity against subsequent infection by the same malady, varying in its completeness and ranging from permanency to but brief duration, and that in a general way full health is more protective against the acquirement and severe results of infection than imperfect health, and that the age of the subject and a long series of other factors play some part in the general matter of liability to these diseases. The work of Jenner in vaccination against small-pox, and more recently of Pasteur against chicken-cholera, anthrax, and rabies stand out with special prominence among the earlier discoveries. Since 1880 the activity of study has made of the intervening period the richest in results in the appreciation of facts, in the elaboration of satisfactory explanations, and in effective warfare against these affections. Bouchard's work, in 1884, in showing the development of protective substances against cholera in the body of an infected individual, should be granted fundamental value. Shortly after followed the recognition in the blood of naturally existing protective principles by Fodor, Hankin, Behring, Nuttall, and others—substances to which at the time Buchner, who likewise contributed, gave the name alexins. Nearly contemporaneously came evidence from Salmon and Smith, Brieger and Kitasato, Roux and Yersin, and others that a heightened resistance follows not only an actual attack of a given infection, but that it may be induced by proper introduction into the subject of the diffusible products of microbic growth—the toxins diffused in the culture fluid (exotoxins) or simply extracted; and the recognition that, besides the ordinary diffusible toxins, it is necessary to take into account the toxins which are not easily diffused, but are retained within the bacterial body until its disintegration (endotoxins), soon offered an acceptable explanation for refractory instances in the application of the principle. In 1888, first, Richet and Hericourt demonstrated that the blood-serum of animals immunized against pyogenic cocci confers to other animals to which it is transferred a protective value against the same strains of bacteria.

By these and other basic studies and a vast contribution of confirmatory results there has, therefore, been established the fundamental idea

that infecting micro-organisms induce their specific effects by the production of a group of chemic substances of harmful import to the body known as toxins, and that in response to the appearance of these materials specific antagonistic materials (antibodies) are developed by the infected organism, and it rapidly came to be realized that the phenomenon of destruction of bacterial bodies by solution by the blood-serum (bacteriolysis), shown originally by Flügge and Nuttall, is based upon the same or closely allied principles. Later, too, the fact that not only are microbic toxins neutralized (antitoxic effect) and bacteria destroyed (bacteriolysis), but also cells introduced into a foreign species (cytolysis); the poison of a few higher vegetables (ricin, etc.), of snakes, and of some of the insects are equally able to excite similar specific reactions, and there is strong reason for belief now that like principles attend the intricate processes of nutrition and the modes of dealing with waste and detritus of the system. If not by identical, at least by analogous interaction, other phenomena, as the flocculation of bacteria and foreign cells (agglutination) and the precipitation from solution of dissolved proteid substances (by precipitins), are included in this same category.

The precise nature of toxins of the infectious organisms is not known, mainly because of the difficulty of their isolation from the admixed albuminous and other substances derived from the medium in which the germs are grown and from the microbic bodies. Many substances which are doubtless produced are probably nonspecific, and probably only the minor bulk may be in any case supposed to be truly specific. They are dialyzable, precipitated by alcohol and ammonium sulphate, and may be modified in their toxic qualities by age, exposure to light and air, to heating, or to the action of various chemicals.

As a general term, the word antigen[1] has been coined to indicate any substance which, when introduced into the living organism, excites a specific immunizing reaction with the formation of antibodies.

At present the most common acceptance regards this process of immunity as a truly chemic one, obeying definitely chemic laws, as expressed in the elaborate theory of Ehrlich, known as the "side-chain theory"; but there is a strong countercurrent of opinion which would not accept Ehrlich's views in their entirety and which, while accepting a basic idea of chemic change, would refer some of the features to physic combinations—adsorption rather than true chemic union (Bordet) fitting the molecules for actual chemic interaction.

---

[1] ἀντι, against, and γίγνω, I produce; a term coined from the prefixes of the two words antibody and generator.

Ehrlich's theory: Ehrlich, taking the well-known ring of the graphic formula of some organic compounds, as the benzol molecule, for argument, supposes each living molecule to be made up of groups of atoms or single atoms in analogous structural relation. The central and most important element or molecule, a primary molecule for the compound in each case, he speaks of as the vital center of the molecular structure (vital nucleus). Linked to this by valence bonds of affinity are secondary, but important, groups of atoms or "side chains" offering unsatisfied valences for combinations or possibility of substitution-combinations in the structure. To these side chains the name receptor[1]

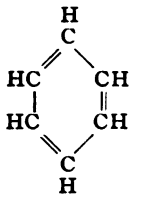

Benzol C_6H_6

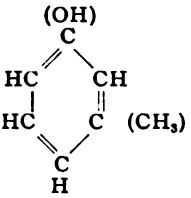

Metacresol $C_6H_4(CH_3)(OH)$

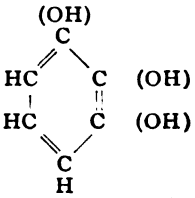

Pyrogallic acid $C_6H_3(OH)_3$

is usually applied, and, where it is supposed that no other function than that of combination of an extraneous molecule is effected through such a receptor, the name haptophore[2] may be employed. The essential character of the molecule, however, resides in the dominant central "vital nucleus." Similarly, he supposes the molecule of an antigen to be constructed so that it may present at least an haptophoric side chain with proper affinity and valence for combination with a receptor of the host molecule, while in addition it contains or is made up of other groups which, when linked to the host molecule, may induce in it special harmful or other effects. Typically, a toxin contains, according to this idea, a haptophore side chain (haptophore) suited in affinity and valence for combination with a receptor belonging to the host molecule, and of a molecule of toxic ability (toxophore[3]), by which it induces harm to the molecule with which it is linked. It is well known, as above stated, that from age, from chemic, and sometimes physic influences, toxins may lose their power to some degree and yet be capable of inducing protective reaction. It is this which has led Ehrlich to accept the idea of the essential duality of the haptophoric and toxophoric functions of the toxin molecule, and he applies the term toxoid to those toxins which have naturally, or from purposeful change, lost this supposed toxophoric

[1] Part of a molecule of protoplasm having the power to attract and combine with a molecule of food proteid, toxin, etc.

[2] ἅπτειν, to seize; φορεῖν, to carry.

[3] τοξικόν, poison; φόρος, to bear.

moiety. Contrasted, too, with typic toxins, analogous molecules with less affinity and with slower combining ability, or less power of maintenance of combination, are spoken of as toxons or epitoxoids. Ehrlich supposes that when the haptophore of a toxin unites with a receptor of the host molecule its harmful action may be restricted to the receptor

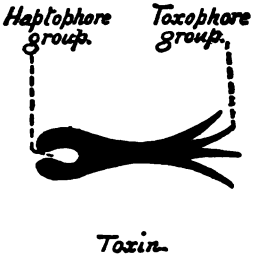

Fig. 1.—The toxin molecule, showing the haptophore (combining) group and the toxophore (poison) group. (After *Ehrlich.*)



Fig. 2.—Showing the combining groups (receptors) of the cell. (After *Ehrlich.*)

itself or the toxophore may enter more widely in its effects upon the whole molecule, affecting finally the vital nucleus of the molecule and destroying the whole group. If this latter result ensues, molecular degeneration and disintegration are fixed upon the cell of which the molecule

Fig. 3.—Haptophores and toxophores united with the cell, causing intoxication. (After *Ehrlich.*)

is a part, the process merely repeating itself sufficiently to vitiate and finally destroy the cell; and, eventually, according to the importance of the affected cells or the extent of the same process through the body of the host, somatic life is endangered or ceases. If, on the contrary, the vicious effect of the toxin be expended merely upon the linked molecular receptor, the essence and vitality of the molecule remain. Weigert's theory of the prodigality of natural repair is now appealed to, Ehrlich holding that the damaged molecule repairs its lost receptor by the forma-

tion of an excess of identical receptors at the location of loss, this continuing thereafter for an indefinite period. From lack of accommodation room upon the original molecule these excessive receptors are cast free, and as such are distributed in the body fluid, still suited for the combination with the same type of toxin molecules and of thus preventing them from working the harm which would follow were the latter to combine with the cellular molecules of the host. In this free state,

Fig. 4.—First stage of antitoxin formation. Toxin molecules attached to receptor. (After *Ehrlich.*)

in the sense that they antagonize toxins by neutralizing them, they constitute the familiar antitoxins. These, according to Ehrlich's views, represent the simplest type of receptors (Receptor I of Ehrlich), and are illustrated by the antitoxins which are in common use in the treatment of diphtheria, tetanus, and of a number of other infections. Theoretically, they should neutralize only the toxins of the infection, and

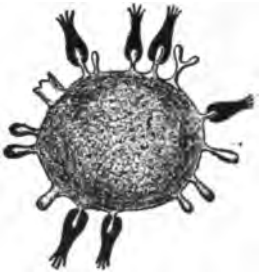

Fig. 5.—Second stage; reproduction of receptors. (After *Ehrlich.*)

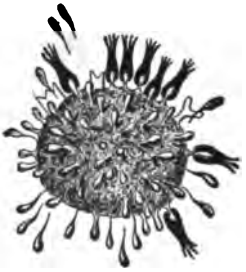

Fig. 6.—Third stage; receptors leaving the cell. (After *Ehrlich.*)

should not possess any other antagonistic features (as toward the prevention or limitation of growth of the specific microbes in the host). As a matter of fact, however, in actual use this true preventive and curative feature is well established in addition to the major antitoxic ability, thus opening the question of the verity of the order in Ehrlich's scheme or of the coexistence with the antitoxin of other orders of receptors. Clearly, however, in the course of an infectious case the neutralizing

value of such free antibodies in the fluids of the subject is operative, reducing the intensity of intoxication and hastening recovery when the actual microbic life is depressed or destroyed in the stage of decline of the disease.

Ehrlich recognizes as a more complex type of receptors a second group (Receptors II) concerned in the phenomena of agglutination and precipitation (agglutinins and precipitins). In the well-known Bordet reaction of precipitation the antigen introduced into the animal is a dissolved albuminous material—as the albumin of the blood-serum from a foreign species—the power of flocculation and precipitation of such material developing after repeated injection. Thereafter, if to the serum of the prepared animal a solution containing the special albumin used for injection be added, the latter is separated from solution and



Fig. 7.—Fourth stage; receptors (antitoxin) free in the blood-plasma. (After *Ehrlich.*)



Fig. 8.—Neutralization of toxin by antitoxin. (After *Ehrlich.*)

forms a definite precipitate. The antibody here developed (precipitin) is regarded by Ehrlich as made up of more than merely a freed combining side chain, more than a simple receptor such as antitoxin. It should be made up of at least a haptophore group, by which it attaches to the albuminous molecule, and a zymophoric[1] group, throwing the molecule of albumin out of solution and causing sedimentation. Because of the fact that precipitating power may be destroyed in the precipitin-containing serum by appropriate heating, and because of the analogy to the coagulating ferments in curdling milk and in blood-coagulation, the peculiar moiety of the precipitin molecule is tentatively regarded as of enzymic nature. Serum which has thus been deprived of its precipitating activity may have the altered precipitin fixed in saturation to the receptors of the albuminous molecules so that the subsequent addition of active precipitins no longer avails to bring about the phenomenon, which is comparable to the similar action of toxoids in relation to toxins.

[1] ζύμη, leaven; φόρος, to bear.

Agglutinins (as operative in the Widal reaction or in hemagglutination) are considered as analogously made up of a haptophore side chain and an agglutinophore, the former serving for attachment to the receptors of the molecular structure of microbes or foreign cells against which the subject has been immunized, and the latter also tentatively regarded as of enzymic nature and inducing in the cells changes fitting them to adhere in groups. Bordet criticises the assumption of this second order of receptors upon the question of its necessity, believing that by the mere adsorption of a suitable simple receptor colloidal changes may be induced in the molecular structure of the bacteria or foreign cells and the dissolved albumins, so that electrolytes (salts) in the solution may induce the agglutination and precipitation.

To explain the actual destruction of microbes in the course of an infection, and the active prevention of development of the same germs in case of subsequent introduction into the body, Ehrlich assumes a third order of molecular receptors (Receptors III), becoming, when freed in the serum, active in the following manner as complex antibodies. As pointed out above, one of the early observations utilized in our ideas of immunity indicated the natural existence of bacteriolytic substances in the blood-serum of animals, and again the increase of bacteriolytic power in the subject in the postinfectious period. Such substances destroy bacteria by changes of erosion and vacuolization, which argue digestion (bacteriolysis), and similarly destroy in specifically immunized animals various foreign cells which have been introduced (cytolysins, hemolysins, splenolysins, nephrolysins, etc.), are evidently the old "alexins" of Buchner, and are essentially the true "immune body."[1] They do not, however, exist in the individual as a single substance, but are formed from two potential elements, the complement and the specific amboceptor, the latter being the proper receptor and stabile on heating, the former a nonspecific material tentatively regarded as an enzyme and thermolabile. The complement is common to the fluids of all animals and at all times, and, although probably not absolutely uniform, may for the present occasion be so regarded, and may be substituted in experiment when inactivated by age, exposure to heat, or other means, by complement derived from any immune or nonimmune animal. It is thus not the specific element in the combination, although it is evidently the active destroying agency in lysis or disintegration of formed antigens. Ehrlich's theory supposes the specific element in the destructive reaction to be a compound receptor having at least two haptophoric side chains or receptors, one of which

[1] Term here used in the same sense common among German writers, and not, as often in England and this country, as synonymous with the specific amboceptor.

is exactly suited in valence and affinity (haptophore) for fixation to the molecular structure of the specific microbe or other foreign cell in question, the second adapted for fixation to the complement molecule (complementophore). It thus serves the purpose of binding together the antigen and complement in such manner that the ferment-complement may act upon and digest the molecules of the former, and eventually disintegrate the whole antigen. The amboceptor or double receptor has been designated by a number of terms, and some confusion and no little mental bother have been occasioned thereby. The fact of its specificity and its necessity, therefore, in actively immunizing the subject against a given infection has, with no impropriety, led to its designation as the immune body, the sensitizer, *substance sensabilitrice, desmon,* intermediate body, and fixative. Amboceptors presumably exist naturally in the serum of animals, accounting in part for the phenomenon of natural immunity; for the bactericidal power seen in selected examples of nonimmunized sera; for the hemolytic ability of certain normal sera for the blood-cells of certain foreign species, and other analogous phenomena, and their presence in excess in immunized sera may thus be referred to the same profuse re-formation after such normal side chains have been fixed and destroyed by the bacteria of an infectious disease or other antigen, as appealed to in the formation of antitoxin.

Here, too, the same type of tentative objection is raised. Is there necessity for presuming the existence of such special complexity? Is it not possible that even simple receptors of appropriate combining power may, even by physical adsorption, rather than definite chemic combination (the latter, of course, possible), so alter the antigen molecular structure that it is fitted for the subsequent action of the complement always present? But whatever objections may be raised it is certain that the presentation of Ehrlich's theory has greatly stimulated study and, as a working explanation, has gained a strong hold on the profession.

According to this view, natural active immunity depends upon the normal existence of amboceptors in the blood, which serve to prevent the infection from development by bringing into effective relation with its micro-organisms the ferment-like complement to accomplish bacteriolysis. Should such amboceptors be deficient at the outstart of the infective course, they are presumed to develop in efficient quantity as the molecular regeneration of these complex receptors proceeds in its course, and the definite limitation of the disease is believed to be established through their agency. Operating with the bacteriolysins in the course of the affection, the excessively produced simple receptors or antitoxins aid in important degree by neutralizing the toxins generated by the mi-

crobic growth. Both, but with particular reference to the amboceptors, continuing to be generated by the cells of the subject after the disease has run its course, are, by their presence, believed to safeguard the individual from further influence by the same type of micro-organisms (post-infectious active immunity). The applications of the theory to an artificially or experimentally acquired immunity is also to be considered.

B. Phagocytic Theory.—Contrasted with the above, but at the same time with certain evident relations, is the phagocytic theory of Metchnikoff, which ascribes the destruction of bacteria and other formed antigens to the power of the leucocytes and other cells to englobe these elements and destroy them by endocellular digestion. These cells, appropriately named phagocytes or devouring cells, include principally the leucocytes, endothelial cells, and occasionally also others. The polynuclear leucocytes—the microphages—are held chiefly active in the destruction of bacteria, and the other types—macrophages—as concerned particularly with the destruction of animal cells introduced into the system, or of cells belonging to the system, but requiring disintegration and removal. The phagocytes are believed to be attracted by a positive chemotaxis to these elements, or to be repelled by a negative chemotaxis, a relation which becomes heightened and persistent by the repetition of activity after experimental immunization, or after the natural course of an infective disease. The destruction of the englobed antigen is believed to be accomplished by enzymes which are developed and retained within the phagocytic body (perhaps in minor degree found in the serum as the result of destruction of phagocytes). Collectively, these digestive materials are spoken of as cytase.[1] Metchnikoff accepts the idea of another and probably specific material emanating as a diffusible product of the phagocyte, playing the part of a fixative, and in more or less degree responsible for the phenomenon of attraction. This substance in the serum is supposed to act upon the antigen (bacteria, etc.) without, however, impairing its integral structure or vitality, so as to fit it for the action of the cytase. Its possible relation with amboceptor and with Wright's opsonin[2] may thus easily be brought into question.

The basis for this theory is firmly fixed in the well-known englobement of bacteria and other foreign cells by leucocytes and other cells of the experiment animal after their introduction into the serous cavities, intravenously, or into the tissues of the subject, and in well-established increase of phagocytic activity after repetition of the experiment. Metchnikoff at first held that the latter—this readiness of attack—might

[1] κύτος, cell, and ase; cell-ferment.
[2] *Opsono*, prepare food for.

PLATE I



Intraphagocytic destruction of bacteria. (After *Metchnikoff,* in Annales de l'Institut Pasteur.) (From Sajous's "Internal Secretions.")

be thought the result of the educative acquirement of appreciation of an antigen repeatedly encountered, an acquirement passing continuously to new phagocytic elements in some manner. This suggestion, however, never obtained any acceptance, and only after the adoption of the idea of a specific fixative or when Wright urged upon the profession his opsonin was there believed to have been assumed a proper scientific theory explanatory of the phagocytic phenomena, which had so certainly been demonstrated by Metchnikoff and his pupils. There is no clear explanation offered by the theory for antitoxic immunity, but there is reason to believe that closer study will show a relation. At least by introducing into a suspension of living leucocytes containing known eosinophilic proportion, toxins of diseases known to be accompanied by eosinophilia, Allen J. Smith has found the proportion of cells showing granules of this type distinctly increased, from which, tentatively, arises the conclusion that these granules (and possibly the neutrophilic and basophilic granules of other cells) are in reality not hereditary characteristics, but are of intravital development under toxic stimulus, and may thus represent antitoxic products. Whether diffused or freed in globular form after destruction of the cells (phagolysis) is uncertain; but at least the possibility of their contribution to the antibodies of the serum is not thus far shown impossible.

1. Artificial Acquired Immunity. **Vaccination.** — The first evidence of the purposeful transmission of an immunity was Jenner's vaccination against small-pox, accomplished by inoculating the unprotected subject with a virus obtained from the cow affected with cow-pox. For a long time this remained unparalleled until, some eighty years later, Pasteur showed that by utilizing for inoculation a strain of anthrax bacilli known to have had their virulence depressed by culture at a temperature above the optimum a similar resistance may be induced in previously susceptible animals.[1] Following the general principle of utilizing specific micro-organisms of lowered virulence for the production in the unprotected individual of a mild course of the disease in question, it is sought to have developed by the somatic reaction specific antibodies, which, by their subsequent presence in the system, will guarantee an active protection against the same disease. The measure is analogous to the old habit of inoculation of human beings with virus from cases of small-pox during the prevalence of mild types, naturally selecting the least intense cases as the source of the virus and timing the inoculation to coincide with periods of good general health of the indi-

[1] Chicken cholera vaccination by Pasteur really preceded, old cultures deteriorated by exposure forming the vaccine; but in case of anthrax the definite purpose of heating to diminish virulence furnishes a clearer example.

vidual to be inoculated. It is likewise analogous to exposure of healthy, unprotected children to others suffering lightly from measles during epidemics of characteristic mildness. The artificial depression of virulence of the specific germs is accomplished in a variety of ways (in a general way by modifying their conditions of life), as by culture at an excessive temperature (anthrax); by passing them through resistant hosts (small-pox in the cow to the production of vaccine, or by passing anthrax through guinea-pigs); by reducing the moisture of their medium of growth and, perhaps, inspissation of the germs themselves (as in the preparation of the supposed antirabies vaccine, or that of symptomatic anthrax); by varying the oxygen available in cultures or by addition of restraining chemicals to the culture medium (anthrax); by exposure to light and air (chicken cholera, etc.). Active immunity may be induced, too, by inoculation of specific organisms killed by trituration, or heating or other means (as in the familiar opsonic vaccines of Wright, or the cholera and plague vaccines of Haffkine, etc.), and, presumably, the identical reactions follow in all these cases, varying in degree, but leading to the formation of antibodies and to special facilitations for phagocytic activity.

Opsonic vaccination, as introduced by Wright, contemplates a special augmentation of phagocytic destruction of the germs of a given bacterial disease. Metchnikoff's original idea of phagocytosis assigned all increases in phagocytic activity to the phagocytes themselves. Wright and Douglass, however, by comparing the activity of leucocytes in serum and of washed (serum-free) leucocytes, have shown that normal serum, even if nonbacteriolytic, must contain a material which greatly aids in the process of phagocytosis, and by comparative experiments after introducing killed bacteria recognize in the latter operation a method of increasing this facilitating material, which, in a general way, is specific for the organisms experimented with. It is clear, too, from their experiments that this substance acts not upon the phagocytes, but rather upon the bacteria, preparing them in some way for the phagocytes. This material these authors denominate opsonin (that which prepares the antigen so as to attract phagocytes and render its destruction more easy). An analogy may be inferred to the fixator of Metchnikoff. What relation opsonins bear to the Ehrlich antibodies is not clear because of our imperfect knowledge. The practical application lies in the fact that, by appropriately repeated injection of killed cultures derived from an already prevailing and resistant infection (as in furunculosis), the opsonic attraction of the living bacteria in the subject is increased, and thereafter phagocytic destruction of the living infection is facilitated.

It should be added in passing that it has been suggested that certain substances may be found which stimulate phagocytes into activity. They are spoken of as stimulins, but their character and even their existence is uncertain. On the other hand, Bail, from experiments showing that mixtures of sterile tuberculous exudate and living tubercle bacilli injected into the peritoneal cavity of experimental animals are rapidly fatal, while the same ingredients injected separately are not fatal, believes that there are substances which, acting upon bacteria, increase their virulence. These he speaks of as aggressins, and there is a suggestion that the leucopenia of certain severe cases of infective diseases may, in some way, depend upon these.

Experimentally at least, another type of vaccination is possible, although in practice little development has been accomplished. This is a method depending upon the inoculation of the susceptible individual with minute amount of ordinary virulent bacteria of the disease in question, with appropriate repetition with increasing quantities of the same germs. The underlying purpose is that of stimulating the cellular reactions by dosages of bacteria distinctly lower than the known minimum lethal quantity. The inherent danger of failure of accurate estimation of quantity and danger of noninhibited incubation make the method one of doubtful utility, even though in experimentation it is of suggestive promise.

2. Artificial Passive Immunity.—The introduction into the system of antibodies of any type, formed elsewhere and not by the active agency of the body elements of the individual to be protected, may, for the period during which these substances are retained unchanged, grant protection against their specific antigens; but with their modification by the body constituents or their excretion by one or other route, the protection disappears and there is induced, of course, by their presence no active production of similar substances. On the contrary, production of material antagonistic to themselves or their vehicles of transmission may be apprehended. However, during the period of their persistence the presence of antitoxic and antibacterial elements is of distinct value to the otherwise insufficiently protected subject. The use of antitoxin for diphtheria illustrates the subject fairly. A suitable animal—the horse—is highly immunized by repeated intravenous injection of gradually increased amounts of the toxin of diphtheria free from diphtheria bacilli, derived by filtration from cultures. The development of antitoxin in the serum of the animal is from time to time tested against a known toxin, and when sufficiently heightened the animal is bled and the serum containing the antitoxin separated from the clot. This serum constitutes the commercial antitoxin. The minimum lethal dose of toxin being determined

(the smallest amount killing with certainty in four or five days a guinea-pig of 250 Gm. weight), the antitoxin is standardized in its dosage, upon the arbitrary basis proposed by Ehrlich, that one unit of antitoxin should neutralize precisely one hundred minimum lethal doses of toxin. In practice it is found that from age deterioration the toxicity of toxins diminishes with greater rapidity than does the antitoxic value of antitoxic serum, at least in the dried state; and, therefore, a recognized antitoxin is utilized as a standard of comparison for the determination, first, of the toxin, with its epitoxoids, against which then the unit value of the fresh antitoxin is standardized.

The antitoxin is therapeuticly administered for the purpose of neutralizing toxins which are developing in the course of the specific infective disease, and both logically and in practice must, for its best effects, be employed early in the affection, before opportunity for combination of these poisons with the somatic molecules has been followed by resultant degenerations and necroses. Its purpose is essentially curative. Yet in practice there is also recognized a preventive value, indicating the coexistence of antimicrobial or inhibitive elements as well, although this feature is by no means to be relied upon.

In this connection there has arisen a realization of a practical danger appearing upon repetition of serum injection in the occurrence of occasionally rapidly fatal results ascribed to the serum itself. More frequently skin eruptions, dyspnea, and other uncomfortable or alarming but nonfatal symptoms have been encountered as manifestations of this so-called "serum disease." (See p. ***.) From the work of Rosenau, especially, there has come to be recognized in this phenomenon a possibility of sensitization of the subject to the foreign serum, spoken of as anaphylaxis.[1] It is particularly brought out if primarily a very minute amount of the serum is injected, followed after appropriate interval by ordinary dosage. While not clearly understood, it is thought that the toxic results depend upon the existence in the proteins of the serum of at least a certain amount of a veritable poison (allergin) combined with nontoxic haptophorous elements; that a special facility of attaching the latter is developed by the exhibition of small dosage, and that when later large doses are introduced this combining facility insures increased combination of the toxic moiety with the molecular receptors of the host.

Welch has urged that if the toxins and microbic bodies (antigens) produce a special resistance in the body of a susceptible host there should logically be developed a similar resistance (and, therefore, viru-

[1] ἀνα, privative; φυλάσσω, I guard.

lence) in the microbes themselves by reaction to these antagonistic factors, and it may be suggested that this possibility may well underlie the well-known fact that increase of virulence in strains of bacteria is known to follow their passage through special animals or their cultivation on special culture media.

The immunizing influence of drugs, as of quinine, as a protective and remedial agency for malaria, mercury in syphilis, the nontoxic arsenic preparations in trypanosomiasis, is omitted as scarcely suited to the present discussion, although it unquestionably has an appropriate bearing upon the question. The question of mutual antagonism of micro-organisms, too, is here passed over, because, although there are a few data which are suggestive of promise, nothing of sufficient value is known of the subject to make the presentation profitable.

In *résumé* it may be said that both passively and, to some extent, actively the individual is naturally protected by structural and physiologic mechanisms, as by membranous coverings of tissue and by the influence of natural or not materially modified secretory and other functions; that if, in spite of such provisions, pathogenic micro-organisms should gain access to the internal structures of the body there is a possibility that unfavorable conditions for development may prevail, and that for at least a number of organisms the n a t u r a l phagocytic ability of the leucocytes or other cells, and the n o r m a l presence of suitable chemical antibodies, may effectually inhibit growth; and that in event of pathogenesis there are by biochemic means induced antibodies, part effective against cellular antigens (bacteriolysins, cytolysins), and part effective against the poisons of the disease (antitoxins), and that in each a definite factor of specificity prevails. Effectual operation of such agencies means the limitation of established disease, and explains the expected postinfectious immunity; and the transmission of these agents from an immunized to a susceptible individual grants a transient and passive immunity to the latter as an artificially induced condition.

DISTURBANCES OF THE CIRCULATION.

HYPEREMIA.

By **hyperemia** is understood distention of the blood-vessels with blood beyond the ordinary volume. Every overdistention of the vessels is preceded by dilation of the vessel lumen. Dilation of the lumen may depend upon:—

1. Paralytic states of the muscularis (*tunica media*) of the arteries and veins;

2. Atony[1] of the walls of the arteries, veins, and capillaries;

3. Organic alterations of the constituents of the walls of the arteries and veins; or it is:—

4. Purely passive.

Paralytic dilation affects only those areas of the vascular system which possess a muscular layer; consequently, the capillaries are never involved. It depends upon the vessel nerves and is produced by paralysis (or section) of the sympathetic (vasoconstricting gray nerve-fibers, vasoconstrictors), or by irritation of cerebrospinal nerves (*i.e.*, of the so-called vasodilators).

Atonic dilation is dependent upon nutritive disturbances, whereby the nutritive tension of the vessel wall or of certain parts (in the arteries, veins, and capillaries) is diminished or abolished by nutritive disturbance.

The organic alterations upon which dilation of the lumen depends consist essentially in growth. The intima especially is apt to be involved, although the cause is usually an organic alteration of the media. The proliferation upon which the growth depends causes persistent, permanent dilation of the vessel lumen. The physiologic analogue of this alteration is the dilation of the vessels of the uterus during pregnancy. Permanent ectasis affects either the arteries (*arterioctasia* or *aneurysma*) or the veins (*phlebectasia* or *varix*); it is either limited (local) in extent or it involves large areas of the vascular system.

Passive dilation occurs not only as a result of increase of blood-pressure upon the inner surface of the vessel wall (by augmentation of the so-called lateral pressure), but also as a result of diminution of the pressure exerted upon the external surface of a vessel. In the former instance all parts of the peripheral vascular system are quite

[1] *Tonus* is the inherent nutritive tension of all living parts.

uniformly altered; in the latter, chiefly the veins and capillaries are altered, because the arteries, owing to their richly muscular walls, are more resistant.

The dilation and increased filling of the vessels cause the intense redness of hyperemic parts. In this respect they may resemble parts in which an increase of vessels has occurred as a result of new formation (vascularization), and, on the other hand, they may easily be mistaken for parts in which hemorrhages (hemorrhagic infiltrations) have occurred. All three conditions: hyperemia, vascularization, and hemorrhage, frequently coexist.

In every instance in which the strongly distended vessels can be recognized by the naked eye, they are either arteries or veins, never capillaries; the latter are too small to be recognized as independent vessels. Capillary hyperemia, therefore, always appears as a uniform redness like that of the lips. In hyperemia of the cheeks, on the other hand, very fine red lines and points can generally be recognized; these are always superficial veins. In general, the question as to whether the visible vessels are arteries or veins must be decided in each organ according to the mode of vascular distribution.

Two forms of hyperemia are to be distinguished: **Active (arterial) hyperemia** or **fluxion,** and **passive (venous) hyperemia** or **passive congestion.**

In **active hyperemia** the blood flows in greater volume and with increased velocity into a vascular area in which the resistance, in comparison to the propelling force, is diminished.

In **passive hyperemia** the blood-stream is retarded by increase of the opposed resistance, in consequence of which a local accumulation of blood occurs in front of the impediment.

The impediments which cause slowing of the blood-stream in passive hyperemia are, in very many cases, located in the venous area and are frequently mechanic; the vessels themselves remain passive. This is the reason why congestive hyperemia is often designated as primary venous hyperemia or passive congestion. On the other hand, active hyperemia, which is decidedly arterial in character and is caused by relative increase in the propelling forces,[1] is designated as active congestion. This terminology, however, is not wholly correct, since the vessels may remain passive (by dilation of the lumen, relaxation of the muscularis) in both passive congestion and fluxion, and the imped-

[1] Since ancient times the view has been held that fluxion develops in those localities where an augmented flow of blood through the tissues or increased activity of the vessels occurs as a result of especial irritation. Indeed, Hippokrates formulated the thesis: *"Ubi stimulus, ibi affluxus."*

iment in congestive hyperemia may be situated also in the arterial vascular area, under which circumstances passive hyperemia is a primary arterial phenomenon.

The blood flows in a closed vascular system. As is known, the cause of the flow is the difference in pressure existing in the different areas of the vascular system. The blood-pressure[1] depends upon the propelling force (energy of the heart) and the resistance[2] offered to the blood-current.

In every increase in the blood-pressure, whether due to increase of the propelling power or diminution of the opposed resistance, the increased pressure within the blood-vessels is distributed uniformly in all directions; consequently, the pressure exerted upon the inner surface of the vessel (lateral pressure) also is increased, and dilation of the lumen occurs. At the same time the velocity—being inversely proportional to the resistance—is increased as a result of diminution of the resistance or increase of propulsion.

Augmentation of the blood-pressure from diminution of the resistance or increase of propulsion may occur either as a result of local increase of pressure without alteration of resistance, or when in general increase of pressure the resistance in certain vessels or vascular areas is unequal, or when local diminution of resistance occurs without alteration of propulsion. Accordingly, three groups of **fluxion** (active hyperemia) may be differentiated:—

1. Through local increase of pressure. This occurs as the result of some impediment which allows less blood to flow through an arterial branch or capillary area. As a consequence of this the blood first congests in front of the impediment,[3] but then flows in greater volume and with increased velocity through the nearest lateral arterial branches or the neighboring capillaries (so-called "collateral channels"). The impediment, therefore, causes an increase in the blood-pressure in the collateral vessels without diminution of resistance within them. This is the form known as collateral (compensatory) hyperemia.[4]

---

[1] The blood-pressure in the aorta corresponds to a column of mercury 250 mm. in height; it gradually declines from here, amounting in the capillaries to only 40 mm. mercury, and is negative in the vena anonyma: —0.1 mm. of mercury. Like all other fluids, the blood flows from places of high pressure to places of lower pressure.

[2] To the impediments belong: size of the area of contact between the blood and the inner surface of the vessel (adhesion); condition of the internal surface of the vessel; consistency of the blood, and the pressure exerted upon the external surface of the vessel.

[3] This is local congestion.

[4] In this state the vessels are entirely passive, not active.

This form of active hyperemia is observed in the most varied forms of impediments to the blood-current in the arterial, capillary, and even in the venous area. In the arterial area the impediment may be compression, ligature, embolism, thrombosis, amyloid degeneration, or cicatrization; in the capillaries it may be every alteration accompanied by diminution in the size of the lumen of the capillaries, *e.g.*, cloudy swelling of the parenchyma of different organs,[1] amyloid degeneration and embolism of the capillaries, the stadium of complete hepatization of fibrinous pneumonia and mixed fibrinocatarrhal pneumonia, the chill stage of fever,[2] and, finally, in the venous area, every hindrance to the blood-current which causes passive congestion.[3]

2. Through general increase of pressure and unequal power of resistance of the arteries and capillaries. General increase of blood-pressure always depends upon an increase of cardiac action; the unequal power of resistance depends upon antecedent affections. New-formed blood-vessels particularly, *e.g.*, in freshly healed wounds, are more intensely injected during increased heart action following bodily exertion or excitement, etc., than the remaining vessels, because their walls are less capable of resistance. The same phenomenon is frequently observed in those parts which have recently been the seat of inflammatory alterations, *e.g.*, upon the skin and visible mucous membranes.

3. Through local decrease of resistance. Provided the force of the heart is not weakened, this depends most frequently upon relaxation or paralysis of the vessel walls. It may originate also as the result of diminution of the pressure exerted upon the outer surface, *e.g.*, on removal of tumors (secondary fluxion[4]), which chiefly compressed arteries, and, finally, as a result of nutritive disturbances, especially not very extensive fatty metamorphosis in the walls of the smaller arteries (so-called atonic form of active hyperemia).

[1] In the kidney in parenchymatous nephritis, when the cloudy swelling is confined to the cortex, anemia of the cortex and compensatory or collateral hyperemia of the pyramids are observed.

[2] Here collateral hyperemia of the internal organs is produced as the result of cutaneous anemia.

[3] In congestion in the veins the congestion extends backward to the capillary area, and every obstruction in the capillary area produces, as above stated, callateral hyperemia.

[4] Secondary fluxion occurs, for example, when the external pressure to which a vascular area has for a long time been subjected is suddenly removed, as in the peritoneum or the pleura after sudden withdrawal of a large amount of exudate. It may be so marked as to cause a high degree of anemia in other organs and by consecutive abstraction of blood from the brain produce syncope. This form of fluxion is probably due to defective elasticity and contractility of the vessel walls (resulting from prolonged external pressure), which after removal of the pressure give way to the inflowing blood. The marked secondary hyperemia which occurs after suspension of the anemia caused by an Esmarch bandage, and is often followed by severe parenchymatous hemorrhage, also belongs here.

Relaxation or paralysis of the walls occurs as the result of nervous influence upon the muscularis of the arteries. According to the nature of the action, three subdivisions may be distinguished: the paralytic, the reflex (psychic), and the irritative form.

The paralytic form of active hyperemia is observed on division of the sympathetic (by suspension of the influence of the vasoconstricting fibers, so-called vasoconstrictors[1]); by use of strong electric currents; during the action of mild heat, *e.g.*, of the hot summer temperature, warm and especially wet fomentations; and after transitory action of cold, which first produced anemia or passive congestion.

To the reflex form of fluxion belongs the hyperemia of the mucous membrane of the uterus during ovulation; the hyperemia of all richly vascular organs during function; of the conjunctiva in irritation of the nasal mucous membrane, and in overtaxing of the retina; of the head after meals, and the hyperemia of certain areas in emotional excitation (psychic form) with the character of exaltation: anger, joy, envy, lust, and shame.

Irritative hyperemia is produced on employment of certain chemic irritants: so-called rubifacients[2]; furthermore, as the result of mechanic irritation, *e.g.*, by friction and scratching,[3] by massage, and, finally in richly vascular parts in inflammation.

The symptoms of active hyperemia are: injection, swelling, elevation of temperature, and pulsation.

Injection[4] is recognized by the pronounced redness. Since in this condition richly oxygenated arterial blood is forced in increased amount and with greater velocity through the arteries and capillaries—*i.e.*, an excess of highly oxygenated blood and, therefore, of oxygen, is brought to the capillary area—while the tissues take up only as much oxygen as they can use, the gas exchange in the capillaries is incomplete and richly oxygenated, arterial blood enters the veins. In this manner the whole hyperemic area is flooded with arterial blood, and, as this is bright red, the whole area appears bright red. In organs with relatively few anastomoses and in local irritation, the injection is more sharply defined,

---

[1] Section of the splanchnic nerve is followed by marked hyperemia of the abdominal vessels; also contraction of the pupils after section of the cervical sympathetic.

[2] Here belong: pungent oils, ammonia, ether, alcohol, acids, alkalies, and others.

[3] Rubbing and scratching first produce transitory anemia; then hyperemia.

[4] Injection (*injicere:* to throw in) signifies, strictly speaking, to force in, the blood being driven into the vessels with greater force and increased velocity. Injection is employed also to designate filling of the arteries or of the vessels in general.

punctate, mottled, wedge-shaped, and lobular; in other cases more diffuse.[1]

As a result of the greater filling of the vessels, the affected area is increased in volume (swollen). In many cases this swelling is so slight that it is recognized with difficulty.

Elevation of temperature is subjectively perceptible, and produces a sensation of burning heat in the skin. Objectively, it can be measured; and in the rabbit's ear, on section of the cervical sympathetic, it amounts to from 5° to 7° C.

Pulsation is observed more frequently subjectively than objectively, especially in localities inaccessible to direct observation (pulsating toothache, throbbing headache).

In most cases active hyperemia is of too short duration to be followed by any secondary phenomena. At all events, increased afflux of arterial blood does not lead to augmentation of nutrition or function.

When of long duration or of high intensity, and especially when present in tissues of loose structure—such as the subcutaneous, submucous, and subserous tissues, the lungs, etc., also in areas which have been the seat of antecedent affections or which are attacked by an inflammatory irritant—active hyperemia is associated with watery exudations from the vessels. In the skin, wheals and nodules, which can readily be diminished on pressure, make their appearance, and in the neighborhood of inflammatory foci collateral edema is produced: *œdema pulmonum.*

Active hyperemia frequently gives rise to hemorrhage,[2] especially in localities (brain and lungs) in which the vessels for any reason (nutritive disturbances, inflammation, chronic alterations, new formation, etc.) are in a weakened condition, *i.e.*, in a state of reduced resistance. In menstruation, also, active hyperemia precedes the bloody discharge.

When fluxion is of long duration or frequently recurs, exfoliation of the epidermis is observed (furfuraceous desquamation after measles; membranous desquamation after scarlatina, etc.).

The wall of the vessel in comparison with the lumen is always thinned by the more intense filling. If this condition persists for a long time, the disproportion between the thin wall and the dilated lumen is compensated by gradual increase of the mural constituents (thickening of the wall). In this manner collateral hyperemia may develop into a

---

[1] The phenomena of hyperemia as well as all circulatory disturbances disappear in the cadaver, because the distribution of the blood is altered after death. (See p. 51.)

[2] See hemorrhages from internal causes; hemorrhagic diathesis, pp. 57-65.

collateral circulation, *i.e.*, the pathologic state be replaced by a physiologic.

As above stated, relative increase of the propelling power of the heart is the cause of the more intense filling and increased velocity in active hyperemia. On the other hand, relative increase of resistance (relative in comparison with the propelling force) is the cause of **passive congestion.**

From what has been stated, it is plain that relative increase of resistance causes a diminution of the difference in pressure. Consequently, slowing of the current and local accumulation of blood occur. If the resistance increases so that it equals the blood-pressure, the differences in pressure cease and the blood-current is brought to a standstill (*stasis*).

This relative increase of resistance may be due to absolute increase of resistance (in unaltered or insufficiently increased propulsion) as well as to diminution of the propulsive force of the heart[1] with unaltered resistance.

Increase of resistance may be due to various causes. Alterations which diminish the size or occlude the lumen of a vessel or of a whole vascular area are frequently found. The blood then accumulates in front of the obstruction, which causes collateral hyperemia (fluxion) in the arteries and congestion in the veins, since in the latter the blood-pressure is considerably lower and the congestion gradually extends backward to the capillaries. In addition, the venous collateral channels are in many cases not large enough to allow all the congested blood to flow onward.

It is usual to distinguish **local** and **general congestion.** The former is characterized by the fact that it occurs in a circumscribed area. In general congestion, on the other hand, the obstruction is situated in a portion of the vascular system through which a large part or all the blood must flow; consequently, general congestion extends over a large area or over the whole body.

Local congestion originates:—

I. Through local increase of resistance without change in the propelling force of the heart. This local augmentation of resistance may be due to:—

1. Compression of veins. The lumen of veins is frequently narrowed or occluded by ligature, thrombosis, pressure of the gravid uterus upon the veins in the true pelvis; by tumors which compress veins or grow into their lumina; by large masses of exudate, particu-

[1] This leads first to general slowing of the blood-stream. If this results in congestion, other factors invariably act as adjuvants.

larly in the body cavities; by pressure of ill-fitting garters, corsets; in incarceration of hernias; by cicatricial contraction in the neighborhood of veins (*e.g.*, in *carcinoma mammæ*), etc., because the veins possess a very thin and extremely yielding wall. Any marked narrowing forms an obstruction which must lead to congestion, because the differences in pressure in the veins are very small, even a slight increase in resistance becoming distinctly manifest.

2. Diminution of the external pressure. Here at first the resistance in the arterial area is diminished; in the veins, on the other hand, the blood-pressure falls in proportion to the resistance. Hence, in the arteries hyperemia is first produced, and in the veins slowing of the current, congestion or, if the blood-pressure is equal to the resistance, stasis or, if the blood-pressure is less than the resistance, a backward flow. This relation changes as soon as the vessels in which the external pressure is reduced are proportionately filled with blood. Then slowing of the blood-current occurs in the veins as well as in the arteries.[1]

3. Permanent dilation of vessels. The blood flows slower in all varices and in cavernous vascular ectases because the blood-pressure is diminished on passage into the comparatively very wide vascular area. Also, in the neighborhood of chronic inflammatory foci (paralytic) dilation of the veins and greater filling and slowing of the current are observed as a result of overstimulation. In the uterus this process, as a persistence of menstrual or puerperal dilation of the vessels, leads to the formation of the so-called uterus infarct.

II. By diminution of the propelling force of the heart. This may be the result of acute febrile diseases or of chronic affections associated with cachexia[2] and marasmus.[3] As a rule, however, reduction of the force of the heart alone does not lead to congestion; on the contrary, here, also, favoring conditions must first be present, under the influence of which local congestions usually occur. To these contributing causes belong:—

---

[1] And if backward flow was present in the veins, a reversal of the same. This combination of passive and active congestion is not rare; for example, it always occurs on compression of arteries in the region between the constricted point and the nearest, higher situated collaterals. On occlusion of an artery, stasis occurs in the same area because at that point the resistance equals the blood-pressure, *i.e.*, the differences in pressure cease.

[2] Cachexia, from κακός = bad, and ἔχω = habit—to behave badly, bad state. Cachexia, in contradistinction to marasmus, implies alterations of the blood and nerves (state of chronic affection, pale (anemic), bloated (hydropsic) aspect, etc.).

[3] Marasmus, from μαραίνω = atrophy, to grow lean, wither. Marasmus indicates particularly the state of senescence, the atrophic processes, simple and degenerative atrophy of senility (withered state of the skin, muscles, heart, etc.); this expression is employed also to designate premature senescence. A diminution of the red blood-corpuscles and of the proteid content of the blood also occurs in marasmus, though the alteration is usually not so marked as in cachexia.

1. Extensive organic alterations of the vessel walls, especially marked calcification of the media and sclerotic, connective-tissue thickening of the intima of the medium-sized and smaller arteries (arteriosclerosis of high degree).

2. The gravity of the blood as a watery liquid. This acts only when the body retains the same position for a long time, especially in the aged who, for any cause, are forced to assume the same posture for a protracted period, or in very ill patients who, from weakness, retain the same position (*e.g.*, dorsal posture).

This weakness of the skeletal musculature is frequently associated with insufficient, shallow respiration (from weakness of the muscles concerned in respiration) and atony of the vessel walls from malnutrition. Thus, the blood as a watery fluid is capable of following its own gravity and of collecting in dependent parts only when various influences which hinder the onward flow and uniform distribution of the blood-current are added to the weakness of the heart. Gravitation of the blood and the resulting permanent overdistention of the deeper parts is designated as hypostasis[1] or hypostatic congestion.

General congestion is the result of affections of those organs through which either all or a great portion of the blood must flow. These organs are:—

1. **The heart.** Among the alterations of the heart are:—

(*a*) Those affections of the ostia associated with narrowing (stenosis) or incomplete closure (*incontinentia*[2]) of the valves which result in general congestion. All the blood must flow through the ostia; therefore, any change in them which obstructs the onward flow of blood disturbs the circulation of the total blood-mass of the body.

In stenosis of the ostia the same conditions exist as in congestion due to compression of the veins and in hyperemia from local increase of pressure, with the difference, however, that an equalization of the disturbance is impossible, because, in the case of the heart, there are no collateral channels.

In incontinence (better than insufficiency) the impediment is due to the fact that a part of the blood expelled from the heart flows back into the ventricle during each diastole because the valves are incapable of complete closure and of intercepting the recoil. Therefore, in incontinence, just as in stenosis, less blood is discharged with each pulsation of the heart than under normal conditions. The consequence is congestion of the whole venous and capillary systems.

---

[1] Hypostasis, from ὑπό and ἵστημι = to stand under, place beneath.

[2] From *in continere*, not contain, *i.e.*, not arrest the recoil or backward flow of blood.

In contradistinction to congenital valvular lesions, which are usually right-sided, the later-acquired valvular lesions are, as a rule, situated in the left heart. Stenosis or incontinence of the aortic orifice or of the left auriculoventricular (mitral) orifice first causes congestion of the lungs; but when the lesions are chronic and of marked degree they invariably produce congestion also in the so-called greater circulation, because the right heart, in spite of the hypertrophy which very soon develops, is incapable of coping with the congested mass of blood, for the congested blood contained in the dilated pulmonary vessels prevents complete emptying of the right ventricle; the latter becomes dilated and incapable of receiving all the blood from the auricle. The incomplete emptying of the auricle, which occurs in spite of hypertrophy of the auricular musculature, produces congestion in the large venous trunks; the congestion gradually extends backward to and into the capillary area.

(*b*) *Morbus cæruleus.* (See Malformations.)

(*c*) Heart weakness, which occurs in severe febrile diseases or is secondary to chronic affections associated with cachexia or marasmus. Anatomically, the former is generally expressed by cloudy swelling; the latter most frequently by brown atrophy of the parenchyma, and later by fatty metamorphosis of the musculature.

2. The lungs. In affections of the lungs those lesions in which the total area of the pulmonary vessels is diminished are of chief importance, and next all changes which impede the circulation in the pulmonary vessels, offering mechanical resistance in a large vascular area.

The first group includes all processes associated with atrophy or ulceration of the pulmonary parenchyma, especially alveolar emphysema, progressive bronchiectasis, and ulcerative caseous phthisis, because in these processes the vessels are obliterated with disappearance of the parenchyma, and, consequently, the total volume of the vascular area is diminished. The greater the disappearance of vessels, the more pronounced the congestion.

To the second group belong highly developed forms of kyphoscoliosis, because this condition sometimes renders large areas of lung useless for respiration; large exudates in the pleural cavities which cause compression of the lungs and their vessels, and, finally, affections accompanied by adhesion of the pleuræ, especially chronic bilateral tuberculous pleuritis and obliteration[1] of both pleural cavities, because the movements of the lungs are thus restricted, the expansibility hindered, and the suction power of the thorax (in inspiration) upon the large venous trunks is diminished.

---

[1] Obliteration: disappearance, effacement.

3. The liver. As is known, the portal blood—a considerable portion of the total blood-mass—flows through the liver. Any alteration of the liver which markedly opposes the onward flow of this volume of blood may cause congestion of the portal area. This occurs most frequently as the result of chronic interstitial inflammation of the liver associated with contraction—so-called cirrhosis[1]; less often as a result of very extensive amyloid degeneration of the liver, carcinoma at the hilus of the liver, large echinococcus cysts, thrombosis, and other alterations.

While cardiac and pulmonary affections produce, in addition to general engorgement, marked congestion of the veins of the upper portions of the body, affections of the liver cause chiefly abdominal congestion.

The discernible phenomena or symptoms of congestion are:—

1. Swelling, in which the hyperemic parts increase in volume as the result of intense engorgement of the vessels. Sometimes certain veins are seen to stand out distinctly upon the surface as bluish cords, *e.g.*, upon the hand in pressure upon the veins of the arm. The swelling causes a subjective sensation of heaviness.

2. Coldness (frigidity). This is subjectively and objectively manifest in tapering extremities. It is due to increased loss of heat, because the radiation of heat is more prolonged by slowing of the blood-current, as well as to diminution of function: the gas exchange between the tissues and the slowly flowing blood (loss of O and absorption of CO_2 by the blood) being more complete than under normal conditions, the capillaries become overloaded with blood rich in carbonic acid; hence, lack of oxygen occurs, and, consequently, oxidation processes are reduced.

3. Cyanosis,[2] bluish-red coloring of the tissues, owing to over-distention of the vessels with blood rich in carbon dioxide.

Congestion may disappear after a time without the production of permanent alterations. They disappear when the cause of congestion (compression of veins, etc.) is overcome or sufficient collateral channels are present for collateral circulation to develop from the collateral hyperemia. The larger, however, the narrowed or occluded vessel and the fewer anastomoses are present, the slower and less complete, as a rule, is the equalization of the disturbance through collateral channels. In general congestion there are no collaterals through which equalization can take place. In every faulty and incomplete compensation of a local congestion, as well as in every case of general congestion, certain typical secondary phenomena are regularly observed. These are:—

[1] From *κιρρός* = blond, yellow, because the remaining liver tissue usually appears yellow.

[2] From *κύανος* = *lapis lazuli*, blue-colored glassy flux.

1. Tendency to watery transudates (hydropsies). These occur either into the tissues (hydropsic infiltration, edema) or upon free surfaces of the body cavities (free hydrops, *e.g.*, abdominal ascites in cirrhosis of the liver, etc.). Hydropsic infiltration is usually more intense the softer and looser the tissues; hence, the loose connective tissue is always first affected.

2. Tendency to hemorrhages. These also may occur into the tissues (hemorrhagic infiltration) as well as upon the free surfaces (free extravasates). They sometimes occur suddenly and are very large (*e.g.*, gastric hemorrhage in abdominal congestion as a result of hepatic cirrhosis); sometimes they take place very gradually, one red blood-corpuscle after the other escaping through the apparently unaltered wall of the capillaries and the smallest veins (hemorrhage *per diapedesin*). This slow hemorrhage occurs in the lungs in pulmonary congestion secondary to valvular lesions of the heart; the escaped blood-corpuscles are transformed into pigment. When in the course of time many blood-corpuscles have extravasated in this manner, the lungs may contain so much pigment that they acquire a brownish color (brown induration of the lungs).

3. Functional disturbances. All soft tissues, especially those with surfaces covered with mucous membrane, also the lungs, kidneys, nerves, and muscles, may be markedly disturbed in function by chronic congestion[1]: the muscles become weak; the sensibility of the skin is reduced to insensibility, and a feeling of numbness develops; from the hypostasis of the lungs a hypostatic pneumonia develops; the kidneys are incapable of preventing escape of albuminous material from the blood and albuminuria develops; the mucous membranes secrete a catarrhal exudate (gastritis, cyanotic catarrhal bronchitis).

4. Thrombosis. This usually occurs in conjunction with general weakness, especially weakness of the heart and of the body musculature.

5. Induration. This change is distinctly perceptible only in a few organs: in the lungs, kidneys, and spleen. Aside from dilation of the vessels, red induration depends upon thickening of the vessel walls and increase of the connective-tissue constituents of the organs. In the lungs, red and brown induration are distinguished. The latter differs from red induration essentially by the amount of pigment. (See No. 2, above.)

6. Atrophy. In chronic general congestion atrophic processes in the parenchyma of the liver, kidneys, and retina develop as a result

[1] See symptoms of congestion under No. 2, p. 44.

of pressure exerted by the strongly distended vessels upon surrounding parts, and as a result of nutritive disturbance due to deficient oxygenation. In the liver the atrophy is limited to the center of the acini, *i.e.*, the area of the true hepatic vein. The liver-cells in that locality disappear with the development of pigment (nutmeg liver). In the kidneys the gland-cells of the urinary tubules are destroyed by fatty metamorphosis.

7. Gangrene. This (senile gangrene from heart weakness and advanced arteriosclerosis, decubitus, incarcerated hernia) is the most unfavorable and dangerous termination of congestion, and is always complicated with active, irritative inflammatory phenomena, while all other sequelæ are essentially of a passive nature.

ANEMIA.

By **anemia** is not meant, as might be assumed from the etymology of the word (ἀν = privativum and αἷμα = blood), absolute bloodlessness, but only deficiency of blood or a diminution of the volume of blood below the normal. In every decrease of blood-supply the vessel lumen must be narrowed. The constriction may be:—

1. Spastic. Only those vessels which possess a *muscularis propria* can contract, namely: arteries and veins. Constriction occurs either as a result of some influence exerted directly upon the *muscularis* from without by a kind of contact action or through the agency of nerves. The latter occurs, for example, in irritation of the sympathetic (irritation of the sympathetic causes anemia of the corresponding half of the face).

2. Tonic. The intrinsic nutritive tension of the constituents of the wall enables the arteries, capillaries, and veins to diminish in diameter as soon as less blood than normal is conveyed to them. All vessels, therefore, are able by means of their tonicity to accommodate themselves to any reduction in the amount of blood (*e.g.*, as a result of hemorrhage).

3. Organic. Organic narrowing occurs:—

(*a*) In inflammatory proliferations, which begin almost exclusively in the internal coat of the arteries (seldom in the veins, never in the capillaries) and may produce thickening of the wall and constriction amounting even to complete obliteration of the lumen.

(*b*) In cicatrization, which is observed only in the walls of arteries and veins, more frequently in the former than in the latter.

(*c*) In amyloid degeneration of the arteries and capillaries, in that the amyloid parts swell, as it were, and thus produce marked contraction of the vessel lumen.

(*d*) To these organic alterations belong embolism and thrombosis of such vessels as have only a few or no anastomoses (*e.g.*, cerebral and renal vessels).

4. Passive. Vessels are narrowed in a purely passive manner by increase of the external pressure, *e.g.*, by compression of the vessels: of the capillaries in fatty liver and in the renal cortex in cloudy swelling of the cortical substance; of the pulmonary capillaries in complete hepatization; also by ligature and cicatricial contraction in the neighborhood of the vessels; by pressure of large exudates, tumors, the pregnant uterus, etc. The delicate capillaries are most often involved by this purely passive narrowing, next in frequency the thin-walled veins, and least of all the arteries, because these possess a very strong, resistant wall.

Diminution of the mass of blood below the ordinary amount is either local: **local anemia,** or **ischemia,**[1] or it involves the whole body: **general anemia,** or **oligemia.**[2]

In **oligemia,** or **general anemia** the total volume of blood in the body[3] is diminished. A small loss of blood produces no perceptible sign and is rapidly compensated by new formation. Not until distinct symptoms (pallor, etc.) become visible, *i.e.*, when the total amount of blood is diminished to a marked degree, do we speak of general anemia. There is, of course, no definite limit.

In consequence of diminution of the total amount, all vessels contain less blood than in the normal state. The vessels accommodate themselves to this diminution by virtue of their tonicity.

Diminution of the total volume of blood occurs either suddenly or gradually. Hence are distinguished:—

1. **Acute oligemia.** This is characterized by sudden severe loss of blood externally. The cause is either injury with severance of continuity (trauma), or ulceration (hemorrhage from gastric ulcer, typhoid ulcer of the intestine, pulmonary hemorrhage in ulcerative pulmonary phthisis, etc.), or passive congestion (gastric hemorrhage in abdominal congestion from cirrhosis of the liver), embolism (*e.g.*, of the superior mesenteric artery), or an especial disposition of the vessels to severe hemorrhage upon slight injury (in so-called bleeders: hemophilia).

2. **Chronic oligemia.** In chronic general anemia also the cause may be losses of blood externally (*e.g.*, recurrent nasal hemorrhages: epistaxis), with the difference, however, that here it is not a question

---

[1] ἰσχαιμος = hemostatic, from ἰσχω = ἐχω = hold back, retain, and αἱμα = blood.

[2] ὀλίγος = little, slight.

[3] The physiologic amount of blood is about one-thirteenth of the body weight.

of a single hemorrhage, but of more or less oft-repeated hemorrhages which exert a marked reaction upon the nutrition of the tissues.

More frequently chronic oligemia is due to a pathologic change, *i.e.*, to chlorosis, pernicious anemia, or chronic diseases associated with cachexia.

In chlorosis[1] not only the volume of blood in the body is diminished, but there is also a reduction of the amount of hemoglobin and sometimes distinct aplasia of the whole vascular system (small heart; narrow, thin-walled, and very elastic aorta, etc.). (See Blood.)

Pernicious anemia owes its name to the fact that it always ends fatally as a result of final marked fatty metamorphosis of the heart musculature and other organs, due to severe disturbance of nutrition. It is distinguished from chronic diseases associated with general anemia by the extreme degree of the anemia, and also by the fact that, aside from the extreme anemia, no other pathologic alterations are demonstrable during life. In contrast to the general anemia (paleness of organs) so conspicuous at necropsy is the marked redness of the bone-marrow of the tubular bones. The bone-marrow assumes in every way the character of that observed in the bones of the newborn; apparently, it reverts to a blood-forming organ. Accordingly, a greater number of nucleated red blood-corpuscles are always found also in the bone-marrow. In almost all cases the liver is remarkably rich in iron and pigment (light brown-red, rust colored). This condition is designated as *siderosis hepatis*. Choked disk is not unusual, and retinal hemorrhage is very common, especially around the papilla, and is a point in differentiation from chlorosis and simple anemia in which retinal hemorrhage is very rare.

The cause of pernicious anemia is not constant, and in many cases obscure. It is due either to affection of the blood-forming organs (lymphatic glands, bone-marrow, etc.), so that regeneration of the blood-corpuscles fails to keep pace with the destruction, or to an agent[2] injurious to the blood itself. To the former group belong chronic affections,[3] such as syphilis and scrofula, which result in alteration and destruction of the lymph-glands. In recent years attention has repeatedly been

---

[1] χλωρος = green.

[2] In many cases, which sometimes occur epidemicly, as, for example, in Italian laborers in the St. Gotthard Tunnel and in brickworkers in the Rhein Province, necropsy shows the *Ankylostomum duodenale* to be the cause. These cases, therefore, are to be classed with such in which the fatal anemia is due to repeated losses of blood.

[3] Here belongs indirectly also gastric carcinoma, which, at necropsy, is often found to be the cause of pernicious anemia, in so far as cancer of the stomach markedly interferes with general nutrition and hence also with the formation of blood.

PLATE II



Pernicious anemia. *A*, megaloblasts; *B*, normoblasts; *C*, polynuclear; *D*, small lymphocyte; *E*, eosinophile; *F*, poikilocytes; *G*, microcyte; *H*, basophilic granulation.

directed to the relation between pernicious anemia and atrophy of the gastrointestinal mucous membrane. Atrophy of the mucous membrane of the stomach is comparatively frequently found, and less often atrophy of the intestinal mucosa. It cannot, however, as yet be decided whether this atrophy is the cause or the result of pernicious anemia. Camac and Milne[1] describe marked degenerative changes in the posterior and lateral columns of the spinal cord, especially in the lower cervical region; also cavity formation in the anterior horn from the tenth dorsal to the first lumbar segment.

Those cases in which no cause can be found are usually designated as primary or idiopathic, the others as secondary pernicious anemia. In every case the volume of blood is very gradually diminished. The red blood-corpuscles present in part abnormal forms: in addition to nucleated red blood-cells, unusually large and strikingly small—so-called macrocytes and microcytes, respectively—and also very irregularly formed, partly club-shaped red blood-cells—so-called poikilocytes—are observed. (See Blood.)

Among those chronic diseases which produce general, though not pernicious, anemia are, first, processes associated with amyloid degeneration, such as consumption, syphilis, and chronic bone suppurations; second, scrofula, inanition from cicatricial and carcinomatous stenosis of the esophagus, gastric carcinoma, chronic lead poisoning, and chronic malaria.

Ischemia is caused by local obstruction of the flow of blood due to narrowing of the vessel lumen. Hence, in every case of local anemia the reduced filling of the vessels is the result of vascular constriction, while in general anemia tonic constriction is, as already stated, the result of diminished filling. Ischemia occurs as a result of contraction, organic change of the vessel wall, or purely passively, and may involve the arterial, capillary, and venous areas.

Capillary ischemia is more frequently purely passive (from compression in fatty liver, in cloudy swelling, etc.) than the result of organic change (amyloid degeneration). The venous form is almost always a local phenomenon. The arterial form, by far the most important, originates as a result of proliferation, cicatrization, compression, amyloid degeneration, embolism, thrombosis, and contraction of the muscularis. The latter form of arterial ischemia, namely: that caused by contraction, is usually designated as spastic anemia. The causes may be:—

1. Emotional excitement with depressive effect: fright (pale cheeks and lips), terror, grief, apprehension, etc.

---

[1] American Journal of the Medical Sciences, October, 1910, p. 563.

APR 28 1927

2. Cold. This (cold air, cold water, ice-pack, etc.) may involve a part of the skin or the whole surface, or exert its effect in the interior of the body (cold drinks, cold enemata, swallowing of ice, etc.). In the chill stage of fever there is anemia of the skin and collateral hyperemia of the internal organs. Probably cold acts directly upon the smooth musculature without participation of the nerves; at least, nerve influence is weakened by cold.

3. Electricity.

4. Mechanic action: scratching, pinching, friction. The primary ischemia is usually very soon followed by hyperemia.

5. Chemic agents: ether,[1] tannin, alum, liquor ferri sesquichlorati, secale cornutum (ergotism, raphania).

The pathognomonic sign of anemia is pallor. Here it must be remembered that there are organs with, as well as without, inherent color. In the former (muscles, spleen, liver, etc.) the characteristic color becomes the more pronounced the more marked the anemia; the others (connective tissue, lungs, etc.) lose their red color the more anemic they become, and finally assume a pale-gray hue.

If the anemic parts are near the surface of the body, then, in addition to pallor, lowering of temperature also is observed subjectively (feeling of coldness, chill) as well as objectively. This is usually most marked in tapering parts of the body (nose, fingers, toes, etc.). The cooling is due to diminished supply of warm blood and local decrease of oxidation processes.

With pallor and coldness there is associated disturbance of function. The sensibility of the nerves is diminished; "furry" or "fleecy" sensation of the skin develops; sometimes all tactile sense is abolished. In a similar manner amaurosis may result from anemia. The muscles contract sluggishly and incompletely, become markedly weak, and, finally, rigid and stiff. The function of the glands (*e.g.*, the sweat and sebaceous glands) is diminished or ceases.

Every local anemia causes hyperemia of other parts. The flow of blood from a vascular area is impeded by venous anemia; in the corresponding capillary area congestion occurs. In capillary anemia fluxion develops in the collateral capillary area (anemia of the renal cortex from parenchymatous nephritis is associated with collateral hyperemia of the pyramids). Arterial anemia may the more readily produce congestion in the corresponding venous area the more intense it is, since slowing of the venous current and lowering of the lateral pressure first cause stasis and then sometimes even backward flow of

[1] Placed upon the skin, this abstracts heat by evaporation and consequently acts similarly to cold.

the current from those anastomosing veins which receive their blood under a higher pressure. Furthermore, every arterial anemia causes also hyperemia in the collateral arteries.

Every local anemia of long standing (*e.g.,* in amyloid degeneration of the arteries and capillaries), also in sudden onset from embolism and in marked exacerbation (constriction or occlusion of arteries by thrombosis), causes disturbances of nutrition which lead to simple or necrobiotic atrophy (yellow softening of the brain, etc.), and, when vital organs (brain or heart) are involved, sometimes even death. When the anemia is due to spasm of the arteries, as in poisoning with ergot, local death may occur under extremely violent inflammatory manifestations (gangrene).

Also, in general anemia of long duration organic alterations occur as a result of chronic disturbances of nutrition. Here the heart is generally most markedly altered, in that a very severe, mottled, fatty metamorphosis of the heart muscle develops, which finally causes death.

Death occurs in acute general anemia when the sudden loss of blood —which causes acute oligemia—reaches a certain degree: when about one-third of the total amount of blood present is suddenly lost.

Distribution of the Blood After Death.

With the occurrence of death the difference between arterial and venous blood ceases. All the blood assumes a dark color from loss of oxygen, and regains its bright hue only through absorption of oxygen, when it comes in direct contact with the atmosphere, *e.g.,* at necropsy.

The distribution of the blood after death is essentially different from that which obtains during life. With death cadaveric pallor of all mucous membranes and of the external skin sets in, so that even parts which previously were hyperemic (as in scarlatina and erysipelas) may now be anemic. All small arteries contract on cooling of the body *post mortem* (so-called *rigor mortis* of the arteries), and force the blood into the capillary and venous areas toward and even beyond the heart. Therefore, in the cadaver the arteries are generally quite empty.[1] In the brain alone, owing to the rigidity of the calvarium, the distribution of the blood *post mortem* is nearly the same as in the living state; but this, of course, is altered if the calvarium is removed. In the remaining portions of the body a movement of the blood takes place as a result of contraction of the arteries and flowing (gravitation) of the liquid parts to deeper-lying sections: hypostasis or hypostatic congestion. In dorsal position of the cadaver, hypostasis is especially marked

[1] For this reason the ancients believed they contained air: *angeia pneumatica.*

in the posterior portions of the lungs and brain (meningeal veins). This movement may also take a direction opposite to that of the circulation. The so-called "death-spots," *maculæ emortualis* (*livores,* bluish-red spots), are due to accumulation, by hypostasis, of liquid blood in the capillaries of the skin of the dependent portions of the body, and partly also to diffusion of blood-coloring matter. They generally appear about from three to four hours after death.

As the capillary blood of the cadaver never coagulates, but is at all times fluid, it can be displaced by pressure with the finger, so that the *maculæ* can thus be made to disappear. This is possible, however, only when the blood lies within the vessels. Blood which has entered the tissues (hemorrhagic infiltration) cannot be displaced by pressure, and this is true also of the dissolved blood-coloring matter diffused in the neighborhood of the vessels at the beginning of decomposition (the dirty, gray-red, frequently branched lines of the skin).

The phenomenon designated as "goose-skin" (*cutis anserina*) occurs with disappearance of the warm blood from the skin, and is due to contraction of the *musculi arrectores pilorum* (erectors of hairs).

The opposite of hypostasis of the blood is anastasis of air—the rising of air into vessels of elevated parts. This, however, can occur only after injury of vessels (by incision). For example, on removal of the heart, air may enter the vessels and mount to the sinuses of the dura mater and the veins of the arachnoid.

In death by paralysis of the lungs (properly speaking, paralysis of the respiratory muscles) the blood is arrested in front of the pulmonary capillaries, while the left ventricle continues to work and forces all the blood onward into the arterial system. In this case arrest of the heart occurs in systole. At the necropsy, therefore, the left chamber of the heart is found strongly contracted and almost empty, the right chamber strongly filled.

In death from paralysis of the heart the left ventricle is arrested in diastole; the blood, therefore, does not enter the aorta, but accumulates within and in front of the left ventricle. This is changed, however, with occurrence of *rigor mortis* of the heart muscle, since the left ventricle may contract *post mortem* and force out all blood. If severe alterations of the heart muscle have occurred during life, this post-mortem contraction does not take place. In this case the left ventricle is found at the necropsy dilated and filled with blood.[1] The right

[1] This old theory of the state of the heart in death from paralysis of the lungs or cardiac paralysis has frequently and justly been attacked; hence, no definite conclusion as to the mode of death can be drawn from the state of the heart (systole or diastole) and filling of the heart chambers at necropsy (usually twelve to twenty-four hours or longer after death).

ventricle, owing to its thin wall and consequent less power of contraction, is usually more or less distended with blood.

As a rule, the blood coagulates within the vessels (not the capillaries) *post mortem*. The rapidity with which coagulation takes place varies, and depends upon the state of the blood and the length of the agony. It is usually slow and the coagula[1] are distinctly lamellated: the lower (dependent) portions of the coagulum contain the red blood-corpuscles (*cruor*), and are blackish red in color; the upper portions consist of coagulated fibrin ("buffy coat"), and are yellowish gray. By careful examination of the coagula found in the vessels, it is said that it is possible to determine in what position of the cadaver coagulation had occurred. The more slowly death comes on—*i.e.*, the more gradually life is extinguished—the more white (bacon) clots will be found, especially in the right ventricle. The blood remains fluid within the body after death in only comparatively few cases—after certain intoxications (overloading of the blood with carbon dioxide as a result of asphyxia), hydremic states, septic and pyemic conditions, and in death from freezing.

Putrefactive changes (chemic decomposition through the agency of micro-organisms) generally come on the earlier the warmer the surrounding media (bed, summer temperature, humidity) and the more bacteria were present in the body previous to death, *e.g.*, after septic processes. Putrefaction (mortification) is retarded or prevented by cold (ice, freezing) and the action of certain chemic substances (*e.g.*, arsenic, chloroform). The first manifestation of putrefaction is, as a rule, decomposition of the blood, namely: solution of the red blood-corpuscles and diffusion (infiltration, penetration, imbibition) of the dissolved blood-coloring matter into neighboring parts (red staining of nonvascular parts, the heart valves, the intima of the aorta, etc., which is not dispersed by pressure). The red color of the blood is transformed by ammoniacal decomposition into slate-gray or grayish green. In the skin the green discoloration is noticed first upon the abdomen. The oxyhemoglobin may be transformed into methemoglobin by the action of the sulphur in the sulphureted hydrogen developed during putrefaction. A dirty greenish or blackish discoloration is thus produced, which is noticeable especially in the gastrointestinal tract and in those portions of the liver, kidneys, and spleen in contact with the intestine.

---

[1] Clots found within the vessels after death are called coagula. Such coagula are usually not adherent to the walls. They are smooth and moist and thus differ from clots found in the vessels during life, which are called thrombi.

HEMORRHAGE.

During life the blood flows in a closed canal system. The walls of this system vary in strength in the different areas, according to the blood-pressure, and are weakest in the capillary area, where, as is known, the wall is composed of only a single layer of cells. Under ordinary normal conditions the wall in every part of the vascular system prevents the escape of blood. In many pathologic states, however, an escape of blood occurs from the natural channels. The escaped blood is called extravasate (*extra—vasa*), and the process itself is designated as extravasation or hemorrhage, or bleeding.

The hemorrhage occurring during ovulation—menstrual bleeding[1]—may be taken as a physiologic analogue of pathologic hemorrhages. Even this form of hemorrhage, however, occasionally assumes a pathologic character, when, as in menorrhagia, it is excessive. If conception occurs with ovulation, the hemorrhage within the ovary itself is always more marked, because with beginning of conception a permanent *affluxus* to the organs in the true pelvis takes place. Consequently, a large *corpus hæmorrhagicum* of the ovary—the subsequent true corpus luteum—always occurs in connection with conception.

Escape of blood from the vessels may occur in various ways: either all the constituents of the blood escape in natural proportion or only the red blood-corpuscles. The first mode is always observed in coarser injuries to the vessels (arteries, capillaries, and veins) with recognizable solution of continuity of the wall. When no macroscopic alterations are recognizable in the tissues and vessels within the hemorrhagic area, only red blood-corpuscles escape. In this case, as Stricker and Cohnheim first observed in living animals under the microscope, the red blood-cells pass slowly through the apparently unaltered wall of the capillaries and venules,[2] at first arranging themselves against the inner surface of the wall, to which they become, as it were, firmly adherent. After a time a part of the cell is seen to penetrate the wall as a fine, pointed process, and appear upon the outer surface. The portion of this pointed process projecting out of the vessel gradually swells to a small knob, which increases in size commensurate

[1] In elderly women at the climacteric, an hemorrhagic endometrium is quite frequently found at necropsy. This condition, which is in no way connected with menstruation, since it is independent of ripening of a Graafian follicle, and sometimes, as in typhoid, cholera, etc., is referable to fluxion, sometimes to congestion due to arteriosclerosis, is tersely designated as pseudomenstruation (*status pseudomenstrualis*).

[2] The small arteries and veins immediately before their passage into capillaries are designated as capillary arteries and veins, respectively. The veins especially, in their behavior in pathologic processes, act very similarly to the true capillaries.

with the diminution of the portion still within the vessel. The connecting portion of both segments, which can be traced through the wall as a fine line, remains delicate and slender during the whole period of transit. Finally, the portion within the lumen disappears and the protruded portion remains connected with the vessel wall for only a short time by a delicate line, until even this separates from the vessel wall and the red blood-corpuscle again assumes, outside the vessel, its original form.[1] This process is designated as **diapedesis** (trickle through, percolate). Arnold has shown that the escape of the red blood-corpuscles always occurs at the point of contact of two or more cells (of the vessel wall). Accordingly, it would appear that escape of red blood-cells is always preceded by loosening of the cement substance between the cells of the vessel wall. Consequently, in a strict sense, diapedesis depends upon lesion of continuity.

The coarser injuries of the vessels, in which all the constituents of the blood are discharged in natural proportions, may occur genetically in three ways, so that, including diapedesis, the following four[2] forms of hemorrhage may be distinguished:—

1. Hæmorrhagia per diabrosin (from διαβιβρωσκω = corrode) originates chiefly from internal causes, by ulceration (ulcerative form of hemorrhage).

2. Hæmorrhagia per diæresin (from διαιρέω = divide, separate) is produced by external causes, mechanic action from without (traumatic form of hemorrhage in a strict sense).

3. Hæmorrhagia per rhexin (from ῥήγνυμι = lacerate) is due partly to internal, partly to external, mechanic causes.

4. Hæmorrhagia per diapedesin, from internal causes.

The causes of *hæmorrhagia per diabrosin* are ulceration, corrosion, and gangrene. For example, hemorrhage from the lungs in pulmonary

---

[1] The transit of the colorless corpuscles (emigration) occurs in a similar manner in suppuration, with the difference, however, that the colorless blood-corpuscles possess independent motion and actively send out prolongations—a phenomenon never observed in red blood-corpuscles. It appears, therefore, that the escape of colorless blood-corpuscles is an active, while that of the red cells is a purely passive, process. The plasma also may pass through the vessel wall without participation of the red or colorless blood-corpuscles. This is the case in stasis (see p. 40) and in dropsy.

[2] Demetrius of Apamea (300 B. C.) differentiated five forms of hemorrhage: 1, *per anastomosin;* 2, *per diabrosin;* 3, *per diæresin;* 4, *per diapedesin;* 5, *per rhexin.* The first of these must be discarded because it is based upon erroneous premises. Pre-existing openings (so-called stomata) for escape of red blood-corpuscles do not exist. Hence, the form of hemorrhage designated by the older writers as *per anastomosin, i.e.,* through these stomata, can no longer be recognized.

consumption[1] is frequently caused by ulceration of the wall of an artery in which occlusion by thrombosis has not yet occurred; hemorrhage from the stomach by gastric ulcer; intestinal hemorrhage from typhoid ulceration, etc.

Hæmorrhagia per diæresin is caused chiefly by trauma, whether inflicted by blunt agencies (impact, blow, fall, etc.) or by sharp instruments and very great force (gash, stab, cut, shot, etc.). In the first instance a contusion is produced; in the second an open wound. In both instances the vessels may be only partially injured or completely severed.

Hæmorrhagia per rhexin depends upon excessive tension, dilation or traction, or relatively too high blood-pressure and consequent bursting or rupture. It is observed in forcible stretching of flexed limbs, in slow passage of the fetal head through the maternal (especially contracted) pelvis (cephalhematoma of the newborn as the result of crushing and rupture of vessels), in extraction of teeth, in tearing away of limbs by machinery, in bursting of aneurisms (of the cerebral and pulmonary arteries, and of the aorta, etc.), varices (of the lower extremities, hemorrhoids, etc.), and of new-formed, thin-walled, and very delicate vessels, *e.g.*, upon the inner surface of the dura mater (in chronic *pachymeningitis interna fibrinosa vasculosa hæmorrhagica*), etc.

In these three forms of hemorrhage all the constituents of the blood, as a rule, escape, and the hemorrhage usually takes place more or less rapidly. Bleeding arteries furnish richly oxygenated and, therefore, bright-red blood which, owing to the high pressure to which it is subjected and in accordance with the pulse-waves, spurts rhythmically in a long, arched stream. From the veins, on the other hand, dark-red blood, rich in carbon dioxide, flows in a uniform, uninterrupted stream, and in bleeding from the capillaries the blood oozes forth as from a sponge. The last form of bleeding is designated as "parenchymatous hemorrhage."[2]

Arterial hemorrhages are usually more profuse than venous and capillary, and are, therefore, more dangerous.

In *hæmorrhagia per diapedesin,* which, as already stated, is due to internal causes, the escape of red blood-corpuscles is generally so slow and the amount lost usually so slight that, as regards any influence exerted upon the organism as a whole, it can scarcely be considered a

[1] Fatal pulmonary hemorrhages are only in very rare instances due to aneurism of the bronchial artery, more frequently to aneurism of the pulmonary artery, and most frequently to progressive ulceration of the pulmonary tissue and of the walls of the arteries. Severe hemorrhages from the lungs may result also from general hemorrhagic diathesis (see p. 62) and from trauma.

[2] The designation "parenchymatous hemorrhage"—bleeding from, not into, the parenchyma—while permissible from a practical standpoint, is theoretically unnecessary.

PLATE III

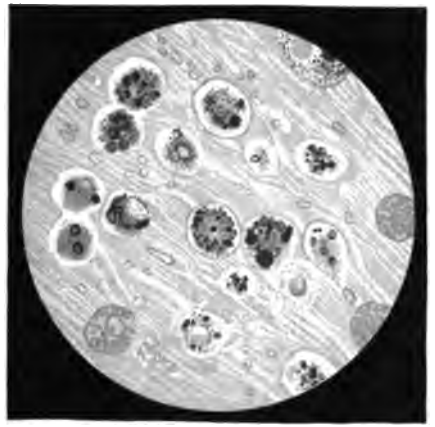

Heart-lesion cells; fresh sputum preparation. Myelin droplet cells and numerous pigment cells with delicate, diffuse, golden-yellow color and fine granulations. Several cells densely filled with coarse granules. (Leitz, 1; Obj., 7.)

true hemorrhage. Sometimes, however, the loss of blood by diapedesis may be so rapid and intense that death may occur in a short time. As Thoma has observed, the blood in these instances pours from the smallest vessels in the form of very minute streams, and immediately after the hemorrhage the small, punctiform openings close, so that after a short time no trace of the source of the bleeding can be seen. According to the investigations of Arnold, the fluid portion of the blood also appears to escape in these cases.

The **internal causes** of hemorrhages are:—

1. Increase of blood-pressure, both absolute and relative. Absolute increase consists either in active hyperemia or congestion (fluxional or stagnatile form of hemorrhage); a combination of both frequently occurs.

Every congestion (compare pp. 39 *et seq.*) may produce hemorrhages. Hemorrhages are especially frequent in heart lesions, particularly lesions of the valvular apparatus; also in cirrhosis of the liver, and in thrombosis of the sinuses of the dura mater. Chronic valvular lesions of the heart usually give rise to red or brown induration of the lungs; in both these conditions a very gradual hemorrhage by diapedesis occurs. The escaped red blood-corpuscles are transformed into pigment, and in greater part taken up by cells (by the flat epithelia of the pulmonary alveoli[1]). Considerable clinical importance is attached to these pigment-laden cells, and they are designated as "heart-lesion cells." (See Plate III.) They are, in part, expelled with the sputum, and under certain circumstances may be of value in differential diagnosis.

---

[1] According to Sommerbrodt, Hoffmann, and others, the "heart-lesion" cells are alveolar epithelia; according to others, partly alveolar epithelia, partly wandering cells (Lenhartz). While the majority of observers are convinced of the significance of these cells in the diagnosis of brown induration, there is now and then some doubt in this direction, since they are occasionally met also in croupous pneumonia, hemoptoic phthisis, and asthma. According to Virchow, the pigment formation occurs by escape of the coloring matter from the erythrocytes and diffusion into the neighborhood, where it collects in pigment granules or crystals; or the red blood-corpuscles, either singly or in masses, are directly transformed into pigment. In both instances the pigment may be yellow, red, or black; diffuse, granular, or crystalline. The blood may undergo pigment metamorphosis even in the capillaries. In addition to the pigment inclosed in cells or lying free in the tissues, Orth found pigment thrombi in the capillaries and even in the larger vessels. The blood-coloring matter may, therefore, be transformed into pigment without participation of contractile cells. On the other hand, the fact first observed by Langhans has often been confirmed, namely: that red blood-corpuscles shrink to a pigment granule only after incorporation by contractile cells, the pigment granule being later transformed by division into a number of small granules. In contradistinction to crystalline hematoidin, which is aferrous, the pigment granules and clusters almost always contain iron; consequently, at Neumann's suggestion, this pigment has been designated as "hemosiderin."

Severe gastric hemorrhages by diapedesis frequently occur in cirrhosis of the liver. In some instances the extravasate may be so great as to cause death.

Thrombosis of the longitudinal sinus produces hemorrhages of the arachnoid and cerebral cortex at the convexity, especially over the posterior portion of the frontal and over the parietal lobes.

Hemorrhages occurring in connection with embolism are closely allied to these examples of the stagnatile form. Embolism of the lungs, spleen, gastrointestinal canal, and in part also of the brain, retina, and kidneys gives rise to hemorrhagic infiltration (infarction) of the corresponding tissue area, because the blood-pressure in the vascular area beyond the occluding embolus is suddenly reduced to zero, and a reverse current sets in from the neighboring communicating capillaries[1] as a result of the change in blood-pressure. In the lungs and intestinal canal under such conditions free hemorrhage also occurs, so that part of the extravasate is expectorated or discharged with the stools. When the large arterial trunks of the intestine are occluded, free hemorrhage is sometimes so severe that death takes place as the result of internal bleeding.

In many cases active hyperemia is all that can subjectively or objectively be demonstrated as the cause of a hemorrhage (fluxionary form of hemorrhage). Since, however, active hyperemia very often occurs without hemorrhage, it must frequently be assumed that an especial weakness (*debilitas*) of the vessel walls exists (compare Pathologic Hemorrhagic Diathesis, p. 64). This local vascular weakness is distinctly demonstrable in all instances in which fluxion involves newly formed vessels with very delicate and therefore less resistant walls (*e.g.*, in *pachymeningitis interna fibrinosa vasculosa*), or involves an area which has already been altered or weakened by an inflammatory irritant (inflammatory form of hemorrhage).

The inflammatory form of hemorrhage is frequent and occurs in almost all tissues. Severe hemorrhages are observed in the serous membranes (*e.g.*, hemorrhagic carcinomatous pleuritis), in the mucous membranes (especially of the gastric mucosa[2]), in the spleen, the brain (here

[1] The blood-pressure in the capillaries is equal to + 40 mm. of mercury.

[2] When the gastric mucosa is catarrhally inflamed and sudden intense contraction of the stomach and abdominal muscles occurs (in vomiting, sneezing, straining, etc.), fluxionary hyperemia may be so greatly increased by temporary obstruction to the flow of blood (by congestion) that small, punctiform hemorrhagic infarctions are produced in the surface of the gastric mucosa, from which, by a kind of autodigestion (the alkaline blood no longer traverses the infarcted portions, which are therefore susceptible to the action of the acid contents of the stomach), so-called hemorrhagic erosions of the stomach develop. The small extravasates occurring from the hemorrhagically eroded portions of the mucosa form fine, brown striæ and puncta, which are suspended in the mucus covering the mucosa and therefore do not become confluent.

generally punctiform hemorrhages, which occasionally become confluent and form larger hemorrhages, *e.g.*, in tuberculous hemorrhagic encephalomeningitis); in the pancreas in hemorrhagic pancreatitis, etc., and also in many acute infectious diseases, which are classed in a special group in section 5. (See p. 61.)

Relative increase of blood-pressure is the cause of hemorrhage in diminution of the pressure exerted upon the outer surface of the vessels, *e.g.*, in dry cupping, balloon ascensions, climbing of high mountains (here the coincident fluxion plays an important rôle).

2. Alterations of the vessel walls. These consist in simple disturbances of nutrition with (*e.g.*, in phosphorus poisoning) and without fatty metamorphosis of the elements constituting the wall, in arteriosclerosis associated with proliferation, etc., and in ectases of the arteries and veins.[1]

Simple nutritive disturbances of the vessel walls give rise to hemorrhages in the course of many acute febrile (compare No. 5) and chronic affections (*e.g.*, in severe icterus), and in poisoning (phosphorus; compare No. 3). Atheroma of the aorta permits the escape of blood from the vessel lumen: on bursting of an atheroma the blood-stream penetrates and, as it were, washes out the atheromatous material, forcibly tears away the media at this point, forms a new channel inside the vessel wall, and thus produces a dissecting aneurism.

Aneurisms of the aorta, particularly in the region of the aortic arch, of the small arteries of the arachnoid, and of the brain (especially miliary aneurisms in the region of the large ganglia), of the pulmonary arteries (more frequently of the pulmonary, less often of the bronchial arteries), and of the large arterial trunks of the extremities, etc., generally give rise, by rupture, to sudden more or less severe hemorrhages. Sometimes the rupture, *e.g.*, of an aortic aneurism bursting externally through the sternum, is preceded by drop-like oozing of blood. Varices of the anus, upon the legs, at the neck of the bladder, in the intestine, etc., may give rise to hemorrhages with or without rupture. In the latter instance the blood escapes from the vessels in congestive and hyperemic states as the result of thinning of the walls.

3. Action of certain poisons: phosphorus, arsenic, potassium chlorate, corrosive sublimate, etc.

The hemorrhages in phosphorus poisoning are due to interference with the processes of oxidation, synchronous increase of proteid disin-

---

[1] The very superficial and usually dilated veins of the mucous membranes, such as are observed especially in richly vascular polypi (of the uterus, nose, etc.), are much more disposed to frequent hemorrhages (especially in congestion and fluxion) than are the true varices, strictly speaking.

tegration, and the consequent fatty metamorphosis of the constituents of the walls, especially in the smaller vessels. Consequently, small, punctiform, striate, and large confluent hemorrhages are found almost everywhere: in the skin, in the *panniculus adiposus,* in the connective tissue between the muscle fibers, in the adventitia of the aorta and larger vessels possessing *vaso vasorum,* in the serous membranes, omentum, endocardium, capsule of the liver; less often in the mucous membranes of the digestive tract, uterus (in pregnant women also in the decidua), in the ovaries, lungs, and rarely in the brain.

Arsenious acid (so-called white arsenic) produces hemorrhages only in the mucosa of the gastrointestinal canal, and sometimes an intense hemorrhagic gastritis.

Corrosive sublimate produces marked hyperemia of the mucosa of the colon, which almost always advances to hemorrhage and hemorrhagic infarction of the mucosa (which are later followed by diphtheritic processes).

In poisoning with potassium chlorate, transformation of hemoglobin into methemoglobin and excretion[1] of the latter through the kidneys occur. The methemoglobin forms pigment infarcts in the kidney, especially in the straight tubules of the pyramids, so that these are often completely occluded.

4 Animal parasites: *Schistosomum hæmatobium, Filaria sanguinis, Agchylostomum duodenale.*

The *Agchylostomum duodenale* (see p. 367) gnaws into the mucous membrane of the upper portion of the small intestine, nourishes itself with the blood of the host, and, after loosening its hold, leaves a small bleeding aperture.

Filaria sanguinis (see p. 358) lives in the blood of man and produces chyluria and hematuria. In the kidneys these parasites are found in the blood-vessels as well as in the tissues (lymph-vessels?).

Schistosomum hæmatobium also resides in the blood-vessels, and by deposition of ova in the mucosa of the urinary passages, colon, etc., causes violent hemorrhagic inflammations, and, among other effects, also hematuria. (See p. 375.)

5. Acute infectious diseases. The manner in which hemorrhages are produced in these affections cannot be stated with absolute certainty, because the various infectious diseases act very differently in this respect. In many cases they seem to be due simply to the coexistence of hyperemia and local debility of the vascular apparatus. In some

[1] It is doubtful whether in this case hemorrhage in a strict sense can be spoken of. It appears that the excretion of methemoglobin begins earlier than the parenchymatous nephritis.

cases the hyperemia apparently depends upon the local presence of the pathogenic agent. At all events, anatomic changes in the constituents of the vessel walls are only rarely demonstrable.

Hemorrhages in acute infectious diseases originate in the most varied localities and tissues of the body. In almost every infectious disease, however, there are certain points of predilection where hemorrhages first and most frequently, though not constantly, occur. For example, the external skin is often the seat of hemorrhages (cutaneous petechiæ) in severe cases of the acute exanthemata: scarlatina, measles, variola, and also in bubonic plague, *typhus exanthematicus*, epidemic cerebrospinal meningitis, and anthrax (here in the region of the malignant pustule). Scarlatina produces an especial disposition to hemorrhagic nephritis, which is sometimes observed also in sepsis, tuberculosis, yellow fever, erysipelas, and other affections. In bubonic plague, the septic processes, glanders, anthrax and yellow fever, ecchymoses of the serous and mucous membranes are frequently found. The ecchymoses may be associated with marked hemorrhage upon the free surfaces, so that in anthrax, as in so-called "bloody flux" (hemorrhagic dysentery), bloody diarrhea, and in yellow fever the characteristic "black vomit," may occur. In yellow fever and plague hemorrhagic infarctions in the lungs are also frequently observed. Hemorrhagic processes in the spleen are not rare in scarlatina, sepsis, and other affections. Typhoid[1] is especially characterized by frequent hemorrhages in the region of the *musculi recti abdominis* as a result of severe parenchymatous myositis, waxy degeneration, and ruptures within these muscles.[2] Nasal hemorrhage (epistaxis) occurs in many severe infectious diseases when the strength of the body has been greatly exhausted, especially in scarlatina, typhoid, erysipelas migrans, furunculosis, pertussis, etc.[3]

6. Chronic diseases which are associated with changes in the blood and result in cachexia (cachectic form of hemorrhage). To these belong chlorosis, leukemia, pernicious anemia, and the marantic stage of malaria, syphilis, tuberculosis, and carcinoma.

The most frequent hemorrhage, which is observed in **chlorosis**, occurs in females, who are decidedly more subject to chlorosis than males, and consists in too severe menstrual hemorrhage—so-called

---

[1] Aside from intestinal hemorrhages, due to premature dislodgment of sloughs. (See Infectious Diseases, p. 507.)

[2] The same changes occur also in fibrinous pleuropneumonia. (For discussion of the hemorrhagic prestadium of fibrinous pneumonia, see Infectious Diseases, p. 532.)

[3] Epistaxis is not infrequent in valvular lesions of the heart, and occasionally it is observed as a vicarious discharge in suppression of the menses.

menorrhagia. Very much rarer are cerebral hemorrhages, which probably are sometimes due to the very thin character of the vessel walls and to the nutritive disturbances of the constituents of the vessel walls so frequently present in young chlorotic individuals.

Pernicious anemia usually gives rise to small hemorrhages which are generally situated in the mucous and serous membranes, in the brain, etc., rarely in the skin, and comparatively frequent in the retina.[1]

Retinal hemorrhages are relatively frequent also in **leukemia.** In this affection hemorrhages, which probably are due to nutritive disturbances within the vessel walls, are observed also in many other organs; epistaxis is particularly frequent. The hemorrhages in the mucosa of the gastrointestinal canal and urinary passages, and in the kidneys, skin, muscles, omentum, lymph-glands, and brain, are usually slight; in the brain, in some instances, they cause by their large size a sudden interruption of function (cerebral apoplexy).

So-called cachectic hemorrhages occur in the most varied tissues and parts of the body. Aside from epistaxis, which occasionally can hardly be arrested and under certain circumstances ends fatally, these hemorrhages caused by nutritive disturbances are usually small.

7. General hemorrhagic diathesis.[2] By this is understood a disposition, a tendency, of the body to hemorrhages at various points upon slight provocation or even to quite spontaneous hemorrhages without demonstrable cause. In contrast to this pathologic general hemorrhagic diathesis stand pathologic local hemorrhagic diathesis, due to local disposition to hemorrhages, and physiologic diathesis (natural delicacy of the vessels, menstrual hemorrhage, etc.).

General hemorrhagic diathesis may be acquired, as in scurvy (scorbutus) and purpura hæmorrhagica (*purpura, morbus maculosus Werlhofii*), or inherited, as in bleeders' disease: *hæmophilia.* Hemorrhages are pathognomonic of these three diseases.

In **scurvy** (*scorbutus*) hemorrhages are observed in the skin, subcutaneous adipose tissue, muscles, the serous membranes, kidneys, and lungs; also from the mucous membrane of the mouth (gums, *stomatitis hæmorrhagica*), the nose, gastrointestinal canal, air passages, urinary tract, and synovia of the joints, respectively. Hemorrhages occur externally from the nose, gastrointestinal tract, and genital canal. Hemorrhages of the gums and pericardium are especially characteristic of

---

[1] According to Müller, retinal hemorrhage is always present in pernicious anemia at its acme, especially near the veins surrounding the papilla. It is rare in chlorosis and simple anemia.

[2] ἡ διάθεσις (διατίθημι) = disposition, state.

scorbutus. The gingival hemorrhages are usually preceded by cyanotic swelling; ulcerations, which occasionally assume a gangrenous character and then readily give rise to metastatic gangrenous foci in the lungs, frequently develop from these hemorrhages. Hemorrhages of the pericardium progress under distinct symptoms of inflammation, as hemorrhagic pericarditis. The same is true also of hemorrhages of the bronchi (hemorrhagic bronchitis) and of the lungs (hemorrhagic fibrinous pneumonia).

The cause of scorbutus is essentially general unfavorable hygienic conditions, principally inadequate and ill-adapted nourishment (too much salted meat, too little fresh vegetables; hence, occasional apparent epidemic occurrence on ships, in besieged cities, etc.); unfavorable state of dwellings (damp, wet, badly ventilated rooms); very severe cold or heat. For some time there has been a tendency to attribute scorbutus to an infection; there is, however, no positive proof of this.

Purpura and **morbus maculosus Werlhofii,** the causes of which are unknown, can scarcely be differentiated from each other. When the spontaneous hemorrhages are small and punctiform and limited to the skin, the process is generally designated as purpura simplex; if they are larger and appear also in other localities (nose, gastrointestinal canal, kidneys, muscles, fasciæ, serous membranes, brain), the condition is called *morbus maculosus Werlhofii.* In both diseases the hemorrhages are usually visible first upon the lower extremities; in purpura they generally remain limited to these parts. *Purpura rheumatica* (*peliosis rheumaticus*) is a combination of purpura with rheumatism: rheumatic swelling of the joints.

Barlow-Moeller's disease (*osteotabes infantum scorbutica*) is due to deficient nutrition, occurs in infants from ¼ to 2 years, and, aside from disturbances of osseous growth, is characterized by hemorrhagic diathesis, especially in the bones, but also in other organs and the gums.

The hemorrhages in **hemophilia** occur partly spontaneously, partly with quite extraordinary intensity upon slight trauma. Both forms of hemorrhage—the spontaneous and traumatic—occur superficially as well as interstitially. The superficial spontaneous hemorrhages occur principally from the mucous membranes of the nose, the whole digestive tract, the female genitalia, the air passages, and the lungs. The spontaneous hemorrhages in the external skin generally occur upon a pathologic basis, *i.e.,* in localities which are pathologicly altered. The traumatic hemorrhages of surfaces follow stabs, bites, and other traumatisms (*e.g.,* laceration of the hymen), especially also after operations (venesection, tooth extraction, etc.). Traumatic interstitial hemorrhages are most

frequently caused by contusion; sometimes, however, also by simple pressure. Spontaneous interstitial hemorrhages are observed principally upon the head and the external genitalia.

Sometimes hemophilia does not involve the whole body, but only one organ, *e.g.*, the kidney: renal hemophilia.

Hemophilia frequently produces large extravasations within (hematomata) as well as outside the body. The hemorrhages are frequently uncontrollable, particularly in small injuries (*e.g.*, from the ruptured hymen). This persistence of the hemorrhage is due partly to atony of the vessel walls, partly to the slight disposition of the blood to form coagula (thrombi). The coagulability of the blood is demonstrable in

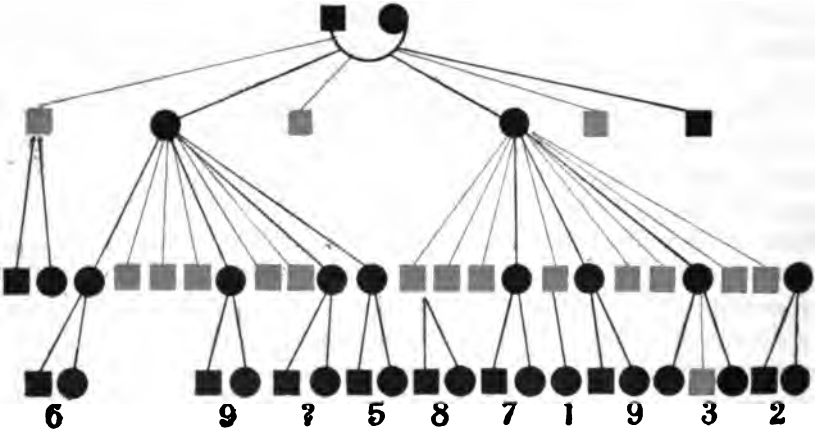

Fig. 10.—Table of the bleeder family Mampel. The red figures are bleeders. ■, male; ●, female individuals. (After *Lossen*.)

all cases, but the coagula are more delicate, gelatinous, and do not possess the tenacity and firmness of ordinary coagula.

In almost all cases spontaneous hemorrhages are preceded by distinctly perceptible phenomena of active congestion. Further, in a causal relation there is also a certain debility of the vascular coats which, according to Virchow, depends upon chronic and acute nutritive disturbances of the vessel tunics, which "sometimes are anatomic, sometimes only functional, in character."

Hemophilia (bleeders' disease) is a pronouncedly hereditary disease; individuals affected with it are designated as "bleeders" ("bleeder families"). Principally, the male members of a family are affected; the disease, however, is inherited also through the non-affected female members. As the majority of the male members of a family succumb to the

disease in youth (some of them reach an advanced age in spite of their hemophilia), the disease is, on the whole, more frequently transmitted through the females than through the males. (See Fig. 10.) When, however, a male bleeder has sons, the disease is comparatively rarely transmitted. It frequently disappears after two or three generations. As a rule, the ratio of affected females to males is 1 to 12 or 13.

While it is doubtful whether all these hemorrhagic processes are independent, another classification is at present impossible.

Pathologic local hemorrhagic diathesis is usually also preceded by phenomena of hyperemia. This is almost always to be observed at the beginning of puberty in healthy, vigorous individuals who suffer from congestions of the head and frequent hemorrhages from the nasal mucous membrane. In many cases the active congestion is dependent upon psychic excitation, corporeal (cardiac) exertion, or the action of alcoholic drinks; in others it apparently occurs spontaneously. The same is true of those individuals in whom frequent hemorrhoidal bleedings occur, which occasionally appear periodically.

Less positively determined is the congestion in unilateral renal hemorrhages. This hemorrhagic diathesis confined to one kidney is of especial interest in so far as until now it has been impossible, either anatomicly or histologicly, to discover any cause for the hemorrhage, in spite of the fact that such kidneys have repeatedly been extirpated and carefully examined.

Finally, we may here mention also *melæna neonatorum,* although this peculiar affection, so far as our present knowledge extends, belongs only in small part (perhaps not at all) in the category of local hemorrhagic diathesis. By *melæna neonatorum* is understood an affection of the newborn which is characterized essentially by the discharge of black, tar-like masses from the gastrointestinal canal. These masses consist in great part of blood which has undergone a certain change. Many cases terminate fatally; a source of the hemorrhage is usually not visible at necropsy; the only alterations which can sometimes, but not always, be found are small, quite flat abrasions of the gastric mucosa (hemorrhagic erosions). Here the process is a hemorrhage by diapedesis, and the small losses of substance indicate that the gastric mucosa, at any rate, participates in the hemorrhage.

According to recent researches it appears possible, from the not inconsiderable number of cases of melena, etiologicly to distinguish two groups: the infectious and the traumatic. In the former group the question is apparently one of general septic affections; in the traumatic group, lesions of the calvarium, the meninges (hemorrhages, etc.), or the brain.

It is customary to distinguish external and internal hemorrhages and to designate as external those which occur directly externally, so that blood is visible as a free hemorrhage upon the free surface. Internal hemorrhages occur in the interior of the body, either as a free hemorrhage upon one of the internal surfaces (of canals or cavities of the body)—in which case the bleeding is invisible, but it can sometimes be diagnosticated from certain symptoms—or in the form of hemorrhagic infiltration into the tissues themselves. When these tissues are visible (*e.g.*, skin, gums), the hemorrhage or the seat of the hemorrhage is recognizable by the more or less distinct swelling and change of color (*e.g.*, in contusions); when, on the other hand, they are situated within the body (in the internal organs) or are covered by other tissues (*e.g.*, musculature), the hemorrhage itself cannot be seen.

The extent of the hemorrhage is generally independent of the locality. Free hemorrhage, as well as hemorrhagic infiltration, may be small or large. If little blood infiltrates the tissues, small, circumscribed, punctiform hemorrhages: ecchymoses, or more extensive extravasations: suffusions, occur; if larger amounts of blood are effused into the tissues, blood-nodes or blood-foci, infarcts, hematomata are produced. In the first instance the tissue is more uniformly permeated with blood or red blood-corpuscles, without injuries of the tissues or vessels being recognizable by the naked eye. In this event the swelling is usually only slight, often scarcely recognizable. In the severer degrees of hemorrhagic infiltration the more intense local accumulation of blood can occur only under marked swellings (generally with the sensation of tension or pain) and distinctly visible rupture and laceration of the tissues. When such a hemorrhage occurs immediately beneath the surface (*e.g.*, beneath the ependyma of the cerebral ventricle) this is, in many cases, also destroyed, so that the hemorrhagic infiltration is associated with free hemorrhage.

Hemorrhagic infiltration is observed in crushing,[1] contusion, congestion and stasis, embolism, thrombosis; in many forms of poisoning, infectious diseases; in general hemorrhagic diathesis, etc.

Small, free hemorrhages in the interior of the body often remain unnoticed; larger free hemorrhages are usually manifested by their sequelæ.

The blood effused into natural canals or cavities of the body either remains *in loco:* latent hemorrhage, or it is subsequently dis-

[1] When the external action is very strong, marked fragmentation of the tissues and laceration of the surface are generally present, so that free hemorrhage also occurs.

charged externally. Latent hemorrhage is observed principally in hemorrhages into closed cavities, *e.g.*, in intermeningeal hemorrhages, in hemorrhages into the pericardium, pleura, peritoneum, joint cavities, cerebral cavities, between the tunica vaginalis of the testes, etc.; more rarely in hemorrhages into the natural canals (urinary passages, stomach, etc.). Subsequent discharge externally occurs, as a rule, in hemorrhages into the lungs (rusty sputum in fibrinous pneumonia, in hemorrhagic infarction) and the air passages (bursting of aneurisms, erosion of vessels in ulcerative processes); into the digestive tract (gastric hemorrhage in hepatic cirrhosis, hemorrhagic erosions, and gastric ulcer; in *melæna neonatorum;* intestinal hemorrhage from typhoid ulcers; in embolism of the superior mesenteric artery, etc.); into the kidneys (hemorrhagic nephritis) and the urinary tract (inflammations, neoplasms, varices), and into the genital canal (in menstruation, parturition, inflammatory processes, richly vascular polypi, etc.).

When the blood is subsequently discharged externally, it appears either pure or mixed with secretion (gastric juice, urine, feces: hemorrhagic secretion) or with exudate (mucus, fibrin, pus: hemorrhagic exudate). In both cases it may be expelled in either a liquid or coagulated state. If pure blood is discharged, it usually possesses its natural color; if it is mixed with exudate or secretion, its appearance may be more or less altered. For example, blood exposed to the action of the gastric juice assumes a dark-brown color; on the other hand, if severe hematemesis occurs suddenly, so that the gastric juice acts upon it but slightly or not at all, the blood is usually quite unaltered; if it is discharged quickly, it is liquid; if it remains for some time in the stomach, it generally coagulates and then frequently forms a complete cast of the more or less distended stomach (with distinct reproduction of the form of the stomach). Blood which passes through the whole or the greater part of the intestinal canal assumes a dark, blackish color, even when it is not mixed with feces (as, for example, in *melæna neonatorum*); while blood from the colon is sometimes discharged almost unaltered (*e.g.*, in so-called red or bloody flux). The blood mixed with mucus and expectorated in fibrinous pneumonia imparts to the sputum the characteristic rust-brown color; on the other hand, the blood in ulcerative processes in the lungs, when a sudden severe hemorrhage (hæmoptoë, hæmoptysis) occurs, is expelled either quite pure and liquid or, more frequently, mixed with air as a foamy, bright-red mass. Menstrual blood is generally liquid, because the acid secretions of the vaginal mucous membrane, with which the blood is mixed, prevent coagulation; in dysmenorrhea, on the other hand, the blood is partly coagulated, because in this case it remains for some

time in the uterus and does not come in contact with the acid vaginal secretions until after it has coagulated. Blood from the kidneys (hemorrhagic nephritis, unilateral renal hemorrhages in local hemorrhagic diathesis) is discharged with the urine and colors the latter a few shades darker, sometimes red; usually the amount of blood is so slight that it can be demonstrated only by careful microscopic examination. If, on the other hand, large amounts of blood enter the urinary tract at one time (from the renal calices and pelvis, ureters, bladder, urethra), coagula are frequently formed, which are either discharged externally or retained in the urinary tract, and then not infrequently serve as the nucleus for calculous formation.

Certain hemorrhages have from ancient times received certain designations. For example: for nasal hemorrhage: epistaxis (ἐπιστάζω = drip); rectal hemorrhage: hemorrhoides (αἷμα - ῥέω = flow, stream forth); bloody spit: hemoptoë (αἷμα and ὤπται, pass. of ὁράω = to become visible); bloody expectoration: hemoptysis (αἷμα - πτύω = to spit); bloody vomit: hematemesis (αἷμα - ἐμέω = to vomit); bloody urine: hematuria; excessive menstrual bleeding: menorrhagia (μήν = moon and ῥήγνυμι = rush or burst forth); for uterine hemorrhage from other causes: metrorrhagia (μήτρα = uterus). Many bleedings owe their designation to the locality of their occurrence: hematothorax, hematopericardium, hematocele, hematometra, hematokolpos (κόλπος = inlet, sheath, vagina). For other hemorrhages the term hematoma (blood-tumor) is used: *hæmatoma duræ matris, hæmatoma vulvæ, hæmatoma ovarii, hæmatoma retrouterinum.* Finally, some forms of bleeding are designated according to their appearance: *purpura:* small red blood-spots of the skin, *melæna* (μέλας = black, and αἷμα) from the black, tar-like dejecta of the newborn.

Hemorrhages may exert an injurious influence upon the organism in a dual manner: first, by the size of the extravasate alone, *i.e.,* by the loss of blood, and, secondly, by functional disturbances of those organs which are the seat of the bleeding.

In external hemorrhage it is a question only of the quantity of blood lost. This may vary within very wide limits. When a third or more of the total amount of blood is suddenly withdrawn from the circulation by internal or external hemorrhage, death occurs from acute anemia.[1] If smaller amounts of blood are lost quickly and in such rapid

[1] The question how much blood must be lost to cause death cannot exactly be answered, because the general condition of the body from which the hemorrhage occurs must be considered. It may, however, be stated that when in adults the loss exceeds 2 liters there is danger of death. Small losses of blood may be fatal!

succession that the organism is unable in the intervals of the hemorrhages to compensate for the loss by regeneration of blood, chronic anemia and hydremia develop. In smaller single hemorrhages which are not too profuse, the loss of blood is compensated in a remarkably short time. Compensation takes place, first, by increase of the watery content of the blood still present, water being drawn from the tissues (hence, great thirst after large hemorrhages); then follows an increase of the colorless blood-corpuscles (leucocytosis), and last begins the new formation of red blood-corpuscles by the so-called hematopoietic organs (bone-marrow, lymph-glands, spleen, possibly also the liver). In this manner large extravasates can be completely compensated in from two to three weeks, and smaller hemorrhages in a shorter time.

Hemorrhages which cause death from the size of the extravasate originate as the result of external injuries, especially on opening of large arterial trunks; by bursting of large aneurisms; rupture of the heart; during parturition and abdominal pregnancies (ectopic gestation); by ulceration in the lungs, gastrointestinal canal, etc.

The **functional disturbances** caused by internal hemorrhages vary according to the locality and size of the hemorrhage. The function of an organ is either more or less markedly disturbed or entirely suspended. In the latter case, if one of the so-called vital organs is involved, death usually occurs suddenly. Thus, severe pulmonary hemorrhages which fill the air passages with blood and arrest respiration in this manner cause death under manifestations of asphyxia, and cerebral hemorrhages, by disintegration of the cerebral substance, pressure upon surrounding tissues, and interruption of nervous impulses, cause death under phenomena of apoplexy. In less severe pulmonary hemorrhages dyspnea may occur, and in smaller cerebral hemorrhages paralysis or paresis develops. Smaller hemorrhages in those portions of the brain important for life (in the large ganglia, internal capsule, island of Reil, pons) are usually more deleterious than comparatively larger hemorrhages in other parts. Hemorrhages of the urinary tract—frequently with distention of the affected portion—cause retention of urine and sometimes complete anuria and uremia. Hemorrhages into the pericardium may, after marked distention of the sac, cause death by pressure upon the heart; hemorrhages into the pleural cavity may cause more or less extensive atelectasis, and hemorrhages into the joints may limit or arrest the power of motion.

When the extravasate in internal hemorrhages is not subsequently discharged externally, but remains *in situ*, the blood either coagulates or remains liquid. In the latter case complete absorption of the extravasate may take place; the serum is

first absorbed, then the red blood-corpuscles are dissolved, the hemoglobin diffused and absorbed like the serum. This is the case especially in smaller hemorrhagic infiltrations (*e.g.*, from contusion) and in hemorrhages into joint cavities and serous cavities (especially the peritoneal cavity). When the blood coagulates (always in cerebral hemorrhages, frequently in pericardial hemorrhages, sometimes in pleural hemorrhages) the extravasate undergoes further changes, which may consist in organization, pigmentation, inspissation, or softening. In coagulation, first the serum is separated from the coagulum in the ordinary manner; when the serum reaches the periphery of the coagulum it is absorbed; if the coagula are peripheral, so that the serum collects in the center, the serum may remain inclosed.

In **organization** cells and vessels grow from without into the coagulum, so that the latter is gradually replaced by connective tissue

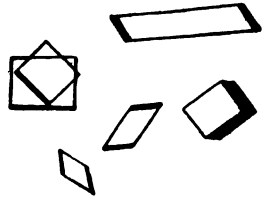

Fig. 11.—Hematoidin crystals from a brown focus of softening of the brain. (Highly magnified.)

which finally is converted into cicatricial tissue. In this manner, if the serum was retained in the center of the coagulum, small cysts develop (especially in the brain); if the serum was in the periphery and has been absorbed, cicatrices result.

Under these circumstances the hemoglobin may be partly diffused and absorbed; some of it, however, usually remains *in loco* to be converted into diffuse, or granular (nodular or amorphous siderin), or crystaliine (hematoidin crystals or fine needles) pigment. (Fig. 11.)

Condensation of the extravasate consists in a gradual inspissation. During this process all the blood-coloring matter may be absorbed in the manner already described, or, at least in part, remain *in loco*. The condensed, dry exudate mass, like many other dead parts, is frequently infiltrated with lime-salts: calcified.

Softening of the exudate may be simple, digestive, or putrid. In simple softening granular disintegration of the fibrin and usually at the same time also disintegration of the red blood-corpuscles without absorption of the hemoglobin occur, so that a brownish pap-like material

develops from the coagulum by imbibition of watery fluid. Digestive softening is confined to superficial, hemorrhagicly infiltrated areas in the mucous membrane of the stomach; under the action of the acid contents of the stomach so-called hemorrhagic erosions develop from these areas by a kind of digestion. Putrid softening occurs only when infectious germs enter the extravasate and a suppurating or putrid process develops.

Hemorrhage may artificially be arrested by ligation, compression, etc., or it ceases spontaneously after a time. Spontaneous cessation is favored by three events: 1, in arteries, by inversion and contraction of the muscularis, which thus produce progressive narrowing of the lumen almost to complete closure; 2, in all vessels, by lowering of the blood-pressure within the vessels as the result of loss of blood, and, 3, by the formation of coagula, first outside the injured vessel. These coagula attract, as it were, the fibrinoplastic substance still present in solution in the blood; for this reason coagulation advances toward the interior of the vessel, and an occluding thrombus is thus finally produced.

STASIS.

By stasis[1] is meant a local arrest of the blood-current within the capillaries without coagulation, but with alteration of the proportion of the constituents. Arrest without change in the proportion of the constituents is designated as stagnation (*stagnare:* submerge, flood, to be under water). The change in the proportion of the constituents in stasis consists in condensation of the blood in a locality by loss of the watery constituents.

Between the blood, the living vessel wall and the surrounding tissues there is a ratio of diffusion which depends upon the chemic and physic characters of these three parts. The diffusion current through the living vessel wall is determined by molecular attraction (attraction theory). Every alteration of the tissues may cause a change in the molecular attraction of the blood. If a tissue area is subjected to irritation which produces alteration of the molecular attraction, acute exudative processes may develop which, by abstraction of the watery constituents, cause condensation of the blood at this point. If this local condensation causes arrest of the blood, stasis occurs.

Stasis, therefore, is not a primary circulatory disturbance; the pri-

---

[1] στάσις = from ἵστημι = stand, arrest.

mary disturbance is tissue alteration,[1] which is associated with local condensation of the blood; the circulatory disturbance is a secondary phenomenon.

Stasis occurs in all inflammations ending in necrosis[2]: for example, in diphtheria[3] and typhoid (in the latter only in the area of the slough); in cauterizations (in the area of the sphacelus); in red heat of the third degree (sloughing, carbonization); in the highest degrees of freezing (gangrene), and by evaporation (*e.g.*, in excoriation in the region of slough formation). The termination of stasis, therefore, is always necrosis.

Stasis has frequently been the subject of experimental and microscopic investigation. That which can be observed under the microscope is about as follows: At first slowing of the blood-current is seen; then the sluggish, colorless (plasmatic) marginal zone of the blood-stream, which is free of red blood-corpuscles, gradually disappears, the red axial stream, consisting of red blood-corpuscles, spreading out and the red blood-corpuscles increasing in number; finally, the whole vessel lumen appears to be densely filled with red blood-corpuscles, which are frequently somewhat shrunken, and the blood-current is arrested.

THROMBOSIS.

Thrombosis[4] is coagulation of the blood within the vessels during life. This is always due to pathologic conditions. Without the latter, the blood flowing within the living vessel walls remains fluid, because the living vessel wall prevents coagulation.

In the act of coagulation the blood passes from the fluid to the solid state; that portion of the blood which becomes firm is called the

---

[1] According to Samuel and Cohnheim, the primary change is an alteration of the vessel wall, which renders the latter incapable of resisting the blood-pressure and of retaining the liquid constituents of the blood.

According to von Recklinghausen, the first visible change is an alteration of the red blood-corpuscles, which become firmer and less flexible.

According to Henle, the result of the alteration of the vessel wall is that more water than albumin and fibrin is abstracted from the fluid portion of the blood; the blood-plasma becomes more concentrated and consequently the viscidity of the blood, and the friction against the vessel wall is increased.

[2] Stasis is not a necessary concomitant of inflammation. It is lacking, for example, in all exudative inflammations. It was first observed in inflammation and was, therefore, formerly considered a concomitant of inflammation. Every inflammation in which stasis occurs (inflammatory stasis) invariably results in local death of the tissues (necrosis).

[3] Only, however, in superficial mortifying, but not in exudative fibrinous, processes. (See Diphtheria, p. 523.)

[4] *θρομβοs* = to clot, from *τρεφω*, *τέτροφα* = to make firm, coagulate.

clot or coagulum.[1] Clotting or coagulation[2] is due to separation of fibrin under the influence of a ferment (fibrin ferment: *thrombin*) which is present in minimal amount in the blood-plasma even under normal conditions. Thrombin is derived from an inactive antecedent: prothrombin (*thrombogen*), which exists in the tissue- and blood- cells, and is converted into ferment (thrombin) under the action of so-called zymoplastic substances; likewise present in the cell-plasma, especially that of the red blood-corpuscles. Thrombin separates from the proteid of the blood-plasma, *i.e.*, the paraglobulin (formerly so-called fibrinoplastic substance), so-called fibrinogen (metaglobulin), which is still fluid, but is precipitated as firm fibrin by lime-salts present in the blood. The zymoplastic substances develop at the instant the blood leaves the vessels, probably chiefly as the result of disintegration of blood-platelets, probably also of red blood-corpuscles and leucocytes. There are also thrombogenetic substances derived from the tissues—tissue coagulin—which act upon the blood chiefly as ferments. The combined action of these various substances explains why the blood does not coagulate in the living vessels. Many authorities assume the existence of substances, referred principally to the endothelia of the intima, which inhibit coagulation. The serum itself remains liquid. Fibrin consists of minute fibrillæ which are intimately intertwined and form a more or less dense reticulum.

With occurrence of coagulation, part of the white cells as well as many of the red blood-corpuscles show signs of disintegration, to which change very probablly is due the formation of the so-called "blood-plates."

Coagulation of the blood occurs outside the vessels, inside the vessels after death,[3] and inside the vessels during life (thrombosis).

I. Coagulation outside the vessels is observed in hemorrhages, when:—

1. The blood is discharged externally. This blood (*e.g.*, venesection blood) may be caught in a receptacle and coagulation directly observed. This occurs either in the ordinary manner, *i.e.*, quite rapidly (ordinary coagulation), or slowly (delayed coagulation). In the first instance the blood-corpuscles are inclosed by the fibrin reticulum,[4] and the fluid serum is pressed out by contraction of the fibrin mass. The specifically heavier fibrin, with the inclosed blood-corpuscles, then sinks in the specifically lighter serum, and the latter collects at the top.

---

[1] See footnote, p. 53.
[2] *Coagulare:* to make coagulate, curdle.
[3] See footnote, p. 53.
[4] Fibrin + blood-corpuscles form the so-called blood-clots, *placenta sanguinis.*

In delayed coagulation the blood-corpuscles, the heaviest constituents, have time slowly to sink and collect at the deepest part before coagulation arrests them. If coagulation now begins, the fluid part of the blood, which is specifically lighter than the blood-corpuscles and therefore lies above them, separates into fibrin and serum above the red blood-corpuscles, so that (in the receptacle) the following strata can be seen from above downward:—

Serum,
Fibrin coagulum (sizy, buffy coat, *crusta phlogistica*).
Blood-corpuscles (*cruor*) { above: the white (*crusta granulosa, cruor lymphaticus*). below: the red, red *cruor*.

2. The blood is extravasated into body cavities during life (in free hemorrhages into the interior of the body: in severe gastric hemorrhages, when the blood remains in the stomach; in hematometra, dysmenorrhea; in hemorrhages into the ureters, etc.), or enters the tissues in large amount (in hemorrhagic infiltration; in hematomata, apoplexia sanguinea cerebri, etc.).

II. Coagulation within the vessels after death (never within the capillaries!) generally occurs slowly, especially in the heart; hence, separation of the blood into buffy coat and cruor is frequently observed in the cadaver (most frequently in the heart). If inflammations in which the inflamed tissues (*e.g.*, in fibrinous pneumonia, pleuritis, and fibrinous pericarditis) formed fibrinous exudates existed during life, the fibrin content of the blood is increased[1]; in this case formation of large numbers of quite firm fibrin coagula is almost constantly observed *post mortem*.[2]

Coagulation occasionally occurs very early, particularly in pathologicly altered vessels and on contact with foreign substance; it may be hastened also by high temperature. In other cases it is absent: for example, in great richness of the blood in alkalies and acids (*e.g.*, carbon dioxide; hence, the blood is fluid when death has occurred from asphyxia).

In bleeders the disposition of the blood to coagulate is usually diminished.

III. Coagulation of the blood within the vessels during life (thrombosis) is caused by:—

1. Passive congestion. This may be due to:—

[1] Also in pregnant women.

[2] The older the thrombus, the more water it loses; it becomes dry and wrinkled. A coagulum formed *post mortem* is surrounded by dead tissue and therefore is not subjected to absorption of water from this source; consequently, it remains moist and smooth.

(*a*) Narrowing or occlusion of the vessel lumen, *e.g.*, by ligation[1] of arteries and veins, compression of veins, marked amyloid degeneration of the capillaries. As a result of this, slowing or arrest (stagnation) of the blood-current occurs. In this case a thrombus does not form at once, but only after hours.

(*b*) Interruption of the continuity of the vessel wall by trauma (severance, rupture) or by pathologic processes. Here retraction of the media and intima with inversion and narrowing of the lumen are observed in the arteries as a result of contraction of the muscularis. In the veins slowing of the current occurs principally as the result of lack

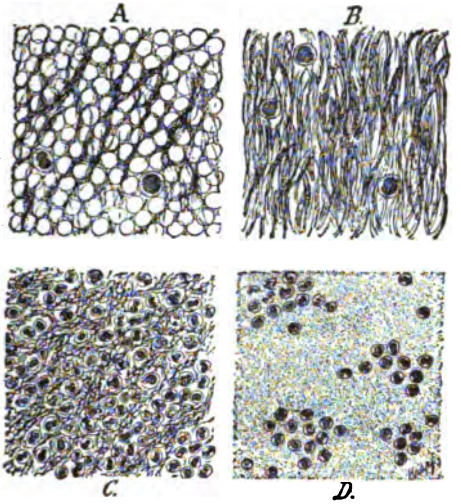

Fig. 12.—*A*, blood-clot; *B*, fibrin coagulum; *C*, white-cell thrombus, with fibrin; *D*, plate thrombus, with scattered leucocytes. (After *Smaus.*)

of the propelling force (*vis a tergo*); occasionally (*e.g.*, in amputations) reversal of the current up to the nearest venous valves results.

In the open, valveless veins of the freshly emptied gravid uterus, contraction of the uterus favors thrombosis by the constriction and compression thus exerted (compression thrombosis).

(*c*) Persistent dilation of the heart and vessels: dilation thrombosis. Here belong varices, aneurisms, partial aneurisms of the heart, dilated auricles. In markedly diminished cardiac power, the recessus between the trabeculæ of the heart acts quite similar to these persistent dilations.

[1] But only when the intima is torn or injured by the ligature. In ligature without injury of the intima, no thrombosis at the point of ligation occurs. When, with careful protection of its walls, a blood-vessel is ligated at two points between which no branch is given off, the blood may remain fluid within the ligated section for weeks.

(*d*) Absolute diminution of the force of the heart as a result of severe acute (*e.g.*, typhoid) or chronic (bone suppurations, tuberculosis, carcinoma) affections in marantic individuals, especially when local impediments also exist. This slowing of the blood-current caused by marasmus always results in the formation of thrombi in the veins only: marantic thrombosis.

2. Alterations of the molecular attraction between the blood and the surrounding parts (*e.g.*, of the internal surface of a vessel). The molecular attraction is altered by:—

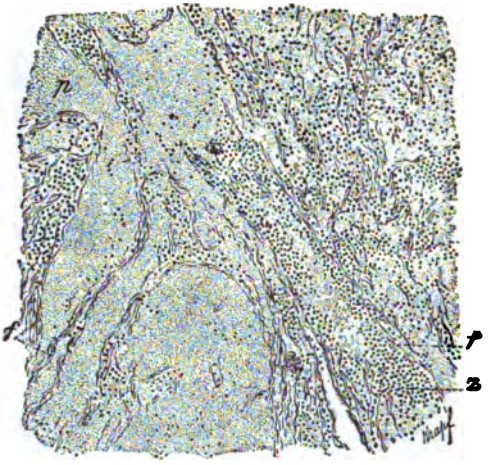

Fig. 13.—Plate thrombus. *f*, fibrin; *p*, blood-plates massed as fine granules; *z*, leucocytes. × 49. (After *Smaus.*)

(*a*) Nutritive disturbances within the vessel walls, simple as well as inflammatory: in the arteries and heart by chronic thickening, calcification, fatty metamorphosis, and ulceration of the intima or endocardium; in the veins by suppurative processes which attack the venous walls from without.

(*b*) In the arteries and veins by gangrenous processes.

(*c*) Foreign bodies which enter the vessels, *e.g.*, ligatures, wood splinters, needles, bullets, coagula, etc.

(*d*) Ferment formation within the flowing blood: ferment thrombosis. Influences which destroy the blood-corpuscles: toxic influences, act as a cause of the formation of fibrin ferment within the blood-vessels. Thus, thrombosis is observed within the smaller vessels in extensive burns, and in poisoning by mercury, arsenic, and phosphorus.

According to their composition, three varieties of thrombi are distinguished:—

1. White thrombus. This is composed of fibrin coagulum and blood-plates.[1] According to the investigations of Zahn and others, it develops in the erythrocyte-free marginal (plasmatic) zone of the flowing blood. (See Fig. 12, D, and Fig. 13.)

2. Red thrombus. This differs from the so-called white thrombus by its great richness in red blood-corpuscles; to the latter it owes its color and name. It develops principally in stagnant blood.

3. Mixed or **lamellated thrombus.** In this, white and red thrombus masses occur together, sometimes even quite uniformly stratified or lamellated. It occurs especially in the interior of aneurismal dilations of the heart and aorta, and in so-called continuous or progressive or secondary thrombus.

When, in addition to the constituents already described, a thrombus contains infectious germs, it is called an infected or infectious thrombus. On the other hand, a non-infectious or bland thrombus is one which contains no infectious germs.

According as a thrombus partly occludes or narrows the lumen of a vessel or completely fills it are distinguished mural (lateral, parietal) or narrowing thrombi, and obstructing or occluding thrombi. In the heart, only mural thrombi occur; in the arteries the mural are more frequent than the occluding; in the veins mural thrombi frequently develop from the pockets of the venous valves, *i.e.*, from the space between the valve and vein wall: valvular thrombi. Occluding thrombi are observed most frequently in solution of continuity, in marasmus, and in inflammations of the veins (phlebitis).

Furthermore, we distinguish between primary or autochthonous (*i.e.*, formed at the place where found) and secondary or progressive thrombus. The former is principally mural and occurs in the heart, arteries, and veins; the latter may be mural as well as occluding, and occurs more frequently in the veins than in the arteries and heart. Progressive thrombi always grow in the direction

---

[1] The blood-plates are considered by Hayem, Bizzozero, Laker, Löwit, Eberth, and Schimmelbusch and others as the constant so-called third formed constituent of the normal blood. A few investigators (Ziegler, Wlassow, and others) are of the opinion that the blood-plates are disintegration products of the red and colorless blood-corpuscles; others consider them globulin precipitates. Lilienfeld considers the blood-plates as derivatives of the nuclei of leucocytes (nuclein platelets). J. Arnold is of the opinion that the blood-plates are produced from erythrocytes by constriction. There is, therefore, no unanimity among authorities as to the question whether the blood-plates are to be considered constant normal constituents of the blood. They are small, flat, rounded or oval corpuscles which are very much smaller than a red blood-corpuscle (the blood-plates are about one-fourth the size of the red blood-corpuscles). These blood-plates cling to each other during coagulation (conglutination) and readily adhere to the vessel wall.

toward the heart. The length of these progressive thrombi is very variable; in some instances thrombi of the large venous trunks may grow onward into the right auricle.

In the heart the external conformation of thrombi may be verrucous[1] (*verruca:* wart), globular (*globus:* sphere), or polypous; in the arteries and veins hemispheric, globular, polypoid, or cylindric. At first most thrombi are very small; then they generally begin gradually to grow, the coagulated fibrin (or the conglutinated blood-plates), like a foreign body, attracting the fibrin still present in solution. In this manner new deposits develop in lamellated form which, with more uniform precipitation, lead to spheric or cylindric, with more unequal precipitation, to nodular, cauliflower-like (verrucous), and villous (polypoid) formations. At first the surface of these coagula is almost always smooth; later, however, it may assume another conformation, appear rough and uneven, especially when portions are broken off or torn away. The surface of thrombi is frequently corrugated or wavy; this is particularly the case when the surface is directed toward the flowing blood, and is almost always to be observed in large parietal thrombi of the heart and aorta, especially within aneurismal dilations.

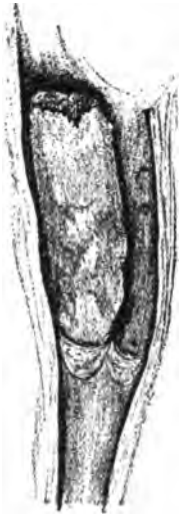

Fig. 14.—Valvular marantic continuous thrombus of the femoral vein of a consumptive girl. At the upper end, directed toward the heart, is a roughened fracture surface. The fragment dislodged from this point caused pulmonary apoplexy by occlusion of a pulmonary artery. (After *Langerhans.*)

Partial thrombi of the arteries and veins which only diminish the lumen are frequently unrecognized during life, because they seldom produce symptoms. Thrombi of the heart frequently cause embolism.

If sufficient collateral circulation is not established by the aid of further anastomoses, occluding thrombi of the veins cause engorgement with its further consequences (tendency to watery transudations, *e.g.,* in *phlegmasia alba dolens;* tendency to hemorrhage, *e.g.,* in the brain in sinus thrombosis; induration; functional disturbances, etc.). (See Results of Engorgement.)

---

[1] Principally upon the valves and *chordæ tendineæ;* rarer, in other parts.

Occluding thrombi of the vena porta and of the inferior vena cava demand special consideration, because a great part of the blood returns to the heart through these veins. In occlusion of the portal vein by thrombosis (also in cirrhosis of the liver) there is intense engorgement of the vena azygos and hemiazygos, *venæ œsophagæ, spermaticæ, umbilicales, parumbilicales,* and of the veins of the *ligamentum teres* and *suspensorium* and of the anterior abdominal wall. Intense congestion of these veins produces a dense convolution of greatly dilated and very tortuous veins, which has been designated *caput medusæ.* The same phenomenon is observed also in occlusion of the inferior vena cava. If in this condition the large radical branches are open, a collateral circulation may readily be established through these. The latter is established through the vena azygos (lumbar and inferior intercostal veins) and hemiazygos to the superior vena cava; through the epigastric to the mammary; through the femoral, abdominal, and thoracic veins to the diaphragmatic and intercostal veins, the *plexus dorsalis* and *plexus spinalis anterior* and *posterior.*

Obstructing thrombi of the arteries produce the same phenomena and results as embolism, with the difference, however, that in embolism the sequelæ (or symptoms) appear more rapidly, suddenly, and, therefore, usually more intensely. (See Embolism, p. 85.) If the occlusion of an artery by a thrombus occurs very slowly, a sufficient collateral circulation may be established. If no collateral circulation develops, then first anemia, if occlusion is complete, and hyperemia in the collateral area are observed. The anemia, owing to its slow development, is usually less dangerous than the anemia following embolism. It may, however, be associated with functional and nutritive disturbances, and even terminate in mortification.

Whenever thrombi remain for some time (one to two days) in close contact with the vessel wall, changes occur in the thrombus as well as in the vessel wall, which may vary according to the composition of the thrombi. The alterations in the thrombi themselves are always of a purely passive nature. When no infection is present, the changes in the vessel walls consist in proliferation of the endothelia and of the intima cells, and in budding of the vasa vasorum. If the vessel walls are diseased, as, *e.g.,* within varicose and aneurismal sacculations, the progressive changes are usually very slight and, consequently, there is at most a very loose union between the inner surface of the vessel and the thrombus.

In other cases the thrombus acts like a foreign body which excites the vessel wall to a more intense reactive process; then it is seen that the cellular proliferation as well as the new vessel formation penetrates

the thrombus and organizes and vascularizes it in a comparatively short time (eight to fourteen days). In organization and vascularization of the thrombus the latter remains passive, in that it gradually is substituted by richly vascular connective tissue. The constituents of the thrombus itself do not participate in the process of organization or vascularization.

In the process of organization the thrombus itself undergoes partial hyaline metamorphosis, the fibrin fibrillæ coalescing to form a homogeneous mass. The thrombus is thus rendered firmer, denser, and smaller. This diminution in size may advance so far that in certain localities where intimate union with the vessel wall has not as yet occurred the thrombus is lifted from the wall, and in this manner the old lumen of the vessel is partly restored (lateral canalization). Later, when the thrombus is replaced by connective tissue, further reduction in the size of the former thrombus may occur as a result of cicatricial contraction and, at the same time, progressive restoration of the old vessel lumen take place.

In other cases partial restoration of the vessel lumen may occur without lateral detachment of the thrombus by the development within the thrombus, through vascularization, of wider vessels which traverse the thrombus in the longitudinal direction of the vessel. If this occurs to a marked degree, a previously occluding thrombus may appear pervious throughout. Sometimes organization and vascularization of the thrombus do not occur even though the vessel walls are not in a pathologic or weakened condition. The reason for this is unknown. Sometimes only the external (peripheral) layers of the thrombus are organized. In large varicose and aneurismal dilations organization and vascularization fail to take place, because the constituents of the wall are in a pathologic condition, in a state of retrograde metamorphosis, and, therefore, progressive changes occur only partially and incompletely.

Whenever organization or vascularization fails to occur, other alterations generally appear which, in contradistinction to progressive organization, may tersely be designated as retrograde changes. These consist in induration or softening.

In induration (hornification, hardening) the thrombus becomes firm, dry, and shriveled; subsequently a deposition of lime-salts (calcification) usually occurs, whereby the indurated thrombus is converted into a stone. This petrification occurs most frequently in the veins (phleboliths).

Softening begins by the red blood-corpuscles losing their coloring matter and undergoing granular disintegration. The fibrin fibrillæ also disintegrate into a granular detritus (soft disintegration product,

from *deterere:* triturate, erode), a creamy, whitish-yellow, pyoid mass (pus-like, puriform mass), which microscopicly consists of small, fine, pale albumin granules. Finally, the colorless blood-corpuscles disintegrate by fatty metamorphosis. If many red blood-corpuscles were inclosed in the softening thrombus, the puriform mass may possess a more or less reddish or reddish-brown color (similar to pus mixed with blood). Puriform softening of thrombi is to be distinguished from true suppurative, purulent disintegration. Puriform softening always begins in the oldest, central lamellæ. If it reaches the surface, there is danger that parts of the softened and disintegrating thrombus may be dislodged by the blood-current and cause embolism. Puriform softening is extremely frequent in parietal thrombi of the heart and in progressive thrombi of the veins. From the latter, smaller or larger fragments are quite often dislodged by the blood-stream just at those points where the thrombus grows out of smaller branches, protrudes into larger, and forms projections exposed to the blood-current. By dislodgment of large fragments sudden death may occur from pulmonary embolism.

True purulent softening of thrombi[1] is always due to the presence of infectious material, whether the latter, as in certain puerperal cases, is within the vessels or whether a suppurative process attacks the arterial or venous wall from without and the thrombosis is the result of purulent arteritis or phlebitis, respectively. In every suppurative softening of a thrombus the disintegration, in contradistinction to puriform softening, progresses from without inward, the pus-corpuscles entering the thrombus from without being furnished, not from the thrombus, but from the vessel wall or the surrounding tissues. Here, also, the danger of embolism is very great, because the thrombus disintegrates, the disintegrating infectious material is transported by the blood-stream and occludes distant arterial vessels. (For further results of embolism, see Embolism.)

EMBOLISM.

The process of embolism (ἐμβάλλειν : to throw into) is dependent upon foreign substances which enter the circulation and, carried by the blood-stream, are forced onward until arrested in some portion of the vascular system, owing to the disproportion between their size and the width of the vessel lumen. The mass which is thus transported and arrested is called an embolus.

[1] Putrid, gangrenous disintegration of thrombi in gangrenous processes is very similar.

Since the blood in the veins (with exception of the portal vein, in which in embolism the conditions are the same as in the arteries) always flows from smaller into larger vessels, embolism does not occur in the venous system; consequently, embolism is always an arterial or capillary phenomenon.

Bodies which are smaller than the lumen of the capillaries (*e.g.*, isolated bacteria) pass unhindered through these vessels with the blood-current. Therefore, all emboli are larger than the diameter of a capillary. On the other hand, the foreign body must be smaller than the largest vessels; otherwise transportation with the blood-current is impossible. The size of the emboli, therefore, is limited on both sides: it may vary between the diameter of the larger and that of the smallest vessels. The largest emboli are found in the lungs and in the large vascular trunks of the extremities; sometimes in the aorta.

Those foreign constituents which may give rise to embolism are the following:—

1. Blood-coagula. Since in embolism the question is one of a process in the vascular system of the living body, the blood-coagula are always produced by thrombosis. Coagula which have formed outside the body cannot accidentally, but only intentionally (*e.g.*, in animal experimentation), enter the circulation. All thrombi—venous as well as cardiac and arterial—may cause embolism, in that either the thrombi are dislodged *in toto* from the vessel wall or, what is by far more frequent, only certain portions are loosened, detached, and carried onward by the blood-current.

Thrombi of those veins in which the blood flows to the right heart, as well as those of the right heart itself, produce, in accordance with the direction of the circulation, embolism in the lungs[1]; thrombi of the left heart and of the arteries produce embolism in the region of the branches of the aorta. Thrombosis of the portal vein is not particularly rare, but it almost never produces embolism of the liver. Thrombosis of the pulmonary veins also is very seldom followed by embolism.

In general, thrombosis causes embolism only when, by one cause or another, portions of a thrombus (or a whole thrombus) are dislodged and carried onward by the blood-current. This may occur, on the one hand, as the result of internal cause, when the thrombus undergoes puriform softening or disintegrates by suppuration. In this regard the so-called progressive thrombi especially are dangerous, because they so

[1] Exceptions to this rule occur when an abnormally large foramen ovale is present in the heart; an embolus from the right auricle may then enter the left auricle and a detached fragment of a venous thrombus (*e.g.*, from the femoral vein) enter the branches of the aorta.

frequently grow from smaller veins into larger, while, at the same time, they undergo puriform softening on the inside. If the softening advances toward the surface, smaller or larger portions are readily torn off by the blood-current from the part projecting into the larger vessel. On the other hand, external mechanic insults often cause disintegration of thrombi. For example, forced, especially rapid, movement of the body; too energetic manipulation (palpation), a blow or incautious pressure, may dislodge a portion of a thrombus.

In some cases it can positively be determined that an embolus is derived from a discovered thrombus[1] by the fact that both thrombus and embolus present roughened, symmetric (fracture) surfaces agreeing in size and form, and corresponding also in color and consistency.

2. Constituents of the wall of the heart and of the vessels. In order for these (they are essentially portions of the endocardium or intima) to become detached from their surroundings, ulcerative processes, *e.g.*, ulceration of the valvular apparatus in malignant (ulcerative) endocarditis, atheromatous processes in arteriosclerosis with subsequent ulceration, etc., are necessary.

3. Tumor masses, which grow into the vessel lumen through the vessel wall. Here contact with the flowing blood occurs. If the tumors are of the soft, medullary type or have become markedly friable as the result of retrograde metamorphosis, small particles may very readily be dislodged by the blood-current. The tumor particles thus dislodged are usually too small to be recognized by the naked eye. Larger fragments are only rarely demonstrable. Von Recklinghausen is of the opinion that in transference of tumor particles (also of thrombi) a backward transportation, *i.e.*, in a direction opposite to the current of blood (see p. 94), may occur, for example, when pathologic causes produce a reversal of the blood-current. This takes place, for example, when the radicles remain open in complete occlusion of a vascular trunk.

4. Individual organ cells: for example, decidual cells are found in the pulmonary capillaries after parturition; liver-cells in the same location after injuries to the liver.

5. Fat. This fat always is derived from the body, *i.e.*, from cells containing fat: liver-cells, cells of adipose tissue, the yellow fat-marrow of the tubular bones. For the fat to be liberated, the cells themselves must be injured—crushed, disintegrated. This may occur in crushing of soft parts, wounds of all kinds, fractures, infections, eclampsia, heart lesions. Fat embolism is always most marked

[1] At the end directed toward the heart.

in the lungs (at the darker stained portions); it occurs also in the kidneys, brain, and heart; more rarely in other organs. The fat emboli are situated chiefly in the capillaries and, therefore, are demonstrable with certainty only by aid of the microscope. (See Fig. 15.)

6. Entozoa. In rare instances cysticercus (in the brain, *e.g.*, in the region of the large ganglia, they are quite rarely found within old, usually completely obliterated vessel walls); somewhat more frequently echinococcus (especially in suppurative disintegration of an echinococcous cyst).

7. Air. This sometimes enters the circulation (pneumathemia) in injuries of veins of the thorax (and coincident labored respiration); also in parturition through the open veins of the freshly emptied uterus. Small air-bubbles may be forced by the right heart

Fig. 15.—Fat embolism of a glomerulus after fracture of both femurs. From a fresh section. (Zeiss Apochr., 4; Comp. Ocul., 4. After *Langerhans*.)

into the branches of the pulmonary artery, and there cause occlusion. Air-bubbles which pass through the pulmonary capillaries may enter the left heart and be forced into the arteries, and there be arrested. If much air enters the vessels, it mixes in the right ventricle with the blood to form a foamy mass, and death quickly ensues by interruption of the circulation. When individuals working in compartments containing compressed air (as in caissons employed in building foundations for bridges and in construction of tunnels) pass suddenly from this high pressure to the pressure of the ordinary atmosphere, the marked decrease in pressure (decompression) may cause liberation within the blood of gases (oxygen, carbon dioxide) in the form of bubbles, which produce mechanic disturbances in the blood-channels (gas emboli). Air or gas may easily enter the vessels by anastasis during necropsy: for example, into the vessels of the meninges, etc., on making incisions into the heart; such occurs also by decomposition in beginning putrefaction.[1] One should, therefore, guard against errors.

[1] See *Bacillus aërogenes*, p. 520.

8. Foreign bodies accidentally or intentionally (experimentally) introduced, such as coal-dust, coloring matters, mercury, silver, etc.

The sequelæ of embolism vary according to the composition and size of the emboli; according to the vascular supply and the vital importance of the affected organ.

In certain cases of embolism of vital organs (heart, lungs, brain) a sufficient equalization of the disturbed circulation is impossible, and death occurs suddenly. Embolism of the left coronary artery is absolutely fatal; the left ventricle is at once paralyzed. The right ventricle continues to work for a short time and then ceases. Owing to the coincident arrest of the left ventricle and the still continued action of the right ventricle, considerable pulmonary edema develops. Occlusion of the right coronary artery is not followed by the same severe sequelæ. Large emboli of the pulmonary artery which occlude a large branch act fatally; here much depends upon the force of the right ventricle; if this is sufficient to break up the embolus, life may continue, because occlusion of smaller branches of the pulmonary artery does not cause death.

As regards the composition of the emboli, it is necessary to differentiate those which convey infectious material from those which possess no infectious properties. To the former—the infectious emboli—belong dislodged portions of thrombi which contain purulent or putrid masses, or microbes capable of producing suppurative or putrid processes; furthermore, coarse or fine particles of the endocardium dislodged by malignant (ulcerative) endocarditis, and tumor masses in so far as they possess infectious properties. In every instance transportation of the infectious material produces infection (so-called metastasis, *q.v.*) at the point where the embolus is arrested.

To noninfectious emboli belong all parts of bland thrombi which are transported and produce embolism, individual cells of organs, fat, and foreign bodies, such as pigments, carbon, mercury, and others mentioned under No. 8. All these noninfectious or, tersely, bland emboli produce essentially mechanic effects by reducing the size of, or occluding, the vessel lumen at the point where they are arrested.

Occlusion occurs in every instance in which the embolus is equal in size to the lumen of the vessel, *i.e.*, when it exactly fits a vessel. As the arteries in general divide dichotomously and the lumen of the branches remains unaltered in size from their point of origin to their division, obstructing, occluding emboli are found chiefly at, or just beyond, the point of bifurcation.

Narrowing of the vessel lumen by embolism occurs when a somewhat elongated embolus is arrested in a transverse direction or, what is more frequent, an embolus lodges at the point of bifurcation of an artery, and, technically expressed, "rides" upon this point. Riding emboli are always smaller (they may be longer, but not thicker) than the vessel lumen in front of the point of bifurcation; consequently, the branches are usually not completely occluded. If one branch is completely obstructed by a riding embolus, the lumen of the other is usually only narrowed. (Fig. 16.)

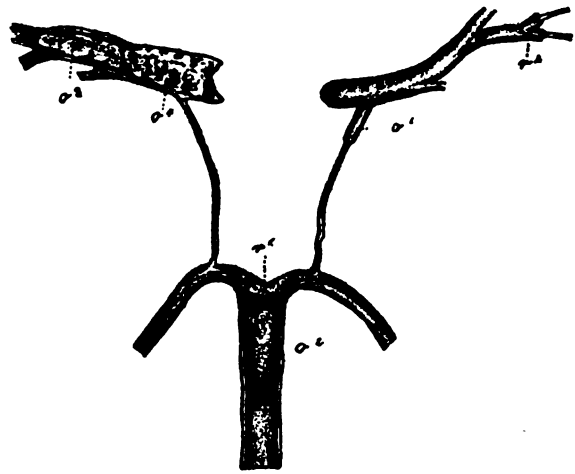

Fig. 16.—Multiple embolism of the arteries at the base of the brain. r^1, riding embolus at the point of bifurcation of the basilar artery into both art. profundæ cerebri; r^2, riding embolus at the point of bifurcation of a branch of the art. fossæ Sylvii sinistræ; o^1, occluding embolus of the art. communicans post. sinistra; o^2, narrowing thrombus supported by the riding embolus r^1; o^3, embolism of the art. fossæ Sylvii dextræ held fast at the point of origin of a branch; o^4, occluding embolus behind o^3, compressed and therefore folded. Natural size. Art. basil. and art. fossæ Sylvii dextræ are cut open. (After *Langerhans*.)

This mechanic effect is exerted by all larger infectious emboli, in addition to their infectious properties; in very small emboli, on the other hand, it is absent.

The immediate results are local anemia, or ischemia, and collateral hyperemia. In complete occlusion stasis of the blood beyond the embolus occurs, because the differences in pressure suddenly cease. Besides, the arteries usually contract and empty themselves. If the vessel lumen is only narrowed (with regard only to arteries), the blood-pressure in the branches in front of the obstruction

is increased (hence, here collateral hyperemia develops), while beyond the embolus it is diminished (owing to the obstruction). The latter area receives less blood, *i.e.*, is more or less anemic.

The further results depend upon the size of the embolus and the vascular supply of the organ. The smallest emboli produce capillary embolism; they produce no local phenomena, because the capillaries everywhere possess numerous anastomoses; the occluded capillaries are simply shut off from the circulation. Under certain circumstances, however, capillary embolism may lead to serious consequences—to functional and nutritive disturbances—namely, when a sufficient number of capillaries to affect a considerable or large portion of the total diameter of a vascular area are occluded at the same

Fig. 17.—Schema of vascular branches with anastomoses. (After *Smaus.*)

time. This may occur, for example, in fat embolism of the lungs, and then has about the same effect as when larger branches of the pulmonary arteries are occluded; since in both instances too large a portion of the respiratory surface is rendered functionless and, therefore, the function of the lungs is entirely interrupted; in consequence of this, death occurs under phenomena of suffocation.

In other cases a locally somewhat circumscribed, but large number of neighboring capillaries may be occluded by shattering of a friable thrombus at the point of bifurcation of an artery and entrance of the smaller fragments into the capillary area. Here, also, local (functional or nutritive) disturbances of the tissues are the result of the circulatory disturbances.

In occlusion of arteries very much depends upon whether anastomoses are present beyond the occluded point or not. Numerous anastomoses, such as exist in the thyroid, the tongue, etc., render possible an equalization of the circulatory disturbance, so that only a short portion of an artery is shut off from the circulation (*e.g.*, at the base of the brain in front of or within the circle of Willis). For example, if

an arterial branch is occluded by an embolus, the flow of blood into the area supplied by its branches ceases. Collateral hyperemia develops in the adjacent vessels, and if abundant anastomoses exist between the various vascular branches, at least the capillaries (see Fig. 17), the blood flows from the side into the occluded area, the primary anemia is followed by hyperemia, which gradually is replaced by equalization of the circulation. If, however, anastomoses are scanty or absent, *i.e.*, if the arteries are so-called terminal (end) arteries (see Fig. 18) in the sense of Cohnheim (*e.g.*, beyond the circle of Willis), occlusion of an artery by an embolus causes sudden interruption of nutrition in the capillary area belonging to it, and therewith also sudden abolition of function. When an embolus only narrows the lumen of such a ter-

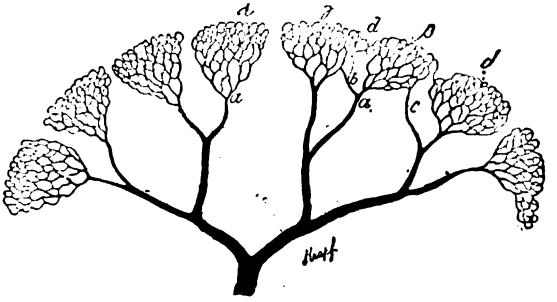

Fig. 18.—Schema of arteries with few anastomoses; so-called end-arteries.

minal artery, *i.e.*, does not completely occlude it, a corresponding, more or less marked interference of nutrition and function results.

Even when a sufficient number of anastomoses are present, nutritive and functional disturbances may occur if several adjacent arteries are simultaneously or successively occluded.

According to Cohnheim, the lungs, brain, kidneys, spleen, and retina belong to those organs which are provided with terminal arteries. In the so-called terminal arteries there is, first, stasis of the blood-current behind the occluded point; the blood-pressure in the capillaries sinks to zero, blood flows in from the collaterals, and, if the blood-current in the veins is preserved by aid of the usually very numerous venous anastomoses, a reversed flow probably occurs also from the veins to the capillaries, because the pressure in the latter is less than in the veins.[1] The capillaries and the smaller veins thus become turgid with blood; from these such an active diapedesis[2] takes place as a result of inter-

[1] This view is denied by some authorities, who hold that the blood is conveyed by the capillaries from collaterals.

[2] Compare Hemorrhage, p. 56.

ruption of the circulation that the whole region belonging to the occluded vessel appears engorged with blood: infarcted.[1] According to Virchow, this infarction is accompanied by phenomena of inflammation: hemorrhagic inflammation.

Arteries possessing so few anastomoses that they do not under certain circumstances convey sufficient blood for nutrition are called terminal arteries (Cohnheim). To such belong the arteries of the brain, liver, spleen, and kidneys. In other organs abundant anastomoses are present which, however, under certain conditions, may likewise be insufficient, as in the lungs, heart, and gastrointestinal canal. They are called "functional terminal arteries." In organs provided with arteries possessing very abundant anastomoses, especially such as are supplied by two or more large trunks, infarcts are very rare. The foci of softening in the brain are always anemic; while small capillary apoplexies often occur at their margins, typical hemorrhagic infarcts are very rare. Infarcts of the kidney also are usually anemic and generally hemorrhagic only when they occur in localities where a capsular artery enters the renal tissue, because this then furnishes a strong collateral supply of blood. White infarcts occur also in the retina after occlusion of the central artery of the retina. In the stomach and intestinal canal, where abundant anastomoses of the small branches are present, the foci are usually hemorrhagic. For the same reason, embolic infarction, as a rule, develops in the stomach and intestines only on occlusion of the chief arterial trunks. In the spleen sometimes hemorrhagic, sometimes anemic, infarcts occur. In the lungs, where the pulmonary arteries possess capillary anastomoses not only with the branches of the bronchial and pleural arteries, but also communicate freely with each other by extraordinarily abundant and wide capillary anastomoses, infarction scarcely ever occurs under normal conditions. Such occurs almost only in lungs in which the tissues are altered by chronic congestion, whereby the congestion in the veins aids in retarding the outflow of the blood from the infarcted area, and the capillaries are disposed to hemorrhage. Infarct is rare in the liver.

As the vessels generally branch dendriticly, the region of an hemorrhagic infarct has a pyramidal form—on incision a wedge-shaped form—the apex of which is always directed toward the hilus of the organ. Within the infarct all movement of the blood ceases, and, consequently, nutrition also is arrested; the affected tissue area (kidney, spleen, intestine, lung) dies.

---

[1] Infarct: from *infarcire:* to stuff.

In the brain the dead part is softened (cerebral softening, *encephalomalacia*); it disintegrates and is variously colored: whitish or reddened by blood, brownish, yellowish, or yellowish white from fatty degeneration. In the extremities the part rendered necrotic by embolism becomes gangrenous; gangrene of the toes is observed with especial frequency after embolism of the popliteal artery. In the spleen, kidney, heart muscle the necrotic part may remain anemic (anemic necrosis, white infarct); on section it is yellowish gray, dry, and of firm consistency, which is explained, on the one hand, by abstraction of water, and, on the other, by coagulation processes within the dead tissues (coagulation necrosis: necrosis plus subsequent coagulation). If the necrotic focus is wedge-shaped, it is called fibrin wedge, owing to the resemblance of the dry, yellow-gray cut surface to coagulated fibrin.

At first every hemorrhagic infarct is blackish red in color, very dense and firm in consistency, and on incision has a quite uniform, smooth, somewhat dry surface. Later, decoloration gradually occurs by solution of the red blood-corpuscles; the infarct becomes paler, assumes a yellowish color (so-called fibrin wedge, anemic or white infarct), and contracts more and more, partial organization taking place from the periphery as a result of a reactive inflammation, so that, finally, a very much smaller cicatrix, which sometimes is pigmented and retracted on the surface, occupies the site of the hemorrhagic infarct.

The name "anemic infarct" is applied to primarily pale anemic foci as well as to those which originally were rich in blood and later became bloodless. Very many conditions are designated as "infarct," and the true meaning of the word is not always considered. There are hemorrhagic and anemic-necrotic infarcts; concrement infarcts (occlusion of tubuli with concrements, *e.g.*, in the kidney tubules in uric acid infarct); placental infarcts (necrotic foci in the placenta; embolism does not exist. The name "infarct" has been chosen because of macroscopic resemblance to infarct and the coexistent necrosis). The so-called splenic infarcts observed in leukemia are not due to embolism. Here are present yellow-gray foci which resemble genuine, *i.e.*, embolic anemic infarcts. Uterine infarct is not due to embolism, nor is necrosis present; uterus infarct signifies chronic fibrous metritis. Pulmonary hemorrhagic infarct is accompanied by hemoptoë and therefore is called also hemoptoëic pulmonary infarct.

Hemorrhagic infarction is usually most markedly developed in the lungs and spleen; in the brain (here rarely red, more frequently anemic, yellow softening in embolism) and kidneys[1] it is inconstant. The opinions why infarction is not the invariable result are greatly at variance; experimental observations (Litten) speak in favor of the view that

[1] Large renal infarcts always have a large yellow center, which is anemic and in a state of fatty metamorphosis, and a comparatively small periphery, which is hemorrhagicly infarcted. The fatty metamorphosis in the yellow, anemic parts begins as early as two hours after (experimental) occlusion of the renal artery. In experimental cerebral embolism also fat may be seen to occur in the neuroglia cells, even after two hours.

hemorrhagic infarction occurs only in localities where anastomoses, although present, are insufficient for the establishment of complete collateral circulation. More recent experimental investigations have shown that in the lungs also occlusion of a vessel does not suffice to produce infarction. Infarction occurred only when embolism was produced at two points behind each other in one vascular area.

In embolism of the large vascular trunks of the extremities, stasis, terminating in gangrene and mummification, occurs because there are insufficient anastomoses for the large trunks. Embolism of the large mesenteric arteries likewise causes stasis; this is invariably followed by intense free hemorrhage by diapedesis; when death occurs, no signs of gangrene are found. When infarction does not take place, the greater part of the tissues (in the brain, the neuroglia cells; in the kidneys and the heart, the parenchyma and stroma) die by necrobiosis, as the result of retrograde fatty metamorphosis.

As regards the size of the emboli, it is further to be noted that, as a rule, the sequelæ are the more unfavorable the larger the emboli, *i.e.*, the larger the occluded arteries (so far as they do not possess sufficient anastomoses). Occlusion of the principal vessels of the organs may suddenly render the latter functionless, while occlusion of smaller branches renders functionless only a portion of the organ corresponding to the size of the vessel. For example, embolism of the central artery of the retina produces amaurosis; embolism of smaller branches, corresponding visual defects; embolism of the large arterial trunks of the lungs, pulmonary apoplexy (death under signs of asphyxia); embolism of smaller pulmonary arteries also produces pulmonary apoplexy if many branches are occluded simultaneously; otherwise, corresponding hemorrhagic infarction with bloody expectoration and temporary embarrassment of respiration.

The functional disturbances also are of very variable significance according to the vital importance of the organs. In paired organs (aside from the organs of sense) embolism of one organ is usually compensated by increased function of the other, without the individual in question necessarily experiencing any marked suffering. In all remaining organs the results are generally the more severe the less the function of the organs or individual parts of them, in so far as the preservation of life is concerned, can be dispensed with. Consequently, embolism of the so-called vital organs (brain, heart, lungs) frequently causes death (suddenly in embolism of the principal vessels: cerebral apoplexy, cardiac apoplexy, pulmonary apoplexy), or very severe functional disturbances (paralyses, pareses, aphasia, etc.), while embolism of the central artery of the retina causes blindness; embolism of the

femoral artery, paralysis or paresis of the leg with subsequent gangrene; embolism of the splenic arteries, infarction of the spleen, whereby in no instance is the continuance of life directly endangered.

Numerous observations have shown that arterial embolism at the point where the embolus is arrested may result in the formation of an aneurism. As, however, the development of aneurism in connection with embolism is observed only in isolated cases, *i.e.*, this change is not a constant phenomenon, further investigations must decide under what conditions aneurism develops after embolism.

As has already been stated, infectious emboli induce metastatic affections (metastatic abscesses, tumor metastases, etc.). Bland, non-infectious emboli also produce, aside from nutritive and functional disturbances of organs, local alterations of the vessel walls, which are due essentially to the fact that the embolus, like a foreign body, stimulates the adjacent vessel wall, exciting in it a progressive formative proliferation which secondarily penetrates into the embolus, at first producing a readily separable adhesion between the wall and the embolus, later leading to firm union, and, finally, ending in complete organization of the embolus.

On the other hand, an embolus may be subjected to the same retrograde changes as a thrombus (*q.v.*). Also, secondary thrombosis may develop in connection with an embolus, in that, as in a continuous thrombus, new coagula are deposited upon the embolus from the circulating blood.

The symptoms of embolism of external visible parts (extremities) consist, during life, at first of cadaveric paleness, coldness, and functional disturbances of the muscles (paralysis or paresis) and of the nerves (anesthesia); in embolism of internal parts only functional disturbances are perceptible.

In sudden occurrence of death the phenomena in the cadaver are so slight that they readily may be overlooked; for, as a rule, only the embolus which occluded the vessel is found, and no secondary phenomena (occasionally there is distinct anemia in the brain). Usually, secondary manifestations are observable only when life has continued for some time after arrest of the embolus. Then the changes are those previously described, according to the duration of life, the size and composition of the embolus, and the vascular supply of the affected parts.

METASTASIS.

By **metastasis** was formerly understood the transfer of a disease in the sense of transfer of office. It was assumed that the disease changed its location, abandoned its old site, and appeared in a new place. At present, by metastasis is understood the appearance of any substance at a point distantly remote from its original location, without the substance from which it was derived necessarily disappearing from the original site. The process is always one of transportation of substances from one locality to another. Wherever these substances are arrested, they cause various effects according to their chemic and physic properties. The routes through which the transport chiefly takes place are the channels of the circulating fluids, namely, the blood- and lymphatic vessels.

Different groups of metastases are generally differentiated:—

1. **Embolic metastases,** namely, arterial and capillary.

If the emboli are sufficiently large to be recognized by the naked eye, the seat of metastasis is always the arterial area or the ramifications of the portal vein. The emboli may consist of dislodged fragments of thrombi (especially infectious), tissue detritus (*e.g.,* in malignant ulcerative endocarditis), fragments of tumors (which, for example, have grown into the lumen of veins and been detached by the blood-current), and of foreign bodies, especially entozoa (*Schistosomum hæmatobium,* echinococcus, perhaps also cysticercus and others).

In capillary embolism the emboli are either very small, macroscopicly invisible particles, *e.g.,* single cells, pigment clumps (pulmonary carbon, which frequently is transported to the spleen and liver in pleuritic adhesions and alveolar pulmonary emphysema), disintegration products, liquid substances, or gases which do not mix with the blood: oil and air.

2. The second group includes firm particles which are smaller than capillaries, *i.e.,* too small to produce embolic processes. These are principally infectious agents: vegetable micro-organisms and protozoa (the latter produce, *e.g.,* in dysentery, metastatic abscesses of the liver); further, tumor-cells (which, *e.g.,* are arrested in the liver and lymphatic glands) and pigments (in tattooing: in lymph-glands, after they have passed the lymphatic capillaries).

Swelling of the lymphatic apparatus in infectious diseases, especially spleen tumor, belongs here. The spleen (and similarly the lymph-glands) forms a filter even for such bodies which easily pass the capillaries and, therefore, retains infectious germs. These, then, manifest their effects in the spleen (or the lymphatic glands).

There is no doubt that the innermost cellular layer of the vessels—the so-called endothelium—often plays an important rôle here; especially in metastases caused by micro-organisms—*e.g.*, in acute miliary tuberculosis—arrest of the bacteria circulating in the blood appears to take place through the cells.

3. To the third group belong substances which circulate dissolved in the blood until they are deposited in a solid form at certain points of predilection. The best-known example is icterus. The bile-coloring matter is transported to other portions of the body by aid of the circulating blood, and there (in the intima of the vessels, in the conjunctiva, skin, kidneys, etc.) deposited as diffuse, rarely as crystalline, bile-pigment; the nerves and cartilages generally do not take up bile-coloring matter even in marked degrees of general icterus.

Lime metastases originate frequently during absorption of large bone masses (lime-salts) and coincident disturbance of excretion through disturbance of renal function. Points of predilection for lime deposits are the kidneys (in almost every cadaver, lime is found in this locality), indurations, thrombi, old adhesions; in rarer instances in the lungs, stomach, dead feti (*lithopædion*), lymphatic glands.

Silver metastases, which produce an irreparable dark coloration of the external skin (*argyria*), are the result of long-continued therapeutic use of silver-salts. The silver is deposited in the form of finely granular, black silver compounds in the connective-tissue spaces of the various organs: in the intima of the large vessels, in the adventitia of the small arteries, in the papillary layer of the skin, in the *stratum mucosum* of the epidermis, in the intestinal villi and sweat-glands, and in the cortex of the kidney, especially in the *tunica propria* of the renal tubuli and the walls of the glomerular capillaries. The black granules are soluble in potassium cyanide, and, therefore, cannot be reduced silver. Perhaps they are transformation products of a silver albuminate. The mode of the process, in which the silver deposits are never observed in the tissue-cells, is still obscure.

In **gout** acid sodium urate is deposited from the blood in crystalline form in the kidneys and various poorly vascularized parts of the body (*e.g.*, cartilage, ligaments, tendons, tendon-sheaths, and in rare instances in the synovialis). (See Autointoxication.)

It is not always possible accurately to determine the route of metastasis formation. This is true especially in many tumor metastases which do not correspond to the direction of the current of either the blood- or lymph- stream. Von Recklinghausen has shown that the transport may take place also in a direction opposite (centrifugal) to the blood- or lymph- current: under certain conditions this is favored

by circulatory disturbances (*e.g.*, congestion with slowing of the current); further, by reversal of the current (*e.g.*, in thrombosis, in occlusion of lymph-channels by tumors), and, finally, by the gravity of the transported substances themselves, in that these, following their own gravity and without regard to the current, fall backward within the sluggish marginal zone: retrograde transport.

A peculiar mode of metastasis not infrequently is observed in the serous membranes. For example, in gastric carcinoma innumerable small metastases sometimes occur in the peritoneum, just as if seed had been strewn over the whole surface (as in sowing). Owing to this similarity, this form of metastasis is designated as dissemination. As the metastases are most numerous in the more deeply situated parts and in folds, *i.e.*, at points where particles most readily can be retained, it is assumed that dissemination depends upon dispersion of tumor-cells.

HYDROPS, OR DROPSY.

Dropsy, or **hydrops,** is the local accumulation of watery liquids separated from the circulating fluids. In a restricted sense, hydrops is accumulation of fluid in pre-existing cavities (*e.g.*, hydrothorax, hydropericardium, etc.); infiltrating hydrops, *i.e.*, uniform distention of the tissue spaces with fluid, is designated as **edema.** Formerly the term dropsy was employed in a broader sense than is now customary, and by it was understood any accumulation of watery fluids regardless of how the accumulation took place. Consequently, many conditions are still designated as dropsies which, strictly speaking, must be excluded from true dropsy. For example, the designation: *hydrops cysticus felleæ, hydrops processsus vermiformis, hydrosalpinx, hydronephrosis, hydrops renum, hydrops uteri, hydrops cysticus multilocularis ovarii* are everywhere encountered. As in all these instances the condition is not a true hydrops, *i.e.*, transudation of watery liquid as such from the circulating fluids, and as the terms have become so firmly established, these so-called hydropsies are designated as *hydropes spurii,* in contradistinction to *hydrops verus* or dropsy in a strict sense.

In every true hydrops, therefore, the watery liquid is transuded as such from the circulating fluids. The locality of transudation is the capillary area. The transudate occurs either in the tissues or in the cavities of the body. In the first instance the process is an hydropsic infiltration; in the second it is a free effusion upon the free surface, *i.e.*, a so-called free hydrops.

More or less all soft, distensible tissues (not bone, cartilage, teeth) may be involved in hydropsic infiltration, but usually the loose (areolar) connective tissue is first affected; next the adipose tissue, the musculature, the brain, the liver, etc. The affected tissues become swollen: edema (οἰδαω = to swell), hydrops, anasarca (ἀνά = through, and σάρξ = flesh) is produced.

There are especial designations for free hydrops according to the place of occurrence: hydrothorax = dropsy of the chest (in the pleural cavities); hydropericardium = dropsy of the heart sac; ascites (ασκίτης) = abdominal dropsy; hydrocele (ὑδροκήλη) = dropsy of the scrotum; hydrocephalus (κεφαλή) = dropsy of the head, water on the brain; hydrarthros (ἄρθρον = joint) = dropsy of the joints; hydrophthalmus = dropsy of the eye.

The watery effusion upon the free surface of the lungs, *i.e.*, into the air-containing pulmonary alveoli, is designated as pulmonary edema, because in this case the process is not an accumulation within a closed cavity.

The effused watery fluid does not always have the same composition. Therefore, three forms are differentiated:—

1. *Hydrops aquosus* (most resembles water).
2. *Hydrops lymphaticus* (because of its resemblance to lymph).
3. *Hydrops chylosus* (has the appearance of chyle; originates as a result of obstruction or laceration of the thoracic duct, or of thrombosis of the subclavian vein, into which the thoracic duct empties).

All three are distinguished by their chemic composition and mode of origin.

The freshly discharged fluid of *hydrops aquosus* and of *hydrops lymphaticus* has the appearance of clear water; the fluid of *hydrops chylosus* has the appearance of chyle or of very dilute milk; hence, the designation *hydrops lacteus.* This is due to the presence of a great amount of fat in minutest subdivision (emulsion). *Hydrops aquosus* and *lymphaticus* differ in so far as the former is not altered on standing (after evacuation) and on contact with the air; *hydrops lymphaticus,* on the other hand, like lymph, separates soft, transparent, gelatinoid coagula which consist of fibrinogen substance. In other words, the coagulable fibrinogen substance is lacking in *hydrops aquosus.*

The constituents of hydropsic fluids[1] are:—

[1] The *liquor sanguinis* (blood-plasma) consists of:—
Fibrin (which coagulates),
Serum { Water, Serum-albumin, Salts, and Extractive matters.
With intact vessel wall there may escape and form effusions:—

1. Water.

2. Albumin: pure albumin or sodium albuminate, up to about 30 per cent. of the albumin content of the blood-serum.[2]

3. Extractive substances: coloring matters, urates, etc.

4. Fats: accidental admixtures which frequently do not originate until a later stage, after long standing by fatty metamorphosis of cells (epithelia, indifferent round cells) as fluid or firm fat, often as disintegration products of the same (cholesterin).

5. Salts: sodium and potassium salts, especially sodium chloride; lime and magnesia salts; the latter are dependent upon the albumin content; phosphates, sulphates, and carbonates.

6. Fibrin ferment and fibrinogen substance: it forms soft, gelatinoid, transparent coagula.

On comparing the constituents of hydropsies with the liquor sanguinis, it is at once noted that hydropsic fluid lacks fibrin, *i.e.*, that hydrops and liquor sanguinis are not identic. In general, the constituents of hydropsic fluids correspond more to the blood-serum (*liquor sanguinis* minus fibrin); they are not, however, identic with the blood-serum, for in every hydrops the water content is greater, the albumin content considerably less, than the blood-serum. Therefore, it is incorrect to designate hydropsic fluid simply as serum or serous fluid. In hydrops serum does not pass through the capillary walls, but a fluid which resembles serum only as regards its salt content. Hence, in hydrops the process is not simply mechanic—a simple filtration—for otherwise the transuded fluid would correspond in composition to that of the *liquor sanguinis*. Apparently, in the passage of hydropsic fluid through the living cell layer (capillary wall) the latter and its relation to the circulating blood—the molecular attraction between the blood and the vessel wall—play an important rôle, the vessel wall permitting only certain parts (the dissolved substances) to transude and retaining others (fibrin, etc.).

---

1. Water + salts = pure watery transudate.
2. Water + salts + serum-albumin = watery transudate: not serous, because only a part of the serum-albumin escapes.
3. Water + salts + serum-albumin + fibrinogen substance (coagulates only on contact with the air) = lymphatic exudate (*hydrops lymphaticus*).
4. Water + salts + serum-albumin + fibrin (coagulates) = fibrinous exudate.
5. Red blood-corpuscles = hemorrhagic product (extravasate).
6. Colorless blood-corpuscles which migrate independently, but are not mechanically forced out (emigration).

1 and 2 form the constituents of the ordinary dropsies.

3 to 6 are exuded in inflammatory processes.

[2] While the blood-plasma contains about 8 to 10 per cent. albumin, transudates seldom contain more than 0.5 to 2.0 per cent. In hydremic states the transudate is poorer in albumin.

The differentiation of serous exudate from congestion transudate, *i.e.*, serous pleuritis from hydrothorax, serous peritonitis from ascites, etc., may be very difficult, since both processes merge into each other, and serous inflammatory effusions may develop from transudates. Clouding of the fluids and admixture of fine flocculi and colloid coagula by no means demonstrate or prove, particularly in cadaveric material, the inflammatory nature of the effusion; because the clouding may be caused by post-mortem dislodgment or even *intra vitam* desquamation of cells from serous coverings. Fibrin coagula also form in transudates. In doubtful cases decisive points are: 1. The state of the affected serous membrane: fine cloudings, marked injection of the capillaries speak in favor of inflammation. 2. Microscopic examination: in presence of a large number of leucocytes a serous inflammation may always be considered.

Among free hydropsies hydrocele fluid contains the greatest amount of fibrinogen substance.

Hydrocephalic fluid contains only a small amount of albumin; its salt content is nearer that of the blood-corpuscles than that of the serum.

Ascitic and edema fluids of the arachnoid contain little albumin;[1] their ratio of potassium to sodium nearly equals that of blood-serum (2.8:40.0).

The cause of hydrops, *i.e.*, of the transudation of the watery fluid, is increase of blood-pressure—augmentation of the lateral pressure up to a certain degree. This increased pressure adapts the capillary wall for the transudation of watery fluids.

Increase of blood-pressure occurs in:—

1. Hyperemia, especially when this affects parts the vessels of which are in a state of mild nutritive disturbance, or when heart weakness coexists (thus, collateral hyperemia of the lungs in pneumonia and in beginning cardiac weakness produces pulmonary edema).

2. Passive congestion. This produces hydrops only from a certain degree of lateral pressure onward. In general passive congestion (from valvular lesions, pulmonary emphysema, hepatic cirrhosis, etc.) general hydrops also develops; in local congestion (from ligature, thrombosis, tumors, pregnancy, large exudates, etc.) corresponding local hydrops develops.

The increase of blood-pressure may be comparatively slight and still produce hydrops, if hydremia coexists (*e.g.*, in albuminuria through loss of albumin [hypalbuminosis of the blood], and in marasmus

---

[1] The following table from Halliburton, after Gorup-Besanez, shows the percentage of proteids in the liquids of the body:—

Cerebrospinal fluid	0.09	Pancreatic juice	3.33
Aqueous humor	0.14	Synovia	3.91
Liquor amnii	0.70	Milk	3.94
Intestinal juice	0.95	Chyle	4.09
Pericardial fluid	2.36	Blood	8.56
Lymph	2.46		

from tuberculosis, carcinoma, bone suppuration, hemorrhages [in marantic hydremia]). Hydremia alone does not produce dropsy; the hydremic state of the blood, however, increases filtration of the watery constituents or the disposition thereto as a result of altered molecular attraction between the blood and vessel wall. Hence, in hydremic subjects a slight increase of blood-pressure suffices to produce dropsy (cachectic hydrops). When, as is so frequent in hydremic individuals, this dropsy quickly disappears, the process is designated as *œdema fugax.*

In the sick, convalescents, and chlorotics (with cardiac weakness), long standing, like hydremia, favors the development of *hydrops gravitativus* in consequence of hypostatic congestion.

Hydrops is sometimes observed in paralyzed limbs, owing to variations of blood-pressure: so-called *hydrops paralyticus.*

The observation that edema frequently disappears after a time teaches that there must be means and routes by which the transuded hydropsic fluid can be removed. These routes are the lymph-channels. The latter possess regulatory properties in so far as they carry off the transuded watery fluids, and by augmented and at the same time increased rapidity of flow in the lymph-vessels prevent—in unobstructed outflow—the occurrence of true dropsy. So long, therefore, as there is no disproportion between transudation from the capillaries and absorption through the lymph-vessels, true hydrops does not develop. As soon, however, as the watery transudation in proportion to the capacity of the lymph-vessels is too great, all the fluid is not removed; a part remains *in loco,* accumulates with time, and dropsy becomes manifest.

In more marked hydrops all participating lymph-vessels become larger and wider; as a result of the increased pressure under which the transuded fluid incessantly flows into the lymph-channels, permanent ectasis develops. The latter is associated with relaxation of the wall, diminution of elasticity, and loss of motive force. The corresponding lymph-glands (*e.g.,* inguinal, iliac, lumbar in edema of the lower extremities) also gradually become larger.

Lymphatic hydrops owes its content of fibrinogen substance probably to active participation of those cells located in the region of the radicles of the involved lymph-vessels. This active participation often develops insidiously, but sometimes it is accompanied by inflammatory phenomena, such as hyperemic redness, pain, heat, mild fever, and greater firmness and hardness of the affected parts. This is the case, for example, in *phlegmasia*[1] *alba dolens,* that painful edema which develops

[1] φλέγμα, mucus.

so frequently in the puerperium in thrombosis of the femoral vein. Owing to these more or less distinct inflammatory phenomena, lymphatic hydrops has been designated also as *hydrops calidus seu inflammatorius*, and, in contradistinction thereto, *hydrops aquosus* is named *hydrops frigidus*.

Lymphatic hydrothorax begins with inflammatory phenomena of the pleura; lymphatic hydrocele and lymphatic hydarthros begin with inflammatory phenomena of the *tunica vaginalis* and *synovialis*, respectively.

Lymphatic edema is associated with inflammatory, painful swelling of the lymph-glands, sometimes with inflammation of the lymph-vessels. From lymphatic edema there are quite imperceptible transitions to erysipelas. Likewise, edema of the glottis is a lymphatic edema which, in its advent and course, very strongly resembles erysipelas; hence, it is named also *laryngitis erysipelatodes*. In this condition an acute inflammatory, hydropsic tumefaction of the aryepiglottic ligament, the epiglottis, and of the upper, so-called false, vocal cords is observed. The true vocal cords, owing to their tense and hard consistency, are but slightly, or not at all, involved.

The differences betwen true erysipelas and lymphatic edema are, that the latter is always a deep-extending process which is local and stationary, generally manifests no disposition to form vesicles, progresses with slight elevation of temperature, and causes only moderate general disturbance.

Both forms—*hydrops lymphaticus* and *hydrops aquosus*—may be acute or chronic. The chronic form is, in general, the more unfavorable from a prognostic standpoint, because severe local or general disturbances usually coexist. The acute form more frequently corresponds to *hydrops calidus*.

The symptoms of free hydrops consist, first, in distention of the body cavities by local accumulation of fluid. The distention causes more or less tense fullness and tension. The parts first and most markedly compressed and distended are those which are softest and least resistant: for example, in ascites, the anterior abdominal wall. The more rapidly the fluid is effused and the more it accumulates locally, the greater the tension of the walls and the harder the hydropsic part on palpation (a hydrocele often is very tense, firm, even hard in consistency). When the tension is less, fluctuation and undulation may be elicited on percussion. The movement caused by percussion is transmitted throughout the whole hydrops like a wave movement. Sometimes several successive wave movements are distinctly perceptible

Changes in position of the organs (heart, lungs, intestines, etc.) contained in the hydropsic sac frequently occur, the movable, soft, and yielding parts being greatly pulled upon, dislocated, and compressed. In ascites the diaphragm is pushed upward and the intestines float upon the water. In hydrothorax the lungs at first retract, owing to their great elasticity; in marked effusion, however, compression of the lungs floating upon the water finally takes place, and they become atelectatic (compression-atelectasis is associated with anemia, because the vessels also are compressed).

Traction and compression are generally followed by functional disturbances, and, after a time, also by nutritive disturbances—atrophy—which, under certain conditions, may advance so far as finally to cause almost complete disappearance of the organs. Thus, the brain atrophies in chronic internal hydrocephalus; the lungs in severe hydrothorax; in chronic ascites, the liver, omentum, and even the anterior abdominal wall, all layers of the latter becoming thin, flabby, and wrinkled. Hydrophthalmos produces atrophic thinning of the sclera and cornea, and under certain conditions hydrocele causes even complete disappearance of the testis.

Hydropsic infiltration also, at first, produces swelling—an increase in volume—by accumulation of watery fluid. The swelling can be displaced by pressure, the fluid generally being quite readily pressed aside. Hence, pressure with the finger produces the characteristic "pit" or "dimple"—a flat indentation which remains for a short time after removal of the finger, and then gradually disappears.

Edematous parts have a translucent, puffy appearance, doughy consistency, and are anemic as the result of pressure upon the vessels. In more marked edema of long duration, atrophy of the adipose tissue occurs, large cavities and fissures filled with fluid forming within the connective tissue. When the connective-tissue parts are thus greatly pushed apart, whereby small hemorrhages are not infrequent, longer or shorter lines—the well-known *striæ cutaneæ*[1]—develop in the skin as the result of separation of continuity.

The lumen of canals (*e.g.*, of the *aditus pharyngis ad laryngem*, the *rima glottidis*) may be so narrowed as the result of more or less intense hydropsic swelling that obstruction, a sort of closure (*e.g.*, by edema of the glottis), occurs.

Tactile disturbances sometimes occur in hydropsies as a result of the tension and pressure, especially in hydropsies accompanied by

[1] These do not differ from the striæ observed upon the abdomen as the result of pregnancy.

inflammatory irritation, as, for example, in *phlegmasia alba dolens;* less often in other cases; for example, in ordinary circummalleolar edema, in which there is almost no subjective sensation.

Ascites is usually associated with disturbances of assimilation of food, in that the movements of the gastrointestinal canal are interfered with and restricted by the pressure of the water, and congestion in the portal vein area and a disturbance in the secretion of the digestive juices coexist.

Lymphatic hydrops is distinguished from simple watery (congestive and cachectic) hydrops by its marked hardness: *œdema durum, sclerema* (e.g., *neonatorum*).

The watery fluid of hydrops is incapable of organization; hence, hydrops in its further progress can undergo only chemic changes. These consist in putrid softening or inspissation.

Putrid softening occurs only when inflammatory processes supervene as the result of entrance of air or infectious germs (at points of puncture, scarification, etc.). As a rule, an erysipelatous state develops, which goes on to suppuration and finally to gangrenous disintegration, because the tissues are in a state of marked nutritive disturbance, and, consequently, incapable of exerting sufficient reactive resistance. Gangrene in hydropsic parts is always the so-called white gangrene, which is distinguished from ordinary (black) gangrene not only by its color (anemia), but also by the fact that it is usually painless. White gangrene is observed principally in the scrotum, upon the labia and the extremities, while ordinary black gangrene attacks chiefly points subjected to pressure (*decubitus*).

In **inspissation** the watery constituents are absorbed, and firm parts, such as cells, extravasates, and exudates, are secreted from the vicinity. The fluid may be clouded and variously colored by these secretions. To these are added, by concentration of the fluids, crystals, and by retrograde metamorphosis of the cellular parts, fat-droplets and cholesterin. Inspissation is always associated with increase, condensation, and induration of the connective tissue, especially in inflammatory hydrops, so that sclerema, induration, true sclerosis develops from œdema durum. These parts are white and tendinous on section, very compact and dense in structure, very firm and hard in consistency, and are cut with difficulty. The surface is uneven (certain parts proliferating, others contracting cicatricially), roughened, puckered, nodular, and fissured. The more frequent the antecedent inflammatory disturbances, the greater, as a rule, is the enlargement, until, finally, marked deformities develop; which have been designated

as elephantiasis. The periosteum is always involved, in that it proliferates and produces hyperostoses and exostoses.

On the other hand, hydropsies may disappear by rapid or slow removal of the watery fluid (by evaporation, more frequently by absorption); the edema of inflamed parts may disappear, for example, by elevation and rest until subsidence of the inflammation; the edema of *phlegmasia alba dolens* by development of collateral channels, etc.

In other cases death results from dropsy, especially in disturbance or interruption of the function of the vital organs by the dropsy, *e.g.*, by hydrocephalus, cerebral edema, edema of the glottis, pulmonary edema, hydrothorax, hydropericardium. Death sometimes occurs suddenly: *apoplexia serosa;* sometimes slowly: in pulmonary edema;[1] sometimes under phenomena of cerebral compression (sopor, coma, fall of temperature).

Cachectic dropsy also, finally, causes death by inanition: digestive disturbances and deficient nutrition accompanied by enormous emaciation.

---

[1] Pulmonary edema may cause sudden death, *e.g.*, in renal disease.

DISTURBANCES OF NUTRITION.
(TROPHIC DISTURBANCES.)

General Remarks upon Nutrition.

ALL vital manifestations of the organs or of their constituent elements (the cells) depend upon nutrition, which is essential for the preservation of life. When nutrition ceases, death of the cells occurs.

As with the preservation, *i.e.*, the continuance, of life, the function of all tissues likewise depends upon uninterrupted absorption of nutriment. The process of absorption of nutriment is designated as endosmosis. This is a chemic process in which the cells actively take up from the circulating juices the material which they require. The material taken up is converted into a constituent of the cells, *i.e.*, assimilated. When, for any cause, assimilation does not occur, a foreign material dissimilar to the cell-substance is present in the cell-body. This may undergo certain modifications through the action of the cell, or it is, after a time, given up by the cell.

Corresponding to absorption there is also continuous elimination of substances, principally waste materials. This process is called exosmosis. Under certain conditions constituents may also be withdrawn from the cells which they, of necessity, require for the preservation of life. If compensation by endosmosis does not quickly occur, the life of the cell is endangered or even destroyed.

During life, therefore, all cells are in a state of equilibrium regulated by endosmosis and exosmosis. Both endosmosis and exosmosis are increased during function, and are uninterrupted during the state of rest.

If substances are taken up by the cells without assimilation and subsequent elimination, the material taken up may injure the cells, disturb their function, and even destroy their vitality. This is the case, for example, in so-called parenchymatous inflammation (*q.v.*) and in coagulation necrosis.

If more material than usual is taken up by endosmosis and assimilated, enlargement of the cell results, and when all cells of an organ

are involved enlargement of the organ takes place. This increase in volume by augmentation of nutrition is designated as hypertrophy.[1]

On the other hand, diminution in the size of the cells or of an organ occurs when less nutritive material is taken up and assimilated than is consumed and eliminated. This decrease in volume from deficiency of nutrition or nutritive disturbances is designated as atrophy.[2]

Increase and decrease in the size of cells is not, however, solely dependent upon nutrition; for many cells take up also fat, pigment, foreign bodies, which they are unable to assimilate, and are thus enlarged in volume. Thus, for example, the liver-cells become larger by taking up fat—by fatty infiltration (hence, every fatty liver is enlarged), and on elimination of the fat they become smaller. On the other hand, strong distention of a fat-cell with fat is a hypertrophic process, because fat is the chief and characteristic constituent of the fat-cell.

In hypertrophy and atrophy the number of cells is not altered. If increase in volume of an organ or of a tissue is due to increase in the number of cells—*i.e.*, to augmentation of the number of cells—the process is not hypertrophy, but hyperplasia.[3] This is not a simple nutritive process, but a formative process.

If decrease in volume depends upon diminution of the number of cells, the process is one of loss—defect—caused by death of the cells: by necrosis or necrobiosis.[4]

Loss of cells by necrobiosis is designated also as necrobiotic atrophy.

Accordingly, it is necessary to differentiate between:—

1. Hypertrophy: Increase in volume without increase in the number of cells.

2. Hyperplasia: Increase in volume with augmentation of the number of cells.

3. Atrophy: Diminution in volume without decrease of the number of cells (simple atrophy).

4. Necrobiosis: Diminution in volume with decrease in the number of cells (numerical atrophy), and

5. Necrosis: Death of the cells without alteration of the number.

Numerical increase sometimes occurs in **metaplasia;** it then, like hyperplasia, belongs to the formative processes. In general, by metaplasia is understood the transformation of one tissue into another

---

[1] ὑπέρ = over, and τρέφω = nutrition.

[2] α priv., and τρέφω.

[3] Hyperplasia, from ὑπέρ = over; πλασις, from πλασσω = to produce, form.

[4] Necrosis signifies: death of the cells with preservation of the external form (*e.g.*, bone necrosis); necrobiosis, on the other hand: death of the cells with obliteration of the external form (*e.g.*, of the muscles in ankylosis).

of the same species, *e.g.*, of fibrous connective tissue into cartilage, cartilage into bone, fibrous connective tissue into adipose tissue. The physiologic example of this is the normal transformation of the fetal mucous tissue into fat-tissue; of periosteum and cartilage into osseous tissue (in growth of bones), and of the red bone-marrow of the tubular bones of the young into the yellow or fat marrow of adults. Metaplasia occurs not only in normal, preformed tissue, but also very extensively in pathologic new formations, whether of inflammatory or neoplastic origin.

Wherever one tissue is transformed into another, it is always necessary to determine whether direct transformation, a true metaplasia, has occurred, that is, whether the cells of the original tissue have been immediately transformed into the cells of the later tissue, for there are other instances in which the original tissue dies and a new tissue is built up upon its remnants (new formation, neoplasia). This process is not metaplasia.[1] In the adult tissues the possibility of transformation of one tissue into another is very limited; each individual species of tissue preserves its specific character (specificity of the tissues). Epithelium is not transformed into connective tissue nor connective tissue into nerve tissue.

Pathologic metaplasia is of quite frequent occurrence. It is subject, however, to certain limitations in so far as transformation of one tissue into another is possible only within closely allied tissue. As already stated, all highly organized tissues, such as muscle, gland (epithelium), and nerve tissue, cannot be transformed into each other. Likewise, no transformation occurs between epithelial tissue, on the one hand, and the large group of connective-tissue substances on the other. Until quite recently it was assumed that connective tissue and epithelium could be transformed into each other. This view has now been abandoned.

Metaplasia is most frequently observed in the group of connective-tissue substances, the derivatives of the parablast: fibrous connective tissue, adipose tissue, cartilage, bone, endothelium, lymph-gland cells. Next to these, epithelium not infrequently undergoes metaplasia.

The cause of metaplasia cannot be recognized in every case. In addition to general and local disturbances of nutrition, the most frequent causes are various forms of irritation (mechanic, functional, formative, nutritive, inflammatory) acting at the point of metaplasia.

---

[1] In this respect, the change in the thymus is quite striking. At first it is an epithelial organ; later it is so infiltrated with lymphatic tissue that the epithelium disappears except a small remnant (the so-called Hassall's bodies). Thus, the organ which originally was epithelial becomes a lymphatic organ. The transformation, however, is not a direct metaplasia of epithelium into lymphatic tissue, but the result of death of the epithelium followed by increase of lymphatic tissue.

In severe general nutritive disturbances, transformation of adipose tissue into colloid tissue and of fat-marrow of the tubular bones into colloid marrow is observed. Here the cells gradually lose their fat, change from the rounded into more elongated, stellate, and spindle-shaped forms, while at the same time a homogeneous, colorless, often mucinous, colloid intercellular substance appears. In less severe nutritive disturbances and with advancing age, gradual diminution in the amount of fat-tissue and progressive transformation into connective tissue are more frequently seen, especially in the omentum.

On the other hand, in general disposition to corpulency (*obesitas, adipositas, polysarcia*), progressive transformation of fibrous connective

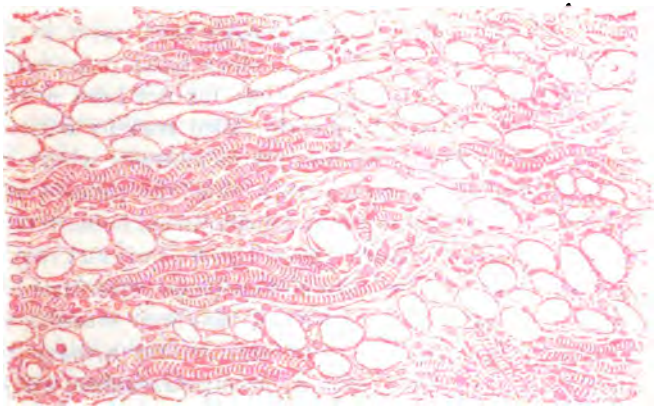

Fig. 19.—Atrophy of muscle with lipomatosis. The muscle-fibers have become very slender, and between them is an excess of fat. Hardening fluids have removed the fat, leaving vacuoles in its place. × 250. (After *Smaus.*)

tissue into adipose tissue is observed. This is always associated with increase in volume of the parts in which the transformation occurs, owing to local accumulation of fat. Probably, at least in the higher degrees, there is also an increase in the number of cells, for in many localities the number of adipose-tissue cells often exceeds the number of fibrous connective-tissue cells normal to the part. These higher degrees of polysarcia cause progressive transformation of fibrous connective tissue into adipose tissue also in localities where only fibrous connective tissue is normal. This is the case at the orifices of the body, *e.g.*, at the anus, where the *panniculus adiposus* of the external parts joins the submucosa of the rectum. There are two internal organs which quite frequently manifest this metaplasia to a marked degree, namely, the heart (fatty heart) and the pancreas. In both, progressive transformation of the intermuscular or interacinous connective tissue, respect-

ively, into adipose tissue occurs from without (from the adipose tissue) inward (see Fatty Degeneration, p. 155, and Hypertrophy, p. 111). A similar change is sometimes observed in the skeletal musculature. (See Hypertrophy and Pseudohypertrophy, p. 109).

In chronic inflammatory processes hyaline cartilage (*e.g.*, in arthritis deformans) is often transformed into fibrocartilage and—the cartilage cells losing their capsules and assuming other forms—into fibrous connective tissue. In other cases cartilage approaches mucous tissue by softening of the homogeneous basement substance into a semifluid colloid. In pathologic cases bone may develop from fibrous connective tissue in the same manner as bone develops from periosteum in a growing individual. This is the case, for example, in old inflammatory products, as in old adhesions of serous membranes, rarer in the region of chronicly thickened vessels. On the other hand, transformation of bone into fibrous connective tissue has thus far not been demonstrated.

Metaplasia of epithelium (frequently called transformation) is confined essentially to those parts of mucous membranes which have been altered by inflammatory processes. As a rule, the process is a transformation of cylindric epithelium into squamous epithelium (*e.g.*, in the bronchi), or hornification (called also epidermization) of the superficial layers of either the normal lamellated squamous epithelium upon mucous membranes or of such as has been transformed from cylindric epithelium (*e.g.*, in the nasal mucosa, the urinary tract, oral mucosa in leucoplakia, of the vagina in *prolapsus vaginæ*, etc.). Allied to this epithelial metaplasia are other processes in which one form of epithelium is displaced by another type: *metatypia*. This occurs in localities where squamous and cylindric epithelium join, *e.g.*, at the *portio vaginalis uteri* in the vicinity of so-called erosions (displacement of squamous epithelium by cylindric epithelium), and in the region of fistulous openings. Here, again, it is important to determine whether one type of cell has been immediately transformed into another or whether the cells originally present have died and the new cells assumed another type; furthermore, whether the change of type is the result of adaptation to altered conditions—*i.e.*, an histologic accommodation. Resting cells differ in type from those which are in motion. Simple change in the form of cells is not metaplasia. Metaplasia is more than this: it includes not only the morphology, but also the function. The question here arises whether an anaplasia—a reversion of the cells to an earlier type—can occur in pathologic states. This earlier type, which corresponds to the first period of fetal development, is characterized by the fact that individual cell types (*e.g.*, epithelia) are not yet sharply

differentiated, and that the cells possess a more decided tendency to growth than at a later period.

Sometimes organs are so modified in structure by disease as to justify the expression "reconstruction." This is true particularly of the liver, which is very markedly altered by chronic interstitial inflammation.

Several observations show that transformation of the epithelium of excretory ducts of glands into true glandular epithelium also is possible.

According to recent observations, transformation of the endothelium of lymph- and blood- vessels into connective-tissue cells, and probably also of connective-tissue cells into endothelium, is more frequent.

HYPERTROPHY.

In order for an organ or a tissue to become hypertrophied, *i.e.*, for more nutritive material to be taken up and assimilated by the individual cells, certain stimuli—nutritive stimulation—an uninterrupted supply of nutriment being present, are necessary. The result of this stimulation is always active increase of nutrition. The stimulation is the result of augmentation of the natural, physiologic, adequate stimuli, *e.g.*, increased demand upon the musculature, increased function of a kidney, testicle, etc. The functional capacity of an hypertrophied organ is augmented only when the functionating cells—the functionating parenchyma of the organ hypertrophy.

In contrast to this true hypertrophy dependent upon increase in volume of the individual functionating cells stands so-called pseudohypertrophy, in which not the parenchyma but other parts increase in volume, the parenchyma itself, however, gradually undergoing atrophy. Consequently, the functional capacity of a muscle in muscular pseudohypertrophy is not only not increased, but usually markedly diminished, often paralytic. The increase in volume of the muscle in pseudohypertrophy is produced by marked interstitial development of fat-tissue between the primitive muscle bundles. The fat-tissue development is not a pure metaplasia of the interstitial connective tissue into fat (see Metaplasia, p. 105), but is partly also a formative process accompanied by proliferation of the connective tissue. This affection, in which the nervous system is not involved, begins in childhood, is slowly but constantly progressive, and often hereditary.

A similar interstitial development of adipose tissue is observed in the musculature in ankylosis and paralysis. Here, also, the true contractile substance is in the state of atrophy. Nevertheless, the two processes should not be considered identic, because in paralysis and ankylosis

the muscles, in spite of the adipose-tissue development, appear markedly reduced and the interstitial development of fat-tissue is a secondary phenomenon—a sequela. Here the interstitial development of adipose tissue is a purely metaplastic and compensatory process for the atrophy of the musculature.

Finally, interstitial development of fat-tissue occurs also in the heart, especially in the right ventricle. This is always an accompaniment of a general lipomatosis. Here the pericardium also is always unusually rich in fat-tissue; from here, under progressive metaplasia of the intermuscular connective tissue into adipose tissue, the latter penetrates between the muscle bundles, and wherever a large amount of fat-cells is already present the true muscle substance atrophies.

True hypertrophy of the musculature occurs in the heart, in the voluntary skeletal muscles, and in the smooth musculature. Hypertrophy of the voluntary skeletal musculature is the result of increased activity: activity hypertrophy. In a measure, this is a physiologic analogue of true pathologic hypertrophy. As a rule, only certain groups of muscles which are markedly taxed are involved, according to the mode of life, labor, occupation, sport, athletics.

Pathologic hypertrophy of muscular organs (of the heart, urinary bladder, gall-bladder, gastrointestinal canal, etc.) is dependent upon more or less increased efforts necessary to overcome pathologic hindrances. Here hypertrophy is always a phenomenon compensating as much as possible the pathologic hindrance; therefore, of itself it is not, in a strict sense, pathologic. The disturbance produced by the pathologic interference is compensated by the hypertrophy: compensatory hypertrophy.

This hypertrophy is observed in the heart, namely, in the left ventricle in stenosis and insufficiency of the valves of the aortic orifice; in high degrees of arteriosclerosis; in contracted kidney; in the right ventricle in chronic affections of the lungs (in which a part of the pulmonary vessels is obliterated: in alveolar emphysema, ulcerative pulmonary phthisis, chronic induration, and chronic bronchitis with coincident total obliteration of both pleural cavities); in stenosis and insufficiency of the mitral valve; in valvular lesions of the pulmonary orifice; in the bladder as trabecular hypertrophy in disturbances and difficulty in voiding urine (from vesical calculi, prostatic hypertrophy, stenoses of the urethra, tumors); in the gastrointestinal canal in narrowings of the lumen (stenoses by tumors, strictures by cicatrices, etc.), and in the uterus during gestation.

In hypertrophy of the muscles (myocardium, voluntary skeletal musculature, and smooth [involuntary] muscles) enlargement of the

diameter of the muscular fibers (of the individual muscle fibers, the primitive muscle fibrillæ and muscle cells) occurs, so that the whole muscle is not longer, but thicker. Only the smooth muscle cells undergo also a very considerable increase in length (*e.g.*, in pregnancy), becoming ten times as long as they were before conception.

Hypertrophy of adipose tissue is observed in all persons who manifest a marked disposition to obesity. This adiposity (metaplasia) frequently is complicated with partial proliferative states (hyperplasias), which result in the formation of fat-tumors (lipomata). In most cases hypertrophy of adipose tissue is accompanied by metaplasia of the connective tissue into fat-tissue. Hypertrophy of adipose tissue often occurs



Fig. 20.—Hypertrophy of the right lung due to disappearance of the left. Anterior view. ⅓ natural size. (After *Langerhans.*)

as a compensatory phenomenon in atrophy of certain organs, *e.g.*, in the hilus of the kidney in granular atrophy of the kidney.

Hypertrophy of glandular organs is particularly marked in paired organs (kidneys, testicles, etc.; also of the lungs in premature shrinkage of one lung, and in unilateral deforming pleuritis) when, for example, one kidney or one testicle is rendered functionless by pathologic processes or extirpation. This is also a vicarious or compensatory hypertrophy, because the defect, the absence of one gland, can be compensated by the augmented activity of the other. In the kidney considerable enlargement of the glomeruli is observed, the capillary loops becoming larger and broader, and the urinary tubules increasing in size. The latter consists essentially in widening—enlargement—of the lumen of the urinary tubules; the glandular epithelia appear to be only slightly enlarged.

In compensatory hypertrophy of one lung as the result of obliteration of the other, the alveoli are unusually large and the bands of the lung-tissue between the air-spaces markedly broad and richly supplied

with very wide capillaries. The lung-tissue, therefore, is increased in surface area and in thickness, and more blood flows through the very widely distended capillaries. In this manner greater gas exchange is possible without increase of alveoli. Consequently, in compensatory hypertrophy of the kidneys and of the lungs the phenomena are very similar, if not, indeed, the same.

Ponfick has drawn attention to an analogous compensatory hypertrophy of individual lobules of the liver in experimental destruction of other lobules (in animals), and a number of observations in man render it highly probable that something similar occurs also in man.

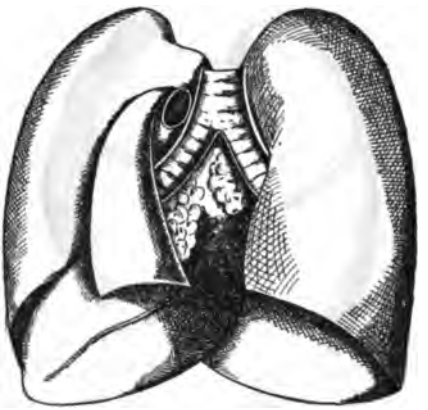

Fig. 21.—Hypertrophy of the right lung due to disappearance of the left. Dorsal view. Heart to the left, partly covered by the completely atelectatic left lung. Both large bronchi are uniformly well developed. ⅓ natural size. (After *Langerhans*.)

Hypertrophy of the milk glands and of the prostate is of frequent occurrence. The milk glands are regularly enlarged toward the end of pregnancy, to again atrophy after lactation or after labor. Very frequently the milk glands of both breasts are unequal in size; sometimes there is more marked development of some of the glandular lobules upon one side. Very considerable hypertrophy of the milk glands is observed at the beginning of puberty independently of pregnancy and lactation. Hypertrophy of the milk glands sometimes occurs even in males, in whom these organs are generally arrested or undergo atrophy during the first years of life.

Hypertrophy of the prostate usually begins in advanced age, at about the time when arteriosclerosis, upon which French authorities would have us believe prostatic hypertrophy depends, becomes distinctly

manifest. Partial hypertrophies of the prostate are usually more frequent than general, uniform enlargement.

In nerves hypertrophy is observed in some cases not only in the axis cylinders, but also in the medullary sheath (the myelin). Alterations in the medullary sheath, which does not belong to the true, cellular part of the nerves, are most frequent.

ATROPHY.

Atrophy is always a nutritive disturbance, a state of diminished nutrition, of defective preservation of whole organs or certain portions of them. It occurs either as simple diminution in the size of the elements: simple atrophy, or with synchronous appearance in the cells of foreign masses which do not belong to the cell in the healthy state, namely, either pigment (pigment atrophy) or fat (necrobiotic atrophy). In simple and in pigment atrophy the number of cells is not reduced; necrobiosis, on the other hand, causes a disappearance of the cells, *i.e.*, a diminution in number. In brown as well as in necrobiotic atrophy the normal constituents of the cells are always diminished, for, although the cells at times appear to be larger, they are, nevertheless, smaller as soon as the foreign constituents (pigment, fat), which occupy the place of the normal constituents, are removed. This reduction in size is accompanied by diminution or suspension of function, because the latter is connected only with the normal constituents of the cells.

Simple atrophy as well as necrobiosis are to be distinguished from hypoplasia,[1] from original defective Anlage in the formation of individual parts.

The cause of atrophy sometimes resides in the part itself, sometimes in insufficient supply of nutritive material. In the first instance the process is a deficiency of natural, adequate stimuli and deficiency of function. A muscle which is not used (owing to ankylosis, fracture, etc.) atrophies; a peripheral nerve which is separated from its ganglion dies by fatty metamorphosis; maxillary bones atrophy after loss of the teeth; glands (testes, milk glands, etc.) atrophy from prolonged inactivity.

If the atrophy is due to insufficient nutrition, it is sometimes local, caused by local circulatory disturbances (ischemia, congestion, hyperemia, inflammation, edema), sometimes general, caused by pernicious anemia or defects of the blood-mixture (leukemia), or by disturbances of general nutrition (deficiency of nourishment alone;

[1] From ὑπό, under, and πλασις, formation. (See p. 105.)

dyspeptic, senile states; disturbances in absorption of the chyme), or by exhausting loss of fluids (repeated loss of blood, suppurations, exudations).

Simple atrophy (wasting, emaciation, macies[1]), by diminution of the bulk of the constituent elements, causes a reduction of volume of whole or individual portions of organs.

In atrophy of adipose tissue (*macies*), which under normal conditions is light yellow in color, the fat-cells and the oil-drops they contain become smaller. The oil-drops finally break up into a number of smaller droplets (simple atrophy). In this diminution in size the oil-drops frequently assume a deep-yellow color. If higher grades of atrophy persist for a long time, the color becomes more and more reddish yellow to brownish red (microscopicly: orange-colored). In the cadaver these parts not infrequently acquire a greenish to blackish color as a result of decomposition. This atrophy with chronic character, which occurs especially in chronic affections associated with marasmus, is called brown atrophy of the adipose tissue.

Atrophy of the **musculature** likewise may occur with or without pigment formation, so that here also a simple and a brown atrophy must be distinguished. In brown atrophy the macroscopic color is due to very small, microscopic, yellowish-brown, amorphous, clodded, very slightly refractive pigment-granules which accumulate in very variable amount, chiefly at both poles of the nucleus. This deposition of pigment occurs not only in atrophied, diminished musculature, but also in some cases of hypertrophy. Here a hypertrophic state had originally existed; with the nutritive disturbance and the pigment thus produced, a certain reduction in volume had secondarily occurred; this was not, however, sufficient at once to produce from the hypertrophy visible atrophy or even a reduction to the normal size. (See Fig. 28.)

Pigment atrophy of the musculature is most frequently observed in the heart. It occurs in old age and in chronic processes (carcinoma) which cause early marasmus.

Brown atrophy of the liver is likewise characterized by the formation of small, brown, amorphous, clumped, slightly refractive pigment-granules associated with disturbance of nutrition and diminution in the

[1] Macies is employed chiefly to designate atrophy of adipose tissue; tabes is now used for atrophy of the peripheral nerves and the spinal cord, formerly for atrophy of the muscles; marasmus (*μαραινω* = disappear) for atrophic changes of the aged and for premature senile phenomena. Cachexia (*κακὸς ἔχειν* = act badly) signifies bad state of the blood (hydremia, etc.) and of the nerves; consumption, the using up of proteid material in high, particularly hectic, fever; phthisis, chiefly for wasting (*φθινω*) of the whole body with febrile manifestations and generally also local ulcerations (principally in the lungs), subsidiarily, every wasting of functionable substance.

size of the cells. This pigmentation always begins in the central zones of the acini and gradually advances from there toward the periphery, under the same conditions which lead to brown atrophy of the heart.

In adults the ganglion cells of the brain contain brown pigment so regularly that certain portions (e.g., *substantia nigra*) are accentuated by it and considered normal. The yellow-brown coloring matter is located in the region of the nuclei. The colorings vary widely according to the age and also individually; not all are within physiologic limits.

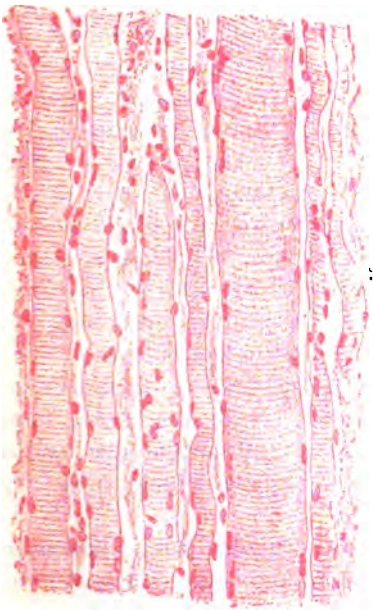

Fig. 22.—Muscle-fibers in simple atrophy. (After *Smaus.*)

Fig. 23.—Atrophy of a muscle with increase of nuclei. × 250. (After *Smaus.*)

Marked pigmentation of the ganglion cells in the cerebral cortex is a suspicious sign. Although the greater capability of the ganglion cells to form pigment must be admitted, such pigmentation is, nevertheless, always a deviation from the type. In many cases of more or less intense accumulation of pigment—brown atrophy of the ganglion cells—complete disappearance of the individual cells unquestionably follows.

In the spleen and testes also nutritive disturbances and diminution in the size of the organs are frequently associated with pigmentation.

Brown atrophy (*atrophia fusca*), therefore, marks a group of chronic nutritive disturbances which probably are irreparable. The cells are present and can functionate, but function is diminished, weakened.

In simple atrophy (*atrophia simplex*) of the tissues and organs (heart, liver, spleen, testes, uterus, ovaries, etc.) the volume of the individual cells (of connective tissue, adipose cells, musculature, gland-cells of the stomach, liver, etc.) is diminished,[1] and often this is microscopicly demonstrable only by exact measurement; other indications of simple nutritive disturbance are lacking. In the adipose-tissue cells, the fat content of the cells diminishes, smaller droplets of fat separating from the larger drops.

Simple atrophy is observed in states of inanition, in hunger and starvation; also in experimental starvation, in animals as well as in man. By accurate measurements it has been found that in hunger the fat-tissue loses most in weight; next the blood, then the muscles and glands, and least the bones and the central nervous system.

In simple atrophy of connective tissue (in atrophic, plexiform omentum; in the valves of the pulmonary and aortic orifices of the heart; in coalescence of contiguous cysts of the kidney, the thyroid, etc.) and of the lung-tissue (in alveolar emphysema) small spaces develop by rarification in the firm substance, which, on further progress, may produce fenestration (of the valves), honeycombing (of the stroma of the kidney), or even reticulation (in the omentum).

In simple and brown atrophy the fluid constituents of the tissues first diminish, and later the formed elements. Hence, the firmness and dryness of atrophied organs; hence, also, the disappearance of the natural turgor of the tissues (sunken face, etc.) in simple, transitory states of hunger.

In **necrobiotic atrophy**[2] (necrobiosis, atrophy with diminution of number, death of the cells with obliteration of the external form, fatty metamorphosis) the appearance of fat within the cells precedes disappearance of the cells. This phenomenon is always a chemic process, in which part of the albuminous constituents of the cell-body is replaced by fat. The chemic alteration of the organic constituents of the cells is manifested by the appearance (on viewing with strong objectives) within the cell-body of very minute points consisting of fat. The nucleus of the cell is at first unaltered, later it is obscured by fat, and, finally, it

[1] Many observations indicate that in simple atrophy as well as in brown atrophy—except of the ganglion cells—diminution in the volume of the cells may advance to complete disappearance.

[2] The view that the fat occurring in the cells in necrobiotic atrophy originates as the result of chemic transformation of the constituents of the cell, namely, of the albumin (so-called "fatty metamorphosis") has recently been combated by a number of investigators who assert that the fat is conveyed to the cells from without. In the absorption of fat, splitting and synthesis probably occur through the agency of the cells themselves. The nucleus remains normal for some time, and in fresh preparations appears to be obscured by fat, but is again rendered visible by extraction of the fat.

disappears. The minutest fat-points quite rapidly increase in number and size, grow to minute fat-droplets, and, finally, fill the whole cell-body. The fat probably locally combines within the cell with certain normal constituents (perhaps with Altmann's granules) in such a manner that the latter are more or less rapidly substituted by fat. In this stage the cell consists in greater part of fat granules, and, therefore, is designated as granular cell. The fatty granular cell, the nucleus and external contour of which are still plainly recognizable, changes into a granular globule, in which neither membrane nor nucleus can be made out, and only in a general way still preserves the external form

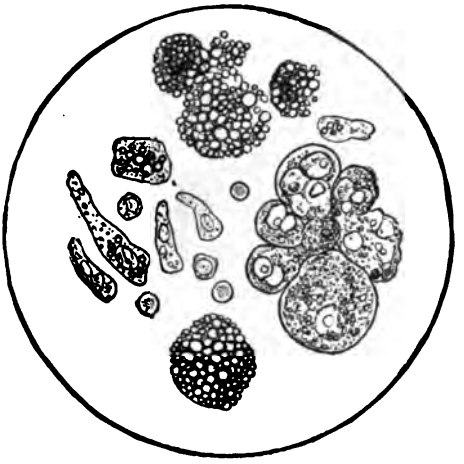

Fig. 24.—Fat-granule spherules in pulmonary carcinoma. × 350.

of the cell. The external contour of the granular globule is granular in accordance with the individual fat-granules. The granular globule is held together by a remnant of the old contents of the cell. In the further stage it disintegrates and furnishes a fatty detritus,[1] a kind of emulsion: emulsion stadium. With this, complete extinction of function and the possibility of reparation, which in simple atrophy does not appear to be excluded, occur. The functional disturbance which follows necrobiosis depends upon the sum of the elements involved.

Almost all cells may die by necrobiosis; only the red blood-corpuscles and the ganglion cells are exceptions. The whole process of necrobiosis has a physiologic analogue in the formation of milk.

The cause is either local circulatory disturbances (congestion, anemia) or general nutritive disturbances (pernicious anemia, leukemia,

[1] From *deterere,* to wear away; *detritus,* disintegration product.

cachexia); or it is a sequela of parenchymatous inflammation. Necrobiosis caused by direct nutritive disturbance is designated as primary; that which follows parenchymatous inflammation is called secondary.

The termination of necrobiosis may be:—

1. Absorption of the fat (physiologic in the corpus luteum), especially within richly vascular organs. In the locality of the disintegrated cells either a cavity filled with more or less clear fluid appears (cystic degeneration) or the adjacent parts gradually approach until contact, *i.e.*, collapse: ***sanatio incompleta.***

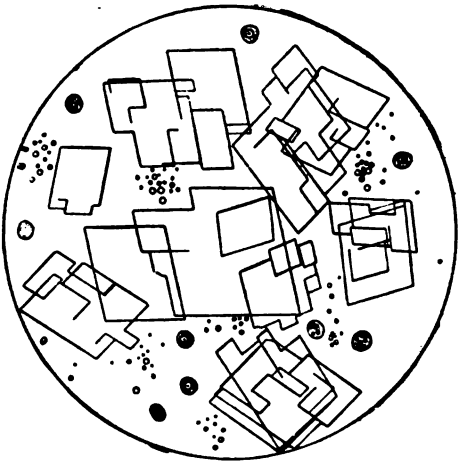

Fig. 25.—Cholesterin plates. Crush preparation. × 350.

2. Secretion of fat (physiologic in the formation of milk), especially upon the surface of glandular organs, *e.g.*, in filling of individual renal epithelia with fat; in this case the fat-granules are washed out with the urine.

3. Retention of fat. This occurs only when neither absorption (from deficiency of vessels) nor secretion (when the surface is not reached) is possible, as, *e.g.*, in the interior of poorly vascularized parts (intima of the aorta). Then cholesterin[1] is almost always separated from the fat in the form of iridescent rhombic plates. (Fig. 25.)

[1] The rhombic cholesterin crystals frequently lie flat upon each other, sometimes in such large numbers that, *e.g.*, in atheroma of the arteries, the characteristic shimmer can be seen through the thin superficial tunic. Cholesterin is soluble in alcohol and ether, but cannot be saponified; it is a constant constituent of atheromatous cysts of the external skin, occurs physiologicly in the vernix caseosa of the fetus as a product of the sebaceous material of the skin.

Necrobiosis of muscle is characterized by the very regular arrangement of the fat-puncta in transverse (corresponding to the transverse markings) and longitudinal (corresponding to the primitive muscle fibrillæ) rows. With the appearance of these fat-puncta the transverse markings become indistinct. If the fat-puncta enlarge and coalesce to form large fat-droplets, as in severe chronic anemias (pernicious anemia), the transverse markings disappear. (See Fig. 26.)

In so-called fatty metamorphosis of the cornea, which, in advanced age, is not infrequently very extensive, usually in arched form (*arcus senilis*, a semicircle open below), the large, flat, stellate cells, of which the transparent cornea is composed, become filled with fat-granules without disintegration of the cells themselves. Consequently, less light enters the eye; part of the rays of light is reflected, imparting a cloudy appearance to the affected portion of the eye (the cornea). This condition may persist for a long time.

Fig. 26.—Small fragments of heart muscle in advanced stage of fatty metamorphosis in severe parenchymatous nephritis. (Zeiss Apochr., 4; Comp. Ocul., 4. After *Langerhans*.)

In the intima of the aorta—a connective-tissue tunic which in transparency possesses a certain resemblance to the cornea—very large, branching, flat cells occur, which become filled with fat and are often recognizable, even with the unaided eye, as minute, light-yellow striæ and puncta.

The examples thus far presented illustrate the different forms of atrophy. In each instance the process is a simple, uncomplicated, and easily interpreted one. Important as it is from a theoretic standpoint sharply to differentiate the three forms of atrophy: simple, fatty (necrobiotic), and pigmentary atrophy, it is equally impossible from a practical standpoint accurately to determine in many undoubted atrophies what rôle one or the other form of atrophy plays. All three forms quite often coexist; sometimes they are complicated also by metaplastic and formative processes.

The difficulties begin even in physiologic atrophy, in so-called involution of the breast gland. As is known, the

thymus gland begins to atrophy early and completely disappears at about the time of puberty, being gradually substituted by adipose tissue. At all events, diminution in the number of cells occurs, though at present it is still undecided how this takes place. Nothing is known of the cause of atrophy of the thymus gland. In very young animals the thymus gland can be operatively removed at a period in which atrophy has not yet begun, without inducing any visible disturbances.

Our knowledge of (physiologic) atrophy of the milk glands after lactation and of the female generative organs at the climacteric period is not much better. Why does the mammary gland cease to produce milk after weeks, months, or about a year, in spite of the fact that the external conditions remain unchanged? What is the internal cause, and in what manner does atrophy occur? Why do the products of the ovaries cease at a certain time—at a time when the rest of the body is still vigorous and capable of function? That the menses cease at the time the products of the ovaries cease, and that with cessation of menstruation the uterus gradually begins to atrophy, are less difficult of interpretation, for as long as menstruation lasts a strong affluxus to the uterus with increase of nutrition occurs at regular intervals. With beginning of the menopause this regularly recurring stimulation of the uterus ceases, and, consequently, atrophy occurs from inactivity: inactivity atrophy, or atrophy from disuse. The same phenomenon may be observed in the uterus after parturition.

This inactivity atrophy is a quite frequent phenomenon also in other organs. As soon as a part is for a long time prevented from functionating—*i.e.*, as soon as the integral stimuli are abolished—diminution in volume occurs without it being possible in every case accurately to state how the atrophy takes place. Thus, in paralyzed limbs and in ankylosis the epidermis, the skin ("glossy skin" develops: smooth, glistening skin resulting from obliteration of the folds, atrophy of the papillary bodies, and thinning of the skin), the muscles (here there is frequently vicarious development of adipose tissue), and bones atrophy. In persons who are not full-grown the bones remain at the stage of development then attained, and do not grow with the remaining skeleton; in some cases there is even diminution in size (especially thinning), which, however, is usually slight. The same phenomena are observed in chronic, particularly recurrent, tuberculosis and suppurative articular inflammations, and in luxations. The musculature atrophies even in temporary immobilization of extremities for fractures. After congenital luxations of the hip the acetabulum disappears and the head of the femur remains rudimentary. In later acquired and unreduced luxations also,

atrophic changes occur in the cartilage (with fibrillation of the homogeneous basement substance) and in the bone.

Glandular organs, such as the testes and mammary glands, also atrophy as the result of prolonged inactivity; the milk glands, *e.g.,* when nursing is possible, but for some reason (sickness, laziness, prejudice) is neglected. Atrophy of the mammary glands is in many cases hereditary, so that in many families the mothers are incapable of suckling their offspring. In most cases the glands themselves are still preserved, but small, of defective construction, and poorly nourished. Atrophy of the milk glands is in many cases accompanied by atrophy of the surrounding adipose tissue.

In old age most of the tissues atrophy: the connective tissue of the skin, the hair, the adipose tissue (hence, wrinkles develop, most markedly in the face), cartilages, bones (symmetric senile atrophy of the external table of the parietal bones, atrophy of the lower maxilla, etc.), teeth, musculature, and the internal organs: ganglion cells of the brain and spinal cord; heart, liver, kidneys, spleen, cornea, genitalia, etc.

This **senile atrophy** belongs, in great part, in the domain of pigmentary atrophy and fatty metamorphosis. Very little is known of the cause of senile atrophy; in explanation it is usual to assume an extinction of the powers of reproduction. At all events, there is no such definite age limit for senile atrophy as for the beginning of the menopause. In some cases senile changes are observed in quite young individuals; this is especially the case when premature senescence with marasmus occurs as the result of chronic affections (marantic atrophy). In these cases the adipose tissue, the musculature, the heart, spleen, and liver are principally attacked by the atrophy.

Atrophy resulting from the action of certain chemic substances (medicaments, poisons, etc.) is observed in lead poisoning: granular atrophy of the kidneys, atrophy of the extensors of the hand; furthermore, in internal and external employment of iodine: atrophy of the hypertrophied thyroid gland; in uric acid diathesis: granular atrophy of the kidneys.

Tissues and organs may also be caused to atrophy from pressure: pressure atrophy. Here, however, two things must not be overlooked: first, that in all soft, compressible tissues the vessels also are compressed and local anemia (ischemia) develops, and, second, that in hard tissues (cartilage, and especially bone) pressure of tissues against the bones (*e.g.,* Pacchionian bodies, aneurisms, tumors, etc.) causes irritation of the periosteum, which leads to formation of granulations and absorption of compact bone. Pressure atrophy of the parenchyma is observed in chronic interstitial inflammations

(kidneys, liver, heart, testes, stomach), which terminate in cicatrization; in extreme congestion of the liver (from valvular lesions of the heart): red, cyanotic atrophy, nutmeg liver (here simple, fatty, and pigmentary atrophy coexist); in the kidneys: passive congestion of the kidney with primary fatty metamorphosis of the parenchyma; in the formation of constrictions of the liver; in atrophy of the testes from hydrocele[1]; of the cornea and sclera from hydrophthalmos; in confluence of neighboring cysts in the kidney and in the thyroid gland. Atrophy of the kidneys from hydronephrosis is complicated by chronic interstitial nephritis terminating in contraction. In all these cases it is well to remember that the capillaries also are compressed by the pressure, so that anemia and, thus, nutritive disturbances occur.

Under neurotic atrophy is included a large group of atrophic processes which develop in connection with various affections of the central nervous system (infantile spinal paralysis, amyotrophic lateral sclerosis, chronic poliomyelitis of adults, progressive [spinal] muscular atrophy, progressive bulbar paralysis, and others), and with injuries, especially gunshot wounds, of the peripheral nerves. The common feature of this whole group is disturbance—interruption—of the conduction and the influence of the nerves. Here it is not solely a question of deficiency of integral stimuli, but either of arrest of direct influence of the nerves upon nutrition (of the skin and muscles, seldom of the bones)—it being assumed that special nutritive centers exist in the brain—or of disturbance of nutrition by stimulation or paralysis of the vasomotor nerves.

According to the condition (state) of the external surface are distinguished smooth atrophy and granular atrophy. In the first the surface of an organ[2] becomes, or remains, smooth; in the second it becomes granular (kidney, liver). In granular atrophy of the kidney the surface is sometimes finely, sometimes coarsely, granular. The finely granular surface always corresponds to a chronic interstitial process; the coarsely granular to a chronic parenchymatous process. In both cases the parenchyma of the kidney atrophies.

---

[1] For other examples of atrophy from dropsy, see Dropsy, p. 98.

[2] Smooth atrophy of the base of the tongue (*atrophia lævis radicis linguæ*) always develops upon a syphilitic basis and is due to an inflammatory, formative process, which, by cicatrization, causes atrophy of the follicles lying posterior to the *papillæ circumvallatæ*. In this instance the base of the tongue is smooth and more or less indurated and white.

GANGRENE.

In contrast to total death of an individual (animal, somatic, systemic death) stands local death of constituent parts (vegetative, molecular death). The constituent parts (cells) possess a *vita propria* (irritability) which may persist for some time after total (somatic) death. In somatic death a succession of processes always occurs dependent upon the *vita propria* of the constituent parts. The latter (with exception of the three vital organs: brain, heart, and lungs, which constitute the *atria mortis*[1]) may die without directly endangering the further existence of the individual.

Death of individual parts, or local death, occurs either with obliteration of the external form: necrobiosis,[2] or with preservation of the organic structure: necrosis. The altered or intact morphologic state indicates the change which has occurred in the organ. The dead part is no longer capable of function.

Gangrene[3] always terminates in mortification,[4] necrosis. Gangrene is the final, extreme, progressive stage of positive inflammatory processes—a degree of inflammation so intense that death of the tissues always results. Hence, the designation hot gangrene in contradistinction to complete death, or cold gangrene—slough (sphacelus).

Gangrene develops as a result of disproportion between the nutrition of a part and the degree of the injurious effect exerted upon it. In many cases the inflammatory phenomena ensue and subside with extreme rapidity, so that they are very easily overlooked and the local death thus becomes the prominent feature; in many other instances the sequelæ, which are chiefly of a cadaveric, putrid nature, obscure the essential process.

The dead state of the tissues, necrosis, is most clearly and sharply manifest in necrosis of bone, because bone is just as slightly altered by secondary cadaveric changes as by maceration. Therefore, necrosis of bone serves in a measure as the type for necrosis in general. It usually develops from suppurative periostitis or osteomyelitis which is accompanied by destruction of the involved afferent vessels. The dead segment of bone—the sequestrum—has about the appearance of a well-macerated bone, and, in contradistinction to living carious bone, is remarkably smooth upon the surface.

---

[1] At one time it was believed that death commenced in the heart, lungs, or brain. These organs were, therefore, called the *atria mortis*: the "halls of death."

[2] Compare Atrophy, p. 116.

[3] γάγγραινα = cancer, cancer-ulcer, cold gangrene, which ends in death.

[4] Galen defined gangrene briefly and aptly: *mortificatio fiens.*

Adipose tissue also is usually very slightly altered in structure in fat-tissue necrosis; the necrotic focus remains morphologicly almost intact, but when viewed with the naked eye it generally appears like a small, yellow-white, opaque spot imbedded in the surrounding yellow fat-tissue.

Dead extra-uterine feti may remain in the abdomen for decades in a macroscopicly and microscopicly well-preserved state, giving up only a portion of their fluid constituents to the surrounding parts.

In direct, complete interruption of nutrition without inflammatory manifestations (*e.g.*, in infarctions, in kidneys in which the arteries have been ligated) a peculiar change often occurs in the cells, in which the nucleus disappears, the contour of the cells, however, at first being still preserved. As these dead cells present appearances similar to firmly coagulated fibrin, Weigert, who has most thoroughly investigated this phenomenon, has designated this change as coagulation necrosis. In this process it is asserted that fibrin is formed within the cells. According to Weigert, this coagulation necrosis is observed not only in interruption of the circulation, but also very extensively in inflammatory and degenerative processes. By some authors caseation also is looked upon as coagulation necrosis. Caseous material, however, is readily distinguished from the more yellowish and less dry foci of coagulation necrosis by its dry, white, opaque character. In caseation also the material is necrotic, dry albumin which originates by inspissation—desiccation—of cellular elements, the intercellular water being first abstracted and then the intracellular, the cells shrinking, losing their contour, and producing irregular, granular, and polygonal clumps. Tubercle, pus, tumors, and hyperplastic lymphatic tissue manifest an especial disposition to caseation.

Superficial necrosis (not gangrene) develops in the region of the focus of desiccation—*i.e.*, of slough formation—when internal organs or external parts deprived of protecting epidermis (*e.g.*, by trauma) are exposed to evaporation.

The causes of gangrene are:—

1. Circulatory disturbances: anemia, congestion, stasis, dropsy, and

2. Action of external injurious influences: infection, intoxication, cauterization, bites of poisonous serpents, higher degrees of burning, and freezing.

Gangrene occurs only when both causes co-operate. External injurious influences alone without disturbance of circulation are no more causative of gangrene than circulatory disturbances alone. Complete interruption of nutrition from cessation of the circulation causes necrosis directly without inflammatory phenomena. In gangrene the relation

between both co-operative causes is generally of such a nature that one —either the circulatory disturbance or the external injurious influence— greatly predominates, and, therefore, the other may easily be overlooked.

Two forms of gangrene are differentiated: **dry gangrene** (*gangræna sicca, mummificatio*) and **moist gangrene** (*gangræna humida, putrescentia*).

Dry gangrene occurs only upon the surface of the body, because evaporation here plays a very important rôle, and this is possible only upon body surfaces on contact of the gangrenous part with the atmospheric air.

Desiccation is always preceded by formation of vesicles. This occurs as follows: The red blood-corpuscles dissolve, the hemoglobin is diffused and stains the blood-serum red; this red fluid uniformly permeates all the dying tissues (*œdema gangrænosum*), and accumulates between cutis and epidermis, elevating the latter from the rete Malpighii in the form of vesicles: so-called gangrene vesicles (gangrenous bullæ). The fluid in the vesicles turns livid, blackish blue, and the vesicles frequently have a certain resemblance to "blood-blisters" (*bulla hæmorrhagica*), which, however, always contain intact red blood-corpuscles. On bursting of gangrene vesicles, *e.g.*, in consequence of active or passive movements of the affected parts of the body, the contents are discharged; the moist tissues are thus deprived of the protecting, imperspirable epidermis, and now begin to desiccate and gradually to shrink as a result of evaporation. Consequently, more or less thick, dried tissue layers (so-called crusts), dark bluish to blackish in color and of very firm, leathery consistency, develop upon the surface. These dry parts have a mummified appearance (hence, mummification).

Dry gangrene develops principally in parts of the body most distant from the heart, most frequently in the toes, and on further progress then advances in the direction toward the heart.

Moist gangrene occurs chiefly in the interior of the body, where evaporation is impossible. Retention of the moisture within the warm, dead parts favors decomposition of the organic substances under the action of micro-organisms — the so-called putrefactive bacteria. **Putrefaction** always begins so early and is so inseparable from moist gangrene that it has, in a measure, become a characteristic feature of moist gangrene. One should not, however, be misled to consider putrefaction the essential process in moist gangrene, for under all circumstances putrefaction always is a secondary phenomenon—a sequela; it can occur only where the tissues have already died. Putrefactive decomposition, which leads to complete destruction of dead tissues, is characterized by the discolored (frequently dirty green) appearance of

the parts and the sickening pungent, extremely repulsive odor. The latter is due to the formation of certain gases: ammonia, ammonium sulphide, and sulphureted hydrogen gases,[1] and to the formation of odoriferous organic substances, fatty acids, and valerianic acid. The stinking gases injure the neighboring parts, excite an irritative state, and favor further extension of the gangrenous process.

As a result of the formation of combustible carbureted hydrogen gas within the gangrenous tissue, smaller and larger cavities—an emphysema—are sometimes produced, which may render the tissue so porous that it acquires a resemblance to baked bread; this characterizes the form of gangrene known as emphysematous gangrene.[2] (See p. 570.)

Simple softening without odor: liquefaction, *colliquatio, e.g.*, the softening of caseated masses (caseous hepatization, caseous lymphatic glands, etc.), should be distinguished from humid gangrene. Simple softening develops by disintegration of dry albumin masses into an albuminous detritus as the result of absorption of water from surrounding parts.[3]

The gangrenous focus is either sharply circumscribed from the beginning: circumscribed gangrene, or it has no distinct line of demarkation and manifests a progressive, eroding character: diffuse gangrene. The latter also, after a time, may be arrested in its progress and become circumscribed. As soon as the gangrene becomes limited, the dead part is separated from the living tissues by a strong reactive inflammation (which always proceeds from the living parts, because the dead part is incapable of reaction), *i.e.*, by a dissecting suppuration, which results in the formation of a kind of cleft. If the dead tissue is superficial, as in typhoid (typhoid slough, sphacelus), dissection begins at the free surface and advances gradually toward the depth, and it may often be ended on the surface, while in the deeper parts open vessels still communicate with the sphacelus. If the slough is mechanicly separated in this stage, hemorrhages readily occur, because the vessel lumina have not yet become occluded by the

---

[1] Sulphureted hydrogen and ammonia cause a rapid solution of the red blood-corpuscles, and stain the blood green or brown to black (analogous to carbonization of wood: brown to black). The action of sulphureted hydrogen upon blood-pigment causes a bluish-gray, slaty coloration (microscopicly: blue granules).

[2] There is an epidemic disease of animals: symptomatic anthrax, "black leg," "quarter-evil" (*Rauschbrand, charbon symptomatique*), in which gas formation is always observed. This gas can be displaced by pressure with the production of a crackling sound.

[3] Simple softening may be due also to the action of solvent or digestive fluids, *e.g.*, in the production of gastric ulcer by the action of the gastric juice (digestive softening).

formation of thrombi. In slow, spontaneous separation of the sphacelus the danger of hemorrhage is almost always excluded.

Separation of the slough produces an ulcer (*ulcus gangrænosum*), which usually quickly becomes cleansed (*ulcus depuratum*), and, if the loss is not too great, readily cicatrizes. Whenever the dead part lies upon a serous membrane (as is frequent in the lungs), a spreading purulent or ichorous inflammation of the serous layer develops (*pleuritis ichorosa*).

In moist gangrene the process generally spreads peripherally and causes very extensive destruction, if the possibility of demarkation and exfoliation is not offered by proximity of a surface (*e.g.*, by expectoration[1] in pulmonary gangrene). In nonputrid gangrene, on the other hand, the sequestrum may be inclosed also within the body by the development of a connective-tissue capsule, or purulent channels develop which open externally and result in the formation of fistulæ.

According to the color are distinguished colorless (*e.g.*, of the bones) and black gangrene (*e.g.*, senile gangrene). The first occurs in anemic, the second in richly vascular, parts. So-called white or yellow gangrene develops in hydropsic subjects in the scrotum, the vulva, and the extremities; it begins as an erysipelatous process (often at points of scarification), then passes into diffuse phlegmonous infiltration, and, finally, leads to disintegration.

If the different forms of gangrene are viewed from an etiologic standpoint, certain groups result according to whether circulatory disturbances or external injurious influences predominate. In occlusion of the arteries by embolism (embolism of the popliteal artery causes gangrene of the foot; embolism of the femoral, gangrene of the foot which may involve the lower half of the leg; embolism of the lung, if the emboli are infectious: lobular gangrenous pneumonia); in severe arteriosclerosis and coexistent cardiac weakness from organic senile changes (*gangræna senilis*); in extreme congestion from incarceration and strangulation; in intense dropsy (white gangrene), and in persistent capillary anemia from pressure (pressure gangrene, decubitus) circulatory disturbances predominate; in gangrene from ergotin, the bite of poisonous serpents (enormous "pasty" swelling, marked hyperemia, and numerous ecchymoses), from cauterization (corrosion: acids, alkalies, metallic salts, etc.) intoxication predominates; in typhoid (in typhoid sphacelus) and diphtheria[2] (of mucous

[1] The expectorated fragments of necrotic lung tissue are histologicly so well preserved that their structure can be recognized microscopicly without difficulty. The elastic fibers appear to be least altered.

[2] Associated with stasis. This is not, however, the cause but only the result of the diphtheritic process.

membranes and wound surfaces: hospital gangrene); in anthrax, furuncle, carbuncle, noma,[1] or *cancer aquaticus, erysipelas gangrænosum,* phlegmonous processes, and in gangrenous disintegration of tumors (carcinoma), infection is the chief factor.[2]

Closely related to gangrene from caustic poisons are combustion (from fire, lightning, etc.) and congelation (freezing, frostbite), inasmuch as the tissues and vessels are simultaneously attacked by the external injurious influence. In *mal perforant du pied* and symmetric gangrene (of the hands, feet, ears, cheeks, nose) there probably is, in addition to pressure (*mal perforant:* gangrene at the point of pressure), disturbance of innervation, for in *mal perforant* the margins are anesthetic, and in some cases lesions of the nerves also have been observed, and in symmetric gangrene it is always tapering parts which are attacked, and, furthermore, those affected are almost always females whose vascular system reacts in an unusually strong manner to external influences (*e.g.,* cold, by local asphyxia). In this respect there is a certain similarity to ergot gangrene, inasmuch as *secale cornutum* also causes gangrene by spastic contraction of the smaller arteries. The connection of gangrene of the hands and feet with nervous disturbances is unquestionable in *lepra mutilans* associated with anesthesia, for in these cases a severe leprous neuritis has repeatedly been determined.

Symmetric Gangrene may occur as an independent process (Raynaud's disease) or in the course of various affections: tabes, syringomyelia, tumors of the spinal cord or nerve-roots; Basedow's disease, hysteria, epilepsy; in infectious diseases: typhoid fever, influenza.

Some authorities designate as **Raynaud's Disease** only the independent form of symmetric gangrene. This, however, is impracticable, for all three stadia of the pathologic process of this affection, namely: (*a*) syncope (regional ischemia), in which the fingers or toes respectively become waxy pale and cold; (*b*) local asphyxia (regional cyanosis) with blue to blackish discoloration of the parts, and (*c*) gangrene with final casting off of the parts (usually terminal phalanges of the fingers), can be produced also by tumors of the nerve-roots, while in many other cases the basis of the malady is obscure. The disease usually subsides after an attack of several months' duration, passing through the stages mentioned, though it may terminate before the third stage. Rarely other parts (tip of the nose, nates, ears) are affected.

Pharyngeal diphtheria is sometimes accompanied by an extensive putrid process. This is designated as gangrenous diphtheria. Diphtheria is of itself a mortifying gangrenous process, but the

[1] Noma starts from the oral mucosa of badly nourished children and spreads to the lips and cheeks; it occurs also in the female external genitalia.

[2] For further details regarding the different examples, see other parts of the text.

latter usually attacks only the surface of the mucous membrane (is superficial). Whenever the term gangrenous diphtheria is employed, it is intended to indicate that a phlegmonous—gangrenous—affection, which extends more or less in the depth, is added to the ordinary superficial diphtheria.

Gangrene of the lungs is always a moist gangrene. In the sputum are always found, in addition to elastic fibers, characteristic fatty acid crystals. Aside from infectious emboli, pulmonary gangrene is caused by aspiration of food particles (often in the insane, but also in other very ill persons who "mis-swallow"), by spreading putrid bronchitis, and by other processes attended by destruction and putrefaction which

Fig. 27.—Slightly curved fatty acid crystals. *a*, isolated; *b*, groups in characteristic arrangement. (Zeiss Apochr., 4; Comp. Ocul., 8. After *Langerhans.*)

extend to the trachea, bronchi, or the lung itself from without (*e.g.*, as a result of carcinoma of the esophagus).

Decubitus (pressure gangrene) always develops at prominent parts immediately over bone, most frequently over the sacrum, owing to dorsal posture assumed by the majority of seriously ill subjects. The first thing noted is an irritative state accompanied by hyperemia which follows anemia; then formation of vesicles occurs. Thus far these are simple friction phenomena which are observed also in chafing of the feet.

Hence, gangrene is not observable at this stage. As soon, however, as the epidermis is broken and the soft parts are deprived of the protecting epidermal covering, an infectious inflammatory process with destructive character develops which, because the tissues have already suffered from prolonged nutritive disturbances in consequence of the anemia (see p. 637), rapidly results in death of the tissues. Putrid

states immediately follow, which either progress more superficially: *decubitus superficialis,* or rapidly extend into the depth, sometimes to the bones or even into the true pelvis: *decubitus profundus.*

In gangrene of the aged, senile gangrene, the vessels are generally pervious (not occluded). A severe arteriosclerosis (with calcification of the media of the medium-sized and smaller arteries), however, is present, which, when cardiac weakness coexists, causes such marked slowing of the arterial blood-current that the nutrition of the tissues is greatly interfered with. As soon as these parts, which are markedly altered in nutrition, are subjected to any slight injury (contusion, pressure, cold, inflammation) which would produce scarcely any reaction in a healthy individual, gangrene at once develops. Sometimes the arterial blood-pressure is so weak that marantic thrombi form in the veins.

Senile gangrene, therefore, is a gangrene of weakness, debility, feebleness, which, like decubitus, always begins with irritation: fluxion, edematous swelling, pain, and vesicle formation.

Among those diseases which favor the occurrence of gangrene and, as it were, furnish a certain disposition are diabetes mellitus and scorbutus, the latter especially in the oral cavity.

PIGMENTATIONS.

The color of the tissues of the visible external, as well as of the invisible internal, organs depends upon three factors: 1, vascularity, *i.e.,* the filling of the vessels (color of the red blood-corpuscles); 2, the inherent color of the tissues (normal pigmentation, so far as they contain pigment[1]; the remaining tissues have a light-gray color), and, 3, abnormal pigmentation (pathologic pigmentation). Thus, during life the visible normal mucous membranes are bright red solely because of the great vascularity of their surface, while poorly vascular parts are more or less pale. For example, the cornea is colorless; hyaline cartilage is bluish gray-white; the epiglottis and inner lining of the aorta are yellowish, because beneath the mucosa and intima, respectively, there is a layer which is very rich in elastic fibers (reticulated cartilage of the epiglottis; elastic media of the aorta), and all parts which consist essentially of elastic material possess a yellowish hue. All highly vascular tissues which have no inherent color assume a light-gray or whitish-gray appearance when bloodless: *e.g.,* ordinary connective tissue, the lungs, etc. All other tissues with inherent color retain their charac-

[1] Pigment, from *pingere*: to color, paint.

teristic hue also in the bloodless state. To these belong: the skin,[1] the muscles, and the spleen (these have a natural reddish color), the liver (grayish brown), the suprarenals, ganglion cells, the choroid with iris, the pigmented epithelium of the retina, the arachnoid (yellowish to dark-brown pigment), and the hair.[2] Likewise, certain secretions (bile, urine, etc.) and the feces are, under normal conditions, always characterized by certain coloring matters.

All these natural colors are not only subject to marked individual variations, but they vary also in the same individual within quite wide limits, depending upon internal (disease, nutrition, etc.) and external influences (light, heat).

Certain anomalies, augmentations and diminutions or defects of the physiologic colorings, constitute the transition from these physiologic to the pathologic pigments. Here belong the leucodermias (leucoplakia) and the abnormally intense pigmentations. Both groups may be congenital or acquired.

Congenital pigment defects are represented by albinism; the acquired by chloasma album (vitiligo). Albinism is a disturbance of development, a partial pigment defect of the eyes,[3] often associated with pigment defects of the hair and skin.

Increase of pigmentation (excess) is congenital in the well-known birthmarks (vascular nevus, *nævus pigmentosus, melasma, nigrities partialis*), and acquired in chloasma of pregnant women, consumptives, in the pigmented scars of old ulcers of the leg, etc., and in freckles[4] (*ephelides*).

The true pathologic pigments are formed by the body under definite pathologic conditions. They are divided into two groups: one group comprises the **hematic pigments,** which reach the affected parts from the blood; the other originates *in loco* by transformation of pre-existing material: **metabolic pigments.** To the first group belong the blood-pigments in a strict sense, and the bile coloring matters; to the second belong the pigment of brown atrophy, of melanotic tumors, and that of the skin in Addison's disease (*melanosis*).

---

[1] The color of the skin (aside from the variable amount of blood) depends upon the pigment in the *stratum mucosum* of the epidermis. According to the variety of this pigment are distinguished the black, brown, yellow, and white races. In general, the color of the skin is found to be darker the nearer the equator is approached. The color of the skin is inherited.

[2] In Europe two races are distinguished according to the color of the hair: the blond and the brunette, and mixed forms.

[3] Owing to lack of pigment in the iris and choroid and to its relative or complete absence in the epithelial cells of the uvea, such eyes appear bright red, because the red color of the blood shows through.

[4] These develop as a result of hyperemic and not of hemorrhagic states.

In contradistinction to these true pathologic pigments formed by the tissue there are certain colored foreign bodies which enter the organism from without, and are partly taken up without consequent pathologic states (the ordinary lung pigment, the dyes employed in tattooing; argyria; blue line on the gums due to plumbism), and partly produce evident pathologic processes (pneumonokonioses: anthracosis, chalicosis, siderosis).

Hematogenous Pigments.

All blood-pigments are derived from the hemoglobin of the red blood-corpuscles. Wherever red blood-corpuscles are separated (by hemorrhage or thrombosis) from the circulation and altered, a partly light-yellow, diffuse, partly granular and clumped yellowish to yellow-brown, amorphous, partly crystalline blood-pigment is formed. The crystalline pigment is either somewhat needle-shaped, yellow-red to rust-brown in color or it forms distinct rhomboids of a ruby-red color: hematoidin (probably identic with bilirubin). The needle-shaped blood-pigments lie chiefly in groups or rosettes. All crystalline blood-pigments contain no iron, and are insoluble in water, acetic acid, ether, and alcohol; they are soluble in chloroform and are destroyed by concentrated mineral acids, in that the color changes, first becoming brown-red, then green, blue, violet, rose, and, finally, dirty yellow.[1]

The same changes in color are observed under similar conditions, also in noncrystalline blood-pigments, which contain iron and are encountered within as well as outside of cells. The granular, ferruginous blood coloring matter is designated as hemosiderin. The iron content, in contradistinction to the organic iron albuminate of the hemoglobin, may be demonstrated by microchemic reactions, in that addition of ammonium sulphide produces a black color, and treatment with potassium ferrocyanide and hydrochloric acid produces a blue color (Berlin blue reaction).

Both blood-pigments—the aferrous and the ferruginous—frequently coexist in extravasates.

The granular pigment often originates by shrinkage of the individual red blood-corpuscles to small pigment masses. From this granular pigment a blackish, aferrous, and likewise granular coloring matter (melanin) appears to be formed after a time, especially in old extravasates. Sometimes hemosiderin is transported through the agency

[1] In cutaneous hemorrhages, in blood-extravasated localities, sugillations, *e.g.*, from contusion, the extravasate spontaneously undergoes visible changes of color: red, blue, green, yellow, brownish.

of cells (wandering, migratory cells), so that the pigment appears at a point distantly removed from the place of its formation (blood-pigment metastasis).

Localities in which blood-pigments are present in the organs in more or less large amount are readily recognized with the naked eye by the light-yellow to dark-brown color. Large accumulations of pigment imply, of course, large antecedent extravasates. Such large extravasates accompanied by pigmentation occur upon the inner surface of the dura in internal hemorrhagic pachymeningitis, and in *hæmatoma duræ matris* resulting therefrom; upon the surface of the brain in trauma (fresh: *encephalomalacia rubra corticalis;* older, as pigmented cicatrices, *plaques jaunes* of the French), especially on the under surface of the frontal and temporal lobes; in the interior of the brain in spontaneous hemorrhages (*apoplexia sanguinea*), especially in the region of the large ganglia; in hemorrhages into the joints; in all large extravasates into soft parts of the body; in hemorrhagic inflammation of serous membranes, the kidneys, etc.

Disintegration of the erythrocytes and transformation of the hemoglobin occur not only when the red blood-corpuscles escape from the circulation, but destruction of the red blood-corpuscles may, under various conditions, take place also in the circulating blood. This is the case under the influence of various poisons which destroy the red blood-corpuscles and cause the hemoglobin to enter the blood-plasma. To these poisons belong arseniureted hydrogen and morel poison (helvella). In these poisonings hemoglobinemia is first produced, and then, the hemoglobin being excreted by the kidneys, hemoglobinuria. In this process numerous precipitates of brown-colored masses—so-called hemoglobin infarcts—are formed in the renal tubules. The same changes are observed also in extensive burns of the skin.

Disintegration of red blood-corpuscles and formation of pigment in the circulating blood occur also in intermittent (malarial) fever. The pigment is blackish in color (called melanin) and is aferrous. It develops as a result of the action of the hemamebæ (malaria plasmodia, *q.v.*), which enter the red blood-corpuscles and destroy them. In severe cases brown, ferruginous hemosiderin also is found. These masses of pigment can be found in almost all organs, and in the severest cases of black-water fever impart to most of the organs a brownish to dark-brown appearance.

In various organs, particularly in the liver, spleen, and bone-marrow, next in the kidneys and pancreas, a more or less intense deposit of yellowish, ferruginous coloring matter: siderosis (*hemosiderin*), is sometimes observed. Quincke, who first drew attention to the occur-

rence of iron in these organs, attributes these iron deposits to old, disintegrating red blood-corpuscles. To a slight degree this process is supposed to be physiologic, yellow hemosiderin and a colorless iron albuminate being formed from the red blood-corpuscles. In markedly increased disintegration and reduced formation of red blood-corpuscles—as in the severe forms of anemia—the accumulation of ferruginous particles is so marked, especially in the liver, that the siderosis can be recognized with the unaided eye and without microchemic reaction by the light rust-brown color.

Through the action of the sulphureted hydrogen, present in the colon, upon adjacent parts of the liver and spleen, a circumscribed, dark, slaty coloration is often observed in these organs. This cadaveric "pseudomelanosis" is due to the formation of iron sulphide from the hemosiderin present in the parts.

In the same manner, a slaty to blackish coloration (*enteritis pigmentosa*) develops in the intestine—in the ileum as well as in the colon—when chronic catarrhs associated with hyperemia existed during life (rarer as a result of passive hyperemia), the hemosiderin deposited at these points during life being transformed into iron sulphide by the action of sulphureted hydrogen.

In 1889 von Recklinghausen drew attention to the pigmentation designated by him as **hemochromatosis.** In this process there is observed, first, a brownish pigmentation of various organs (liver, lymph-glands, adipose tissue, vessel-sheaths, serous membranes) by hemosiderin, and, second, an aferrous coloring matter, called by von Recklinghausen *hemofuchsin,* which is found chiefly in the smooth musculature of the gastrointestinal canal, most frequently in the longitudinal layer of the jejunum (particularly in tipplers). Von Recklinghausen demonstrated the coexistence of both pigments (hemosiderin and hemofuchsin), and to designate this he introduced the term hemochromatosis. Hemofuchsin is distinguished from other blood coloring matter by the fact that it forms glistening, yellowish-brown granules or spherules which are readily extracted by alcohol. Apparently, it is a coloring matter combined with fat.

With these blood-pigments in a strict sense are to be classed several other coloring matters. Here belong the so-called lipochromes, coloring matters the origin, composition, and significance of which are little known, which, combined with fat in the interior of fat-cells, occur inside the corpora lutea as so-called lutein, and in ganglion cells.

In **ochronosis**[1] (Virchow) there is a uniform, diffuse, dark-

[1] ωχρος = yellow.

yellowish, brownish to blackish coloration of the intercellular substance of all cartilages, especially of the costal and bronchial cartilages; further, of the tendinous insertions, ligaments, lymph-glands, and vessel intima, especially within arteriosclerotic parts. This pigmentation is to be distinguished from the very much rarer, granular, rust-brown pigment of the cartilage cells themselves. In very marked degrees of ochronosis the cartilages (*e.g.*, the intervertebral disks) are totally black.

Icterus[1] develops as the result of absorption of bile coloring matters (bilirubin, etc.) by the blood and the deposition of them in the tissues (they appear also in the secretions and excretions). It is always first apparent in the liver as diffuse or granular pigment. The cause is most frequently mechanic obstruction to discharge of the bile. Bilirubin (like the diffuse blood-pigment) generally uniformly infiltrates the tissues as dissolved coloring matter. The deposition of fine, yellow-red, needle-shaped bilirubin crystals is rarely observed, most frequently in the kidneys of the newborn with *icterus neonatorum*. Here they may fill the straight renal tubules and form so-called bilirubin infarcts (Orth). Chemicly, bilirubin behaves like hematoidin; therefore, it is assumed that it also is formed from hematin by splitting-off of iron. On addition of sulphuric acid it gives the same color reactions as hematoidin.

Icterus may occur without obstruction to the outflow of bile. The liver-cells are surrounded by blood-capillaries, from which they receive the material for the elaboration of bile. In this region of exchange between the liver-cells and the blood lies the cause of this form of icterus. Poisons may so act upon the hepatic cells that the bile formed by the latter is not discharged into the biliary channels, but into the blood (toxic icterus). The icterus occurring in infections and septic processes also must be explained in this manner. This discharge of bile in a false direction, *i.e.*, into the blood, is called diffusion icterus, parapedesis, paracholia. If for any reason (*e.g.*, the liberation of abundant hemoglobin as the result of destruction of numerous red blood-corpuscles in the blood, absorption of large hemorrhagic exudates) too much material for the elaboration of bile is at one time supplied to the cells, the latter produce more bile (hypercholia) containing a great amount of coloring matter (pleiochromatic bile); often the cells cannot discharge all the bile in the usual manner through the biliary channels, and, as they are unable to retain it (acathectic icterus), part must be discharged into the blood (*icterus pleiochromicus*).

The bile coloring matters which have entered the tissues are excreted through the kidneys. Therefore, in icteric cadavers more or less bile coloring matter is always found within the renal epithelia, especially in the convoluted tubules, and, as a rule, most abundant in those epithelia which present more or less marked organic changes, particularly cloudy

[1] The biliary acids also enter the blood.

swelling. If, as usually is the case, hyaline tube-casts also are present, these are strikingly bright and palely stained.

Every icterus is visible first in the liver; hence, at necropsy, icterus confined to the liver is frequently observed. If the bile coloring matter has extended farther into the body, the biliary staining is usually best recognized in the conjunctiva and the intima of the vessels. On the other hand, the brain of adults is never icteric; icteric (yellow) staining of parts still free of or poor in myelin occurs only in the newborn.

Icterus in valvular lesions, in pyemia, and in *icterus neonatorum* is considered by many (in contradistinction to ordinary hepatogenous icterus) as hematogenous icterus, caused by rapid disintegration of red blood-corpuscles, though this view is actively combated by others.

Icterus neonatorum has thus far not been satisfactorily explained. It is not due to obstruction in the bile-ducts. Oestreich suggests that it may be the result of digestive processes occurring in the gastrointestinal canal immediately after birth (particularly bacterial and putrefactive processes), and of introduction of new foreign substances through the portal vein into the liver. Here the process is a kind of toxic action upon the liver-cells (toxic icterus), to which, however, the cells soon become accustomed. In icterus neonatorum bile is present in the blood and is excreted through the kidneys, where it stains the uric acid infarcts occurring in the straight renal tubules, the apices of the pyramids, reddish or golden yellow.

As a result of congestion of the bile, deeply bile-stained, partly golden-yellow, partly green, homogeneous concretions are often found in the bile-capillaries as small, quite highly refractive, sausage- and cylindric shaped, partly branched bodies. In long-continued and severe cases of icterus bilirubin is transformed into biliverdin; chronic green icterus, *icterus viridis,* is thus produced.

Metabolic Pigments.

The physiologic analogue of the pathologic, metabolic pigments is furnished by the normal pigments of the skin (yellow to brown), the choroid (brown), and of the epithelium of the retina (black). Here the pigment is united with special cells (pigment-cells). The pigment content of the skin depends upon individual (blond and brunette) and racial peculiarities, may vary within wide limits in one and the same individual, is generally markedly increased in summer upon exposed parts, especially under direct action of air and the rays of the sun, and disappears in winter. Therefore, it is dependent to a great degree upon external influences. It is always more pronounced in certain portions of the body (areola of the nipple, vulva, scrotum) than in others; under certain conditions it is very markedly increased in some localities without

being pathologic, *e.g.*, in normal pregnancy in the vicinity of the nipple areolæ and the linea alba.

In pathologic metabolic pigmentation there is either increase—excess—of the otherwise normal pigmentation or appearance of pigment in localities and cells which, under normal conditions, form no pigment. To the first group belong the often very intense and, therefore, marked pigmentation of the skin during pregnancy (*chloasma uterinum*); summer freckles (*lentigo æstiva, ephelides*), which, as the name indicates, occur chiefly in summer, but in certain individuals do not disappear in winter; congenital pigment marks (*nævi*) and pigmented warts.

In **Addison's disease** (*morbus Addisonii*) the skin, owing to increase of the cutaneous pigment, acquires a brownish to brownish-gray, bronzed hue (bronzed skin), especially in localities which normally are highly pigmented. The pigment is located partly in the form of granules in the deepest epithelial layer, partly within wandering corpuscles (chromatophores), partly within the branched connective-tissue cells immediately beneath the epithelium. Pigment is found also in the adventitia of the vessels of the cutis, where, under normal conditions, no pigment exists. In higher degrees and in cases of long duration, pigment maculæ similar to those of the external skin occur also in the oral mucous membrane. On the other hand, cases of bronze disease occur in which distinct pigment defects are recognizable.

The pigment (melanin) in pigmented—melanotic—tumors, which so often develop from pigmented nevi, moles, and pigmented warts, is an aferrous, sulphur-containing coloring matter of yellowish, brownish to blackish hue, which is formed within the tumor-cells in irregular, smaller and larger granules and clumps. As this pigment is aferrous and contains sulphur, the consensus of opinion is, that it is not derived directly from the blood; at least, it must be assumed that the cells are especially active in the formation of the pigment from the coloring matter of the blood. That, in spite of this, there is a certain dependence upon the blood, appears from the fact that often the most intense pigmentations are found in the immediate vicinity of the vessels. Melanuria is sometimes present in individuals suffering from melanotic tumors.

A number of organs possess pigment, but usually to only a slight degree: *e.g.*, the heart, liver, testes, suprarenals. In advanced age this pigment always increases in amount and, as at the same time there is diminished function, the increased pigmentation is attributed to retrograde changes in the cells. This pigment is amorphous, granular, or in clumps; sometimes yellow, sometimes brown; occasionally, when severe general and more chronic nutritive disturbances exist, and also in youth-

ful individuals, it occurs in such abundance that the affected organs have a more or less distinct brown color: *degeneratio fusca.* If, at the same time, distinct signs of atrophy (diminution from nutritive disturbances) are present, as is frequently the case, the condition is designated as brown atrophy of the affected organs (liver, heart, etc.). In the heart this aferrous pigment is deposited chiefly at both poles of the muscle nucleus, and there forms small clumps which often have the form of equilateral triangles. Within the liver-cells the quite dark brown pigment usually forms smaller and larger clumps in the region of the nucleus.

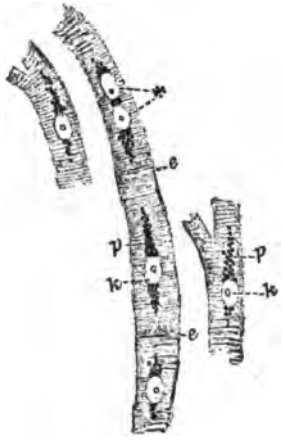

Fig. 28.—Brown atrophy of the heart. *k,* nuclei; at * two nuclei in one cell; *e,* Eberth's cement lines; *p,* clusters of granular, brown pigment at both poles of the nuclei. (Zeiss Apochr., 4; Comp. Ocul., 4. After *Langerhans.*)

In all these pigments still unknown material is transformed (metabolicly) into coloring matter by the vital activity of the cells and accumulated in the cells.

Foreign Pigments.

The ordinary black pigment of the lungs is inhaled vegetable carbon (smoke, soot). This is looked upon as physiologic, since it occurs everywhere in the lungs without causing demonstrable injurious effects. The lungs of domestic animals also contain the same pigment. The black pigment of the lungs is generally quite rapidly transported to the bronchial glands, and, when vascularized adhesions exist between the pleuræ, also to the costal pleura. Transportation occurs by way of the lymph-channels.

The lungs of coalminers and other mine workers frequently contain such an abundance of physiologic pigment that the whole lung assumes a more or less intense black color: anthracosis. In stonecutters quartz fragments enter the lungs as dust and are deposited in the same localities as ordinary black pigment of the lungs: chalicosis. The deposition of red iron oxide in factory workers is much rarer: *siderosis pulmonum.*

In these three processes—the pneumokonioses—the whole lung-tissue gradually becomes indurated.

Aside from the bronchial glands, all these pigmented foreign bodies are deposited chiefly and, at first, almost solely in the true connective

tissue, *i.e.*, in the neighborhood of the bronchi, in the vessel-sheaths, in the pleura, and in the connective tissue which unites the individual lobuli.

Black pulmonary pigment is sometimes especially abundant in slaty indurations of the lungs resulting from chronic inflammatory processes (*phthisis indurativa pigmentosa*): black phthisis. This is probably due partly to the fact that the lymph-channels are obliterated and the pigment, therefore, cannot enter the bronchial glands. All black pigment within slaty indurations of the lung consists of carbon. Under certain conditions, in absorption processes, *e.g.*, in alveolar emphysema, the pigment enters the circulation and is then deposited in other organs: liver (principally within Glisson's capsule), spleen (especially in the follicles), and kidneys.

In agyria, resulting from continued therapeutic use of silver nitrate, precipitates of silver occur in minutest, punctiform distribution in various parts of the body, *e.g.*, in the rete Malpighii and the stratum mucosum of the epidermis, in the sweat-glands, glomeruli, tunica propria of the renal tubules, etc. (Compare Metastases, p. 94.)

In tattooing, pigments (carmine, carbon, etc.) are rubbed into the skin through fine punctures. Part of these pigments remain *in loco;* another portion enters the lymph-channels, is transported to the nearest lymph-glands, and there deposited near the hilus.

In chronic lead poisoning through the gastrointestinal canal, the so-called "blue line" (lead line, gingival line) develops upon the gums—a bluish-black coloration of the gums at the junction with the teeth. This is due to deposition of minute particles of lead sulphide beneath the epithelium in the neighborhood of the vessels. (For blood changes, see p. 326.)

DEGENERATION.

Degeneration is always a passive process in which the elements, although preserved, are in a state of diminished function. The changes are first of a chemic nature, but morphologic alterations also soon become manifest. Diminution in function always conveys the conception of transformation into an inferior tissue. Calcareous, amyloid, hyaline, waxy, colloid, mucous, albuminous, and fatty degenerations are distinguished. In the four first forms the persisting tissues become firmer, denser, and more resistant to reagents.

Calcareous degeneration, or **calcification,** is exemplified by petrification (infiltration of silicic acid with preservation of structure), and originates by separation of lime-salts from the blood and deposition of minute granules of carbonate and phosphate of lime in the tissues

(infiltration, incrustation). In deposition of large amounts, the individual granules usually coalesce to form a homogeneous, glass-like mass.

Three varieties of calcareous deposits must be differentiated:—

1. Petrification: In this process stony masses, consisting either of lime-salts (calcification) or urates (gout), are deposited in the tissues.
2. Ossification: This is an active metaplastic process which results in the formation of true osseous tissue (with bone-corpuscles).
3. Lithiasis: True stone formation within cavities and ducts. This has nothing to do with the tissue: gall-stones, urinary calculi, fecal calculi, salivary calculi, prostatic calculi.[1]

Calcification (petrification, or calcification, in a strict sense) is either an atrophic, retrogressive process—*e.g.*, in calcareous deposition in the cartilages of elderly people and in calcification of the aorta and arteries in arteriosclerosis—or simple calcification of dead masses. These may belong partly to the body, as, for example, lithopedion (the dead and calcified ectopic fetus), or be introduced partly from without (*e.g.*, dead entozoa: cysticerci, echinococci, trichinæ, pentastomum). To petrification of dead masses belong also the calculi originating from calcification of organic substances (*e.g.*, pathologic caseous material): pulmonary calculi[2] (calcified caseous masses in ectatic bronchi or in ulcerated lung cavities) and vein-stones (phleboliths, calcified thrombi).

In calcification, lime-salts in solution infiltrate those parts which become the site of the lime-salts and are there deposited by conversion from the liquid into the solid state. The combinations thus formed are generally phosphate and carbonate of lime, frequently combined with salts of magnesia. These lime-salts can readily be dissolved by mineral acids; in the solution of carbonate of lime active liberation of gas occurs: carbonic acid. Under the action of sulphuric acid calcium sulphate—the well-known gypsum crystals—is produced.

Ossification is always preceded by alteration of the tissues, in which either an increase of the cells occurs or the intercellular substance becomes denser and more homogeneous: cartilaginification.

In cartilage (of the ribs, larynx, trachea, bronchi, etc.) and arteries petrification as well as ossification occur. Calcification of cartilage, which is of such frequent occurrence in advanced age in the so-called permanent cartilages (costal cartilages, etc.), has its physiologic analogue in

[1] For description of the various calculi, see the sections dealing with the organs affected.

[2] These are sometimes expectorated.

the zone of preliminary calcification of growing tubular bone. It begins with deposition of lime-salts in the capsules of the cartilage cells, and, after these are filled, incrustation of the true (remaining) intercellular substance takes place. When the lime-salts are dissolved, the old cartilage (but not, however, decalcified bone-tissue) reappears.

Ossification of permanent cartilages is quite frequently observed in the larynx and trachea, seldomer in the costal cartilages, in old age and sometimes also in earlier life, particularly when marked obesity or catarrhal affections of the respiratory passages coexist.

In petrification it is of decided significance for the vital function whether the lime-salts are located in the intercellular substance or in the cells themselves. Calcified cells represent dead, functionless, and consequently useless parts. In calcification of the basement substance, on the other hand, the affected parts are not

Fig. 29.—Pulmonary calculus, natural size.
(After *Langerhans.*)

to be regarded as dead; so long as the cells live, nutrition of the parts continues; in many cases only the function is more or less disturbed.

Calcification of cells, however, always presupposes their previous death, since living cells never calcify. Hence, ganglion cells of the cerebral cortex, which, after trauma (blow, fall, etc.), are so often found calcified at the point of strongest violence, are dead before they become the site of deposit of lime-salts. If the trauma was sufficient to cause hemorrhagic destruction of the cerebral cortex and, later, to produce pigmented cicatrices upon the surface, the at first granular, later more homogeneously calcified, ganglion cells and their processes (the region of the nucleus is usually free of lime-salts) will be found in the periphery of the brown-pigmented cicatrices.

In calcification of the fiber-cells of the crystalline lens (in white cataract with chalky appearance) these also die before calcification. The same holds good also for the epidermoidal cells, which, when they coalesce during calcification, form a kind of sand; for the adipose-tissue cells in fat-tissue necrosis, and for the musculature—the striated muscle, *e.g.*, of the heart, as well as, and more frequently, the smooth muscle, particularly in advanced age.

In the medium-sized and smaller arteries it is chiefly and quite often the media which calcifies, the individual muscle-fibers first becoming filled with lime-salts. In this stage the calcified spindle-shaped elements can generally be recognized by the naked eye as very minute striæ (fresh: yellowish; dried: white). The greater the number of calcified cells, the less distinct the striation and the more rigid the arterial tube. Finally, the adjacent dead lime-spindles coalesce to form a uniform lime-plate, lime-salts being deposited also upon the surface of the spindles.

In calcification of large arterial trunks: aorta, carotids, iliacs, etc., the site of the lime-salts is not the predominant elastic media, but the intima. Here, besides ordinary petrification, ossification also occurs within the arteriosclerotic areas. The bone-corpuscles, however, are very seldom so well developed as in ordinary bone; as a rule, they are very small, slightly serrated, somewhat scanty, and difficult to recognize. Petrification is generally preceded by a more or less homogeneous, hyaline metamorphosis of the basement substance. This is the case in calcification of old adhesions of serous surfaces, of fibrous callosities of the muscles, as a result of which the so-called "exercise" and "riders'" bones (*myositis ossificans*) are produced; of contracting cicatricial connective tissue in the region of foreign bodies, parasites, and dead tissue (fibrous capsules).

Psammomata, sand tumors, and the closely allied psammosarcomata and psammocarcinomata occupy a position intermediate to both the preceding groups—*i.e.*, between calcification of the cells and calcification of the intercellular substance—in so far as calcification of the cells as well as of hyaline degenerated intercellular substance and hyaline degenerated vessels, respectively, occurs. In the first case (psammomata) the so-called sand granules are chiefly round, and, like the physiologic brain sand of the pineal gland, are concentricly lamellated; in the second case they form irregular spicula, needles, and rods, and are also partly lamellated.

In fibromyomata of the uterus, so-called uterus-stones—*calculi uterini*—are formed after previous homogeneous metamorphosis of the connective tissue through calcification, which usually involves also the smooth muscle-cells. On maceration these stony formations, which sometimes reach the size of a child's head, yield a friable mass; they are not, therefore, true stones, but calcified tumors which have grown from the uterine wall.

Homogeneous calcification, which partly involves the vessels, partly the elastic fibers and the homogeneous basement substance of the lung tissue, is sometimes observed in the lungs. Usually the cause is unknown; the tissue, however, is not dead. In some cases this calcifica-

tion is due to sudden surcharging of the body with lime-salts as a result of excessive absorption of lime-salts and synchronous retardation of excretion through the kidneys (lime metastasis). The same holds good also for the occurrence of lime in the stroma of the stomach.

In the kidneys lime may occur as so-called lime-infarcts in three different localities: first, in granular form within the tunica propria of the collecting tubules of the pyramids, especially after antecedent catarrhal papillary nephritis; second, as solid cylinders, with roughened surfaces, in the lumina of the straight and convoluted tubules, and, third, in corrosive sublimate poisoning as incrustation of the epithelia injured and rapidly killed by the intoxication.

In **gout**[1] there is excessive formation of uric acid and defective excretion through the kidneys and skin. Consequently, there is, in a measure, overloading of the blood with uric acid,[2] or at least a distinctly demonstrable increase of the uric acid content and a deposition—localization—of urates in the internal organs, especially in the intercellular substance of poorly vascularized parts: in the hyaline articular cartilages, in the capsular ligament and the articular ligaments, the tendons and tendon-sheaths, the synovialis, and in the perichondrium (after the manner of infiltration). In this way are produced irregular, friable protuberances with mortar-like contents, *e.g.*, upon the ear and in the region of the joints: tophi.[3] Acid sodium urate crystallizes in rhombic plates which sometimes are so fine that they appear like minute spicula. Why large amounts of uric acid instead of urea are formed is unknown. The infiltration of uric acid salts into the joints is always preceded by a "gouty attack"—an *arthritis urica*—an inflammatory irritation of the joint accompanied by redness of the synovialis and slight increase of the synovia. Chronic *nephritis urica* is not the result of uric acid infarcts, for it exists also in the absence of uric acid infarcts. The *irritamentum* is rather the overloading of the blood with uric acid or the result of disturbance in metabolism.

In **lithiasis** (cholelithiasis, coprolithiasis, urinary calculi, salivary calculi, prostatic calculi)—*i.e.*, true stone formation—stones form in the body cavities and ducts lined with epithelium. The substances of which the stones are composed vary according to the locality in which they occur. They usually develop by separation of insoluble compounds from the secretions and excretions of the body, and union with lime-

---

[1] Gout is derived from *gutta*, a drop.

[2] The excessive amount of uric acid in the blood and the deposition of urates in various localities have given rise to the designation "uric acid diathesis."

[3] Tophi of the aural cartilage are small, pinhead- to pea- sized, quite firm swellings in the upper portion of the aural cartilage, especially the upper portion of the groove of the helix.

rence of iron in these organs, attributes these iron deposits to old, disintegrating red blood-corpuscles. To a slight degree this process is supposed to be physiologic, yellow hemosiderin and a colorless iron albuminate being formed from the red blood-corpuscles. In markedly increased disintegration and reduced formation of red blood-corpuscles—as in the severe forms of anemia—the accumulation of ferruginous particles is so marked, especially in the liver, that the siderosis can be recognized with the unaided eye and without microchemic reaction by the light rust-brown color.

Through the action of the sulphureted hydrogen, present in the colon, upon adjacent parts of the liver and spleen, a circumscribed, dark, slaty coloration is often observed in these organs. This cadaveric "pseudomelanosis" is due to the formation of iron sulphide from the hemosiderin present in the parts.

In the same manner, a slaty to blackish coloration (*enteritis pigmentosa*) develops in the intestine—in the ileum as well as in the colon—when chronic catarrhs associated with hyperemia existed during life (rarer as a result of passive hyperemia), the hemosiderin deposited at these points during life being transformed into iron sulphide by the action of sulphureted hydrogen.

In 1889 von Recklinghausen drew attention to the pigmentation designated by him as **hemochromatosis.** In this process there is observed, first, a brownish pigmentation of various organs (liver, lymph-glands, adipose tissue, vessel-sheaths, serous membranes) by hemosiderin, and, second, an aferrous coloring matter, called by von Recklinghausen *hemofuchsin,* which is found chiefly in the smooth musculature of the gastrointestinal canal, most frequently in the longitudinal layer of the jejunum (particularly in tipplers). Von Recklinghausen demonstrated the coexistence of both pigments (hemosiderin and hemofuchsin), and to designate this he introduced the term hemochromatosis. Hemofuchsin is distinguished from other blood coloring matter by the fact that it forms glistening, yellowish-brown granules or spherules which are readily extracted by alcohol. Apparently, it is a coloring matter combined with fat.

With these blood-pigments in a strict sense are to be classed several other coloring matters. Here belong the so-called lipochromes, coloring matters the origin, composition, and significance of which are little known, which, combined with fat in the interior of fat-cells, occur inside the corpora lutea as so-called lutein, and in ganglion cells.

In **ochronosis**[1] (Virchow) there is a uniform, diffuse, dark-

[1] ωχρος = yellow.

yellowish, brownish to blackish coloration of the intercellular substance of all cartilages, especially of the costal and bronchial cartilages; further, of the tendinous insertions, ligaments, lymph-glands, and vessel intima, especially within arteriosclerotic parts. This pigmentation is to be distinguished from the very much rarer, granular, rust-brown pigment of the cartilage cells themselves. In very marked degrees of ochronosis the cartilages (*e.g.*, the intervertebral disks) are totally black.

Icterus[1] develops as the result of absorption of bile coloring matters (bilirubin, etc.) by the blood and the deposition of them in the tissues (they appear also in the secretions and excretions). It is always first apparent in the liver as diffuse or granular pigment. The cause is most frequently mechanic obstruction to discharge of the bile. Bilirubin (like the diffuse blood-pigment) generally uniformly infiltrates the tissues as dissolved coloring matter. The deposition of fine, yellow-red, needle-shaped bilirubin crystals is rarely observed, most frequently in the kidneys of the newborn with *icterus neonatorum*. Here they may fill the straight renal tubules and form so-called bilirubin infarcts (Orth). Chemicly, bilirubin behaves like hematoidin; therefore, it is assumed that it also is formed from hematin by splitting-off of iron. On addition of sulphuric acid it gives the same color reactions as hematoidin.

Icterus may occur without obstruction to the outflow of bile. The liver-cells are surrounded by blood-capillaries, from which they receive the material for the elaboration of bile. In this region of exchange between the liver-cells and the blood lies the cause of this form of icterus. Poisons may so act upon the hepatic cells that the bile formed by the latter is not discharged into the biliary channels, but into the blood (toxic icterus). The icterus occurring in infections and septic processes also must be explained in this manner. This discharge of bile in a false direction, *i.e.*, into the blood, is called diffusion icterus, parapedesis, paracholia. If for any reason (*e.g.*, the liberation of abundant hemoglobin as the result of destruction of numerous red blood-corpuscles in the blood, absorption of large hemorrhagic exudates) too much material for the elaboration of bile is at one time supplied to the cells, the latter produce more bile (hypercholia) containing a great amount of coloring matter (pleiochromatic bile); often the cells cannot discharge all the bile in the usual manner through the biliary channels, and, as they are unable to retain it (acathectic icterus), part must be discharged into the blood (*icterus pleiochromicus*).

The bile coloring matters which have entered the tissues are excreted through the kidneys. Therefore, in icteric cadavers more or less bile coloring matter is always found within the renal epithelia, especially in the convoluted tubules, and, as a rule, most abundant in those epithelia which present more or less marked organic changes, particularly cloudy

[1] The biliary acids also enter the blood.

swelling. If, as usually is the case, hyaline tube-casts also are present, these are strikingly bright and palely stained.

Every icterus is visible first in the liver; hence, at necropsy, icterus confined to the liver is frequently observed. If the bile coloring matter has extended farther into the body, the biliary staining is usually best recognized in the conjunctiva and the intima of the vessels. On the other hand, the brain of adults is never icteric; icteric (yellow) staining of parts still free of or poor in myelin occurs only in the newborn.

Icterus in valvular lesions, in pyemia, and in *icterus neonatorum* is considered by many (in contradistinction to ordinary hepatogenous icterus) as hematogenous icterus, caused by rapid disintegration of red blood-corpuscles, though this view is actively combated by others.

Icterus neonatorum has thus far not been satisfactorily explained. It is not due to obstruction in the bile-ducts. Oestreich suggests that it may be the result of digestive processes occurring in the gastrointestinal canal immediately after birth (particularly bacterial and putrefactive processes), and of introduction of new foreign substances through the portal vein into the liver. Here the process is a kind of toxic action upon the liver-cells (toxic icterus), to which, however, the cells soon become accustomed. In icterus neonatorum bile is present in the blood and is excreted through the kidneys, where it stains the uric acid infarcts occurring in the straight renal tubules, the apices of the pyramids, reddish or golden yellow.

As a result of congestion of the bile, deeply bile-stained, partly golden-yellow, partly green, homogeneous concretions are often found in the bile-capillaries as small, quite highly refractive, sausage- and cylindric shaped, partly branched bodies. In long-continued and severe cases of icterus bilirubin is transformed into biliverdin; chronic green icterus, *icterus viridis,* is thus produced.

Metabolic Pigments.

The physiologic analogue of the pathologic, metabolic pigments is furnished by the normal pigments of the skin (yellow to brown), the choroid (brown), and of the epithelium of the retina (black). Here the pigment is united with special cells (pigment-cells). The pigment content of the skin depends upon individual (blond and brunette) and racial peculiarities, may vary within wide limits in one and the same individual, is generally markedly increased in summer upon exposed parts, especially under direct action of air and the rays of the sun, and disappears in winter. Therefore, it is dependent to a great degree upon external influences. It is always more pronounced in certain portions of the body (areola of the nipple, vulva, scrotum) than in others; under certain conditions it is very markedly increased in some localities without

being pathologic, *e.g.*, in normal pregnancy in the vicinity of the nipple areolæ and the linea alba.

In pathologic metabolic pigmentation there is either increase—excess—of the otherwise normal pigmentation or appearance of pigment in localities and cells which, under normal conditions, form no pigment. To the first group belong the often very intense and, therefore, marked pigmentation of the skin during pregnancy (*chloasma uterinum*); summer freckles (*lentigo æstiva, ephelides*), which, as the name indicates, occur chiefly in summer, but in certain individuals do not disappear in winter; congenital pigment marks (*nævi*) and pigmented warts.

In **Addison's disease** (*morbus Addisonii*) the skin, owing to increase of the cutaneous pigment, acquires a brownish to brownish-gray, bronzed hue (bronzed skin), especially in localities which normally are highly pigmented. The pigment is located partly in the form of granules in the deepest epithelial layer, partly within wandering corpuscles (chromatophores), partly within the branched connective-tissue cells immediately beneath the epithelium. Pigment is found also in the adventitia of the vessels of the cutis, where, under normal conditions, no pigment exists. In higher degrees and in cases of long duration, pigment maculæ similar to those of the external skin occur also in the oral mucous membrane. On the other hand, cases of bronze disease occur in which distinct pigment defects are recognizable.

The pigment (melanin) in pigmented—melanotic—tumors, which so often develop from pigmented nevi, moles, and pigmented warts, is an aferrous, sulphur-containing coloring matter of yellowish, brownish to blackish hue, which is formed within the tumor-cells in irregular, smaller and larger granules and clumps. As this pigment is aferrous and contains sulphur, the consensus of opinion is, that it is not derived directly from the blood; at least, it must be assumed that the cells are especially active in the formation of the pigment from the coloring matter of the blood. That, in spite of this, there is a certain dependence upon the blood, appears from the fact that often the most intense pigmentations are found in the immediate vicinity of the vessels. Melanuria is sometimes present in individuals suffering from melanotic tumors.

A number of organs possess pigment, but usually to only a slight degree: *e.g.*, the heart, liver, testes, suprarenals. In advanced age this pigment always increases in amount and, as at the same time there is diminished function, the increased pigmentation is attributed to retrograde changes in the cells. This pigment is amorphous, granular, or in clumps; sometimes yellow, sometimes brown; occasionally, when severe general and more chronic nutritive disturbances exist, and also in youth-

ful individuals, it occurs in such abundance that the affected organs have a more or less distinct brown color: *degeneratio fusca.* If, at the same time, distinct signs of atrophy (diminution from nutritive disturbances) are present, as is frequently the case, the condition is designated as brown atrophy of the affected organs (liver, heart, etc.). In the heart this aferrous pigment is deposited chiefly at both poles of the muscle nucleus, and there forms small clumps which often have the form of equilateral triangles. Within the liver-cells the quite dark brown pigment usually forms smaller and larger clumps in the region of the nucleus.

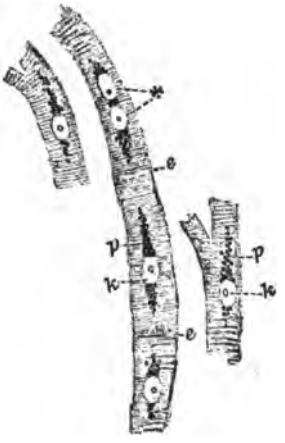

Fig. 28.—Brown atrophy of the heart. *k,* nuclei; at * two nuclei in one cell; *e,* Eberth's cement lines; *p,* clusters of granular, brown pigment at both poles of the nuclei. (Zeiss Apochr., 4; Comp. Ocul., 4. After *Langerhans.*)

In all these pigments still unknown material is transformed (metabolicly) into coloring matter by the vital activity of the cells and accumulated in the cells.

Foreign Pigments.

The ordinary black pigment of the lungs is inhaled vegetable carbon (smoke, soot). This is looked upon as physiologic, since it occurs everywhere in the lungs without causing demonstrable injurious effects. The lungs of domestic animals also contain the same pigment. The black pigment of the lungs is generally quite rapidly transported to the bronchial glands, and, when vascularized adhesions exist between the pleuræ, also to the costal pleura. Transportation occurs by way of the lymph-channels.

The lungs of coalminers and other mine workers frequently contain such an abundance of physiologic pigment that the whole lung assumes a more or less intense black color: anthracosis. In stonecutters quartz fragments enter the lungs as dust and are deposited in the same localities as ordinary black pigment of the lungs: chalicosis. The deposition of red iron oxide in factory workers is much rarer: *siderosis pulmonum.*

In these three processes—the pneumokonioses—the whole lung-tissue gradually becomes indurated.

Aside from the bronchial glands, all these pigmented foreign bodies are deposited chiefly and, at first, almost solely in the true connective

tissue, *i.e.*, in the neighborhood of the bronchi, in the vessel-sheaths, in the pleura, and in the connective tissue which unites the individual lobuli.

Black pulmonary pigment is sometimes especially abundant in slaty indurations of the lungs resulting from chronic inflammatory processes (*phthisis indurativa pigmentosa*): black phthisis. This is probably due partly to the fact that the lymph-channels are obliterated and the pigment, therefore, cannot enter the bronchial glands. All black pigment within slaty indurations of the lung consists of carbon. Under certain conditions, in absorption processes, *e.g.*, in alveolar emphysema, the pigment enters the circulation and is then deposited in other organs: liver (principally within Glisson's capsule), spleen (especially in the follicles), and kidneys.

In agyria, resulting from continued therapeutic use of silver nitrate, precipitates of silver occur in minutest, punctiform distribution in various parts of the body, *e.g.*, in the rete Malpighii and the stratum mucosum of the epidermis, in the sweat-glands, glomeruli, tunica propria of the renal tubules, etc. (Compare Metastases, p. 94.)

In tattooing, pigments (carmine, carbon, etc.) are rubbed into the skin through fine punctures. Part of these pigments remain *in loco;* another portion enters the lymph-channels, is transported to the nearest lymph-glands, and there deposited near the hilus.

In chronic lead poisoning through the gastrointestinal canal, the so-called "blue line" (lead line, gingival line) develops upon the gums—a bluish-black coloration of the gums at the junction with the teeth. This is due to deposition of minute particles of lead sulphide beneath the epithelium in the neighborhood of the vessels. (For blood changes, see p. 326.)

DEGENERATION.

Degeneration is always a passive process in which the elements, although preserved, are in a state of diminished function. The changes are first of a chemic nature, but morphologic alterations also soon become manifest. Diminution in function always conveys the conception of transformation into an inferior tissue. Calcareous, amyloid, hyaline, waxy, colloid, mucous, albuminous, and fatty degenerations are distinguished. In the four first forms the persisting tissues become firmer, denser, and more resistant to reagents.

Calcareous degeneration, or **calcification,** is exemplified by petrification (infiltration of silicic acid with preservation of structure), and originates by separation of lime-salts from the blood and deposition of minute granules of carbonate and phosphate of lime in the tissues

Higher degrees of amyloid degeneration are always accompanied by pronounced states of cachexia, dropsy, and a marked degree of anemia and marasmus.

As regards its physical appearance, **hyaline degeneration** (von Recklinghausen) possesses a certain resemblance to amyloid degeneration. The hyaline masses are homogeneous, colorless, glassy; they are swollen and have a strongly refractive index, but give no iodine reaction (do not stain with iodine). They have an especially great affinity for the acid aniline dyes: eosin, acid-fuchsin (which cannot, however, be considered a specific staining, since other tissues also stain with these dyes), and are refractory to water, alcohol, and organic and inorganic acids (acetic acid, sulphuric acid). Hyaline substance is an albuminate the occurrence of which is confined essentially to connective tissue (old and new) and fibrin; in this regard, however, there is no unanimity of opinion. Von Recklinghausen designates as hyaline many other things which appear homogeneous. In the connective tissue it is the fibrillated basement substance which, as it were, swells, becomes broader and more transparent. An exactly similar change is not infrequently observed in the so-called reticular connective tissue of the lymph-glands, through which, upon gradual disappearance of the nuclei, a somewhat plump, homogeneous, and irregular stroma develops. The smaller vessels appear to be quite frequently altered in this manner, their walls being considerably swollen (especially in the brain, thyroid and lymph glands), and also the intima of the aorta (in chronic endoaortitis deformans), and the thickened valves of the heart in endocarditis. In some cases the hyaline-degenerated connective tissue gives a partial amyloid color reaction, for which reason it appears to be justifiable to assume that hyaline degeneration may be the early stage of amyloid change. In fresh and in old coagula (thrombi) a hyaline transformation by a kind of inspissation is frequently observed, in which the fibrin becomes homogeneous, loses its fibrinous form, and can no longer be teased. Weigert is of the opinion that fibrin manifests the hyaline character especially when it is subjected to the action of abundant plasmatic fluid.

In its external appearance **waxy degeneration** of the striated musculature (Zenker) is very similar to amyloid and hyaline degeneration, and is, therefore, classed sometimes with one, sometimes with the other, process. The transverse marking is lost and the primitive muscle-bundles are transformed into homogeneous, glistening, and very friable cylinders.

Waxy degeneration was first observed in typhoid fever, but it occurs in many acute infectious diseases and in the neighborhood of extravasates, injuries, inflammatory foci, and in tumors. (See Fig. 31.)

In **colloid**[1] **degeneration** (also called gelatinous, gelatiniform degeneration[2]) clear, bright, spheric albumin masses (alkali albuminate) are secreted by cells, which, on contact with fluids rich in salts, are transformed into a kind of gelatinous mass, concretion. The colloid masses are insoluble in water and swell slightly under the action of alcohol and acetic acid; they are firm, rigid masses which are easily friable and then present fracture surfaces similar to glass. They are either slightly yellow or colorless. If larger masses are secreted, distinct concentric lamellation can frequently be observed; the central parts are distinctly and often quite darkly colored, yellow, and brown. This coloration gradually diminishes from within outward toward the younger lamellæ. A point of predilection for these colloid masses is the thyroid gland, especially in *struma gelatinosa* Similar masses are secreted by the epithelia of the kidney and, on contact with salts of the urine, form strongly refractive, rounded, or elliptic concrements.[3] They are not hollow, but solid masses which occlude the lumina of the urinary tubuli. The greater the number of concretions formed, the more the urinary tubules (and likewise in *struma gelatinosa* the acini of the thyroid) are dilated, the epithelia at the same time becoming flatter. The latter gradually disappear; the interstitial substance between the various urinary tubuli atrophies until, finally, small cysts are produced by confluence of the tubules. The solid masses subsequently may be transformed into a richly albuminous fluid.

Eig. 31.—A portion of the soleus muscle from a case of typhoid fever. Preparation teased after treatment with Müller's fluid. × 200. Reduced ⅓. (After *Green.*)

Mucoid degeneration has its physiologic analogue in the mucous secretion of the cervix uteri and in the embryonal mucous tissue

---

[1] *Colla:* glue.

[2] The designations employed by various authors do not harmonize, as opinions frequently differ. The current terminology, as so often is the case in other instances, also is incorrect. Thus, in *carcinoma gelatinosum* and *struma gelatinosa* the adjective does not indicate, as might at first be assumed, similar characteristics, but the comparison with gelatin is purely external, the change in both cases being very different.

[3] These must not be mistaken for hyaline casts of the urinary tubules, which, according to some authors, consist of hyaline fibrin; according to others, of coalesced hyaline epithelia.

(still present at birth in the umbilical cord as Wharton's jelly). In the cervix uteri the mucus is elaborated by the superficial epithelia and epithelia of the scanty glands, and in the embryonal mucous tissue it forms the basement (intercellular) substance. There is an analogous pathologic formation of mucus which originates either in the epithelia or appears as a basement or intercellular substance. The epithelia of the whole respiratory tract, of the stomach and of the colon, of the urogenital system, of the middle ear, and of the conjunctiva—*i.e.*, almost all so-called mucous membranes—may secrete mucus under pathologic conditions (in exudative inflammations). Only a few localities are exceptions, particularly the surface of the tongue, the esophagus, the small intestine, and the true pulmonary alveoli. In all cases the mucus is elaborated by the cylindric epithelia of the surface and of the glands, especially of the excretory portion of the glands, these being transformed into the well-known goblet-cells. The "goblet," which is always situated near the surface of the cell, is colorless and homogeneous, in contrast to the rest of the cell. According to the intensity of the change, the upper clear portion of the cell has the form of a crescent, or the goblet extends farther downward, thus producing the form of a parabola, the nucleus being pushed toward the lower and more pointed portion of the cell. Finally, the mucous metamorphosis of the cell-body may advance to the base of the cell, so that with disappearance of the nucleus the cell dies *in toto*. According to most investigators, in milder cases restoration of the cylindric epithelium from the goblet-cell is probable.

In transformation of other tissues which belong to the group of connective substances (connective tissue, adipose tissue, etc.) into pathologic mucous tissue, the formation of mucous basement substance also depends upon the activity and influence of the cells, though with the difference, as compared with mucous formation from epithelia, that the formation of mucus can nowhere be directly followed within the cell-body. Transformation of connective tissue and adipose tissue into mucous tissue is always a process associated with general nutritive disturbances (as a result of severe chronic diseases), or it occurs in old age, when the vital and nutritive energy has already strongly declined. Hence, this phenomenon indicates an atrophic process with the character of retrogressive degeneration.

The substance which especially distinguishes mucous formation is mucin. This chemic body is still insufficiently characterized. Analysis shows that it contains a slight amount of nitrogen. According to the researches of Landwehr, it is a combination of albumin with a colloid carbohydrate. Mucus is especially characterized by its tenacious, pronouncedly ropy consistency. Unmixed—it very often occurs mixed

with other masses, *e.g.*, cells—it is clear, colorless, transparent. Mucin manifests a great disposition to take up water, in which case it swells strongly. On treatment of mucus with acetic acid or alcohol the mucin is precipitated in the form of threads and flakes, the mucus contracting and assuming a whitish-gray color. Mucin is soluble in combination with free alkali.

Besides connective tissue and adipose tissue, mucous transformation frequently occurs in cartilage, seldomer in the bone-marrow; in all these cases, however, changes occur through which the affected parts are so

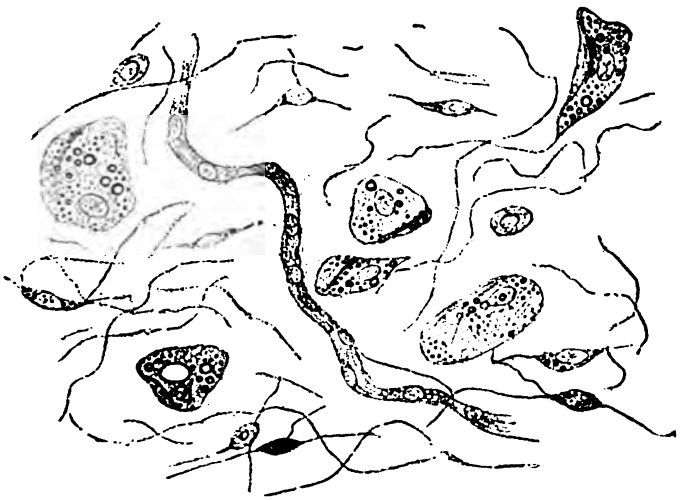

Fig. 32.—Mucoid degeneration of the pericardial fat-tissue. Fresh section. (Leitz Obj., 7; Ocul., 2. After *Langerhans.*)

transformed that they closely approach true connective tissue. In cartilage especially, fibrillation of the basement substance, and, therewith, a close approach to fibrocartilage, is always recognizable. In mucous degeneration of fat-tissue (in the omentum, the pericardium, at the hilus of the kidney, in the *panniculus adiposus,* in so-called colloid marrow of the tubular bones) increase of the mucous basement substance goes hand in hand with atrophy of the adipose-tissue cells, the latter losing their fat and shrinking to thin, leaf-like scales (see Fig. 32); this mucous basement substance does not, however, appear to depend upon the atrophic fat-cells, but to be formed solely from the now predominating connective tissue or its cells present also in the fat-tissue. The striated intercellular substance is rarefied, but it is almost always still recognizable.

In **myxedema** (Ord), the disease resulting from congenital or acquired defect of the thyroid, accompanied by cachexia and depending upon autointoxication, the firm swelling of external parts, beginning in the face and gradually extending downward, is due to a similar mucoid, mucinous degeneration of the connective tissue of the cutis and of the uppermost layer of the *panniculus adiposus*. Only the connective-tissue trabeculæ between the fat-lobuli are the seat of mucoid change. In the severer cases of this affection all connective tissue, including that present in the interior of the body, is finally involved by the same mucoid degeneration. Myxedema differs, however, from ordinary mucous degeneration, in so far as increase of volume is always perceptible, the altered part swelling and becoming firmer to the touch. At the same time proliferative processes (*i.e.*, progressive as well as retrogressive changes), which are absent in simple mucous degeneration, occur in the connective tissue, showing the inflammatory character of the affection. Therefore, under normal conditions there must be elaborated by the thyroid (through secretion) products which are of the greatest importance in the normal metabolism of the human body. In the absence of these products (iodine, etc.) pathologic deviations in metabolism occur which result in degeneration of the tissues. Owing to the similarity of these alterations to the phenomena caused by intoxication, it is assumed that, in the absence of the thyroid, some substances or metabolic products become active which, in the presence of the thyroid secretion, are chemicly neutralized and eliminated from the body, *i.e.*, under normal conditions are prevented from exerting deleterious action. Because these toxic metabolic products are formed in or by the body itself, this process is called autointoxication.

Closely related to these mucous transformations is the occurrence of homogeneous, mucinous material in tumors: in myxoma, myxofibroma, myxosarcoma, myxocarcinoma, or *carcinoma gelatinosum*, etc. In these tumors also the mucus may be formed from epithelia (*e.g.*, in cylindric-celled carcinoma from cylindric epithelia), or, what is by far more frequent, occur in the connective-tissue basement substance.

Albuminous, or **parenchymatous, degeneration** begins with cloudy swelling (*intumescentia opaca*) of the parenchyma.[1] The first change observed in this process is enlargement of the whole organ as well as of the individual constituent elements. The parenchyma cells swell and become more cloudy as the result of accumulation within

[1] By parenchyma (παρ - εν - χέω = beside; within; pour, in the sense of the Ancients: namely, between vessels and nerves) is understood that part of an organ which is most characteristic and important for the function; for example, in muscle, the contractile substance; in the liver, the liver-cells.

them of numerous, minute particles of albumin, which, on microscopic examination, appear as indistinctly outlined granules. The vessels do not actively participate; indeed, ischemia often exists as a result of swelling of the parenchyma. In this stage of cloudy swelling the specific function of the elements is weakened (for example, renal epithelia produce albuminous urine), but they still are capable of restitution. With assimilation or secretion of the newly imbibed material, restitution occurs, or the second stage—that of so-called retrogressive fatty metamorphosis—follows. In the latter case the albuminous granules are first replaced by very minute fat-puncta, and later by quite small fat-droplets. At first the nucleus is still plainly recognizable; subsequently, however, it gradually becomes more and more indistinct until, finally, the whole cell appears to be filled with minute drops of fat. Such a cell is no longer capable of restitution; it disintegrates and forms a milky fluid (emulsion stadium) which may easily be absorbed (necrobiosis:[1] atrophy with loss of external form).

Albuminous degeneration of the heart, kidneys, liver, stomach, and muscles is an extremely frequent phenomenon which is observed in severe acute processes accompanied by high fever, in many chronic diseases, and in poisoning. Cadaveric influences also may produce a similar change; that is to say, there is a cadaveric clouding of the organs which cannot be distinguished from the parenchymatous form occurring during life.

Many authorities have recently asserted, and with good reason, that in so-called fatty metamorphosis the cellular proteid is not chemicly transformed into fat, as Virchow taught, but that the fat is taken up from without by the cells in some still unknown modification, and not as ready fat, Altmann's cell granula being gradually substituted by fat-droplets. The importance of this process for the function and preservation of the cells is, perhaps, about the same as Virchow's fatty metamorphosis, because in this form of change also an integral constituent of the cell is lost and replaced by another inferior or injurious component.

Fatty degeneration.[2] By this term, in contradistinction to fatty infiltration (of adipose-tissue cells, liver cells, intestinal villi), fat retention (in fatty liver, in the intestinal villi), and so-called fatty metamorphosis (necrobiotic atrophy), is understood that affection of the muscular system (heart and skeletal muscles) which is characterized

[1] See Necrobiotic Atrophy, p. 116.

[2] Some writers use the term "fatty degeneration" as synonymous with "fatty metamorphosis." This, however, is incorrect.

by a more or less marked interstitial development of adipose tissue—a proliferation and metaplasia of the connective tissue existing between the primitive muscle-bundles into fat-tissue. The fat-cells between the primitive muscle-bundles push the latter apart and cause nutritive disturbances. Such muscles, therefore, are strikingly pale in appearance, scarcely resembling muscle substance. In the heart this condition, which is similar to that process occurring in artificial fattening of cattle (*Mastung*), may be followed by atrophy and considerable disturbance of function.

In the voluntary skeletal muscles this interstitial development of adipose tissue is always observed in so-called muscular pseudohypertrophy (*pseudohypertrophia musculorum*), in paralyzed

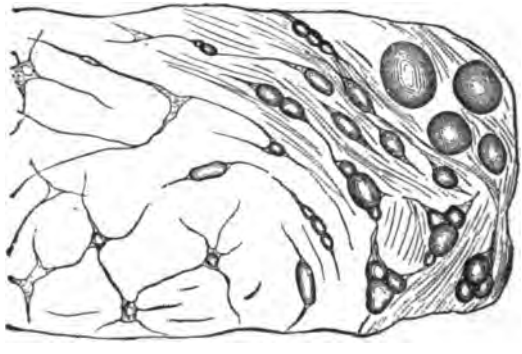

Fig. 33.—Fatty infiltration of connective tissue, showing the accumulation of fat within the cells. × 300. (*Rindfleisch.*)

limbs, in ankylosis, and in excessive corpulency. In the latter condition the pancreas also often manifests a quite similar fatty degeneration, adipose tissue developing between the individual lobuli. This change is frequently, perhaps most often, designated as lipomatosis. It is distinguished, however, by the fact that the adipose-tissue development is primary, while in paralyzed limbs and ankylosis atrophy of the musculature precedes the fat-tissue development, which is, therefore, a secondary manifestation.

Fat substances are normally deposited in not inconsiderable amount in the body-cells and tissues. Part of these belong to the constitutional substances of the plasma, varying in amount according to the specific and functional nature of the cells. This "stabile" fat is not used in metabolism, even in the state of starvation, for in animals dead from starvation the muscles always contain an abundance of fat. A series of body tissues, especially the adipose tissue in the subcutaneous and subserous panniculus, as well as the liver-cells, are capable of storing

superfluous fat. This "labile" depot fat may rapidly be given up when occasion demands.

Not all fatty substances are morphologicly visible and microscopicly demonstrable. Chemic examination often shows in microscopicly fat-free organs a fat content up to 20 per cent. and more of the dry substance. This is due to the fact that the fat substances are either dissolved in the plasma fluids or invisibly finely divided. The chemic nature of the fatty substances **(lipoids)** is not uniform. The chief mass, especially of the depot fat, consists of neutral fats: the triglycerides of oleinic, palmitinic, and stearinic acid. The amount of soaps is slight. On the other hand, most cells contain more complex combinations, such as lecithin (= distearin-glycerin-phosphoric acid-cholin), protagon (= lecithin + cerebrin), and cholesterin-holding fats. Some of these compounds are characterized by especial optical peculiarities, in that they show double refraction in polarized light, swell in water into peculiar, darkly contoured formations, and are stained with neutral red. Drops and clods with these peculiarities are designated as **myelin.** This is not a definite chemic body, but, as far as is known, a mixture of various components. Of chemicly pure substances belonging here soaps of the oleic acids, particularly their cholesterin mixture and cholin combinations, manifest double refraction. It is very probable that the phenomenon of double refraction depends upon such substances in solution with other lipoids; on the other hand, it depends also upon concentration and temperature. Pure lecithin and protagon are not double refractive, but in the body always contain other substances. Therefore, according to present knowledge, no sharp line of distinction can be drawn between single and double refractive substances, and most fat-like drops in the body must be regarded not as chemicly pure substances, but as mixtures. While the fatty substances in the fat-depots are single refractive, such myelin substances are physiologicly found in the cortical cells of the suprarenals, in the lutein cells, in the epithelia of the gall-bladder, and in involution of the thymus. These myelin substances have excited interest only since they have been found in pathologic processes, *e.g.*, in fatty change in the intima of the aorta, in the alveolar and renal epithelia, and in various tumor-cells. They are usually mixed with ordinary fat-droplets. In the atheromatous aorta, the gall-bladder, and other tissues, the occurrence of double refractive droplets may be followed by precipitation of crystalline cholesterin, so that in this a connection between cholesterin admixture and double refraction can be surmised. Similar myelin droplets may occur also in autolysis, *i.e.*, in nonbacterial tissue disintegration at body temperature, and may

be demonstrated, by extraction with alcohol, in various organs, especially nerve- and brain- tissue (Gierke).

The kidney very frequently is found in a state of fatty degeneration, the epithelia of the convoluted tubules being principally involved. The cortex, and, therefore, the surface, of the kidney acquires a yellow-white color (white kidney); as it is common for only certain parts to be the seat of fatty degeneration, a yellow mottling—a sprinkled appearance—may be manifest. The fatty degenerated epithelia easily become dislodged from the tunica propria and enter the urine through the renal tubuli downward; they often remain coherent and appear in the urine as cylindric bodies (renal casts), in this case, epithelial casts. As the fatty degenerated epithelia disappear partly by excretion with the urine, partly by disintegration and absorption of the fatty detritus, the kidney suffers in different localities a loss of cortical substance; where substance has been lost, the surface sinks inward; the previously smooth surface becomes granular (granular atrophy). The depressed areas contain little or no fatty degenerated epithelia, but only stroma and blood-vessels, and are, therefore, more gray-red in color. As fatty degeneration affects the parenchyma, it has been designated also as parenchymatous degeneration: "parenchymatous inflammation." The latter designation is inappropriate.[1] (See Inflammation, p. 172.)

Fatty degeneration may follow albuminoid degeneration; it occurs also independently.

REGENERATION.

Regeneration is an active formative process in which, after the occurrence of defect caused by pathologic processes or trauma, the type —genus—of the defective tissue is renewed. The reproduction—restoration—of lost parts of tissue ranks with inflammatory processes. The products of regeneration (*e.g.*, in solution of continuity) and of inflammation cannot always be sharply separated from each other, though there is a difference, in so far as the regenerated tissue, without exception, preserves the type of the lost tissue, while the inflammatory product deviates from the genus in form, type, and amount. Regeneration, strictly speaking, pathologic regeneration,

[1] A sharp line must be drawn between inflammation and degeneration: inflammation is not degeneration. Degeneration is something passive: the tissues suffer. In inflammation, on the other hand, an *actio* of the tissues is noticeable: hyperemia, exudation, emigration, production of new tissue occur. In some cases degeneration and necrosis of the epithelia are recognizable without any pathologic change in the interstitial tissue; then only degeneration is present: parenchymatous degeneration, but not inflammation. This change is incorrectly called parenchymatous inflammation.

has its counterpart in physiologic regeneration of the epidermis, hair, and nails, of the epithelium of mucous membranes and of many glands (*e.g.*, sebaceous glands, milk glands), of the blood, etc. In physiologic regeneration replacement of the consumed and exhausted parts takes place always from homologous elements; for example, loss of epithelium is compensated by epithelium by division of the cells. In like manner, compensation in pathologic regeneration is obtained from the remaining tissues, not from other parts (not from the colorless blood-corpuscles, etc.).

Division of the cells, through which new formation and restoration occur, is always preceded by division of the cell-nuclei. Owing to improved methods of investigation and modern instruments, the earlier assumption of a "direct" nuclear division has been almost wholly abandoned in favor of "indirect" nuclear division (karyomitosis, karyokinesis).[1] Although "direct" (amitotic) nuclear division is still quite frequently observed (for example, in the leucocytes), it appears, as Flemming asserts, that this is not a physiologic process through which increase and new formation of cells may occur, but a degeneration phenomenon; "or, perhaps, in many cases (formation of multinucleated cells by fragmentation), by enlargement of the nuclear periphery, it is connected with cellular metabolism."

Certain lower classes of vertebrates possess extraordinary power of regeneration, so that, for example, in the lizard the whole tail may be regenerated within from three to five months. In mammals and birds extremities and whole organs cannot be replaced; certain parts of organs as well as feathers (molting), however, are completely regenerated.

Under favorable conditions almost all human tissues are capable of regeneration; but the presence of a matrix from which new formation can develop in accordance with the old type is always necessary. In some organs (for example, in the central nervous system; in the terminal apparatus of the cutaneous nerves after loss of skin; in the villi of the small intestine, etc.) regeneration has not as yet been observed; in others (for example, in the large glandular organs of the abdomen and in the smooth muscles) regeneration is doubtful, although in the liver it has often been positively demonstrated; in others, again, regeneration is incomplete. For example, in rupture of cartilage, connective tissue or bony callus usually develops; in fat tissue: scar tissue, which, perhaps, is subsequently converted into adipose tissue; in the peripheral nerves the medullary sheath is lost. In pathologic cases the

[1] According to Flemming's investigations, "indirect" nuclear division (mitosis), for example, in leukemia, appears to be the normal process of division in the leucocytes also.

following tissues are most completely, and to a very marked degree, capable of regeneration: epithelium, the blood (*e.g.*, after hemorrhage), connective tissue, bone, the lens (provided the lens capsule is preserved), certain glands (*e.g.*, uterine glands after separation of the placenta), the hair in youth and after certain diseases (typhoid, variola, scarlatina). The regenerative power of the various tissues diminishes with age; it is greater in the embryo than in the newborn, and is often abolished with cessation of growth. It is the less the higher the development the various tissues have undergone for specific function.

It is doubtful whether regeneration occurs after extirpation of the spleen. In this regard it must be remembered that often not only one large spleen is present in the body, but also several smaller, so-called accessory spleens. One of these may assume the function of the removed organ and undergo compensatory hypertrophy.

Slighter losses of skin and probably also of mucous membrane (epithelium and connective tissue) are completely regenerated; greater losses of substance, which extend to the subcutanous adipose tissue or to the submucosa, are only partially regenerated, scar tissue taking their place. Although the latter consists principally of epithelium and connective tissue, it is distinguished in detail of structure by bulk, density, vascularity, absence of papillæ, etc.

If the lens capsule is preserved, the lens can be completely regenerated.

Most prolific is regeneration of bone, especially after fracture. As a rule, the first thing observed after simple, uncomplicated fracture is marked hemorrhage, whereby the point of fracture becomes more or less intensely swollen. Then formation of inflammatory granulation tissue follows—a soft, cellular (round and spindle cells), very richly vascular tissue. From this arise numerous trabeculæ and bands of cartilage substance composed partly of hyaline cartilage, partly of osteoid substance.[1] The hyaline cartilage masses are either provisionally calcified or converted into osteoid substance. From this, bone is finally formed by appropriation of lime-salts. The primarily soft callus is thus gradually transformed into osseous tissue. The formation of callus is almost always very marked, sometimes excessive: *callus luxurians*. The spiculæ and prominences present upon the surface of a callus correspond to small projecting splinters of bone which have been fixed in their new position. While on farther advance of the process thick, firm, compact osseous masses are formed upon the surface of the bone, the *tela ossea* disappears from the interior by absorption, marrow tissue taking its place.

[1] Osteoid substance is bone without lime-salts.

After a longer period, part of the superfluous external osseous material (spiculæ, protuberances, etc.) being absorbed, the callus gradually assumes the form of the old bone. In this manner regeneration results in a new piece of bone, which differs only very slightly from the old. Callus formation originates, first, from the periosteum; second, from the inflammatory marrow tissue, and, third, from the parosteal connective tissue.

Pathologic organization may occur with or without the formation of vessels: vascularization. It rarely occurs without new for-

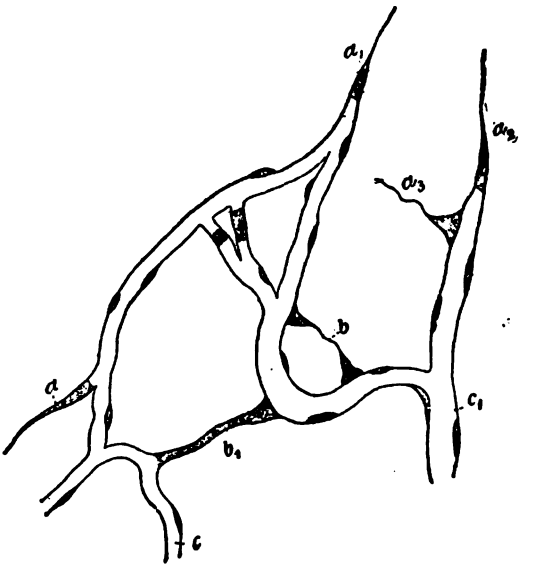

Fig. 34.—Formation of capillary vessels. a, a_3, buds; b, b_1, buds joining; c, c_1, complete young capillary. × 320. (After *Arnold.*)

mation of vessels, and then only under certain conditions, and results in a tissue which is of little functional value and, under certain conditions, injurious to the organism (cicatrices). The formation of new vessels can best be observed in organization of thrombi and fibrinous exudates of serous membranes. The vessel may develop in two ways: 1. By budding, the old capillaries sending out small, hemispheric prolongations which, at first, are solid, but, later, by growth into quite elongated cells, become hollow at their basal attachments to the vessel and appear filled with blood; these primarily "blind" vascular buds unite with each other and thus form new capillary anastomoses; or 2, the new formation of vessels starts from cells belonging to the connective tissue, *i.e.*, from stellate, so-called "vessel-forming" elements which form

a reticulum by means of anastomosing filaments and are in direct connection with the vessel walls. These cells are occasionally filled with blood, under which circumstances a channel can be recognized.

New vessels are never formed from pleuritic exudate, a thrombus, the adhesive exudate of wound margins in the healing of wounds, or from secretions of ulcerating surfaces, but always, as in the accompanying new formation of connective tissue, from the surrounding tissue—that is, from the cells of the vessel wall, the pleura, etc. Pleuritic exudate, a thrombus, etc., form only a provisional material, which is replaced by the new-formed tissue (substitution). The thrombus exudate acts as a foreign body, like a sponge or a bullet, irritates the surrounding parts, and excites a formative process, with the difference only that the fibrinous material, owing to its chemic and physic properties, is infiltrated by the new-formed tissue and gradually disappears, while other foreign bodies are surrounded by a dense fibrous connective-tissue capsule and remain *in loco*. Hence, organization of thrombi always begins in the periphery, adhesion between the vessel wall and the thrombus being the first step.

As a result of organization an organic (vascularized) union of the apposed surfaces occurs. Those newly formed tissues which organicly unite existing parts are called **adhesions**, and the inflammations which give rise to adhesions are designated as adhesive inflammations. Within the adhesions, which assume different forms according to existing conditions (*e.g.*, rest, movement, friction), lymph-vessels, large blood-vessels (arteries and veins), elastic fibers, and even nerves are found after a time. In elongated adhesions numerous capillaries, which coalesce upon one side to form a large vascular trunk, and upon the other side again break up into a large number of smaller vessels, are frequently found.

By **transplantation** (grafting) is understood the transference of living tissue, after separation from the matrix, to another tissue or another locality in the same or another individual. The chances that the transferred[1] tissue will grow to the part to which it is conveyed are the greater when the transplanted tissue remains united to the matrix by a kind of bridge, the more vessels the new locality contains, and the larger the surface (wound surface) into which new vessels can grow.

During the first few days nutrition occurs by plasmatic flow; then blood-vessels enter and circulation is established. If infection or mechanic injury occurs, or if a layer of blood is present between the graft and the base, the transplanted tissue dies. In transplanted cutaneous

[1] After the manner of grafting of trees.

tissue almost all parts, *e.g.*, elastic tissue, etc., are preserved. The structure of a cutaneous cicatrix differs greatly from such a transplant, particularly in regard to the elastic tissue. A cicatrix contains little or no elastic fibers, while the transplanted tissue always shows an abundant elastic reticulum such as is present in normal skin.

The vital energy of the transferred tissue is of great importance for the success of transplantation; therefore, young tissues are more adapted for this purpose. While portions of tissue which are transferred to foreign, heterologous soil usually atrophy after a time, transplantation of skin and bone upon homologous soil soon results in definite incorporation of the transplanted tissue.

INFLAMMATION.

Inflammation, phlogosis, is a local reaction to an irritant, an effort of defense, characterized by hyperemia, passage of fluid and cellular constituents from the vessels into the tissues, and proliferative, degenerative, and regenerative changes. It is a local increase of the nutritive processes (augmented combustion and destruction, with elevation of temperature) due to internal or external influences (chemic, physic, organic inflammatory irritants), which, however, does not result in strengthening, but in weakening or abolishment, of function, since it possesses a destructive, degenerative character. Essentially, therefore, it is a local disturbance of nutrition, distinguished from other nutritive disturbances by the intensity of the changes, rapidity of course, and the character of the danger. Inflammation is distinguished from simple irritation, which is more functional in character, by the disturbances of nutrition; the difference, however, is only quantitative in so far as inflammation is an augmentation of irritation, *i.e.*, develops from irritation.

The phenomena of inflammation[1] differ according as the process occurs in richly or poorly vascularized parts. In highly vascularized parts the inflammatory reddening, active (inflammatory) hyperemia[2] (*rubor*), is usually very pronounced: dilation of all vessels with acceleration of the blood-current (the uniform redness of inflamed parts is always due to intense engorgement of the capillaries). These local disturbances of circulation occur only in richly vascular parts, and, therefore, are not a constant manifestation of inflammation.

[1] According to Celsus-Galen, the four cardinal signs of inflammation were: *calor* (heat), *rubor* (redness), *tumor* (swelling), and *dolor* (pain), to which subsequently was added *functio læsa* (disturbance of function).

[2] Inflammatory hyperemia differs from simple congestion by its persistence, which probably is due to continuous irritant action upon the vessel walls.

Elevation of temperature (*calor*), which is manifest in visible richly vascular parts, is the result, on the one hand, principally of stronger flow of arterial blood to the locality (hyperemia), and, on the other, to a slight extent, of increased combustion.

The inflammatory **pain** (*dolor*) is due to tension (*tumor*) of the tissues, and is present only in parts richly supplied with nerves, and, therefore, stands in the same relation to inflammation as do the local circulatory disturbances. Inflammation, however, extends the more rapidly the more richly the part is supplied with vessels and nerves.

In spite of these various symptoms, depending upon the anatomic arrangement or structure of the inflamed tissue area, the essentials of the inflammatory process always remain the same. The process begins with injury to the tissues, which is followed by escape of fluid and cellular constituents from the vessels, and cellular proliferation.

The primary change observed in most inflammations after action of the irritant is active hyperemia[1]: dilation of the vessels, increased velocity of the blood-current, and augmented blood-pressure,[2] which soon are followed by escape of fluid from the capillaries and venules. At first the red blood-corpuscles occupy the center of the current, forming the so-called axial stream; at the periphery blood-plasma flows free of red cells, constituting the so-called plasmatic marginal zone, within which the leucocytes lag somewhat behind the red blood-cells. Soon the velocity of the current becomes slower, owing to increased pressure in the tissues; the axial stream becomes broader, the vessels still remaining dilated; leucocytes gradually accumulate in the marginal zone, flow more slowly, and finally adhere in great numbers to the inner surface of the vessel walls: marginal position of the white blood-corpuscles. Arrest of the leucocytes is followed by their passage through the vessel walls into the surrounding tissues: emigration,[3] which is chiefly a passive, partly a migratory (active ameboid), process. (See Fig. 35.) In the act of emigration the leucocytes send delicate prolongations through cement substance in the vessel wall—perhaps also through the endothelial cells—the protruded portion forming a small bud upon the outer surface

---

[1] It is still disputed whether inflammatory hyperemia is the result of irritation of the vasodilators or paralysis of the vasoconstrictors. Recent investigations, however, seem to indicate that it is due to paralysis.

[2] The sense of pulsation accompanying inflammatory fluxion is more frequently subjective than objective.

[3] While the significance of emigration of leucocytes in inflammation was first pointed out by Cohnheim, in 1867, escape of both white and red blood-corpuscles was observed to take place from the interior of the vessels into the adjoining tissues first by W. Addison, in 1843 (Exper. and Pract. Research in Inflamm., 1843), and then by Waller, in 1846 (Philosoph. Mag., Oct. and Nov., 1846).

of the vessel. As more and more of the body of the cell passes through the vessel wall, the portion outside increases in size, that part remaining within the vessel gradually diminishing, until, finally, the whole cell escapes into the tissues, in the spaces of which it continues to manifest ameboid movements.[1] Along with the white blood-corpuscles, occasionally before them, red blood-cells and blood-platelets leave the vessels with

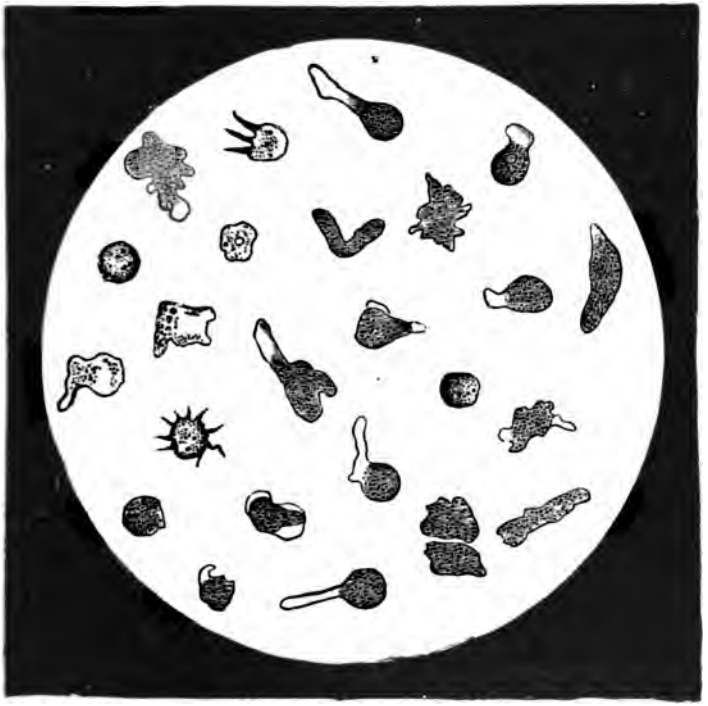

Fig. 35.—Leucocytes of man, showing ameboid movement. (*Landois.*)

the plasma and collect in the tissues or in preformed cavities as exudative inflammatory constituents.

Formerly it was supposed that only the polymorphonuclear (neutrophilic) leucocytes migrated from the vessels; recent investigations, however, have shown that while, in accordance with the preponderance of these elements in the blood, the majority of the leucocytes derived from the blood are of this type, the lymphocytes also are capable of leaving the vessels. These lymphocytes have a small round or slightly indented nucleus surrounded by a very narrow rim of homogeneous pro-

[1] An abundant accumulation of leucocytes outside the blood-vessels is a positive sign of acute and especially of purulent inflammation.

toplasm. In addition to the round migratory cells derived from the blood there occur in the inflammatory exudate also histogenous mononuclear wandering cells, derivatives of the adjacent connective tissues, especially the adventitia of the blood-vessels (adventitial cells), which migrate into the inflamed area and morphologicly are indistinguishable from the lymphocytes above mentioned. Both these forms of mononuclear cells, therefore, are designated as small round or granulation cells.

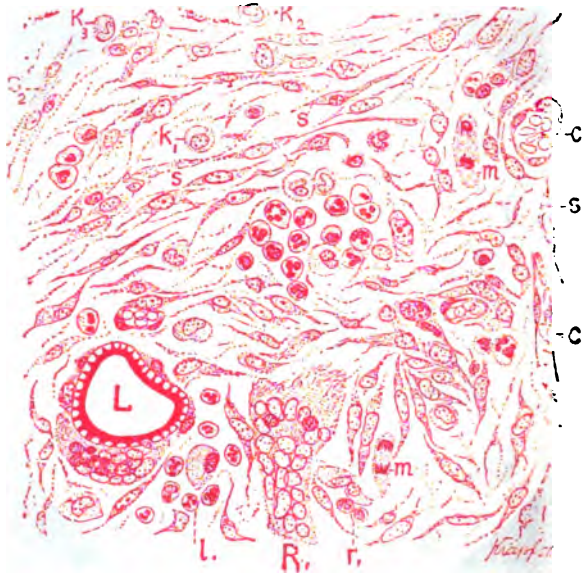

Fig. 36.—Granulation tissue from the peritoneum of a guinea-pig after injection of lycopodium spores. *s*, spindle-cell; *m*, the same with mitotic figure; k_1, k_2, k_3, wandering cells with large nuclei; *l*, leucocyte with polymorphous or fragmented nuclei; *r*, mononuclear cells; *R*, giant cells; *c*, young capillary; *L*, lycopodium spore with adherent giant cell. (*Smaus.*)

Among the mononuclear wandering cells occurring in an inflamed area there can be distinguished morphologicly: 1. Cells slightly larger than red blood-corpuscles, with a large, intensely staining nucleus and a small, scarcely visible border of protoplasm: lymphocytes. 2. Cells which are decidedly larger and have a comparatively small, clear nucleus and a marked, slightly granular border of protoplasm. These are regarded as derivatives of young connective-tissue cells (fibroblasts), also as transformed white blood-cells. They possess pronounced phagocytic powers, and, accordingly, not infrequently contain small, round cells (leucocytes and lymphocytes). Owing to the various

forms which these cells assume, they have been designated as polyblasts. These cells correspond to the "large phagocytes" of Metchnikoff; the "large leucocytoid wandering cells" of Marchand; the "polyblasts" of Maximow; the "klasmatocytes" of Ranvier, and the so-called "epithelioid cells." 3. Round or somewhat irregularly shaped cells with abundant cytoplasm and a usually eccentric nucleus, with nucleoli or coarse chromatin granules, which stains blue with methylene-blue and contains irregularly arranged granules, while the cell-body stains intensely red with pyronin: plasma-cells. These cells very probably are derivatives exclusively of lymphocytes.

Leucocytoid wandering cells, plasma-cells, polyblasts, klasmatocytes, and mast-cells, the latter of which are usually lacking in granulation tissue, are brought into close relationship to each other by Maximow. According to this author, the polyblasts, which constitute the greater portion of the granulation tissue, are principally migrated and altered lymphocytes, the lesser number originating from klasmatocytes; they may form cells resembling fixed klasmatocytes. According to Ranvier, the klasmatocytes are cells which have migrated from the vessels, but have become fixed in the tissue, and are especially abundant in the vicinity of the vessels. They are delicate, elongated, or dendritic protoplasmic formations, usually of very considerable length, with rounded or elongated nuclei, from the body of which small portions may very readily be separated by marginal constriction. Marchand also observed these cells especially in the adventitia in the omentum, and followed their development in inflammation and inflammatory tissue formation. According to his investigations, they form, on the one hand, large motile phagocytes and giant cells, and, on the other, elements of the nature of lymphocytes and large mononuclear leucocytes which, perhaps, even may become true leucocytes by migration into the blood-channels. Their conversion into fixed connective-tissue cells he does not regard as established. These cells, as well as lymphocytes, plasma-cells, etc., are designated by Marchand as "leucocytoid cells." In regard to the plasma-cells also, various views exist: Some authors differentiate Unna's and Marschalko's plasma-cells, of which the former are said to be derived from connective tissue, the latter from lymphocytes; this differentiation, however, is not quite tenable, for it is probable that all plasma-cells are derivatives of lymphocytes or lymphoblasts.

Schridde differentiates lymphocytic and lymphoblastic plasma-cells, the origin of which from lymphocytic elements is proved by the presence in them of the same type of granula.

As above stated, the mononuclear and polynuclear polymorphous cells may be polyblasts or klasmatocytes, but the majority of them are derivatives of the fixed connective tissue: fibroblasts, which, especially in inflammations not markedly necrotic or purulent, generally preserve the characteristics of connective-tissue cells. They are stellate and spindle-shaped formations with long processes, clear nuclei, and typic nucleoli. In marked proliferations they are densely arranged, and, therefore, are smaller and their processes indistinct. Occasionally they may be round, which renders very difficult their differentiation from lymphocytic polyblasts. Some of the fibroblasts present in granulation tissue are derived also from endothelia of lymph-vessels or blood-vessels (*e.g.*, in the organization of a thrombus). The latter origin and also the question whether endothelial cells of the abdominal and thoracic cavities may be converted into fibroblasts are still unsettled; according to recent investigations, it is doubtful whether such transformation occurs. Giant, or multinucleated, cells are very frequently, if not always, present in granulation tissue. They are formed chiefly from fixed connective-tissue cells and vessel endothelia, but may be derived also from leucocytoid cells—in the former instance by continued division of nuclei and defective division of the protoplasm of one cell; in the latter instance, probably chiefly by coalescence of a number of cells. They act principally as scavengers (Lubarsch).

As the polymorphonuclear cells exuded from the blood in the acute stage of inflammation soon disappear and are replaced by wandering cells derived from the tissues, the mononuclear form of wandering cells predominates in the chronic stage. They may be converted into large, round, or irregularly shaped cells: so-called "leucocytoid cells" of Marchand. As already stated, these cells, in the presence of not too irritant foreign bodies, act principally as phagocytes and remove disintegration products from the tissues: phagocytosis. In the formation of connective tissue some of these mononuclear wandering cells, probably only those derived from the tissue, again become fixed elements.

In accordance with what already has been stated, the following groups of cellular constituents of inflammatory exudate may be distinguished:—

(*a*) Cells derived from the blood, extruded or migrated through the blood-vessel walls: leucocytes, lymphocytes, red blood-corpuscles, and blood-platelets.

(*b*) Cells originating from proliferation in the exudate: derivatives of migratory cells.

(*c*) Cells derived from proliferation of the fixed tissue-cells in the vicinity of the inflammatory focus which wander into the inflamed area.

In some instances, however, the proliferative changes in inflammation are so slight as compared with the alterative and exudative changes that they often are regarded as insignificant or as independent of the inflammatory process. There is no doubt, however, that they are present even in the early stages of acute inflammation, and in some instances may obscure the exudative processes.

(*d*) To the above must be added cells dislodged or desquamated from serous and mucous membranes, ducts, and glands, etc.: epithelia, glia-cells, etc., which manifest more or less marked regressive alterations.

According to the rapidity and intensity with which the process is established and runs its course are differentiated: acute and chronic inflammation; as regards the forms of inflammation, they are designated as alterative, exudative, and productive, or proliferative. A topographic division of inflammation into parenchymatous and interstitial, and superficial and infiltrating, also is made according to the locality of the inflammatory process.

While the division into superficial and infiltrating inflammation is of no especial significance and should be abandoned, the division into parenchymatous and interstitial inflammation, according as the inflammatory process involves principally the parenchyma (functionating) or the interstitial (supporting) tissue of an organ, although based upon Virchow's obsolete conception of inflammation, is permissible, provided the essentials of inflammation be borne in mind.

A *résumé* of the rôle played by the vessels and parenchyma in inflammation was presented by Rudolph Virchow.[1] The words "vessels, parenchyma, and inflammation," says the author, are of very ancient origin, for they are of frequent mention in the old humoral pathology. In the course of centuries they have undergone great alterations in their significance corresponding to the progressing knowledge of actual conditions, and the history of our science very distinctly shows that these mutations have not as yet come to a conclusion. If, in spite of these changes, the same words, indeed to no small degree even the formulæ in which they occur, have still been preserved in the parlance of physicians, the confusion resulting therefrom, and which is constantly recurring, is readily explained by the fact that the old words are accompanied by old conceptions.

With respect to the vessels, it is to be deplored that, even at the present time, vessels in general are usually spoken of, while it should almost always be necessary accurately to designate the kind of vessels which is meant. In the old humoral pathology the veins exclusively were regarded as the channels for the blood. This is readily understood when it is considered that even today congested veins chiefly attract the attention of physicians and anatomists, because they are to a large extent superficially placed and, hence, become prominent in irritative and inflammatory processes. However difficult it may be for many physicians to refer blush-

[1] Virchow's Archiv, Bd. 149, Heft 3, p. 381.

ing originated through nervous influence to the veins, it is equally tempting for them to regard the "injection" observed in irritation of mucous membranes, especially in chronic inflammations (conjunctivitis, pharyngitis, tracheitis, gastritis), as arterial, or even capillary, instead of venous.

Up to the time when the arteries were demonstrated to be blood-conducting channels and the occurrence of blood within them was no longer referred to an *error loci*, a participation of the arteries in inflammation in the modern sense was not considered. The latter began with the discovery by Harvey of the continuity of the circulation. This, it is true, was somewhat more than two and a half centuries ago. But it should not be forgotten that it was not until forty-two years later that Malpighi saw the capillary current, and that the capillary vessels, *i.e.*, the limitation of the capillary current by proper walls, were not demonstrated until our own time. What wonder, then, that the attitude of the vessels to the local processes continued to be a subject of dispute; that the important question as to the formation and origin of vessels in their relation to inflammation was answered in a manner entirely at variance with the views entertained at the present day.

To Marcello Malpighi will always belong the credit of having displaced simple theoretic speculation by actual observation. With him, who not only observed the capillary current in motion, but also discovered the fibrin and red blood-corpuscles, began a new and lasting alteration in the theory of inflammation. Malpighi was the first physician to employ the microscope in the exploration of the intrinsic structure and the finer vital processes of the different portions of the body, and through his efforts a technique, until then unknown, was introduced into scientific research.

Strange to relate, it is still a serious task of modern teachers to accustom medical students to the thought that the capillary vessels, upon which so much depends in the study of not only inflammations, but also of numerous other physiologic and pathologic phenomena, cannot be seen with the naked eye, and that a simple macroscopic examination, therefore, does not suffice to form an opinion as to the nature of the rôle played by the vessels. Indeed, it can readily be understood that even the microscopic observations of the first decades of the nineteenth century, conducted without knowledge of the capillary walls and with imperfect optical instruments, were chiefly productive of erroneous results. In that period especially belongs the revival of the old idea of the origin of new capillary vessels in the beginning of inflammation, and of the inflammatory exudation associated therewith.

This exudation assumed a foremost position in observation when, in the course of the first half of the nineteenth century, pathologicoanatomic research became more and more extended and also formed the basis of clinic discussion. Of the four cardinal symptoms of inflammation, which the Galenic doctrine had made the common property of physicians, but two: *rubor* and *tumor*, came within the sphere of pathologicoanatomic research, while the other two: *calor* and *dolor*, remained to the clinician and the experimental pathologist. Of the former two, *tumor* was interpreted as the constant sequela of inflammatory exudation. Thus, it came to pass that, chiefly through the later Vienna school, exudation attained the foremost position in the symptom-complex of inflammation. Quite logically, attention was directed toward accurate examination of the exudates and so far with good reason, since *rubor* frequently disappears in the cadaver and is, therefore, valueless as a constant symptom.

Here a most striking and important change of ideas immediately took place. While the word *tumor* was used to designate swelling of the organs (an *intumes-*

centia), the word *exsudatio* conveyed the idea of a free substance escaping or exuding from the organs. Hence, the composition of the exudates escaping from the surfaces of mucous or serous membranes, be they located either exteriorly or within channels or cavities, was zealously studied with the aid of optic and chemic means. If, however, a swelling occasionally appeared (*e.g.*, in hydrocele, a tumor of the testis; in an ascites, swelling of the abdomen), a free exudate was, nevertheless, always present external to the organs and no intumescence of the organs themselves. For inflammation, however, two chief varieties of exudates were recognized, viz., the fibrinous and the purulent, which served as sufficient proof of previous or still-existing inflammation. Upon this basis rests the differentiation into adhesive and purulent inflammation universally accepted since the time of John Hunter.

Since, however, the simple tumefactions, which unquestionably are very frequent, could not be explained by the free exudates, infiltrations were introduced to explain them. Here it was assumed that substances were separated from the vessels and entered the neighboring tissues, but did not advance beyond the free surface of the organs. But many organs possessed no free surface, *e.g.*, the brain, to which, nevertheless, not one, but several varieties of inflammation were credited.

Under the influence of these views, the ontologic idea of inflammation, which had been held for centuries, was gradually lost. Not only were the signs, the so-called cardinal symptoms, obliterated, but the nature of the changes also proved to be different, and it became necessary to distinguish the kind of inflammation under observation by adjective additions. For the unprejudiced observer, no doubt could remain that the nature of the alterations could by no means adequately be expressed by the word inflammation. But one thing remained: that for every kind of inflammation the participation of the vessels appeared to be the starting point for the collective process as well as for the varieties of the same.

It was in this period that Virchow directed attention to the parenchyma of the organs. He used the word, in the sense adopted by Vesal and Th. Bartholin, to designate the tissue located outside or between the vessels; but within this tissue he differentiated the specific parts to which the organ owes its peculiarity (the *substantia propria*) from the interstitial tissue. Hence, he applied the name "parenchymatous inflammations" to those processes which caused swelling of the specific parts of an organ.

Virchow's conception of inflammation, which assumed that the tissue-cells, excited to greater activity by the inflammatory stimulus, took up more nutriment, increased in size, and proliferated, thus forming the inflammatory cellular constituents, the circulatory disturbances being regarded as of secondary importance, has given rise to much confusion. Aside from the fact that circulatory disturbance has been shown to be of predominant importance in inflammation, Virchow's theory should be discarded not only because it is untenable, but because it renders impossible the separation of inflammation from certain purely alterative and progressive processes. On the basis of this theory many processes are designated as parenchymatous inflammation which, strictly speaking, are degenerative in nature. It should, therefore, be emphasized that parenchymatous degenerative alterations occurring without the phe-

nomena of inflammation (exudation) should not be designated as parenchymatous inflammation, but only as parenchymatous degenerations. Only when, in addition to true inflammatory phenomena, regressive or progressive processes are predominant, especially in the parenchyma, can parenchymatous inflammation be said to exist. On the other hand, every inflammation is interstitial, because it occurs especially in the interstitial tissue in which the vessels are situated. Here, also, interstitial inflammation can be said to exist only in so far as the interstitial changes, as compared with those observed in the parenchyma, are decidedly predominant.

With full appreciation and application of the above distinctions, alterative, productive, and exudative parenchymatous or interstitial inflammations, respectively, can be differentiated. As, following the precedent of Virchow, there still is a tendency to designate as "parenchymatous nephritis, neuritis, encephalitis, myelitis," etc., processes which are purely degenerative in nature, and not in any sense inflammatory, it is advisable to employ such terminology cautiously and as infrequently as possible. In certain organs, however (lungs, kidneys, etc.), topographic designation is of value, since the inflammatory phenomena may be most marked in the parenchyma. For example, in scarlatina, chiefly the glomeruli of the kidney are affected: glomerulonephritis. This does not, however, designate the character of the inflammation, but indicates simply that the inflammatory process involves principally the glomeruli.

The parenchymatous alterations occurring in inflammation are at first chiefly degenerative: cloudy swelling or albuminous degeneration, fatty infiltration and degeneration, absorption of water (hydropsic swelling), colloid degeneration. (See Degeneration, p. 139.) In high degrees of inflammation the local processes are followed by alterations in remote parts of the body, which are due to the action of toxic substances associated with the inflammatory process: *e.g.*, toxins of bacteria or injurious metabolic products of the affected tissues. These alterations also are manifested by degenerative changes—cloudy swelling, fatty degeneration, etc.—of different organs; tumefaction of the lymphatic glands, fever, increase of leucocytes in the bone-marrow, and, therefore, also in the blood (leucocytosis), and the formation of antitoxins.

Exudative Inflammations.—In these forms of inflammation the exudative phenomena predominate. According to the nature of the exudate, a number of varieties are differentiated:—

1. Purulent inflammation.
2. Serous inflammation.
3. Hemorrhagic inflammation.
4. Fibrinous inflammation.
5. Catarrhal inflammation.
6. Caseous inflammation.
7. Ichorous (putrid) inflammation.

Purulent inflammation is generally divided into two forms: (*a*) those occurring in the interior of the tissues: so-called interstitial suppurations, and (*b*) those occurring upon the surface of serous or mucous membranes.

(*a*) In the interstitial type there is always formation of pus within the interstitial tissue, at first as a purulent infiltration, which is preceded by exudation of a serous or serofibrinous fluid. The pus is almost exclusively derived from the blood by emigration of colorless (white) blood-corpuscles. Two forms of interstitial suppurative inflammation are differentiated, namely, phlegmonous: diffuse suppuration with mortification and thrusting-off of necrotic shreds, and abscess: circumscribed suppuration with solution and disappearance of the tissue without separation of necrotic masses, with formation of a (pus) cavity. Both phlegmon and abscess begin with inflammatory edema. This edema fluid is at first almost clear, but becomes more and more clouded by gradual accumulation of emigrated white blood-corpuscles (leucocytes). An abscess may rupture externally, and, after discharge of the contents, finally heal by cicatrization. If the abscess is situated at some distance from the surface, the pus, partly of its own gravity, partly following the route of least resistance of the surrounding tissues, penetrates the adjacent structures, and, by new purulent solution of tissue, makes its way to the surface: gravitation, burrowing, or congestive abscess. In this manner quite long and narrow sinuses—fistulous passages—frequently develop, which are lined with a layer of granulation tissue: so-called pyogenic membrane.

Sometimes the pus remains *in loco,* is transformed by inspissation into a cheesy substance (caseation, tyrosis), and is separated from the living tissue as a dead mass by a reactive connective-tissue capsule. The caseated and encapsulated abscess very frequently is the seat of deposition of lime-salts. Much less frequently the pus is transformed by fatty metamorphosis into a readily absorbable emulsified mass.

Likewise, a phlegmon, which usually is progressive in character, may spontaneously become circumscribed, and, after discharge of the necrotic parts, gradually heal. In other instances, however, it advances and causes either death of the individual or more or less extensive destruction of the affected tissues.

Accumulation of pus beneath the horny stratum, in the lower portion of the epidermis (rete Malpighii), with partial liquefaction of the underlying epithelial layers, results in the formation of a so-called pustule.

In purulent secretion of many surfaces (pericardium, pleura, joints, etc.), marked accumulation of pus in preformed cavities may readily occur; such accumulations of pus are designated as empyema.

Pus is a yellow or greenish-yellow, cloudy, creamy, slightly alkaline fluid consisting chiefly of a liquid and pus-corpuscles (leucocytes). The liquid is closely allied to blood-serum, but contains no fibrinogen, and is rich in globulin. It not infrequently contains also mucus and flocculi or shreds of fibrin. The pus-corpuscles possess active ameboid movement; in the dead state they are usually round, slightly transparent, faintly granular, and generally contain several (2 to 7) small, round nuclei without nucleoli (so-called fragmented nucleus, polynuclear leucocytes), and fat-droplets. Some of the pus-corpuscles have a single nucleus (mononuclear). It is often observed that as far as the purulent infiltration extends the mononuclear pus-corpuscles are in excess, and that where liquefaction of the tissues already has occurred almost only cells with fragmented nuclei (polynuclear leucocytes) are to be seen.

In some cases the pus is more watery in character and poorer in pus-corpuscles. The prognosis in these forms of suppuration is usually more unfavorable, because the disposition to localization of the suppuration is less. The most malignant forms of suppuration are those accompanied by gas formation (see Gaseous Phlegmon, p. 498) or putrid, gangrenous states. These phenomena are due to especial conditions (the pyogenic agent and complications).

The causes of all suppurations are chemic—whether chemic substances, such as turpentine, croton oil, cinnamic acid, mercury, and others, or products of bacteria or the bacteria themselves. The latter, from the standpoint of the practitioner, are by far the most frequent and almost exclusive causes of suppuration. Among the bacteria, two varieties of cocci—staphylococci and streptococci—are considered to be the most frequent pyogenic agents. While *Staphylococcus pyogenes aureus* and *albus* (see p. 498) generally produce more circumscribed suppurations (pus of creamy consistency: *pus bonum et laudabile* of the Ancients), the streptococci (see p. 498) cause the above-mentioned more malignant suppurations, which have a great tendency to spread and produce a more watery pus. When a suppuration possesses an ichorous, putrid character, this condition is due to putrefactive microbes and an especial disposition of the tissues.

As a pronounced chemic action is present in suppuration, the accumulation by emigration of countless colorless corpuscles at the point of chemic action is designated as chemotaxis. According to Buchner, the chemotactic—attractive—action upon the colorless blood-corpuscles is not exerted directly by the chemic substances introduced, but by new-formed metabolic products of the tissues (proteid bodies) elaborated as the result of the action of the chemic substances upon the tissues. When chemotactic action is exerted through the agency of bacteria, it is not the excretions of the bacteria, but disintegration products from the richly albuminous bodies of the bacteria, which act in this manner. Therefore,

in bacterial suppuration the chemotactic—attractive—action is due to the proteid bodies of disintegrated bacteria as well as to the albumin bodies produced by destructive action upon the tissues.[1]

The simple introduction of pyogenic bacteria does not, however, suffice to produce a bacterial suppuration. If, for example, a pyogenic agent is injected into a vein, no infection results, because the bacteria are destroyed in the circulating blood by virtue of its bactericidal properties. In order to excite suppuration, bacteria in general must be able to locate and increase at some point, for example, in a wound. If infection occurs in this manner, its further course is essentially dependent upon two conditions: 1, the virulence of the bacteria; 2, the physic and chemic state of the tissues. There are portions of the human body in which a suppuration once established almost invariably progresses much more unfavorably than in others; and different persons are affected very differently by pyogenic agents, just as differently as by the bites of insects, so that under the same conditions of exposure to infection one individual acquires a suppuration, while another remains healthy. In many cases the resistance of the tissues may be so greatly reduced by local (crushing, etc.) or general nutritive disturbances (*e.g.*, diabetes), and, perhaps, at the same time furnish such a favorable (chemic and physic) soil for bacteria, as to render the course of suppuration especially severe and unfavorable.

In most infectious diseases the injurious action of the pathogenic agent is due to formation of substances, very susceptible to external influences, called bacterial toxins, the chemic nature of which is not accurately determined. Some of these are soluble, diffusible substances produced by the bacterial cells and, when isolated, produce the same symptoms as are excited by the pathogenic agents themselves. In a number of other infectious diseases the pathogenic action is exerted by so-called endotoxins, which can be isolated by boiling with caustic potash, *i.e.*, toxic substances intimately connected with the bacterial cells and liberated only on their death and disintegration. Here belong also the bacterial proteins, which are characterized by great resistance to high temperatures. The pathogenic bacteria are assumed also to produce substances (aggressins) which render the tissue-cells less resistant to invasion.

The solvent and histolytic (proteolytic) properties of pus have been known for a long time. Leber and others have indisputably demonstrated experimentally that the pus, and not the metabolic products of bacteria or other chemic substances, possesses the property of dissolving not only solidified gelatin and coagulated egg-albumen, but also living tissues. This solvent power, called histolysis, proteolysis, is chemic in nature and due to the action of proteolytic enzymes, which, according to recent investigations, although present in the fluid exudate, are not connected with the liquid, but with the pus-corpuscles themselves. There are also present in the exudate antiproteolytic enzymes, which tend to arrest the action of the proteolytic ferments.[2]

---

[1] According to some authorities, bacterial toxins also exert chemotactic action.

[2] S. Weil has recently shown (*Deutsch. med. Woch.*, Jan. 12, 1911, p. 66) that inflammatory pleuritic and peritoneal transudates poor in leucocytes exert upon a number of bacteria a marked bactericidal action which is the stronger the more markedly "inflammatory" the character of the transudate. In such inflammatory fluids there is accumulation of protective substances which probably are not specific but of a general nature. From this point of view, an abundant transudate is an expression of strong reaction of the organism, and thorough removal of this protective fluid would be inadvisable.

(*b*) Certain surfaces and membranes in the inflammatory state are particularly prone to generate exudative products. In the front rank stand the mucous, serous, and synovial membranes. In its capability to form exudates, the inner surface of the pulmonary alveoli resembles these, because in this locality there are many superficial vessels. Above all, it is necessary that the surface be vascular: that blood be there from which the exudate can be formed under the action of cells. Poorly vascular or nonvascular surfaces (for example, the endocardium, articular cartilages) cannot form exudates. Likewise, the intima of the arteries and veins manifests no disposition to elaborate exudates, and, hence, there is no exudative arteritis or phlebitis. The external skin would more frequently form exudates were the nonvascular epidermis absent; this holds back the exudate, so that vesicular, bullous, and pustulous affections develop in the skin, as a result of which the epidermis is elevated.

According to the character of the exudates elaborated by serous, mucous, and synovial[1] surfaces, several categories are differentiated:—

1. Mucous exudate.
2. Cellular exudate:—
   (*a*) Epithelial cells: desquamative exudate.
   (*b*) Leucocytes: purulent exudate.
   (*c*) Erythrocytes: hemorrhagic exudate.
3. Serous exudate.
4. Fibrinous, croupous, pseudomembranous, or diphtheritic exudate.
5. Ichorous, putrid exudate.

The mucous, desquamative, and purulent exudates [(1, 2 (*a*), and 2 (*b*)], limited to the mucous membranes, are generally classed as catarrhs.[2] The desquamative and mucous catarrhs constitute the milder forms. Mucous membranes provided with pavement epithelium produce chiefly desquamative catarrhs (proliferation of the epithelial cells and exfoliation in more or less large lamellæ). Thus, for example, the tongue (coated tongue), the esophagus, vocal cords, and pulmonary alveoli are distinguished by the fact that they secrete principally cells, while, on the other hand, certain mucous membranes covered with cylindric epithelium—the stomach, colon, uterus, air passages (trachea, bronchi)—produce principally mucus.[3] The bladder, conjunctiva, and middle ear also produce mucous exudates. The small

[1] The richly vascular arachnoid (in the inflammatory state: arachnitis) furnishes no free exudate, but an infiltrate; therefore, it behaves differently from the serous membranes.

[2] Catarrh, from καταῤῥέω = to flow down, because the exudate is readily movable.

[3] Ropy, more or less tenacious, frequently glairy masses which coagulate upon addition of acetic acid. The mucus is formed in the cylindric cells themselves and afterward set free upon the surface. (See Mucoid Degeneration, p. 151.)

intestine manifests only a moderate disposition to secrete mucus: catarrh of the small intestine furnishes a secretion composed principally of water and epithelial cells, though in some instances it may be seromucous or mucopurulent. Purulent exudates rarely occur in the stomach (phlegmonous gastritis) and small intestine (follicular abscess and ulcer), seldom in the colon, and frequently in the air passages. Purulent exudates are produced by the serous membranes (*e.g.,* empyema, purulent peritonitis), the synovialis of the joints (*pyarthros*), the middle ear, genitourinary passages (*e.g.,* gonorrhea, cystitis, pyelitis, pyelonephritis), conjunctiva, air passages, and rarely the *tela chorioides* and *plexus chorioidei.*

Chronic mucous catarrhs usually produce very tenacious, adhesive mucus, which readily stagnates in the excretory ducts of glands (the peptic glands of the stomach, Lieberkühn's crypts of the colon, and the glands of the cervix uteri), and by gradual local accumulation causes dilation of the glands themselves. The latter condition may give rise to small cysts, so that the mucosa contains either isolated, small, glassy cysts—*ovula Nabothii* in the cervix uteri—or is more or less densely studded with cysts: gastritis, colitis, chronic cystic catarrhal endometritis. These cysts may, like a foreign body, irritate the adjacent tissues and cause proliferation, so that as a result of proliferation the cysts protrude above the surface and develop into pedunculated formations or small, cystic polypi (colitis, chronic cystic polypoid catarrhal endometritis).

In the air passages, chronic mucous catarrhs, by continued irritation, favor calcification and ossification of the tracheal and bronchial cartilages. In the smaller and minutest bronchi chronic catarrhs sometimes produce a chronic, fibrous, obliterating bronchitis.

Under certain conditions atrophy of the glands occurs as a result of chronic mucous catarrhs, *e.g.,* of the nose and nasopharynx, so that the mucosa finally becomes dry.

Chronic catarrhs of the vagina (chronic *fluor albus,* leucorrhea) impart to the vaginal mucosa a peculiar smoothness and a dense, often leathery consistency: smooth atrophy of the vagina (*atrophia lævis vaginæ*).

In purulent catarrhs (blennorrhea) the exudate either flows downward (*e.g.,* out of the nose, vagina, urethra) or remains *in loco* (*e.g.,* in the smallest bronchi). In the latter case either caseation by inspissation or fatty metamorphosis and absorption occur.

As pus possesses the property of liquefying tissues by a kind of enzyme action (see p. 175), and, when inclosed, spreads downward by gravity or in the direction of least resistance by virtue of its infectious

properties, sacculated collections of pus (especially in the abdomen) may rupture into adjacent organs (from without inward); for example, an hepatic abscess may rupture through the diaphragm into the pleural cavity or into the lungs; a perityphlitic exudate into adjacent intestinal coils.

In **hemorrhagic exudates** the product is not alone hemorrhage, but hemorrhage plus exudate, *i.e.*, two elements. The exudate may be mucous, fibrinous, or purulent. A classic example of hemorrhagic exudate is fibrinous (croupous) pneumonia: extravasate plus fibrinous exudate. (See Fibrinous Pneumonia.)

Serous exudates occur as the initial stage of inflammation, forming in the tissue-spaces the so-called inflammatory edema, and in the body cavities (*e.g.*, pleura) inflammatory hydrops. The serous fluid contains relatively few cells (leucocytes), which may disintegrate and cause precipitation of fibrin: serofibrinous exudate.

Fibrinous, croupous, pseudomembranous, or diphtheritic exudates. The true seats of fibrinous exudates[1] are the serous membranes (*e.g.*, pleura, peritoneum, pericardium); the respiratory tract, including the nose and nasopharynx (especially in children); the pharynx; the synovialis; the alveoli of the lungs; less often the conjunctiva, middle ear, and other surfaces, *e.g.*, the mucosa of the gastrointestinal canal.

In the serous membranes the exudate may be purely fibrinous (dry: pericarditis and pleuritis sicca); usually, however, it is accompanied by exudation of serous fluid (serofibrinous exudate), and often of blood (fibrinous pneumonia). If large amounts of watery fluid or pus are exuded with the fibrin, these, when present in the pericardium, the abdominal, and pleural cavities, may produce signs of compression and interfere with the functions of the heart, the lungs, etc. In the lungs, partial atelectasis is most frequent: simple red atelectasis, when the exudate is not too large; when, on the other hand, it is very abundant: anemic compression atelectasis.

Under certain conditions fibrinous exudate of the lungs may become organized; then carnification occurs—an atelectatic, dense state of the lungs, which imparts to the latter a certain resemblance to muscle. This termination, however, is unusual; as a rule, resolution takes place; less frequently caseation, suppuration, or gangrene.

Upon mucous surfaces the exudate generally assumes the form of a pseudomembrane, which is either superficial (croup) or deep

[1] Exudation of fibrin in firm, coagulated form. The fibrin remains *in loco*, is not movable as in other exudates; this is the reason a fibrinous inflammation (*e.g.*, of the pleura) so often occurs as a localized, circumscribed process.

(diphtheria;[1] see p. 523). In the superficial form of pseudomembranous exudate there is necrosis and loss of the epithelial layer of the affected surface. The deep form is attended by more or less extensive necrosis and sloughing of the mucous membrane, particularly marked in the intestinal mucosa. In the respiratory passages the pseudomembranous development may be so exuberant as completely to occlude the lumen. The under surface of those pseudomembranes exfoliated or removed from surfaces in which the mucous membrane has not sloughed presents numerous depressions and excavations, arranged in sieve-like order, which correspond to the ostia of the mucous glands upon which it rested, and are produced by exudation of mucus which indented the pseudomembrane at these points.

In the serous membranes the fibrinous exudates are caused by the pneumococcus (lungs, pleura, meninges), streptococcus, and meningococcus (peritoneum and meninges); in the mucous membranes, particularly the diphtheria bacillus and streptococcus (respiratory tract, conjunctiva), and also other bacteria (intestine) and toxic substances (mercury: intestine).

Ichorous, putrid exudates, the most virulent forms of exudative inflammations, originate through the action of materials in a state of decomposition and containing bacteria; they are characterized by the offensive odor and the discolored appearance (*e.g.,* ozena; putrid bronchitis).

Among the **sequelæ** of exudative inflammations, ulceration and adhesion deserve especial mention.

In ulceration there is loss of substance, which is thrust off externally. The ulcer need not necessarily secrete any kind of material, *e.g.,* pus. Special forms of ulceration are: Indolent, atonic ulcer, which manifests no disposition to heal; rodent ulcer,[2] which has a progressive, more or less rapidly invading character; serpiginous ulcer, which cicatrizes at one side while it advances at another; gangrenous, necrotizing ulcer, which casts off gangrenous masses; in this case the ulcer base has the same character as the sloughed material—is not cleansed. As a rule, ulcers heal by the formation of granulation tissue, *i.e.,* young, very vascular, and richly cellular connective tissue, which forms small, red granules (granula) upon the free surface. The termination of healing (see p. 162) is always epidermization, which starts from the

[1] It is now the custom to designate as diphtheria those forms of pseudomembranous exudate due to the Löffler bacillus.

[2] The phagedenic ulcer also is a rodent ulcer which, however, extends only upon the surface.

epithelium at the margin of the ulcer. The formation of skin is sometimes prevented by too intense development of granulation tissue—so-called "proud flesh," *caro luxurians*. The scar (*cicatrix*) which finally takes the place of the ulcer develops from a primarily very vascular, soft tissue with a small amount of intercellular substance which, by gradual increase of the latter, is converted into a dense, rigid, poorly vascular, and, therefore, pale connective tissue, and with advancing condensation forms quite broad, firm sclerotic bands. Scar formation is usually accompanied by retraction; hence, the cicatrix often occupies a lower level than the surrounding parts, and sometimes has a radiate appearance at the point of junction with the healthy tissue.

Adhesion,[1] agglutination or union of two apposed surfaces, is the most frequent result of fibrinous inflammations of serous membranes. It is produced by organization of the fibrinous material. Flat and cord-like adhesions are differentiated. Partial adhesions very frequently occur between the pleuræ; complete adhesion of two apposed surfaces in their whole extent causes obliteration of the affected cavity, for example, of a pleural cavity. Fibrinous exudates, however, produce adhesions only when two apposed surfaces are inflamed and the endothelial covering destroyed; when only one side (of the pericardium, etc.) is inflamed and covered with exudate, no adhesion occurs, but, as a rule, circumscribed, tendinous thickening (*macula tendinea*), and, finally, with recurring inflammation, a callous induration (e.g., *perisplenitis callosa*).

Productive inflammation begins in the stroma[2] of the organs, *i.e.*, within the supporting substance of the parenchyma, in the form of cellular growth (proliferation) of the interstitial connective tissue, which, however, does not result in purulent softening, but in the formation of a durable, very dense, cicatrix-like tissue: induration. In this process three stages may be differentiated: 1, proliferative stadium; 2, true connective-tissue stadium, and, 3, cicatrix stadium. In the first stage is seen only a granular mass which corresponds to the nuclei of the freshly proliferated connective-tissue cells and, even on observation with lenses of medium magnification, appears roughened or distinctly granular. These young, primarily round cells develop into spindle-shaped and stellate connective-tissue cells, and thus is produced a fibrillated intercellular substance. The intercellular fibers subsequently contract, as in all pathologic new-formed connective tissue, and become more straight and elongated. Then follows (as a result of further

[1] See p. 162.

[2] The stroma (*struere:* intersperse) is composed of vessels, nerves, and accompanying or binding connective tissue.

contraction of the intercellular substance and coalescence of adjacent straight fibers) the formation of dense sclerotic bands—the termination of the process, the true cicatrix stage: cicatrization. The firmness of the new-formed connective tissue is due to the production of fibrillated intercellular substance. The more this retracts and condenses, the more the intervening parenchyma atrophies. The termination of the process, therefore, is more or less complete destruction of the parenchyma by induration and diminution in size of the affected organ (granular atrophy of the kidneys, cirrhosis of the liver, myocarditic indurations, *q.v.*).

Productive inflammation always occurs in the neighborhood of dead or foreign masses. If the foreign bodies and dead parts exert only a simple irritative action, a scanty, dense connective-tissue capsule results; if the irritation is more intense, a dissecting purulent inflammation develops, which, under certain conditions (for example, an embolus of infectious material containing bacteria), terminates in abscess (metastatic abscess in the lungs, liver, kidneys, heart, skin, etc.).

FEVER.

Fever (*febris*, from *ferveo;* πυρετός, from τὸ πυρ) is characterized by increase of the body temperature beyond the normal measure—by pathologic elevation of the animal heat—due to internal causes.[1] It is not a disease, but only a manifestation, a process occurring in the course of many diseases.[2] While the exact mechanism of fever is still unexplained, the phenomenon is assumed to be due to the action of certain soluble, so-called *pyretogenctic* substances, which, in the majority of instances, are toxins contained within or elaborated by bacteria or protozoa. To these must be added autointoxication with products of disintegration of organic constituents (injured or broken-down cells[3]), to which so-called "aseptic surgical fever" is due. In how far these toxic substances directly influence the chemic metabolism of the body or act upon the regulatory centers of the central nervous system is undetermined. Fever due to local affection of these centers, *e.g.,* in cerebral diseases, injuries, etc., is rare (Gierke).

[1] According to Galen, fever is: *calor præter naturam* (*præter:* beyond, *i.e.,* heat above the ordinary degree, due to internal causes).

[2] The temporary rise of temperature due to violent muscular movements (epileptic convulsions), insolation, etc., cannot be classed as fever.

[3] Rise of temperature may be caused by disintegration of red blood-corpuscles, by transfusion or injection of water into the blood, or in absorption of large hemorrhagic effusions: in fracture, etc.; liberation of fibrin ferment under similar conditions; after intravenous injection of physiologic secretions: milk and urine. Hypernephroma and other tumors may produce fever by formation of toxins which enter the circulation.

The average temperature of the body is generally considered as 37.2° to 37.4° C.[1] This is not constant, however, but is subject to certain variations. Usually it is lowest in the morning after the night's rest, and highest in the late afternoon hours (between 6 and 7 o'clock). It rises with muscular and glandular activity (work and digestion), and falls with strong radiation from the surface of the body to the surrounding medium. The maximum daily variation amounts to not quite 1° C. In the normal condition the temperature, by virtue of the regulatory power of the body (perspiration, etc.), never rises above 38.0° C. Temperatures of 38.0° to 38.5° C. are designated as slight febrile; from 38.5° to 39.5° C. as moderate febrile; to 40.5° C. as pronounced febrile; above 39.5° C. in the morning and 40.5° C. in the evening as high febrile, and above 41° C. to above 42° C. as hyperpyrexia.

Suppurations and tuberculosis manifest a very variable type of fever. Very frequently the fever is remittent, but it may be also continuous, and there may be afebrile intermissions. Therefore, a remittent fever of obscure origin must be always interpreted as an indication that somewhere in the body a purulent or tuberculous focus exists from which absorption of poison occurs.

As a rule, several stadia of fever can be differentiated, especially in the acute febrile infectious diseases. The initial stadium—pyretogenetic—includes the onset of the disease and its course up to the lowest of the temperatures characteristic of the high stadium (*fastigium*, acme). The first stage is short or long according as the fever rises rapidly or slowly. A sharp rise of the fever curve is almost invariably accompanied by chill. During the chill either only the musculature of the cutaneous vessels (pale, cool skin; subjective sensation of chilliness) and of the hairs (goose-skin) is contracted or spasms occur in other groups of muscles: trembling, chattering of the teeth, to the most violent attacks of shivering. The chill may last for from a half-hour to two hours. With its subsidence the second stage, the *fastigium* (acme), begins, the stage also in which the patients experience the sensation of heat. The duration of this stage varies between a few hours and several weeks. In a favorable course the third stage now follows: the stadium of defervescence—the return to the normal temperature. This may occur quite suddenly and quickly: crisis, or more slowly and protractedly: lysis. In critical decline the temperature falls abruptly to normal, usually within a few hours, accompanied by quite profuse perspiration.

---

[1] In adults, the axillary temperature is from 36.2° to 37.5° C.; the rectal and vaginal temperature from 36.8° to 38° C. In children, the temperature in these localities is somewhat higher. The blood is warmer than external parts and averages about 39° C.

Decline by lysis generally extends over many days, usually with distinct oscillations, the maximum and minimum becoming each day less than on the preceding day. The stage of convalescence, which follows the stage of defervescence, is distinguished by the fact that so long as the patient is kept in a very quiet and proper state the temperature remains normal, but on the slightest provocation is still subject to unusually great oscillations, because the regulatory forces do not as yet functionate in the same manner and as promptly as in health. Any strained movement of the body, psychic excitement, indigestible or very hearty meals suffice to call forth distinct, pathologic elevation of temperature.

In an unfavorable course, death almost always occurs in the acme (*fastigium*), sometimes without the temperature undergoing any change, but more frequently, however, under very pronounced deviations. Death is preceded either by a marked continuous rise of temperature (above 42° C.—so-called agonal elevation of temperature) or a very abrupt decline (collapse temperature[1]), or the temperature varies within very wide limits, quite sudden elevations and declines alternating with striking rapidity.

Three different types of fever are differentiated:[2] the continuous, the remittent, and the intermittent types. Continued fever is characterized by very slight daily variations; the difference between maximum and minimum does not exceed 1° C. In remittent fever these variations are more pronounced, *i.e.*, greater than 1° C. Intermittent fever consists, as it were, of a number of febrile attacks (paroxysms) interrupted by afebrile periods (apyrexia). Each single paroxysm of fever has an initial, an acme, and a defervescent stage, and runs its course within a few hours. The afebrile intervals are almost always longer than the febrile paroxysms. The latter, in spite of the intermissions, are considered as one disease, since they are due to a single cause. A quotidian, a tertian, and a quartan intermittent fever also are differentiated according as the succeeding paroxysms recur on the second, third, or fourth day after the first attack.

Many diseases have a typical fever curve (*e.g.*, typhoid, intermittent fever, etc.). The curve always manifests certain individual variations, though the essential, characteristic points are usually always repeated, so that the existence of intercurrent processes (complications, etc.) can be surmised from the occurrence of striking deviations. In the chronic

---

[1] Associated with cold, pale extremities; bluish lips and nails; flabby skin; small, irregular pulse; great prostration; cold sweat, dizziness, and slight hebetude.

[2] Recurrent fever is an especial form. (See p. 502.)

febrile affections there is no constant curve. Often, indeed, the various stadia cannot be recognized, because long-continued remissions and exacerbations alternate in a very irregular manner.

The constant and essential pathognomonic phenomenon of fever—the pathologic augmentation of the body (animal) heat—is due to increased metabolism. The whole process of tissue metamorphosis in the organism is augmented in fever. The absorption of oxygen, the elimination of carbonic acid, the excretion of urea, and the radiation of heat are increased. As digestive disturbances, nausea, disposition to vomit, and diminished assimilation of food are also present, every fever has the character of a quick consumption (most marked in hectic fever). As a result of the increased oxidation processes almost all parts of the body, not only the blood, but also the parenchymatous juices, the fat, the glands, the muscles, etc., are consumed in a more marked degree.

Recent investigations would seem to indicate that an augmentation in the total metabolism does not occur in fever. Hence, the so-called febrile consumption must in the main be referred to diminished assimilation. The degree of augmentation of O consumption in fever may be moderate, but is never entirely lacking. It cannot be reckoned in percentage because of the lack of normal comparative values. According to Rolly (*Deutsch. Arch. f. klin. Med.*, Bd. 103, p. 116), the values for O consumption in fever, except in children and immature subjects, are usually about 5 c.c. pro kilo and minute. The increased temperature may be accompanied by increased consumption of O and *vice versâ;* this parallelism between the temperature and height of O consumption, however, is inconstant. At the termination of the fever the O consumption generally declines. As the relation of the C to N is unaltered either in the urine, the body proteids or body tissues of febrile subjects as compared with the normal, the assumption that there is a qualitative alteration of metabolism in fever is untenable. Indeed, it is probable that the metabolism in fever is qualitatively the same as in the normal and that, owing to the inanition and the febrile noxæ, an increased disappearance of protein, glycogen and also of fat occurs; as a result of the increased disappearance of these substances there is augmented respiratory gas-exchange during fever. That the febrile temperature alone, when it remains within moderate limits (39° C.), causes no especial hyperoxidation of proteid substances, has been shown by Rolly and others by investigation of the N excretion.

Although localized alterations which stand in undeniable relation to the fever are observed in many febrile diseases (*e.g.*, pneumonia, typhoid, erysipelas), the local processes by no means suffice to explain the fever. The circulatory disturbances always associated with fever, the increased frequency of the respiratory and cardiac movements, the disturbances of the digestive tract, the marked disturbance in the nerve-centers (stupor, delirium, etc.), the rapidity of onset of some febrile attacks, and the quick control of the latter by antipyretics (*e.g.*, quinine), which act not only upon the lymph-glands (causing leucocytosis) and

the infectious germs (hemamebæ in malaria), but also upon the nervous system—all these unquestionably indicate a cause located in the nervous center, even though the substance irritating the nervous system is found in the blood (*e.g.*, septic material, metabolic products of bacteria, ptomaines). At all events, the process is always chiefly a disturbance of the regulatory centers of metabolism, caused perhaps by the action of toxalbumins.

After protracted, but especially after very high and violent, fever, cloudy swelling of the myocardium, kidneys, gastric mucosa, liver, and body muscles is generally found at necropsy. The relation these parenchymatous cloudy changes bear to the fever as such, *i.e.*, to the high temperature, has not as yet been definitely determined. There is, however, a general disposition to assume that the myocardium may be so influenced and finally so organicly altered by fever that death occurs as the result of cardiac weakness.

MALFORMATIONS.

UNDER malformations are comprised all those faulty, abnormal formations of the whole body or of its parts which are due to defective intra-uterine Anlage or to a departure from the normal intra-uterine development: *vitia primæ formationis.* Insignificant deviations which produce no very striking difference of form or shape and no disturbance of function are designated as simple anomalies, while those malformations associated with very decided disfigurement of the external form are called monstra (τέρατα). Three great groups are generally differentiated—*monstra per defectum, monstra per excessum,* and *monstra per fabricam alienam*—which again are divided into a greater or lesser number of subdivisions, in accordance partly with their origin, partly with their external conformation.

As to the causes of malformations, little that is positive is thus far known. Three theories are advanced to explain the origin of malformations: 1, the pathologic theory, according to which pathologic processes in the embryo are supposed to give rise to malformation (Morgagni); 2, the embryologic theory (Meckel, Geoffroy), according to which all manifestations are to be considered as the result of arrest of development, and, 3, the mechanic theory, according to which mechanic effects (pressure, traction, etc.) are assumed to be the causative elements. It is certain, however, that many simple anomalies are decidedly hereditary, *e.g.,* supernumerary fingers. In other cases, pathologic states have been positively demonstrated, as, for example, adhesions between amnion and fetus; and, finally, there are also a number of observations which demonstrate that mechanic conditions, for example, constriction of fetal parts by the amnion, may be the cause of malformations.

MONSTRA PER DEFECTUM

are malformations characterized by incomplete organization.

I. Defect is the most prominent characteristic: **simple malformations.**

A. Lack or arrest of development of large portions of the body:—

1. *Amorphus, acardiacus amorphus:* formless mass covered with skin.

2. *Mylacephalus:* vertebræ, ribs, pelvis, intestine, and usually also kidneys present; no heart; extremities indicated; cephalic end also is indicated by a sometimes hirsute protuberance.

3. *Acephalus:* lower part of the body with one or two extremities, with various large parts of the spinal column; sometimes with upper extremities, also with rudimentary head. Thorax, if present, always open anteriorly; heart always absent. The other internal organs may be present or absent.

4. *Acormus,* devoid of trunk: rudimentary head with imperfect brain, without trunk. Insertion of funis in cervical region.

B. Lack or arrest of development of individual parts.

(a) Head:—

1. *Acrania* (*kranioschisis*): Defect of the roof of the skull, mostly associated with anencephalia, defect of the brain, and adermia; partial defect of the skin. The base of the skull is greatly shortened. Originates through flat synechia of the fetal head with the amnion, or as a result of a fetal hydrencephalocele. (See III, B, 1.) Acrania is sometimes also associated with pseudoencephalocele (*q.v.*).

2. *Hemicrania:* Rudimentary frontal, occipital, and parietal bones. Brain rudimentary or absent; in the latter instance it is usually associated with pseudoencephalocele.

3. *Microcephalus:* too small brain in consequence of premature synostosis of the cranial bones.

4. *Cretinismus:* too short cranial basis from premature ossification of the sphenobasilar synchondrosis. (Compare goiter and premature synostosis.)

5. *Cyclopia* (*monopsia*): both orbital cavities approach each other, or both eyes lie in one orbital cavity (originated by confluence of both), or one eye (by coalescence of both) lies in the middle line of the head in one cavity. In higher grades the ethmoid, septum narium, and vomer are absent. Chiasma and optic tract are preserved or lacking. Individual parts of the brain are lacking (convolutions, corpus callosum, olfactory nerve), or it ends anteriorly as a simple vesicle. Pons and cerebellum are usually present; also medulla oblongata.

6. *Agnathia:* absence of the inferior maxilla or lack of the inferior maxillary processes of the first branchial arches. As a rule, the superior maxilla, palatine processes, and sphenoid bones also are undeveloped; the ears approximated to contact on the under surface: *synotia.* Sometimes agnathia and cyclopia coexist.

7. *Aprosopus* (*schistoprosopus*): greater or smaller parts of the face are wanting (*e.g.,* nose, mouth, eyelids) as a result of incomplete

formation of the first branchial arch. In the middle line of the face a fissure, so that oral and nasal cavities are not closed. Inferior maxilla present.

(β) Vertebral column, spinal cord, thorax:—

1. *Amyelia:* general or partial defect of the spinal cord; originates through hydromyelocele. (See III, B, 1.)

2. Absence of individual ribs, vertebræ.

(γ) Pelvis and extremities:—

1. *Amelus:* absence of all extremities.

2. *Peromelus:* all extremities are deformed.

3. *Phocomelus:* hands and feet are situated directly upon the shoulders or hips, respectively.

4. *Micromelus:* abnormally small extremities.

5. *Abrachius:* upper extremities wanting.

6. *Perobrachius:* defective forearms and hands situated upon normal upper arms.

7. *Microbrachius:* one or both arms well developed, but too small.

8. *Monobrachius:* absence of one upper extremity. Here must be included defects of individual bones of the upper extremities; most frequently the radius is absent, less often the clavicle or scapula.

9. *Sympus,* siren formation: coalescence of both inferior extremities; pelvis and sacrum defective; urethra and rectum without opening.

10. *Apus:* absence of lower extremities or short stumps.

11. *Monopus:* defect of one lower extremity. The corresponding half of the pelvis lacking, often also abdominal wall (prolapse of viscera).

12. *Peropus:* arrested development of one or both lower extremities.

13. *Micropus:* abnormally small inferior extremities. Here are to be included defects of individual bones of the lower extremities; most frequently the fibula or patella is absent. Absence of individual fingers or toes (*perodactylia*) not infrequently occurs; coalescence of fingers and toes also is frequently observed (*syndactylia*).

(δ) Internal organs, viscera: Absence of whole organs is frequent in malformations without head and heart. Complete absence of individual organs occurs also in other instances.

Absence of the nose (or proboscis-like prominence) in cyclopia.

Absence of the lungs in absence of the diaphragm, in fetal hydrothorax.

Absence of the lips: *achelia.*

Absence of the tongue: *aglossia,* mostly in agnathia.

Absence of the gall-bladder: an abnormally dilated *ductus hepaticus* then exists.

Absence of one kidney: simultaneous compensatory hypertrophy of the other. Both suprarenals present.

Absence of the suprarenals, especially in defective development of the brain.

Absence of the urethra: in cloaca formation.

Absence of the urinary bladder: ureters open directly into the urethra.

Absence of one or both ovaries.

Absence of the uterus.

Absence of one or both Fallopian tubes.

Absence of the external female genitalia.

Absence of the vulva alone.

Absence of the hymen alone.

Absence of one or both mammary glands; frequently with simultaneous costal defects.

Absence of breast nipples.

Absence of the prepuce.

Absence of the penis.

Absence of one or both testes: *monorchia, anorchia.*

Absence of the epididymis.

Absence of the seminal vesicles.

Absence of the pericardium: in ectopia cordis.

Partial defect occurs in the brain: *e.g.*, lack of the corpus callosum.

Absence of the septum narium (only one, often abnormally small, nasal cavity).

Absence of the inferior turbinate bone.

Absence of the epiglottis.

Absence of the upper section of the esophagus and blind ending of the pharynx.

Absence, partial, of the trachea in communication with the esophagus.

Absence of the tracheal cartilages, mostly with abnormal coalescence.

Absence, partial, of the lungs, with compensation through the other lung.

Absence of the *frenulum linguæ* in adhesion of the tongue to the floor of the oral cavity; too short frenulum.

Absence of the middle section of the esophagus with sacculated dilation of the upper end; frequently with simultaneous communication with the trachea.

Absence of the lower portion of the intestine, of the colon, of the rectum.

Absence, partial, of the urethra in epispadia, hypospadia (displacement of the opening of the urethra to the under surface of the glans or of the shaft up to the root of the penis).

Absence, partial, of the hymen: cribriform hymen and *hymen fimbriatus* (notched hymen), abnormally wide and hiatiform hymen.

Absence, partial, of the seminal ducts.

Absence, partial, of the prepuce: too short frenulum, too narrow opening of the foreskin (phimosis).

Absence, partial, of the heart:—

1. Arrested growth at a very early stage of development (about the first fetal month).

(*a*) Simple muscle sac with *venæ cavæ* as a result of persistence of the undivided embryonal truncus arteriosus (*cor biloculare*).

(*b*) Ventricle with arteries and auricle with *venæ cavæ*.

(*c*) Two auricles, one ventricle; aorta simple (incomposite), gives off pulmonary veins (*cor triloculare biatriatum*).

2. Septum defects with deviations in development of the arterial ostia.[1] The *truncus arteriosus communis* (primitive aorta), which originally served for aorta and pulmonalis, is divided into aorta and pulmonalis by the formation of a septum. The formation of this septum occurs at about the same time as, and in dependence upon, the *septum atriorum* and *septum ventriculorum*. Hence, defects of the *septa atriorum et ventriculorum* and deviations of the ostia frequently coexist, deviations in the formation of the *septum trunci arteriosi communis* being accompanied by deviations in formation of the *septum atriorum* and *septum ventriculorum*. In deviations in the formation of the *septum trunci* (aortic septum) resulting from false position, defective development in wrong direction, unequal halves are produced which are associated with stenosis formation, atresia, or false position of the aorta and of the pulmonalis. The latter is more frequently affected by atresia or stenosis than the aorta. The following forms are differentiated:—

(*a*) Auricular defects.

(*b*) Ventricular defects, and in these again are differentiated defects of the whole anterior septum: large defects of the (usually preserved) pars membranacea up to the anterior wall of the heart, with deviated position of the aorta far to the right, and defects in the posterior part of the anterior septum. These septum defects may be combined with:—

[1] For complete absence of the heart, see p. 187.

(α) Stenosis or atresia of the pulmonalis, and stenosis of the conus pulmonalis. (See Fig. 37.) In stenosis of the ostium pulmonale the pulmonalis is abnormally narrow; ductus Botalli usually open. The whole anterior ventricular septum is lacking. In atresia of the ostium pulmonale the anterior ventricular septum is likewise absent. Both ventricles empty the blood into the aorta. Ductus Botalli open. Foramen ovale open. Pulmonalis cord-like, solid. In congenital conus stenosis the conus of the pulmonalis is, as it were, separated from the right

Fig. 37.—Stenosis of the conus pulmonalis of the right ventricle and partial defect of the septum carneum ventriculorum. ⅔ natural size. (After *Langerhans.*)

ventricle by a narrow space. The posterior portion of the anterior septum of the ventricle is absent. Ductus Botalli closed. Foramen ovale open.

This conus stenosis may readily be complicated by other anomalies: defective auricular septum, aorta stenosis, transposition of the large vascular trunks, atresia or stenosis of the mitral.

(β) With stenosis or atresia of the aorta. Here the whole anterior ventricular septum, or only a part below the ostium aorticum, is lacking. Foramen ovale remains open. Pulmonalis is wide, communicates with the descending aorta.

3. Stenoses or atresia of the arterial and venous ostia without septum defect.

(*a*) Stenosis or atresia of the pulmonalis without defect of the ventricular septum as a result of abnormal division of the *truncus arteriosus communis* with normal position of the arterial trunks. Right ventricle either rudimentary in early disturbance or even dilated and thickened in later developing disturbance. Foramen ovale and ductus Botalli open.

(*b*) Stenosis or atresia of the aorta without defect of the ventricular septum. Pulmonalis communicates with the aortic arch. Ascending aorta serves as trunk for the coronary arteries. Ductus Botalli wide open, usually also foramen ovale. Left ventricle small, narrow, usually undeveloped. Left auricle narrow.

(*c*) Stenosis of the aorta in front of the ductus Botalli: persistence of the fetal isthmus aortæ between point of origin of the left subclavian and ductus Botalli.

(*d*) Stenoses or atresias of the venous ostia as a result of abnormal formation of the auricular septum.

4. Septum defects without alteration of the ostia: persistence of the foramen ovale and breaches in the septum ventriculorum close beneath the *ostium aorticum*.

5. Transposition of the large vascular trunks. Normally, the septum trunci divides the fetal *truncus arteriosus communis* from the left and behind into two halves: to the left in front (pulmonalis), and to the right behind (aorta). Transposition of the great vessels is produced as a result of defective Anlage of the septum trunci, the latter dividing the truncus from the right anteriorly into a half lying to the left anteriorly (aorta), and a half lying to the right posteriorly (pulmonalis). In this case the blood flows out of the right auricle through the right ventricle into the aorta, and from the left auricle into the pulmonalis. The foramen ovale and ductus Botalli are usually open. Sometimes septum defects coexist. Transposition of the large vessels occurs chiefly in *situs inversus*, dextrocardia. Transposition of the arterial trunks and of the ventricles is designated as corrected transposition of the large arterial trunks (observed in dextrocardia).

6. Defective development of the valves: increase or diminution in the number of valves: most frequently two or four semilunar valves. (See Fig. 38.)

C. Abnormal smallness.

1. Dwarf formation (*nanosomia, microsomia*): developed individuals under 112 cm. (3.9 ft.). Trunk and head are usually dispro-

portionately large. Sometimes, however, all parts are properly proportioned.

2. Abnormal smallness of individual parts: of the heart and arterial vascular system (hypoplasia of the heart, aorta, and arteries in chlorotics); of the lungs (in hernia of the diaphragm and location of the abdominal viscera in the thorax); of the brain (in microcephalics); of the spleen, thyroid, lips (*microchelia*), tongue, (*microglossia*), frenulum linguæ, stomach, intestine (abnormally short), uterus, Fallopian tubes, mammary glands, penis, testes, or of all the male sexual organs (generally with simultaneous absence of the pubic hair and beard), fingers, toes, and ear.

II. Arrested development characterized by disturbance of the normal evolution of the originally rightly established germ. No defect but

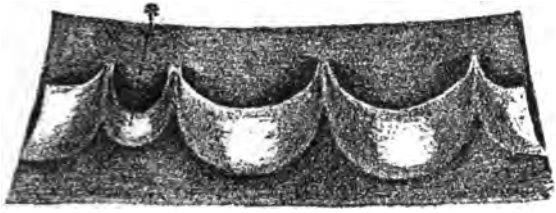

Fig. 38.—Four pulmonary valves of a 55-year-old man. Natural size. (After *Langerhans.*)

evolution of the primary Anlage without adherence to the normal direction.

1. Formation of two or three kidney pelves as the result of unusual confluence of the originally separate reniculi to form one kidney; also lateral position of the renal pelvis.

2. Coalescence of all reniculi to form one kidney: horseshoe kidney (*renes arcuati*). The union of both kidneys generally occurs at the lower pole, seldom at the upper; is sometimes associated with low position of the kidney.

3. Communication of the trachea with the esophagus. (See I, B.)

4. Communication of the rectum with vagina and urethra, etc. (See Cloaca Formation.)

5. Multiple sexual formation: *Hermaphroditismus.* (See also Male and Female Generative Organs.)

There is a *hermaphroditismus verus* and a *hermaphroditismus spurius.* In true hermaphroditism the generative apparatus of an individual contains both male and female germinal glands; in false hermaphroditism (*pseudohermaphroditismus*) there is a combination of male

(or female) generative canals with female (or male) external genitalia, respectively.

There are three forms of true hermaphroditism:—

1. *Hermaphroditismus verus bilateralis:* testes and ovaries on both sides.

2. *Hermaphroditismus verus lateralis:* a testicle on one side and an ovary on the other side.

3. *Hermaphroditismus verus unilateralis:* testicle or ovary on one side; testicle and ovary on the other side.

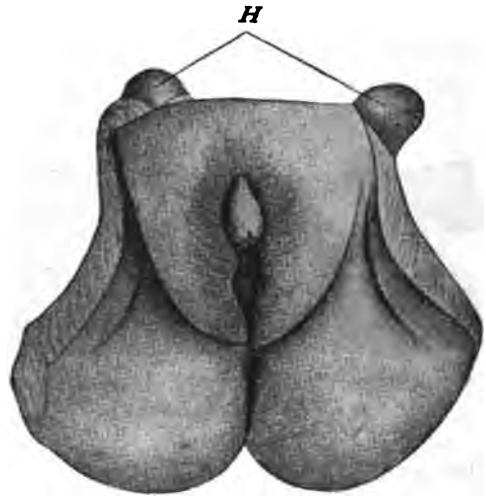

Fig. 39.—Pseudohermaphroditismus masculinus externus. *H*, testes. ⅔ natural size. (After *Langerhans.*)

There are two forms of spurious hermaphroditism: *pseudohermaphroditismus masculinus* and *femininus*:—

1. Masculine pseudohermaphroditism (with testes) is divided into three subdivisions:—

(*a*) Complete: testes, generative canals (tubes, uterus, vagina), and external genitalia female.

(*b*) External: testes, generative canals male; external genitalia alone female. (See Fig. 39.)

(*c*) Internal: persistence of Müller's duct (rudimentary vagina, uterus, tubes); testes and male external genitalia.

2. Feminine pseudohermaphroditism (with ovaries) also is divided into three subdivisions:—

(*a*) Complete: ovaries; persistence of the Wolffian ducts; external genitalia with male type.

(*b*) External: ovaries; internal female generative canals; external genitalia alone have male type.

(*c*) Internal: ovaries and external female genitalia; persistence of the Wolffian ducts.

In the cases of true hermaphroditism thus far observed male and female generative organs capable of function were not present, the testes or ovaries being in an atrophied condition. The majority of pseudo-hermaphrodites belong to the male sex. The indefiniteness of the Anlage of the generative organs and of the whole external appearance (voice,

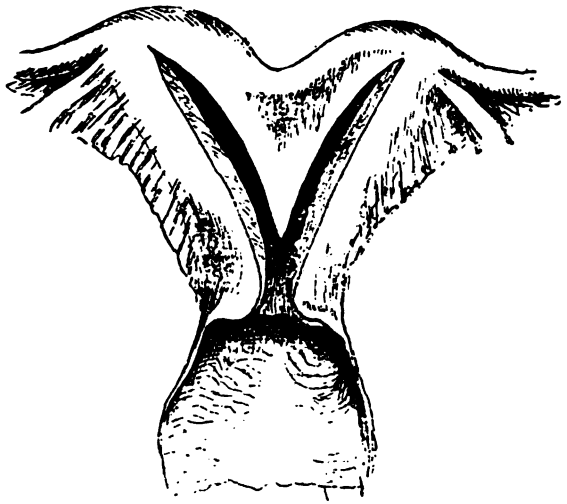

Fig. 40.—Uterus bicornis. 20-year-old servant girl. ⅔ natural size. (After *Langerhans.*)

beard, mammæ, sexual inclination) is characteristic of pseudohermaphroditism. Hence, this explains why male hermaphrodites have been reared as females, and, *vice versâ,* why male hermaphrodites have been married as females.

III. Arrested developments in which maturing of the embryonal state was interrupted. **Arrest in the embryonic stage of development** is the characteristic feature.

A. Duplication of the uterus and vagina as a result of incomplete union of Müller's ducts (which is said to begin in the second fetal month. [See Male and Female Sexual Organs.]) or as a result of their maturity. Complete lack of the uterus and its appendages (lig. rotunda, lata and tubes) is very seldom observed; usually a solid rudiment is to be found. Coalescence of Müller's ducts to form the uterus and vagina (tubes remain separate at the insertion of

the lig. rotunda) begins in the middle from the eighth week on; coalescence to form the vagina is sooner accomplished than that of the uterus.

Absence or arrest of development of one of Müller's ducts produces *uterus unicornis,* as the other side only is developed. In *uterus duplex* both Müller's ducts are developed, but are not united with each other or are united only at the cervix; then either two uteri or one collum with two diverging corpora uteri are produced: *uterus bicornis.* (See Fig. 40.) In partial union (viewed externally) to form one uterus and persistence of the apposed surfaces, *uterus septus* originates. (See Fig. 41.) The septum may persist only in the corpus or in the corpus and

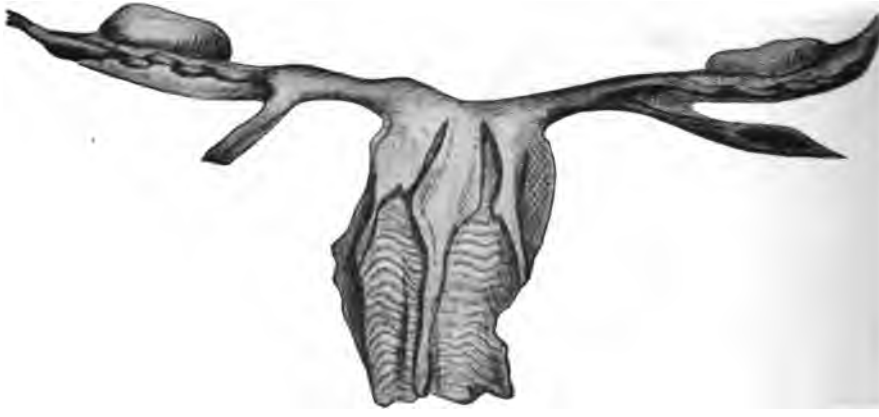

Fig. 41.—Vagina septa et uterus septus. Natural size. (After *Langerhans.*)

collum, or even in the vagina. *Uterus fœtalis,* or *infantilis,* is simple arrest of development, a cessation of growth in the fetal stage of evolution: normally formed, very small uterus, the collum of which is about twice as long as the corpus. On the other hand, an abnormally small uterus the cervix and body of which are about of equal length, and whose wall is thin and flabby, is designated as *hypoplasis uteri.*

B. Cleft or fissure formation: Most cavities and canals of the body are originally in the form of plates, but in the first month they are transformed into grooves by inversion of the margins. From these develop cavities and canals, the margins growing toward each other and finally uniting. If coalescence is arrested, the cavities or canals remain open and form clefts of the lips, jaws, palate, neck, trachea, intestine, bladder, skull, spinal column, thorax, and abdomen. Cloacæ formations: abnormal communication between anus, bladder, and generative tracts are also arrested developments, for, in the earliest period of embryonal life, there is normally a free communication. In

the fourth week of embryonal development, cloacal orifice is the common opening of the intestine, urachus, and of the later urinary bladder, into which the Wolffian ducts also empty. Cloacal opening does not disappear until the middle of the third month onward, when the individual ostia become differentiated.

1. Clefts of the skull and spinal column (*cranioschisis, rachischisis,* and *craniorrhachischisis*) are, in a small number of cases, traceable to embryonal adhesions between the amnion and fetus. In the majority of instances they are due to disturbances of the central nervous system or of its membranes, which, according to most authorities, are induced or caused by primary aplasia of the spinal column and musculature. Edema of the cerebral and spinal arachnoid (*meningocele* or, better, *hydromeningocele cerebralis* and *spinalis*), or ectases of the ventricles of the brain or of the central canal of the medulla spinalis (*hydrocele cerebri* or, better, *hydrencephalocele,* and *hydrocele medullæ spinalis* or, better, *hydromyelocele,* also called hydrorrhachis interna cystica), either prevent union of the posterior vertebral arches or, by pressure, cause atrophy (absorption) and perforation of the bones. In rare cases spina bifida is a pure spinal hydromeningocele, as a rule, only in the lower portion of the spinal cord: *hydromeningocele spinalis sacralis* or *lumbosacralis;* if it is situated higher, the condition is generally called *hydromyelocele.* This is generally associated with a very marked arrest of development, frequently with complete interruption of the spinal cord. The spinous processes are usually absent in spina bifida. Sometimes *fissura vertebralis—spina bifida anterior*—coexists. As a rule, the bulging sac of spina bifida has a funnel-shaped depression at the center. This is the point which is adherent to the lower end of the spinal cord. Hydrencephaloceles (with and without atrophy of the brain) are usually situated in the middle line (*hydrencephalocele occipitalis, palatina,* etc.), most frequently in the *squama occipitalis* (the spinous process of the occipital vertebra), and are then usually complicated with *spina bifida atlantica* (of the atlas) or *cervicalis.* By bursting of a hydrencephalocele and hydromyelocele there is always complete destruction of the affected portion of the central nervous system: general or partial *anencephalia* or *amyelia.* If the collapsed sac of the hydrencephalocele is very vascular, it forms a red, spongy mass at the base of the skull: *fungus cerebri* or *pseudoencephalocele* (*cerebrum spurium*).

2. Clefts of the lips, jaw, and palate: Cleft palate (split or fissured palate; *palatum fissum,* complicated harelip, wolf's jaw: *rictus lupinus*): *cheilognathopalatoschisis,* develops unilaterally or bilaterally as a result of defective union[1] of the superior maxillary,

[1] Normal in the eighth to ninth week.

and the palatine processes of the first branchial arch with the anterior end of the frontal process, the intermaxillary, and the nasal septum or the vomer. The fissure extends through lip, superior maxilla (between canine and external incisor teeth), and palate; the soft palate and the uvula are divided in the middle; an open communication exists between nasal and oral cavities. Cleft palate occurs alone as well as in connection with thoracic and abdominal clefts. The upper lip and maxillary process (between canine and incisor teeth) alone may be cleft uni- or bi- laterally, the superior and inter- maxillary not having united. This cleft may extend to the nostril.

In harelip (fissured lip, *labium leporinum*), either a groove or a fissure, which may extend to the nostrils, is present in the region between canine and incisor teeth. Harelip occurs more frequently upon the left than upon the right side; it is often bilateral.

3. *Fistula colli congenita* (called also tracheal fistula) is an opening situated, either laterally or medially, about 2.5 cm. above the sternoclavicular articulation at the inner margin of the sternocleidomastoid muscle. The opening is very small and leads to a blind-ending passage, lined with mucous membrane (ciliated epithelium), which is sometimes sacculated. The lateral fistula is traceable to arrested closure of the third and fourth branchial clefts; the median to defective union of the third and fourth branchial arches.

4. Thoracic and abdominal clefts always lie in the anterior median line of the trunk. If the whole thorax and abdomen to the navel are cleft as a result of arrested union of the visceral plates, the thoracic and abdominal viscera are prolapsed. In fissure of the chest alone (*thoracoschisis*), ectopia cordis usually exists. The slightest degree of thoracic cleft is *fissura sterni*. Congenital abdominal fissure (*gastroschisis*) may extend from the manubrium to the symphysis, or (inclosed thorax) from the xyphoid process to the symphysis or the navel. In the latter case congenital umbilical hernia exists: omphalocele, or *hernia funiculi umbilicalis*.

If abdominal fissure extends to the symphysis, cleft of the bladder also exists, because the posterior portion of the allantois cannot close to form the bladder wall.

5. Cleft of the bladder: *ectopia vesicæ urinariæ* (*inversio vesicæ urinariæ*), is characterized by the fact that the posterior wall of the bladder lies exposed in a fissure of the abdomen. Sometimes the urethra also is cleft and forms an open channel which runs upon the upper surface of the penis: *epispadias*. As a rule, fissure of the bladder is associated with incomplete union of the symphysis; frequently

with defect of the clitoris, vagina, atresia of the vagina, and arrested development of the penis.

6. Intestinal cleft: *fissura intestinalis congenita,* is a rare complication of abdominal fissure. In this condition, as in vesical cleft, the open cecum or ascending colon is seen in the abdominal fissure.

7. Cloacæ formation: To be distinguished are cloacæ formation:—

(*a*) With clefts of the abdomen and bladder: viscera prolapsed, inclosed by a sac at the lower end of which is located the cloacal opening. Intestinal opening situated above in the middle of the cloaca; colon terminates blindly or is absent; ureters open into the bladder, and alongside of these also the seminal vesicles or, in the female, the separated Müller's ducts.

(*b*) With clefts of the bladder: intestinal opening in the center of the cleft urinary bladder; laterally the openings of the ureters and seminal ducts or vagina.

(*c*) In closed urinary bladder: anus absent (*atresia ani*); rectum communicates with the urinary tract or genital canal.

8. *Hernia peritonealis congenita.* Congenital hernias of the peritoneum are characterized by displacement of the abdominal viscera. They are produced by protrusion of the peritoneum at a feebly resistant point in the abdominal walls, an aperture or cleft thus originating in the abdominal parietes. The protruded portion of the peritoneum is called the hernial sac, and the constricted portion, which unites the hernial sac with the abdomen, the hernial orifice or portal (hernial aperture).

In the abdomen, external and internal hernias are distinguished. External hernias are visible externally, and originate by protrusion of the abdominal wall. Internal hernias are not perceptible externally.

External hernias are: external and internal inguinal, crural, ischiadic, perineal, vaginal, foraminis ovalis, umbilical, and abdominal.

Internal hernias are: diaphragmatic, retroperitoneal (duodenojejunal), and mesenteric.

Most of these are acquired. The following are congenital:—

(*a*) External inguinal hernia (external to the epigastric artery; here also runs the spermatic cord).

(*b*) Umbilical hernia; in the fetal state a loop of the ileum lies within the navel opening.

C. Atresiæ.[1] These originate by the originally solid parts remaining solid, no lumina developing—not being transformed into canals: atresiæ of the pylorus, intestine, ureters, urethra, Fallopian tubes, uterus,[2]

[1] Atresia, from ἀ = privativum, τρῆσις (τιτράω = penetrate).
[2] More frequent at the external than at the internal os.

vagina, and hymen; or by the skin not folding in to unite with existing canals: atresia oris (*astomia*), ani (usually combined with atresiæ of the vagina, urethra, or of the ends of the spermatic ducts); or by adhesion of existing ostia: atresia of the vulva, nose, aural canal, vagina, and hymen (either the whole vagina is absent or only a part, in consequence of obliteration of Müller's ducts; sometimes an occluding transverse wall is present immediately behind the hymen).

D. Various other embryonal conditions without consonant characteristics:—

1. Meckel's diverticulum of the intestine is a congenital dilation (sacculation) of the intestine, a remnant of the omphalomesenteric duct from the period of communication of the intestine with the umbilical vesicle. Meckel's diverticulum is situated in the lower segment of the ileum, upon the convex side opposite to the mesenteric attachment, about one meter above the ileocecal valve. It is sometimes connected with the navel by a cord—the obliterated omphalomesenteric duct.

2. Cryptorchidism is the fetal condition: location of the testes in the abdomen; oftener unilateral than bilateral. From the third month onward descent of the testicles is said to begin, and in the seventh month the testes are assumed to enter the processus vaginalis. Cryptorchidism is usually associated with *microrchidismus.*

3. Congenital luxations, displacement of the heads of bones from their sockets as a result of incomplete formation (arrested development) of the sockets.

4. Club-foot, *pes varus;* flat-foot, *pes valgus, planus,* and horse-foot, *pes equinus,* as well as the combinations *pes equinovarus* and *equinovalgus* and *pes calcaneus* (hook-foot) and *talipomanus* (club-hand). In club-foot the external margin of the foot is directed downward, the sole inward; in *pes valgus* the internal margin of the foot downward and the sole more outward; in *pes equinus* (called also tip-foot) the sole directed backward, the dorsum forward; in *pes calcaneus,* heel downward, sole forward. The fetal position of the feet corresponds to about that of *pes varus;* in the newborn also this position is still plainly to be seen. The correct position is assumed through axial rotation when the habit of walking is being acquired. Here, therefore, we have to deal with a persistence of a fetal condition—arrested development or an exaggeration of a fetal state. Congenital club-foot, like other congenital anomalies of position, develops also as the result of the action of abnormal pressure under special conditions. Club-hand, *talipomanus,* is produced by rudimentary development of the radius.

MONSTRA PER EXCESSUM

are malformations characterized by excessive and supernumerary development.

I. Excessive Formation:—

1. Giant growth, gigantism, *macrosomia,* is either manifest before birth or begins only after birth. Giant formation affects chiefly the skeleton, the muscles, etc. The generative function is very frequently impaired.

2. Abnormal size of individual parts: Acromegaly (Marie): Enlargement of the extremities and tapering parts of the human body—the hands, feet, nose, lips, chin, tongue; later the lower limbs, the lower portions of the forearms, and the lower maxilla. The hypertrophy affects the bones and soft parts, begins in youth or middle age, and is always associated with great muscular weakness, disturbances of sensibility, headache, and defective memory, impairment of vision, and anemia. Anatomicly, distinct enlargement of the hypophysis is observed in many cases. According to the observations of Friedreich and Erb, this affection occurs also in several members of the same family. According to von Recklinghausen, it is a disease of neurotic origin.

Fig. 42.—Abnormal length of the uvula. At * flat verrucæ. Natural size. (After *Langerhans.*)

Macrocephalia; hydrocephalus (apparent enlargement of the brain; in fact, atrophy exists); *macroglossia* (frequent in cretins); *macrotia; macrodactylia; dermatocele adnata* (excessive development of skin; sacculated, folded skin); excessive size of the thyroid, thymus (*asthma thymicum*); abnormal length of the omentum, mesentery (sometimes results in volvulus and incarcerations), intestine, ureters, clitoris, ovaries, testes, penis, and uvula. (See Figs. 42 and 43.)

3. Abnormal hairiness (*hirsutio adnata, hypertrichiasis,* e.g., of pigment-marks) and abnormal development of pigment, *e.g.,* in *nævi pigmentosi.*

II. Multiple Formations:—

A. Double malformations: *monstra duplica,* twin malformations; *heteradelphia:*[1] general or partial duplication of the body.

[1] *Heteradelphia,* from ὁ ἕτερος = the other, and ἀδελφός = brother.

Either both bodies are uniformly developed or one is defective and, as it were, forms a parasite of the more or less normally developed autosite from which it receives its nourishment. It is now generally assumed that double malformations develop from one ovum, and are formed upon one yolk. As regards the further development, there are two theories: the fission theory and the adhesion theory. Observations are chiefly in favor of the former theory.

(α) Duplications of the upper end of the body: *terata anadidyma.*

Fig. 43.—Clitoris hypertrophy and precocious hirsuteness in a 9-year-old girl. Photograph. (After *Langerhans.*)

1. *Diprosopus,* double face: One body with two connected, incomplete heads (defective brain).

2. *Dicephalus,* double head: One trunk, two heads. (See Fig. 44.)

3. *Ischiopagus:* Two upper bodies with a common pelvis, and two or four lower extremities.

4. *Pyopagus:* Two almost completely separated bodies; only sacrum and coccyx, rectum, and sometimes also vagina single.

(β) Duplications of the lower end of the body: *terata katadidyma.*

1. *Dipygus:* Double lower body, single head.

2. *Syncephalus* (*janiceps*): Two individuals united at the trunk and head.

3. *Craniopagus:* Two individuals united at the roof of the skull (frequently at the vertex).

(γ) Duplications of the upper and lower ends of the body: *terata anakatadidyma.*

1. *Prosopothoracopagus:* Skull cavities separated: lower jaws united; thorax and neck merge into each other.

2. *Thoracopagus:* Union at the thorax of two otherwise completely separated individuals (Siamese twins: Chang and Eng).

3. *Thoracoabdominopagus:* Union at the thorax and abdomen. (See Fig. 45.)

Fig. 44.—Dicephalus. (*Leishman.*)

Fig. 45.—Thoracoabdominopagus. (*Leishman.*)

4. *Epignathus: prosopothoracopagus parasiticus: fœtus in fœtu.*[1] The parasite is connected with the oral cavity of the autosite (usually at the hard palate), protrudes from the oral cavity.

5. *Epigastrius: thoracopagus parasiticus: fœtus in fœtu.* The parasite is connected with the autosite at the ensiform process (as far as the navel).

6. *Engastrius:* Abdominal inclusion of a parasite.

7. *Rhachipagus:* Union of two individuals at one point only of the spinal column. Head, neck, a part of the thorax, and lower extremities double.

[1] *Fœtus in fœtu* signifies that a fetus is grown over by a second fetus and is, therefore, inclosed within the latter: *inclusio fœtalis.* In addition to the above-mentioned fetal inclusions occur: *inclusio subcutanea, mediastinalis, testiculi, ovarii, cerebralis.*

B. *Monstra triplica:* Triple monsters are extremely rare.

C. Multiple formation of the extremities: —

1. *Polymelia:*[1] The number of whole or half extremities is increased.

2. *Polydactylia:* The number of fingers or toes is increased. This malformation—better, anomaly—is quite frequent and hereditary.

Fig. 46.—Thoracoabdominopagus, with ectopia viscerum. (*Sheffield.*)

D. Multiple formation of individual organs:—

Excess of the bones of the skull: Wormian bones, *ossa intercalaria, os incæ.*

Excess of the vertebræ: caudal formation (originates more frequently through enlargement of the coccygeal vertebræ).

[1] τὸ μέλος = limb.

Excess of the ribs, especially through division of the ribs (costal cartilages and costal bones) normally present.

Excess of the muscles.

Excess of the toes.

Excess of the nails: in multiplicity of the fingers and as a result of division of the nails.

Excess of the lungs (three lungs).

Excess of the lobes of the lung: *lobi accessorii.*

Excess of the lobes of the liver: *lobi accessorii.*

Excess of the bronchial trunks (three bronchial trunks).

Excess of the cartilages in the trachea.

Excess of the intestine: duplication of the cecum and of the vermiform process.

Excess of the thyroid: three lobes, *lobus accessorius,* starting from the isthmus and reaching to the hyoid bones; and *thyreoidea succenturiata* at the upper or lower ends of lateral cornua.

Excess of the mammary glands: *polymastia;* scattered mammary glands in the region of the axilla, thorax, inguinal region, back, thigh.

Excess of the nipples: *polythelia* (according to the theory of descent or evolution, is frequently considered as atavism).

Excess of the pancreas: *pancreas succenturiatus* and accessory lobes which inclose the duodenum, and occur also in the jejunum.

Excess of the bladder, through formation of a septum: *vesica bipartita.*

Excess of the ureters: two or three, when two or three renal pelves are present in one kidney. (See p. 193.)

Excess of the urethra.

Excess of the ovaries.

Excess of the tongue.

Excess of the spleen: supernumerary spleen, *lien succenturiatus* in the gastrolienal ligament.

Excess of the suprarenals: upon or in the kidney, or in the course of the *vasa spermatica interna* to the true pelvis.

Excess of the renal pelvis: through abnormal embryonal coalescence of the reniculi.

Excess of the ductus choledochus: duplication.

MONSTRA PER FABRICAM ALIENAM.

Monstra per fabricam alienam are malformations caused and characterized by changes of position.

1. *Situs transversus, inversio viscerum:*—

This rare displacement quite accurately represents the **negative** of the normal position.

2. Displacement of individual organs:—

Displacement of the heart to the right: *dextracardia.*

Displacement of the heart externally: *ectopia cordis* in *fissura thoracica.*

Displacement of the urinary bladder: *ectopia vesicæ urinariæ* in *fissura abdominalis.*

Displacement of the spleen, stomach, liver, and intestine in *hernia diaphragmatica congenita* and in *fissura abdominalis.*

Displacement of the ovaries in the inguinal region or in the labia majora: *descensus anomalis ovariorum.*

Displacement of the left kidney: abnormally deep position in the true pelvis, at the margin of the latter, at the *fovea inguinalis.*

Displacement of the cecum to the left side.

Displacement of the descending colon in the middle or through the radix mesenterii.

Displacement of the greater lobe of the liver to the left.

TUMORS.

THE idea conveyed by the term tumor cannot accurately be defined; tumors do not constitute a distinct group according to their nature and peculiarities. Many inflammatory swellings formerly classed with the tumors have for obvious reasons recently been excluded. This is due chiefly to the removal of former difficulties of diagnosis in many swellings. For definite reasons, all swellings and enlargements in which there is liability of error in diagnosis are designated as tumors. As the most varied formations are called tumors, a scientific division of them is possible, as Virchow has shown, only from an anatomicogenetic standpoint. Virchow says the first and most important question is always: "How does the tumor originate?" From this anatomicogenetic standpoint, Virchow distinguishes three great groups:—

I. Extravasation and exudation tumors.
II. Dilation and retention tumors.
III. Tumors originating by proliferation.

All proliferation tumors, that is, tumors in a strict sense, are composed not of specific elements, but of the same constituents as the body; they develop from the tissues of the body, forming a connected part of it, and are, therefore, subjected to the same conditions and laws as the body itself. Their histologic constituents sometimes correspond to the type of tissue in which they originate; sometimes they deviate from the type of the matrix tissue. The former variety of tumor is called homologous; the latter, heterologous. The terms homology and heterology, therefore, refer to the relation of the tumor to the matrix. For example, a lipoma in adipose tissue is an homologous tumor; a lipoma located in the arachnoid is an heterologous tumor. Tumors the cells of which differ from those normal to the part in which they develop are called heterotopous.[1]

In general, the homologous tumors, which, strictly speaking, represent only local proliferations or hyperplasias of the normal tissues, correspond to the benign, and the heterologous to the malignant, tumors. The malignancy of tumors depends chiefly upon the formation of new, similar foci in distant organs (metastases, generalization).

[1] ἕτερος, other; τόπος, place.

Homologous tumors are local, usually manifest no tendency to form metastases, and for this reason are benign; occasionally, however, they may acquire accidental malignancy as the result of secondary disturbances (pressure upon the vessels and nerves, etc.) produced by them. Heterologous tumors differ in their malignancy (not all are malignant). The more closely the type of the tumor resembles the type of tissue in which it originates (an osteoma cell, for example, is closely related to connective tissue, because bone also belongs to the group of connective substances), the less is its malignancy; the more it deviates from the matrix, the greater is the disposition to metastatic formation. Furthermore, among tumors of similar nature, the most malignant are always those which are highly vascular and succulent.

While, in general, homologous tumors are benign, this is not always the case, because even simple myomata may assume a malignant character: destroy the adjacent tissues and form metastases. Hence, the malignant or benign character of a tumor cannot with absolute certainty be determined by its histologic structure alone. In the great majority of cases, however, the malignancy of a tumor is shown by its heterologous structure.

Most tumors originate from one focus, *i.e.*, are unicentric; rarely they develop from a number of foci: multicentric. When a tumor originates within a tissue, it displaces the adjacent parts (expansive growth), forming rounded or irregular nodules, or, like the roots of a tree (see p. 271), it sends prolongations into the surrounding structures, penetrating and filling the interstices: infiltrating growth. There are tumors, however, which are diffuse from their inception, form more or less uniform depositions in the organs, and produce in them condensations and protrusions. The so-called basement substance (stroma[1]) generally originates as the result of secondary proliferation of the connective-tissue structure of the organ in which the tumor develops. A certain amount of connective-tissue stroma, which carries the afferent and efferent vessels, is present in all tumors. This stroma is not especially marked in tumors composed of connective tissue, but in neoplasms consisting principally of bone, muscle, etc., it is more distinct, being most pronounced in tumors of an epithelial nature, in which the epithelial constituents are designated as parenchyma and the connective tissue as stroma.

The formation of metastases is dependent upon secondary infection; the original tumor, that is, the parent nodule, forms a focus of infection, from which new germs (cells) are disseminated.

---

[1] στρῶμα = a bed.

Metastases may take place by way of the lymph-channels (involvement of adjacent lymph-glands in the direction of the lymph-current), or by the blood-vessels (involvement of distant organs: generalization), or by direct dispersion of germs (dissemination) independently of the lymph- or blood- vessels, *e.g.*, in the peritoneal or pleural cavity: transplantation or implantation metastases.

Tumor metastases frequently develop in the immediate neighborhood of the primary focus: regional metastases. In rupture into veins metastases may occur in different parts of the body: lungs, liver, etc. In persistence of open foramen ovale or in retrograde transport, other localizations may occur by the blood-channels. Infection may occur also by direct contact: contact carcinoma (one lip upon the other or one labium of the vulva upon the other). Giant-cells, chorionic villi epithelia, and cells from the placenta may be conveyed by the blood.

In contrast to metastatic formation stand local progression (focal growth) and recurrence in loco. Local progression by continuity or by contiguity consists in the formation of new foci—small, young nodules—in the periphery of the old focus. In the beginning, these daughter-nodules are separated from the parent-nodule; gradually, however, as the result of further growth, contact, and coalescence, they unite to form one mass. This is the usual mode of growth of malignant tumors. Therefore, in order to make an exact microscopic examination of a tumor, it is necessary always to examine also the younger, peripheral, zone.

Recurrence takes place by eruption of new tumor-nodules at the site of operation from germs which have not been removed.

The question as to what constitutes the real carrier of infection in local progression and metastases has not as yet been satisfactorily determined. It is certain, however, that there is a cellular contagium. Tumor-cells have repeatedly been shown to be carriers of infection in metastases, and mostly in blood-vessels. In dissemination, tumor-cells can with certainty be accepted as the true semina. According to all recent investigations, it is at least questionable whether, in addition to conveyance by cells, it is possible for infection to occur also through the agency of a juice elaborated by the tumor-cells themselves, as was formerly assumed. The tumor-cells act at the site of metastasis as seed, multiplication—proliferation—of the transported cells resulting in the formation of a new tumor-nodule. Each metastatic nodule then becomes a new focus of infection, from which, in turn, the impulse to the formation of new tumor-nodules may be given. In carcinoma of the stomach, the first

metastases are generally observed in the nearest epigastric lymph-glands. These take up and retain the injurious cells (germs) and thus, at first, serve as a protection against further advance of the affection; as soon, however, as they become so far involved by the carcinoma tissue that the germs (cells) can no longer be retained, the lymph-glands nearest to them always become involved. Such involvement in gastric carcinoma may extend upward to the subclavicular lymphatic glands and downward to the inguinal glands.

In regard to **etiology**, two points are of essential importance: 1, the local exciting cause (*causa occasionalis*), and, 2, local predisposition (*causa prædisponens*). The latter is frequently hereditary, and may be congenital (*nævi*) or develop at a later period of life (carcinoma of the uterus at the climacteric). This predisposition depends partly upon a marked tendency to disease—upon a certain vulnerability in the presence of noxious influences. On the other hand, local predisposition may be acquired through antecedent general and local disturbances. Thus, in later periods of life, tumors manifest a certain disposition to develop in scars and birthmarks (particularly melanotic nevi). Furthermore, those parts of the body which, from their position and structure, are subjected to a frequent traumatism and irritation are especially distinguished by a tendency to tumor formation. To these belong particularly the margins of the orifices of the body. Finally, abnormal position, for example, retention of the testes within the abdominal cavity or in the inguinal canal, is also to be mentioned as an etiologic factor in the development of malignant tumors. (See Carcinoma, p. 272.)

The various forms of tumors manifest a predilection for certain localities, which are characterized particularly by their histologic structure, position, and form. On the other hand, there are certain organs and parts of the body which very rarely become the seat of tumor formation, that is, which possess a certain degree of immunity.

In general, a certain antagonistic relation exists between those organs attacked by primary and those attacked by secondary tumor formation. The liver, lungs, kidneys, and serous membranes are pre-eminently the seat of secondary tumors, seldom of primary, and, *vice versâ*, the skin, the mucous membranes, the uterus, etc., are almost always attacked by primary tumors, very rarely by secondary.

In every tumor different stages can and must be distinguished. Most tumors originate as the result of active, irritative processes, and, accordingly, begin with an irritation stage. The stimulus which leads to the irritation may be external or internal, but, in order to produce specific products, it must always differ in its nature and energy from inflammatory stimuli. The malignant tumors are found chiefly in

those organs which are most exposed to external irritation, namely, in organs upon the surface. The stage of irritation, just as in inflammation, passes by cellular proliferation into the stage of granulation. In other cases this granulation stage is lacking, inasmuch as elements originate by hyperplasia which fully preserve the peculiarities of the primary elements. The granulation stage is succeeded by that of differentiation, in which the characteristic peculiarities of a tumor become plainly manifest, and following this comes the fluorescent stadium. This is determined by the cells having reached the acme of development, that is, a stage in which further progressive development is no longer possible. The cells may persist in this stage of highest development, and form durable and permanent constituents of the body, or they have a shorter period of existence, a transitory character, and, after a more or less brief time, perish by retrogressive metamorphosis (necrobiosis, softening, inspissation, caseous metamorphosis, and calcification). Certain tumors (*e.g.*, lymphomata) are characterized by the stability, others (*e.g.*, carcinomata) by the instability of their elements. Between these are the most varied transition forms. Passive, retrogressive metamorphoses are the cause of the ulceration which occurs in tumors of superficial parts. If this takes place early, the ulcer may become such a dominant feature (*e.g.*, in the early stage of gastric carcinoma) as almost totally to obscure the character of the tumor.

The majority of malignant tumors, like the benign, are at first quite latent, so that frequently the patients become cognizant of their condition only after an advanced stage is reached (*e.g.*, ulceration, putrefaction). All forms which are associated with ulceration, putrefaction, great loss of tissue, disturbances of digestion, severe hemorrhages, and loss of fluids lead more or less rapidly to the development of a cachectic state, which, finally, is the cause of death.[1]

Tumor cachexia probably is due to disturbance in the so-called "internal secretions," the neoplasm producing injurious and probably ferment-like bodies, and imparting them to the body juices. It is not improbable that this cachexia deprives the body of the ability to render displaced tumor-germs (cells) innocuous, and, therefore, these can form metastatic tumors.

I. EXTRAVASATION AND EXUDATION TUMORS.

For the most part these have a cystic character. They originate from accumulation of such materials as are derived immediately from the blood—extravasations (hematomata)—or from accumulation of

[1] In the absence, of course, of intercurrent events.

exuded watery fluids, consisting of water, salts, a certain part of the albuminates of the blood-serum, and fibrin: hydroceles, hygromata.

Hematomata originate partly in connection with traumatism (all cephalhematomata, hematoma of the vulva, othematomata), partly as the result of inflammatory processes (*hæmatoma duræ matris, retro-uterinum, hæmatosalpinx;* many muscle hematomata), and partly from other local causes.

Cephalhematoma (*tumor cranii sanguineus,* cranial blood-tumor) is an affection of the newborn. It is produced during passage of the fetal head through the narrow portions of the maternal pelvis, when the soft parts covering the bony cranial vault—generally over one of the parietal bones—are strongly compressed, crushed, or contused. Certain vessels of the tender and more yielding, richly vascular internal layer of the periosteum are thus readily injured, so that *hemorrhagia per rhexin* is produced. The extravasate accumulates between the bone and the periosteum, and detaches the latter. The hemorrhage generally ceases on the second or third day after birth. The extravasate remains fluid and is gradually absorbed; at the same time, the periosteum in the neighborhood of the hemorrhage, *i.e.,* at that point where it is still connected with the bone, begins to proliferate and produce new bone substance, which gradually increases until an osseous ring or wall is formed around the soft, fluid blood-mass. By progressive new formation of bone, this ring becomes a bony shell, which, after complete absorption of the extravasate, finally comes in contact with the bone denuded of periosteum.

Hæmatoma vulvæ is most frequently produced during parturition, and, like cephalhematoma, owes its origin to mechanic action. It differs from the latter, however, in that the extravasate penetrates and more uniformly infiltrates the tissues, and does not form a kind of cyst as in cephalhematoma.

Hæmatoma vaginæ develops as the result of rupture of a hemorrhoidal vein; *hæmatoma ovarii* results from obstruction, stasis (interruption), of the venous current. In both these conditions the tissue is infiltrated and infarcted with blood, but no spaces filled with blood are formed.

Hæmatoma glandulæ suprarenalis develops in the medullary substance, and may destroy the latter more or less, so that it forms a kind of cyst, which is completely surrounded by cortical layer. The cause of the hemorrhage is unknown. This hematoma is observed most frequently in the newborn, especially in cases in which death has occurred suddenly. As in these cases there frequently is no other anatomic alteration than the hematoma, it is possible that the sudden occurrence

of death is closely connected with *hæmatoma suprarenale.* At present, however, it is impossible to form a positive conclusion in this regard.

Othematoma (*hæmatoma auriculæ*) is sometimes preceded by certain pathologic alterations of the cartilage (inflammatory, partial softenings), caused by nutritive disturbances or antecedent violence, which especially predispose to destruction on receipt of trauma. Accordingly, the hemorrhagic effusion enters between the cartilage and perichondrium, as well as within the cartilage itself, when fractures occur. Hence, fragments of cartilage not infrequently adhere to the perichondrium. The hemorrhage generally occurs at the inner side of the auricle and forms rounded swellings of doughy consistency. In the process of healing of othematoma, a permanent deformity of the auricle results; with absorption of the extravasated blood, a reactive perichondritis accompanied by cicatricial retraction takes place, which draws the auricle inward toward the auditory canal, producing at certain points irregular distortion. This deformity, as Gudden and Winkelmann have shown, is constantly to be observed in ancient statues of boxers and wrestlers. This demonstrates that othematomata or their sequelæ were known even to the ancients. In the beginning of the past century othematoma was a frequent phenomenon in the insane (it was usually located upon the left ear), and was probably due to the less humane treatment of the insane of that period.

Hæmatoma duræ matris begins as an independent inflammatory process of the dura mater with production of a fibrinous exudate upon the inner surface. (See *Pachymeningitis interna fibrinosa vasculosa hæmorrhagica,* p. 590.) By organization and vascularization, the exudate is transformed into a richly vascular layer of connective tissue. The new-formed vessels are very delicate and readily bleed on variations of blood-pressure, and in congestion and fluxion. As a result of frequent recurrences and organization of the new extravasates, the new-formed layer upon the inner surface of the dura may gradually increase in thickness, the contiguous hemisphere becoming at the same time somewhat flattened. When the fibrinous layer and the delicate vessels traversing it thus become more and more concealed by the extravasates, and apparently only hemorrhagic masses adhere to the inner surface of the dura—*i.e.,* when the inflammatory character of the process is no longer recognizable—the condition is designated as *hæmatoma duræ matris.* The hemorrhages within the hematoma are sometimes so voluminous that death occurs from pressure of the extravasate upon the brain.

Hæmatoma retrouterinum develops, analogous to hematoma of the dura mater, from circumscribed exudative inflammation of the peritoneum in Douglas's *cul-de-sac* (in men, in the retrovesical fossa, though

less often). In this case, also, the fibrinous exudate becomes organized and vascularized; the hemorrhages which follow and are situated within the new-formed tissue layer take place, as in the dura mater, from the delicate, thin-walled, new-formed blood-vessels on variations in blood-pressure. The hemorrhages are sometimes so extensive that large blood-tumors, distinctly palpable during life, develop, which completely obscure the beginning of the process and the origin of the hemorrhage.

Hæmatoma uteri polyposum generally has a polypoid form and often a comparatively thin, slender pedicle. It is invariably due to antecedent parturition or abortion, and always develops at the point of placental attachment. It develops gradually, new blood-masses exuding and enlarging the polypus. The external portions of the larger polypi of this nature are usually quite firm; the interior generally consists of superimposed lamellæ of fresh, dark-red masses of blood. These hematomata distend the body of the uterus and, when they have grown larger, also dilate the cervix in funnel form (downward), and sometimes protrude from the os as rounded bodies. The growth is generally accompanied by quite profuse metrorrhagia.

The development of muscle hematoma is always associated with rupture of muscle. As a rule (in acute infectious diseases, particularly in typhoid fever), the rupture is referable to antecedent inflammatory changes (parenchymatous myositis, waxy degeneration). In some cases, however, hemorrhage occurs without inflammation, *e.g.*, in bleeders (*hæmophilia*). In instances due to external, traumatic influences (laceration, stretching, etc.), pathologic alteration of the contractile muscle substance has usually provided an especial disposition to rupture, for in intense stretching of normal muscle the tendon tears more readily than the muscle substance. Muscle hematoma occurs most frequently in the lower portion of the rectus abdominis muscle in typhoid fever. In more or less severe effusion of blood and after longer or shorter duration, a reactive connective-tissue capsule generally develops in the region of the extravasate. The blood-mass subsequently diminishes in size by contraction. A quite dry, amorphous, brownish-red content is then found within a capsule.

The accumulation of a primarily clear fluid within a closed cavity is designated as hygroma. The space in which the fluid accumulates is either a natural, preformed cavity of the body or a new-formed cavity. To the first group belong: *hydrocele scroti* (hydrops of the scrotum, *hernia aquosa;* see Male Sexual Organs); *hydromeningocele cerebralis* and *spinalis* (*lumbosacralis* or *spina bifida*); *hydrencephalocele* (*occipitalis, frontalis, palatina,* etc.), and *hydromyeloccle.* (See Malformations, under Fissures of the Skull and Spine,

p. 197.) To the second group belong: *hygroma duræ matris; bursæ,* and ganglions (*hygromata*).

II. DILATION AND RETENTION TUMORS.

These, also, have a cystic character. They originate as the result of accumulation of materials in a pre-existing space. The secreted materials are elaborated in a particular manner, some secreting organ exercising a special action upon their composition; they are chiefly liquid or they contain an excess of organized elements or a combination of both. Cystic ectasis of the space involved progresses in accordance with the amount of accumulating secretion. The accumulation occurs either at the seat of secretion (*e.g.,* in the true secreting portion of a gland) or in a locality distinctly removed from the point of elaboration (*e.g.,* in the excretory duct of a gland). In all instances retention occurs in pre-existing, open spaces, generally in ducts. The cause of retention is either mechanic obstruction—constriction (stricture, stenosis)—or closure (obliteration, atresia by agglutination or adhesion, compression, valve-like closure) of the ducts, or it is due to a peculiarity of the excreted material, generally to such a tenacious, viscid, and adhesive consistency that, although the ducts are open, the secreted material cannot be expelled.

In the beginning the retained materials usually preserve their characteristic peculiarities. Later, the character of the cystic contents may be completely altered both in form and chemic composition.

To the retention tumors belong[1]: atheroma of the external skin; milium; comedones; acne; mucous cysts of the cervix and body of the uterus, the stomach, the colon, and air passages; *hydrops processus vermiformis; hydrops cystidis felleæ; hydrops tubarum; hydrops folliculorum ovarii; hydrometra;* cystic bronchiectasis and trachectasis; *diverticulum vesicæ urinariæ; hydrops cysticus renum;* hydronephrosis; *ranula pancreatica, sublingualis, parotidea;* spermatocele, and galactocele.

III. THE PROLIFERATION TUMORS.

This group of true neoplasms developing from proliferating tissue is divided according to the histologic structure into:—

1. Histioid tumors.
2. Organoid tumors.
3. Teratoid tumors.

[1] To avoid repetition, only an enumeration will be given in this place. For the more minute details, see the descriptions accompanying the different organs.

In structure the histioid tumors correspond to a simple tissue, the organoid to an organ, and the teratoid to a whole system of the body. With these three forms are to be classed also the so-called "combination tumors," in which several tumor forms are combined.

1. The Histioid Tumors.

The histioid tumors are made up principally of a simple tissue, which belongs either to the family of connective substances or to the lymphatic structures, or is composed of more highly developed tissues (muscles, nerves, vessels).

FIBROMATA, CONNECTIVE-TISSUE TUMORS.

Fibromata (*tumores fibrosi*) consist of ordinary connective tissue. They are local formations which, with few exceptions, originate from connective tissue and are, therefore, regarded as benign tumors. They have an irritative origin and occur in the external skin, in the periosteum, in the fascias, in mucous, serous, and synovial membranes, and in various organs. In many tumors of this nature the epidermis covering them is quite markedly involved.

Fibromata occur (*a*) in diffuse, elephantiasic, or (*b*) in circumscribed, nodular, tuberous, or (*c*) in warty, papillary form. These three forms are not sharply separated from each other, but frequently coexist in one and the same tumor.

The elephantiasic (diffuse) form may be acquired, inherited (congenital), or endemic. The endemic variety is observed only in tropic and subtropic zones, where it attacks principally the natives. The lower extremities (elephant legs) are by far the most frequent seat; next in frequency come the genital organs (of these the scrotum is most often affected); sometimes, also, the upper extremities, while the trunk and face usually are exempt. (See Filaria Sanguinis.)

Elephantiasis arabum, pachydermia, begins as an acute inflammation of the skin, which closely simulates erysipelas. The skin swells, accompanied by febrile phenomena, and acquires a very dense, edematous character, which, however, differs markedly from ordinary doughy edema by its greater and firmer consistency. As in erysipelas, the swelling spreads rapidly over a large area of the skin. This is early associated with lymphangitis (shown by hot, painful, hard, red striæ in the course of the lymph-current) and acute inflammatory swelling of the lymph-glands (lymphadenitis). The latter is so marked as to produce mechanic obstruction to the lymph-current, causing congestion of lymph and dilation of the lymph-channels, which often extend to the papillæ. The

connective-tissue cells, as well as the epithelia of the small lymph-vessels, proliferate. If such a part is incised, a clear liquid exudes, which behaves exactly like lymph, *i.e.*, contains only fibrinogen substance and, therefore, coagulates only after contact with air (lymphatic edema). The fibrinous substance owes its presence partly to lymph-stasis, the exuded and exhausted materials not being removed; partly, also, to local inflammation in the root area of the lymphatic vascular system.

If such attacks repeatedly recur in the same localities, permanent thickening and condensation of the tissue gradually supervene. This is the beginning of elephantiasis in a strict sense. On incision, such a part appears occupied by very dense, broad, white, frequently almost tendinous bands, and is infiltrated with a clear, yellow, sometimes somewhat viscid mass. In many cases the condensation and thickening are confined to the surface; in others they extend to deeper parts, involving the adipose tissue, muscles, and even the periosteum. In the first instance the surface of the skin is rough, due principally to hypertrophy of the papillæ: *elephantiasis papillaris seu verrucosa;* in the other cases the tumefaction is more uniform, so that the surface may be quite smooth: *elephantiasis lævis.* If the process extends irregularly, tubercles and nodules develop: *elephantiasis tuberosa, nodosa.* As a rule, the epidermis also proliferates; sometimes the rete Malpighii is the seat of intense pigmentation: *elephantiasis fusca et nigra.* The longer the process lasts, the more the normal tissues—adipose tissue, nerves, and muscles—disappear, being substituted by sclerotic connective tissue containing clear serum. This is also the cause of the anesthetic form. Wherever the periosteum is involved in the process, new osseous tissue is formed, which sometimes has a smooth, sometimes a roughened, spiculate surface: hyperostoses and exostoses. Here not infrequently fusion of neighboring bones (*e.g.*, of the tibia and fibula) takes place. Although elephantiasis is generally characterized by its slight disposition to ulceration, it may ulcerate as a result of trauma, therapeutic interference, and occasionally also spontaneously by bursting of vesicles or by excoriations (rhagades) from which at first clear lymphatic fluid is discharged: *elephantiasis ulcerosa.*

The hard form of elephantiasis, thus far described, is distinguished from the soft forms, which are partly acquired, partly congenital. The congenital soft variety is found extensively in monsters with incomplete circulation, which are incapable of living. Partial congenital elephantiasis, on the other hand, occurs also in the viable newborn. This soft form consists of excessive, congenital proliferation of the fetal subcutaneous mucous tissue or adipose tissue (*polysarcia*) in the later period of fetal life.

Sometimes the vessels (veins, more rarely the lymphatics) are so greatly developed that the whole mass assumes a cavernous appearance: *elephantiasis teleangiectodes.*

Acquired soft elephantiasis has its seat of predilection in the external genitals, especially the scrotum, and the labia majora.

Fibroma molluscum is very closely related to elephantiasis. This is a connective-tissue tumor of loose structure out of which a clear, yellowish, richly albuminous fluid can be expressed. It consists of a very fine fibrous network divided by coarse bands into smaller and

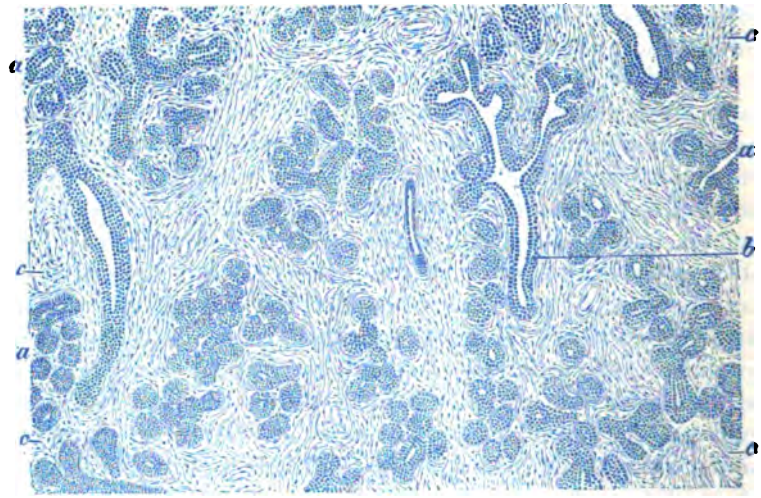

Fig. 47.—Adenoma mammæ acinosum. *a*, gland acini; *b*, gland ducts; *c*, connective-tissue stroma. × 30. (After *Ziegler.*)

larger lobules. Between the very fine fibrillæ is found the expressible fluid. The smaller tumor-nodules of this nature belong chiefly to the cutis; the larger extend into the panniculus adiposus. In contradistinction to elephantiasis, they develop without inflammatory or febrile phenomena.

A process analogous to interstitial inflammation of other organs—*e.g.,* to interstitial nephritis—but which is generally classed with the tumors, occurs in the mammary gland. This is interstitial mastitis, which, as a diffuse process, sometimes results in atrophy and induration of the whole organ, or, as a partial (lobular) focus, sometimes leads to the formation of small, dense nodules. Diffuse interstitial mastitis, or *fibroma mammæ diffusum,* begins with proliferation of the connective-tissue stroma of the whole gland, and with

further progress leads to the formation of a very contractile intercellular substance, which gradually destroys the function of the breast by compression of the parenchyma. Finally, generally after several years, the gland is converted into a small, very hard, and painful fibroma, which is very troublesome and may easily be mistaken for scirrhous mammæ. For this reason this form of mastitis, like *mastitis interstitialis partialis s. lobularis,* is regarded as a tumor.

In partial interstitial mastitis (*fibroma mammæ tuberosum s. lobulare*) a number of small, hard, almost cartilaginous nodules fre-

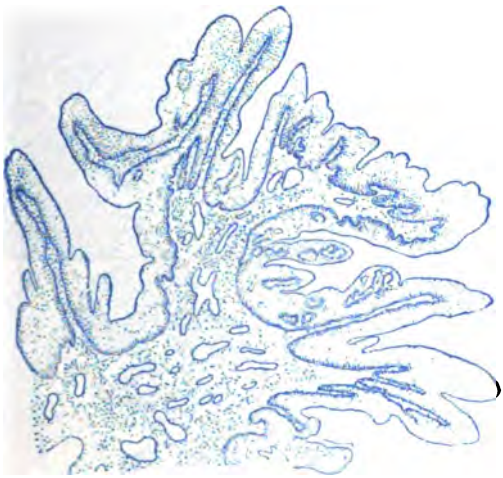

Fig. 48.—Papilloma (acuminate condyloma). (*Smaus.*)

quently develop, which are freely movable or, if a mild, general interstitial mastitis coexists, immovable, in which instance they arouse the suspicion of scirrhous carcinoma. Because fibroma tuberosum occurs in multiple form, it may apparently return after extirpation, new nodules subsequently developing from foci which were too small to be palpated at the time of operation.

An analogous form of fibroma occurs in the kidneys, localized interstitial inflammation resulting in the formation of a nodule which is generally the size of a millet or hemp seed. This fibroma is observed in otherwise normal kidneys, as well as in such affected with general interstitial nephritis. In the latter instance it represents, as it were, a local increase (excess) of the general process.

Papillary, warty, villous fibroma develops in membranous surfaces and in the smaller ducts. It begins as a flattened protuberance or as a small, round, button-like nodule. If villi or papillæ are nor-

mally present, these form the starting point by enlarging, sending forth solid villous prolongations, and, finally, dividing and branching in dendritic form until the surface of the tumor assumes a cauliflower-like appearance. Where no physiologic papillæ or villi are present, pathologic villi at first develop, from which, as the process advances, similar dendritic branchings then proceed. To these warty, connective-tissue excrescences belong the Pacchionian granulations; *endocar-*

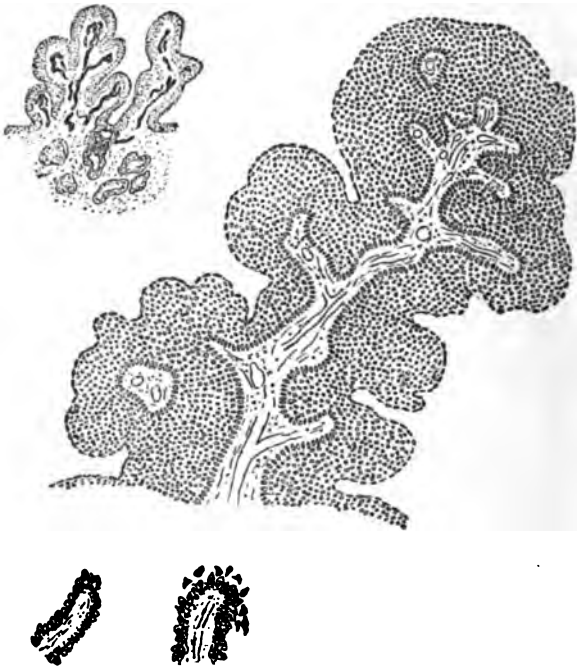

Fig. 49.—Benign papilloma of the bladder. (After *Kaufmann.*)

ditis verrucosa, papillaris villosa; the nodular and warty fibromata of the surface of the liver, spleen, ovaries, testes, *synovialis,* gall-bladder, urinary bladder, and others. All these formations begin with increase of the connective tissue, *i.e.,* with cellular proliferation, and gradual increase of intercellular substance. In some no vessels are to be found; in others vessels grow in from the base of the tumor after it has reached a certain size.

The Pacchionian granulations in their growth not only break through the dura, but produce also deep atrophic depressions in the internal table, and occasionally even in the external table of the

vault of the cranium. They always develop from the arachnoid, are generally situated on the convexity near the longitudinal sinus, and occur independently or in conjunction with uniform fibrous thickening of the arachnoid. They sometimes grow into the sinuses, just like the fetal villi of the placenta into the maternal placental sinuses.

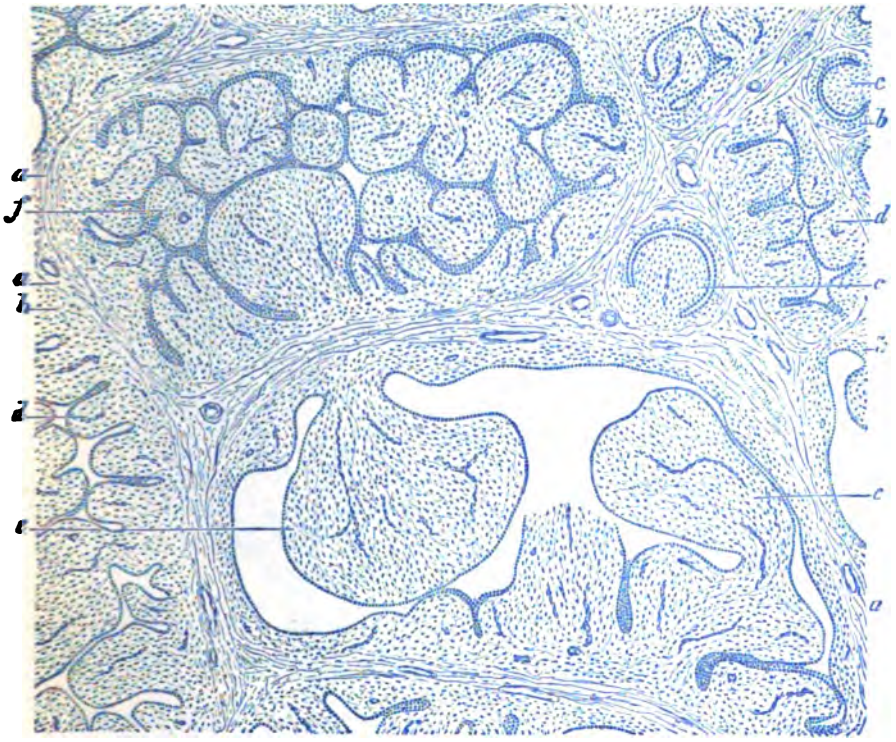

Fig. 50.—Intracanalicular fibroma. *a*, dense intercanalicular fibrous tissue; *b*, richly cellular pericanalicular tissue; *c*, *d*, *e*, nodular intracanalicular proliferations in longitudinal section; *f*, intracanalicular proliferations in transverse section. × 25. (After *Ziegler*.)

To the vascular papillary fibromata belong the so-called papillary tumors (*fibroma papillare*) of the urinary bladder, which may give rise to very exhausting hemorrhages, and frequently are mistaken for villous carcinoma.

Subcutaneous, or **follicular, condyloma** grows from the walls of the hair follicles, and may frequently be forced to the surface by pressure.

Villous tumors of smaller ducts—of the bile-ducts and milk-ducts—behave like those previously described. In the bile-ducts they cause complete interruption of the discharge of the bile, and severe and often fatal icterus.

Fibroma papillare intracanaliculare mammæ gradually fills, distorts, and distends the milk-ducts with very hard fibrous masses of oval, round,

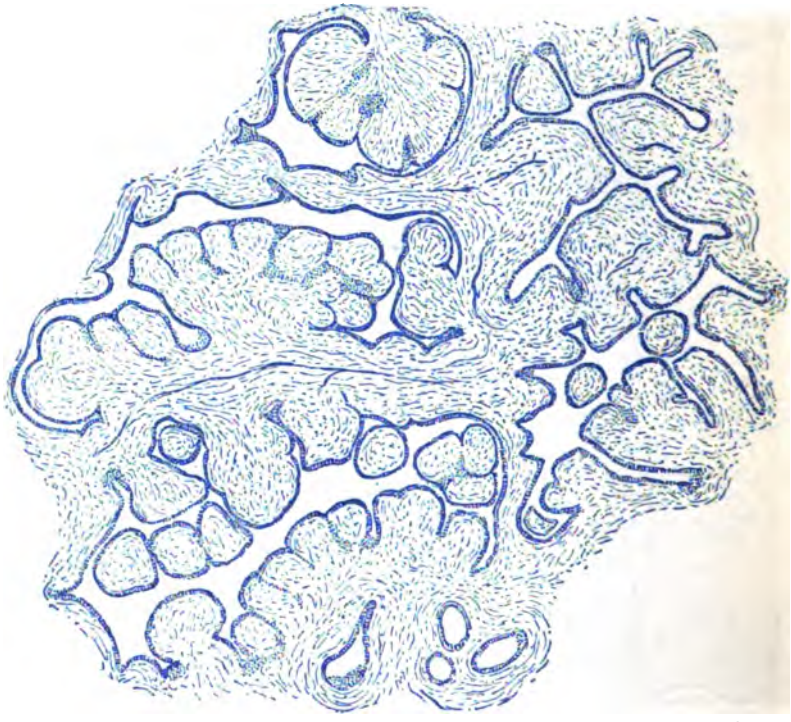

Fig. 51.—Intracanalicular fibroma of breast. (After *Kaufmann.*)

irregular, or polypous form. The distention may be so great as finally to produce large cavities or cysts, which, in addition to the tumor-nodules, are filled with a serous, mucous, or thick, milky or pap-like, yellowish-red material containing an abundance of cholesterin and blood-pigment. Into these cysts the tumor masses protrude in papillary or cauliflower-like form. All the intracanalicular nodules are covered with a layer of cubic or cylindric epithelial cells, which is continuous with the epithelial lining of the distended milk-ducts, and has been pushed into the duct lumen by the fibrous growth.

If these tumors are extirpated, apparent recidives may take place, because other parts also become involved.

The tumors are generally of slow growth and may attain large dimensions (several pounds). They sometimes undergo sarcomatous degeneration, under which circumstances their growth may be rapid. Occasionally carcinomatous change is observed.

In corn (*clavus*), which is frequently classed with the hard warts of the external skin, the papillary portion of the skin is involved to only a relatively slight degree. Proliferation of the epidermis is the predominating feature.

Fig-wart, *ficus, condyloma acuminatum,* has a cauliflower-like surface, and resembles a small berry. It sometimes attains the size of an apple or larger, and is composed of fine papillæ, in which the vessels

Fig. 52.—Condyloma acuminatum. *a*, enlarged and branched papillæ; *b*, epidermis. × 20. (After *Ziegler.*)

occupy most of the space, and of epidermis thickened from 10 to 20 fold. Acuminate condylomata[1] are found chiefly at the mucocutaneous junctions.

Warts of the skin: *verrucæ,* the congenital: *nævi,* as well as the acquired: *porri* (*porrus* or *porrum*), often occur in large numbers and always in localities subjected to frequent slight irritation. They usually have a fissured surface. If the horny layer is unaltered the wart is soft in consistency (flesh wart, *verruca mollis s. carnea*). Hypertrophy of the horny layer causes hardening of the wart (*verruca dura*). According to Smaus, the hard warts, which occur with especial frequency upon the skin of the fingers, and originate as a result of inflammatory hyperplasia of the epithelium and of the papillary bodies, are infectious and communicable.

The tuberous form of fibroma occurs in the skin, fascias, and periosteum. In the skin the fibromata are usu-

[1] *Condyloma latum* is a syphilitic product.

ally multiple, seldom solitary, of miliary to hen's-egg size, sometimes soft and elastic, sometimes dense and hard as cartilage. In the fascias they are either multilocular or unilocular; each lobule has a radiate and fascicular arrangement. In the fascias three forms are differentiated: *simplex, mucosum,* and *petrificans.* In *fibroma mucosum* a mucinous fluid, which characterizes it, can be expressed, and in cases of long standing it generally forms large tumors. *Fibroma petrificans* is traversed by calcified parts in the form of nodes and bands, seldom by ossified tissue.

Fibroma of the periosteum is not often observed. Sometimes, however, it forms nodules, which become dangerous by virtue of their size and position. These periosteal fibromata are distinguished from exostoses by being movable upon the bone. The usual seat is the base of the skull. Here they form nasopharyngeal polypi and retropharyngeal tumors, which may develop from the anterior lacerated foramen, from the spheno-occipital bone, or the upper cervical vertebræ, especially the atlas and axis.

In contrast to the hyperplastic fibromata thus far discussed stand the heteroplastic fibromata, which, however, are not, in a strict sense, malignant because they do not form metastases. They occur principally in bone (*fibroma ossium*), starting either from the bone-marrow or from the bone-tissue. The most frequent locations are the maxillæ, which are occasionally greatly swollen by this variety of tumor.

LIPOMA, ADIPOSE-TISSUE TUMOR.

Lipomata consist principally of true adipose (fat) tissue. The individual cells are of exactly the same nature as those of the subcutaneous adipose tissue. These neoplasms, which may attain considerable dimensions, form circumscribed, rounded, or lobulated tumors, which frequently are surrounded by a fibrous connective-tissue capsule. On incision the cut surface presents more or less distinct lobulation. They develop in the subcutaneous tissue, especially of the back, thighs, and neck, where they often are multiple and symmetric; in the axillæ; rarer in the mesentery and omentum, joints, pia, intestinal wall, brain, liver, kidneys, etc. By displacement of the skin in polypous form, pendulous lipomata are produced.

Two forms are differentiated: the hyperplastic and the heteroplastic lipoma. The first is a local excess, an unusual increase of fat-tissue, a local polysarcia. Every lipoma, like ordinary adipose tissue, is composed of a number of fat-lobules. As, however, the individual fat-lobules vary in size and are arranged to form larger, irregular-sized lobes, and are also separated by connective-tissue septa

of varying width, there is not the same regularity in lipomata as in ordinary adipose tissue. If the connective tissue is present in the same amount as in normal fat-tissue, the tumor is designated as *lipoma molle.* If, on the other hand, the connective-tissue septa are unusually broad and compact, so that the whole tumor has a dense, hard consistency, the growth is spoken of as a *lipoma durum* or *fibrosum.* Occasionally the vessels are so abundant that they predominate: *lipoma teleangiectodes;* at other times calcification and ossification are present in the connective-tissue stroma: *lipoma petrificum, ossificum.* The connective tissue may also have a soft, gelatinous consistency: *lipoma gelatinosum, colloides.*

Every more or less large lipoma is always associated with new formation of fat-cells. These are not derived from the old fat-cells, but from connective-tissue cells which proliferate and become filled with fat (liquid oil). When a number of lipomata develop in an individual, the process is never one of metastasis, but of multiplicity. This, as well as the fact that lipoma usually does not become manifest until middle and advanced age, indicates that lipoma may be acquired. Among the causes is to be mentioned alcohol, which particularly favors obesity. In every instance, however, a local predisposition also must be present. This, like polysarcia, may be hereditary and congenital.

In general, lipomata manifest little disposition to undergo spontaneous retrogression; indeed, they often undergo no diminution in size even in spite of marked general emaciation. Sometimes the central portions undergo softening from necrosis and disintegration of the cell membranes, with the production of a cyst filled with liquid oil. This change is probably the result of nutritive disturbances. In other cases decomposition of the neutral oil droplets and union of the liberated fatty acids with lime-salts to form sebate of lime take place, giving rise to a mortar-like, friable mass.

As a consequence of repeated trauma, a *lipoma molle* may develop into a *lipoma fibrosum;* or suppuration (abscess) or ulceration may occur, which readily assumes a gangrenous character.

Hyperplastic lipoma is observed, on the one hand, in localities where adipose tissue is normally found, and, on the other hand, in those parts where loose connective tissue exists, which is transformed into fat-tissue by polysarcia; thus, in subcutaneous, subfascial, submucous, subserous, intramuscular, intraorbital, subperitoneal regions.

Three forms are differentiated:—

1. *Lipoma simplex tuberosum,* in the subcutaneous adipose tissue, particularly in parts which are flabby and folded, and in the radix mesenterii.

2. *Lipoma capsulare,* in the periphery of any organ, *e.g.,* kidneys, heart, eye, mamma, and in the periphery of a hernial sac.

3. *Lipoma polyposum,* which begins as a smooth protuberance and gradually develops into a pedunculated polypus (subcutaneous, subserous, submucous). This develops most frequently in the *appendices epiploicæ* of the large intestine. By branching of the polypoid form, *lipoma arborescens* is produced. If the polypi have long pedicles, the pedicle gradually grows smaller until the lipoma finally becomes free; besides, the external layer usually undergoes induration and ultimately acquires a cartilaginous consistency. After interruption of the blood-supply, the fat-cells of the interior degenerate and form an oil-cyst. The free bodies of the abdominal cavity: *corpora libera,*[1] develop in this manner from the appendices epiploicæ.

Heteroplastic lipomata also develop from connective tissue, but in localities where fat-cells are not normally present: in the cortex of the kidney, in the arachnoides, in the scrotum (tunica vaginalis propria and tunica dartos), and in the labia majora.

Lipomata frequently are combined with fibroma, angioma, chondroma, etc.

MYXOMA, MUCOID TUMOR.

Mucous tissue is really a fetal tissue and is present in the fetus in all localities where adipose tissue subsequently exists. It represents, therefore, the primitive stage of adipose tissue. On the other hand, fat-tissue is sometimes transformed into mucous tissue, particularly in the subpericardial adipose tissue in atrophic conditions, in the bone-marrow (colloid marrow), in the hilus of the kidneys, etc.

This mucous tissue, like adipose tissue, may form tumors: mucous tissue tumors, or mucous tumors, *myxomata.* Homologous and heterologous myxomata are distinguished according as the tumor develops from pre-existing mucous tissue or from another tissue belonging to the group of connective substances.

Mucous tissue has a soft, often fluctuating consistency, is infiltrated with a viscid, ropy, colorless, or yellowish fluid which contains mucin (mucus) as a basic substance. In the younger portions chiefly round cells are present; in the older portions anastomosing spindle-shaped and stellate elements are found. Besides these, a small number of intercellular fibrillæ are seen traversing the mucoid basement substance. A myxoma thus composed is called *hyalinum* or *gelatinosum;* if greater cell proliferation is present, which gives to the tumor a myeloid appear-

[1] The *corpora libera* of the joints (*mures articulares,* joint mice) usually have another genesis; only exceptionally do they originate from pedunculated lipomata.

ance, it is called *myxoma medullare*. *Myxoma lipomatodes* contains fat-cells in a gelatinous basement substance. *Myxoma cystoides* develops from softening and liquefaction, as a result of destruction of the cells. If more fibers are present in the basement substance, so that the tissue acquires a denser, firmer consistency, the growth is then designated as *myxoma fibrosum*. By condensation of the basement substance and transformation into a cartilaginous structure (formation of a capsule around the cells), *myxoma cartilaginescens* is produced, while *myxoma teleangiectodes* is characterized by its great vascularity.

Myxoma of the placenta (*mola hydatidosa*, vesicular mole, *mola racemosa*) frequently occurs in abortion, very rarely at parturition. It develops from the fetal villi of the placenta. In the normal state these consist of an epithelial covering (exochorion) and a mucoid basement substance (endochorion). Myxoma of the placenta begins with proliferation of the epithelium and prolongation of solid buds of the endochorion. The buds develop into large vesicles, which in turn send forth new buds. These, again, form new buds, and so on. This growth of the villi is sometimes accompanied by marked cellular proliferation; sometimes, however, the cells also degenerate by mucoid transformation or fatty metamorphosis. The greater part of the basement substance consists of a relatively liquid, mucoid mass, which is expelled when the vesicles are punctured. Myxoma of the placenta deprives the fetus of nourishment and thus causes its death. The tumor may continue to grow after death of the fetus. Then, as a rule, a large mass, apparently composed only of a great quantity of blood and vesicles of varying dimensions (miliary to cherry size), arranged like a bunch of grapes, is expelled at the time of abortion. Such myxomatous formations sometimes occur to a limited extent as partial placental myxomata, in connection with well-developed children born at full term. This growth probably is due to an alteration of the endometrium (endometritis), the development of the maternal vessels at first being unusually marked, thus exerting upon the surface of the ovum a strong irritative action, which causes proliferation of the villi.

Not infrequently a partial fibrous placental myxoma is in the primary stage of development at the time of abortion. This formation is the result of inflammatory changes of the endometrium, especially of endometritis decidua. The diseased villi form dense nodules consisting of firm myxomatous tissue quite rich in connective-tissue fibers and cells.

In adults myxomata occur principally in localities where loose connective tissue and thick layers of adipose tissue are present: upon the thigh, back, hands, cheeks. These tumors are rare, but they some-

times attain large dimensions, and, like lipomata, always have a lobulated structure. They are often so rich in fat-cells that they represent true transition forms of the lipomata. They generally arise from the deeper parts, *i.e.*, are subfacial and intramuscular. Myxomata of bone usually develop from the medullary tissue and frequently form mixed varieties, especially with enchondroma: *enchondroma myxomatodes,* and, swelling the bone, not rarely attain considerable size.

Fig. 53.—Papillary cystocarcinoma of the breast with myxomatous degenerated papillæ. *a,* connective-tissue stroma; *b,* myxomatous degenerated papillæ; *c,* proliferated multilamellated epithelium. ×80. (After *Ziegler.*)

Heteroplastic myxomata are more common than the hyperplastic forms already described. They develop from tissues which belong to the class of connective substances. The connective substance of the central nervous system and peripheral nerves—the neuroglia and the neurilemma—is very frequently the point of origin of myxomata: *glioma myxomatodes.* Here belong many tumors of the greater hemispheres, which are characterized by marked softness, gray color, and transparency, discharge a mucoid fluid, and collapse at the center or are converted into true cysts, and also the false neuromata of the peripheral nerves.

Myxoma of the female breast, like fibroma, starts from the interstitial tissue. Either the whole stroma of the mamma is involved, giving rise to diffuse swellings, or the growth is confined to single lobules, causing the formation of isolated nodules; or, like intracanalicular papillary fibroma, the tumor grows into the lumina of the milk-ducts and fills them with mucoid tumor masses: *myxoma proliferum, arborescens.* The glandular structure is always more or less destroyed in the process.

Mucoid tumors are occasionally found also in the testes and in the lungs, more rarely in the salivary glands (parotid).

Heteroplastic myxomata are characterized by their great tendency to recur. Rarely, they are malignant in the true sense of the word, and form metastases in various tissues. Multiplicity is more frequent, especially in the peripheral nerves.

CHONDROMA.

Cartilaginous tumors (*tumores cartilaginosi*) are divided into the hyperplastic and heteroplastic forms. The former are purely local formations, smaller outgrowths from pre-existing permanent cartilage: ecchondroses, while the heteroplastic forms, or enchondromata, develop either from a noncartilaginous matrix or from transitory cartilage which should have developed into bone.

Ecchondroses are generally situated upon the costal cartilages, at the synchondroses (*synchondrosis spheno-occipitalis, symphysis pubica*), the intervertebral cartilages, and upon the permanent cartilages of the respiratory organs. They begin as small, button-like swellings by proliferation of the uppermost layer of the cartilage or perichondrium: *ecchondroma verum simplex.* With further growth ossification very frequently occurs at the base: *ecchondroma ossificans,* and sometimes also retrograde metamorphosis, amyloid masses developing in the cartilage-cells and intercellular substance: *ecchondrosis amyloides.* In other cases vesicles form within the cartilage-cells: *physalides;* at the same time the interstitial substance frequently softens (the cells proliferating), so that the whole tumor consists almost entirely of vesicular cells: *ecchondrosis physalifora prolifera.*

Ecchondroses of the cartilages of the larynx and trachea are sometimes flat, sometimes nodular, and generally directed inward, but they very seldom cause considerable narrowing of the lumen. Ecchondroses occasionally develop from the upper and lower margins of the tracheal cartilages and, by coalescence, may produce a bridge-like fusion of several cartilages. The mobility of the trachea is thus decidedly interfered with.

Upon the *symphysis ossium pubis* the ecchondrosis is situated at the posterior surface, where it forms a protuberance. *Ecchondrosis spheno-occipitalis* is a cartilaginous outgrowth upon the surface of the *clivus* at the junction of the sphenoid with the occiput. The synchondrosis of both these bones generally ossifies at puberty. If the dura is penetrated by the ecchondrosis, the latter spreads out upon the inner surface of the dura as a button-like growth.

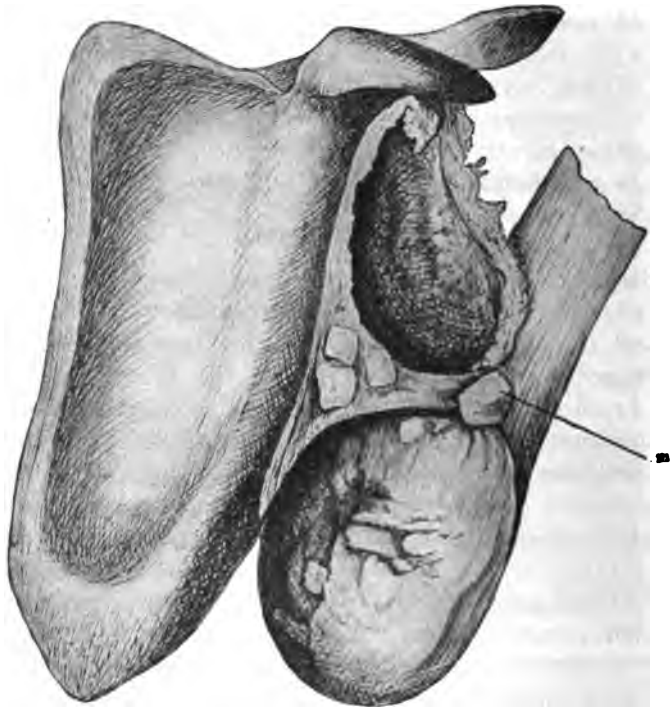

Fig. 54.—Chronic arthritis deformans of the left shoulder-joint. Subluxatio et mures articulares. 53-year-old cabman. At *m* thin-pedicled, hard, movable part (so-called joint mouse in process of development) at the margin of the cartilage surface (by proliferation of the cartilage). The humerus is in reversed position, *i.e.*, is rotated outward. ⅔ natural size. (After *Langerhans.*)

Growths having sometimes a more villous, sometimes a nodular, button-like form occasionally develop (in arthritis deformans) from the outer margins of articular cartilages and hang into the joint. These are partly pedunculated, partly sessile. The former are movable, may become separated from their pedicles, and then constitute the *corpora libera* or *mobilia* (joint mice, *mures articulares*). On the

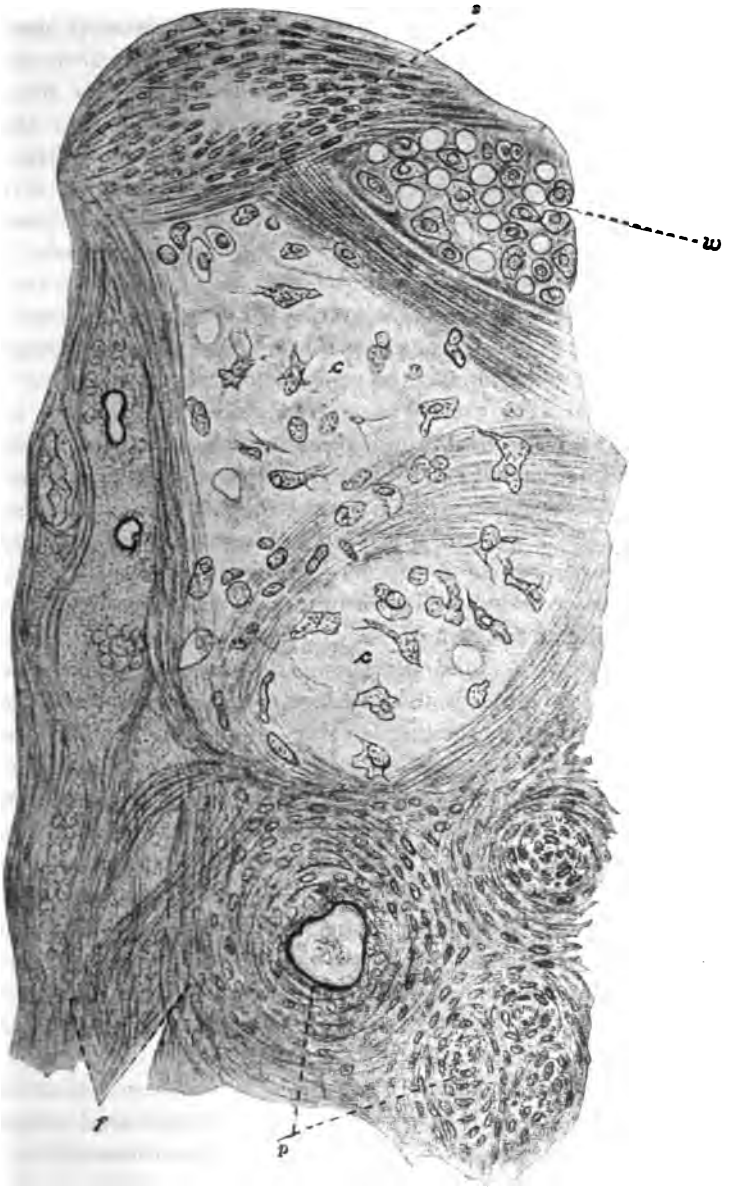

Fig. 55.—Carcinoma fibrochondrosarcomatodes from the right submaxillary of a 20-year-old man (removed by operation). *p*, epitheliomatous pearls and interlacing bands of squamous epithelia (prickle cells); *s*, sarcomatous parts, consisting of large spindle-cells with a small amount of striated intercellular substance; *f*, broad, fibrous, poorly cellular connective-tissue trabeculæ; *c*, cartilaginous area, partly with hyaline, partly with striated hyaline basement substance; *w*, strikingly large, markedly proliferated cartilage cells with a small amount of hyaline basement substance. (Zeiss Apochr., 16; Comp. Ocul., 4. After *Langerhans*.)

other hand, the free bodies of the joints may develop also from the periosteum and the synovial membrane. The periosteal develop as outgrowths of the periosteum; they push the synovialis into the joint and there branch dendriticly. The synovial excrescences also produce villous formations, which at first are fibrous; at a later stage, however, like the periosteal, they are transformed at the ends into cartilage and, finally, calcify or ossify. If portions of these growths become detached, *mures articulares* are produced, as in the former instance. Calcified *corpora mobilia* are called arthroliths. Some of these formations (especially the solitary) are round, oval, or discoid, frequently patella-shaped; some (especially the multiple) are irregular, nodular, and warty; in some, again, the remnant of a pedicle can be recognized. All these differ very greatly in size.

Aside from the corpora mobilia which develop from lipomata (*q.v.*), there is another group traceable to trauma. These are cases in which part of the articular cartilage is detached. Sometimes the detached fragment fits exactly into the fractured surface of the cartilage.

The broad, sessile articular ecchondroses may, by their size, produce considerable deformities of the joints and limit motion to a marked degree. All these cartilaginous formations are referable to irritative processes, and are, therefore, most frequently observed with erosion and eburnation of the cartilage, thickening of the synovialis, and attrition of the ends of the bone in chronic arthritis deformans (e.g., *malum coxæ senile*).

Heteroplastic chondromata: **enchondroma** and **osteoid chondroma,** which is to be distinguished from the former, are more common than hyperplastic chondromata. Both these forms occur pure, as well as in many tumors mixed with other tissues: *enchondroma s. chondroma osteoides mixtum.* In these combination tumors the cartilaginous portion may be slight, forming small, disseminated islands of cartilage, or occupy a large, continuous part of the tumor. Enchondroma is frequently combined with carcinoma (see Fig. 55), and osteoid chondroma with sarcoma.

Enchondroma consists of hyaline, fibro-, or reticular cartilage. Osteoid chondroma generally contains quite small, round, spindle-shaped, and branching elements without capsules. The intercellular substance is very dense, quite highly refractive, homogeneous, or only slightly striated; forms thick trabeculæ or a very close meshed reticulum, so that only very small spaces and rarely cells are visible. On boiling, this intercellular substance yields glue—not chondrin; this sharply distinguishes osteoid chondroma from enchondroma. There is also a soft variety of enchondroma: *enchondroma albuminosum,* characterized by

an albuminoid intercellular substance, which is frequently converted into mucus. Another form: *enchondroma gelatinosum* (*molle*), likewise belongs to the soft varieties; it is rich in large, stellate elements; sometimes it contains also a considerable amount of mucus: *enchondroma mucosum*. If some parts of the tumor consist chiefly of cartilage and others of true mucous tissue, the tumor is either an *enchondroma myxomatodes* (when the cartilage is in excess) or a *myxoma cartilagineum* (when mucous tissue is in excess). *Enchondroma teleangiectodes* is highly vascular. This is particularly the case with the soft forms. The marked vascularity is not infrequently associated with partial ossification. Calcification (petrification) is more frequent, in which first the capsules, later also the true intercellular substance, become the seat of calcareous deposits.

Softening and **ulceration** (particularly of the softer forms) begin with retrograde fatty metamorphosis of the cells and transformation of the intercellular substance into a mucoid, viscid mass. Besides, hemorrhages easily occur from solution of continuity which, in time, impart a yellowish and brownish color to the beginning cystic degeneration.

Enchondroma, especially that of **bone**, is a tumor of early life, and is occasionally congenital. Probably some cases are referable to disturbances in the development of the bone, particularly rachitis, which, with its irregular and often serrated line of ossification, has repeatedly attracted attention in this respect, a number of cartilaginous foci, often surrounded by bone-tissue, being found. The parts of the bony system most frequently predisposed to the formation of enchondroma appear to be those in which ossification occurs late and often irregularly.

Enchondromata of the soft parts offer less ground for an explanation of their origin. It may be stated, however, that retention of the testes within the abdominal cavity furnishes a marked predisposition. In very many cases the tumor develops after trauma (fracture).

Enchondromata of the soft parts are often mixed tumors. The cartilaginous portion always has a lobulated structure. The tumor develops from chronic inflammation of connective tissue, which fact speaks decidedly in favor of the irritative origin of enchondroma. Pure enchondroma occurs in the salivary and generative glands, the lungs, the subcutaneous adipose tissue, and in the fascias. Enchondroma of the lung is generally situated in the hilus of the lung; in rare cases in the center of the parenchyma or beneath the pleura. Of the salivary glands the submaxillary and parotid are especially liable to enchondroma. The female generative glands are less often affected than are those of the male. Enchondromata of the testes and also of the subcutaneous tissue are generally mixed tumors.

Two forms of **osteoenchondroma** are differentiated, namely, the internal: central, and the external: peripheral, enchondroma. Central enchondroma develops from the bone-marrow or from the compact bone substance, and usually originates quite latent. The more it grows, the more the bone is distended, the periosteum proliferating and new osseous lamellæ being deposited upon the exterior. This new-formed osseous capsule gradually becomes thinner as the process advances, because the new formation of bone cannot keep pace with the growth of the tumor. Finally, small platelets of bone are found upon the surface of the tumor only at certain points. The growth of the tumor advances by the constant development of new foci, in the form of nodules, adjacent to the primary and older focus. The tumor thus acquires a nodular exterior, and upon section has a lobulated structure. The formation of new nodules frequently occurs in such a manner as to leave a small layer of apparently intact tissue between mother- and daughter- nodules. This is the beginning of true metastases; the surrounding tissue becomes, as it were, infected and more or less rapidly disappears with advance of the tumor-tissue. In this way the tumor invades also the soft parts, the connective tissue forming the avenues for further development.

Peripheral enchondroma develops partly from the periosteum, partly from the surface of the bone itself. It has no period of latency and no osseous covering, and, as a rule, does not begin to develop until later in life. Its most frequent seat is the pelvis, particularly those localities which correspond to the synchondroses and earlier cartilaginous points of union.

Enchondromata belong to the malignant tumors which form metastases. The neighboring lymph-glands are often involved by metastases, and sometimes the internal organs (lungs). Solid enchondroma buds are not infrequently observed within the lumina of lymphatic and blood-vessels—a proof that the tumor masses grow through the vessel wall. Tumor particles may thus readily be transported by the lymph- or blood-current.

Osteoid chondroma has a rather smooth surface. It forms very large tumors, but manifests no pronounced tendency to form metastases. Its most frequent seat is in the long tubular bones, especially at the extremities, namely, the knee-joint ends of the tibia and femur. If there is not too great an amount of calcareous deposit, this form of tumor can be cut with the knife, because complete ossification seldom occurs. Combination with sarcoma is frequent. Osteoid chondroma of the soft parts is rare and generally not entirely pure.

OSTEOMATA.

Osteomata consist of bone. They are atypical osseous growths which develop from periosteum, cartilage, or some other tissue belonging to the connective-tissue group. They differ from the other histioid tumors, which occasionally ossify here and there, by the fact that the whole tumor is always finally transformed into bone-tissue. If the preponderating element in mixed tumors is true osseous tissue, these also are called osteomata. According as the principal mass con-

Fig. 56.—Exostosis of the inferior maxilla. ⅔ natural size. (After *Langerhans.*)

sists of compact bone-tissue or spongiosa or marrow-tissue, the tumor is called ***osteoma durum*** or ***spongiosum*** or ***medullosum,*** respectively. The bone-marrow may be red (lymphoid: corresponding to the state of growing cylindric bone) or yellow (fat-marrow) or gelatinous.

Two forms are differentiated: hyperplastic and heteroplastic osteomata. **Exostoses** belong to the first group. They are of local significance only, and always remain stationary. *Exostosis cartilaginea,* which develops from cartilage, consists of compact bone with a cartilaginous and frequently somewhat irregular, nodular surface. In marked growth the more centrally located part generally becomes spongy; later it is converted into marrow-space, so that the new-formed bone-marrow may unite with the true bone-marrow. These exostoses are found upon the cylindric bones (in the neighborhood of

the intermediary cartilage at the point of insertion of the muscles), the scapula, the pelvis, and inferior maxilla. Their origin usually dates from the early period of life.

In rachitic pelvis, *pelvis spinosa,* the nodular and spinous exostoses are situated in the region of the iliopubic synchondrosis, *i.e.*, at the point where cartilage was present at an earlier period of development. Hence, authorities are inclined to assume that these exostoses are the result of proliferation of cartilage.

The great majority of all exostoses have a connective-tissue origin, most of them developing from the periosteum. A few originate from

Fig. 57.—Pelvic exostosis.

bone granulations, bone-tissue being first transformed into granulation tissue (*e.g.*, in consequence of an old ulcer, as of the foot), and this, later, again producing new bone.

While the term exostosis is always used to designate more circumscribed, smooth, or button-like and also pedunculated, compact outgrowths, the name **osteophytes**[1] is applied to more general, cortic, young, porous osseous growths, the product of a periostitis. Periostosis signifies cortical, compact swelling which extends over a large area of the bone, while hyperostosis means increased thickness of a whole bone or a whole section of a bone (e.g., *hyperostosis calvariæ:* thickening of the whole calvarium).

Leontiasis ossea is produced by hyperostosis of the bones of the face, and is frequently associated with nodular and spinous exostoses. Partial hyperostoses of the bones of the face are not rare.

[1] These do not form tumors. See alterations of bones, p. 905.

They are most frequent upon the maxillæ (especially the superior maxilla), and are the result of trauma, or of irritation from the teeth. In *arthritis nodosa* bony growths, which occasionally attain considerable size, are found upon the articular ends. Supracartilaginary exostoses are osseous growths which develop from the margins of the vertebræ, grow over the intervertebral cartilages, and merge with exostoses of neighboring vertebræ or with the vertebræ themselves, so

Fig. 58.—Supracartilaginous exostoses of the vertebræ, especially of the two first lumbar vertebræ (the two lower in the drawing). ⅓ natural size. (After *Langerhans.*)

that adjacent vertebræ are united by osseous bridges over the intervertebral disks. Exostoses of the cranial vault occur upon the internal and external surface as protuberances and as button-like or pedunculated small tumors. These seldom attain considerable dimensions, but when they do and are located upon the internal surface they may become very dangerous by the pressure and irritation exerted by them upon the brain (Jacksonian epilepsy). In the larger exostoses the internal and external tables of the skull are frequently involved at corresponding points at the same time. The exostoses sometimes possess a certain macroscopic and microscopic resemblance to ivory: *exostosis*

eburneæ. These are of very dense structure and, like ivory, consist of concentricly arranged lamellæ, and have a yellowish-white color, especially when the bone begins to dry. They are generally situated upon sclerotic bone substance.

Upon the great toe two forms of exostoses occur: *exostosis subungualis* and *exostosis articularis*. The former is situated beneath or at the margin of the nail, and is characterized by intense painfulness; the latter in the metatarsophalangeal joint after dislocation. The second form is the result of ill-fitting and especially too-pointed shoes, because, as is well known, the foot is broadest at the anterior part. As a result of dislocation of the great toe, subluxation gradually develops; the articular surface is compressed by the foot-covering and is irritated by the friction; a chronic periarthritis is induced, resulting in the formation of flat exostoses at the margin of the joint.

In contrast to exostoses stand, in a measure, **enostoses**, which develop in the interior of the bone from the bone-marrow. Osteomata developing from retained teeth possess a certain similarity to these. In contrast to true dental tumors (dental osteomata) stand alveolar exostoses. Dental osteomata consist either of an increase of the cement substance in the form of hyperostosis or exostosis, or they are small cement exostoses which are covered with enamel: *dentes proliferi*. If the tumor consists principally of dentine it is designated as **odontoma**.

Alveolar exostoses may develop from the periosteum of the alveolar process (especially as periostosis or hyperostosis) or, in the case of retained teeth, they form capsules around the imprisoned tooth: bone capsule, bone cyst. In consequence of this, pronounced swelling of the jaw may occur. Retention of the teeth is sometimes caused by coalescence of the teeth (either *in toto* or only at the roots or crowns) in the deeper parts. If the dental pulp is replaced by a hard bony mass (in injuries, caries, etc.), the process is designated as internal odontoma. Dental tumors sometimes develop also from misplaced teeth (dislocated, displaced dental germs), *e.g.*, upon the gums, in the nasal cavity, antrum of Highmore, etc.

Discontinuous exostoses always develop from parts which originally were detached or subsequently broken off by trauma (*e.g.*, by fracture). They are distinguished from the other forms by the fact that they are movable.

To the osteomata of fibrous, tendinous, and connective-tissue parts connected with the periosteum belong *exostosis apophytica* and *exostosis tendinea*—a progressive ossification of the tendons, fascias, and muscles which begins in the bone. These exostoses also are occasionally

discontinuous, *i.e.*, not connected with the bone, and hence movable. Such discontinuous sesamoid bones are the *ossa præpubica*, which develop close to the pelvis, in the vicinity of the anterior margin of the os pubis and ossa ischii, and extend for a greater or less distance into the various muscles and fascial attachments of the thigh. The best-known example is the so-called "riders' bone," which is either continuous with the pubic bone or attached by ligamentous or fibro-cartilaginous tissue. Here also belongs the so-called "exercise" or "drill bone" (*myositis ossificans*), occurring in the left deltoid muscle, which develops as a result of impact of the musket. All these osteomata are due to particular traumatism and especially to strained activity of the affected parts.

Finally, to the class of hyperplastic osteomata belongs the sometimes significant osseous tumor which develops as the result of excessive callus formation (*callus luxurians*) in fractures: *osteoma fracturæ*. Callus luxurians is characterized by the fact that the callus is not confined to the fractured ends, but extends far into the surrounding parts, and even deep into the muscular structures.

The frequent occurrence of multiple exostoses is not due to metastasis, but, as in the case of solitary exostoses, is either the result of multiple local irritation or an hereditary phenomenon.

Heteroplastic osteomata always occur in soft parts, and invariably develop from inflammatorily thickened or new-formed connective tissue, *e.g.*, from pleuritic adhesions. They occur in the cerebral and spinal arachnoid as flat plates or small, somewhat rounded, angular or serrated islets, which are smooth externally and roughened internally. Osteomata duræ are not infrequently observed upon the inner surface of the dura mater, especially in the anterior portion of the falx cerebri. Smaller osteomata are found in the eye, in the posterior portion of the choroid, rarely in the vitreous, where they usually occur after phthisis bulbi resulting from antecedent traumatic or purulent destruction. Osteomata are very rare in the lungs, and still rarer in the skin, where they occur in elderly persons in the form of sand.

PSAMMOMATA.

These connective-tissue tumors are characterized by the presence of sand granules (ψάμμος = sand). The latter resemble in every way the normal sand grains (*corpora arenacea*) of the pineal gland in the aged. They are small, concentricly lamellated formations which are calcified either completely or only at the center, and occasionally coalesce to form mulberry- or sausage- shaped masses. These sand granules are inclosed by loose or firm connective tissue.

Psammomata not infrequently occur upon the inner surface of the dura mater; the smaller ones often in large numbers. They are often found in the choroid plexus, in which locality they sometimes attain the size of a walnut. Upon the inner surface of the dura mater, however, psammomata form only cherry-sized, hemispheric, smooth or roughened tumors of dense consistency and reddish, gray-white color. They may cause compression and atrophy of the adjacent nerve substance. Psammomata are very rare in the brain, lymph-glands, etc. Sometimes these formations are not pure psammomata, but so-called

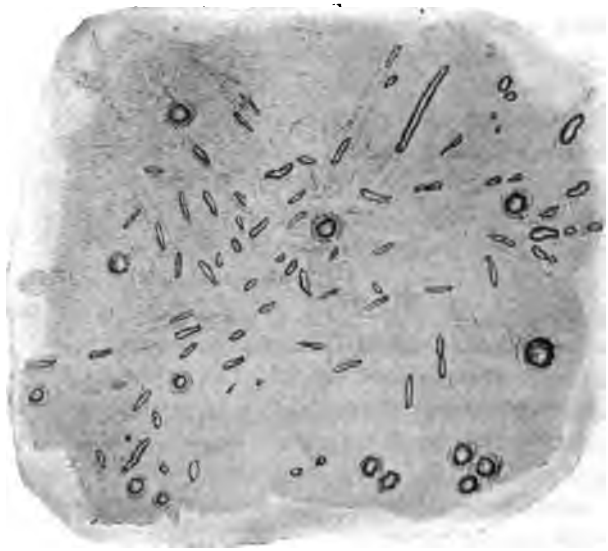

Fig. 59.—Psammoma duræ matris. Double-knife section. (Zeiss Apochr., 16; Comp. Ocul., 4. After *Langerhans.*)

psammosarcomata, if they are richly cellular or consist entirely of spindle cells. They are differentiated from genuine sarcomata by the fact that they remain localized, do not form metastases, and, as a rule, do not grow very large.

On the other hand, psammocarcinomata are, in their nature, occurrence, and course, genuine carcinomata, and are peculiar only in so far as so-called sand granules are frequently present in the stroma.

MELANOMATA.

Melanomata develop as a result of increase of pre-existing pigmented connective-tissue cells and usually form only small, tumor-like nodules in the cerebral and spinal arachnoid, skin, the intermediate layer

of the suprarenals, the iris, choroid, and adipose tissue, which, in the atrophic state, not rarely manifests a tendency to pigment formation (brown atrophy of the adipose tissue).

As pigmented cells in general are designated as chromatophores, the name chromatophroma has been suggested for these tumors. Macroscopicly, the pigmented portions of these growths are brownish black.

These tumors are distinguished from the malignant forms: melanosarcoma and melanocarcinoma, by their benign nature.

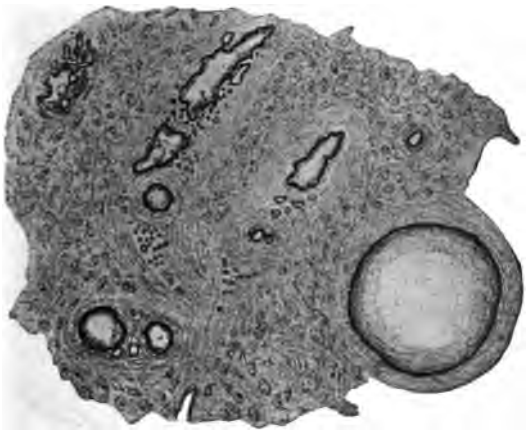

Fig. 60.—Psammoma duræ matris. Double-knife section. (Zeiss Apochr., 4; Comp. Ocul., 4. After *Langerhans.*)

GLIOMATA.

Gliomata develop from the neuroglia—the peculiar connective and supporting tissue of the nerve-centers. Soft (medullary), hard (fibrous), and telangiectatic forms are differentiated. *Glioma medullare* is very richly cellular, scarcely any reticular intercellular substance being recognizable. It is rare, while the mixed forms: myxoglioma and gliosarcoma, are frequent. *Glioma durum,* or *fibroglioma,* is rich in parallel fibrillæ, which in part are so densely arranged that some portions of the tumor possess a cartilaginous consistency. It usually contains corpora amylacea.

Gliomata of the ependyma are very frequent. They are small, submiliary. rarely hemp-seed sized, hard granules (*ependymitis granulosa,* particularly in chronic hydrocephalus).

Cerebral gliomata (most frequent in the white substance of the frontal and occipital lobes) sometimes reach very considerable dimen-

Psammomata not infrequently occur upon the inner surface of the dura mater; the smaller ones often in large numbers. They are often found in the choroid plexus, in which locality they sometimes attain the size of a walnut. Upon the inner surface of the dura mater, however, psammomata form only cherry-sized, hemispheric, smooth or roughened tumors of dense consistency and reddish, gray-white color. They may cause compression and atrophy of the adjacent nerve substance. Psammomata are very rare in the brain, lymph-glands, etc. Sometimes these formations are not pure psammomata, but so-called

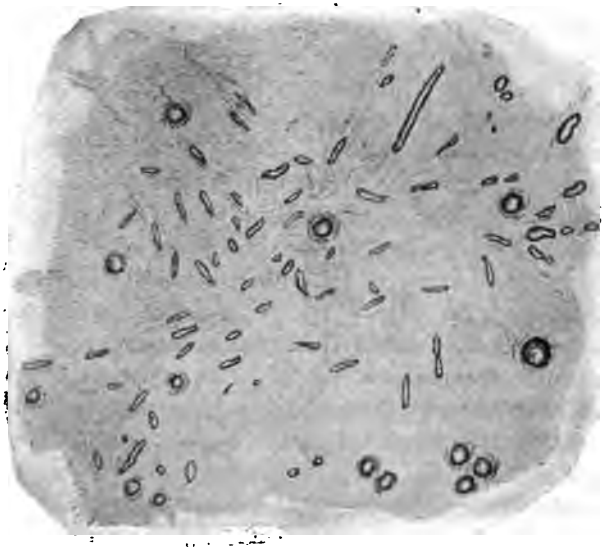

Fig. 59.—Psammoma duræ matris. Double-knife section. (Zeiss Apochr., 16; Comp. Ocul., 4. After *Langerhans.*)

psammosarcomata, if they are richly cellular or consist entirely of spindle cells. They are differentiated from genuine sarcomata by the fact that they remain localized, do not form metastases, and, as a rule, do not grow very large.

On the other hand, psammocarcinomata are, in their nature, occurrence, and course, genuine carcinomata, and are peculiar only in so far as so-called sand granules are frequently present in the stroma.

MELANOMATA.

Melanomata develop as a result of increase of pre-existing pigmented connective-tissue cells and usually form only small, tumor-like nodules in the cerebral and spinal arachnoid, skin, the intermediate layer

of the suprarenals, the iris, choroid, and adipose tissue, which, in the atrophic state, not rarely manifests a tendency to pigment formation (brown atrophy of the adipose tissue).

As pigmented cells in general are designated as chromatophores, the name chromatophroma has been suggested for these tumors. Macroscopicly, the pigmented portions of these growths are brownish black.

These tumors are distinguished from the malignant forms: melanosarcoma and melanocarcinoma, by their benign nature.

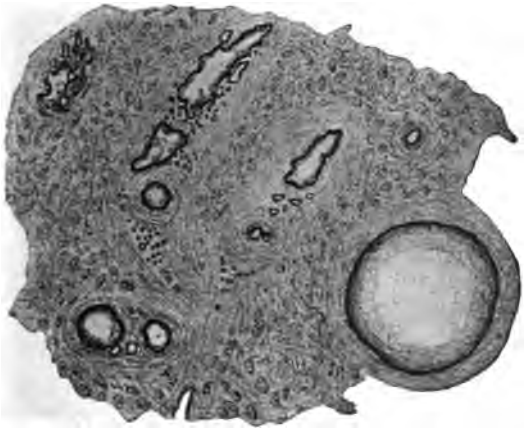

Fig. 60.—Psammoma duræ matris. Double-knife section. (Zeiss Apochr., 4; Comp. Ocul., 4. After *Langerhans*.)

GLIOMATA.

Gliomata develop from the neuroglia—the peculiar connective and supporting tissue of the nerve-centers. Soft (medullary), hard (fibrous), and telangiectatic forms are differentiated. *Glioma medullare* is very richly cellular, scarcely any reticular intercellular substance being recognizable. It is rare, while the mixed forms: myxoglioma and gliosarcoma, are frequent. *Glioma durum*, or *fibroglioma*, is rich in parallel fibrillæ, which in part are so densely arranged that some portions of the tumor possess a cartilaginous consistency. It usually contains corpora amylacea.

Gliomata of the ependyma are very frequent. They are small, submiliary. rarely hemp-seed sized, hard granules (*ependymitis granulosa*, particularly in chronic hydrocephalus).

Cerebral gliomata (most frequent in the white substance of the frontal and occipital lobes) sometimes reach very considerable dimen-

sions (about as large as an apple), and merge with the surrounding brain matter without any definite line of demarkation. The center is generally somewhat firmer than the periphery. The medullary form is more frequent than the fibrous. Owing to secondary changes, the cut surface of the tumors usually presents a very variable appearance. In the telangiectatic forms there is a decided tendency to hemorrhages, which occasionally obscure the tumor, especially as they may cause death under the semblance of apoplexy. In consequence of fatty metamorphosis, large portions often assume the appearance of smoked bacon,

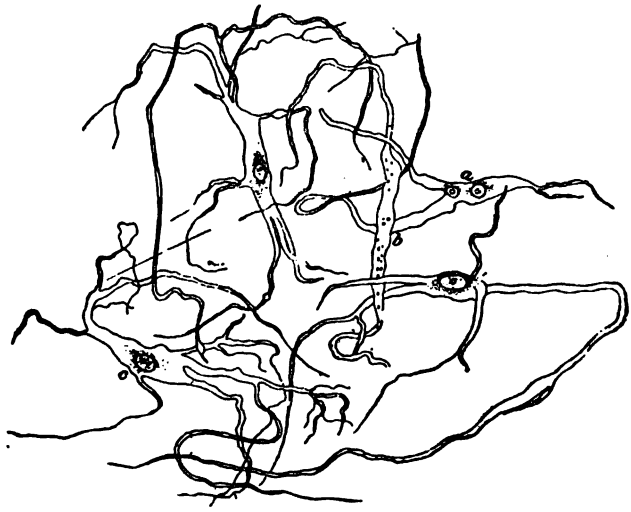

Fig. 61.—Isolated cells from a cystic myxomatous glioma of the left frontal lobe. Large cells with numerous partly branched prolongations. At *a* a cell with two nuclei; *b*, cells without nuclei; *c*, cells with one nucleus and two nuclei. (Zeiss Apochr., 4; Comp. Ocul., 8. After *Langerhans*.)

and by disintegration of the cells and softening of the intercellular substance cyst cavities develop, which, after a time, may contain perfectly clear fluid. In other parts the albuminous substances become inspissated and transformed into caseous material by absorption of the watery constituents.

These gliomata are almost always solitary, and even on long standing do not give rise to metastases. The larger the tumor, the more, as a rule, the other parts (the large ganglia, corpus callosum, etc.) are compressed and displaced.

Gliomata of the cerebral nerves resemble in every way those of the brain.

Gliomata of the retina (see also p. 1056) develop from the basement connective-tissue fibers and the intermediate granular layer. They occasionally have a lobulated structure. As soon as the bulb is entirely filled with the tumor masses, the lens and iris are pushed forward. With further progress perforation exteriorly occurs, usually at

Fig. 62.—Glioma with stellate cells, their processes forming part of the fibrous elements. × 500. (After *Smaus.*)

the corneal margin; *exophthalmia fungosa* develops, the dark-red, readily bleeding, spongy tumor growing out in fungous form: *fungus hæmatodes*. These retinal gliomata sometimes form metastases, but, in general, they are not as malignant as the mixed tumor: gliosarcoma of the retina.

SARCOMATA.

Sarcomata (σάρξ = flesh) are tumors which, histologicly, belong to the group of connective substances, and are distinguished from the

remaining connective-tissue neoplasms by the exuberant development of cells.[1]

The intercellular substance of sarcomata is seldom pure connective, glue-yielding tissue; it often contains albuminous and mucinous constituents, so that granular precipitates are produced; it may be homogeneous (in myxosarcoma) or granular (in gliosarcoma) or fibrillar.

Sarcomata with very rich vascular supply (*sarcoma teleangiectodes*) manifest a marked tendency to hemorrhage: *sarcoma hæmorrhagicum*. *Sarcoma diffusum* invades quite uniformly the whole or a part of an organ in the form of infiltration, while *sarcoma tuberosum* is the common form of tumor. *Sarcoma fungosum* spreads upon the surface in fungous form with projecting margins; *sarcoma polyposum*, in its external form, resembles an ordinary polypus.

As regards **etiology,** it must be emphasized that birthmarks (*nævi materni*) and flesh warts, especially the soft varieties (*verrucæ molles s. carneæ*), manifest an especial disposition later to undergo sarcomatous development, and that this is frequently observed in very small children. Next come true melanomata, congenital pigment marks (*nævi pigmentosi*), from which, upon the trunk (back) and face, sarcomata, especially melanosarcomata, develop, particularly as a result of repeated irritation, *e.g.*, scratching, friction of garments, etc. These sarcomata generally do not develop until advanced age, most commonly as a result of trauma or of continued irritation (*e.g.*, from a carious tooth). In the same category belong also those cases in which the sarcoma is referable to a scar (*e.g.*, after a bite wound): keloid (κηλὶς = scar).

As regards **malignancy,** experience teaches that the small-celled sarcomata are more dangerous than the large-celled, while the spindle-

[1] Accepting the definition of Virchow, a tumor is diagnosticated as sarcoma when it is possible to make out in its richly cellular tissue: 1, a diffuse, irregular arrangement of cells in a more or less scanty basement substance; 2, a direct connection with the blood-vessels, which are carried by the connective tissue, and, 3, a continuous and gradual transition into the adjacent tissue. To diagnosticate a neoplasm as sarcomatous upon the basis of these general peculiarities alone, however, would sometimes lead to great error, for ordinary granulation-tissue formations possess the above-described peculiarities. Indeed, it is just here that a knowledge of the time and mode of development of a tumor offers great aid in differentiation. Such information, however, cannot be obtained in all cases. On the contrary, it is not infrequently necessary to make a diagnosis without this support. In these cases, however, a knowledge of the normal structure of the organ in which the tumor originates, particularly of the nature of its various pathologic changes, will furnish the principal support in examination. The greater this knowledge, the more readily the possible difficulties which the structure may present may be overcome. This knowledge of the appearance of the pathologic and normal conditions is all the more useful in view of the fact that a sarcomatous neoplasm manifests sometimes slight, sometimes marked, individual differences according as it develops in one or the other species of connective tissue, according as it originates from one or another organ. How different in structure are sarcomata of the brain, bone-marrow, ovary, and of the skin!

celled sarcomata usually remain stationary for a considerable period. Here, however, the character of the affected organ, its relation to the rest of the body, and especially to the vascular and lymphatic system, are also of importance. Sarcomata of the testicle form metastases more rapidly than sarcomata of the ovary. The largest and most dangerous are mediastinal sarcomata; next to these come sarcomata of the orbit (*q.v.*).

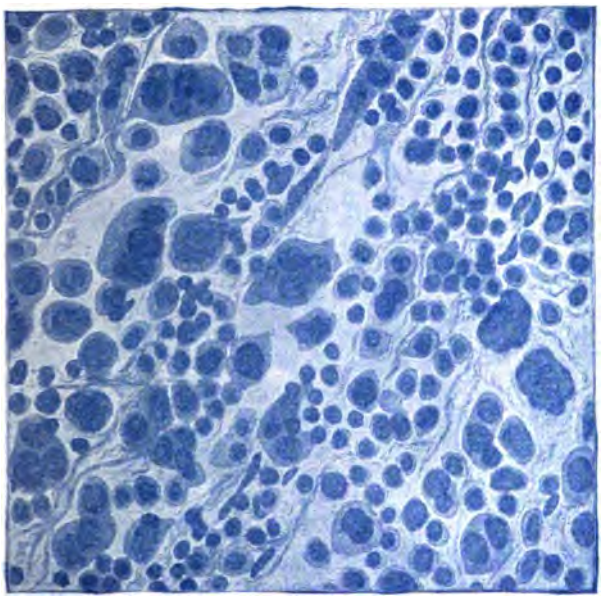

Fig. 63.—Myeloid sarcoma involving all the lymph-glands and associated with abundant white nodule formation in the spleen, and nodules and indurations in the liver. × 500. (After *Ziegler.*)

The malignant, infectious nature of sarcomata is shown, first, by continuous infection of neighboring structures, adjacent homologous tissues being first attacked, and, later, the heterologous tissues; second, by discontinuous infection, new tumor-nodules, separated from the mother-nodule by a small amount of normal tissue, appearing in surrounding parts, and, third, by true metastasis, *i.e.*, the involvement of distant parts, particularly the internal organs. The metastases always correspond in their histologic character to the primary tumors; for example, the metastases of osteoid sarcoma are always osteoid sarcomata, even in the lymph-glands and internal organs. In general, sarcomata manifest less disposition to form metastases in lymphatic glands and lymphatic vessels than carcinomata. The blood-current often appears

to facilitate the formation of metastases, *e.g.*, in pulmonary metastases of osteoid sarcomata. The nature of metastasis formation speaks, on the whole, in favor of the view that the infecting substances are the tumor-cells themselves.

The elements of sarcomata, and, hence, the sarcomata themselves, are generally relatively stable formations. Partial retrogressive metamorphoses consist in so-called fatty metamorphosis, caseation, softening, and ulceration. The latter is much more rarely observed than in carcinomata.

It is customary to classify sarcomata as follows:—

According to the nature of the tissue of which they are com-

Fig. 64.—Isolated cells from a spindle-celled sarcoma (*sarcoma fusicellulare*): *a*, cells with two nuclei; *b*, cells in state of fatty metamorphosis; *c*, one process of the cell is bifurcated; *d*, long spindle cells; *d*, short spindle cells. (Zeiss Apochr., 4; Comp. Ocul., 4. After *Langerhans*.)

posed: fibro-, myxo-, glio-, melano-, chondro-, and osteo- sarcomata, respectively; according to their consistency, which depends principally upon the richness and character of the intercellular substance: soft and hard; according to the size of the cells: the small-celled and the large-celled sarcomata. *Sarcoma medullare* consists principally of cells—contains only very little intercellular substance. The cells of all sarcomata are derivatives of the cells of the connective substances, but they frequently reach a higher stage of development. According to the form of the cells are differentiated: round-celled sarcoma (*sarcoma globocellulare*), spindle-celled sarcoma (*sarcoma fusocellulare*), and reticulate-celled sarcoma (*sarcoma reticulare*). Giant-celled sarcoma (*sarcoma gigantocellulare*, myelosarcoma) is characterized by the

presence of numerous multinucleated giant cells. In all sarcomata the cells are separated sometimes by a slight amount (often scarcely recognizable), sometimes by more intercellular substance. Hence, the giant cells occasionally present a certain resemblance to cancer alveoli. There are, however, also true mixed forms (*carcinoma sarcomatodes*), in which certain areas possess a purely sarcomatous, and others a carcinomatous, structure.

Fig. 65.—Myeloid or giant-celled sarcoma. (*Virchow.*)

In **alveolar sarcoma** (see Fig. 66), the reticulum may occasionally be very delicate and formed of spindle cells, individual fibers, or by alveolar prolongations of the sarcoma-cells. The cells which fill the alveoli are often closely arranged like epithelia and intimately connected with the alveolar wall; if they are loosened from the alveoli, which, in contradistinction to carcinoma, is not readily accomplished, there generally are observed no entirely free spaces, as in carcinoma, but the alveoli usually are traversed by fibrillæ.

Melanosarcomata of the eye (melanocarcinomata and mixed forms occur here also) may originate from the corneal margin as flat, rounded, slightly lobulated, mottled pigmented tumors; or from the adipose tissue of the orbit (these soon cause exophthalmos or grow outward alongside the globe); or from the choroid, and then usually from the posterior

portion. The latter may perforate at the corneal margin, or follow the course of the optic nerve, or grow through the sclera.[1] These melanosarcomata usually extend early to the cerebral and spinal arachnoid, and also form numerous metastases in distant internal organs. Next to the eyes, the skin and rectum are most frequently the seat of primary melanosarcomata.

Osteosarcomata, *sarcomata ossium,* are divided into two principal groups: the external—periosteal, and the internal—myelogenous. The first develop from the periosteum, and are usually hard forms (*fibro-, chondro-, osteo- sarcomata*); the myelogenous are

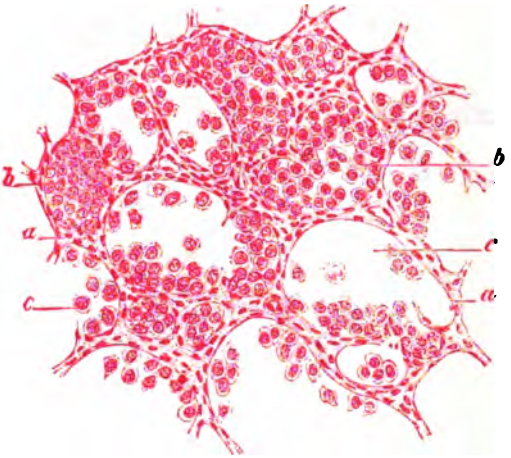

Fig. 66.—Alveolar sarcoma of the lymph-glands. *a,* stroma; *b,* cell-nests; *c,* alveoli with isolated cells. × 100. (After *Ziegler.*)

chiefly medullary forms. Periosteal osteosarcomata frequently invade the spongiosa at the point where the spongy portion of the bone lies close to the periosteum, in which case it is difficult to decide whether a periosteal or a myelogenous form exists. These tumors are usually composed of spindle cells; less frequently of round, stellate, or reticulate cells. Round cells are found in the youngest lamellæ, and are constant constituents of the cartilaginous lamellæ; the stellate and reticulate cells occur in the firmer, fibromatous, osteoid, and osseous parts. Giant cells are most frequently observed in the periosteal sarcomata of the jaws: **epulis**[2] (*sarcoma gigantocellulare*). The periosteal sarcomata soon invade in their growth the adjacent connective tissue, the fasciæ, and muscles, while they generally grow around

[1] See sarcoma of choroid.
[2] ἐπί = on; οὖλον = gum.

the vessels, nerves, and tendons. They form metastases in the mediastinal, bronchial, and cervical lymph-glands, and especially in the lungs. Sarcomatous epulis is sometimes hard, sometimes soft, and is situated either upon the jaw or invades the deeper structures. In the latter case the roots of the teeth also are usually involved. Some of them apparently develop from the periosteum of the alveolar processes. All forms of epulis readily recur.

Myelogenous osteosarcomata are very vascular, and consist prin-

Fig. 67.—Melanosarcoma of the choroid. Extrascleral deposits in and around optic nerve.

cipally of soft tissue; bone-tissue is either entirely absent or present only in the form of a capsule or shell. Their seat is chiefly in the spongiosa. Owing to their marked tendency to form cysts, they are called also cystic sarcomata. To the nonencapsulated sarcomata belongs *sarcoma fasciculatum*—a medullary sarcoma which is characterized by a distinctly radiate structure.

Parosteal sarcomata are closely allied to the periosteal; they are sometimes firmly connected with the bone. Medullary forms generally develop at the points of insertion of the muscles, and hard forms at the points of attachment of the fasciæ. These also recur *in loco*, and often form metastases in the lungs.

Sarcomata which develop from the fasciæ at a distance from the bone belong to the fibrosarcomata. Closely related to these are the sarcomata of the vascular sheaths.

Retroperitoneal sarcomata are generally medullary spindle-celled sarcomata; they sometimes form very large tumors, which may exert marked pressure upon neighboring parts.

Fungus durœ matris is located upon the inner surface of the dura in the region of the sella turcica and the petrous bone. It is usually composed of spindle cells, and causes deep erosion of the bone and atrophy of the brain without invading these structures.

Fig. 68.—Epulis. Numerous large spindle-shaped cells and four giant cells. Fresh section. (Zeiss Apochr., 4; Comp. Ocul., 8. After *Langerhans*.)

Large spindle-celled sarcomata, which originate from and adhere very firmly to the dura, invade the brain, but can very readily be shelled out and, indeed, often drop out spontaneously, are quite frequently observed upon the convexity of the brain. These sarcomata are generally pale reddish gray in color, and often present yellowish mottling; they are somewhat irregular, sometimes nodular upon the surface, quite dense, and have a distinctly striated intercellular substance. They do not form metastases. (See Edothelioma.)

In contrast to these the sarcomata which originate in the brain itself are soft and usually mixed tumors: **myxosarcomata** and gliosarcomata. These also are usually sharply bounded by the surrounding brain substance, and on incision are partly yellow mottled,

partly gray, and translucent; the telangiectatic forms are often bright red on section and partly hemorrhagic. These sarcomata always remain localized.

The serous, synovial, and mucous membranes in general manifest little disposition to form sarcomata. When sarcomata develop in these parts they grow slowly by formation of new nodules. The gastric mucosa is most frequently affected, and next the uterine and nasal mucosæ.

Glandular (adeno-) **sarcomata** (myxosarcoma and fibrosarcoma) are of more frequent occurrence. In the breast they attack

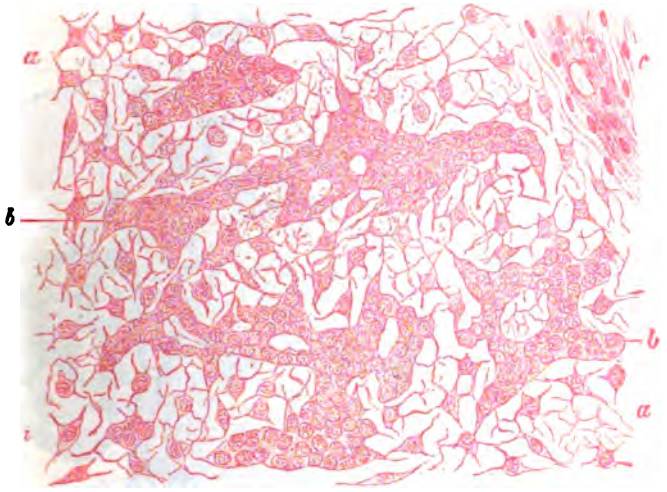

Fig. 69.—Section through a myxosarcoma (cylindroma). *a*, mucous tissue; *b*, fibrillated tissue. × 250. (After *Ziegler.*)

either a part (in the region of the sinuses) or the whole gland, but they rarely attain large dimensions. Generally, the surrounding adipose tissue also is involved. The milk-ducts are almost always markedly dilated. In contrast to carcinoma, the axillary glands generally remain uninvolved, even after long duration. Metastases are located in the pleura and lungs.

Lymphosarcoma (*sarcoma lymphaticum s. lymphomatodes*) differs from all other sarcomata in its seat of origin as well as histologicly. It develops as a result of progressive, often excessive, proliferation of the cells of the lymph-glands, the cells frequently changing their character and developing into large, often multinuclear cells, and it sometimes causes a similar proliferation in the adjacent lymph-glands: *i.e.*, heteroplastic, lymphosarcomatous affections of neighboring parts, and,

finally, generalization—metastases in distant organs. This malignant form is always medullary, in contradistinction to the hard form, which depends chiefly upon abundant intercellular connective-tissue proliferation of the septa of the lymph-glands, and results in the formation of only small, localized tumors. The medullary form originates most frequently from the cervical glands, mediastinal or retroperitoneal lymph-

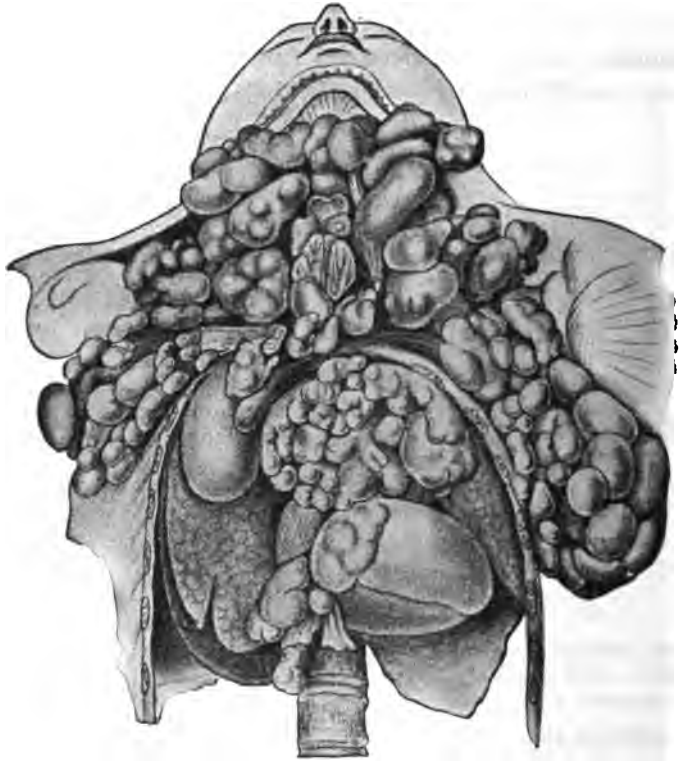

Fig. 70.—Lymphosarcoma of the lymph-glands of the neck, axillæ, and mediastinum. (After *Dietrich.*)

glands, and may easily be confounded with scrofulous glands. The most malignant lymphosarcomata are the mediastinal. The thymus gland is sometimes the seat of lymphosarcoma.

By **aleukemic myelosis (myeloid pseudoleukemia)** is understood all myelogenous tissue formations (independent of compensatory proliferations occurring in the anemias) in which the myeloid cells which they contain do not enter the blood to any marked degree. The process involves principally the lymph-nodes, which are enlarged and palpable.

The term **myelosarcoma** is employed to designate tumors composed of myeloid elements originating outside the bone-marrow. Their exact mode of origin is unknown.

The structure of **myelomata** varies. In most instances the cellular elements are myelocytes (myelocytoma), though a case in which the tumor was composed of erythroblasts (erythroblastoma) has been reported; or both these types of cells may be present (erythromyeloblastoma). Occasionally the tumors are characterized by a greenish color, the origin and nature of which are unknown (chloromyeloma). In many cases of myeloma Bence-Jones's albumin is found in the urine. The cells of the tumors are occasionally found in the blood.

Plasmocytoma is a rare tumor composed of plasma-cells and confined to the bone-marrow. The plasma-cells frequently are found in the blood.

H. Schridde[1] tabulates as follows the processes classed as pseudohyperplasias or true hyperplasias of the blood-forming tissues and to which, in his opinion, inappropriate names have in part been given:—

1. Pseudohyperplasias:

(*a*) Tuberculosis.

(*b*) Hodgkin's granuloma.

2. True hyperplasias:

(*a*) Regenerative and compensatory hyperplasias of the myeloid and lymphatic tissues.

(*b*) Tumor-like hyperplasias:—

(α) Aleukemic myelosis.
Aleukemic lymphadenosis.

(β) Leukemic myelosis.
Leukemic lymphadenosis.

(*c*) Genuine tumors of the blood-forming tissues:—

(α) Myeloma.
Lymphoma.

(β) Myelosarcoma.
Lymphosarcoma.

The pseudohyperplasias (tuberculosis, Hodgkin's granuloma), the true hyperplasias, especially aleukemic myelosis and lymphadenosis, and lymphoma and lymphosarcoma have heretofore frequently been classed under the term "pseudoleukemia," because clinicly the enlargements of certain groups of lymph-nodes (in the neck, groin, etc.) sometimes occurring in them possess a certain similarity to the lymph-node tumefactions observed in leukemic myelosis. They differ clinicly from the latter, however, by the aleukemic blood-findings. The most varied alterations: infectious granulomata, tumor-like hyperplasias, and true tumors, have, therefore, been included under the collective term "pseudoleukemia," which has led to great confusion. The designation "pseudoleukemia" is logicly

[1] Aschoff's Path. Anat., Bd. ii, p. 127.

untenable, because by it must be understood a blood-finding similar to that in leukemia. If the name is used at all, it should be employed only in connection with the blood-picture observed in leukanemia.[1] For these reasons Schridde would discard the term "pseudoleukemia."

LYMPHATIC TUMORS.

To this group belong the leukemic tumors, the typhoid, scrofulous, and simple hyperplastic lymphomata, and tubercle. Only the leukemic and the simple hyperplastic lymphomata will be discussed here. The other forms are fully considered in other portions of the text. (See p. 251.)

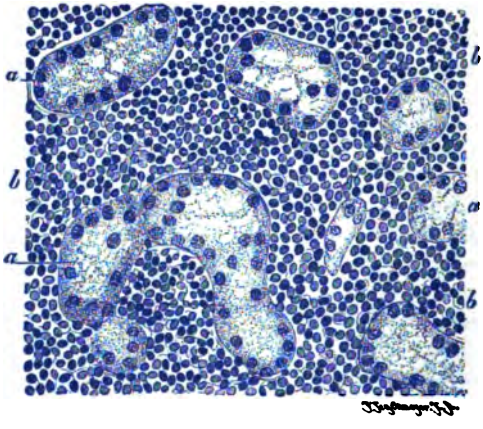

Fig. 71.—Leukemic infiltration of the renal cortex. *a*, urinary tubules; *b*, lymphocytes. × 150. (After *Ziegler.*)

Leukemia[2] develops either from the lymph-glands (lymphatic leukemia) or from the bone-marrow (medullary or myelogenous leukemia). In the first form progressive enlargement of the lymphatic glands and spleen occurs coincidently with advance of the disease. This enlargement is essentially due to increase of the parenchyma, which, however, is always accompanied by hyperplasia of all the remaining tissue. The spleen is at first softer, but becomes harder and firmer with further growth. In the more marked forms of the disease, heteroplastic proliferations are asociated with the hyperplastic, lymphatic growths, lymphoid tissue occurring in organs in which otherwise no such formations exist, namely, in the liver, kidneys, and retina. Involvement of these organs occurs either in the form of a diffuse lymphatic infiltra-

[1] Leukanemia is said to differ from pernicious anemia by the absence of hemosiderosis of the liver. (See Blood, p. 673.)

[2] For changes occurring in the blood, see Blood, p. 661.

tion, which starts from the vessels, or as small, circumscribed tumors composed entirely of lymphatic elements (follicular form). These manifest no disposition to undergo retrogressive metamorphosis; they are enduring structures, in contradistinction to (lymphatic) tubercles, the elements of which are characterized by their great tendency to disintegrate.

Myelogenous leukemia (leukemic myelosis) is characterized clinicly by the marked alterations of the blood (diminution in the number of the red blood-corpuscles; presence of large numbers of myelocytes and myeloblasts; eosinophilic and neutrophilic granulations within the same cell; erythroblasts, etc.). There are marked changes in the bone-marrow: increase of myeloblasts, ripe and unripe myelocytes; myeloid foci occur also in the liver, spleen, lymph-nodes, skin, and mucous membranes, etc.

Lymphomata, which may be local or general, are simple hyperplastic growths composed of lymphocytes and a fibrous reticulum in no way differing from that of the normal gland. They occur most frequently in the mesentery and do not form metastases. A variety known as **chlorolymphoma** is macroscopicly characterized by a green color. Histologicly, they manifest no deviations from the other variety.

Aleukemic lymphadenosis (lymphatic pseudoleukemia) is, as far as is known, histologicly indistinguishable from lymphatic leukemia.

Hodgkin's granuloma (disease) has no connection with so-called pseudoleukemia. The process occurs principally in youth, and involves most frequently the lymphatic glands of the neck, though the lymph-nodes of other localities (*e.g.,* groin) may be affected. Histologicly, the growths are composed of short spindle-cells, occasionally arranged in small bands, between which here and there are small remnants of lymphatic tissue and often numerous so-called giant-cells. More or less large areas of necrosis also are present, in the periphery of which very numerous eosinophilic cells are found. This eosinophilia is observed also in the liver, spleen, and other organs.

To the group of simple hyperplastic lymphomata belong hypertrophy of the tonsils, polypous hyperplasia of the solitary follicles of the intestine, and hyperplasia of the thymus gland. (See Status Lymphaticus.)

Hypertrophy of the tonsils is the result of chronic pharyngitis. *Angina catarrhalis tonsillaris,* or tonsillitis, is always accompanied by acute inflammatory swelling (edema and hyperplasia) of the tonsils. The tumefaction may very speedily subside or terminate in abscess or induration. If the catarrhal inflammation frequently recurs or the acute

process becomes chronic, permanent enlargement—a true hyperplasia—of the tonsils usually supervenes. As there is no disposition to spontaneous retrogression, but, on the contrary, a slow growth generally occurs in accordance with the repeated attacks of inflammation, the hyperplasia of the tonsils may become so decided as to threaten suffocation from narrowing of the pharynx. If the enlarged tonsils are removed by operation, small remnants generally remain, from which an equivalent for the extirpated tonsils sometimes develops. This hypertrophy of the tonsils (better: hyperplasia) is due essentially to increase of the lymphatic elements. Hyperplasias consisting principally of an increase of connective tissue are much rarer, and always result in induration and occasionally in ossification.

Polypous hyperplasia of the solitary follicles of the intestine is likewise a sequela of chronic catarrhal inflammation of the mucous membrane. At first the follicles are only somewhat more strongly swollen and a little more prominent than normal; later they become more and more elevated above the surface until, finally, small pedunculated polypi develop.

Pseudoleukæmia gastrointestinalis is an affection characterized by enlargement of the tonsils, cervical lymph-glands, spleen, the follicles of the gastrointestinal tract, and adjacent lymph-glands, due to hyperplasia of the lymphoid elements of these structures. The malady is associated with oligemia, poikilocytosis, occasionally nucleated erythrocytes, a relative increase in the small mononuclear leucocytes (lymphocytes), which occasionally may exceed in number the polymorphonuclears, but there is no leucocytosis. It is distinguished from Hodgkin's disease by the absence of tumefaction of the superficial lymph-glands. In the intestinal tract the follicles may be so enlarged as to form sessile or pedunculated nodules of considerable dimensions. The etiology is unknown.

So-called *asthma thymicum* occurs in young children as the result of hyperplasia of the thymus gland and consequent pressure upon the trachea, nerves, and vessels. Sometimes death occurs under the phenomenon of asphyxia. (See Status Lymphaticus.)

MYOMATA.

Myomata consist principally of muscular elements, either striped: *myoma striocellulare,* or smooth: *myoma lævicellulare.*

Myoma striocellulare (**rhabdomyoma**) occurs congenitally in the heart muscle. In the tongue (macroglossia) it is more frequently congenital than acquired. Macroglossia generally affects the anterior portion of the tongue, the lymphatic vessels and the inter-

stitial connective tissue being chiefly involved. Acquired macroglossia is almost always due to traumatism. In the congenital form the accelerated growth, the hyperplasia of the tongue—which even at birth is unusually large—begins soon after birth, and is generally accompanied by inflammatory phenomena.

Myoma lævicellulare (**leiomyoma**) generally consists of smooth muscle and connective tissue. If the latter is present in large amount, the tumor is designated as fibromyoma. As smooth muscle is colorless, pure myomata containing little or no connective tissue have a translucent, gray appearance. The more connective tissue present, the whiter the cut surface. In those portions containing fibrous connective tissue only, the tumor has a tendinous, sometimes a distinct mother-of-pearl-like, appearance. The blood-vessels are generally very few in number; in some cases, however, they may be so numerous and large as to impart a reddish color to the whole tumor: *myoma teleangiectodes* (**angiomyoma**, *myoma cavernosum*).

Growth occurs by division of the muscle-cells in all parts of the tumor. The elements are very enduring structures, which, in general, manifest little disposition to undergo retrogressive metamorphosis. If subsequent fatty metamorphosis occurs, fibrous induration follows, and frequently also calcification.[1] Softening and cystic degeneration are rarer. On the other hand, a distinct spontaneous diminution in size is frequently observed in advanced age (senile atrophy).

Myoma is a tumor of advanced life, is never congenital, and at the earliest begins at the period of puberty. It always has an irritative origin; repeated irritations (catarrhal inflammations of the mucous membranes) are often the cause, sometimes insufficient use (uterine myomata are said to be found most frequently in spinsters, while myomata are never observed in the arteries).

The uterus is the common seat of myomata. Myomata of the skin in the region of the breast nipples, upon the scrotum and eyelids, are rare; myomata of the digestive canal, especially of the stomach, are more frequently observed. Here they usually develop toward the serosa or mucosa, so that they sometimes assume a polypoid form.

Myomata of the prostate are generally designated as prostatic hypertrophy (*q.v.*). Two forms of prostatic hypertrophy are differentiated: glandular and fibromuscular hyperplasia.

The first form is much rarer than the second. Sometimes the muscular elements, sometimes the connective tissues, are principally affected; the process, however, is always disproportionate, *i.e.*, as a rule, only

[1] Compare p. 142.

certain points of predilection are more markedly enlarged. True prostatic myoma frequently originates from the upper margin of the isthmus—from the so-called posterior or middle lobe. It grows upward, at first forming a flat-round protuberance over the internal orifice of the urethra, and later a more or less large, globular, sometimes pedunculated tumor which may cause valve-like occlusion of the urethral orifice. The larger tumors are always distinctly lobulated in structure. Next in frequency to the so-called posterior lobe, the lateral portions (the true lobes) are the parts from which more or less large, lobulated myomata develop. Myoma of the bladder is rare.

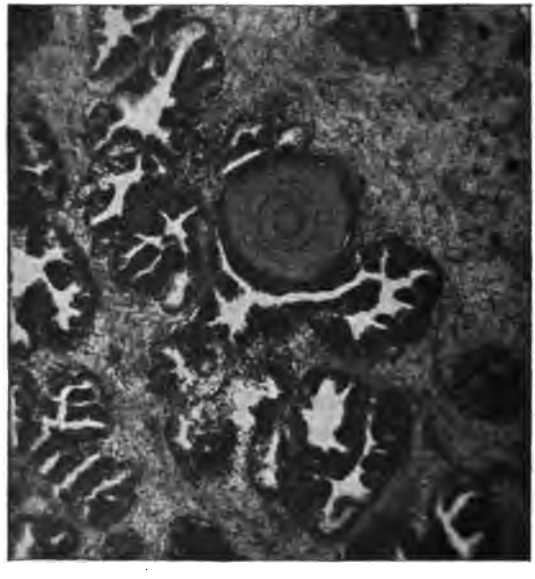

Fig. 72.—Hypertrophy of prostate. In the center, a so-called prostatic calculus.

Myomata of the uterus are almost always fibromyomata. Their relation to the uterus is like that of lipomata to adipose tissue. They are partial excessive hyperplasias. Three forms are differentiated according to their location:—

1. Submucous myomata.
2. Intraparietal (intramural) myomata.
3. Subserous (subperitoneal) myomata.

Submucous and subserous myomata either have a broad base or develop as pedunculated polypi. The muscular substance of the pedicle frequently atrophies, so that only a bridge of richly vascular connective tissue remains. Then, the tumors are generally very poorly vascular

and very hard. The subserous forms sometimes attain an enormous size (the size of a child's head and larger), and by friction, traction, and pressure upon neighboring parts may give rise to secondary disturbances. The most common location is the fundus. The submucous forms also start most frequently from the fundus, or from the posterior or anterior wall; they also are often pedunculated, but are generally softer than the subserous. The uterus itself, in accordance with the growth of the tumor, must enlarge in submucous myoma; it is not simply dilated, but the wall also is frequently hypertrophied. Inversion of the uterus is occasionally caused by the tumor when uterine contractions force the tumor toward the exterior; sometimes the tumor may also be detached and spontaneously expelled by the contractions.

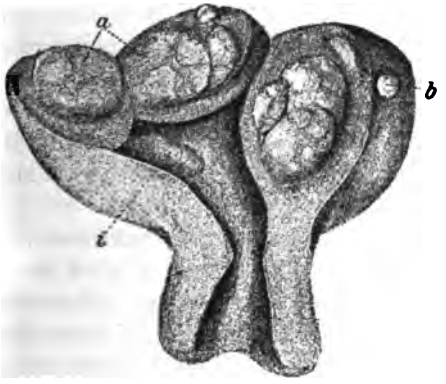

Fig. 73.—Myoma of the uterus. *a*, intraparietal; *b*, subserous; *c*, submucous. From a 54-year-old woman. Half natural size. (After *Langerhans*.)

In every case of submucous myoma the mucous membrane is in a state of chronic catarrhal inflammation, and manifests a tendency to hemorrhage. In chronic cases superficial ulceration, suppuration, and, finally, also gangrenous disintegration of the tumor very readily occur, and often are favored by therapeutic measures or physical examination. The submucous forms, like the subserous, may produce secondary disturbances by the size of the tumor.

The broad-based submucous fibromyomata constitute the transition to the intraparietal forms. The latter often grow larger than the subserous and submucous forms, and sometimes fill the whole abdomen—to about 50 kilograms (110 pounds) in weight. The cut surface of these large tumors is sometimes smooth and uniform, sometimes distinctly lobulated. They develop principally from the posterior wall of the uterus. With gradual growth the uterine cavity becomes

greatly altered in form; being displaced and drawn upon in its long axis, the cavity not infrequently assumes a crescentic or semicircular shape. If several myomata coexist, the cavity becomes still more markedly altered, much reduced in size, tortuous, and increased in length, so that it is sometimes difficult to trace the course of the long, narrow, distorted uterine canal. Frequent accompaniments are flexions (anteflexion and retroflexion), generally in the neighborhood of the internal os; elongation of the uterus, and often prolapsus. In some cases the myomata grow laterally into the *ligamentum latum*. These intraparietal forms also may produce secondary disturbances in surrounding parts.

Myoma teleangiectodes cavernosum occurs as a special form which, upon section, may present an almost sieve-like appearance. These are the softest and most richly muscular forms. Sometimes only a part of the tumor, sometimes the whole tumor, is of this nature. This variety of tumor occurs at a relatively early period and perhaps develops from the ordinary forms during pregnancy, in which state the whole uterine mass is altered in a very similar manner. By virtue of its innumerable dilated vessels and its numerous muscular elements, it possesses, within certain limits, the ability to increase or decrease in size, that is, to vary in dimensions.

The cystic form of myoma, *myoma cysticum*, produced by cystoid metamorphosis of a primarily solid tumor, is of rare occurrence. The cysts owe their origin to foci of softening. Hemorrhages into the interior occur easily, so that the contents of the cysts become hemorrhagic: *myoma cysticum hæmorrhagicum*. Cystic myomata like ovarian cysts, are multilocular.

By partial sarcomatous metaplasia, uterine myomata may be converted into true mixed tumors: **myosarcomata.** These also undergo cystic degeneration by fatty metamorphosis and disintegration of the cells, and by softening and solution of the intercellular substance: *myosarcoma cysticum.*

Myomata of the neck of the uterus: *myomata colli uteri*, are comparatively very rare; they usually develop into intracervical polypi, which occasionally protrude into the vagina. Elongation of one or both lips is almost invariably present also in this condition. If myomata of the uterine neck attain considerable size, dislocation of the body of the uterus may readily take place.

Myomata vaginæ are of rarer occurrence than myomata of the uterine cervix; they form quite large, soft tumors.

Myomata ligamentorum uteri usually develop by extension of uterine myomata to the respective ligaments. The ligaments may, however, also be the seat of independent myomata.

Myomata of the Fallopian tubes are equally rare; they are always of small size.

On the other hand, large fibromyomata may develop from the **ovaries.** These belong to the hardest forms, contain but few muscular elements, and, consequently, are very closely related to pure **fibromata.** Richly muscular fibromata are of very exceptional occurrence. In this condition the remaining tissue of the ovary is usually in a state of chronic interstitial oöphoritis—a proof of the irritative origin of fibromyomata.

NEUROMATA.

Neuromata consist of nerve substance and connective tissue. They occur most frequently upon the spinal nerves, more rarely upon the sympathetic, and most rarely upon the cerebral nerves. They occur also in the brain, spinal cord, and the ganglia. It is customary to differentiate peripheral and central neuromata; fibrillar or fascicular neuromata, and cellular or ganglionic neuromata. The peripheral neuromata must again be divided into those of the nerve-trunks and those of the nerve-endings—the so-called terminal neuromata. They sometimes consist, according to the principal constituent, of nerve substance—pure neuromata; sometimes a large amount of interstitial tissue is present, mixed forms thus originating: fibroneuromata, glioneuromata, myxoneuromata. According to the nature of the nervous substance, three groups are differentiated:—

1. *Neuroma fibrillare amyelinicum:* nonmedullated, gray neuroma. Upon section a dense fibrillar reticulum is seen which is macroscopicly and microscopicly similar to the fibromata.

2. *Neuroma fibrillare myelinicum:* consists of medullated nerve-fibers.

3. *Neuroma medullare:* soft, sometimes more white, sometimes more gray, ganglionic neuroma, often with soft, glious interstitial substance.

Heteroplastic neuromata are located in the sexual glands: testes and ovaries.

Amputation neuroma belongs to the hyperplastic neuromata. If a number of neighboring nerve-trunks lie together in the amputation stump, they frequently coalesce and form a single nodule. In a similar manner, regeneration occurs within the cicatrix in simple division of a nerve, budding taking place from the axis cylinder of the central stump, and these buds growing into the peripheral stump. Amputation neuromata are usually ovoid or spheric swellings of insignificant size

(seldom as large as a plum). Those varieties which develop after ligature of nerves, and many others of traumatic origin, are closely related to the last-mentioned forms. Others originate in the neighborhood of chronic inflammatory alterations. To these belong the neuromata in congenital and acquired elephantiasis. Congenital neuromata are not infrequently multiple, nodules being present either upon the same nerve (rosary-like) or upon the branches of a nerve (plexiform) or upon many nerves. The same relation exists in hereditary neuromatosis. Central neuromata belong to the congenital formations. These are usually multiple, small nodules of gray substance within the white matter, which often lie beneath the ependyma of the lateral ventricles.

An hyperplastic neuroma formation occurs in the spinal cord in the form of a congenital sacral and coccygeal tumor.

True neuroma is a local, benign tumor. It develops slowly, may recur and even become multiple, and, consequently, under certain conditions, may be malignant; it never, however, forms metastases of the glands, and does not result in generalization.

Fatty metamorphosis, softening, and cystoid transformation are rare.

ANGIOMATA.

Angiomata consist essentially or wholly of new-formed vessels, or of vessels with new-formed elements of the wall. Not all partial dilations of the vessels with tumor-like exterior (aneurisms and varices) belong here. The limitations cannot, however, everywhere be sharply defined, since new formation of elements of the vessel wall occurs also in simple aneurism and varix. Furthermore, all those tumors are to be excluded which have already been mentioned as telangiectatic subdivisions in connection with other tumors.

Three forms of angiomata are differentiated:—

1. *Angioma cavernosum.*
2. *Angioma simplex.*
3. *Angioma racemosum.*

1. Cavernous angioma consists of numerous, large, intimately connected blood-spaces which occupy the position of the capillaries and merge into wide, tortuous, and frequently sacculated veins. The size and form of the spaces are very variable; they are lined with delicate endothelium, and consist of a basement structure (trabeculæ and flat partitions with nodal points) composed of ordinary connective tissue. In this are sometimes found also elastic fibers and smooth muscle; in the coarser trabeculæ also vessels (*vasa vasorum*) and

nerves. The tumors are of greater or lesser density according to the amount of this tissue present. They are partly compressible (like the *corpora cavernosa*), partly noncompressible; partly pulsatile, partly not. They receive their blood from arteries, with which they always are connected, and convey it to veins. Encapsulated cavernous angioma (*angioma cavernosum circumscriptum, incapsulatum*) has an especial connective-tissue capsule which is the product of a secondary inflammation of adjacent tissue, and is, therefore, absent in very young tumors. The capsule forms the definite limits of the growth. *Angioma cavernosum diffusum,* like all other angiomata, has no capsule; here gradually enlarging interstitial areas, consisting of the surrounding tissue, develop at the margin and grow in between the blood-spaces. Encapsulated angiomata grow to walnut size; the diffuse to the size of the fist. Flat extension is characteristic of the latter. Both forms originate from dilation of new-formed vessels and their transformation into cavities, which may coalesce, the interstitial tissue disappearing by atrophy. The dilation of the vessels is not passive distention with gradual thinning of the walls, but an active hyperplasia, an ectasis with progressive increase of the mural elements. Hence, angioma also belongs to the proliferation tumors the origin of which is due to irritation.

These angiomata are not infrequently congenital, beginning as smaller or larger red spots; they are very rarely hereditary. The congenital may remain stationary for a long time, and then suddenly begin to grow rapidly. In some acquired cases trauma is stated as a cause.

According to their location are differentiated external and internal angiomata.

Cutaneous angiomata are more or less elevated; they are sometimes uneven, lobulated, and resemble in form a strawberry or mulberry. They are located most frequently upon the head and adjacent parts of the throat and neck; those parts which in early embryonal life correspond to the fissures (branchial clefts, oral and nasal clefts, lachrymal and palpebral clefts), and which do not close until a late period of intra-uterine life, are especially disposed. These fissural angiomata extend from the external skin to the neighboring mucous membrane, *e.g.,* from the lip to the gums, and in the depth to the adipose tissue and sometimes into the muscles. The auricular angiomata are the most common; then follow in frequency the labial, nasofrontal, palpebral, and, finally, the buccal angiomata. Upon the throat and neck, the submaxillary and retroauricular regions; upon the trunk, the region of the sexual organs, are especial points of predilection.

The **subcutaneous angiomata** have points of predilection similar to the cutaneous. Two forms are differentiated: lipogenous and

phlebogenous. The former lie in the fat-tissue and are diffuse angiomata, which grow comparatively large and often secondarily involve the skin. This, probably, is the commonest form of angioma. The phlebogenous are encapsulated and intimately connected with venous trunks. Upon the head the subcutaneous angiomata occur principally upon the cheeks and in the orbital cavities; upon the trunk, in the axillary region. Of the extremities, the forearms and hands are most often affected.

Pure muscular and pure glandular angiomata are among the greatest rarities.

The osseous, particularly peripheral angiomata of the bones, are somewhat more frequent, especially in those parts where the bone is uncovered by muscles, or only by a very thin layer (head, scalp, sternum).

Of internal cavernous angiomata, that of the liver is most frequent. It develops after birth (as does that of the spleen and kidneys), is found oftener in elderly persons than in the young, and, therefore, belongs to the acquired angiomata. It sometimes attains the size of a walnut, and usually lies directly under Glisson's capsule, at a point where ordinarily true liver-tissue is found. It begins in the center of an acinus, with connective-tissue proliferation. The development of vessels occurs in the new-formed connective tissue.

2. Simple angioma (*angioma simplex, teleangiectasis*) consists of very wide, partly new-formed, capillaries, the walls of which are altered. The arteries and veins also may be involved, though the alteration of the capillaries always predominates. This form of angioma also is distensible (swells) in congestive states. Ordinarily it does not appear in tumor form, but as a diffuse, flat growth. The margin is not sharp; on the contrary, transition is rather gradual. One of the most frequent forms of simple vascular tumor is *nævus vasculosus seu teleangiectodes,* the so-called mother's or birth- mark. The more superficial the vessels, the brighter is the red color of the angioma: *nævus flammeus:* "fire-mark" or "port-wine mark." These diffuse nevi attain the greatest size upon the face and extremities. In general, they have the same points of predilection as the cutaneous cavernous angiomata.

Nævus subcutaneus teleangiectodes lipomatodes is frequently of true tumor form, sharply defined, and noncapsulated.

In *angioma simplex hyperplasticum* numerous, thick-walled, corkscrew-like vessels occupy the place of the capillaries.

Angioma varicosum simplex affects principally the venous radicles, while the true capillaries are but slightly involved. The smallest veins

are strongly dilated, varicose; the normal tissue gradually disappears as a result of this sacculated ectasis. This form occurs in the skin, in the subcutaneous and deep tissues, and in the liver.

Venous (varicose) and simple angiomata are usually congenital, but they develop also soon after birth. They generally grow rapidly; spontaneous retrogression also occurs.

Hemorrhoids (piles), which are closely related to cutaneous angiomata, are located either outside (covered with squamous epithelium) or within the anus (covered with cylindric epithelium)—either subcu-

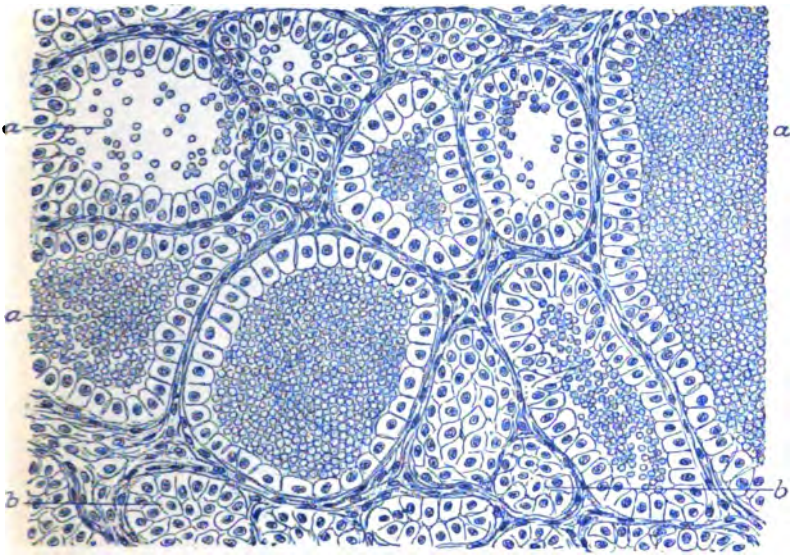

Fig. 74.—Hemangioma with hypertrophic endothelia (endothelioma) of the kidney. *a*, blood-vessels filled with blood; *b*, blood-vessels filled with proliferated epithelia. × 300. (After *Ziegler.*)

taneous or submucous; occasionally also they are semisubcutaneous and semisubmucous. In this condition the hemorrhoidal plexus in the region of the external sphincter of the anus is involved. The varicose points correspond most frequently to the highly vascular longitudinal folds (*columnæ Morgagni*) within the anus. The hemorrhoidal nodes consist of a convolution of very tortuous varices. The cut surface, therefore, sometimes has an apparently cavernous appearance. Between and in the vicinity of the individual varices there is always a certain amount of tissue, called hernial sac, containing veins and arteries. These hemorrhoids are of very frequent occurrence, but they usually do not develop until middle age. A certain predisposition appears to be of importance,

but an especial immediate cause (retention of fecal masses, chronic catarrh of the rectum, etc.) is always required in order to produce the local disorder of the anus. In addition to the hemorrhoidal bleedings, this local affection is associated in successive order with fluxional disturbances of other organs, due to congestion in the vascular apparatus. There are two different forms of bleeding in hemorrhoids. Only one originates from the hemorrhoidal nodes; the other comes from the vessels of the mucosa. The latter is an accompaniment of an existing

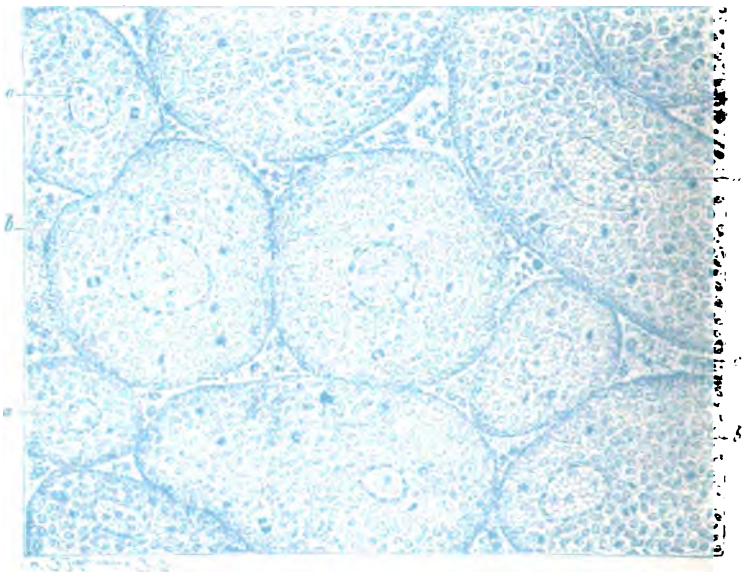

Fig. 75.—Section through a nodular so-called angiosarcoma of the thyroid gland. *a*, transverse section of vessels; *b*, perivascular cell cylinder with numerous mitoses in transverse section; *c*, granular masses with cells between the individual cell cylinders. × 80. (After *Ziegler*.)

chronic catarrh, while the former is usually the result of increased blood-pressure. The hemorrhoidal nodes, especially after severe hemorrhage, may spontaneously subside, shrivel; inflammation with final ulceration or gangrene is more frequent. Thrombosis with subsequent connective-tissue contraction or softening sometimes occurs, from which abscess and anal fistula may result.

Simple angiomata are found also in the central nervous system—in the brain, spinal cord, arachnoid, and tela chorioides. In the brain the floor of the fourth ventricle is relatively frequently affected. The structure is always in the form of blood-sacs, the communication of

which with vessels can plainly be demonstrated. The blood-sacs develop either from capillaries or small veins.

In the class of false angiomata: *angiomata spuria,* belong the angiomatous varieties of other forms of tumors. Indeed, the development of ectatic vessels is sometimes so pronounced that the angiomatous character, at least in certain parts of the tumor, predominates. This is true especially in soft gliomata, myxomata, and sarcomata of the brain, and in lipomata, myxomata, and sarcomata of soft parts and of the bones of the extremities. The same phenomenon occurs also in



Fig. 76.—Extirpated lymphangioma of the hand. *l,* wide lymph-vessels; *b,* connective tissue. (Zeiss Apochr., 16; Comp. Ocul., 4. After *Langerhans.*)

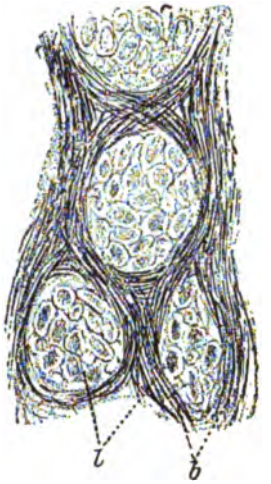

Fig. 77.—A part of Fig. 76 strongly magnified. *l,* elastic lymph-vessels with single layer of epithelium; *b,* connective tissue. (Zeiss Apochr., 4; Comp. Ocul., 4. After *Langerhans.*)

many polypi of mucous membranes, especially in the posterior portions of the nasal cavity, in the uterus, and in the anterior part of the female urethra.

3. The racemose angiomata are characterized by the fact that the whole extent of a vessel is dilated. Here the tumor character may be obscured. It is often very difficult to draw a distinct line between simple ectasis, varix, and aneurism.

Thus, dilations of the vessels without true tumor character occur in *aneurysma spurium arteriovenosum* or *anastomoticum,* which, usually of traumatic origin, is caused by communication between arteries and veins.

In cirsoid aneurism, *aneurysma racemosum,* there is dilation of the branches of an artery as well as of its collaterals. The more marked the dilation, the more the adjacent tissue atrophies (*e.g.,* bones). Aside from the dilation, such a vessel increases in length, whereby it becomes tortuous and varicose. If the condition occurs only upon the trunk of an artery, it is designated as *aneurysma serpentinum.* A portion of these cases develop in intra-uterine life; a portion are the result of mechanical influences. Increase in the mural constituents is always present. As soon, however, as marked sacculation occurs, the walls become gradually thinner. Racemose aneurism occurs most frequently upon the head and extremities.

Closely allied to racemose aneurism is the more frequent *varix racemosum* (*cirsoides, anastomoseon*). It occurs principally upon the lower extremities, the labia, and the spermatic cord (varicocele of the veins of the spermatic cord), rarely upon the head (here, after erosion of the skull, it may communicate with the sinus of the dura mater), and upon the hand. Spontaneous thrombosis, which occasionally results in the formation of phlebitis, readily occurs in these racemose varices.

Lymphangioma occurs most frequently in the racemose form as *lymphangioma racemosum.* As such it may form tumors of considerable size. Furthermore, lymphangioma participates markedly in elephantiasis lymphorrhagica, especially in the tropics. In macroglossia also there is an interstitial hyperplasia of the connective tissue with the formation of lymphatic spaces: *lymphangioma cavernosum.* Lymphangiomata develop by hyperplasia with ectasis as well as by true new formation of lymph-vessels.

2. The Organoid Tumors.

These are composed of several tissues combined to form a complicated structure and often arranged in organ-like manner.

CARCINOMATA.

In their histologic structure carcinomata possess a marked resemblance to true glands—organ-like (organoid) structures. Like glands, they consist of a connective-tissue stroma[1] (see Fig. 78) and epithelia, which lie in groups. (See Fig. 79.) There is, however, a characteristic difference, inasmuch as the epithelial groups have no central lumen, as do all true glands. The spaces occupied by the epithe-

[1] The stroma frequently undergoes hyaline change and very rarely calcification.

lial groups are called alveoli,[1] because, on section, they present a certain resemblance to the arrangement of lung-tissue. As these alveoli are completely filled with epithelia, solid cell-nests are produced. In the latter no definite arrangement or order of the epithelia can be recognized; indeed, the impression almost always received is that the epithelia are grouped together lawlessly.

The size of the alveoli containing the epithelia in relation to the breadth of the connective-tissue stroma varies within very wide limits. In scirrhous carcinoma the connective tissue is so much in excess

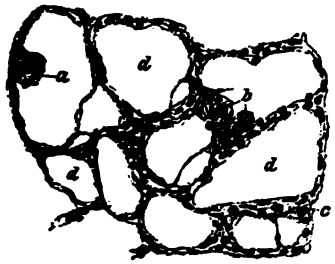

Fig. 78.—Carcinoma stroma from a renal carcinoma of a 51-year-old man. *d*, empty alveoli; *c*, stroma; *a*, one epithelial cell; *b*, two epithelial cells.

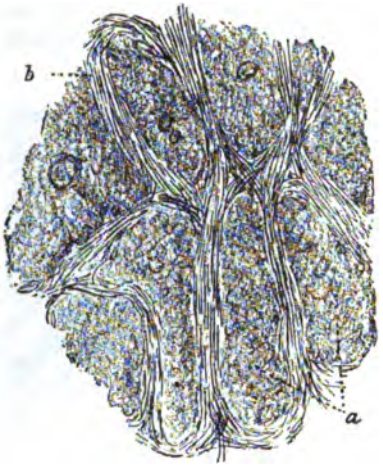

Fig. 79.—Section from an extirpated carcinoma of the parotid of a 54-year-old woman. *b*, stroma; *a*, alveoli completely filled with epithelia. (Zeiss Apochr., 16; Comp. Ocul., 4. After *Langerhans.*)

that it is often possible positively to perceive the alveoli and the epithelia filling them, and thus to determine the carcinomatous structure, only after the most careful and exact microscopic examination. In medullary carcinoma, on the other hand, the alveolar structure may be so obscured—so slight in comparison to the width of the alveoli—that it is easily overlooked. Between these extremely cellular and very poorly cellular forms there are numberless transition forms, the alveoli being sometimes large or small, the stroma narrow or broad.

[1] In microscopic sections there is unquestionably a resemblance to filled alveoli: a section through the freely communicating alveoli of the lung causes these to appear absolutely separated. From this resemblance to the pulmonary alveoli, the statement that carcinoma has an alveolar structure and that the alveoli are filled with groups of epithelial cells will readily be understood.

Here attention must be called to confusion of compact carcinoma cell-nests with surface section of glands, which occurs by section through the wall of a convolution of a duct, the lumen not being included in the section. Such diagonal sections are characterized by the fact that on transverse section the nuclei of the cells become smaller and smaller in the direction toward where they disappear, and, finally, only those parts of the cell are cut in which no nuclei are present. (See Fig. 80.)

Oestreich has compared the development of carcinoma with the growth of the roots of a tree, extending in all directions from the surface downward, *i.e.*, from the point of origin into the surrounding parts, especially into the deeper tissues. (See Fig. 81.) The growing epithelial masses resemble the roots: they are

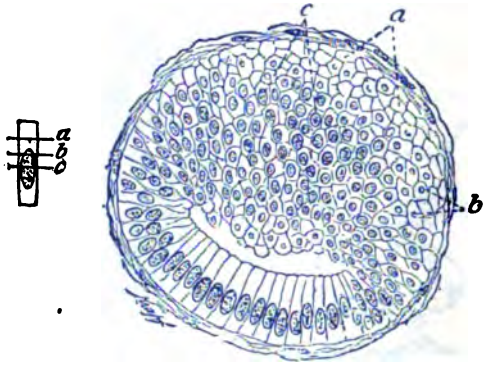

Fig. 80.—Slant section through a regular gland. Contrasted with atypical proliferated cells the nuclei grow steadily smaller toward *c* and *b*, and are lost at *a*. The opposite gland wall is given as cut perpendicularly. (After *Amann*.)

thicker or thinner, broader or narrower, branched or undivided. The soil between the roots corresponds with the tissue which has been penetrated by the epithelium. At one place the epithelial roots are close together; at another place they are farther apart. The relation of the roots to the soil, *i.e.*, of the epithelial masses to the penetrated tissues, cannot always be recognized in microscopic sections, because in the latter the divided epithelial roots appear distinctly separated. Section through epithelial roots and penetrated tissue severs the roots in very different directions: certain roots are cut across, others lengthwise, and others at the point of branching. Very diverse pictures are thus produced, which, however, correspond in so far as more or less closely arranged, but apparently isolated, epithelial roots can always be seen in the tissues. When tips of roots (epithelial bands or cords) are cut through, individual epithelial cells or small groups of them can be seen. The tissue into which the epithelium grows, penetrates, and destroys or causes to disappear is not always the same. In many cases it is connective tissue: then the interstitial tissue (stroma) of the carcinoma is connective tissue. In other cases the epithelium invades the musculature (*e.g.*, muscularis of the stomach in gastric carcinoma): then the stroma of the carcinoma is muscular in nature. Where the

epithelium grows between the liver-cells, the latter represent the stroma. The growth of carcinomatous epithelium within the lungs—within the alveoli or lymph-vessels—occurs into the pre-existing spaces.

The word carcinoma (ὁ καρκίνος, crab) is derived from an external appearance—which is by no means constant—in that carcinoma of the female breast, which is often accompanied by cicatricial contraction, causes congestion of the cutaneous veins, so that the latter, strongly engorged, stand out prominently from the skin and run toward the region of the nipple. The appearance presented by the female breast

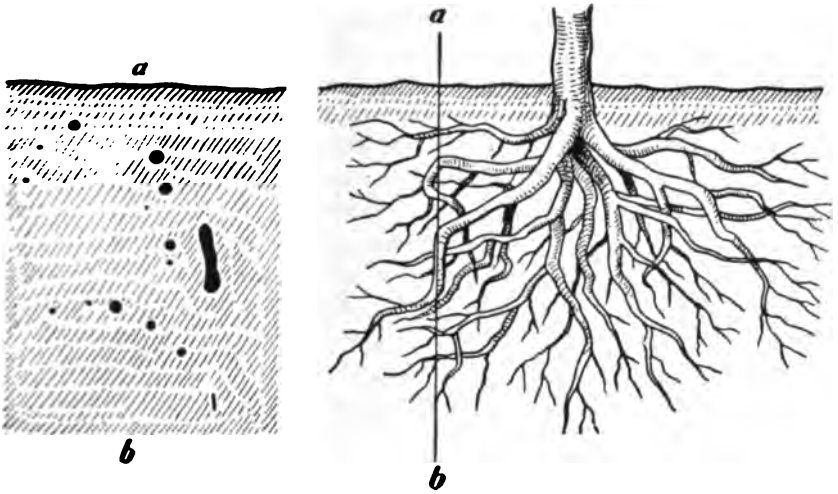

Fig. 81.—On the right the roots of a tree. On the left a view of section through roots and soil in the direction *a* to *b*. (After *Oestreich.*)

as a result of this change has a remote resemblance to a boiled crab, and, owing to this resemblance, ancient physicians employed for this disease the designation crab (cancer). Since then this name has been retained, although at different times very different conditions were included under this term.[1] At the present day is understood by carcinoma an **atypical epithelial growth which extends from the surface inward and forms for itself channels and routes at the points of least resistance.** Therefore, strictly speaking, carcinoma does not consist of stroma and alveoli filled with epithelia, but of epithelial papillæ which grow into the depth and there often form dendritic branchings. The

[1] "The word cancer is best regarded as the substantive which is equivalent to the adjective malignant, so that a malignant tumor of any sort, carcinomatous or otherwise, is a cancer. If we accept this, there is no longer any need of discussing the compass of the word cancer."—Moxon.

alveoli are, therefore, not closed spaces, but only diagonally or transversely sectioned papillæ; and the stroma is, in great part at least, the old tissue into which the epithelial papillæ have grown. As the connective tissue of the stroma or of the structures adjacent to the carcinoma frequently proliferates, a portion, but not all, of the connective-tissue structure (stroma) of a carcinoma may be new formed.[1]

As regards **etiology** only three factors are definitely known, namely, **heredity, advanced age** (on an average from the 40th year onward), and **irritation.** The first consists probably only in an inherited disposition, a certain weakness or vulnerability of the tissues which, how-

Fig. 82.—Stroma of cancer, lying in which are the alveoli, from which the epithelioid cells have been removed by pencilling. × 300. (After *Cornil and Ranvier.*)

ever, does not of itself suffice for the development of carcinoma. Advanced age also can be considered only as a moment favoring carcinomatous development, since not every elderly person is affected with carcinoma; on the contrary, young individuals also die from it. Advanced age is, perhaps, of influence in the development of carcinoma, in so far as retrogression of many tissues begins at this period. The third point, namely, irritation, has been positively established, partly by clinical experience, and partly by histologic observation. Antecedent inflammatory disturbances, ulcerative processes and cicatrices, continued and oft-repeated chemic and mechanic irritation of certain portions of the

[1] While in certain localities connective tissue as well as epithelium may be produced, and new blood-vessels may develop, the essential constituent characterizing the tumor is solely the epithelium growing unrestrictedly. Carcinoma, therefore, must be designated as an epithelial growth.

body, and traumatic influences are, in many cases, responsible for the irritative inception of carcinoma. It has repeatedly been observed that carcinoma develops in tissues which deviate in structure from the normal arrangement of the affected region of the body, or are incompletely developed or in a state of involution. For example, carcinoma develops from a cicatrix which is subjected to particularly marked irritation; from an old ulcer of the leg or a chronic gastric ulcer; carcinoma of the lip, principally in habitual pipe-smokers ("clay-pipe or smokers' cancer"[1]); the so-called "chimney-sweepers' cancer" upon the scrotum of chimney-sweepers, and "paraffin-workers' cancer" upon the external skin of the forearm in paraffin workers, and the horny carcinoma after prolonged use of arsenic. In the intestinal tract the constricted portions —the naturally narrow parts—are the locations most frequently affected with carcinoma; these are just the regions in which the surface comes in close and intimate contact with the ingesta during function. Finally, the greatest percentage of all carcinomata is found in those parts of the female body which most frequently are subjected to injury and irritation, namely, the breasts (milk-ducts) and the cervix of the uterus.

Opposed to this irritation theory of the genesis of carcinoma, which is well supported by numerous facts and is essentially due to Virchow, are other theories, namely, Cohnheim's, according to which carcinomata develop from embryonic germs (inclusion theory); the parasitic theory, which, although generally abandoned, here and there still finds adherents, and other theories. At present the question seems to be whether, in the beginning of carcinoma development, proliferation of the epithelium or a change in the subepithelial structures (*cutis, mucosa*) is the primary phenomenon. Here it is assumed that both parts in their intact state are interdependent and mutually so influence each other that they inhibit proliferation. If, from any cause, this equilibrium is disturbed and the restraining influence of one tissue thus suspended, the other tissue begins to grow, and the above-described atypical epithelial proliferation may now take place. In order to elucidate this and other questions, many attempts have been made experimentally to produce carcinoma or to transplant human carcinoma into animals, but usually only with little or no success. In this regard there was published several years ago an experimental study (Borsch, of Vienna) which is of great interest, in so far as it appeared to indicate that a way had been found by which cutaneous carcinoma may with certainty be produced experimentally in animals. Borsch influenced productive processes (wound healing, inflammation, etc.) by continued irritation of a physic

[1] In 54 consecutive cases of carcinoma of the lip observed by Bryant, 9 had never smoked. Pract. of Surg., Am. ed., 1881, p. 393.

and chemic nature, and demonstrated that such long-continued irritation prevented their normal progress. Consequently, an increased and more rapid formation of cellular elements occurred, whereby the individual cells became more and more unstable. In this manner alterations corresponding to cutaneous carcinoma were obtained. Should these experiments be confirmed, a decided advance would be made in our knowledge of this subject, and, at the same time, a confirmation of Virchow's irritation theory would be furnished.

Almost all carcinomata, even the richly cellular, are characterized by a peculiar hardness; the more they approach the scirrhous form and the slower they grow, the harder they are. In almost all carcinomata, with the exception of the true scirrhous forms, a milky substance can be expressed from the cut surface by lateral pressure.[1] This cancer milk consists principally of the epithelial cell-nests, which



Fig. 83.—Cells from a scirrhus of the mamma. × 350. (After *Green.*)

always are in a state of partial retrograde fatty metamorphosis. This is often so far advanced that the whole cellular content presents great resemblance to milk or colostrum. In this case it is often very difficult microscopicly to find well-preserved cells. This retrograde metamorphosis, through which a portion of the carcinoma cells is destroyed, has been designated by Virchow as a kind of spontaneous cure which, however, is of no significance for the carcinoma patient, because the further development of the carcinoma is not arrested by it.

In the beginning, many carcinomata form only a simple swelling. If the affection progresses, certain differences appear which are of decided importance to the patient. Thus, in certain carcinomata the alveoli at the surface of the skin or mucous membranes disintegrate, chemic and physic influences acting from without (intestinal contents, external surfaces of the body, urinary passages, etc.), which cause the carcinoma nests to be discharged. In this manner a carcinomatous ulcer, *ulcus carcinomatosum,* often develops without the formation of

[1] It is sometimes thick and on pressure exudes from the cut surface in vermicelli-like form. (See Epithelioma, p. 280.)

a genuine, distinctly recognizable tumor. Carcinomatous ulcer occurs principally in carcinomata of superficial parts; in many instances it can be differentiated from a simple ulcer only by microscopic examination, distinct carcinoma structure being recognizable only in the (sometimes thickened, tumor-like) margin and base of the ulcer. This ulcerative form of carcinoma is usually associated with profuse secre-

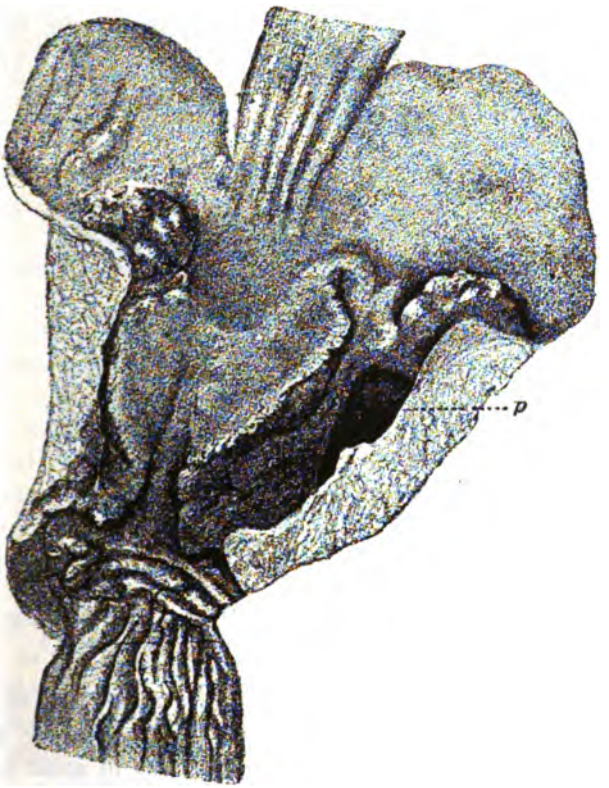

Fig. 84.—Ulcus carcinomatosum ventriculi perforans colon transversum. The site of the carcinoma is the greater curvature. At *p*, the point of perforation. ⅓ natural size. (After *Langerhans*.)

tions, which, more than anything else, favor the development of carcinoma cachexia. As a rule, as a result of external influences which excite suppuration or putrefaction, disintegration of the surface of the ulcer with mortification soon occurs, which transforms the carcinomatous ulcer into an *ulcus putridum*. Occasionally, however, the carcinomatous ulcer may be so cleansed of all carcinomatous masses that it appears as an *ulcus depuratum*. In such localities cicatrices are formed, while new

carcinoma eruptions appear at other points and produce new destruction. With cicatrization there is always retraction, which, especially in canals, particularly in the esophagus, stomach, and intestine, may produce marked narrowing: *stenosis carcinomatosa.* More or less intense narrowing is often associated with even the first swelling and tumor formation. This is the case especially in the naturally narrow portions of the gastrointestinal tract: the esophagus, the cardia, the pylorus, etc.

In contrast to the ulcerative form stands the true tumor form. In this condition disintegration of the surface is by no means excluded, but the formation of tumor is usually most prominent. These carcinomata also develop from the surface, but later extend chiefly

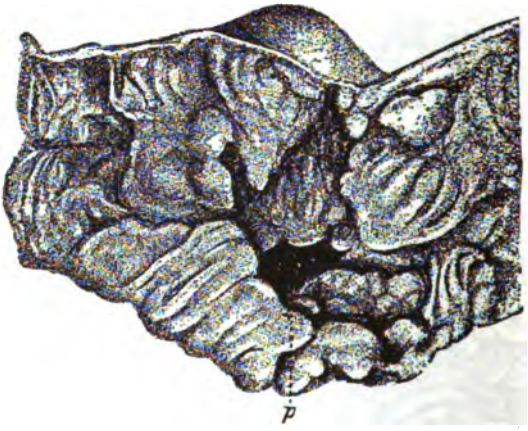

Fig. 85.—Same as Fig. 84; view from transverse colon at *p*, the point of perforation. ½ natural size. (After *Langerhans.*)

into the deeper parts, *e.g.,* into the subserosa. They have either a fungous form with broad base and overhanging margins or a nodular, lobulated, irregular surface. The conformation is in great part due to the development of new daughter-nodules in the neighborhood of the older tumor-nodules, as a result of which the tissues are pushed aside, undergo atrophy, and finally are replaced by carcinoma tissue. The daughter-nodules preserve for a time a certain independence and coalesce with the older parts of the tumor only on further progress of growth: growth *per appositionem.* These tumors generally form liver metastases, in which retrograde fatty metamorphosis always occurs, but never ulceration.

A large number of carcinomata are characterized by their association with wart-like or papillary proliferations: *carcinoma papillare.* The proliferated, enlarged papillæ are sometimes branched and then

form long, villous excrescences: *carcinoma villosum,* "villous cancer" (*e.g.,* in the bladder). The surface thus acquires the appearance of a cauliflower: *carcinoma cauliflore.* In all these papillary and villous forms of carcinoma the superficial excrescences do not consist of carcinoma masses; they are pure inflammatory proliferations of the surface, such as occur also in ordinary warts, in condylomata, etc. The papillary growth is sometimes so abundant that the quite scanty carcinoma tissue beneath the papillæ and villi can be found only with difficulty.

A third form in which carcinoma appears externally is smooth, atrophic: *cancer atrophicus, retrahens*—the scirrhous form.[1] It begins as a scarcely noticeable swelling, so that often only the unusual hardness of the affected part arouses the suspicion of carcinoma. Extension takes place slowly in the form of diffuse infiltration as infiltrating, indurating carcinoma, and always results in very marked diminution in size of the affected parts by contraction of the new-formed connective tissue (*e.g.,* in the intestine), almost never in ulceration.

Fig. 86.—Gastric carcinoma in an old woman. Fungous form. The seat of the carcinoma is the posterior surface of the stomach, midway between the cardia and pylorus. At the lesser curvature: extension of the carcinoma into the submucosa. ¼ natural size. (After *Langerhans.*)

According to the variety of epithelium which fills the so-called alveoli are differentiated: squamous-celled carcinoma, cylindric-celled carcinoma, transitional-celled carcinoma, and glandular-celled carcinoma. These different forms depend upon the epithelium of those surfaces from which the carcinoma develops. Frequent deviations, however, occur, *e.g.,* squamous-celled carcinomata developing —sometimes even with hornification—from the gall-bladder or the bronchi, which are provided with cylindric epithelium. In these cases an epithe-

[1] Scirrhus does not occur in tumor form.

lial metaplasia (see p. 108) must have preceded the development of the carcinoma. Squamous-celled carcinomata sometimes develop from localities which possess no epithelium,[1] for example, from the tibia. A definite explanation for all these cases is at present impossible. It may, however, be supposed that displaced embryonal germs, or cells conveyed at a later period—after birth—by the blood-current or lymph-stream, may be the starting point of tumors. That displacement of cells does occur in the body is shown by the fact that decidual cells are always found in the pulmonary capillaries of women who have died shortly after labor, and also by the fact that liver-cells not infrequently can be found *post mortem* in the lungs of eclamptics.

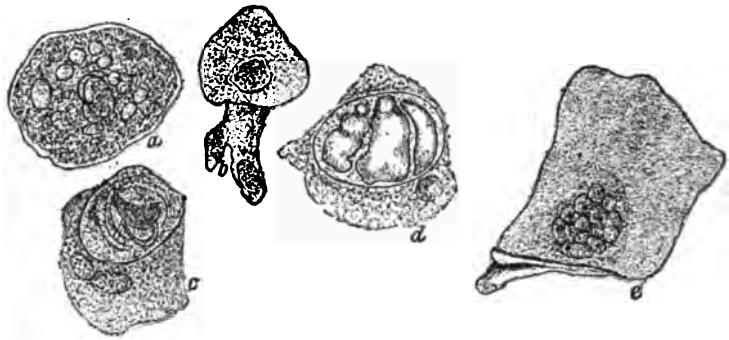

Fig. 87.—Seven isolated cells from an epithelioma of the parotid. *a*, an epithelial cell which, besides a nucleus, contains several homogeneous, spheric inclusions; *b*, two ordinary epithelial cells; *c*, two epithelial cells, one containing several dark bodies; *d*, a cell with large, clear space in which lie 4 glistening bodies of various size; *e*, large, flat cell with 13 nuclei and nucleoli. The lower edge of the cell is incurvated and somewhat folded. (Zeiss Apochr., 4; Comp. Ocul., 4. After *Langerhans*.)

Furthermore, it should be remembered that markedly polymorphous cells, in regard to which it is often impossible to decide from what kind of epithelium they were derived, are sometimes present in carcinomata. This is due to the fact that the epithelia exactly preserve and reproduce the typical, inherited form only so long as they remain under physiologic conditions in or upon the surface. As soon, however, as they proliferate atypically in the deeper tissues, they abandon their physiologic locality, and then all sorts of variations in size, form, and contents occur. This is due to the changed (pathologic) conditions under which the cells are

[1] When carcinoma develops in localities where normally epithelium is lacking, it should be borne in mind that epithelium may be included in regions where it does not belong as the result of faulty development during the embryonal period of life. For example, in the neck, carcinoma develops from rests of the branchial clefts (branchiogenous carcinomata).

placed, and often also to lack of space. The epithelia must accommodate themselves to the given space and frequently change their form. It is for this reason that very multiformed and not infrequently quite small, poorly developed cells are so often found, of which it can only with difficulty or not at all be stated from what kind of epithelium they originated. The more rapid the growth, *i.e.*, the larger the alveoli, the less typical are the epithelia within the alveoli. On the other hand, strikingly large cells sometimes occur, in that either segmentation of the

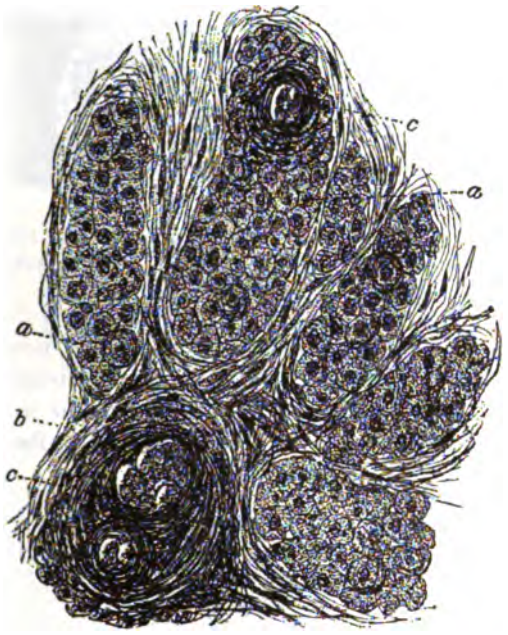

Fig. 88.—Section from an epithelioma of the uterus, woman aged 49. In 2 alveoli "cancer pearls": *a*, alveoli; *b*, stroma; *c*, "cancer pearls." (Zeiss Apochr., 4; Comp. Ocul., 4. After *Langerhans*.)

nucleus does not follow division of the cells, or coalescence of cells (*syncytium*) or else inclusion of cells within cells takes place. The nuclei and nucleoli are often very large, much larger than in normal epithelium. The cells and nuclei frequently contain inclusions and partial cellular or nuclear degenerations, which often have been interpreted as parasites.

Squamous-celled carcinoma develops from surfaces which are covered with squamous epithelium. A subdivision of this is epidermoidal carcinoma, cancroid epithelioma, in which the cells are characterized by a disposition to hornification. Epithe-

lioma consists of very large alveoli which are filled with more or less hornified cells. These cells are arranged partly in lamellated, partly in concentric, layers as epithelial onions, epidermis spheres, or cancroid pearls. The lamellated layers frequently interlace in the form of intertwining, tortuous bands, so that microscopicly the



Fig. 89.—Metastatic epitheliomatous nodules, *a*, *b*, *c*, removed from the cheek of a man aged 54 years. The largest nodule, *a*, is excavated by ulceration. Natural size. (After *Langerhans*.)

cells are seen close together, now from the surface, now from the edge. In the latter case the lamellated structure is most distinctly recognizable. The concentricly lamellated epithelial pearls present in their peripheral portions a certain resemblance to the concentric lamellæ of an onion.



Fig. 90.—Ear lobe of a young woman with multiple pearl tumors immediately beneath the epidermis. The whole lobe is swollen and edematous. The three visible nodules, the largest of which is the size of a millet seed, have a whitish, glistening, porcelain-like appearance. (Natural size. After *Langerhans*.)

Epithelioma is the common form of carcinoma of the skin and of mucous membranes covered with squamous epithelium: of the lip, tongue, esophagus, vulva, vagina, cervix uteri, and penis. It occurs also, however, upon the mucous membrane surfaces which, like the bronchus and gall-bladder, are covered with cylindric epithelium, and in deep-seated parts: bones, glands, especially the salivary glands, etc. As a rule, ulceration occurs early. On lateral pressure worm-like

masses (vermicelli, not cancer milk), which possess great similarity to the pap-like contents of atheroma, can be expressed from the cut surface.

Carcinoma frequently develops upon the leg from a chronic ulcer of the leg (*ulcus cruris*). These epitheliomata begin very slowly, are at first indistinguishable from the callous ulcer, gradually extend into the depth, and, finally, destroy the bone. They may persist for years without forming metastases.

In chimney-sweepers cutaneous carcinomata frequently occur upon the scrotum, likewise in paraffin-workers; in the latter, however, also upon other parts of the skin, especially upon the forearm.

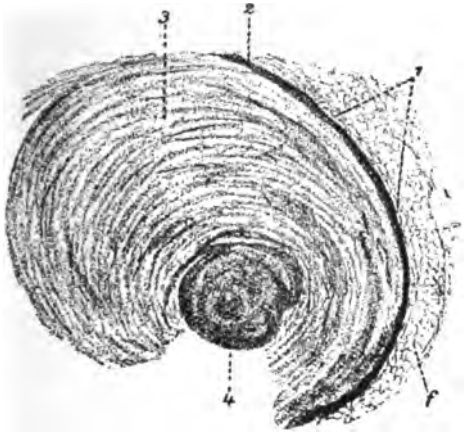

Fig. 91.—Section from Fig. 90 (margaritoma auriculæ). 1, external single layer of cells, consisting of large, clear cells; 2, small, dark, cellular layer containing many fine droplets (eleidia or fat?); 3, broad layer of hornified epidermis cells; 4, dark, concentric, lamellated center; *f*, surrounding adipose tissue. (Zeiss Apochr., 16; Comp. Ocul., 4. After *Langerhans*.)

Closely related to epithelioma is the **pearl tumor** (*cholesteatoma, margaritoma*). This consists of hornified cells arranged in layers, like an onion, to form epidermis spheres, which frequently coalesce. Similar formations occur physiologicly in the nail-bed, on the toes, and in the hair-follicles. Pearl tumor often develops in localities where epidermoidal cells do not normally occur, *e.g.*, in the arachnoid, in bone, and in the middle ear. In other localities (*e.g.*, the testes) it frequently occurs mixed with other tumors. Pearl tumor is usually imbedded in connective tissue, which sometimes has a fibrous character. In contradistinction to epithelioma, pearl tumor never forms metastases. It grows by division of the cells and occurs in the arachnoid, brain, bones (most frequently in the petrous bone), testes, uterus, etc. It may become as

large as the fist or larger, and finally cause death by injury to vital organs, *e.g.*, the brain.

It is important to examine how far cholesteatoma is a true neoplasm and not simply an accumulation of squamous epithelium.

Cholesteatoma of the **middle ear** is generally accompanied by chronic purulent inflammation of the middle ear and of the petrous portion of the temporal bone (caries). Squamous epithelium grows inward from the external auditory canal



Fig. 92.—Squamous epithelioma of the lip, showing pearly body. × 250. (*Gray.*)

through the perforated drum membrane into the usually considerably destroyed middle ear, causes epidermidization of the wound surface, and offers the basis for cholesteatoma of the ear. Every cholesteatoma of the ear presents externally to the epithelia a so-called matrix—a kind of membrane which produces hornified epithelium. This matrix, corresponding to the deeper layers of the epidermis, must have grown into the middle ear, and there, as in the external skin, it produces epithelia. The new-formed epithelium hornifies in the same manner as in the skin. Here, however, there is not, as upon the external skin, the same possibility of rapid elimination of the hornified masses; they accumulate in the middle ear and, in accord with their mode of origin, very readily acquire a scaly or lamellated arrangement. In the same manner pearl-like epidermoidal masses develop in certain skin diseases, *e.g.*, elephantiasis, where retention of hornified epithelium occasionally occurs. It is, therefore, questionable whether cholesteatoma of the middle ear

should be regarded as a true neoplasm, *i.e.*, a tumor. The erosion of the bone caused by cholesteatoma of the ear is, perhaps, not the result of the cholesteatoma, but of the coexistent suppuration, in part also of simple pressure atrophy due to the increasing accumulation of epithelial masses.

The conditions are entirely different in **cholesteatoma** of the **arachnoid,** which is observed especially at the base of the brain, but also, as already stated, in other localities. Here nodules of pearl-like appearance develop; here also the

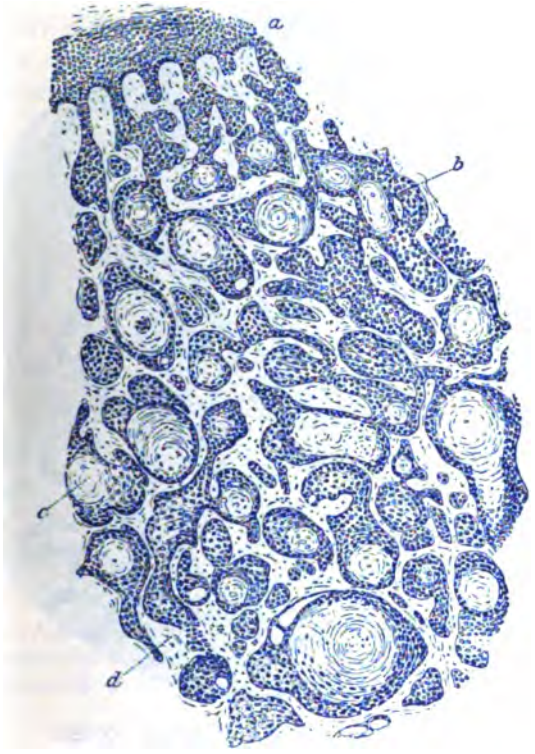

Fig. 93.—Hornified squamous-celled carcinoma. (After *Kaufmann.*)

growth is composed of hornified and fatty degenerated epidermoidal cells. The larger the tumor, the more the adjacent parts are compressed and displaced.

The existence of epidermoidal cells within the closed skull-cavity must be foreign. Here the process undoubtedly depends upon embryonal displacement of epithelial cells. This assumption of the origin is supported by the fact that not only epithelium, but also parts of the skin (hair, glands), are sometimes met with in this locality. The presence of epithelium (epidermis) alone produces an epidermoid; the presence of parts of the skin (derma) gives origin to a dermoid. At all events, arachnoidal cholesteatoma is a genuine tumor. After displacement of epithelium (epidermis) into the skull-cavity has occurred as a result of embryonal processes, proliferation of this tissue into a large tumor-like formation, which very markedly differs from the surrounding structures, sooner or later develops.

Cholesteatoma is a local growth and at most displaces and compresses the adjacent structures. When located within the cranium, serious results may follow from compression.

Cylindric-celled carcinoma contains in its alveoli partly typical cylindric epithelial cells, partly somewhat irregular, spindle-shaped, and caudate cells, and frequently also somewhat cubical forms. It occurs

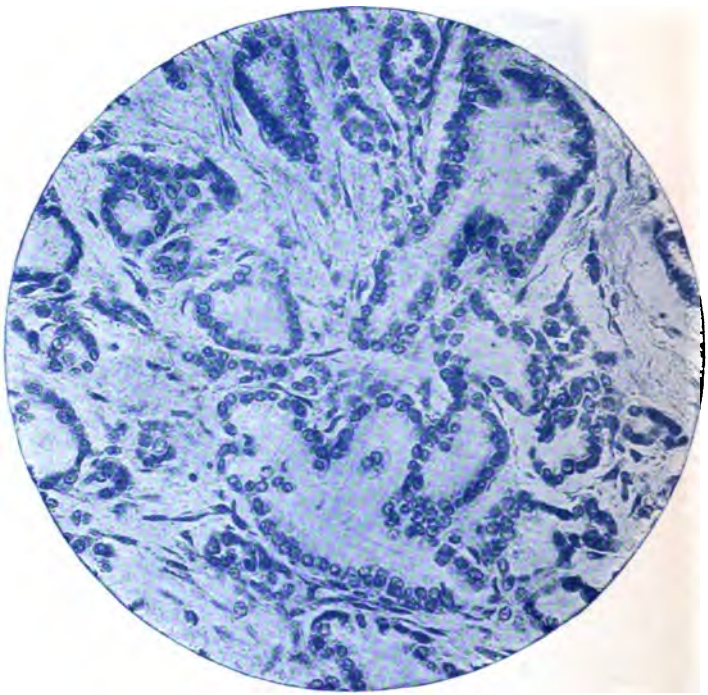

Fig. 94.—Adenocarcinoma of breast. × 250.

wherever the mucous membrane is normally provided with cylindric epithelium, and with especial frequency in the digestive canal and in the body of the uterus. The consistency of this carcinoma is less hard than that of epithelioma, partly, indeed, quite soft. True tumor formation is less frequent than the ulcerative form. Carcinomatous stenoses frequently develop in the stomach and intestine. Large tumors possessing a certain resemblance to colloid carcinoma sometimes develop as a result of mucoid metamorphosis of the cylindric epithelia (goblet-cells).

Glandular carcinoma (*carcinoma glandulare*, adenocarcinoma) presents manifold differences as regards the epithelial elements. Sometimes the epithelial cells resemble the liver-cells, sometimes

the glandular cells of the pancreas, etc. They develop principally from the glandular organs: stomach, mammary glands, pancreas, testes, ovaries, kidneys, prostate, etc., and usually have a tumor form.

Transitional-celled carcinoma is provided with polymorphous transitional epithelia such as occur physiologicly in the urinary passages. It occurs principally in localities where different forms of epithelia meet, *e.g.*, at the *portio vaginalis uteri*, where the epithelium of the cervix uteri joins that of the vagina.

Especially worthy of consideration is **colloid carcinoma** (*carcinoma gelatinosum, seu alveolare*), in so far as it, like epithelioma, is

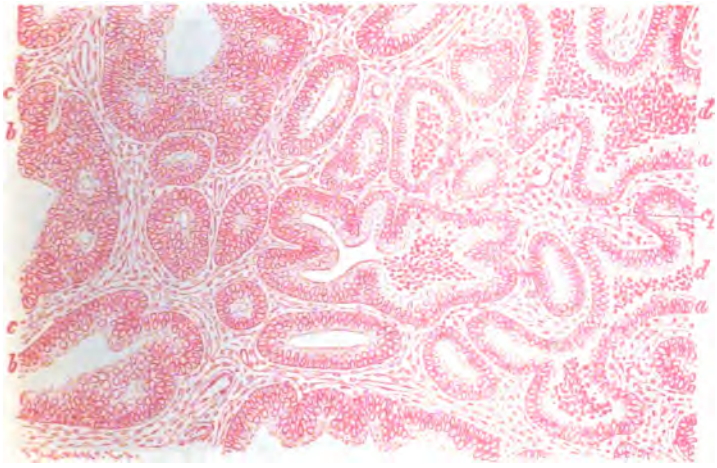

Fig. 95.—Adenocarcinoma of the rectum. *a*, branched glandular tube with lamellated epithelial layer; *b*, tube with markedly proliferated epithelium and papillary elevations; *c*, c_1, stroma; *d*, round-celled infiltration. × 80. (After *Ziegler.*)

characterized by the large size of the alveoli—which frequently can be recognized even with the naked eye—and by the contents of the alveoli, which consist partly of a colloid material, partly of cells. Sometimes only small groups of cells inclosed in an excess of colloid substance are seen on microscopic examination. The colloid material is to be interpreted as a kind of mucous tissue which belongs to the walls of the alveoli, *i.e.*, to the stroma. The colloid masses, therefore, are found principally between the stroma and the carcinoma cells, sometimes also between the cells. When much connective tissue has already been transformed into colloid material, colloid carcinoma is conspicuously poor in connective-tissue stroma and blood-vessels. Consequently, hemorrhagic products are altogether absent. In spite of the fact that the sur-

face is almost always ulcerated, there is no tendency to putrid decomposition and mortification, because the mucus possesses a very indolent character, forming, as it were, a protective covering. The unusual size of the alveoli is due in part to the frequent confluence of neighboring alveoli as the result of complete transformation of the stroma into mucous tissue. In addition, however, there are in every colloid carcinoma localities in which the ordinary character of the carcinoma can be seen,

Fig. 96.—Colloid carcinoma. Fresh section. (Zeiss Apochr., 4; Comp. Ocul., 4. After *Langerhans.*)

Fig. 97.—Carcinoma gelatinosum. Fresh section. (Zeiss Apochr., 16; Comp. Ocul., 4. After *Langerhans.*)

where epithelial groups are separated by the stroma. In these localities the mucous transformation of the stroma has not yet begun. Wherever this has already begun or is advanced, the epithelia, which may be derived from different varieties of epithelium, are usually already so far altered by retrograde change that the form can no longer be recognized.

Colloid carcinomata usually form tumors and produce considerable swellings, but are relatively benign, since they remain stationary for a long period. Often they produce almost no symptoms for a long time. They occur chiefly in the large intestine (especially in the rectum), stomach, omentum, peritoneum, and lungs. In the stomach and intestine, they often produce serious symptoms of stenosis.

In general, carcinoma occurs oftener in the female than in the male. This is due principally to the frequency of disorders of the female sexual organs (uterus and mammæ). In the scale of frequency the female sexual organs stand first[1]; then follow the stomach, the external skin, esophagus, colon, testes, the external genitals, prostate, urinary bladder, pancreas, thyroid, bile-ducts, lungs, bronchi, liver, etc.

In contrast to primary carcinoma development stands secondary, metastatic formation, in which the lymph-glands and the liver are most frequently affected, and next the lungs, the serous membranes, bones, etc.

Fig. 98.—Colloid carcinoma of the pylorus. Marked contraction of the whole stomach, which is unopened. ⅔ natural size. Woman aged 77. (After *Langerhans.*)

The primary tumor always forms a focus of infection from which new, secondary foci are derived. The malignancy of carcinoma consists (1) in contagion of the neighborhood, in the gradual transformation of adjacent parts into carcinomatous tissue; (2) in ulceration with exhausting secretions from the ulcerating surface, and (3) in generalization, *i.e.,* carcinomatous involvement of distant parts, principally the internal organs. The fatal hemorrhages which sometimes occur usually take place not from veins, but from arteries, which ulcerate before an occluding thrombus has formed. The arteries are decidedly more resistant to carcinoma than are the veins; the arteries are generally surrounded by carcinoma and may occupy the center of the tumor and still retain their function. On the other hand, veins are early in-

[1] According to the statistics of Welch, based upon an analysis of 31,482 cases of primary carcinomata, the stomach was the seat of carcinoma in 21.4 per cent., and the uterus in 29.5 per cent. Pepper's Syst. of Pract. Med., ii, p. 533.

volved by the tumor; the carcinoma may even grow into the lumen without interrupting the blood-current, the carcinomatous masses thus coming into direct contact with the blood. As a rule, however, thrombosis occurs quite early.

Formation of secondary, new carcinoma-nodules takes place either in the immediate neighborhood of the old nodule: continuous extension (contagion), or in localities somewhat remote from the original nodule, intact tissue forming a more or less large interspace: discontinuous extension, or in other organs at a

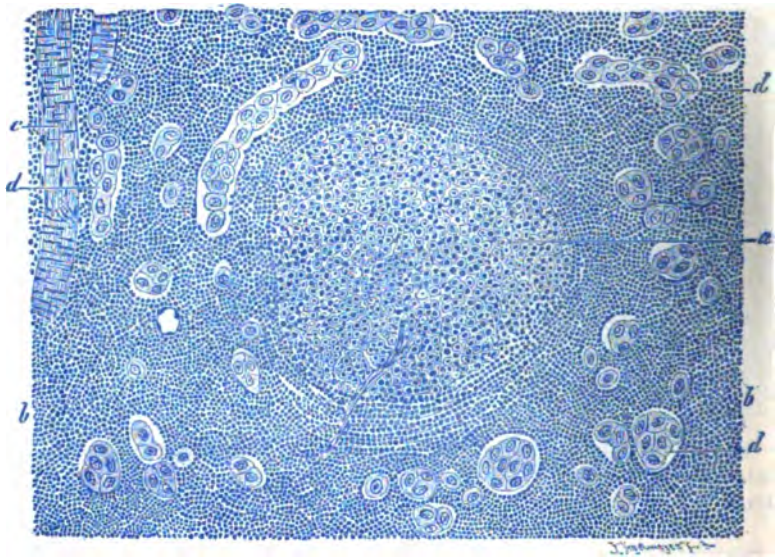

Fig. 99.—Section from an enlarged axillary lymph-gland with beginning carcinoma development. *a*, germinal center of a lymph-node; *b*, lymph-channels; *c*, artery; *d*, carcinoma cell-nests. × 60. (After *Ziegler.*)

greater or lesser distance from the primary focus: true metastasis formation. Extension occurs, first, in the direction of the lymph-stream (sometimes also in the opposite direction, when interruption of the stream has occurred), or by means of the blood-current, or by dissemination, *i.e.*, in cavities of the body by gravitation of tumor-germs. The tumor-cells themselves are always to be regarded as the carriers of the infection, not only in dissemination, but also in extension by the blood and the lymph-stream.[1]

[1] The lymph-vessels are often completely occluded by carcinomatous masses, most frequently in the pleura pulmonalis, from the hilus in a direction against the current.

The great tendency of all carcinomata to early recidive (recurrence) is in part explained by the fact that even after quite extensive operation some remnants of germs of the tumor still remain. In all cases in which the neighboring lymph-glands become involved after operation, it may with certainty be assumed that metastases had taken place in the lymph-glands previous to operation. It is a striking fact that operative intervention sometimes induces a more rapid course, a more intense growth, and a more rapid formation of metastases, and, therefore, appears to increase the malignancy.

Not all carcinomata are equally malignant. Epitheliomata may often persist for years without forming metastases, and are, therefore,

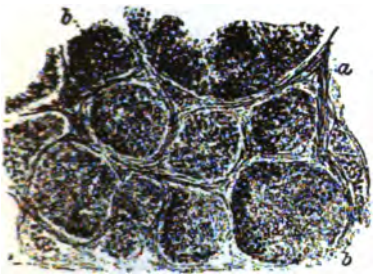

Fig. 100.—Section from carcinoma of the stomach. *a*, stroma; *b*, alveoli, the epithelia of which have undergone fatty metamorphosis. (Zeiss Apochr., 4; Comp. Ocul., 4. After *Langerhans.*)

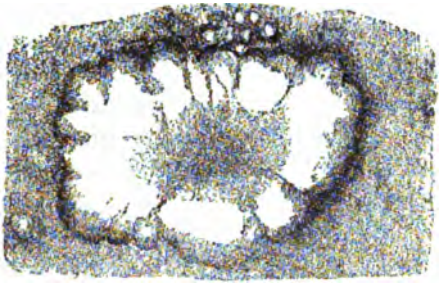

Fig. 101.—Metastatic carcinoma of the liver with characteristic central umbilication. In the periphery of the large nodule are several small, young nodules. (Natural size. After *Langerhans.*)

relatively benign tumors. In general, the succulent and richly cellular forms, which are characterized also by rapid local growth, usually form metastases earliest, while the more dry and poorly cellular forms generally remain stationary for a considerable time.

Carcinoma cells are much more perishable structures than most epithelial cells. As a rule, retrograde metamorphosis begins very early, most frequently fatty metamorphosis, and less often caseation and calcification. The fatty metamorphosis facilitates absorption of the contents of the alveoli, a firm, cicatricial-like connective tissue finally taking the place of the carcinoma. In this manner partial spontaneous cure of carcinoma occurs, which is also manifest externally by cicatricial contraction, seen most distinctly in metastatic carcinoma-nodules in the liver, which frequently have a central indentation upon the surface (the result of absorption of the older central parts). (See Fig. 101.)

If calcifications occur in the stroma, quite analogous to the calcifications in psammoma (see pp. 239 and 240), this form of carcinoma is designated as psammocarcinoma (in the ovary, peritoneum).

The **digestive apparatus** manifests many points of predilection for the development of primary carcinomata, while secondary carcinomata are exceptional. Above the diaphragm chiefly epitheliomata are found; below it chiefly medullary carcinomata, and at the anus, again, chiefly epitheliomata.

The stomach is most frequently affected[1]; then the esophagus, rectum, and oral region. In the latter, the lower lip and the margin of the tongue especially are the seat of epitheliomata. In both, the ulcerative character predominates; both usually begin as a firm, slightly elevated carcinomatous infiltration; from this a crater-like ulcer or cavity develops as a result of rupture of the carcinoma alveoli and expulsion of their epithelial contents. The tongue may thus appear to have sunken in on the affected side.

Carcinomata of the pharynx are of the squamous-celled type. They usually form nodular swellings in the throat, and may, mechanicly, compress the esophagus and larynx to a considerable degree.

In the esophagus there are three points of predilection:—

1. Isthmus of the esophagus between the cricoid cartilage and spinal column.
2. Point of crossing with the left bronchus.
3. Hiatus œsophageus of the diaphragm.

Esophageal carcinoma occurs most frequently at the point of crossing with the left bronchus. Almost all esophageal carcinomata are epitheliomata.

Esophageal carcinoma develops as a small, round, flat swelling with smooth or villous surface. By disintegration of the surface the alveoli open and their thread- or vermicelli- like contents are expelled; an ulcer with uneven, nodular, partly villous surface: *ulcus verrucosum,* is thus produced, which has a tendency to extend in girdle form and produce an annular ulcer. After a time the carcinoma papillæ and subsequently the ulcerative process gradually attack the muscularis and the deeper coats or adjacent structures. Esophageal carcinomata very seldom remain unobserved for any length of time. As a rule, disturbance of deglutition takes place at an early period and often increases until complete stenosis occurs, rendering it impossible to nourish the patient *per os;* not infrequently a gastric fistula must be established (by gastrostomy) if death does not supervene before this time.

---

[1] See footnote, p. 287.

As a result of contact of the ulcerated surface with the ingesta, decompositions are produced, which frequently transform the carcinomatous ulcer into a discolored, foul, putrid ulcer. After complete infiltration of the esophagus, the affection invades the neighboring organs and destroys either the bronchi (aspiration of ingesta and gangrenous pneumonia) or a large vessel (fatal hemorrhage) or the pericardium or costal pleura (pericarditis, pleuritis with fulminating, lethal course). Metastases develop early in the nearest tracheal and mediastinal lymph-glands. Sometimes the epigastric lymph-glands also are involved and

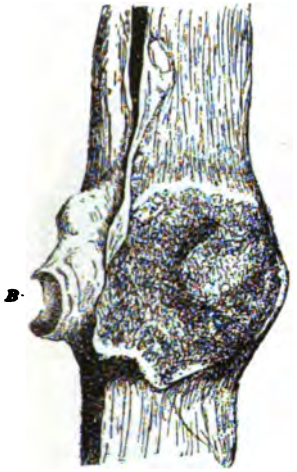

Fig. 102.—Carcinomatous ulcer of the esophagus, without stenosis, at the point of crossing of the left bronchus. *B*, left bronchus. (½ natural size. After *Langerhans.*)

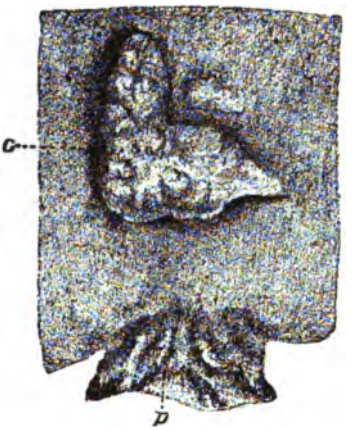

Fig. 103.—Carcinoma of the lesser curvature of the stomach, without ulceration. *c*, carcinoma; *p*, pylorus. (½ natural size. After *Langerhans.*)

transformed into tumors the size of a hazelnut, walnut, or small apple. These soon become adherent to the stomach, invade its walls, and, finally, produce gastric metastases. In such cases a decision as to which was the primary tumor is possible only by microscopic examination, *i.e.*, by determination of the character of the epithelium.

Carcinomata of the stomach start from the mucous membrane, even though, as frequently is the case, they advance more rapidly in the submucosa than in the mucosa itself. They are most commonly located at the pyloric or the cardiac end of the stomach,[1] but they occur

[1] Of 2214 cases of gastric carcinoma analyzed by Welch (*loc. cit.*), 60.8 per cent. were in the pyloric region.

also upon the anterior and posterior surface (here, at least, in the beginning, frequently in fungous form), and at the greater and lesser curvature. Carcinoma of the pylorus very soon produces stenosis, which results in marked disturbances, such as retention of the ingesta in the stomach, acid decomposition and gas formation, and hemorrhages and catarrhal inflammation of the remaining gastric mucous membrane (clinicly: phenomenon of stenosis formation with vomiting of coffee-ground-like, hemorrhagic matter). In carcinoma of the cardia retention of ingesta in the stomach with its sequelæ is lacking;

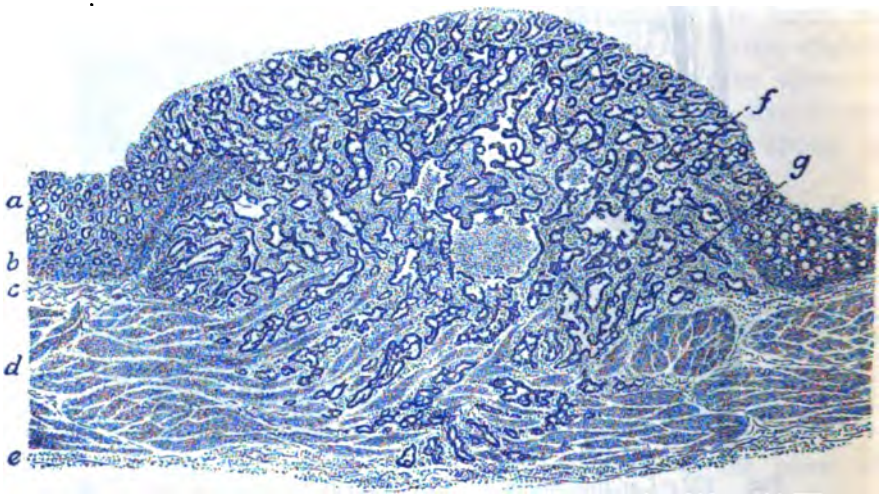

Fig. 104.—Adenocarcinoma of the stomach in stage of development. *a*, mucosa; *b*, muscularis mucosæ; *c*, submucosa; *d*, muscularis; *e*, serosa; *f*, *g*, adenocarcinoma. × 16. (After *Ziegler*.)

nevertheless, decompositions occur. Carcinomata of the surface of the stomach may often remain latent for a long time without causing vomiting or pain. These gastric carcinomata sometimes belong to the ulcerative, sometimes to the tumor, form. In the medullary tumor, villous-formed excrescences, which are very vascular and frequently give rise to hemorrhages, sometimes grow from the mucous membrane: *carcinoma villosum cauliflore*. On disintegration of carcinoma masses in the stomach, such deep ulceration may occur that adjacent organs (*e.g.*, liver, pancreas, spleen, lymphatic glands, omentum, colon: see Fig. 85), likewise becoming affected by contiguity, are also involved in the ulcerative process, and form the floor of the ulcer. In scirrhous carcinoma the whole stomach may be greatly decreased in size and also very decidedly shortened at the curvatures, without a true tumor or an

ulcer being anywhere demonstrable. The mucous membrane is then atrophied, usually presents slaty pigmentation, and is often so firm that the wall is almost rigid. The musculature is often reticulated, because the carcinomatous proliferation infiltrates the musculature along the course of the blood-vessels. In all cases in which the passage is obstructed by gastric carcinomata (*stenosis carcinomatosa*), the muscularis is usually greatly hypertrophied, often from 4 to 5 mm. in thickness.

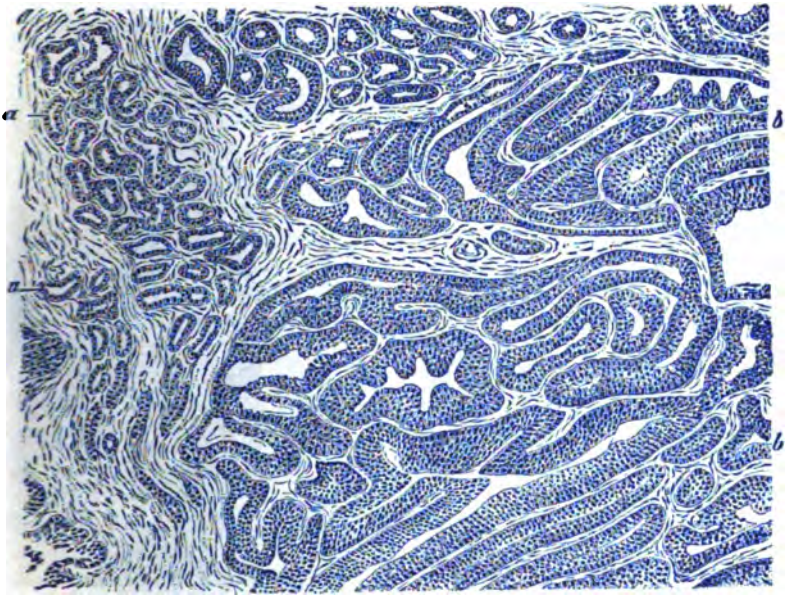

Fig. 105.—Bean-sized adenocarcinoma of the breast in stage of development. *a*, normal gland tissue; *b*, atypic glandular proliferation. × 100. (After *Ziegler*.)

The epithelium of gastric carcinoma is either cylindric, cubic or quite small and uncharacteristic in form. In the first case it may be assumed that the carcinoma originated from the superficial layers; in the second case from the true cubic peptic epithelium (*i.e.*, from the lower portion of the glands), and in the third from the middle layers with transitional forms.

Colloid carcinoma is generally situated at the pylorus, where it causes decided swelling of the whole stomach wall (see Fig. 98), so that, finally, the individual gastric coats can no longer be differentiated. It produces symptoms of stenosis, and frequently is ulcerated upon the surface.

Gastric carcinomata soon produce metastases in the liver and lymphatic glands, first in the epigastric glands,[1] later in those along the course of the thoracic duct, until, finally, individual lymph-glands, which have undergone carcinomatous change, can easily be palpated in the left supraclavicular region. Perforation of the stomach wall and fatal perforative peritonitis occasionally occur in gastric carcinoma, especially

Fig. 106.—A breast in section; it contains an endothelioma (perithelioma). The nipple is unaffected. (After *Bland-Sutton.*)

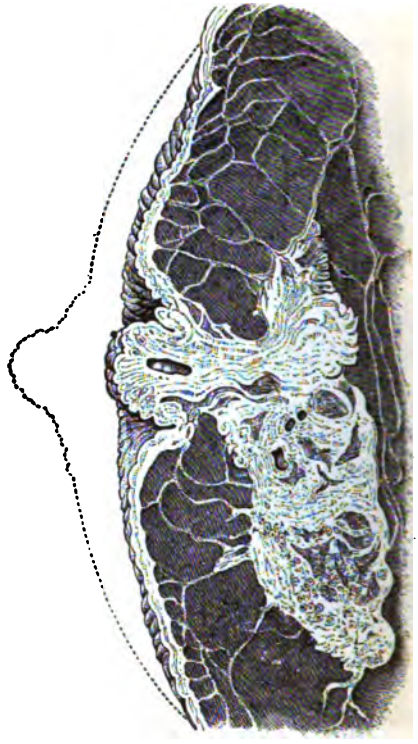

Fig. 107.—A breast with its nipple in section from a case of duct cancer. The nipple is inverted. (After *Bland-Sutton.*)

as a result of putrid decomposition with mortification, provided the point of perforation does not previously become adherent to adjacent parts by an adhesive inflammation.

Carcinoma of the rectum is usually a colloid carcinoma, seldom

[1] According to the statistics of Welch (*loc. cit.*), in 1574 cases of gastric carcinomata with metastases, the latter occurred in the lymph-glands in 35 per cent.; liver, 30 per cent.; peritoneum or intestine, 23 per cent.; pancreas, 8 per cent.; pleura and lung, 6 per cent.; spleen, 2 per cent. In 2214 cases of gastric carcinoma the ratio was 5 males to 4 females.

a melanotic tumor. As a rule, it produces decided stenosis. Colloid carcinoma also usually remains stationary for a long time, and slowly involves adjacent parts, especially the bladder. It manifests very little tendency to form metastases.

Carcinomata of the small intestine are cylindric epithelial-celled carcinomata, and frequently of colloid type. They cause stenosis, extend to adjacent parts, and cause partial or general peritonitis.

Carcinomata of the milk glands (breast) are partly glandular,

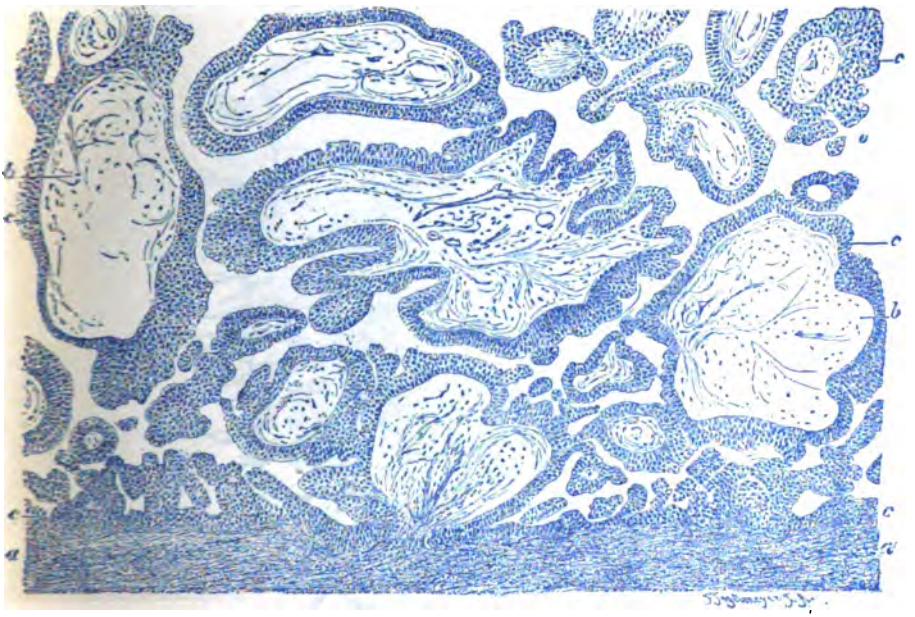

Fig. 108.—Papillary cystocarcinoma of the breast with myxomatous degenerated papillæ. *a*, connective-tissue stroma; *b*, myxomatous degenerated papillæ; *c*, proliferated multilamellated epithelium. × 80. (After *Ziegler*.)

partly cutaneous. Both cause early metastases in the axillary glands, and often very soon extend to the other mamma. They produce metastases in the pleuræ, lungs, and liver, sometimes in all organs, and even in the bones. While the carcinomata starting from the skin are so-called epitheliomata, the glandular carcinomata generally have cubic, less often cylindric, epithelium.

Colloid carcinoma (*c. gelatinosum*) of the breast is rare,[1] and is observed chiefly in elderly individuals.[2] The growth may be very slow. It occurs in an infiltrating and tuberous form, and in the latter instance

[1] According to Lang, in 1814 mammary carcinomata, the colloid form occurred in 17 cases: 0.93 per cent.

[2] In 5 cases observed by Kaufmann, the ages ranged from 48 to 82 years.

produces a rounded or discoid nodule intimately connected with the surrounding tissue, from the periphery of which small, round nodules often develop. Incision shows a reticulated, honeycomb-like structure filled with a transparent colloid substance, rarely a pap-like granular material. The colloid material may be grayish white, yellowish, brownish, cranberry-jelly-like, or bloody-mottled, and sometimes resembles that observed in a strumous thyroid gland. Cases also are observed in which,

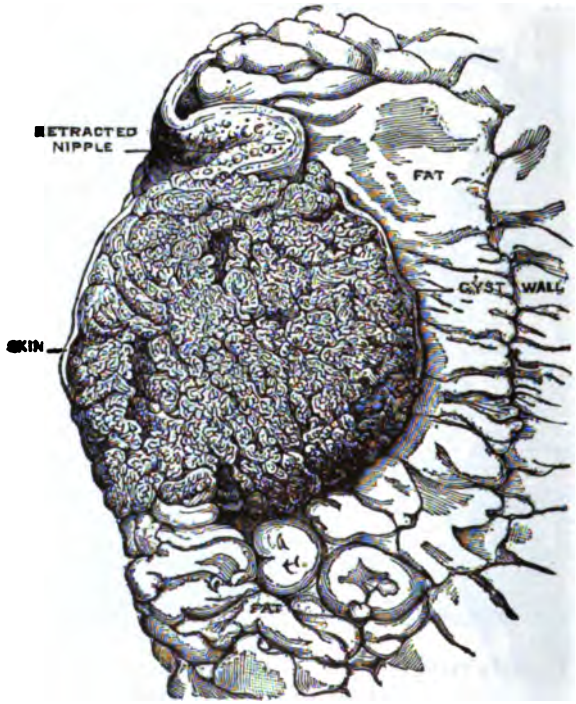

Fig. 109.—A cancerous breast in section, showing retraction of the nipple. (After *Bland-Sutton.*)

in addition to an ordinary glassy, pale-gray scirrhus of slight extent, an ovoid nodule protrudes from the surface of the mammæ. The axillary glands, which long remain uninvolved, may sometimes present the characters of an ordinary richly cellular carcinoma with no trace of colloid metamorphosis; in other cases the metastases in this locality also are colloid. If operated upon early, the prognosis is relatively good; in neglected cases, however, ulceration and formation of distant metastases occur.

Paget's disease; carcinomatous eczema of the breast.—In 1870 Paget described certain forms of eczema of the female nipple

and areola which manifested a chronic character and finally developed into carcinoma in every way resembling, in the involvement of the lymphatic glands, recidives, etc., carcinoma of the breast. It is now known that this process is, from the beginning, a carcinoma developing from the glandular epithelia of the milk-ducts. The carcinoma cells advance to the epidermis, which they so alter as to produce the clinic features of eczema, *i.e.*, the eczema is a secondary phenomenon.

With few exceptions, carcinomata of the **uterus** develop in the *portio vaginalis uteri*, at the site of transitional epithelium. They are

Fig. 110.—Carcinomatous ulcer of the body of the uterus. ½ natural size. (After *Langerhans.*)

principally epitheliomata and carcinomata composed of transitional epithelium, less frequently cylindric epithelial-celled carcinomata. They are often associated with marked villous, papillary, and cauliflower-like, richly vascular excrescences of the surface. Therefore, they easily give rise to profuse hemorrhages, ulcerate early, and rapidly undergo putrid decomposition. They extend gradually downward to the vagina and upward to the body of the uterus; sometimes very early involve the deeper structures, and then produce communication of the urinary and genital tracts (vesicovaginal fistula), less frequently rectovaginal fistula. When the carcinoma extends to the peritoneum, perforation and putrid peritonitis may occur, though rarely. On the other hand, the *ligamenta lata* are usually soon involved, and often to such a degree that the true

pelvis appears to be almost filled with tumor masses. The iliac and inguinal lymph-glands are the first to become involved. Liver metastases are rare.

Carcinoma of the body of the uterus is very much less frequent than carcinoma of the cervix. Carcinoma of the body of the uterus is usually a cylindric epithelial-celled carcinoma which results in the formation of large tumors, while carcinomata of the cervix progress essentially under the form of putrid ulceration.

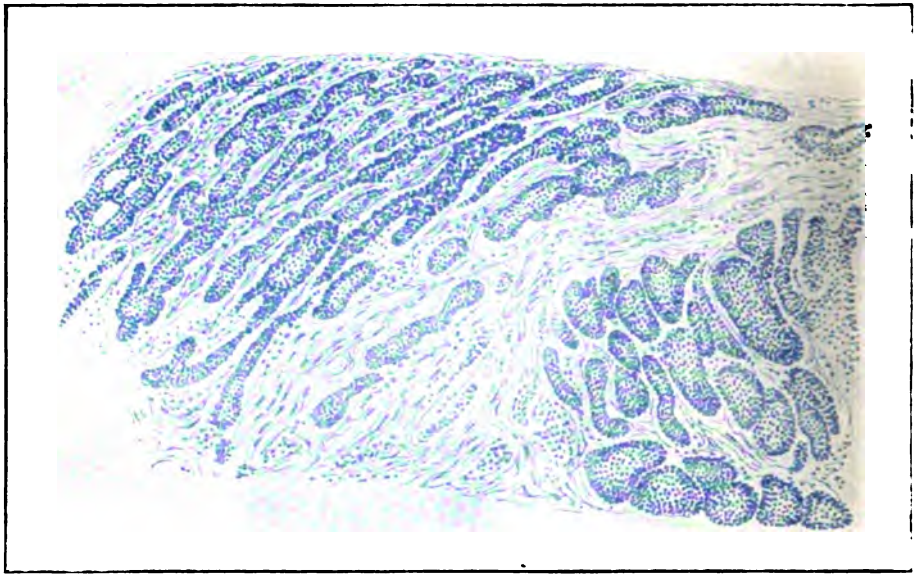

Fig. 111.—Epithelioma of vagina.

Carcinomata of the vagina are rare. They are at first dense, hemispheric growths with villous surface. Disintegration soon occurs. They are squamous-celled carcinomata (epitheliomata).

In the **ovary** cystomata (*q.v.*) predominate, in which transition from cystoma into carcinoma or from carcinoma into cystoma (*carcinoma cysticum*) is frequently observed. Pure carcinomata, however, particularly colloid carcinoma, also develop from the ovaries, and, furthermore, medullary carcinoma and other forms which approach the scirrhous type. Calcifications sometimes occur in the stroma, as in psammoma: psammocarcinoma.

Carcinomata of the bladder are often characterized by the enormous size of the villous proliferations, while only little carcinomatous tissue is present in the bladder wall. They belong to the benign car-

cinomata, in so far as they remain stationary for years without forming metastases. An especial type of carcinomata are those which infiltrate the whole bladder and greatly thicken and enlarge it without manifesting any particular tendency to undergo ulceration. These also are

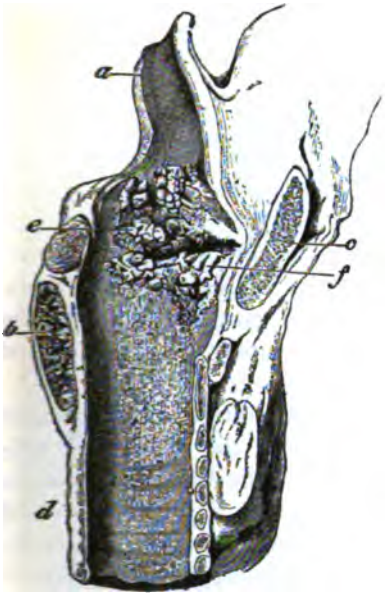

Fig. 112.

Fig. 112.—Papillary epithelioma of the larynx. *a*, epiglottis; *b*, ossified annular cartilage; *c*, thyroid cartilage; *d*, trachea; *e*, *f*, papillomata. Natural size. (After *Ziegler.*)

Fig. 113.—Carcinoma of the larynx. Sagittal section through the larynx and trachea. *a*, carcinomatous proliferation; *b*, left vocal cord; *c*, trachea; *d*, left half of the epiglottis; *e*, pharyngeal wall. Natural size. (After *Ziegler.*)

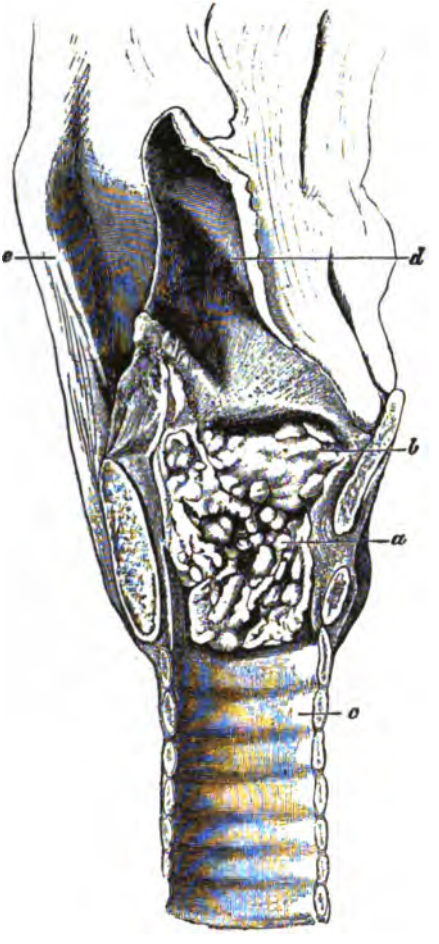

Fig. 113.

squamous epithelial-celled carcinomata, not scirrhous. There is no tendency to cicatrization, but in the infiltrating form this carcinoma is nearly related to scirrhous.

Soft (cylindric epithelium) and hard (scirrhous) carcinomata and villous and colloid carcinomata develop from the **gall-bladder** and the large bile-ducts. Gall-stones are frequently found in the gall-bladder, but these cannot be considered as the cause of the carcinomatous

development. These carcinomata generally extend to the glands at the hilus and to the liver itself. Severe, green icterus is usually present.

As a rule, carcinomata of the **pancreas** and **salivary glands** (*carcinoma glandulare*) are quite hard. In the pancreas they begin most frequently in the head, seldom in the middle portion or in the tail, and generally produce severe icterus through biliary engorgement, in that they involve the ductus choledochus or surround or compress it. Pancreatic carcinomata sometimes extend also to the stomach, and frequently to the liver.

Carcinoma of the larynx develops chiefly from localities covered with squamous epithelium, especially from the vocal cords. It forms at first a somewhat flat swelling, later a coarsely nodulated tumor. It is sometimes accompanied by intense papillary proliferation of the surface, and soon undergoes disintegration. It early causes difficulty in respiration, and bronchopneumonia and pulmonary gangrene later follow as a result of aspiration. Metastases occur principally in the adjacent lymphatic glands.

Carcinoma of the trachea develops from the retrotracheal mucous glands. Bronchial carcinoma arises from the superficial epithelium or from the epithelium of the glands of the bronchial mucous membrane. Bronchial carcinoma is strikingly often a squamous-celled carcinoma (epithelioma), and usually extends to the lungs, first following the lymph-channels in the connective tissue; later, however, involving also the true lung parenchyma. The bronchial glands are always involved and often also other organs.

Carcinomata of the lungs are composed of either squamous or cylindric epithelium. Metastatic carcinoma of the lung is quite frequent. The primary forms usually start from the bronchial epithelium, though they may originate from the epithelium of the excretory ducts of the mucous glands. Myxadenocarcinoma, or complex form, also is observed. It is a remarkable fact that the focus from which the carcinoma originated is not, or, at least, only rarely, found at necropsy. At first glance such a lung appears almost as if it were hepatized. Usually, however, it has a peculiar pale, marrow-like consistency, which is not observed in pneumonia. Often only the pulmonary alveoli are filled with epithelia, so that a certain similarity to catarrhal pneumonia is observed even on microscopic examination. The bronchial glands always show the typical structure of carcinoma, namely, alveoli filled with epithelia.

Carcinoma of the kidney is quite rare. The growth is usually soft, rarely hard. The former may produce large tumors, but manifests only a slight tendency to form metastases. Extension does not take place until the renal capsule is destroyed by the carcinomatous process.

The **testicle** is the seat of soft, quite large carcinomatous tumors, which occasionally involve the scrotum and then ulcerate. The cut surface is usually pale and marrow-like. Mixed tumors are much more frequent.

Next to the lymph-glands, the **liver** is the most frequent seat of carcinoma metastases. Sometimes, however, primary carcinomata develop from the liver, either in the form of one or several nod-

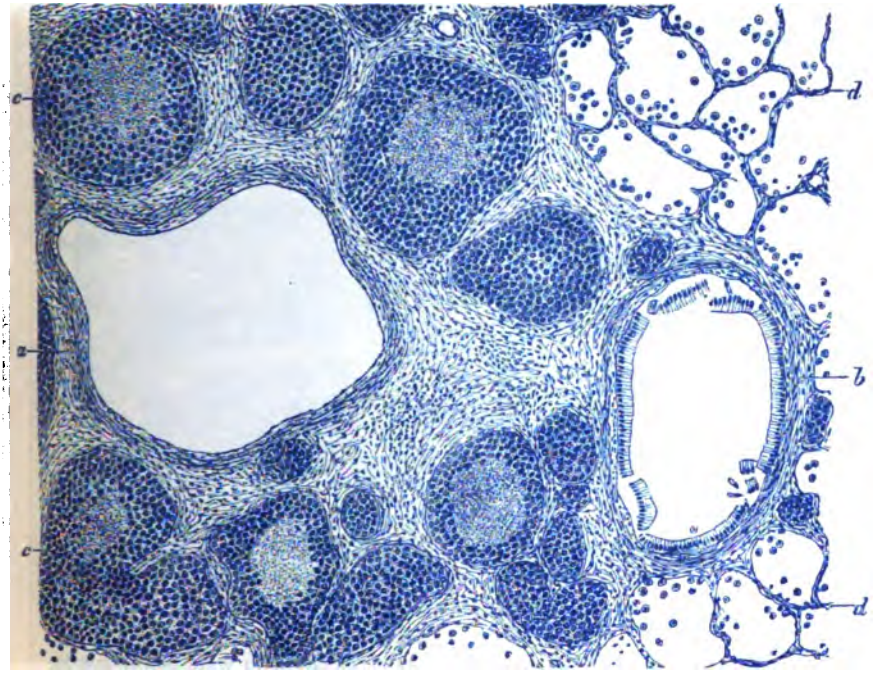

Fig. 114.—Metastatic lymph-vessel carcinoma of the periarterial and peribronchial lymph-vessels of the lung after carcinoma of the stomach. *a*, artery; *b*, bronchus; *c*, periarterial and peribronchial lymph-vessels filled with carcinoma cells and lymph; *d*, lung-tissue with desquamated epithelia and leucocytes in the alveoli. × 25. (After *Ziegler.*)

ules or as a diffuse carcinomatous degeneration. In addition, there is a third form which progresses essentially in the portal connective tissue and starts from the bile-ducts. This last form is composed of cylindric epithelial cells, while in the two other forms the carcinoma-cells are very closely related to the liver-cells, manifesting only a slight difference in size. With the exception of the first form, severe icterus usually coexists.

Carcinomata of bone vary greatly in their occurrence, course, and the character of the epithelium (cylindric and squamous epithelium). As a rule, they are not very large tumors, but they are relatively frequently the cause of spontaneous fractures. In other cases enormous numbers of nodules, which are but slightly elevated above the surrounding parts and have a grayish-translucent or yellow-gray-brownish appearance, are found in all the bones—in the spongiosa, the marrow, and in the compact bone. In these cases no primary tumor can, as a rule,

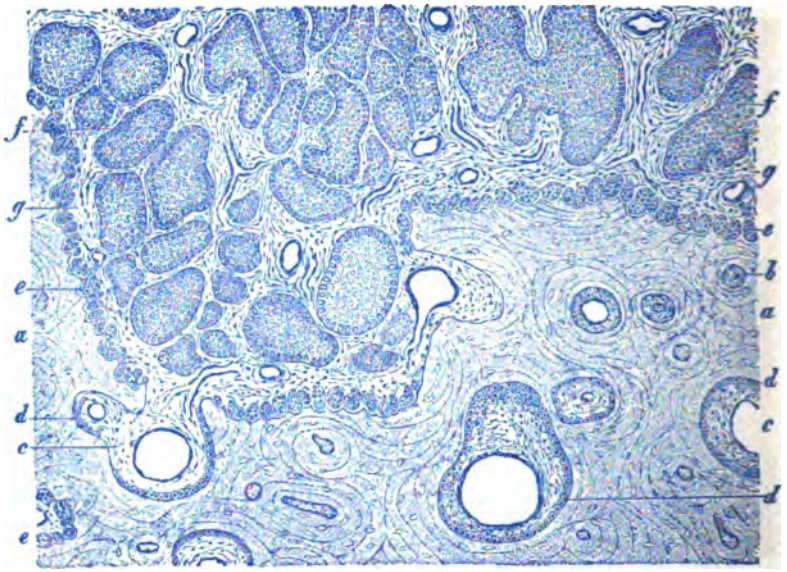

Fig. 115.—Bone resorption and apposition in the vicinity of a metastatic carcinoma nodule in the diaphysis of the humerus. *a*, corticalis humeri; *b*, normal Haversian canals; *c*, dilated Haversian canals with wide blood-vessels; *d*, osteoblasts; *e*, osteoclasts and Howship's lacunæ; *f*, carcinoma papillæ; *g*, stroma of the carcinoma. × 50. (After *Ziegler.*)

be found. Sometimes a scarcely visible carcinoma of the prostate is the primary tumor.

Carcinoma of the **prostate** is more frequently composed of cylindric epithelial cells than of cubic epithelial elements, and sometimes forms tumors as large as an apple. It may ulcerate into the urethra, and extend to the neck of the bladder and seminal vesicles. Prostatic carcinomata attack principally middle-aged adults, but they are observed also in old age.

Carcinomata of the **thyroid** are most frequently composed of cubic epithelium, rarer of cylindric epithelium. Both forms are soft,

very malignant, and soon produce metastases. The first form often undergoes partial colloid degeneration.

Primary carcinomata and carcinoma metastases occur in the **serous membranes,** and more frequently in the peritoneum than in the pleuræ. Violent inflammation of the serous membrane accompanied by effusion and extravasation generally takes place: *peritonitis* and *pleuritis carcinomatosa hæmorrhagica.* Primary colloid carcinoma with cylindric epithelium is rarely observed in the peritoneum, and is probably dependent upon inclusion of portions of the embryonic intestine during the developmental period, or upon a psammocarcinoma.

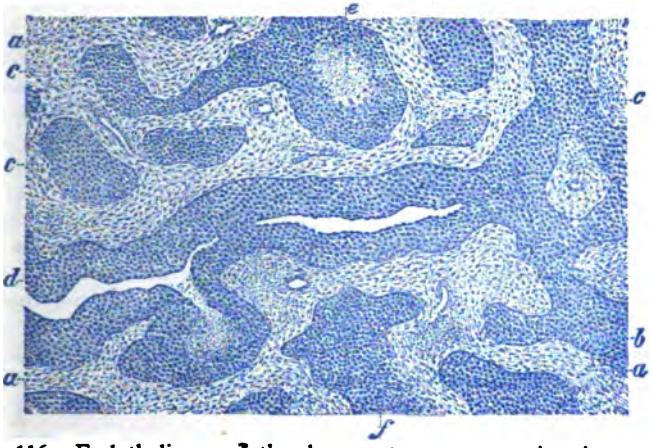

Fig. 116.—Endothelioma of the dura mater, *a*, connective-tissue stroma; *b*, small-celled foci; *c*, foci of cells produced from proliferation of lymph-vessel endothelia; *d*, endothelial cell strands with lumen; *e*, focus of fatty degeneration in an endothelial cell strand; *f*, cell strand which at the right side gradually merges with the adjacent connective tissue. × 25. (After *Ziegler.*)

So-called endothelial carcinomata—better, **endotheliomata**—in which not epithelia, but endothelia, of lymph-vessels are grouped in alveolar spaces, are also observed in the peritoneum and pleura. These cellular masses are due to proliferation of the endothelia of the lymph-vessels and lymph-spaces. The endothelial proliferation is not always confined to the spaces, but often diffusely invades and infiltrates adjacent parts. For this reason these tumors are frequently designated as endothelial sarcomata. Since, however, these endotheliomatous growths manifest characteristic differences as compared with carcinoma as well as sarcoma, it is better to designate them as endotheliomata. These tumors form flat, diffuse, or more granular, sometimes nodular swellings, which are, in general, benign. They remain station-

ary for a long time, but recur *in loco,* sometimes repeatedly, and, finally, also form metastases. Besides the peritoneum and pleuræ, where they are most frequently observed, these endothelial tumors occur also in the salivary glands (parotid), skin, mucous membranes, *e.g.,* in the larynx (the author repeatedly examined such a tumor, which recurred every year, each time rendering surgical intervention necessary); in the meninges, the mammæ, and in other localities. According to the observations at hand, it may be assumed that these endotheliomata sometimes undergo genuine sarcomatous and carcinomatous degeneration.

Histologicly, endotheliomata belong to the connective-tissue formations. They develop particularly from endothelia of the lymph-vessels and lymph-spaces of the connective tissue, and occasionally also from endothelia of the blood-vessels as well as from the so-called perithelia, *i.e.,* cells of the *adventitia capillaris,* which rest upon the adventitia of many blood-vessels. According to Volkmann, the cells of serous surfaces also belong to the endothelia. Endotheliomata may originate in all localities in which endothelium exists. The term **perithelium** is applied in a restricted sense to cells of perivascular sheaths which occur only in certain organs (brain, testes, etc.), and more broadly to the outermost layers of flat adventitial cells. (See Fig. 116.) The rare endotheliomata originating from the endothelia of the **blood-vessels** are designated as **intravascular endotheliomata (angiosarcoma,** or **intravascular** or **endothelioid hemangiosarcoma,** or **hemangioendothelioma);** those derived from the perithelia are called **peritheliomata** or **perivascular hemangiosarcomata.** (See Fig. 118.)

Endotheliomata originating from lymph-vessels upon the surface of large serous cavities (*e.g.,* **pleura** and **peritoneum**), which may invade neighboring cavities and also form metastases, formerly were incorrectly designated as **"endothelial carcinomata."** Microscopicly, these tumors (called also **mesothelioma**) consist partly of gland-like tubules and sometimes wide, irregular cavities; partly of solid papillæ, bands, and complexes of large, closely arranged polymorphous cells, among which giant cells also are observed, presenting a structure resembling adenomata and carcinomata (squamous celled). If the tumors extend into the tissue-spaces and lymph-spaces, the endothelia of the latter are, as a rule, no longer recognizable. By some authorities it is assumed that they are immediately involved in the tumor formation (so-called **regional infection**); by others that, owing to contact with the neoplasm cells, they simply swell, but as a result of this they are no longer distinguishable from the tumor elements. Occasionally, however, the autochthonous endothelia can be distinguished from the invading elements.

In the **dura mater** endotheliomata frequently are observed in which flat, round, or polygonal endothelial cells, arranged in small strands, lie within large or small meshes of abundant, richly vascular connective tissue. The cell groups and fibrous bundles intimately interlace. Both these tissues originate from preformed constituents of the dura mater. If in the growth of the tumor these two tissues are equally represented, a **fibroendothelioma** results; if groups of endothelial cells predominate, an **alveolar endothelioma** is produced, which differs from carcinoma by the intimate connection of the alveolar contents with the alveolar wall. In the tumors with flat cells, the cells may here and there be concentricly arranged, or the cell groups appear to be turned around their long axis, presenting on cross-section onion-like structures. Sometimes thick, branched

papillæ, composed of compactly arranged lamellated endothelia, also develop, which often present cleft-like lumina. In the interior of the papillæ are found granular **foci**, resulting from fatty degeneration, which are not tinged with nuclear stains. The papillæ lie in a fibrous stroma against which, however, they are not everywhere sharply demarcated; here and there transitions of the cells are seen at the junction with the fibrous tissue. Nevertheless, the tumor microscopicly presents a certain resemblance to squamous-celled carcinoma, especially because of the occurrence of concentricly lamellated endothelial pearls.

Endotheliomata of the **salivary glands** especially of the **parotid** and **submaxillary**, originate from tissue-spaces lined with endothelia. The cells form groups or bands separated by fasciculi of connective tissue. Within the interfascicular cell groups there frequently occur spheric, papilliform, and cylindric hyaline (or colloid) masses, which are regarded as secretory products of the cells.

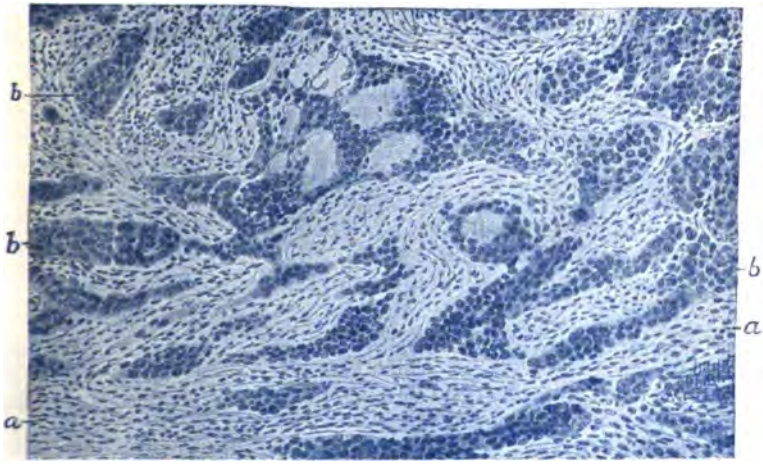

Fig. 117.—Endothelioma of the pleura. *a*, proliferated, thickened pleura tissue; *b*, cell strands. × 100. (After *Ziegler.*)

Adenoid tubular formations apparently filled with secretion thus develop in which the cells may be arranged in cubic, cylindric, or radiate order. Hyaline masses are often found also in the connective-tissue stroma, *i.e.*, outside the cell bands, and sometimes wide lymph-spaces are observed. These endothelial proliferations are often observed in **mixed tumors** of the parotid. This tumor, called **hyaline endothelioma, interfascicular endothelioma, cylindroma,** etc., is designated by some authorities as sarcoma (*angiosarcoma endothelioides,* tubular sarcoma). Kaufmann regards as appropriate the designation *endothelioma lymphangiomatosum cylindromatodes.* The formation of the haline cylindric inclusions is so striking as to suggest its recognition in the nomenclature. Designation of the tumor simply as "cylindroma" is inadmissible, since sarcomata originating from blood-vessels contain hyaline, cylinder-like formations, and similar structures may occur also in carcinoma.

Endotheliomata presenting the structure described under endothelioma of the dura mater are of rare occurrence in other localities, *e.g.*, upon the face, in the region of the eye (orbit) and nose. Endotheliomata of the **palate** are relatively frequent and manifest a marked tendency to undergo hyaline or mucoid degenera-

tion of the cells as well as of the stroma. Clinicly, they are generally benign, form no metastases, and do not recur after extirpation.

The rare **alveolar endotheliomata** of the **lymph-glands** sometimes resemble carcinomatous infiltration. This form of tumor has been designated also as *sarcoma alveolare epithelioides.*

Endotheliomata of the **pleura** are rare and usually originate from endothelia of the lymph-vessels and lymph-spaces, in some instances probably also from the superficial cells of the pleura. They develop in the form of a diffuse, hard infiltration, or as soft nodules and knobs or condylomatoid excrescences, which here and there are covered with a layer of fibrin and blood-coagula. When they are small, they greatly resemble tubercles. Metastases occur by way of the blood-channels, and secondary nodules may develop at points of exploratory puncture.

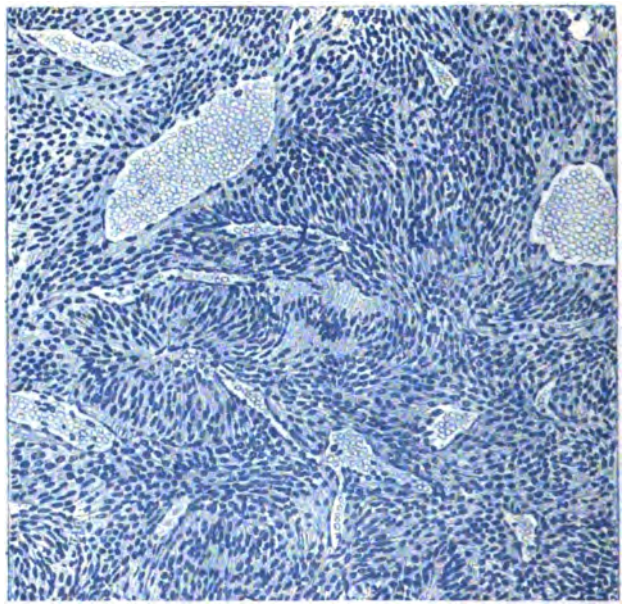

Fig. 118.—Perithelioma of choroid and ciliary body. Walls of blood-vessels formed of columnar cells radiately surrounding the lumen.

Carotid Tumors.—The carotid body, which is inconstantly present, is not infrequently the site of tumor formation. It is a structure 5 mm. long, 3 mm. wide, and 2.5 mm. thick, situated in the bifurcation of the common carotid artery. According to some authorities, it is derived from the sympathetic chromaffin system anlage which buds off from the central nervous system; others derive the chromaffin elements from the nerve anlage which passes from the upper cervical sympathetic ganglion between the two carotids. In structure the tumors originating from this body are more closely allied to the endotheliomata than to any other class. In the early stages they are encapsulated, benign, slow growths, but they may later grow rapidly and assume malignant characteristics, occasionally with the formation of metastases. In the early periods the tumor is from the size of a robin's egg to one that is just palpable, situated beneath the sternocleidomastoid or its anterior margin, on a level with the upper border of the thyroid cartilage. As the tumor pro-

gresses, more and more structures are involved. The sexes are equally affected, chiefly between the ages of 20 to 30 years, at which time the gland either atrophies or goes on to tumor formation. Growths have been known to develop, however, as late as the sixtieth year.[1]

ADENOMA AND ADENOCARCINOMA.

Local hyperplasias of the mucous membrane in the form of larger or smaller sessile swellings or pedunculated polypi are often observed upon the surfaces of mucous membranes. In these areas an excess of growth has occurred which, aside from the local enlargement, presents

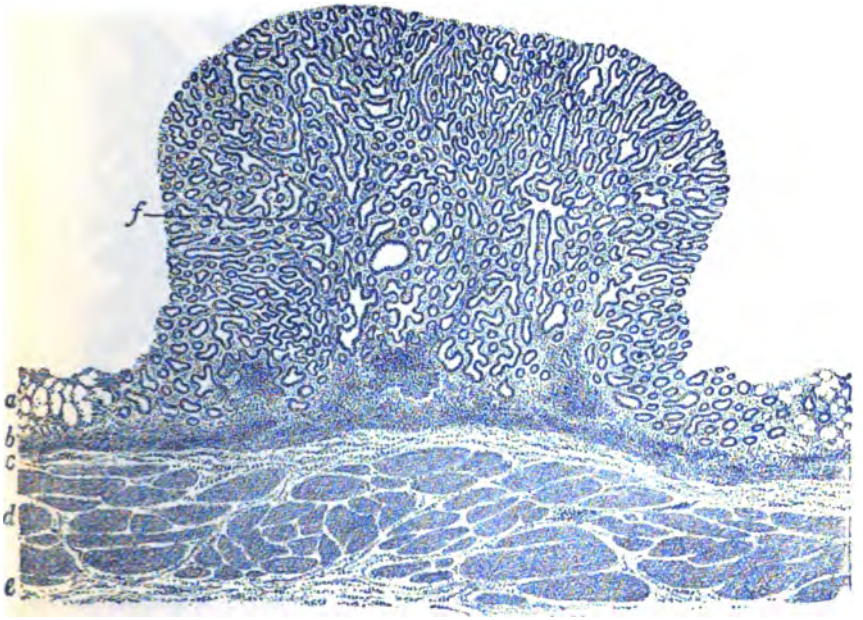

Fig. 119.—Tubular adenoma of the stomach in atrophic mucosa. *a*, atrophic mucosa; *b*, muscularis; *c*, submucosa; *d*, muscularis; *e*, serosa; *f*, adenoma. × 16. (After *Ziegler*.)

nothing pathologic. These formations, in which all constituents have proportionately increased, are best designated as local hyperplasias of the mucous membrane. Entirely analogous hyperplasias are seen in the liver in the form of pea- to hazelnut- sized nodules. (See Fig. 121.) These formations not infrequently manifest a tendency, with advancing growth, to extend also to other tissues. (See Fig. 120.) Growing into and destroying these, the proliferating parts assume characters of malignant tumors: *adenoma destruens*. They are then no longer benign local hy-

[1] For detailed description of these tumors, with literature, see J. G. Callison, Ann. of Surg., Dec., 1913, p. 741.

perplasias, but in malignancy resemble the carcinomata, for as soon as they once manifest the tendency to involve other parts metastases in adjacent and distant structures may also occur. Even in these cases the anatomic arrangement may be unaltered; by the aid of the microscope portions of mucous membrane can be seen which, apparently, are normal in structure, but which differ from the normal by the excessive development. These malignant tumors, which, in spite of their apparently harmless structure (in that they preserve and reproduce the simple

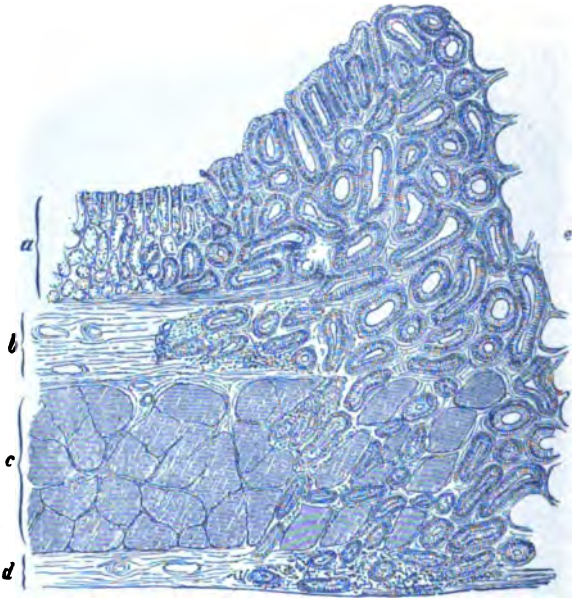

Fig. 120.—Adenocarcinoma of the stomach (schematic). *a*, mucosa; *b*, submucosa; *c*, muscularis; *d*, serosa; *e*, neoplasm. × 25. (After *Ziegler*.)

glandular character), behave decidedly different from the local hyperplasias of the mucous membrane, are best designated as adenomata. These closely resemble carcinomata not only in their often very great malignancy, but they also frequently manifest the characters of transition to carcinoma. So long as the process is characterized by one layer or several layers of orderly arranged epithelium upon a tunica propria and by distinct lumina, a pure adenoma exists, provided this tumor manifests malignant characters. As soon, however, as transition to carcinoma—*i.e.*, the formation of alveoli completely filled with irregularly arranged epithelia—is noted in this tumor, the process is, in every instance, a transitional or mixed tumor—an adenocar-

cinoma. Adenomata, as well as adenocarcinomata with cylindric or cubic epithelium, develop from the gastrointestinal canal and corpus uteri; they occur also in the prostate, testes, ovaries, mammæ, thyroid gland, pancreas, and liver; in the latter case sometimes in connection with cirrhosis of the liver.

Adenomata of the **round ligament** of the uterus are rare. They are unilateral or bilateral, nonencapsulated growths situated anywhere in the inguinal canal, vary in size from that of a hazelnut to that of a hen's egg, and are intimately adherent to the surrounding tis-

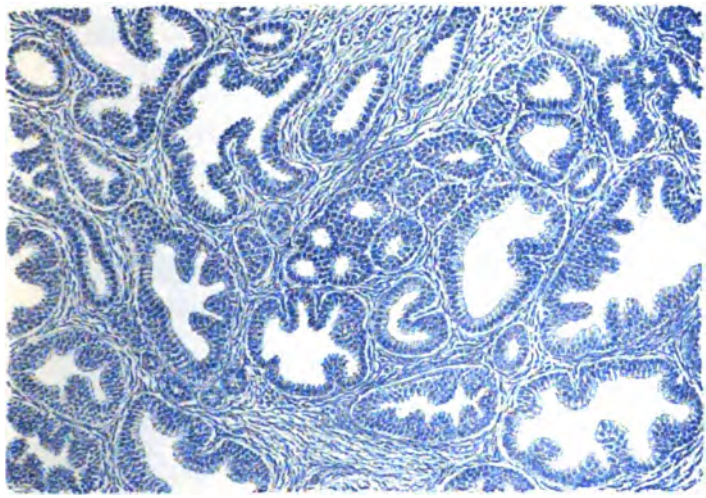

Fig. 121.—Papillary adenocarcinoma of the bile-ducts (hazelnut-sized nodule, metastases in the lungs). × 100. (After *Ziegler.*)

sues. Histologicly, they consist of a very vascular connective-tissue stroma inclosing semiglandular epithelial formations. The origin of these tumors is referred to remnants of the duct of Wolff.

CYSTOMATA.

Cystomata are tumors composed of cysts. They differ from all other cysts in that new cysts continually develop by progressive proliferation of the constituents of the wall. Hence, the process is the development of proliferating cystic tumors provided with an epithelial lining. The epithelium consists of large cells with distinct nucleus and nucleolus.

These formations are closely related to the carcinomata, in so far as the cysts, analogous to the alveoli of carcinoma, are formed by pro-

liferation. The difference is that the alveoli of carcinoma contain collections of cells, while the cysts of cystomata contain fluid. In the **ovary**, the most frequent seat of cystomata, cystic alveoli and alveoli filled with cells occur together. Cystomata generally form an aggregation of cysts presenting the appearance of a bunch of grapes the berries of which vary greatly in size. Some have very thin walls, like

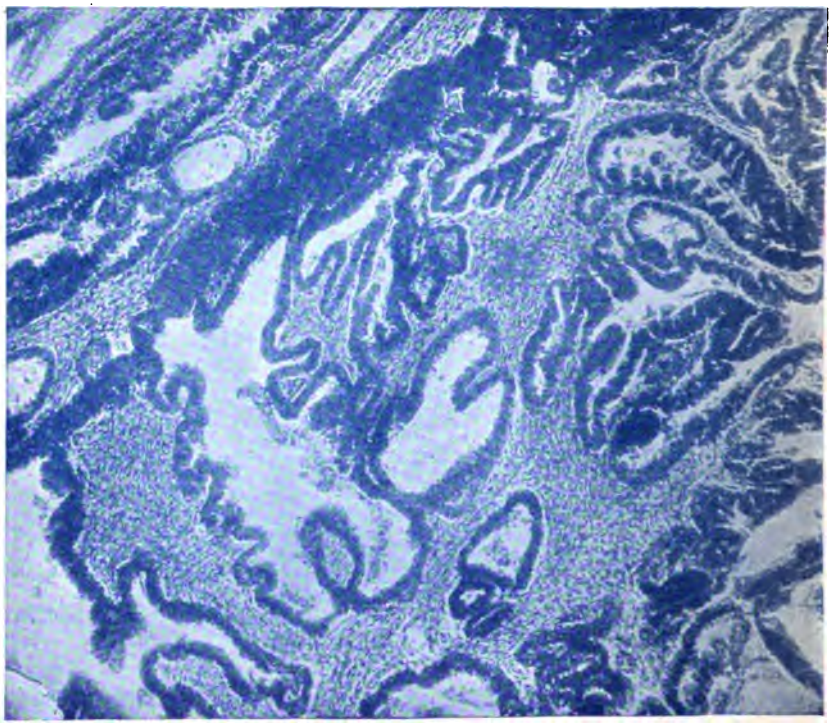

Fig. 122.—Papillary cystadenoma of the ovary. × 300.

ripe grapes; others have thick walls. The contents of the cysts at first consist of a gelatinous mass which later becomes liquid, sometimes very pale yellow, sometimes greenish or dark red from hemorrhagic admixtures. The individual vesicles converge toward the stem; the larger cysts always originate by confluence of the smaller. Cystomata are the heaviest, but not the largest, tumors of the ovary. In rare cases cystomata, like carcinomata, form metastases throughout the abdominal cavity, especially when cysts are opened by trauma or operation, and their contents disseminated over the peritoneum.

The fluid of ovarian cysts contains paralbumin. This substance, it has been claimed, is diagnostic, but it is neither distinctive nor peculiar to ovarian fluid. CO_2 or acetic acid will form a precipitate, but this phenomenon also is fallacious from a diagnostic standpoint. Floating in the fluid are a number of small cells (Drysdale's corpuscles), about the size of leucocytes, filled with glistening granules which are unaffected by acetic acid or ether. They are devoid of nuclei, none appearing even after treatment with acetic acid. Some authorities claim that they are the nuclei of epithelial (goblet) cells of

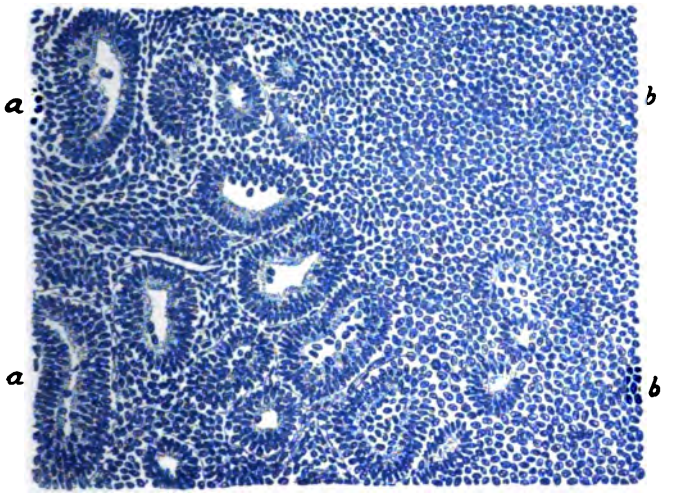

Fig. 123.—Teratoma (adenosarcoma malignum) of the kidney of a child of 7 years. *a*, tissue with gland tubes; *b*, sarcoma tissue. × 300. (After *Ziegler.*)

the cyst. Drysdale claims the granules are neither fatty nor albuminous; it is possible they may be mucous. They are not pathognomonic. So-called gorged corpuscles of Bennett (Gluge's cells) also are found, but they are not distinctive. These are very large cells gorged with granules of fat. They occur where fatty degeneration is progressing. Cholesterin in crystalline form is another constituent which may be present in large amount. Red blood-corpuscles are rare unless inflammation or trauma exists. Pus-cells (leucocytes) are present in variable amount.

3. The Teratoid Tumors.

The teratoid, or systematoid, tumors contain, in incomplete manner, a number of organs which correspond to an organ system.

Some of these tumors belong to the class of double monsters—of the parasitic fetus. In a measure they form cysts, in that a capsule incloses the whole tumor. On the other hand, as they always contain more or less complete portions of skin, all these tumors are included under the head of dermoid cysts. Besides skin, these dermoid cysts always contain a pap-like material, corresponding to the contents of atheromatous cysts, which is composed of desquamated, partly fatty-metamorphosed epithelia, cholesterin, fat-crystals, etc. The skin sometimes contains very well developed or hypertrophied papillæ, and is vascular and often provided with sweat and sebaceous glands, hair-follicles, and hairs. Many dermoid cysts contain also cartilage, bone, teeth, muscle, milk glands, more or less complete eyes, and also brain and nerve substance.

These dermoid cysts grow slowly, and occasionally attain considerable dimensions. They occur in the subcutis, ovary, brain, orbits, lungs, testes, etc.

POISONING.

THE phenomena of poisoning depend in general upon the concentration and amount of the acting toxic substance. Concentrated acids, for example, produce severe phenomena of poisoning, while they are harmless when highly diluted. Many medicaments act therapeuticly in medicinal doses, and as poisons in larger amounts. In this connection individual susceptibility is often very variable; the age and habits of the individual are usually of great significance. Hence, there is no definite limit beyond which a chemic substance acts as a poison. Accordingly, the anatomic alterations caused by poisons, and which are here of prime importance, are also subject to wide deviations. Here, also, aside from the quantity and concentration of the poison, the length of time which elapses between the primary action and the occurrence of death is very essential. If some time elapses before death occurs, part of the poison may be removed from the stomach by vomiting or the stomach-pump, and a portion may be eliminated also through the kidneys and intestine.[1] Under these circumstances anatomic alterations cannot always be observed. The conditions are entirely different, however, with poisons which cause death rapidly. In this instance local alterations are very frequently found.

Three great groups of poisons can be differentiated according to their action upon the human organism.[2] To the first group belong all chemic substances which exert an especially deleterious action upon the blood; these are the so-called blood poisons. To the second group belong all substances which produce alteration of the tissues, and to the third group such poisons as leave no visible evidence of their action.

I. Although, in addition to alteration of the blood, changes in the tissues frequently occur in connection with the **blood poisons,** they are insignificant compared with the effects upon the blood. To the blood poisons belong carbon monoxide (CO), carbonic acid (carbon dioxide, CO_2), sulphureted hydrogen (H_2S), hydrocyanic acid (HCN), and potassium cyanide (KCN).

[1] Poisons may be eliminated also by the saliva, milk, bile, sweat, blood (menstrual), and volatile poisons by the lungs (alcohol, ether).

[2] As space does not permit detailed discussion of all poisonings, only the most frequent and important alterations accompanied by decided and characteristic anatomic changes will be dealt with.

In **poisoning by carbonic oxide gas** (CO) (from charcoal fumes or illuminating gas) the blood, which is generally fluid, assumes a bright cherry-red color as a result of transformation of the oxyhemoglobin into carbonic-oxide-hemoglobin (demonstrable with the spectroscope). The latter is incapable of taking up oxygen. The red blood-corpuscles are not altered. If the action of the carbonic oxide ceases before death occurs, recovery may take place, or the individual dies from so-called secondary affections (*e.g.*, pneumonia from aspiration of vomited matter, foci of softening in the brain due to severe disturbances in nutrition resulting from union of carbonic oxide with the hemoglobin). After more or less prolonged action, the heart, liver, and kidneys are in a state of intense cloudy swelling. If death does not take place at once, violent bronchitis (sometimes hemoptysis) and bronchopneumonia occasionally occur.

In **carbon dioxide (carbonic acid) poisoning** (CO_2) almost all the blood remains fluid and has a dark-red color. Death results from interference with respiration, due to gradual accumulation of carbon dioxide and consequent progressive deoxidation of the blood; asphyxia occurs in consequence of reaction upon the nervous system (respiratory center) and heart. Carbon dioxide poisoning is observed in death from suffocation (hanging, strangulation, drowning, suffocation from aspiration of foreign bodies and solid masses of food, hemoptysis, aspiration of vomited matter, edema of the glottis, etc.).

In **poisoning with hydrocyanic acid** (prussic acid) (HCN), **potassium cyanide** (KCN) (especially in the form of oil of bitter almond), and **nitrobenzol** ($C_6H_5NO_2$) (mirbane oil), the parts of the cadaver have the odor of bitter almonds—perhaps not always distinguishable in the case of hydrocyanic acid, in nitrobenzol more intense than in hydrocyanic acid. The latter generally presents no other characteristic signs, while in poisoning with potassium cyanide (owing to its content of potassium carbonate) caustic action and severe hyperemic hemorrhagic alterations are often observed in the stomach. Nitrobenzol poisoning also gives rise to hemorrhagic hyperemia of the gastrointestinal mucosa, and the brain, liver, and kidneys are often intensely hyperemic. The blood coagulates slightly, and in poisoning with hydrocyanic acid is either bright cherry-red (according to Kobert, owing to the absorption of much hydrocyanic acid) and rich in oxygen or dark red. According to Kobert, cyanmethemoglobin is formed from the hemoglobin. According to Geppert, this is incapable of taking up or liberating oxygen. Furthermore, hydrocyanic acid exerts a direct paralyzing action upon the central nervous system.

After poisoning with nitrobenzol the blood is slightly coagulable, but it has a characteristic dark-brown color; for this reason the skin also occasionally has a dark grayish-blue color, while in hydrocyanic acid poisoning the cadaveric maculæ have a striking bright-red appearance. The gastrointestinal canal, brain, liver, spleen, and kidneys are very dark red.

In poisoning with **sulphureted hydrogen** (H_2S)—the chief constituent of the gas in privies and sewers—death occurs in a short time owing to the formation of sulphmethemoglobin and to paralysis of the central nervous system. The blood is remarkably dark, almost inky black; the organs have the specific odor of rotten eggs. It is doubtful whether an analogous poisoning can occur as the result of autointoxication from intense accumulation and decomposition of fecal matters in the intestine.

Other blood poisons act principally by destruction of the red blood-corpuscles and transformation of the hemoglobin into methemoglobin (brown color). This transformation may take place within the red blood-corpuscles as well as after they have been destroyed and the hemoglobin has passed into the blood-plasma. The methemoglobin is taken up by the spleen, liver, and bone-marrow, and when more methemoglobin is produced than these organs can retain it is excreted by the kidneys: methemoglobinuria. Methemoglobin is not formed in every instance in which hemoglobin enters the blood-plasma; under the action of arseniureted hydrogen, phallin (from *Amanita phalloides, Agaricus muscarius,* fly agaric), and helvellic acid (the active substance of helvella or *Morchella esculenta;* this toxic substance is removed by boiling; the water in which it was boiled is poisonous), hemoglobinemia (red color) and hemoglobinuria are produced. Deposition of blood-coloring matter in the liver, bone-marrow, and spleen and pigment infarcts in the kidneys also occur in these cases as a result of the intense destruction of the red blood-corpuscles. In fatal cases icterus is present.

Methemoglobinemia is produced by many oxidizing substances (ozone, iodine, nitrites, nitrates, etc.) as well as by reducing agents (pyrogallol, hydrochinon, pyrocatechin, alloxanthin, nascent hydrogen, etc.) and many other substances (toluidin, aniline salts, etc.). Pyrogallol, anilin, sulphureted hydrogen, toluylendiamin, nitroglycerin, nitrobenzol, amyl nitrite, phenylhydrazin, potassium chlorate, and others are especially characterized by the formation of methemoglobin.

In poisoning with **potassium chlorate,** the cadaveric maculæ (cadaveric ecchymoses, hypostases) present a peculiar dull-gray color.

The cause of death is generally parenchymatous nephritis and almost complete occlusion of the urinary tubules with methemoglobin; the latter is at least partly responsible for the complete anuria. In severe poisoning death occurs in a few hours. The blood then has a chocolate-brown color. In addition, potassium chlorate manifests general potassium action upon the heart (paralysis, cardiac weakness).

Finally, **ricin** (from the seed of the castor-oil plant) and **abrin** (seed of *Abrus precatorius*, jequirity, or wild licorice) are violent blood poisons which cause disintegration of the red blood-corpuscles and formation of thrombi. They may finally cause death by the production of violent catarrhal manifestations on the part of the gastrointestinal canal, accompanied by icterus, severe parenchymatous changes of the organs, and hemorrhages.

II. In the second large group of poisons, which are characterized especially by alterations of the tissues, three different modes of action can be differentiated: Irritation, parenchymatous inflammation, and corrosion.

To those agents which exert only an irritative action, producing hyperemia and swelling, belong various substances in gaseous or vapor form, *e.g.*, bromine, iodine, chlorine, ammonia, nitrous oxide, sulphurous acid, osmium, oil of mustard (*Oleum sinapis*), and others. The irritative action may extend to the mucous membrane of the eyes and nose (in bromine vapors), of the respiratory passages (iodine vapors and chlorine gas), and of the digestive canal. Often only hyperemia and secretion of watery or mucoid masses occur; occasionally, however, very violent inflammations and, under certain circumstances, even mortification may supervene. On swallowing irritant substances generally no hyperemia is produced in the mouth, because the poisonous agent too quickly passes this organ. In the gastrointestinal canal, on the other hand, very violent catarrhal inflammation may occur, which usually is accompanied by very active vascular injection and often by hemorrhages.

To the true **corrosive poisons** (*venena corrosiva*) belong, first of all, concentrated organic and inorganic acids (hydrochloric, nitric, sulphuric, carbolic, salicylic, oxalic, and glacial acetic acids); the caustic alkalies and alkali salts (*liquor potassæ, sodæ, ammonii caustici; potassium sulphuratum, permanganicum, bichromicum*), and the metallic salts (silver nitrate, corrosive sublimate, zinc chloride, copper sulphate, lead acetate, or sugar of lead, etc.). When greatly diluted they are usually harmless; in strong or concentrated solutions, however, like many other substances (*liquor ferri sesquichlorati*, cantharides, etc.), they produce violent gastroenteritis when ingested. Occasionally fibrinous exudations are produced through the agency

of chemic substances, especially in the pharynx and larynx (*e.g.*, vapors of *liquor ammoniæ fortior*); fibrinous membranes are then formed (in the stomach by the action of boiling water), *i.e.*, a variety of croup. This occurs when complete corrosion does not take place, *e.g.*, also in sulphuric acid and carbolic acid poisoning. With **corrosion** the circulation invariably ceases; consequently, exudation of fibrin cannot take place. Membranes which may become loosened and be discharged are also produced in corrosion. These are not, however, pseudomembranes, but true membranes, principally the necrotic exfoliated mucous membrane.

The **corrosive processes** are accompanied by phenomena of irritation. Here, also, hyperemia and hemorrhage at first ensue. The blood, owing to chemic union with the corrosive substance, is transformed into a condition designated as carbonization, because the attacked hemorrhagic parts assume a blackish-brown color.

The peculiarities of the action upon the albuminous substances are best seen when very little blood is present; otherwise, they are obscured by hemorrhagic reddening. At first clouding of the mucous membrane occurs as the result of precipitation of albuminates, whereby the parts may assume a cloudy, whitish hue.

This primary stage of mortification is followed by the second—that of ulceration and exfoliation. At the point between the mortified and nonmortified tissue a demarkating and dissecting suppuration develops; this results in exfoliation of the dead parts and the formation of a corrosion ulcer: *ulcus corrosivum.* The exfoliated membranes (mucosa and submucosa) are always rough upon the external (superficial) surface, and smooth upon the inner (exfoliated) surface, as a result of suppuration. Croupous membranes, on the contrary, are smooth externally and rough internally. The corrosion ulcer heals readily, provided the individual survives. Granulations then develop upon the surface of the ulcer and result in the formation of a layer of connective tissue (not in regeneration of the mucous membrane). This cicatrization is always associated with contraction, which varies in degree according to the depth of the corrosive action. In the esophagus the narrowing (stenosis) may be so pronounced as to permit the passage of but small sounds, and in the stomach the contraction is sometimes so extreme that this organ becomes very small and wholly insufficient.

The corrosive action is rarely of uniform intensity over large areas. The principal seat of action of all corrosive substances is the stomach. The ingesta pass the mouth and esophagus quite rapidly; consequently, very little carbonization of these parts is found and rarely

true ulceration. In the esophagus those localities which are points of predilection for the formation of carcinoma are especially disposed to corrosion, namely, those parts which are principally adapted to bring the ingesta into intimate contact with the mucosa of the esophagus: (1) the isthmus behind the cricoid cartilage; (2) the crossing of the esophagus with the left bronchus; (3) the part immediately above the *hiatus œsophageus* of the diaphragm. In the stomach the pylorus is always the most intensely altered; the fundus is more rarely and less severely altered; the remaining parts often show no signs of corrosion, but they also may be altered *in toto*. The whole inner surface of the esophagus (mucosa, submucosa, more rarely parts of the muscularis) may also be corroded, exfoliated as a tubular mass, and sometimes suddenly be vomited by violent regurgitant peristalsis. The corrosion rarely extends deeper than the muscularis. Therefore, perforation of the stomach never takes place immediately after corrosion, but, if it ever occurs, only after the lapse of weeks. Post-mortem perforation, however, may very early occur after corrosion (*e.g.*, in transportation of the corpse), and the remaining abdominal organs may then be attacked by the corrosive substance (*e.g.*, sulphuric acid). In this case signs of peritonitis, which are never absent in perforation during life, are always lacking.

In **poisoning with sulphuric acid** a brown eschar is sometimes formed at the corners of the mouth by spilling of the liquid. **Nitric acid** leaves a yellow, and **hydrochloric acid** a gray or grayish-white, eschar. In but few instances, however, can this feature be relied upon as of positive diagnostic importance; indeed, in many cases all external evidence of escharotic action is absent. The yellow staining of the gastric mucosa is always due to imbibition of bile, owing to entrance of bile into the stomach as the result of violent efforts of vomiting.

In the neighborhood of the escharred parts imbibition of blood-coloring matter and edema generally exist. As a rule, the pylorus forms the lower limit of the corrosive action; corrosion is seldom observed beyond the pylorus. If death does not occur early in cases of sulphuric acid poisoning, parenchymatous degeneration of the heart, kidneys, and liver, with ultimate fatty metamorphosis, may supervene.

In poisoning with **acetic acid** transformation of the surface into a jelly-like condition has been observed, after which true softening followed. Sometimes grayish-white or blackish eschars develop upon the mouth.

Corrosion occurs also in poisoning with **oxalic acid** and **potassium oxalate** (sorrel salt), which kill by paralyzing the central nervous system. The occurrence of calcium oxalate in the urinary tubules is characteristic of oxalic acid poisoning.

Carbolic acid sometimes alters the urine, especially after prolonged action, and imparts to it a dark olive-green color. It may also produce symptoms of poisoning and sudden collapse, by action upon

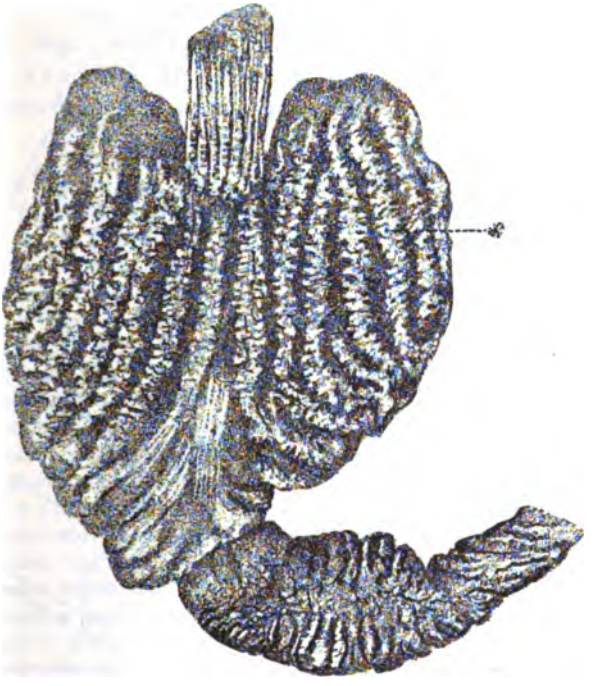

Fig. 124.—Gastric mucosa strongly swollen and folded. The crests of the folds have been corroded by carbolic acid. Duodenum in part strongly swollen; mucosa closely folded; occasional folds slightly corroded upon the crests. (Suicide. ⅛ natural size. After *Langerhans.*)

the central nervous system, from absorption through the skin, surface of wounds, genital passages, and rectum. When the first, usually very severe, collapse subsides, a violent bronchitis develops, which begins insidiously and is often attended by only slight symptoms; this is accompanied by a very extensive fibrinocatarrhal bronchopneumonia, which, in many instances, also appears insidiously and frequently ends in death. At necropsy the organs often have a characteristic odor of carbolic acid.

Ammonia, after absorption through the intestinal canal, acts as

a violent irritant upon the mucous membrane of the respiratory passages, and sometimes causes death from edema of the glottis.

Many animal poisons are similar in action to the corrosive poisons. They sometimes produce more or less violent local inflammation (at the point of entrance), sometimes necrosis. Here belong cantharidin (from the beetle, *Lytta vesicatoria*); phrynin or bufidin (from the cutaneous glands, parotid, of toads); the secretion of the venom glands of serpents and scorpions; the secretion of the sting glands of bees, wasps, hornets, and of the salivary glands of gnats, mosquitoes, gad-flies, and flies, and the secretion of the poison glands of spiders (*tarantula*). Snake poisons exert also a paralyzing action upon the central nervous system. The sting of certain scorpions is fatal.

In the poisonous serpents the poison is contained not only in the secretion of the poison glands, but also in the blood-plasma, where it occurs in species which, although possessing poison glands, are unarmed with poison fangs. In most serpent poisons and in the poison of the scorpion, spiders, etc., hemolysins[1] are present which dissolve red blood-corpuscles *in vitro*, in which process lecithin plays an important rôle. The hemolysin of cobra poison and other serpent poisons combines with this normal constituent of the red blood-corpuscles to form lecithidines, whereby, according to Ehrlich's terminology, the poison and the lecithin become linked as amboceptor and endocomplement, thus considerably increasing the avidity of the cytophile group of the amboceptor, *i.e.*, its hemolytic action. It has been shown that the neurotoxin of cobra poison, which causes severe manifestations of poisoning, is not bound by lecithin, so that this serpent poison can be separated by the lecithin method into two different toxic components: hemolysin and neurotoxin. The poisons of viperidæ and several colubridæ contain, according to Flexner and Noguchi, a third toxin (hemorrhagin) which causes the marked local effects of bites of the viperidæ: the hemorrhagic edema, etc., probably by injury of the vascular endothelia. The toxinoid animal poisons also possess, in common with bacterial poisons, the ability to produce in the living animal body so-called antibodies which form with the toxic substances inactive compounds, and the serum of animals immunized to serpent poison can be employed in the therapy of serpent bites. The **antivenene** of Calmette is effective only against cobra poison and other essentially neurotoxic snake poisons; it does not neutralize the action of hemorrhagin. Calmette has recently succeeded in producing a polyvalent serum by successive immunization against both categories of poison.

Injection of water into the blood produces hemolysis by disturbance of the osmotic equilibrium between the blood-corpuscles and the surrounding fluid. Ether (*in vitro; in vivo* the ether is given off beforehand to the blood-plasma, when the ether content of the latter diminishes), chloroform, biliary acids, glycerin, AsH_3, toluylendiamin, chlorates, felicic

[1] Certain bacteria, *e.g.*, staphylococci and streptococci; cholera, tetanus, and pyocyaneus bacilli; also elaborate **hemolysins**, *i.e.*, substances which dissolve red blood-corpuscles in the blood. This solvent action is designated as **hemolysis**, and is characterized by the discharge of the hemoglobin from the red blood-corpuscles into the blood-plasma and destruction of the red cells.

acid, morells (*e.g., Helvella esculenta*), many serpent poisons (see p. 320), and toxins of infectious agents also produce hemolysis. A large number of pathogenic bacteria produce hemolysins which dissolve erythrocytes also in bouillon tubes. Besides, the normal blood-serum of many animals dissolves the red blood-cells of other animals (even those of an individual of the same animal species: **isolysis**[1]), so that only the blood of the same animal species can be used for transfusion. Further, it is possible experimentally to impart to the blood-serum of an animal, A, the ability to dissolve the erythrocytes of an animal, B, when the blood of animal B is repeatedly injected into the body of animal A. In other cases of hemolysis chemic alteration is predominant. The hemolysins exert a lipolytic

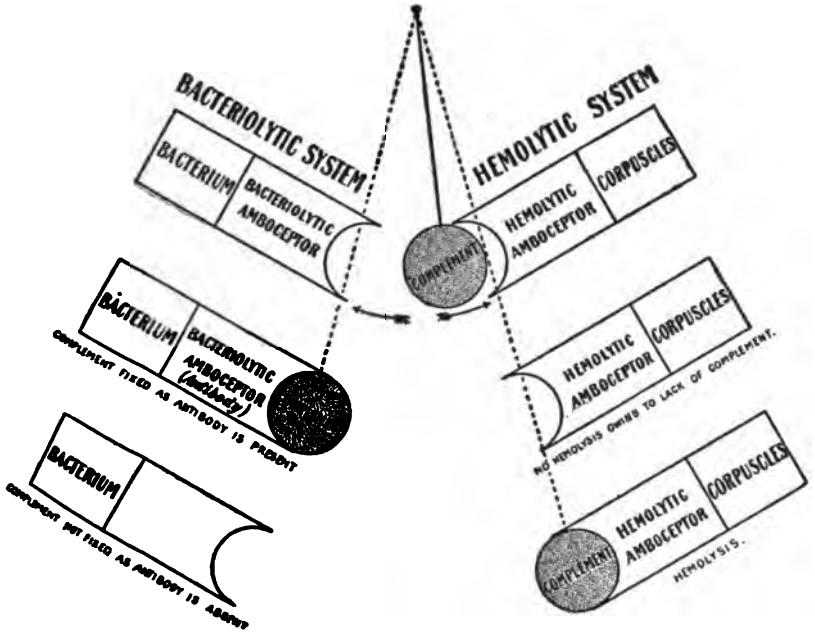

Fig. 125.—Principle of complement fixation illustrated by a free-swinging pendulum. (After *H. Fox.*)

action, and, as the erythrocytes contain lipoid substances, hemolysis here can readily be comprehended. The action of saponin, which binds cholesterin, offers an insight into an especial case: erythrocytes are five times as sensitive to saponin in isotonic sodium chloride solution as in their own serum. If the cholesterin is removed from the blood-plasma, the latter loses its antihemolytic power and the cholesterin of the erythrocytes is at once attacked (Askanazy).

The phenomenon of hemolysis is now extensively employed in the **Wassermann-Bruck reaction** in the diagnosis of syphilis. In this test there are used:—

1. The blood-serum of the patient, which, if he has syphilis, represents an anti- or immune body: amboceptor.

[1] Therefore, in transfusion in the human subject, the serum of the blood to be transfused should previously be tested as to its hemolytic action upon the corpuscles of the recipient.

2. Antigen: an extract of a syphilitic organ containing *Spirochætæ pallida* (usually the liver of a syphilitic fetus).

3. Complement, which is present in every blood-serum.

4. Red blood-corpuscles of a sheep.

5. Antibody or amboceptor to these red blood-corpuscles, prepared by injecting an animal (*e.g.*, rabbit) with red blood-cells of a sheep.

If the patient's blood-serum is an immune serum, *i.e.*, contains syphilitic antibody, it is united by the complement with the antigen in the extract. The complement, therefore, becomes "fixed," and, as (with the aid of the amboceptor) it cannot dissolve the red blood-cells, no hemolysis occurs: the red blood-cells form a sediment. On the other hand, if syphilis is not present the patient's blood-serum is not an immune serum for syphilitic antigen, *i.e.*, contains no syphilitic antibody; the complement, therefore, remains free and unites with the sheep blood-cell amboceptor and red blood-cells and dissolves the latter, *i.e.*, hemolysis occurs. This "complement fixation," however, does not appear to be specific,[1] since an antigen, which still will bind the syphilitic immune body in the presence of complement, can be extracted from normal organs of animals (*e.g.*, the heart muscle[2] or liver).

The **Noguchi modification** of this test differs essentially in the use of human red blood-corpuscles and human blood-corpuscle amboceptor.

Subcutaneous injection of blood-serum, egg-albumen, or other indifferent soluble animal, vegetable, or bacterial proteid into guinea-pigs or other animals produces in these animals a state of hypersensitiveness, called **anaphylaxis,** or **allergy,** which becomes manifest on subsequent injection, after a certain interval (about ten days), of the same kind of proteid. Very minute quantities of the proteid (*e.g.*, $\frac{1}{1000000}$ Gm. of horse serum) suffice to produce sensitization; the second dose, however, must be comparatively large (*e.g.*, 3 to 6 c.c.). The blood-serum of anaphylactic animals, when injected subcutaneously, renders within a few hours other animals of the same species passively hypersensitive to reinjection. This form of anaphylaxis is known as "**passive anaphylaxis.**" (Otto.) The sensitized mother can convey this condition to the offspring (fetus), whether injections are made before or during pregnancy. This **inherited anaphylaxis** lasts for about six weeks. It cannot be transmitted through the milk or sperma. **Eosinophilia** is regarded by some as a blood symptom of acquired anaphylaxis. A **familial form** of anaphylaxis has recently been described.[3] According to Rosenau and Anderson, the essential agent in passive transference of anaphylaxis is "allergin," an antibody characteristic of anaphylaxis and specific for its antigen. On the other hand, Friedberger designates the anaphylactic toxin as anaphylatoxin, which he regards as the same in all forms of anaphylaxis. Immediate anaphylactic symptoms can be produced in normal (nonsensitized) animals by injection of suitable mixtures of antigen and anaphylactic antibody.

Dyspnea is pronounced; the pulse shows marked irregularity (vagus pulse); the blood-pressure sinks rapidly to zero as a result of paralysis of the peripheral

[1] According to Stitt (Practical Bacteriology, etc., Blakiston, 2d ed., 1910, p. 140), "the Noguchi method gives a positive reaction with nonsyphilitic sera in about 7 per cent. of cases, and the Wassermann gives a negative reaction in about 9 per cent. of syphilitic sera."

[2] Manoiloff (*Cent. f. Bakt.*, Bd. 57, H. 5), substituting normal gastric juice for the amboceptor recommended by Wassermann, has obtained the same results as with the Wassermann hemolytic amboceptor.

[3] Berlin. klin. Woch., No. 21, 1911, p. 938.

vasomotor apparatus. There are vasodilation in the splanchnic area, resulting in hyperemia of the abdominal organs, increased peristalsis, and diarrhea; leucopenia, decreased coagulability of the blood, disapperance of complement, and rapid fall in temperature. Animals frequently die in convulsions in from five minutes to one hour. Death is due to paralysis of respiration. The heart continues to beat for some time after cessation of respiration. At necropsy the lungs are enormously distended (emphysematous), due to spasm of the bronchial muscles of peripheral origin. Animals which recover return to the normal condition within from twelve to twenty-four hours, and are then immune (antianaphylactic) to further injections. Antianaphylaxis may be produced if the animals are injected during, *i.e.*, about the middle or toward the end of, the anaphylactic incubation period; otherwise anaphylaxis develops.

According to Rosenau and Anderson, the hypersensitiveness in sensitized guinea-pigs lasts about two years. According to Curie, man injected once with horse serum remains for five years hypersensitive to reinjection. All warm-blooded animals thus far examined can be rendered anaphylactic, although sensitiveness in individual species is very variable. Man is not very sensitive. Of cold-blooded animals the results thus far have been positive only in the frog.

Anaphylaxis occurs, as a rule, only when the proteid of the first injection (antigen) is parenterally (*i.e.*, extraenterally) introduced. While heterologous proteid taken *per os* is completely broken down in the intestinal tract by the ferments there present and is syntheticly converted into homologous proteid in the intestinal wall, the proteid parenterally introduced acts as an irritant and, after a certain period of incubation, excites the formation of large amounts of strongly specific antiproteid bodies (amboceptors). If albumin is parenterally introduced by intravenous reinjection into the organism of an animal in which, as the result of former injection, antibodies (amboceptors) specific for the proteid in question circulate, union of antigen and antibodies occurs and results in a quite sudden disintegration of the proteid, which, of course, at the time of the first injection, only very gradually took place. The intermediate substances thus produced are, perhaps, the same as those formed in enteric digestion; however, as they are not in the lumen of the intestine and not removed from direct action upon the organism, certain groups of these decomposition products apparently are unusually toxic.

Accordingly, anaphylaxis may be regarded as a form of parenteral albumin digestion, *i.e.*, an intoxication by intermediate products liberated during extraenteral disintegration of proteid. The disintegration products themselves probably are not specific, but only the mode of toxin formation; since on employment of the relatively small doses, such as are found to be fatal on reinjection, an intense liberation of toxin can occur only when the homologous antibody has been increased by previous preparation.

When a sublethal dose is reinjected after about ten days, the antibody is in great part anchored by the proteid and thus rendered inactive, so that soon thereafter the animal can endure many times the otherwise fatal dose. This state is designated as **"antianaphylaxis."**

The union of the antibodies formed during the period of action of the first injection with the homologous proteid introduced at the time of reinjection does not of itself exert a toxic action; but from this union disintegration results solely through the agency of complement, whereby, as already stated, intermediate toxic products are formed.

Therefore, in anaphylaxis, as in hemolysis, etc., we have three components which interact with the formation of toxin. These are: (*a*) antiproteid body produced by the first injection; (*b*) the proteid of the second injection, and (*c*) complement. With these three components Friedberger[1] has produced also in the test-tube what he regards as the same intermediate toxic product, which he designates as **"anaphylatoxin."** For example, if the precipitate produced by the union of albumin and antibody is acted upon by normal guinea-pig serum, the latter acquires such acute toxicity that, when freed from the precipitate by centrifugation, it causes rapid death of guinea-pigs under symptoms of anaphylaxis. On the other hand, if the precipitate is digested with inactivated guinea-pig serum (*i.e.*, serum deprived of complement), no anaphylatoxin is formed. A toxic dose of anaphylatoxin can be liberated from even 1 mg. of heterologous serum, which corresponds to 0.1 mg. of albumin. Friedberger's view has recently been denied by Keysser.[2]

When a normal animal is subcutaneously injected with a large, but sublethal dose of heterologous serum, the normal antibodies, which are present only in small amount, do not disintegrate the proteid as rapidly as is the case in an animal previously treated. In the blood of such an animal there still is present more or less disintegrated remains of antigen in addition to the new-formed antibody. These two components apparently react with each other but slightly or not at all. If such a serum is injected into another animal, the antibody, with the antigen residue, reacts with the formation of anaphylatoxin, and through the action of such a serum alone a genuine primary antiserum anaphylaxis develops. (Friedberger.) That the antibody plays a decisive rôle in this form of anaphylaxis is shown by the fact that absorption of the antibody renders the serum nontoxic.

By **anaphylaxis** due to **antitoxin** (horse serum) is understood the severe symptoms occurring in certain individuals immediately after the first injection. It is very rare and should not be confused with **serum sickness** (see below), which occurs in about 10 to 20 per cent. of all persons injected with antitoxin, is a natural reaction to the introduction of an heterologous serum, and is observed about ten days after injection.

Many measures have been recommended to overcome the danger of anaphylaxis occurring in therapeutic injection of serum. Small amounts of serum should be used, as the danger increases with the dose. For this reason high-potency sera are preferable. Heating for a number of days at from 55° to 56° C. considerably diminishes the toxicity without loss of antitoxic potency. Prophylactic injection of antitoxic serum of sheep has been advised, after which, in case of advent of diphtheria, high-potency horse serum can be used. Calcium chloride or calcium lactate, 0.1 to 1.0 Gm. *per os* for three days, have also been recommended. Atropine has been employed in animals as a prophylactic. The most certain agent, however, is the use, before reinjection, of a small dose of serum subcutaneously in order to establish antianaphylaxis.

In **echinococcus** an antibody is formed in the organism of the host by resorption of small amounts of the albumin of the parasite. If in such individuals, at the time of incision of the cysts, large amounts of the albumin are suddenly resorbed from the peritoneum, severe acute toxic phenomena referable to anaphylaxis develop.

According to Friedberger,[3] **eclampsia** is a state of anaphylaxis in which

[1] Deutsch. med. Woch., 1911, No. 11, p. 482.
[2] Cent. f. Bakt. Beilag. zu Abt. I, Bd. 50, H. 51.
[3] Münch. med. Woch., 1910, p. 2699.

resorption of the liquor amnii during gestation sensitizes the organism. The increased resorption *intra partum* produces the symptoms. Serum of eclamptic women renders guinea-pigs passively hypersensitive to subsequent injection of liquor amnii. The sudden death from respiratory failure of apparently healthy infants after the first copious nursing from the breast of mothers who have passed through eclamptic attacks, especially *post partum*, is probably also referable to anaphylaxis.

The nature of idiosyncrasy to medicines (drugs) is wholly obscure. As the agents here are chemic bodies possessing no antigen properties, *i.e.*, substances incapable of producing antibodies, a connection with anaphylaxis is denied in spite of the similarity of the symptoms. Recently, however, a certain relation has been assumed to exist; for example, iodoform idiosyncrasy is said to originate not from the iodine as such, but from an iodoproteid which acts as an antigen producing an antibody to iodoproteid.

Serum sickness and **serum intoxication** are terms employed to designate the phenomena (pruritus, fever. urticaria, edema, arthralgia, adenopathy, sometimes albuminuria) which follow in about 10 to 20 per cent. of the cases of subcutaneous injection of antitoxin in man. The symptoms generally appear about the eighth or twelfth day after injection, though persons who previously have been injected may manifest symptoms earlier. The patient appears to have been sensitized (see Anaphylaxis). Serum sickness is usually unattended by danger, the symptoms generally subsiding within a few days.[1] The following table of Miller and Root,[2] based upon the observations of Lucas and Gay, shows the percentage of children manifesting symptoms after injection and the relation to the number of doses:—

Injection.	No. injected.	Total No. reacting.	Per cent. reacting.	Reactions Classified.			
				Children showing general symptoms.		Children showing local symptoms.	
				No.	Per cent.	No.	Per cent.
1st	1000	3	0.3	3	0.3	....	....
2d	281	26	9.3	17	6.1	16	5.6
3d	103	15	14.6	11	10.6	13	10.0
4th	36	13	36.1	5	14.0	11	30.5
5th	25	12	48.0	6	24.0	11	44.0
6th	15	11	73.3	5	33.3	10	66.6

After poisoning with **preparations of mercury**, very severe changes are produced in the large intestine, even when the mercury has not gained entrance to the body through the mouth. In this case the poison must have entered the circulation and been excreted into the intestine. This is a secondary form of poisonous action. Here, however, an alteration occurs which appears as though it had been induced by action exerted directly upon the surface and not from within outward. The change is generally confined to the large intestine, though

[1] Sudden death may follow injection of diphtheritic antitoxic serum.
[2] Therap. Gaz., Feb., 1910.

in some cases it may extend to the ileum and jejunum. The manifestations closely resemble those of dysentery: *colitis hæmorrhagica diphtherica* (*q.v.*). They sometimes begin a few hours after application of bichloride of mercury to large wound surfaces, and may cause death in a very short time. In such cases, in addition to the intestinal alterations, cloudy swelling of most of the organs, particularly the kidneys, is observed. The epithelia of the convoluted tubules of the kidney appear to be incrusted with lime, *i.e.*, the epithelia are still present and can be stained, but they are covered with a very thin layer of lime, so that they become plainly visible only after solution of the lime. As cells calcify only when dying or dead, this may be regarded as an indication that the epithelia of the urinary tubules are severely injured or possibly dead. In addition, countless solid lime infarcts are formed, especially in the convoluted renal tubules. The freshly deposited lime often dissolves upon addition of dilute acetic acid. If a number of days elapse before death occurs, compact lime deposits —countless lime infarcts—are found, some of which are visible macroscopicly, while beginning deposition is demonstrable only upon microscopic examination. The enormous number of lime infarcts is characteristic of mercurial poisoning. Furthermore, stomatitis with salivation, which not rarely advances to ulceration (upon the gums, cheeks, margin of the tongue) and sometimes even to loss of the teeth and necrosis of the maxillæ, frequently develops as a first sign of poisoning. This, however, is much more frequent in chronic mercurialism. The caustic action exerted by corrosive sublimate and other mercurial compounds is often very severe when large amounts are introduced into the gastrointestinal canal.

Preparations of lead (especially *plumbum aceticum*, or sugar of lead, basic lead carbonate or white lead, litharge) in large quantity produce acute gastroenteritis, intense swelling and hyperemia with small hemorrhages, and swelling of the intestinal follicles. The glandular epithelium of the stomach, kidneys, and liver is in a state of cloudy swelling; in the brain, cerebral membranes, and kidneys, strong hyperemia exists; after a few days icterus occurs. The feces have a blackish appearance, due to lead sulphide.

In chronic poisoning the gums at the junction with the teeth have a slate-blue color, due to the deposition of lead sulphide in the tissue of the mucosa.[1] Marked anemia; degeneration of Meissner's plexus of the submucosa of the intestine and of Auerbach's plexus (in the intestinal musculature), which causes lead colic and constipation;

[1] According to some observers, the deposit is superficial.

chronic nephritis (granular atrophy); cellular infiltration of the adventitia and fatty metamorphosis of the media of the arteries, and fatty metamorphosis of certain groups of voluntary muscles (extensors of the extremities—lead paralysis, palsy) are present also.

When there is no disease of the blood and clinic examination reveals no cause for the secondary anemia, a high content of the blood in erythrocytes showing basophilic granulation (more than 1:10,000) is strongly suggestive of lead poisoning. Likewise, in the absence of other causes, especially such of a toxic nature, the presence of an abundance of hematoporphyrin in the urine (hematoporphyrinuria), to which attention may be directed by the red color of the urine, is also an indication of lead poisoning.

As regards the etiology of the arthralgia and encephalopathy in lead poisoning, nothing definite is known pathologicoanatomicly. Garrod asserts that lead favors the deposition of urate of soda about the joints. Extreme emaciation, *macies,* is always observed, and is due to general disturbance of nutrition. Lead is also very fatal to the life of the fetus; pregnant women suffering from chronic lead poisoning abort early or give birth to stillborn children.

Lead is taken into the body through the mucous membranes, wounds, and ulcer surfaces, and retained for a long time. It is finally excreted with the bile and urine. The most frequent victims of chronic lead poisoning are painters, who often employ lead in their colors and do not observe sufficient care in cleansing the hands before meals.

The action of **phosphorus** in acute poisoning is manifested principally by parenchymatous degeneration of the large glandular organs of the abdomen (stomach, small intestine, liver, kidneys, pancreas), of the heart, and of the general musculature, with final fatty metamorphosis. In the arteries, also, extensive fatty metamorphosis occurs within a very short time. From the second or third day onward intense icterus develops. If death occurs very rapidly, the stomach sometimes has a distinct garlicky odor.[1] In the parenchymatous degeneration of the large internal organs and in the icterus, the post-mortem findings in phosphorus poisoning often conform in every way with those observed in severe sepsis. The sole characteristic exception is the spleen, which is unaltered in phosphorus poisoning; in septic processes, however, it is usually swollen as the result of hyperplasia of the pulp. Further, a positive basis for the diagnosis of phosphorus poisoning is frequently offered by innumerable small,

[1] The urine is diminished in amount and contains blood, albumin, and sometimes fibrinous casts. Urea disappears almost entirely as death approaches, the peculiarity most distinctive in fatal cases being the presence of paralactic acid. The stools may appear phosphorescent in the dark.

partly confluent hemorrhages: petechiæ of the skin; ecchymoses of the subcutis, serous membranes, liver capsule, vessel-sheaths; sometimes hemorrhages in the gastrointestinal canal, lungs, ovaries, and brain.[1] These, however, may sometimes occur also in sepsis.

The characteristic changes are, as a rule, most pronounced at about the sixth or eighth day. Corrosion of the surface of the stomach seldom occurs; the parenchymatous inflammation of the peptic glands—gastroadenitis or *gastritis glandularis*—begins in the fundus, *i.e.*, in that portion where the vessels supply the blood. Owing to progressive swelling of the glands, the blood can enter the mucosa to only a slight degree, and hence anemia of the gastric mucosa develops. This so-called parenchymatous gastritis stands parallel to parenchymatous hepatitis and nephritis.

Chronic phosphorus poisoning occurs only in factory workers who handle this substance. It consists in stomatitis and periostitis of the maxillæ, with loss (shedding) of the teeth, hyperostosis (osteophytes), and carionecrosis. As a result of the latter a great portion of the lower maxilla may be destroyed. Suppurating fistulous tracts often form, which open either into the mouth or externally. Through prolonged action of small quantities of phosphorus, sclerosis of the spongiosa develops in growing bone at the cartilagino-osseous junction.

In acute **arsenical poisoning** (mostly through the agency of arsenious acid, so-called white arsenic), and through the copper salts of the arsenical dyes: Schweinfürth, Scheele's, Rinmann's, or Paris green (arsenite of copper), death may occur quite suddenly—after twenty minutes to one hour—under phenomena which are referable to the nervous system (collapse, convulsions). If a number of hours elapse before death takes place, alterations of the gastrointestinal canal occur which greatly resemble the phenomena of Asiatic cholera. An acute gastroenteritis is then present; the gastric mucosa is swollen, bright red, studded with small hemorrhages, and covered with a layer of mucus, which is often tinged with blood; the follicles are enlarged (*gastritis follicularis*). Sometimes small, round ulcers with injected margins are observed in the gastric mucosa. In such instances small, white arsenic grains (octahedra), which, on burning, emit a garlicky odor, are not infrequently visible in the mucus and upon the floor of the ulcer. In the small intestine the swelling, the hyperemia,

[1] Most important changes are said to occur also in the blood, it being thick, fluid, and noncoagulable. It contains a large amount of fat, and its corpuscles are altered in form and decreased in number, while an increase of the white elements is also said to take place. It contains an undue amount of tissue waste in the form of uric acid, creatin, etc.

the formation of small extravasations of blood, and swelling of the follicles are repeated. The contents of the intestine contain no bile (not because engorgement is present, but because no more bile is formed), and resemble rice water.

If death does not occur for several days, exactly the same alterations as are found in phosphorus poisoning are present: fatty metamorphosis of almost all the organs, though usually in somewhat milder degree, because death takes place earlier.

Arsenic can still be detected in the body after a number of years. It prevents putrefaction, and often rapidly leads to complete mummification. Arsenic usually disappears very rapidly from the gastrointestinal canal. (See paragraph 4, p. 333.)

In chronic arsenicism (arsenism, arsenicalism) cutaneous eczemas develop from which carcinoma sometimes originates; also, but rarely, melanoses of the skin, and, as arsenical paralyses occur, probably also degeneration of the nervous system. Perhaps renal changes also occasionally occur, because dropsy has been observed. The two last-named alterations, however, have not been sufficiently investigated.

Ehrlich-Hata "606"; salvarsan (dioxydiamidoarsenobenzenedihydrochloride). The knowledge of the dosage, indications, technique of administration, and mode of action of this widely discussed, new arsenical preparation is incomplete. On contact with the air it is readily decomposed (oxidized) with the formation of toxic compounds, and very probably it is rapidly altered also in the body, especially when introduced subcutaneously or into the muscles. As the specific action is due solely to the arsenobenzol, this chemic change suspends the inhibiting or destructive influence upon the syphilitic virus. The cases of poisoning thus far recorded are undoubtedly due to the arsenical derivatives thus produced, since most authorities state that pure, unaltered arsenobenzol is nontoxic. The methyl-alcohol formerly used in preparing the injections does not appear to have been the cause of any of the toxic effects.

The local action is very marked and in some instances widespread. Martius,[1] who examined twelve cadavers that came to necropsy in from two to three weeks after injection, states that in every case of subcutaneous or intramuscular injection of salvarsan, no matter in what dilution or dose, extensive and complete necrosis involving all tissues (connective tissue, adipose tissue, muscles, vessels, and nerves) coming in contact with the drug is observed in the region of injection. This tissue necrosis favors retention (deposition) of the chemical, but, owing to the thrombosis of the vessels in the region, it probably also in no slight

[1] Münch. med. Woch., 1910, p. 2769.

degree inhibits general intoxication from absorption of arsenical derivatives. The necrotic tissue may be thrown off as sequestra, in which arsenic can be demonstrated after several months. The necrotic focus not infrequently becomes infected, either from the blood (*e.g.*, in angina) or by local invasion or contamination of the injected solution, resulting in the formation of large abscesses filled with yellowish-green pus and necrotic shreds, which, when situated deep in the musculature, may easily be overlooked. In the gluteal region infection (streptococcic) thus established may be followed by thrombosis of the iliac and femoral veins and fatal pulmonary embolism.

Intragluteal injection may be attended also by disturbances or injury to the sciatic nerve and its branches, lasting for days or weeks, manifested by radiating pains, violent and persisting colonic and vesical tenesmus, dysuria, retention of urine, constipation, severe paralysis of the leg with atrophy of the muscles (reaction of degeneration), all probably due to local (necrotic) involvement and not to neuropathic action.

Acute nephritis, attended by necrosis of the epithelia of the convoluted tubules, and transitory albuminuria and even hematuria have been recorded.

Ingersheimer[1] has shown by animal experimentation that a large amount of arsenic is found in the eye, and this he explains upon the assumption of an especial affinity of the preparation for this organ. Arsenic is found also in the urine of human subjects in about ten minutes after injection.

Valvular and other lesions of the heart, pulmonary tuberculosis, tabes, chronic nephritis, etc., are conditions in which administration of the preparation is dangerous. There is also an idiosyncrasy to salvarsan.

Of the fatal cases recorded,[2] one was by Ehrlich himself credited directly to the action of the remedy. Martius reports a case with valvular lesions in which death occurred in five hours after injection of 0.5 Gm., and Willige describes a case that died three and a half hours after injection, death being preceded by vomiting, intestinal colic, and fluttering pulse. At necropsy hyperemia of the organs was found, and arsenic was demonstrated in the blood and all organs; arsenical poisoning was diagnosticated.

The Wassermann reaction may or may not disappear after injection.

While the numerous more or less severe toxic effects, such as atrophy and inflammation of various nerves (optic, facial, auditory, abducens, sciatic), diminution or abolishment of certain reflexes, gastrointestinal disturbances, etc., reported as occurring weeks and months after the use of

[1] Münch. med. Woch., 1910, p. 2674.
[2] These are very numerous.

arsenobenzol have not with certainty been traced to the new remedy, it is equally uncertain that they were not due to its action. According to E. Finger,[1] these by-effects appear about five months after injection of the remedy. Sir Jonathan Hutchinson has drawn attention to the possibility of salvarsan giving rise to arsenical cancer.

The disadvantages (necrosis, abscess formation, paralyses, etc.) attending subcutaneous and intramuscular injection are said to be overcome by intravenous injection. Aside from the difficulties and dangers ordinarily attending this method of administration, it unquestionably is the most rational, because it enables accurate dosage; action takes place at once; there are no depôts established for retention of arsenical derivatives, which later may be absorbed with toxic effect, and excretion of the drug is rapidly effected.

As continued exposure to the air results in the formation of toxic oxidation derivatives which cause the toxic effects, it is important that the glass containers be free from flaws admitting even minute amounts of air; the powder should be unaltered in appearance and in a finely divided state, and collect in small masses (balls) only after opening the container.

Experimental investigations made by Meissner[2] indicate that injections of acid salvarsan cause coagulation of the blood and thus lead to occlusion of the pulmonary arteries. When salvarsan was added to horse or ox serum a dense, white, flocculent precipitate occurred. This was not observed when salvarsan rendered alkaline by sodium hydrate was used; the serum retained its golden-yellow color and normal consistency. These tests apparently demonstrate that the severe pulmonary disturbances observed after injection of salvarsan into animals are due to the precipitant action of the chemical. Experiments were undertaken also to determine the nature of the precipitate: 5 c.c. of ox serum were diluted with water, and a solution of 0.15 Gm. of salvarsan in 40 c.c. of water added. The centrifugated precipitate treated by the Kjeldahl method showed after distillation 0.0284 Gm. of nitrogen, corresponding to 0.1775 Gm. of proteid. The same amount of the same serum without addition of salvarsan contained 0.3159 Gm. of proteid. Therefore, about one-half of the proteid in the ox serum had been precipitated by the salvarsan. The precipitate was insoluble in water or physiologic salt solution, *i.e.*, consisted of denatured proteid.

These investigations seem to indicate that in man also the fatal action of acid salvarsan is due to thrombosis of the pulmonary arteries and the sequelæ. At all events, the anatomic alterations found in the lungs of animals corresponded with those recently observed in a man dead in Hamburg after an injection of acid salvarsan. Ehrlich's report of the necropsy findings in this case is as follows:—

"The left pleura shows, principally over the lower lobe, moderately thick, discolored, greenish-gray, easily detachable deposits. In addition there are upon the pleura a number of hard, yellowish, pinhead-sized nodules surrounded by a delicate red areola. The lung is greatly increased in volume. The upper lobe and the

[1] Wien. klin. Woch., 1911, No. 2, p. 65.
[2] Deutsch. med. Woch., March 16, 1911, p. 491.

upper half of the lower lobe are everywhere crepitant; this is entirely absent in the lower half of the lower lobe, which is dense on palpation. Upon the cut surface appears a very succulent, gray-red tissue containing a slight amount of air. Otherwise the lung contains a good amount of air.

"The right pleura shows a small amount of gray, fibrinous deposit; otherwise it is smooth and glistening. Upper and middle lobes present the features of the first upper lobe. The lower lobe feels hard; no crepitation. Incision shows an airless, dirty red, finely granular tissue, which the finger readily penetrates. An abundance of brownish-red, not foamy fluid is discharged upon pressure. The bronchial mucosa on both sides is slightly reddened; the lymph-vessels are not involved."

Meissner strongly emphasizes that salvarsan should be rendered decidedly alkaline. According to him, 1 Gm. of salvarsan requires for neutralization (indicator phenolphthalein) 4.4 c.c. of normal sodium hydrate. The precipitate which forms dissolves only in an excess of sodium hydrate, usually about 6 c.c. additional being necessary.

Secale cornutum, ergotin (the toxic constituents are sphacelinic acid and cornutin), ergot of rye, produces formication in the limbs (ergotism), deafness, and coldness of the fingers and toes, and sometimes in chronic cases (*ergotismus spasmodicus, gangrænosus*) gangrenous necrosis of peripheral parts (tips of fingers, ears, tip of nose, etc.), without disease of the arteries, caused by spasm of the smooth musculature and consequent intense, persistent ischemia. Intestinal ulceration and symptoms of degenerative changes in the nervous system (tabes) occasionally occur.

III. In the third great group, of poisons which produce no distinct and characteristic organic changes, belong, first of all, the so-called **nerve** and **cardiac poisons.** These give rise principally to manifestations of irritation or paralysis. To the poisons which may cause death by paralysis of the central nervous system belong alcohol (C_2H_5OH), ether ($C_2H_5OC_2H_5$), chloroform ($CHCl_3$), nitrous oxide gas (laughing gas, N_2O), chloral hydrate, opium, morphine, cocaine, strychnine, aconitine, atropine, nicotine, quinine, digitalin, muscarine, colchicine, veratrine, and others.

Alcohol acts as an irritant when employed locally upon mucous membranes; internally, it may produce manifestations of acute poisoning (intoxication). After a brief stage of excitation, a stage of depression with dilation of the vessels follows. As a rule, headache is present. Sometimes death occurs with loss of consciousness, coma, slowing of respiration, and cyanosis, and sometimes quite suddenly (apoplectiform).

Chronic consumption of alcohol in excess favors obesity, and causes catarrh of the air passages, insomnia, state of terror, muscular tremors, delirium tremens, cirrhosis of the kidneys and liver, induration of the myocardium, degeneration of the vessels, and alteration in the ganglion cells of the retina.

Ether may cause death under signs of active hyperemia and hemorrhage of the small bronchi and mild hemorrhagic conditions of the lungs, often not until some time after its action. In other cases (in narcosis) death occurs rapidly during administration (in which case latent renal disease probably is present). Chronic abuse of ether produces phenomena similar to those observed in chronic alcoholism. Employed locally it causes, by rapid evaporation, decided cooling with anemia and suspension of sensation.

Chloroform acts as a local irritant upon mucous membranes; its internal action causes death by paralysis of the central nervous system. Anatomic findings are negative.

As anesthetics (ether, chloroform, ethyl bromide) affect consciousness and sensibility earlier than motility and reflexes, a different resistance of different portions of the nerve-centers has been assumed, in that first the brain is affected, then the spinal cord, and last the medulla oblongata.

Noteworthy is the unusual tolerance to poisons, a sort of acquired immunity to certain toxic substances repeatedly introduced into the body, called also from an old historical example, **mithridatism.**[1] Examples are the tolerance to alcohol and tobacco, which may be increased to apparently complete suspension of the toxic reaction to large doses. The cause of this tolerance for poison is very difficult to explain. In contrast to bacterial immunity and the effect of bacterial toxins, the chemic poisons, so far as is now known, possess no ability to excite the formation of antibodies which suspend or neutralize the toxic action. A certain analogy with the bacterial immunity acquired by some exists in arsenic poisoning only in so far as arsenic eaters (men and animals) acquire immunity only for the ordinary mode of introduction of the poison and arsenious acid in substance, but die after subcutaneous injection of much smaller doses. In the acquisition of tolerance to alcohol and morphine, it may be assumed that the organs acquire an increased ability to destroy these substances.

Opium is the inspissated juice obtained by incision of the unripe capsules of *Papaver somniferum.* The most active of the alkaloids of opium is morphine, isolated by Sertürner, in 1805. Poisonings occur in children who chew the plant (also *Papaver rhœas*); also through the pernicious habit of administering by unscrupulous adults of decoctions of the capsules to infants as a soothing potion. Children under 5 years of age are very susceptible to the action of opium poison and die in convulsions. In adults suicide by morphine is not infrequent: convulsions occur in adults only in exceptional instances. Characteristic of morphine poisoning is that vomiting and diarrhea are usually absent. The most important symptoms are: slowing of the pulse and respiration, marked contraction of the pupils, somnolence, insensibility, and general paralysis, finally also of the respiratory center. As the heart beats for some time after cessation of respiration, poisoned persons have been resuscitated by prolonged artificial respiration. Atropine in doses of 1 mg., administered at most three times in succession, has proved effective as an antidote.

[1] Mithridates VI or the Great, *circa* 120 B. C., a king of Pontus and Bithynia, was credited with such protection, acquired intentionally as a preventive against poisoning by his enemies.

Cocaine, which is used chiefly in the form of the hydrochlorate,[1] is an alkaloid obtained from the leaves of *Erythroxylon coca.* Externally it should be employed at most in 3 per cent. solution, and subcutaneously in not more than 0.02 Gm. at a dose. One gram is usually a lethal dose, though permissible maximal doses have produced alarming symptoms. Spinal cocainization, *i.e.,* subdural injection of cocaine for anesthetization of the lower portion of the body, is almost obsolete. The toxic symptoms produced by cocaine are very variable. Sometimes excitation occurs (cocaine delirium, cardiac palpitation, anxious state, epileptiform convulsions); chiefly, however, paralysis (syncope, unconsciousness, even paralysis of respiration). Dilation of the pupils associated with rigidity and a sensation of dryness of the throat is characteristic of cocaine poisoning.

Chronic cocaine poisoning, or so-called **cocainism,** occurs in victims of the morphine habit who employ cocaine as a substitute or in addition to morphine injections. The symptoms are emaciation which terminates in marasmus. Aside from mydriasis (in morphine habitués: miosis), a paranoid, hallucinatory psychosis, persecution mania, abnormal sensations, etc., are characteristic, especially of pure cocaine habitués. In pure cocaine victims cocaine can be withdrawn at once

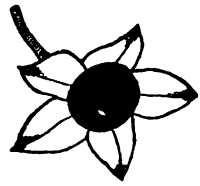

Fig. 126.—Atropa belladonna (nightshade). About ⅔ natural size.

without injury; in morphine-cocaine habitués, however, the cocaine administration can soon be suspended, but the morphine only slowly withdrawn.

Strychnine, which is employed in the form of strychnia sulphate, is an alkaloid derived from the seed of *Strychnos nux vomica,* a tree of India. It is technically used in the poisoning of animals (rats, dogs). Toxic effects have been produced by its use in suicide, murder, and as an abortifacient. Medicinal poisoning with strychnine through mistakes and from repeated employment as a result of cumulative action has been observed. The lethal dose is 0.03 Gm.; for children, 0.004 Gm. Typic of strychnine poisoning are the (tonic) tetanic spasms occurring at intervals of about a minute and with preservation of consciousness. Protrusion of the eyeballs and mydriasis are present. Vomiting is rare; the name "vomic nut" for *Strychnos nux vomica* is, therefore, somewhat misapplied. Death usually occurs by paralysis of respiration during the acme of a paroxysm. Necropsy shows very little that is characteristic. Rigor mortis occurs with surprising rapidity and persists for days. Antidotes are chloroform inhalations and adrenalin, though the efficacy of the latter has recently been questioned.

Atropine, the active substance of *Atropa belladonna,* deadly nightshade, is a white, bitter, intensely poisonous alkaloid. The symptoms produced by its action are diminution of secretion, transpiration and intestinal peristalsis; marked dilation of the pupils, due to paralysis of the nerve-endings of the oculomotor nerve in

[1] It was introduced into ophthalmology by Koller, in 1884, for anesthetization of the cornea, and since then has otherwise been employed as a local anesthetic.

the iris; photopsia, violent headache, erythema of the body and face, enormous rapidity of the pulse, hallucinations, and delirium. Death is observed in 10 per cent. of the cases. Recovery generally occurs after a quiet sleep. Dilation of the pupils persists for some time. A good antidote is morphine (except in children under 5 years of age!) subcutaneously. A case of poisoning in a girl has recently been reported, due to ingestion of strawberries which had been enveloped in belladonna leaves, the juice of the partly crushed leaves and probably also portions of the leaves themselves being combined with the berries.

Nicotine poisoning. Tobacco: Chronic nicotine[1] poisoning is manifested by trembling of the hands, pallor of the face, emaciation from hypersecretion of gastric juice and saliva, cardiac disturbances from degeneration of the myocardium, and especially disturbances of vision, due to alterations in the ganglion cells of the retina. Ordinary newspaper print soon becomes illegible; vision for colors is markedly obtunded. The pupils are contracted, unequal, and react sluggishly. That chemic irritation of tobacco poison plays a rôle in the etiology of carcinoma of the lip has frequently been asserted.[2] Recently carcinoma of the tongue has also been stated as sometimes due to irritation from tobacco. The descendants of workers in tobacco and strong smokers are frequently degenerates.[3] In Holland nicotinism is very prevalent, owing, it is said, to the very low cost of tobacco. Acute nicotine poisoning has occurred after tobacco enemata and admixture of tobacco with the food.

Quinine, *quinia,* is an alkaloid obtained from cinchona bark (Jesuit's bark). There are persons who possess enormous idiosyncrasy to this drug. Vomiting is usually frequent; tinnitus aurium and disturbances of vision occur and also internal and external hemorrhages. Such hemorrhages, which occurred after two doses of ½ gram each of the hydrochlorate and terminated fatally, have recently been reported.[4] Quinia idiosyncrasy and even fever may occur also after protracted administration. Quinia also inhibits the ameboid movements of the white blood-corpuscles.

Foxglove, *Digitalis purpurea,* contains various poisons which are comprised under the collective name of d i g i t a l i n. Poisoning occurs usually as a result of cumulative action of therapeutic doses. In the beginning of poisoning there is repeated vomiting of grass-green matter. In the primary stage no action is exerted upon the heart. Digitalin so stimulates the terminations of the vagus nerve—which inhibits the heart's movements—that the pulse becomes arrhythmicly more and more slowed, and finally even cardiac action may be arrested. A noteworthy symptom of digitalis poisoning is green and yellow vision. In contrast to many other poisonings, digitalis poisoning usually extends over a number of days. In the treatment absolute rest in bed and interdiction of all unnecessary movements on the part of the patient are to be observed. The best prophylaxis is the avoidance of digitalis treatment except as a last resort.

Fly fungus, fly agaric, *Amanita muscaria.* The dried and hence less toxic plant is eaten by various Siberian tribes to produce inebriation. The boiled and therefore partly or entirely nontoxic fungus is eaten in southern France and northern Russia. Drunken delirium is typical of this form of poisoning. The cause of the poisoning is frequently confusion with the edible *Amanita cæsarea.*

---

[1] Named after Jean Nicot, who introduced tobacco into Europe about 1560.
[2] See footnote, page 273.
[3] Münch. med. Woch., 1909, No. 21, p. 1093.
[4] *Ibid.,* 1910, No. 45, p. 2319.

Amanita bulbosa s. phalloides (Fig. 127), white agaric. Long incubation of the poison: ten hours or more. About 70 per cent. of the cases end in death, generally on the second or third day. Necropsy shows, among other findings, marked fatty change in the liver, kidneys, myocardium, and musculature. Convalescence usually is protracted.

Helvella esculenta is the cause of morel poisoning. The poisoning is due to eating unboiled helvellæ. Helvellæ which have been only broiled and even morel soup have caused fatal poisoning. Therefore, when morels are to be eaten the poisonous water in which they were boiled should be poured off. The first symptoms of poisoning occur at the earliest within four hours after ingestion. The poison, so-called helvellic acid, dissolves the red blood-corpuscles, as a

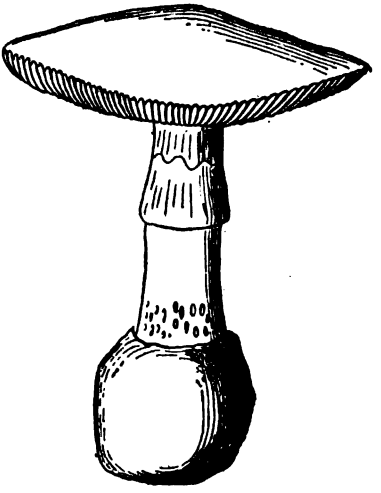

Fig. 127.—Amanita bulbosa. About ½ natural size.

result of which icterus is the most conspicuous manifestation. Pathologicly, hemorrhages are found in the body cavities and marked degeneration of the liver.

Morchella esculenta, nearly related to *H. esculenta,* is regarded with suspicion.

Meadow saffron (*Colchicum autumnale*). The plant and seeds contain the alkaloid colchicum. Children are often poisoned by eating the seeds, which are rich in colchicine. Colchicum is one of the most dreadful vegetable poisons; in Germany the mortality is 90 per cent., the highest of all poisonous plants. The symptoms are very violent and consciousness usually is preserved to the end. The plant generally kills within twenty-four hours, which fact is emphasized by the ancient Greeks in the name ephemeron.

Artemisia absinthium, vermuth. Among alcoholic subjects, the frequency of epilepsy in absinthe drinkers is attributed to the vermuth in the absinthe.

Aspidium felix mas, male fern. Poisoning with this agent may produce the severest symptoms. The chief effects are solution of the red blood-corpuscles and alterations of the fundus oculi, which occasionally may result in permanent blindness. Fatal cases have been recorded.

Cicuta virosa s. aquatica, water hemlock, poison turnip. The rhizome contains a yellow, malodorous juice the active principle of which is

cicutoxin. Epileptiform convulsions are the chief toxic symptoms. The mortality is about 45 per cent.

Hyoscyamus niger, henbane, poison tobacco, stinking nightshade, contains hyoscyamin and scopolamin. The symptoms of poisoning are similar to those of belladonna (*q.v.*).

Juniperus sabina, common savin, cover-shame. The young twigs are used in decoction as an abortifacient, but not always with success and often with ill-effects upon the mother. The active constituent is an ethereal oil. Severe action is exerted upon the kidneys, and profuse uterine hemorrhages occur.

Lolium temulentum, cockgrass, darnel. A fungus lives in the seed and renders the latter poisonous. Eating of bread to which meal containing the fungus has been added almost always causes trembling of the tongue and limbs. In other respects the toxic symptoms resemble those observed in atropine poisoning. In recent years this form of poisoning has become very rare.

Solanum tuberosum, potato. The unripe, frozen, partly decayed, and greenish discolored tubers and perhaps also the water in which unpared potatoes have been boiled are poisonous.

Croton oil is obtained from the seeds of *Croton tiglium.* These seeds contain, in addition to the poisonous oil, a toxic albuminous body. Four seeds, or twenty drops of the oil, suffice to kill an adult. Internally it produces gastroenteritis, and its external application has resulted in phlegmonous inflammation.

Physostigmine, or **eserine,** is an alkaloid derived from the seeds of Calabar bean—a species of physostigma. It is generally employed in the form of the salicylate. It is sometimes employed in ophthalmology (as a miotic) and is known for its disagreeable by-effects. It should be administered with caution.

Pilocarpine, usually administered in the form of the hydrochlorate, is obtained from the leaves of *P. jaborandi* and *selloanus.* It acts like nicotine, as a cardiac poison and a miotic. It markedly stimulates secretion (profuse perspiration, salivation, strangury); in the bronchi the mucus may accumulate to such a degree that it cannot be expectorated and suffocation results. Atropine is antidotal.

Santonin. Intoxication with this drug has occurred after careless administration, prolonged use, and in persons possessing an idiosyncrasy. The chief symptoms are convulsions and chromopsia, principally yellow vision.

Strophanthin, a glucosid from the seed of species of strophanthus, is, like digitalis, a heart poison. As it subsequently affects the kidneys its use should be exceptional.

Conium maculatum, poison hemlock, spotted parsley. The cause of poisoning is usually confusion with edible plants. The active substance is an alkaloid: coniine. The typical symptoms are burning in the throat, ascending paralysis, finally paralysis of the respiratory center. Consciousness usually remains clear to the end.

Daturia stramonium, thorn-apple, Jimson weed, stinkweed. The plant contains scopolamine, atropine, and hyoscyamine. The toxic symptoms are similar to those observed in belladonna poisoning (*q. v.*).

Still to be mentioned is a group of poisons which correspond in so far as they are toxic decomposition products formed from proteid bodies by the action of bacteria. This is the case in vegetable (*sitotoxismus*), fish, meat (*kreatoxismus*), sausage, and cheese

(*tyrotoxismus*) poisonings. The poisonous products are designated as toxic cadaveric alkaloids, ptomaines, toxins, toxalbumins, and toxenzymes. In their action some of them resemble the vegetable alkaloids, and some of them manifest the action of ferments. In cases in which death occurs there is usually present, in addition to evidence of irritation of the gastrointestinal canal (vomiting, diarrhea), only cloudy swelling of the heart muscle and of the large glandular organs.

Toxins and **toxalbumins** are amorphous colloidal, more or less thermolabile products of cellular activity which are not characterized by definite chemic properties or constitution, but solely by their physiologic reactions. The supposition that they are toxic albumin bodies has thus far not been established. Toxins produced naturally by the animal body are frequently and perhaps always mixtures of substances differing in action, as is true, according to Ehrlich, also of diphtheria toxin and other bacterial toxins.

Putrefactive toxins are substances elaborated by micro-organisms, *i.e.*, either during the metabolism of these forms of life or in the process of decomposition produced by them in their nutrient media. A chemicly well-characterized group of putrefactive substances are basic bodies. *Sepsin*, derived from decomposed yeast, and other substances discovered by Selmi and Brieger and others belong to the group of bodies designated by Selmi as ptomaines or cadaveric alkaloids, *i.e.*, to the series of amines, diamines, and ammonium bases. Some of these substances, e.g., *cadaverin* (pentamethylendiamin) and *putrescin* (tetramethylendiamin), are nontoxic; only a small number, such as neurin, muscarin, and mydalein, belong to the strongly active poisons. It cannot be said which of these substances play a rôle in intoxication with putrefactive substances. Sepsin, according to the bacteriologic investigations of E. Levy, seems to be a product of Hauser's proteus bacillus; according to Faust, it is a dioxycadaverin.

The phenomena resembling the symptoms of cholera or of acute arsenic poisoning present in sepsin poisoning in animals render it probable that choleriform food poisonings are due to sepsin or an allied toxin. The pathogenesis of these intoxications is still obscure.

The poisonings observed after ingestion of "tainted" meat, sausage, fish, cheese, and vegetables may be placed in three groups. The toxic phenomena occur rapidly, because the poison enters the body in sufficient amount preformed.

1. The first group of meat poisonings is produced by the flesh of animals which, before slaughtering, suffered from pyemic or analogous purulent affections, or from enteric disease produced by so-called en-

teritis bacteria, the first of which to be accurately studied was the *Bacillus enteritidis* (Gärtner). Here, however, the process is not simply the transference of bacteria, but also incorporation of thermostabile toxins. In other cases the toxin of the bacilli demonstrated in sausage is destroyed by heat. The enteritis bacteria in question belong to the typhoid and coli group of bacilli. Some of them resemble the *Bacillus paratyphoid-B* and Löffler's mouse-typhoid; others, to which Gärtner's bacillus belongs, are related to the typhoid bacillus.

2. The second group of meat poisonings is due to micro-organisms which enter the flesh after death of the animal. Pronounced putrefaction need not be present. Here, in addition to intoxication, infection also exists, whether with the proteus or colon bacillus. In these two forms the toxic effects are manifested essentially by violent gastrointestinal disturbances (diarrhea, colic, vomiting) which sometimes terminate fatally.

3. The third group of meat poisonings is a severe and often fatal disease state which represents a pure intoxication, and is observed after ingestion of "decomposed" sausage, ham, fish, and even vegetables. The poisoning, called "botulism," is due to a strong, thermolabile neurotoxin (botulin, ptomatropin), elaborated by the *Bacillus botulinus* (van Ermengem), and which attacks the nerve-centers. The bacillus and its toxin may be present in food which appears entirely unaltered or sometimes has an odor of butyric acid—the product of numerous anaërobes. In experiment animals (cats), as in man, there are ocular disturbances (ptosis, mydriasis; in man demonstrable paralysis of accommodation and diplopia), then paralysis of deglutition, paralysis of the vocal cords and of the extremities. Death follows under bulbar symptoms. Anatomicly, aside from hyperemia of the organs, alterations in the ganglion cells of the central organs have been described. Botulism is a pure bacterial intoxication, for the bacteria do not increase in the body of the victim; it, therefore, resembles tetanus.

Autointoxication. — The domain of autointoxication is essentially chemic. By some authorities autointoxication is regarded as due to retention—resorption—of normal or abnormal metabolic products which should be eliminated. The precision of this definition, however, has been somewhat invalidated by the failure of many sharply to distinguish between toxic intermediate or end products, originating during chemic processes occurring within the cells and tissues, and toxic bodies formed within the organism by the action of micro-organisms and animal parasites. For example, the effects of the toxins produced in intestinal putrefaction or in decomposition of the urine in the bladder solely by bacterial influence, and frequently also the still hypothetic toxins of

intestinal worms (bothriocephalus, ankylostomum), are almost universally classed with the autointoxications, while the toxins elaborated by pathogenic schizomycetes are relegated to another domain of pathology.

Disturbance (alteration, diminution, or lack) of function of certain secretory or excretory organs and occlusion of excretory ducts resulting in retention and absorption of secretion lead to accumulation of toxic metabolic substances and to corresponding sequelæ. The kidneys, liver, suprarenals, thyroid gland, etc., serve for the removal or excretion of poisons or elaboration of substances necessary for the performance of normal function. Uremia and diabetic coma unquestionably are forms of poisoning, and the cachexia of cholemia, myxedema, and malignant tumors may likewise be classed here. An excellent example of autointoxication is tetany, an affection characterized by intermittent spasms of the muscles of the upper extremities, and referred to disturbance in the parathyroids (*tetania parathyreopriva*), dilation of the stomach, etc. Many other affections (chlorosis, pernicious anemia, etc.) are interpreted as intoxications. As regards Basedow's disease, the negative pathologicoanatomic findings indicate a functional, nervous, or chemic origin, probably the latter. The suprarenals must exert a function of a chemic nature, since their destruction or extirpation leads to autointoxication.

By rapid and abundant disintegration of body substances, particularly of albumin, combustion of the acid intermediate products of metabolism does not occur; these flood the tissues and blood, and cause an acid intoxication: acidosis.

Besides the well-known products of metabolism, such as carbon dioxide, biliary acids, ammonia, carbaminic acid, oxalic acid, sulphureted hydrogen, which under certain circumstances are toxic, many others, such as acetone; diacetic, lactic, and oxybutyric acid; cholin; the phenols and toxins formed in intestinal putrefaction, etc., are brought into relation with autointoxication; also such as are assumed or supposed to exist in the urine or blood-plasma of patients, as indicated by toxic effects produced in experiment animals.

That abnormal acid formation in metabolism, whether oxybutyric, lactic or another acid, in the form of general acidosis, may cause severe autointoxication can, according to recent investigations, no longer be doubted. On the other hand, it is questionable whether acetone is of any importance in this respect.

In ammoniemia (ammoniacal fermentation of urine in the bladder), cholemia (*icterus gravis*), and uremia the toxic effects of ammonia, of the biliary constituents, and of the waste products of metabolism normally excreted through the kidneys play a more or less

decided rôle, but they by no means suffice to cause all the phenomena manifested in these intoxications.

The occurrence of cholin in the blood and in the cerebrospinal fluid in affections of the nervous system has recently been investigated by various authors. A positive finding is by some regarded as a result of pathologic disintegration of nerve substance (lecithin, etc.) and as of diagnostic significance. On the other hand, the possibility of auto-intoxication by the continued action of cholin has also been emphasized. The toxicity of cholin, as is known, is slight. Recent investigations confirm that it is not demonstrable unaltered in the urine after ingestion of relatively large amounts, and that it is decomposed in normal metabolism.

Uremia.—The nature of this form of autointoxication, which is due to insufficient excretion of the substances eliminated by the kidneys, is still obscure. It is not known whether the symptoms are due to retention of the normal urinary constituents or to abnormal products produced in the nephritic process. Uremic intestinal diphtheria, the uremic pericarditis, and the increase of blood-pressure and cardiac hypertrophy are referred to the action of the toxic substances.

Affection of both kidneys, as in chronic nephritis, causes various disturbances. Those substances which should be eliminated are not excreted by the kidneys; some are retained within the body and produce toxic action: autointoxication. This retention of urinary constituents in the blood is called "uremia." All these toxic substances are conveyed with the blood to the organs and undoubtedly injure the nutrition of the cells (protoplasmic poison). The more chronic the disease, the more anemic the patient becomes; the coexistent emaciation is usually somewhat obscured by the edema that is present. The toxins mixed with the blood exert an action upon the brain—cortex (convulsions, etc., true uremia); upon the eye (retinitis albuminurica) and the vascular system. The protracted contraction of the arteries (hard, tense pulse), likewise a toxic effect, causes hypertrophy of the left ventricle and further circulatory disturbances.

Eclampsia gravidarum is by some regarded as uremia. Since, however, nephritis may sometimes be absent and certain alterations occur in eclamptics (necrotic hemorrhagic foci in the liver with capillary thrombosis) which are lacking in uremia, it is generally regarded as a peculiar form of autointoxication of pregnant women, the origin of which is referred to the placenta and is favorably influenced by interruption of pregnancy. The hyperemesis observed in many gravid females also is accepted as of toxic origin.

An ingenious explanation has been offered by Dienst,[1] according to which eclampsia is an affection produced by fibrin ferment; and nephritis of pregnancy and

[1] Arch. f. Gyn., 1910, Bd. 90, H. 3.

even the hydropsic states without albuminuria in pregnancy are to be regarded as in a measure precursors, prestadia, of eclampsia. Not only in nephritis of pregnancy, but also in eclampsia, he was able constantly to find many multinucleated, *i.e.*, old, leucocytes in the blood; in still greater numbers during labor and most abundantly after parturition. In nephritis of pregnancy these leucocytes gradually and slowly decrease in number a few days after parturition. The severity of the clinic symptoms goes parallel to the number of these multinucleated leucocytes. The difference between the nephritis of pregnancy and eclampsia is essentially that in eclampsia a quite sudden increase in the number of these leucocytes occurs during the uterine contractions and often not until just after parturition (puerperal eclampsia), and that with occurrence of convulsions an equally rapid diminution of the multinucleated cells takes place within a few hours, which indicates a marked production of fibrinogen and fibrin-ferment. The available protective substances within the body are sufficient to combat this sudden, great augmentation of multinucleated leucocytes and their products of disintegration—the liberated fibrin-ferment—and consequently there form in the smaller vessels numerous thromboses, which, by offering great resistance to the circulation, cause fluctuations in the cerebral pressure and thus excite convulsions. The accumulation of multinucleated leucocytes in eclampsia is referred to venous congestion of the small pelvis and the lower extremities during pregnancy. This must be particularly marked in those cases in which eclampsia occurs. By the uterine contractions and diminution in the size of the uterus, this pressure is quite suddenly suspended, and the abundant entrance of leucocytes into the general circulation is thus explained. In addition to this pressure, it is assumed that a congenital idiopathic hyperleucocytosis exists in subjects who subsequently develop eclampsia, as well as in nephritis of pregnancy and in the hydropsic states of pregnancy. (See p. 324.)

Gout, *arthritis uratica s. urica,* is generally regarded as a manifestation of so-called uric acid diathesis: accumulation of uric acid in the juices of the body. This accumulation may occur as the result of increased formation as well as from diminished excretion. While the chief symptoms are usually limited to the joints, the process may involve the internal organs, especially the kidneys. In about 50 per cent. of the cases there is a hereditary history. Chronic lead poisoning is said to be a frequent cause. Deposits of uric acid occur in the renal epithelia; these are followed by contraction of the cortical interstitial connective tissue, which may result in contracted (so-called gouty) kidney. Hypertrophy and dilation are observed in the heart. Garrod regards gout as the result of diminished excretion of uric acid; that the kidneys, even in the earliest stages, functionate defectively, and, hence, uric acid accumulates in the blood. When this reaches a certain degree, separation, first of fluid, later of crystalline urates, occurs under the influence of slight causes, *e.g.*, cold, trauma, etc., and thus gout is established. This theory has found wide acceptance, but presents certain points of weakness, chief of which is the assumption of primary renal insufficiency. Ebstein believes the locality of increased uric acid formation is in the muscles, and especially in the

bone-marrow, whence it is conveyed to the general circulation through the narrow channels of the cartilage; in these channels congestion may readily occur and result in deposition of soluble neutral urates in the cartilage which cause acute inflammation. Necrotic foci originate in the affected cartilage, and in these localities, under the influence of the acid reaction of the dead tissues, crystalline urates are deposited. Ebstein admits Garrod's hypothesis only for primary renal gout. Pfeiffer is of the opinion that the uric acid in gouty subjects circulates in a readily precipitable form (designated by him as "free acid"), and, therefore, deposition of its salts in the joints, as well as the formation of tophi without inflammation, occurs in regions in which local necrotic foci have resulted from trauma. If a sudden increase of the alkalinity of the juices now occurs, part of the deposited uric acid is dissolved and the uric acid going into solution produces the inflammatory process. Pfeiffer supports his view on the basis of observation of the uric acid in the urine of gouty subjects and on the fact that the use of alkaline mineral waters is sometimes followed by attacks of gout.

The occurrence of toxic metabolic products in the **urine** of normal and diseased individuals may also be considered in connection with autointoxication. It has been found that the urine of healthy and diseased persons, when injected intravenously into animals, is more or less toxic. The toxicity of the urine in various diseases has been studied particularly by the French and designated as the urotoxic coefficient (Bouchard). These investigators, however, were unable to isolate any definite toxin from the urine. From the urine of healthy women there has recently been obtained in pure form and analyzed a number of more or less toxic bases (methylguanidin, novain, reductionovain, gynesin, mingin, vitiatin). According to their constitution, novain and reductionovain resemble cholin; methylguanidin and vitiatin resemble kreatin. Very little is known regarding their toxicity and mode of action.

Diabetes.—It is assumed that from the normal pancreas by an "internal secretion" a substance enters the body which is necessary for the assimilation of the sugar in the liver and muscles, and the absence of which leads to accumulation of sugar in the blood and to its excretion with the urine.[1] Besides, there often occur in the blood and urine an abundance of acetone and acetoacetic acid; to these, as well as to β-oxybutyric acid, are attributed the development of nervous disturbances, cephalalgia, "neuritic" phenomena (nerve degeneration), neu-

[1] The theory of an internal secretion of the pancreas is thus far an unproved hypothesis. The absence of diabetes in spite of total destruction of the pancreas and its occurrence in spite of complete preservation of this gland render it probable that carbohydrate metabolism is regulated not by a hypothetic product of internal secretion, but by a nervous mechanism.

ralgias, and, finally, the often fatal diabetic coma. The latter is frequently interpreted as an acid intoxication. These substances appear to have no distinct relation to the sugar excretion, because they do not regularly occur in experimental diabetes following pancreas extirpation. In man the pancreas is almost never entirely destroyed, and sometimes scarcely distinctly altered; alterations often found are simple or lipomatous atrophy, cirrhosis, sometimes calculous formation; by some authorities especial emphasis is laid upon destruction of the islands of Langerhans. There is no scientific basis for the assertion that the Jewish race is more liable to diabetes than other races.

Disturbances[1] of the secretion of the **ductless organs,** such as the suprarenals, ovaries, thyroid, parathyroids, pituitary gland, etc. The functional connection of certain of these glandular organs with other parts of the body has long been recognized for the genital sphere, but the nervous system was regarded as the agency in the correlation. It is now known that these glands elaborate a secretion and impart it to the body fluids, and that the disturbances of correlation resulting from their destruction cannot depend upon a nerve lesion, since the pathologic consequences are removable by transplantation of the glands and even by administration of their chemic substances in the form of juice, tablets, etc. (See Basedow's Disease.)

Recent investigations have thrown much light upon the subject of chemic interaction within the organism. While it was long ago shown that the liver continues and completes the chemic work of the intestinal juices, it has only lately been learned that functional excitation and stimulation to growth also are due to variously constituted chemic substances designated by Starling as **hormones** (ὁρμαω = excite). Although we are still far from a knowledge of the chemic agents and the nature of the impulse to cellular activity, certain observations have prepared the way to this information. An example of such "stimuli" is CO_2, which not only excites respiration in the newborn, but continuously maintains the function of the respiratory center. CO_2, therefore, is a specific irritant for the medulla oblongata. The secretory products of the intestinal canal, such as the secretion of bile and of the intestinal and pancreatic juices after entrance of the chyme into the duodenum, are not excited by nervous stimulus, but by a **"secretin"** elaborated by the intestinal mucosa which enters the blood and excites the glandular secretions in question. In the hypertrophy of the lacteal glands and the secretion of milk in pregnancy, there is no action of the genitalia with co-operation of the nervous system; for repeated injections of extract of rabbit feti into the body of virgin rabbits produce not only a hypertrophy of the mammary glands of these animals

[1] In regard to both diabetes and Addison's disease, general disturbance of the organism is usually absent when carcinoma has destroyed the substance of the pancreas or suprarenals respectively. According to Hansemann, it may be possible that the carcinoma-cells derived from the epithelia of either of these glands still preserve sufficient of the original peculiarities to enable them to fulfill the function of the mother-cells and thus to prevent the appearance of the general disturbances (diabetes, Addison's disease) which occur on destruction of these organs.

corresponding to the enlargement observed in pregnancy, but also a secretion of milk in the glands. Only embryonic tissue is capable of exerting such an effect upon the development of the genitalia. Perhaps the fact that some tumors in childhood (*e.g.*, teratomata of the pineal gland and others) may be accompanied by premature development of the genitalia can be explained in an analogous manner through the agency of "hormones" which originate in tumors with embryonal tissue (Askanazy).

The **suprarenals** are organs which may give rise to disturbances in organ correlation. Here may be mentioned the hypoplasia of the suprarenals in arrested development of the cerebrum (anencephalia, etc.). This hypoplasia of the suprarenals has been regarded only as defective development of the **chromaffin** elements of the medulla of the suprarenals, which belong to the sympathetic nervous system. In such suprarenals, however, the cortex also is hypoplastic. In the suprarenals we know the chemic nature of at least one of the secretory products (adrenalin), which is formed by the chromaffin tissue. It increases blood-pressure and is, perhaps, responsible for the preservation of the normal vascular tonus. Owing to the constancy of anatomic alterations (usually tuberculosis, rarer tumors, fibrosis) of the suprarenals in Addison's disease, the latter affection must be regarded as in some way cannected with the lesions of these glands: to atrophy of the chromaffin system. Sometimes the affection of the suprarenals is unilateral, the other gland being congenitally absent.

The term **chromaffin** is applied to cells which belong to the sympathetic nervous system, and are characterized by an affinity for chromic acid salts (yellow or yellowish-brown coloration in solutions of chromic acid salts). The term **phæochrome** (φαιος = blackish, brown) also is employed to designate this reaction. Chromaffin cells are found in the sympathetic, the suprarenals (medulla), carotid glands, coccygeal glands. As the medulla of the suprarenals is derived from the sympathetic, these glands, with the coccygeal and carotid glands, because of their content of chromaffin cells, nerve-fibers, and ganglion cells, are classed as "paraganglia." From the coccygeal and carotid glands, tumors may originate which contain chromaffin cells, in the carotids often wrongly designated as peritheliomata.

Alterations of the pineal gland are, perhaps, the cause of metabolic disturbances (local in general adipositas).

Extirpation of the **thyroid** produces a severe cachexia (*cachexia thyreopriva, strumipriva*) which embarrasses not only the body, but also the mental functions, resulting finally in death from marasmus. The sequelæ of thyroidectomy progress under symptoms of intoxication; toxicity of the blood of thyroidectomized animals has been observed.

The nature of the metabolic toxin which the thyroidectomized organism no longer is able to neutralize is unknown.

Very marked disturbances are produced also by hypertrophy of the thyroid, as in Basedow's disease (*q.v.*).

The influence of the sexual glands (ovaries, testes) upon different portions of the body and the psychic centers is well known: puberty, climacteric, aplasia; oöphorectomy, castration: eunuch, capon, ox. The ovary is said to possess an internal secretion produced by the lutein cells of the corpus luteum.

Gastrointestinal Autointoxication.—Great significance is attributed to this form of intoxication. It is regarded as due not only to pure endogenous metabolic products of fermentation in the digestive tract, but also to products of intestinal bacteria, because in decompositions in the intestine it is difficult to say how much is referable to certain disturbances in the activity of the intestinal enzymes, and how much to increased activity of the intestinal bacteria. On the other hand, the pathologic phenomena attributed to the activity of animal intestinal parasites should not be designated as autointoxication; the intestinal bacteria as such are physiologic and play a physiologic rôle in the chemism, but not the entozoa.

Many of the symptoms of gastric catarrh have been attributed to autointoxication. Here gastric dilation is to be borne in mind, which may produce phenomena of tetany in the absence of all signs of alteration in the parathyroids. Disturbances occur also as a result of retention of intestinal contents, especially in the ileum, which, as a rule, is quickly passed by the feces, the latter undergoing physiologic putrefaction only in the colon. Coprostasis in the small intestine, as occurs in atony, paralysis of the intestine (*e.g.*, in peritonitis), and in mechanic obstruction of the intestinal lumen, may have the most serious results. Here manifest alterations can be found in the urine (indicanuria, cystinuria), which are due to increased intestinal putrefaction and resorption of the putrefactive products.

Among the substances which may be resorbed in enterogenous autointoxication is to be mentioned SH_2, which can be demonstrated in the respired air and the urine. In cases of rapid death (one to two days) after occlusion of the intestine by a foreign body, *e.g.*, a large gall-stone, there is a tendency to speak of autointoxication. Also in the severe symptom-complex of acute peritonitis, autointoxication is assigned a rôle from paralysis of the intestine.

By many authorities sclerosis of the liver and kidneys is referred to resorption of toxic substances in chronic intestinal disturbances. There seems to be some foundation for the belief that many arterio-

sclerotic conditions are due to prolonged continuous influence of toxins absorbed from the intestinal tract. Although the liver is usually the organ most markedly involved (sclerosis), the toxins sooner or later pass this barrier and act upon other organs (*e.g.*, the kidneys), especially the arteries, the nutrition thus being impaired. The parenchyma is gradually and insidiously destroyed (parenchymatous degeneration), and slowly substituted by fibrous connective tissue.

Another source of disturbance is disease of the liver and biliary ducts. When discharge of the bile through the natural channels into the intestine is interfered with or when, owing to disease of the liver-cells, it is insufficiently excreted or secreted in false direction, *i.e.*, into the tissue-spaces (parapedesis), **icterus** occurs, *i.e.*, absorption of bile constituents into the blood (**cholemia**). Even in simple icterus these morbid admixtures may produce, aside from the abnormal discoloration, disturbances in the form of languor, increased exhaustion, pruritus, somnolence, slowing of the pulse. When the icterus is intense and chronic (*icterus gravis*, e.g., in carcinoma of the bile-ducts or the head of the pancreas), severe cerebral phenomena (coma) and so-called hemorrhagic diathesis occur, *i.e.*, a disposition to hemorrhages which often are difficult to arrest. This should be borne in mind in operations upon jaundiced patients, since such subjects may die from hemorrhage after a relatively uncomplicated gall-bladder operation. The substances which enter the circulation and produce this cholemia are bile-coloring matters: the biliary acid salts. Ammonia salts, leucin, and phenol also are to be considered in this autotoxic effect. The conditions are more complex when the liver itself is markedly diseased and no longer is able to perform its important synthetic and detoxicating function. Then an hepatogenous autointoxication may occur without icterus. In such chemic hepatic insufficiency the formation of urea and fixation of glycogen are affected. In rapid destruction of the liver-tissue (*e.g.*, in so-called acute yellow atrophy of the liver), there can be found in the urine, as well as upon the cut surface of the liver, chemic evidence (leucin, tyrosin) of disturbance of metabolism. In nonicteric atrophic hepatic cirrhosis, also similar terminal manifestations, may develop, clinically with appearance of delirium and coma. Furthermore, the toxic manifestations of icterus may be modified by the sequelæ of hepatic insufficiency.

ALTERATIONS CAUSED BY ANIMAL AND VEGETABLE ORGANISMS, INCLUDING THE INFECTIOUS DISEASES.

I. ALTERATIONS CAUSED BY ANIMAL PARASITES.

OWING to their nutritional requirements, the **animal parasites**[1] are assigned, either continuously or temporarily, during certain stages of their development, to a sojourn within or upon the bodies of other animals. Their relation to other animals is, therefore, one of nutritive dependence, in which respect they differ from pseudo- or false parasites (ova and larvæ of flies, earwigs, etc.), the residence of which in man is rather accidental (*e.g.*, in wounds).

Some of the parasites always remain upon the surface (**epizoa:** fleas, lice, hair-sac mite: steatozoön, or *Demodex folliculorum;* and **entozoa:** *Oxyuris vermicularis:* pin-worm; *Ascaris lumbricoides, ankylostoma,* and others); others enter the parenchyma of organs (**organozoa:** itch-mite: *Sarcoptes scabiei;* trichina, sand-flea: *Sarcopsylla penetrans;* filaria, cysticercus, echinococcus, etc.), and, finally, a few take up their abode principally in the blood (**hematozoa:** *Schistosomum hæmatobium, Hæmamœba malariæ*).

In southern regions, especially in the tropics, the number of animal parasites is considerably larger than in temperate countries, partly because of climatic conditions, but partly also on account of the lower state of civilization (insufficient cleanliness, consumption of raw food, deficient clothing, bad dwellings). Some parasites are dependent during the whole period of their existence upon the human body (*e.g.*, the mites: acarina); others (*e.g.*, teniæ) are able to complete within man only certain periods of development, and in order further to develop—*i.e.*, owing to conditions of nutrition—they must temporarily be transmitted to animals, especially domesticated animals. Others, for example,

[1] A parasite is an organism that inhabits another organism and obtains nourishment from it. It may be a phyto- (vegetable) parasite or a zoö- (animal) parasite; an ectoparasite (epizoön, epiphyte) or an endoparasite (entozoön, endophyte); occasional or constant; temporary or stationary; obligate or facultative; a true or a pseudo- parasite. Parasites that attain their full development upon or within a single host are said to be autecious or autoxenous; those that pass different stages of development upon or within different hosts are said to be heterecious or metecious. Accidental parasites are those which, though ordinarily not parasitic, have found entrance into the body. (Gould.)

the female of the sand-flea, seek the human body in order simply to deposit their ova. Many, like the trichina, possess the ability actively to penetrate the human tissues; others are less harmful and, at most, are passively transported to more important localities.

The behavior of the human organism toward these parasites is quite variable. Delicate persons, especially children, react very energeticly (convulsions) even to intestinal parasites which *per se* are harmless, while in others their presence is noted only incidentally. Many parasites produce very violent local alterations; others, according to the vital importance of the organ attacked, are sometimes dangerous, sometimes harmless; in the latter case they frequently remain unnoticed. For example, cysticerci of the arachnoid often remain undetected until necropsy, while in other localities, *e.g.*, in the large ganglia of the brain, they give rise to severe pathologic phenomena. In like manner an echinococcus of the liver which has died prematurely may remain unnoticed, while a large suppurating echinococcus cyst of the liver frequently causes death.

The animal parasites of man belong to the **arthropoda,** the **vermes,** and the **protozoa.**

The **arthropoda** (αρθρον = joint; πους = foot) are animals with a laterally symmetric body and usually distinctly articulated (foot-like) appendages. The sexes are separate almost throughout. Of these, two classes occur in man: **insecta** and **arachnoidea.**

The class **insecta** is represented by the order *hemiptera* (*aptera*[1]) and the order *diptera.*[2]

To the order **diptera** (two-winged; with sucking-mouth parts; large, composite eyes; membranous anterior wings, and posterior wings reduced to small appendages; poisers, halteres) belong the flea (*Pulex irritans*), the sand-flea (*Sarcopsylla penetrans*), and the flies (*brachycera*).

The male of the ordinary **flea** (*Pulex irritans*) is 2 to 2½ mm., and the female 4 mm. in length. It sucks the blood and produces a characteristic papule, of variable size, with a small, central, punctiform ecchymosis, surrounded by a slight area of hyperemia, which soon disappears. Urticaria is a rare sequela. The bite of the flea is accompanied by marked itching. The ova are deposited in the soil, rarely upon the human host.

The **sand-flea:** *Sarcopsylla penetrans* (in Central and South America, Africa, and Asia), is yellowish brown in color and about 1 mm. in length. The fecundated female penetrates the skin of the feet,

[1] *Aptera* = without wings.
[2] δίπτερος = with two wings.

especially the region of the toes, occasionally also that of the legs and scrotum. It increases in size as the result of the development of the ova, and produces a whitish nodule the dimensions of a small pea, in which the head appears as a brown punctum. It excites inflammatory, suppurative, and ulcerative processes. Its presence sometimes causes no disturbance.

Myiasis.—The larvæ of flies (*brachycera*) occur under the skin and upon the adjacent mucous membranes (nose, mouth, bronchi, lungs, urethra, vagina, etc.) and body cavities (*Myiasis externa*), or the intestinal tract (*Myiasis interna s. intestinalis*).

The flies **Lucilia macellaria** (in America) and **Sarcophaga mag-**

Fig. 128.—Auchmeromyia luteola, Fabr.

nifica (in Europe, especially in Russia) deposit their ova during the day in cutaneous ulcers, the nose, and auditory canal of persons sleeping in the open. The larvæ may produce marked destruction of the soft parts and even of the cartilage. They have been observed in the nose, antrum of Highmore, and frontal sinus, and may enter the conjunctival sac, the eye, the tympanic cavity, and even the cavities of the skull, causing meningitis and cerebral abscess.

The larvæ of **Hypoderma bovis** and **Hypoderma diana** occasionally enter the human skin, wander subcutaneously, and produce large, painful furunculous nodules, which may result in gangrene. At the side of the nodule is an aperture through which the larvæ breathe and discharge their excreta.

Auchmeromyia luteola (Fabr.), in tropic and subtropic Africa. (See Fig. 128.) The fly does not bite, but the larvæ are blood-suckers. The larvæ remain in the soil during the day, emerging at night to suck human blood.

Myiasis of the stomach and intestines is rare. Larval infection may take place through contaminated food, especially when the gastric secretions are disturbed, perhaps also *per anum*. In chronic intestinal myiasis, in which larvæ may be passed in the stools at intervals for years, disturbances of the colon (pseudomembranous mucous colitis) are present, and intestinal ulceration and even stenosis have been observed.

For other flies see Sleeping Sickness, Malaria, and Yellow Fever.

To the order **hemiptera** (or suborder *aptera:* wingless insects with sucking-mouth parts, indistinctly articulated thorax; large, nine-ringed metathorax, small eyes) belong the head-louse (*Pediculus capitis*), the body-louse or clothes-louse (*Pediculus vestimenti* or *corporis*), the brow-louse (*Pediculus palpebrarum*), the distemper-louse (*Pediculus*

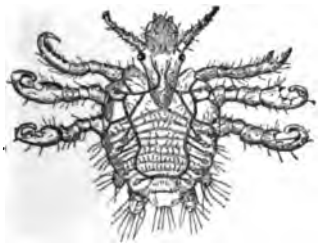

Fig. 129.—Phthirius pubis (crab-louse). (After *Landois.*)

tabescentium), and the crab-louse or pubic louse (*Phthirius pubis, Pediculus pubis, Pediculus inguinalis*).

The **head-louse** (*Pediculus capitis*), the male of which is 1 to 1½ mm., and the female about 2 mm., in length, inhabits exclusively the hairy parts of the head. The ova, called "nits," are about 0.6 mm. and adhere to the hairs. This parasite occurs especially in children and filthy adults. As a result of frequent scratching (incited by the intense itching caused by the bite of the insect) moist, pustulous, scabbed, eczematous patches develop, which may extend to the skin of the face.

The **clothes-** or **body- louse** (*Pediculus vestimenti*) is from 2 to 4 mm. in length, and inhabits folds and seams of the underclothing (shirt, etc.), where it also deposits its ova. It occurs especially in senile and filthy individuals, and seeks the body of man in order to suck his blood, leaving small papules. As these are attended by itching, excoriations and eczematous states are produced as a result of scratching, especially between the shoulder-blades, upon the trunk, and nates. The excoriations sometimes go on to pustulation and abscess formation, which invariably result in pigmentation: "vagabond's skin" (resembling that in Addison's disease) and small cicatrices.

The **crab-louse** (*Phthirius pubis*) is about 1 mm. in length; the female somewhat larger. The ova are pear-shaped and measure 0.8 x 0.4 mm., and are arranged in rows upon the hairs. It usually occurs only among the pubic hairs, but occasionally it advances farther: to the axillæ and even to the eyebrows (brow-louse), but not to the scalp. As the accompanying pruritus is not as aggravating as in the case of the previously mentioned lice, eczema is less frequent. Sometimes pale-bluish spots (*maculæ cæruleæ*) are observed upon the skin of the breast, abdomen, and thigh. It is transmitted during coitus.

Acanthia lectularia (*Cimex lectularius*), bedbug, is brownish red in color, 5 x 3 mm. in size; the ova are white and measure about 1 mm. They inhabit the mattresses and crevices of beds, the spaces

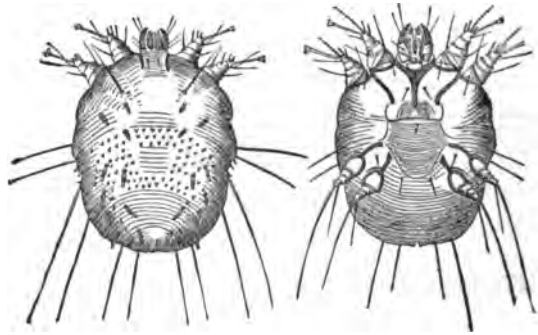

Fig. 130.—Sarcoptes scabiei. Female seen from above and below. (After *Gudden.*)

beneath carpets, crevices in furniture, walls, etc., whence they emerge at night to suck human blood. The bite produces an itching papule, upon which, on scratching, a bloody scab forms.

The class **arachnoidea** (spiders, mites, etc.) is represented by the order *acarina* and *linguatulidæ*.

To the **acarina** (mites with biting or sucking-mouth parts, indistinct separation of head, thorax, and metathorax, tracheal respiration, and chitinous, bristly, and spiculated cuticula) belong the itch-mite (*Sarcoptes scabiei*) and the hair-sac mite (*Acarus folliculorum*).

The **itch-mite**: *Sarcoptes scabici,* of which there are several species (the female 0.3 to 0.5 mm., the male 0.2 to 0.3 mm., in length), produces in man the condition known as scabies, itch (in dogs, mange). Gaining access to the skin, it penetrates the outer skin, makes more or less slanting channels in the epidermis, and advances to the papillary bodies. The female fills the channels with her eggs. This mite has a shield-formed, yellowish-white body, with large feet (four pairs), which

are covered with bristles, the two anterior pair supplied with pedunculated suckers. Upon the dorsum are numerous transverse folds and spicula. The ova-filled channels in the epidermis attain a length of 3 cm., are usually crescentic or slightly spiral in form, and possess two ends: the cephalic end—the point of entrance of the mite and where a small papule, vesicle, or pustule generally develops which soon dries—and the caudal end, which frequently is visible as a small, white punctum. The channel, in part at least, appears dark as the result of accumulated dirt. The mite is located at the terminal (caudal) end of the channel. Frequently an elongated, reddish swelling is seen instead of the dark mite-channel. The points of predilection of the itch-mite are

Fig. 131.—Acarus folliculorum with low magnification.

Fig. 132.—The same with high magnification.

the lateral aspects of the fingers, the region of the finger-web, the hand- (wrist) and elbow- joints, the anterior axillary folds, the navel, the penis, and, in persons with delicate skin, the epidermis of the palms of the hands and the soles of the feet. The itch-mite causes violent pruritus, which excites to repeated scratching (hence: itch: scabies: from *scabere,* to scratch). This, in turn, leads to an eczema, which sometimes terminates in pustulous and deep inflammations: lymphangitis and lymphadenitis. Infection takes place by direct contact, *e.g.,* by cohabitation, and also by clothing. In neglected cases abundant epidermoidal crusts may form which contain mites, ova, and larvæ.

The **hair-sac mite,** *Demodex folliculorum* (0.3 to 0.4 mm. in length), occurs in groups and creeps into the hair-sacs, sebaceous and Meibomian glands, the head directed inward. In dogs and swine they are often so numerous that they cause alopecia. The hair-sac mite is elongated, with a worm-shaped, attenuated posterior body. It has four short,

stumpy feet upon the anterior portion of the body. It very frequently occurs in man without giving rise to symptoms.

Argas reflexus, pigeon-tick (see Fig. 133), is dirty gray in color, about 5 mm. in breadth, 7 mm. in length, and covered with a mosaic-like shell. It has four pairs of legs, the snout lying in front of the first pair. In the fasting state it is flat, but when gorged with blood it often is enlarged to many times its former size. It usually is confined to the bodies of pigeons; occasionally, however, it attacks man, sucking his blood only at night. Erysipelatoid eruption, severe inflammatory edema of the skin and mucous membranes, and distressing asthma are, according to Alt, disturbances caused by it.

The larvæ of various species of *trombidium:* **Leptus autumnalis s. irritans,** "chigger," grass-, gooseberry-, or harvest- mite, harvest-bug, are

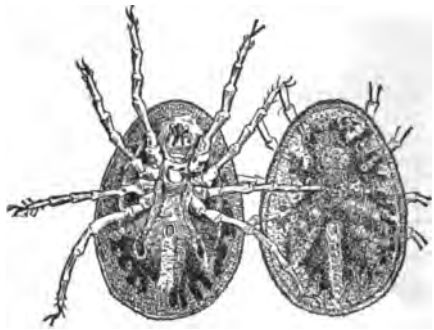

Fig. 133.—Argas reflexus. × 4. (After *Alt.*)

prevalent in midsummer and autumn upon grasses and bushes. The reddish-brown mites, which are recognizable with the naked eye, penetrate the uncovered portions of the skin and produce erythematous, urticarial, and eczematous processes, accompanied by itching and sometimes by febrile phenomena.

Ixodes reduvius, common, dog-, or wood- tick, the male of which is 1 to 2 mm., and red or black in color, the female 4 mm. in length, round, and yellowish red, occasionally attacks the unprotected skin of man to suck his blood. When the female is gorged with blood, it may measure 12 mm. in length. As its name indicates, its habitat is shrubbery. If the biting parts of the tick become detached and are left in the wound, inflammatory processes may develop. Usually the bite is unattended by any special disturbance.

The **Kedani** (*akamushi*) **mite,** observed in Japan, chiefly in individuals who handle hemp, is orange-red in color, about 0.16 to 0.38 mm. x 0.1 to 0.2 mm., and is provided with red eyes and numerous fine hairs.

At the point of lesion a vesicle or scab develops, followed by lymphadenitis, conjunctivitis, a morbilliform exanthem accompanied by fever, obstinate constipation, and sometimes delirium. The severe effects of the parasite become manifest when the biting mite is injured, apparently because toxic substances from the body of the mite then exert their influence (Askanazy). According to some authorities, the symptoms following the bite of this tick are due to bacterial infection. The affection may persist for several weeks, and occasionally causes death.

Trombidium tlalsahaute occurs in Mexico, and usually attacks the axillæ, eyelids, the navel, or prepuce.

Ornithodorus moubata. See Recurrent Fever.

The order **linguatulidæ** (tongue-worms) has but two representatives: *Linguatula rhinaria* and *Porocephalus constrictus.* The linguatulidæ are arachnoidea altered by their parasitism.

Linguatula rhinaria s. pentastoma tænoides is an elongated, flat, worm-like parasite, tapering slightly toward the caudal extremity. The male is white and measures 20 x 3 mm., the female is yellowish and measures 130 x 10 mm. in size. On both sides of the mouth, which is situated on the ventral surface and surrounded by a chitinous ring, are two retractile hooks. The oval egs are 0.09 x 0.07 mm. The adult inhabits the nasal cavity and frontal sinus of a number of mammals, especially the dog, in the nasal secretions of which ova containing embryos are discharged. The adult very rarely occurs in the same localities in man, where it produces rhinitis and epistaxis, but the larval form, designated as *Pentastoma denticulatum,* is quite frequently observed in the internal organs. The larva attains a length of 5 mm., has two pairs of hooks, and is composed of from 80 to 90 rings provided with numerous minute spicula. The parasite is most frequently located in the liver, rarer in the spleen, kidneys, or lungs, beneath the peritoneum, in the submucosa of the intestine, and in the mesenteric glands. At first it appears as a small, whitish, slightly curved body within a gray, translucent cyst; later it exists as a calcified body in a dense connective-tissue capsule. This parasite generally produces no symptoms. Infection occurs by ingestion of ova containing the embryos, which rupture the shell, penetrate the intestinal wall, and, through the lymph- and blood-streams, reach the various tissues, where they become encysted after about six months.

Porocephalus constrictus (*Pentastomum constrictum*) is 13 mm. in length and 2.2 mm. in breadth, cylindric in shape, milk-white, with yellow hooklets. Only the larval form has been found. Cases have been observed in Egypt and British Africa, the larvæ being found in the liver, lungs, and intestinal mucosa.

Worms, **vermes,** are skeletonless animals with symmetric, flat, or cylindric bodies, without organs of locomotion, and in part supplied with bristles, hooks, and suckers. Of these only two classes, *nematelminthes* and *platyelminthes,* occur in man.

The **nematelminthes** are represented by only the order *nematodes:* round-worms with mouth, intestine, and anus. Here belong of the family of *ascaridea:* the spring-worm or maw-worm (pin- or seat-worm: *Oxyuris vermicularis*), and the large round-worm (*Ascaris*

Fig. 134.—Oxyuris vermicularis (female). Natural size. (After *Langerhans.*)

Fig. 135.—Two eggs of Oxyuris vermicularis. (Zeiss Apochr., 4; Comp. Ocul., 4. After *Langerhans.*)

Fig. 136.—Oxyuris vermicularis (female and male). (After *Leuckart.*)

lumbricoides); of the family of *filaridea:* the thread- or Guinea- worm (*Filaria medinensis*) and *Filaria sanguinis;* of the family of *trichotrachelidea:* the *Trichinella* (*trichina*) *spiralis* and the whip-worm (*Trichocephalus dispar* or *Trichuris trichiura*), and, finally, of the family *strongylidea: Dochmius ankylostomum* or *Ankylostoma duodenale, Uncinaria duodenalis.*

Oxyuris vermicularis is the smallest and probably also the most common of all round-worms. It occurs in the large and small intestines and vermiform appendix. It has been found also in the nose. The male is thread-like in form, 3 to 5 mm. in length; its caudal end is coiled. It has a spiculum and two pairs of preanal papillæ. The

female is thicker and longer, 8 to 12 mm. in length; its tail end tapers to a point. (See Figs. 136 and 138, *h.*) At the broad cephalic end is situated the triangular mouth, surrounded by three retractile nodules or lips. The vulva is situated in the anterior third of the body. The ova most commonly contain segmented yolk, and often embryos, and are only occasionally observed in the feces. Oxyuris occurs principally in children and often produces no symptoms; pruritus of the anus frequently exists, sometimes catarrh of the colon and vagina and more rarely (in delicate individuals and children) nervous phenomena (convulsions). The worms may enter the vagina and rarely the uterus and bladder, and occasionally they may be expelled from the mouth. They may bore into the intestinal mucosa, and rarely enter the peritoneal cavity through the

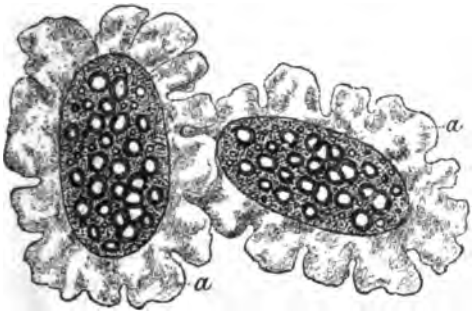

Fig. 137.—Two eggs of Ascaris lumbricoides. *a*, albuminous envelope (Zeiss Apochr., 4; Comp. Ocul., 4. After *Langerhans.*)

Fallopian tubes from the uterus and become fixed in Douglas's sac. Infection occurs *per os* through agency of contaminated fingers, polluted fruits, vegetables, etc. (See Fig. 138, *f, g.*)

Ascaris lumbricoides (Linné, 1758) also is of frequent occurrence, and generally is located in the jejunum and small intestine. It is cylindric in shape and tapering at both extremities. It is observed most frequently in children. The male is smaller (up to 250 mm. in length and 3 mm. thick) than the female (up to 400 mm. long and 5.5 mm. thick). The caudal end of the male is curved and provided with two spicula (chitin points). The triangular mouth is surrounded by three muscular lips. The genital aperture of the female is situated about the middle of the body, somewhat nearer the oral opening. Usually only a few worms are present, but it often occurs in large numbers (several hundred) and may induce symptoms of irritation in the intestine. Some authorities assume that the symptoms are due to a toxin secreted by the worm. The worms may wander to the stomach, esophagus, oral cavity, trachea, etc. They may enter also the ducts of the liver and

pancreas, and even perforate the intestine and enter the peritoneal cavity or the bladder, and be voided with the urine. Numerous ova are always found in the intestinal contents and can readily be demonstrated in the feces. Infection occurs through water and soil. (See Figs. 137 and 138, *a, b, c.*)

The **Guinea-worm,** *Filaria s. dracunculus medinensis* (Gmelin, 1789), is whitish or yellowish in color, has a thread-like body (0.6 to 0.8 m. in length, 2 mm. thick), a rounded anterior end, and terminal circular mouth with six papillæ. The statements in reference to the discovery of the male are conflicting. This worm occurs in the tropics (India, Africa, particularly the West Coast; Guiana, Brazil, West Indies). The intermediate host is a tropic species of fresh-water cyclops. The larvæ probably reach man through drinking-water. It is seated in the subcutaneous connective and adipose tissues, especially of the lower extremities in the region of the ankle, and gives rise to abscess formation or ulceration. *Filaria medinensis* has occasionally been found in the lungs, eyelids, conjunctiva, and tongue.

The larvæ of **Filaria bancrofti** *s. sanguinis hominis* (Lewis, 1872) also are found in the tropics. They are delicate, cylindric, transparent, actively motile organisms, from 0.2 to 0.4 mm. in length, 0.004 mm. in width, with rounded head and slender, tapering tail. It is surrounded by a structureless sheath, projecting beyond both extremities in the form of a flagellum or hood, within which the embryo usually moves quite actively. They are met with in the blood- and lymph- vessels and urine of patients suffering from hematuria, chyluria, chylous dropsies, and lymph-scrotum. They are said to be found in the blood at night, and in the daytime only when the patient sleeps during the day. According to v. Linstow, this phenomenon appears to depend upon the width of the capillaries, the diameter of which is usually greater at night; Manson, however, believes the filariæ are driven or attracted from the peripheral circulation by metabolic products elaborated by the person during the waking state. The larvæ enter the intestine of the mosquito during the act of blood-sucking, and, as in malaria, these insects reinfect the human host.

The larvæ are discharged in the urine during attacks of chyluria and hematuria. The mature worm is filiform in shape and from 8 to 10 cm. in length. It inhabits the lymph-vessels, causing congestion of lymph and elephantiasic formations, especially in the lower extremities and scrotum: **lymph-scrotum.**

Filaria loa (*oculi*), the male, is 22 to 33 mm. in length and 0.4 mm. in breadth, and upon the cuticle are numerous nodules. The cephalic end is somewhat wedge-shaped, and flattened in front. The tail end is curved and presents preanal and postanal papillæ, and two spicules of

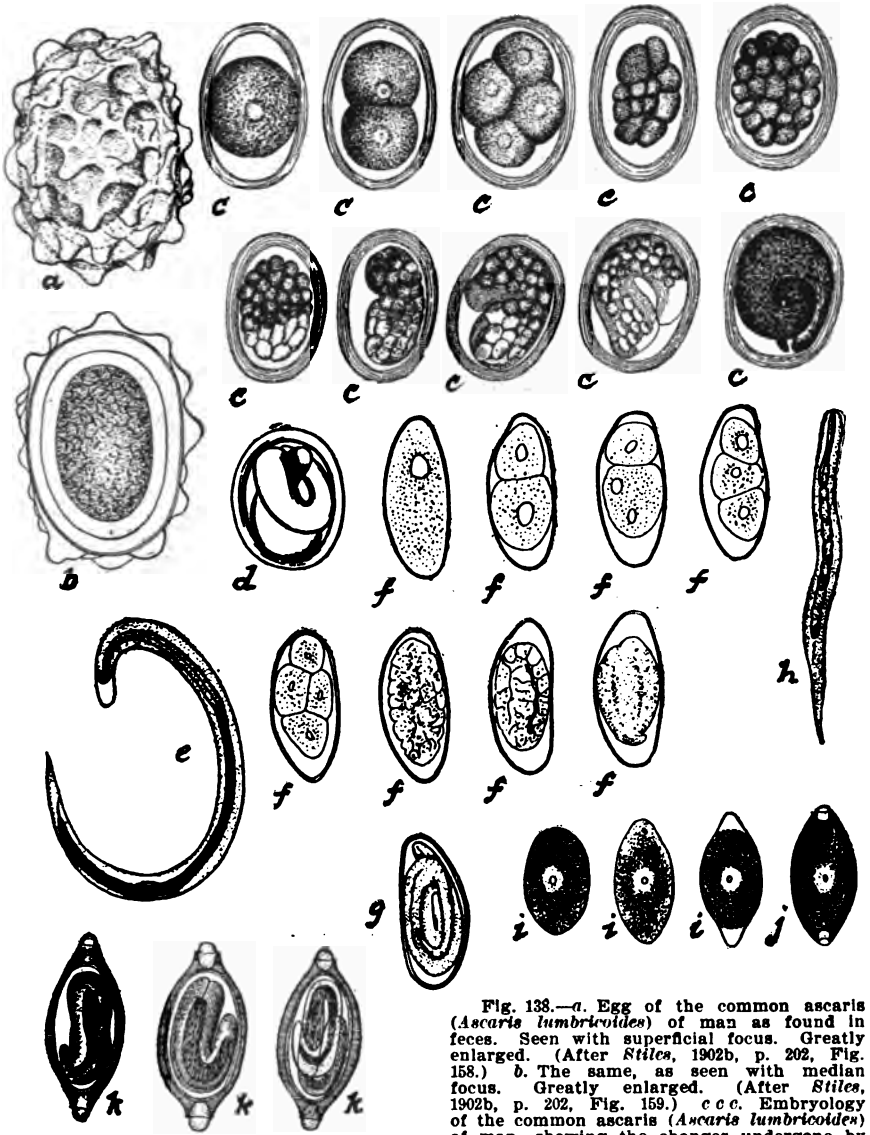

Fig. 138.—*a*. Egg of the common ascaris (*Ascaris lumbricoides*) of man as found in feces. Seen with superficial focus. Greatly enlarged. (After *Stiles*, 1902b, p. 202, Fig. 158.) *b*. The same, as seen with median focus. Greatly enlarged. (After *Stiles*, 1902b, p. 202, Fig. 159.) *c c c*. Embryology of the common ascaris (*Ascaris lumbricoides*) of man, showing the changes undergone by the egg after being discharged in the feces. (After *Leuckart*, 1867, p. 213, Fig. 154.) *d*. Embryo of the common ascaris (*Ascaris lumbricoides*) of man, in the eggshell. (After *Leuckart*, 1867, p. 215, Fig. 156.) *e*. Free embryo of the common ascaris (*Ascaris lumbricoides*) of man, casting its skin. (After *Leuckart*, 1867, p. 214, Fig. 155.) *f f f*. Embryology of the common pin-worm (*Oxyuris vermicularis*) of man, showing the changes undergone by the egg while in the female worm. (After *Leuckart*, 1868, p. 322, Fig. 191.) *g*. Embryo of the common pin-worm (*Oxyuris vermicularis*) of man, in the eggshell, as found in fresh feces. (After *Leuckart*, 1868, p. 328, Fig. 196.) *h*. Full-grown embryo of the common pin-worm (*Oxyuris vermicularis*) of man, after it has escaped from the eggshell. (After *Leuckart*, 1868, p. 328, Fig. 195.) *i i i*. Egg of the common whip-worm (*Trichuris trichiura*) of man, showing changes undergone while still in the female worm; *j* is the stage found in fresh feces. (After *Leuckart*, 1868, p. 491, Fig. 275.) *k*. Later stages of development of an allied whip-worm (*Trichuris affinis*) of sheep and cattle, showing changes after the egg escapes in the feces. (After *Leuckart*, 1868, p. 494, Fig. 276.)

almost equal length. The female is 32 to 37 mm. in length and 0.5 mm. in width, and also has a nodulated cuticle. The posterior extremity is straight. This filaria was observed in Africa and was brought to America by the negroes, and into Europe by the whites. *Filaria loa* lives in the subcutaneous tissue of man and may enter the conjunctiva or orbital tissue. The mode of infection is not definitely known, but it is assumed to occur through the agency of insects (probably mosquitoes) which

Fig. 139.—Filaria sanguinis hominis in human blood. From photomicrograph. × 500.

bite during the day, since the larvæ of this parasite (**Filaria diurna**) appear in the blood during the day. Some authorities regard *Filaria loa* as the parental form of *Filaria diurna.*

Filaria perstans, the larvæ of which are found in the blood both day and night, occurs in Africa and South America. It is situated in the retroperitoneal tissue, in the region of the pancreas, suprarenals, and roots of the mesentery.

Filaria philippinensis is probably a distinct species occurring in the Philippines.

Trichinella (trichina) spiralis was discovered in human muscle by Paget, and described and named by Owen in 1833. Leidy, in 1847, was

the first to discover this parasite in the flesh of the hog. It occurs in man, wild and domesticated swine, rats, mice, cats, dogs, rabbits, and guinea-pigs in the undeveloped state as muscle trichinæ, and in the sexually mature form as intestinal trichinæ.

Intestinal trichinæ are found in the stomach, duodenum, and upper portion of the jejunum after ingestion of flesh containing muscle trichinæ. The sexes develop separately and impregnation is recognizable

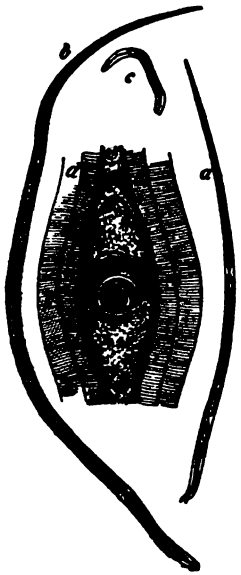

Fig. 140.—Trichina spiralis. *a*, male; *b*, female; *c*, embryo; *d*, muscle trichina. (After *Claus*.)

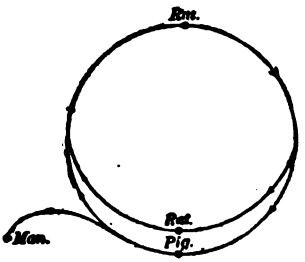

Fig. 141.—Diagram of the hosts of trichina. (After *Bollinger*.)

after the lapse of five days. The embryos require about two weeks for development, after which time they escape from the mother-worm into the intestine, and the intestinal trichina (adult) expires. The young embryos produced in the intestine are actively motile. They penetrate the intestinal wall, enter the peritoneum, and from there migrate to the neighboring parts: diaphragm, pleural cavities, etc., until they finally invade the skeletal musculature, especially the intercostals, diaphragm, platysma myoides, base of the tongue, etc.[1] In the muscles they wander within the primitive muscle bundles to the region of the tendinous attachments. In the process of growth they coil into spiral form.

[1] According to the researches of Askanazy, it is probable that the intestinal trichinæ penetrate the mucous membrane of the intestine and there (or in the chyle vessels) deposit their young. The lymph-stream then conveys the embryos onward.

Although the muscle trichinæ possess a very low organization, they live for a long time (it is said for decades). The development of muscle trichinæ into adult males and females takes place within the intestine of individuals who have ingested living muscle trichinæ (in man, for

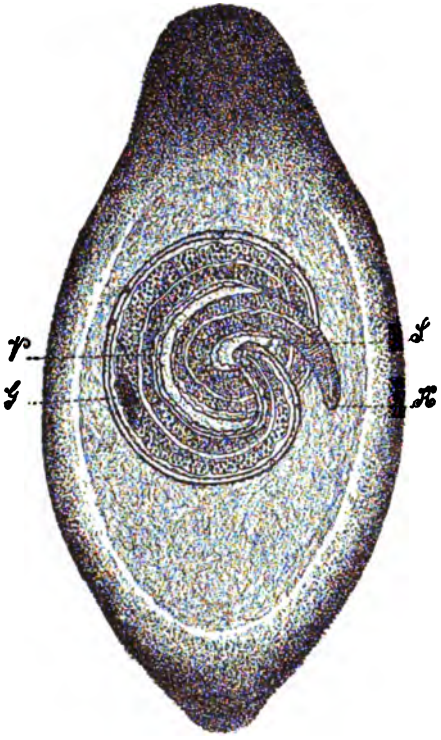

Fig. 142.—Trichina capsule with well-preserved, living trichina. Capsule slightly calcified. *K*, head end (thin); *S*, tail end (thick); *V*, digestive canal; *G*, collection of pigment belonging to the undeveloped genital apparatus. (Zeiss Apochr., 16; Comp. Ocul., 8. After *Langerhans*.)

Fig. 143. — Calcified trichina; form quite well preserved. Capsule contains a little lime. (Zeiss Apochr., 16; Comp. Ocul., 4. Reduced ½. After *Langerhans*.)

Fig. 144.—Trichina capsule with fragments of a calcified trichina. Capsule contains an abundance of lime only at the poles. (Zeiss Apochr., 16; Comp. Ocul., 4. Reduced ½. After *Langerhans*.)

example, through the agency of raw or rare pork). From what has been said it is seen that a short stadium of intestinal life alternates with a longer stadium of muscle life.

The worm never exists in a free state, but always as a parasite. Transmission occurs from one animal to another through consumption of

infected flesh. It is still questionable whether transference may occur also through the agency of excreta.[1]

Trichiniasis, as a disease, belongs to the period in which no capsule formation has as yet taken place. Encapsulation is the result of a reactive process on the part of the muscle, *i.e.*, it represents a process of healing, by which the further advance of the trichinæ is arrested, and begins about the twenty-first day and ends about the sixtieth day. Calcification of the capsule begins about three months after invasion of the muscle, and is completed after a year and a half. The lime is usually deposited in the capsules in granular form and consists of small, often very densely arranged, highly refractive granules (calcification in granular form). For this reason the capsules usually appear very dark, often quite black, by transmitted light on microscopic examination of fresh specimens; on the other hand, by reflected light they are chalky white.

Fig. 145.—Empty, slightly calcified trichina capsule. Fat-tissue at both poles. (Zeiss Apochr., 16; Comp. Ocul., 4. Reduced ½. After *Langerhans.*)

Homogeneous calcification occasionally occurs, but only in the cylindric ends at the poles of the capsules. On macroscopic examination the calcified capsules appear as small, short, chalk-white lines, just recognizable with the naked eye, arranged parallel with the muscle fibers.

The capsules develop from the true contractile substance as a result of proliferation of the muscle nuclei and destruction of the whole primitive bundle. The structureless sheath of the bundle, however, is only thickened. The capsule has a central ovoid portion, the poles of which

[1] As infection can occur after ingestion of cooked pork, the question as to what temperature will with certainty kill the trichinæ is important. Heating at from 170° to 200° F. for six or more hours usually suffice; but as the size of the object to be cooked, the number of trichinæ, and the degree of encapsulation play a rôle, further investigations are necessary in this direction. Trichiniasis, undoubtedly, is of more frequent occurrence than generally is assumed, sporadic cases often being overlooked, owing to the difficulty in diagnosis. In such instances, as well as in epidemics, the most important aid is examination of the blood; thus far it is the only affection in which eosinophilia is constantly so high (from 10 to 86 per cent.), this symptom rarely being absent. The eosinophilia begins with migration of the trichinæ from the intestine into the musculature and is most marked at the height of the muscular symptoms, from which time onward it slowly declines. The total number of leucocytes is usually increased; the number of neutrophiles during the eosinophilia is relatively and sometimes absolutely diminished. (For conditions in which eosinophilia otherwise occurs, but in lesser degree, see Blood.)

gradually merge into a short, thick, cylindric prolongation having a rounded extremity. The central portion is transparent and incloses a cavity containing the plainly visible, spirally coiled trichina. The latter is invisible after it has died (after decades) and become calcified. In contrast to the capsule, calcification of the trichina itself is always homogeneous. At the poles of the capsule there is often, but not always,

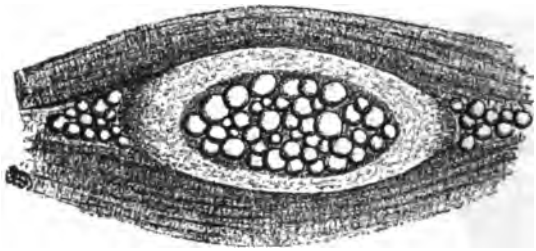

Fig. 146. — Trichina capsule filled with adipose tissue. Fat-cells at the poles. Same magnification as in 143-145. (After *Langerhans.*)

found on microscopic examination a small, somewhat triangular space occupied by fat-tissue cells. (See Fig. 146.)

Calcification of the trichinæ and their capsules[1] does not always terminate the retrograde alterations occurring in them. On the contrary, it is probable that when the capsule and trichina are calcified they, like a dead part, very frequently excite new proliferations in their neighbor-

Fig. 147.—Trichina capsule, almost completely resorbed, indicated by a finely granular mass and recognizable by its form. Fat-tissue at the poles. Same magnification as in Figs. 143-145. (After *Langerhans.*)

hood, which first cause absorption of the lime-salts and subsequently complete elimination of the trichinæ and their capsules. In this connection it can be observed that after partial absorption of the lime-salt of the capsule (*e.g.*, at one pole) the latter is broken through by the proliferation—that a young, richly vascular granulation tissue has penetrated into the interior of the capsule. Furthermore, the calcified trichina disappears with the advance of the granulation tissue, and then either the

[1] Hilton, in 1821, first described the calcified trichina capsules, but mistook them for cysticerci.

capsule is slowly destroyed by proliferation or the granulation tissue is transformed into fat-tissue within the partly well-preserved and still recognizable capsule. Absorption of the decalcified parts (trichina and capsule) also often occurs without the formation of granulation tissue, *i.e.*, without the occurrence of reactive phenomena in the neighborhood of the capsule. In this form of absorption the lime-granules nearest the inner layer of the capsule seem always to disappear earlier than those lying in the outer portions of the capsule.

The developed muscle trichina attains a length of about 0.8 mm. The sexually mature male intestinal trichina is 1.5 mm., and the female 3.0 mm., in length. The anterior extremity of the trichina is attenuated; the tail end blunt and rounded; in the male the posterior extremity possesses two conical projections, directed toward the ventral surface. With these the male clasps the female during copulation. The intestinal canal begins with a quite small, muscular portion which merges into the wider and comparatively long esophagus. With this the gastrointestinal canal is connected by a simple dilation. The male generative apparatus consists of testes and seminal duct, which, in common with the intestine, opens at the posterior end. The sexual apparatus of the female is composed of an ovarium, uterus, and vagina. The orifice of the latter is located some distance forward—at the junction of the first and middle thirds.

Trichiniasis,[1] or **trichinosis,** in its violent forms possesses a certain resemblance to typhoid. It is a febrile disease associated with headache and stupor. The penetration of the peritoneum by the young muscle trichinæ irritates this membrane. Catarrhal inflammation exists in the upper portion of the small intestine. In addition to this, characteristic edema of the eyelids and extremities, diffuse bronchitis, and sometimes bronchopneumonia are present. The groups of muscles attacked by the trichinæ are the seat of violent inflammation (myositis) which renders difficult the acts of mastication, deglutition, and respiration.

The **whip-worm,** *Trichuris trichiura, Trichocephalus dispar* (Rudolphi, 1801), usually inhabits the cecum in numbers varying from four to twelve. It occasionally is found in the colon, vermiform appendix, and rarely in the ileum. The male is from 40 to 45 mm. in length; the female up to 50 mm. in length. The anterior portion of the body is slender and thread-like, and frequently is buried in the mucous membrane; the posterior portion thick, and, in the male, spirally coiled and

[1] Zenker (*Deutsches Arch. f. klin. Med.*, viii, p. 387) was the first to elucidate the whole subject of trichiniasis and to emphasize its serious nature, on the basis of the observation of a fatal case in a girl of 19 years.

armed with a spiculum 2.5 mm. in length within a pocket provided with spines. The posterior portion of the body of the female is almost straight; the genital aperture is at the junction of the thread-like and swollen portions. This worm occurs quite frequently, but it is comparatively harmless, except when present in large numbers, when they may produce intestinal disturbances, serious cerebral symptoms, or even cause death.[1] In what way the worm is injurious is undecided. Some maintain that it sucks blood like the ankylostoma; others, that it secretes a toxin. One of the most prominent symptoms of trichocephaliasis is anemia. The ova are 0.05 to 0.054 mm. in size (see Fig. 149) and found

Fig. 148. — Trichocephalus dispar. *a*, male; *b*, female. Both in natural size and highly magnified. (After *Leuckart.*)

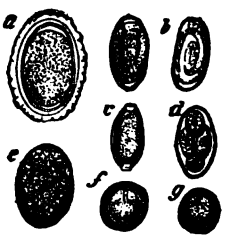

Fig. 149.—Eggs of nematodes. *a*, ascaris; *b*, oxyuris; *c*, trichocephalus; *d*, ankylostoma; *e*, dibothriocephalus; *f*, Tænia saginata; *g*, Tænia solium. (After *Leuckart.*)

in the feces, where they may be innumerable. They are yellow to reddish brown, oval, spindle-shaped, and have a clear pole at either end. The eggs are usually swallowed in water or with soil.

Dioctophyme renale (Eustrongylus gigas) is a very large blood-red or bluish-red nematode occurring in dogs, seals, etc. The male measures up to 40 cm. in length and 5 mm. in thickness, and has a blunt, square-cut posterior extremity. The female may attain a length of 1 m. and a diameter of 1 cm. The ova, which are found in the urine, are oval, 0.064 to 0.04 mm. in dimensions, brownish in color, except at the poles, which are uncolored, and show numerous depressions. They require an intermediate host for further development, perhaps a fish. This parasite

[1] *Corrsbl. f. Schweiz. Aerzt.*, April 15, 1907.

occasionally is observed, singly or several together, in man in the urinary tract (renal pelvis, ureter, and bladder), where it produces renal colic, dilation of the renal pelvis, and retention of urine. The inflammatory processes (indicated by pyuria and hematuria) which accompany its presence, such as pyelitis, suppurative nephritis, perinephritis, with final atrophy of the renal parenchyma, are probably the result of bacterial action.

Echinorhynchus gigas, which is of frequent occurrence in the intestine of swine, is very rarely observed in the small intestine of man. It possesses a retractile rostellum with hooks, and a long sac-like body. The ova, which are discharged with the feces, undergo further development in intermediate hosts (insects and crustacea), and with their host enter the intestine of the swine.

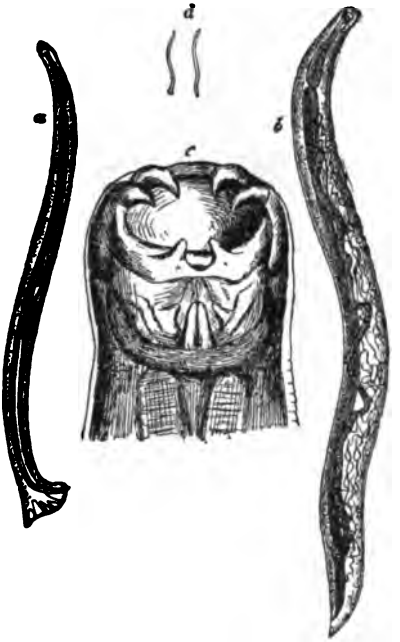

Fig. 150.—Agchylostoma duodenale. *a*, male; *b*, female; *c*, head; *d*, natural size. (After *Leuckart.*)

Agchylostoma duodenale (Dubini, 1843), *s. dochmius* (Leuckart, 1876), *s. uncinaria duodenalis* (Ralliet, 1885), or hook-worm, occurs in the upper portion of the small intestine, oftener in the jejunum than in the duodenum. It was discovered by Dubini, of Milan, in 1838. It is observed particularly in the tropics and subtropics, but also in Switzerland and the regions of the Rhine, especially in brick workers. The disturbance caused by it is known as dochmiasis or agchylostomiasis, or **uncinariasis;** Egyptian, tropic, brickmakers', or tunnel anemia; miners' cachexia, and jail debility. It is a small, cylindric worm, the female of which attains a length of 18 mm., and the male 10 mm. The tail of the latter terminates in a broad, trilobed bursa copulatrix, at the bottom of which open the intestine and vas deferens accompanied by two slender spicules. The genital pore of the female lies behind the middle of the body. The mouth end is curved toward the dorsal surface; the oral aperture is armed on the ventral surface with four claw-like hooks, and on the dorsal surface two comparatively delicate tooth-like bodies. (See Fig. 150.) Agchylostoma occurs singly and also in very large numbers (many hundreds and in some cases several thousand). In the latter instance continued losses of blood occur,

which finally result in severe and often fatal anemia. They were discovered by Greisinger, in 1851, to be the cause of Egyptian chlorosis. The worms cling by their teeth to the mucous membrane, into which they bore to the submucosa, suck themselves full of blood, and leave a small bleeding hole in the mucosa. The worms are said also to elaborate a hemolytic toxin. The ova are 0.023 mm. in breadth and 0.044 mm. in length, and are found in large numbers in the feces (sometimes several millions are passed daily). They require water and moist, warm soil for their further development. The larvæ escape from the eggshell,

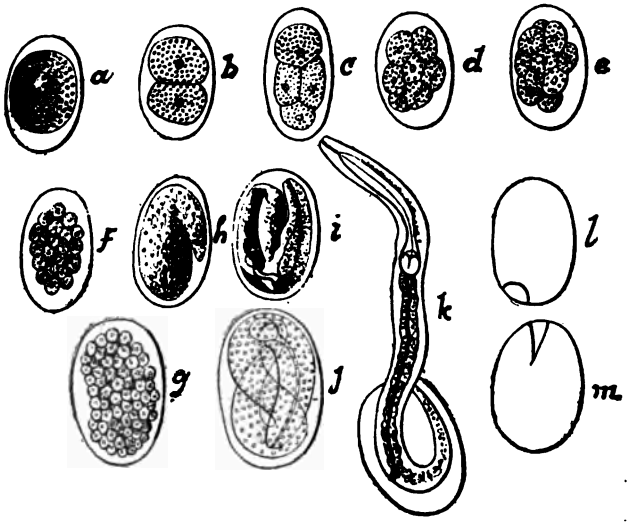

Fig. 151.—Embryology of the Old World hook-worm (*Agchylostoma duodenale*) of man. *a, b, c, d, e, f, g,* segmentation of the egg; *h, i, j,* the embryo; *k,* a rhabditiform embryo escaping from its eggshell; *l, m,* empty eggshells. Greatly enlarged. (After *Perroncito,* 1882, p. 342, Fig. 142.)

molt several (four) times (ecdysis), and creep around everywhere; get upon the hands of earth (clay) workers and thence to the mouth, or they are ingested with drinking-water, or most frequently enter the skin[1] through the hair and sweat follicles (Looss), and after various migrations (blood to lungs, bronchi, esophagus) finally reach the ileum. The parasites were found by Baumler in the intestine two years after infection, and by Peroncito even after four years and longer. The blood may show marked eosinophilia.

Uncinaria (agchylostoma) americana s. necator americanus (Stiles, 1902), so-called American hook-worm, occurs in the Southern

[1] Most often of the feet and between the toes: "ground-itch."

States of North America, the West Indies, South America, Africa, Asia, etc. Thus far, this worm has been observed in the ileum only in man. It is shorter and more slender than *Agchylostoma duodcnale.* The buccal capsule is smaller, and, instead of four ventral hooks, is provided

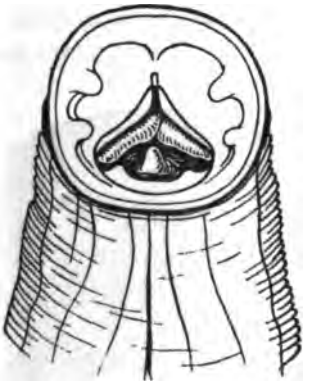

b

Fig. 152.—Head of Necator americanus. (After *Daniels.*)

on both the ventral and dorsal sides with a pair of semilunar plates, the ventral pair more prominent, like those of the dog hook-worm (*Uncinaria stenocephala*). Two pairs of lancets, one dorsal, the other

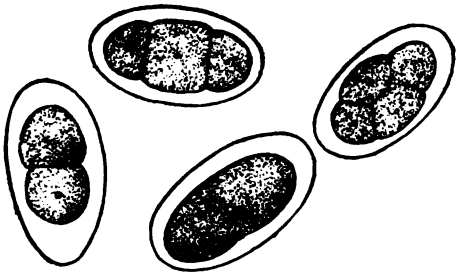

Fig. 153.—Four eggs of the New World hook-worm (*Uncinaria americana*), in the one-, two-, and four- cell stages. The egg showing three cells is a lateral view of a four-cell stage. These eggs are found in the feces of patients and give a positive diagnosis of infection. Greatly enlarged. (After *Stiles.*)

ventral, are situated deep within the oral capsule. The genital pore is at the junction of the anterior and middle third of the body. Infection probably occurs in the same manner as in *Agchylostoma duodenale.* The ova are larger than in *Agchylostoma duodenale.*

Strongyloides intestinalis (*Anguillula intestinalis s. stercoralis*) occurs in the small intestine and lives upon the chyme, and not upon the blood. It was formerly looked upon as the cause of Cochin China diarrhea, but alone it appears to be incapable of producing injurious effects. It often occurs in conjunction with agchylostoma. Aside from China, it occurs in Africa, Japan, Europe, West Indies, South America, and several cases of infection with this worm have been reported in the

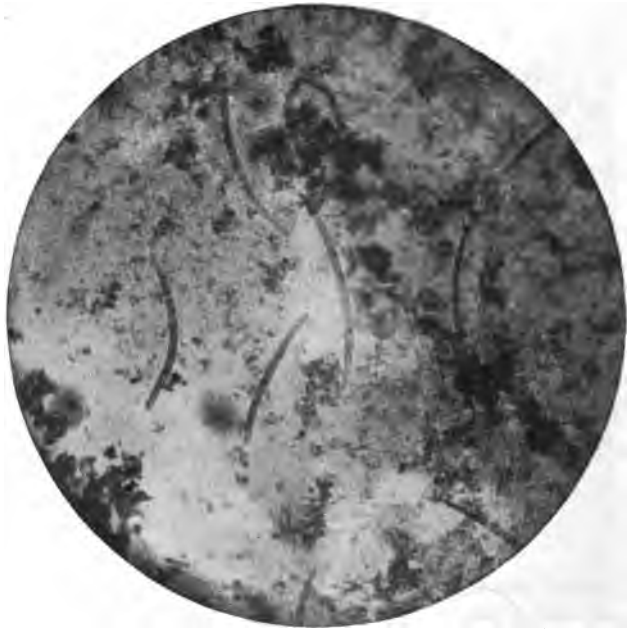

Fig. 154.—Strongyloides intestinalis in feces. (Leitz Obj., 3; Ocul., 4.)

United States. These nematodes, *Strongyloides intestinalis* and *s. stercoralis,* which formerly were regarded as separate species, are now known to be different stages of development of the same parasite, *i.e.*, two succeeding generations of the same species, one of which (*A. intestinalis*) lives as an intestinal parasite, and the other (*A. stercoralis*), its young, lives free.

The intestinal form (*A. intestinalis*), which by some (*e.g.*, Leuckart) is considered to be hermaphroditic; by others (*e.g.*, Rovelli), to increase by parthenogenesis, is 2 to 2.5 mm. in length and 0.034 mm. in width. According to Askanazy, it bores into the intestinal mucosa, especially into the epithelium of Lieberkühn's glands, to obtain nourishment and to deposit ova, which are found in the base of the membrane

in all stages of segmentation up to the formation of the young worms. The young worms leave the intestinal mucosa and enter the intestinal lumen, where they grow somewhat and are discharged with the excreta.

The various abodes of the worms here summarized (*Agchylostoma* in the duodenum, *Ascaris lumbricoides* in the jejunum, *Trichuris trichiura* in the cecum, *Oxyuris vermicularis* in the colon) doubtless depend upon the varied nutritive requirements of the animals. They live in great part upon the nutrient materials supplied to the host. From without they enter the intestine and there produce enormous numbers of ova or embryos. The oxyurides multiply in the intestine, but the *Ascaris lumbricoides* does not. The ova of the latter can further develop in stagnant water. Leuckart believes the larvæ of *Agchylostoma duodenale* live in muddy water.

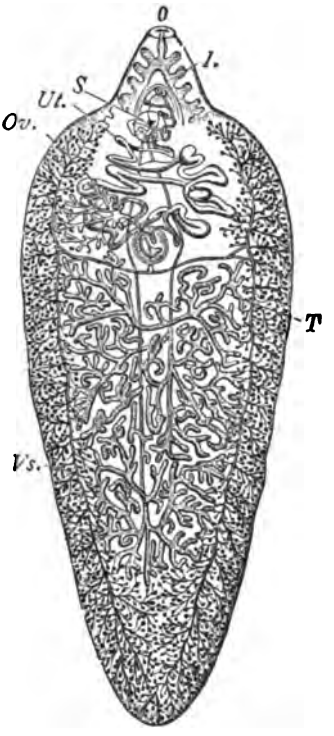

Fig. 155.—Fasciola hepatica (Lank.). *I*, intestine; *Vs*, vitelline sacs; *Ov*, ovary; *O*, oral aperture; *Ut*, uterus; *S*, ventral sucker; *T*, testes. (After *Claus.*)

Of the **platyelminthes** (flat-worms) the *trematodes*, with the *cestodes*, occur as parasites in man.

The **trematodes** are sucking worms of tongue- or leaf- like form. They are provided with a mouth, a forked intestine without anal opening, and are usually supplied with suckers upon the ventral surface, and sometimes with hook-shaped organs of adherence. They are hermaphrodites: the male and female generative organs have a common opening into the genital pore. In man they are represented by the families *paramphistomidæ*, *fasciolidæ*, and *schistosomidæ*. The most important are: *Distomum hepaticum*, *Schistosomum hæmatobium*, *Opisthorchis felineus* (perhaps identic with *D. sibiricum*), *lanceolatum*, and *Panagonimus westermani*.

Gastrodiscus (*amphistomum*) **hominis** is 5 to 8 mm. in length and from 3 to 4 mm. in width. According to Braun, this parasite has been observed only twice in man. It was found in large numbers in the colon and cecum. It occurs in India and the Philippines, and possibly also in other tropic regions.

Fasciola hepatica (Linné, 1758), *Distomum hepaticum*, liver fluke, is found in man and also in the ox, sheep, goat, camel, hog, horse, ass, squirrel, deer, antelope, kangaroo, beaver, and produces in sheep the so-called "rot," "liver rot," "fluke rot." It has a short, cone-shaped anterior body and flat, obovate posterior body. It is about 40 mm. in length and 12 mm. in breadth. It occurs in Europe, North Africa, North and South America, Australia, Asia, India, Japan, China, etc. It resides in the biliary ducts of the liver, where it may cause obstruction and inflammation, perhaps also ulceration and stenosis. It may occasionally reach the lungs, muscles, and connective tissue. The

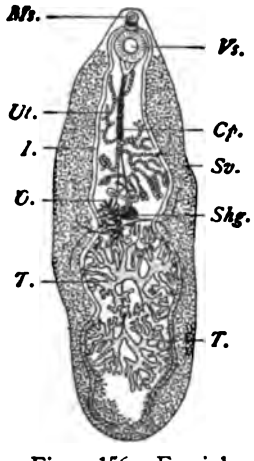

Fig. 156.—Fasciolopsis buski (Lank.). *Vs*, ventral sucker; *Cp*, cirrhous pouch; *I*, intestinal fork; *Sv*, vitelline sac; *T*, testes; *O*, ovarium; *Ms*, mouth sucker; *Shg*, shell-gland; *Ut*, uterus. (After *Odhner.*)

Fig. 157.—Fasciolopsis rathouisi (Poir.). The mouth at the top, and under it the genital pore and ventral sucker, behind which again is the uterus. The vitelline sacs are at the sides, and posteriorly in the central field the ramified testes; the ovary is in front of the right one. (After *Claus.*)

ova of *Fasciola hepatica* are met only here and there in the bile-ducts and gall-bladder. It is supposed that *Fasciola hepatica* migrates from the duodenum into the liver. The ova are found in the feces.

Fasciola hepatica, var. *angusta* (Raillet, 1895), was observed by de Gouvea in the human lung.

Fasciolopsis (distomum) buski (Lankester, 1857) has been observed in Natal and east and south Asia and thus far, in man, only in the intestine.

Distomum rathouisi (Poirier, 1887) is related to fasciolopsis, and, according to Braun, has been observed but once, namely, in a Chinese

woman. P. Manson mentions two other cases. According to Theobald, Scheube states that *Distomum buski* is the same as *D. rathouisi* and *D. crassum.*

Dicrocœlium lanceatum (Stiles and Hass, 1896), *Distomum lanceolatum* (Mehlis, 1825), is lancet-shaped. It is 10 mm. in length and 1.5 to 2.5 mm. in breadth. It likewise is found in the bile-ducts. It is rare in man, but more frequent in sheep and cattle, cat, dog, rabbit, pig, hare, horse, ass, llama. The intermediate host is unknown.

Opisthorchis felineus (Riv., 1885), *Distomum felineum,* is from 8 to 16 mm. in length and from 1.5 to 2.5 mm. in breadth. It is flattened and somewhat pointed anteriorly; posteriorly it is broader and rounded, and without spicule. The ventral sucker is situated at the junction of the anterior fifth. This distoma, like *Distoma sibiricum,* which resembles it in every way and with which, probably, it is identical, formerly was observed chiefly in the dog and cat. After it had already been shown by a report from Tomsk that *Distoma sibiricum* had been found in the liver in 9 human subjects, and in 1 case in the neighborhood of St. Petersburg, Askanazy, in 1900, observed *Distomum felineum,* which until then had not been met with in man, in a number of persons, all living in the district of Heydekrug (east Prussia). Both these species of distoma (felineum and sibiricum) occupy the bile-ducts (also the intestine and pancreatic duct), and cause dilation, inflammation or atrophy of the surrounding tissues, and proliferation of epithelium. In 2 cases carcinoma developed as a result of these tissue changes. The number of worms present may be over 100. Little is known of the development of this parasite.

Metorchis truncatus is only 2 mm. in length. It occurs in the seal, cat, dog, fox, and man. The mode of invasion is unknown.

Paragonimus westermani (*Distoma pulmonale*), which is 8 to 10 mm. in length and from 5 to 6 mm. in breadth, has been described by von Baelz (and Manson) as a pulmonary parasite occurring in China, Korea, and especially in the Philippines and Japan. It has been observed also in Europe and North America. Each parasite lies in a small cavity which communicates with a bronchus. It causes hemoptysis and occasionally severe pulmonary hemorrhage. (See Fig. 158.)

Opisthorchis sinensis, *Distoma spathulatum s. japonicum,* resembles *D. felineus,* and occurs principally in Japan, where, according to Katsurada, in the province of Okayama, 56 to 57 per cent. of the population are infected. More than 4000 of these parasites may occur in one individual! It is found chiefly in the gall-bladder and bile-ducts, though in 12 per cent. of the cadavers examined by Katsurada it was observed also in the pancreas and occasionally in the intestine. It is 10 to 14 mm.

in length and 2.4 to 3.9 mm. in breadth, and without spines. The ova within the parasite contain the ciliated miracidium. In the liver it produces dilation and sacculation of the bile-ducts, proliferation of the con-

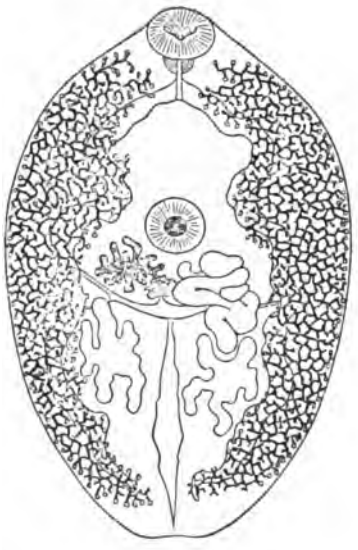

Fig. 158.—Paragonimus westermani. (After *Looss.*)

Fig. 159.—Schistosomum hæmatobium (Bilh. 12/1). Male contains the female in the canalis gynæcophorus. (After *Looss.*)

nective tissue and epithelium, interstitial hepatitis, atrophy, and fatty degeneration of the parenchyma. The mode of infection is unknown.

Opisthorchis noverca (*Distoma conjunctum*) is nearly related to *Op. felineus* and *Op. sinensis*. It was observed in the bile-ducts in two cadavers examined by McConnell in Calcutta.

Heterophyes heterophyes, 2 mm. in length and 1 mm. in width,

occurs in Egypt and Japan. In man it is found in the small intestine, and the ova are discharged with the feces.

Schistosomum (*distomum*) **hæmatobium** (Bilharz), *s. Bilharzia hæmatobia,* differs greatly from the forms already mentioned in that the sexes are separate. The female is cylindric, filiform, up to 19 mm. in length, and pointed at each end; the thicker male is up to 14 mm. in length and has a flat body, which is incurvated ventrally in tubular shape, forming a canal: so-called *canalis gynæcophorus,* for the reception of the

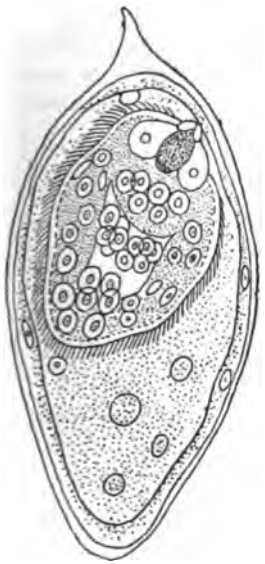

Fig. 160. — Schistosomum hæmatobium (from urine). (After *C. W. Daniels.*)

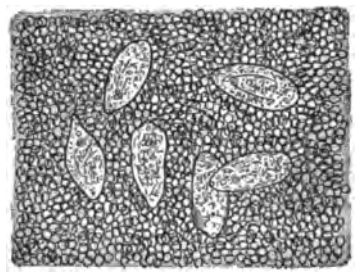

Fig. 161.—Eggs of distoma from urinary sediment. (After *Purdy.*)

female during copulation. (See Fig. 159.) *Schistosomum hæmatobium* occurs principally in Egypt; also in Arabia, Cyprus, Cape Colony, east and west Africa, and in the West Indies and North and South America. It is seated in the veins of the abdomen (roots of the portal vein and perineum), occasionally also of the lungs. The ova are 0.05 mm. in breadth, 0.12 mm. in length, and nearly always have a terminal or lateral spine.[1] (See Fig. 160.) The deposited ova cause inflammation (catarrh) and ulceration of the mucous membrane of the ureters, blad-

[1] Ova with lateral spine are said by Sambon to be passed by another species: *Schistosomum mansoni.* In 27 appendices examined at necropsy by G. A. Turner (*Transvaal Med. Jour.,* July, 1910, p. 251), terminal-spined ova were found in 85 per cent., lateral-spined ova in 5 per cent., and mixed ova in 10 per cent.

der (hematuria), and colon (dysentery). Urinary fistulæ; papillomata of the bladder, cervix uteri, penis, vulva (producing false elephantiasis), intestines, rectum, and around the anus, and not rarely epitheliomata also are observed. The ova are observed also in the prostate, kidneys, vermiform appendix, liver, and lungs **(Distomum pulmonale).**

The following table, based upon 27 necropsies by Turner[1] upon natives of the east coast of Africa between latitude 14 degrees south and latitude 26 degrees south, shows the number of times the various organs were affected:—

Tribe.	Number examined.	Times appendix infected.	Times bladder infected.	Times bilharzia worms in portal veins.
Myambaam	7	6	4	1
Shangaan	5	2	5	3
Nyassa	4	3	4	3
Yao	1	1	1	1
Barue	1	1	1	1
Mocambique	8	6	8	6
Quilimane	1	1	1	1
Total	27	20	24	16

In Egypt a large portion of the poorer population suffers from *Schistosomum hæmatobium.* Death sometimes results from general exhaustion. Infection is said to occur through the agency of drinking-water, but most probably it takes place through the skin of bathers in infected waters or of waders in mud, the larvæ entering in the same manner as those of *Agchylostoma duodenale.* The period of incubation is about six weeks, as symptoms appear within from one to two months after exposure.

Schistosomum mansoni is a name given by Sambon to a hypothetic species said to pass ova with a lateral spine.[2] (See Fig. 162.)

Schistosomum japonicum (Katsurada), *Schistosoma cattoi,* occurs in China, the Philippines, and Japan, and causes the so-called "Katayama disease," an affection characterized by ascites, enlargement of the spleen and liver, and diarrhea which often is mucohemorrhagic. The male is 9 mm. in length and less than 0.5 mm. in breadth. The female is slender and longer than the male. The mature worms occupy the blood-vessels of the mesentery. The ova are found in the liver and in the submucosa, muscularis, and subperitoneal portions of the intestine, especially of the

[1] See footnote, p. 375.
[2] *Ibid.*

rectum and appendix; also in the mesenteric glands, gall-bladder, and pancreas, and are discharged with the feces. The life history is unknown.

The **cestodes**[1] are **tape-worms:** flat worms without mouth and intestine, which develop by alternation of generations (metagenesis) and, as a rule, remain connected with the scolex, from which they originate by budding. The scolex, which may possess suckers and hooklets, forms the so-called head.

The embryo of the cestodes (onchosphere) is provided with six hooklets (hexacanth) at one pole. On entering the alimentary canal the shell is dissolved and the embryo migrates, by means of the hooklets, to the various tissues and organs. The six hooklets are then discarded, and from the opposite pole develops a scolex (head and neck) like that of the tape-worm from which the embryo originated.

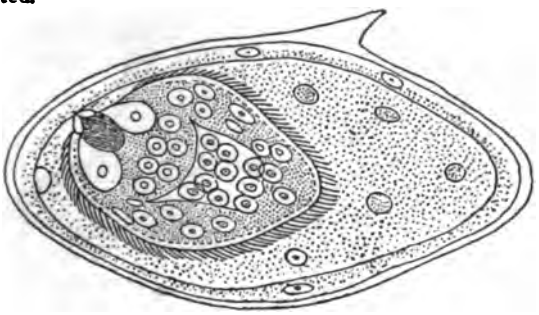

Fig. 162.—Schistosomum (?) hæmatobium (from feces). (After *C. W. Daniels.*)

The tape-worms are represented in man by the family *tæniidæ* and *bothriocephaloidea.* Of the family *tæniidæ* occur, among others: *Tænia solium, Tænia saginata,* and *Tænia echinococcus;* of the family *bothriocephaloidea: Dibothriocephalus latus.*

The tape-worms consist of certain constant parts. The majority are composed of connected, band-like segments: *proglottides* (the true sexual animals), are flat, quadrangular in form, and possess the ability to contract and expand in length and width. The segments nearest the anterior or cephalic end are broad and short; those nearer the inferior extremity long and narrow. The neck is thread-like, quite long, and carries the head: a button-shaped or spheric, usually pigmented swelling about the size of the head of a pin. Hence, the tape-worm always constitutes a colony of animals, in which each animal occupies the position of an individual. Each segment possesses independent generative organs. Upon each segment is a marginal striation corresponding to canals, which unite in the interior of the segment to form one common channel.

[1] κεστος = a girdle; εἶδος = like.

The canals constitute the female generative apparatus; their white color is due to the numerous ova which they contain. Every segment possesses also a male generative apparatus and is, therefore, hermaphroditic. Upon the side of each segment—in dibothriocephalus in the center upon the surface of each joint—is a projection provided with an aperture. Here open the male and female generative apparatus, one behind the

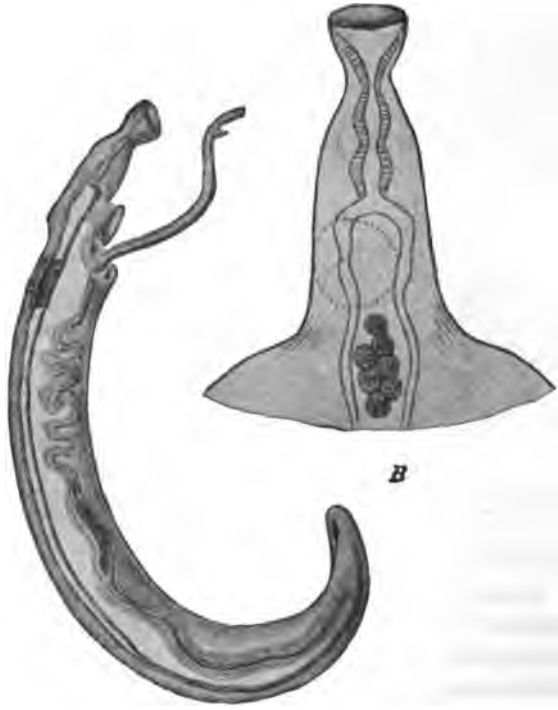

Fig. 163.—*A*, Schistosomum japonicum; *B*, anterior extremity of male, enlarged. (After *Fulleborn.*)

other. The excretory duct of the female generative apparatus is straight and opens within the genital pore, behind the male excretory duct, which has a tortuous course. Out of the latter projects a spicule: penis, cirrus, which can enter the female generative aperture.

Development of the embryo takes place in the ova within the individual segments. The ova have a quite hard and radiately striated shell. Within the ova in the oldest, mature segments the small embryos are often plainly visible microscopicly. These have six comma-shaped hooklets, arranged about one pole, and of which two always stand parallel with each other.

The usual habitat of tape-worms is the small intestine. The last joints, containing ripe ova, become detached and are discharged with the feces. The further development of the ova is always accomplished through the medium of another animal.[1] The ova are taken up with the food and enter the stomach, where the shell is digested by the gastric juice and the young animals are set free. These then wander into the body and develop into larvæ (*cysticerci*) within the organs. Thus, like young trichina embryos, they possess the ability to penetrate the tissues.

The frequency of occurrence of the various forms of tape-worm is shown by the following table, by Krabbe, based upon 300 cases:—

TABLE OF FREQUENCY OF TÆNIÆ (300 CASES). (AFTER KRABBE.)

	Tænia saginata.	T. Solium.	T. cucumerina.	Dibothriocephalus latus.
Under 1 year			9	
1 to 10 years	11	7		
10 to 20 "	14	5		
20 to 30 "	79	15		10
30 to 40 "	35	15		6
40 to 50 "	20	4		6
50 to 60 "	15	2		
60 to 70 "	4			2

Dipylidium caninum (*Tænia canina* or *cucumerina*) is a common parasite of the dog and often of the cat. It is comparatively rare in man, and is observed almost always in children, in whom it may cause intestinal and nervous symptoms. It is 35 mm. in length and 2 to 3 mm. in breadth, and possesses a scolex with a markedly bulbous rostellum upon which are situated several circles of rose-thorn-like hooklets. The proglottides are often reddish gray in color, and in isolated state resemble cucumber seed, and are dejected almost daily. The genital organs are duplicated. The genital pores are lateral and open on opposite edges of the segments. The cysticercoid develops in the dog-louse (*Trichodectes canis*) and in the flea of man (*Pulex irritans*) and the dog (*Pulex serraticeps*), and through ingestion of these vermin they reach the intestine, where development into the tape-worm takes place.

Hymenolepis nana (*Tænia nana*), which occurs in large numbers, chiefly in children, is 1 to 4 cm. in length and 0.5 to 1 mm. in breadth, and has a spheric scolex with rostellum and a wreath of from 24 to

[1] Autoinfection also may occur, by mouth through fecal-contaminated fingers or by entrance of segments from the intestine into the stomach, where the embryos may be liberated from the ova by the gastric juice.

38 hooklets. It closely resembles *H. murina,* prevalent in rats. The proglottides, of which there are about 150, are quite narrow. The genital pores are lateral. It has been shown that the worm may bore into the intestinal mucosa and cause diarrhea, nervous symptoms, and convulsions. The mode of infection is unknown, but it is assumed that cysticercoid and tape-worm develop in the same body. According to

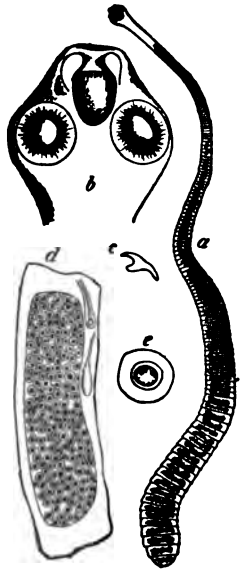

Fig. 164.—Tænia nana. *a*, the whole worm (× 9); *b*, head (× 50); *c*, hooklet (× 300); *d*, segment (× 50); *e*, egg (× 125). (After *Leuckart.*)

Fig. 165.—Egg of the dwarf tape-worm (*Hymenolepis nana*) of man, greatly magnified. (After *B. H. Ransom.*)

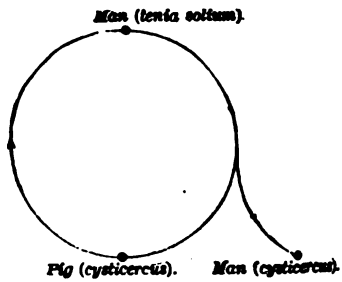

Fig. 166.—Plan of alternation of hosts with Tænia solium. (After *Bollinger.*)

Stiles, the intermediate hosts of this tape-worm are insects and myriapoda, which become infected from grain soiled with feces of the rat.

Tænia solium[1] (Linné, 1767), armed or **pork tape-worm,** may attain a length of 2 or 3 m. (6 to 10 feet); it sometimes grows to a length of 35 feet and longer. It occurs in man, swine, sheep, cats, dogs and rats, monkeys, etc. It is of frequent occurrence in certain parts of Europe, and comparatively rare in North America. The proglottides are about 10 mm. in length and 6 mm. in breadth, and vary in number from 800 to 1000. The cystic entozoön (larva) of *Tænia solium* is called *Cysticercus telæ cellulosæ,* because it frequently was

[1] Latin: *solus,* alone, because it was supposed to be always alone.

found in the cellular tissue, *i.c.*, in the interstitial connective tissue. In man the cystic larvæ often occur in the muscles, in the arachnoid, in the brain, eye, and heart, and may cause severe functional disturbances. The animal most frequently attacked by the cysticercus is the hog (in the muscular and adipose tissue, especially in the omentum).

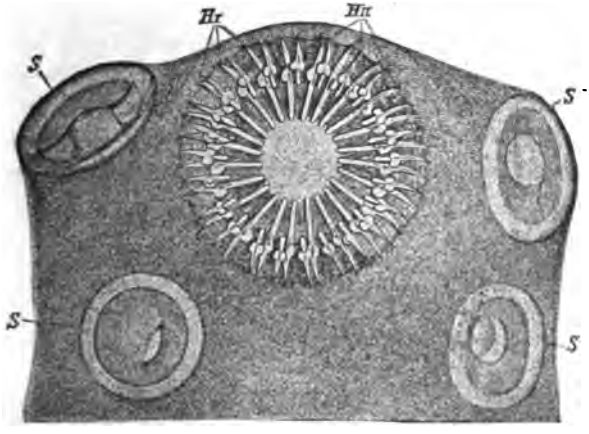

Fig. 167.—Head of Cysticercus cellulosæ. *S*, 4 suckers; H^1, wreath of large hooklets; H^{11}, wreath of small hooklets. (Zeiss Apochr., 16; Comp. Ocul., 4. Reduced ½. After *Langerhans.*)

The cystic entozoön forms a vesicle (cyst; hence, cysticercus) provided with a long, thin process: the neck, upon the end of which is seated a button-shaped enlargement: the head. (See Fig. 170.) The

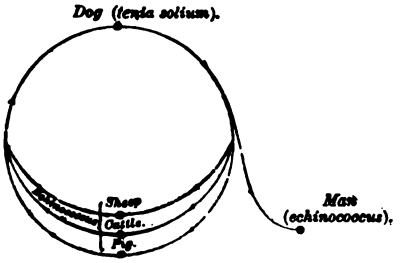

Fig. 168.—Diagram of the hosts of echinococcus. (After *Bollinger.*)

head and neck can be drawn into the cyst (invaginated); they are identical with the head and neck of *Tænia solium.* The *Cysticercus cellulosæ,* therefore, is a tape-worm in which the segments (proglottides) are replaced by a vesicle (cyst). From the cysticercus a tape-worm is developed, the vesicle being cast off and the segments growing from the neck and head. This occurs when a living cysticercus of the swine enters

the human intestine. The three forms—the six-hooked embryo, the cysticercus, and the tape-worm—represent only different stages of development of one and the same individual. Upon the scolex (head and neck) of *Tænia solium* and *Cysticercus cellulosæ* are four equidistant, circular suckers. (See Fig. 167, *S.*) A mouth does not exist. Nourishment is obtained by endosmotic imbibition. If the scolex is viewed from in front, there can be seen between the suckers a number—26 to 28—of large and small, alternating long and short hooklets, arranged in circular or wreath-like form: wreath of hooklets. Between the hooklets can be seen the radiate and concentricly marked musculature, which serves

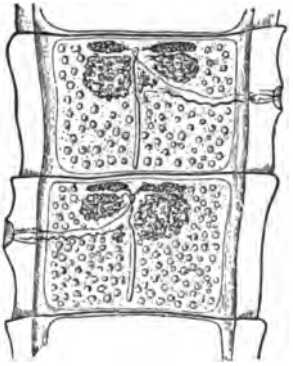

Fig. 169.—Two fairly mature proglottides of Tænia solium, with sexual organs and excretory vessels. Note that the vagina cuts off a small portion of one ovary. (After *C. W. Daniels.*)

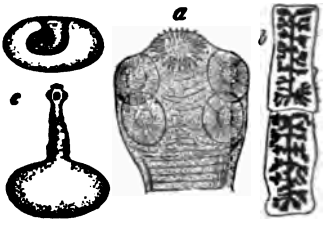

Fig. 170.—Tænia solium. *a*, head; *b*, proglottides; *c*, Cysticercus cellulosæ (invaginated and protruded). (After *Leuckart.*)

for movement of the hooklets. Viewed from the side, a circular prominence: the *rostellum,* which sometimes is pigmented, is seen to surround the crown of hooks. In the interior is a network of water vessels: water system. The most resistant parts are the hooklets. These are chitinous structures, fastened by their bulbous ends to the parenchyma; the free crescentic portion is pointed and can be raised and lowered by the muscles already mentioned, which are inserted into the hook at two points and act antagonisticly. The concentricly lamellated, round or oval, strongly refractive bodies frequently observed upon the neck (readily soluble in HCl, leaving a slightly organized shell) are, like the blackish pigment of the head, indications of somewhat advanced age of the tape-worm. The eggs are oval and have a thick, radiately striated shell, within which can be seen the embryo with six hooklets.

It is not known how long a tape-worm may exist in the intestine. Dead cysticerci, however, are often found. Probably these may live for five or six years. After death they become reduced in size and atrophy.

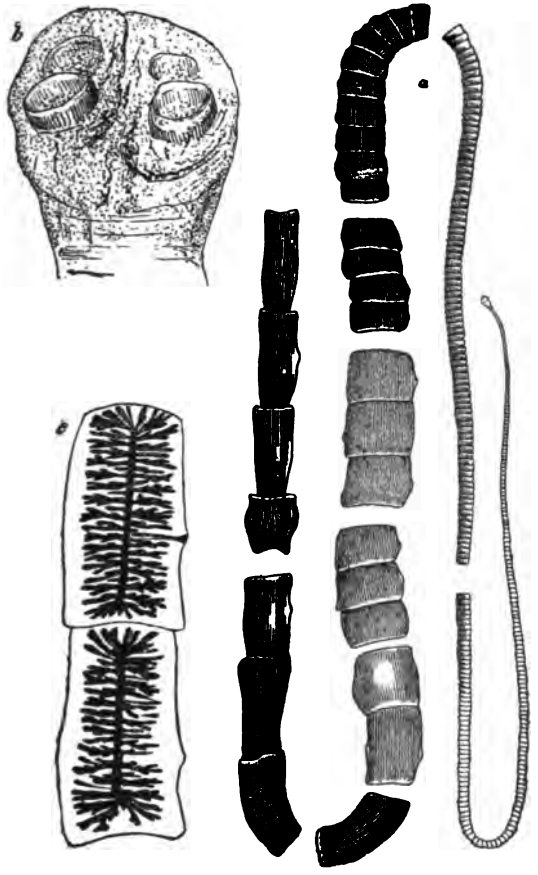

Fig. 171.—Tænia saginata. *a*, natural size of the worm at different sections; *b*, head (with pigment canaliculi); *c*, proglottides. (Partly after *Leuckart*.)

Tænia saginata,[1] *s. mediocanellata, inermis,* unarmed or **beef tape-worm,** is distinguished from *Tænia solium* by the greater length of the whole worm (up to 10 m.—33 feet—and longer) and of the individual segments, which are also broader and thicker. It is the most frequent tape-worm of man. The head is cubic in shape, has no rostellum, in place of which is a sucker-like, often pigmented organ, and no crown of hooklets. The neck is distinctly jointed. The lateral generative

[1] From *saginare:* to fatten, to cram.

opening lies somewhat behind the middle of the segment. In the adult form it is found only in the intestine of man.

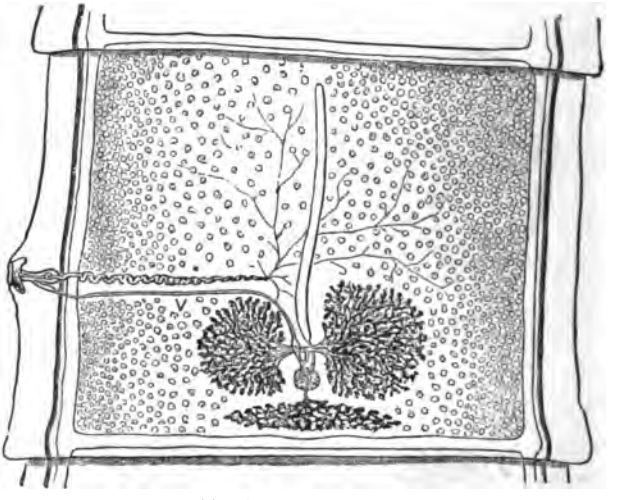

Fig. 172.—Proglottis of Tænia saginata, with genital organs. Note that the vagina, *V*, passes round the left ovary and not through it. (After *C. W. Daniels.*)

The cysticercus of *Tænia saginata: Cysticercus e tænia mediocanellata, Cysticercus bovis,* has the same head as *Tænia saginata* and, therefore, has no hooklets. It is found in the ox, especially in the

Fig. 173.—Two ova of Tænia saginata. (Zeiss Apochr., 4; Comp. Ocul., 8. After *Langerhans.*)

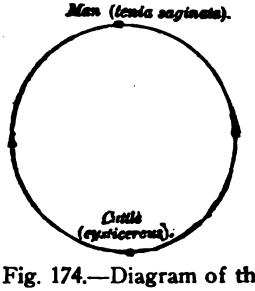

Fig. 174.—Diagram of the hosts of Tænia saginata. (After *Bollinger.*)

muscles (*pteryogoidei externi* and *interni*), rarer in other organs (heart, etc.). It is somewhat smaller than *Cysticercus cellulosæ.*

Tænia africana (von Linstow, 1900) and *Tænia confusa* (Ward, 1896) have been observed in man, the former in German East Africa, the latter in Lincoln, Neb.

Tænia echinococcus (v. Siebold, 1853), dog tape-worm, inhabits the intestinal canal of the dog and wolf. It is at most 5 to 6 mm. in length. The cysticercus stage occurs chiefly in the liver and lungs of the sheep, ox, and especially of the dog. The head is small, 0.3 mm. in width, and has a double row of 28 to 50 hooklets; the rostellum is comparatively large. The hooklets are considerably (about ⅙) smaller than those of *Tænia solium*. To the neck are attached three, at most four, proglottides, of which the last is much longer than the others, and alone contains the fully developed organs of reproduction. *Tænia echinococcus* does not occur in man, but the cysticerci do: *echinococcus polymorphus* (echinococcus cyst), and most frequently in the liver, but also in the lungs, kidneys, spleen, bones, pelvis, nose, brain, etc.



Fig 175.—Tænia echinococcus of the dog. *a*, tænia; *b*, hooklets; *c*, membrane fragment. (After *Leuckart*.)



Fig. 176. — Lamellated echinococcus membrane. (Zeiss Apochr., 16; Comp. Ocul., 4. After *Langerhans*.)

Echinococcus forms a cyst (so-called mother-cyst) *echinococcus unilocularis*, which is firmly inclosed by an envelope, consisting of a reactive connective-tissue capsule derived from the surrounding tissue. The mother-cyst consists of two different layers: the external is semitranslucent, grayish white, chitinous, and has a distinctly lamellated structure (see Fig. 176); the external lamellæ of this layer are the oldest; the internal the youngest. The lamellæ are probably a product of the internal, nonlamellated layer. This is the thinnest, is highly granular, and forms the true germinal or parenchymatous layer (endocyst). Upon the internal surface of the parenchymatous layer are seated the so-called brood-capsules attached by a pedicle. The mother-cyst contains also a quite clear liquid, almost entirely free of albumin, and depositing a sediment. This fluid has a specific gravity of from 1.009 to 1.015, and contains large amounts of leucin and tyrosin. Traces of succinic acid, inosite, and sodium chloride, and sometimes large amounts of cholesterin, are found in this fluid. Hematoidin crystals are rarely observed, most frequently in *echinococcus multilocularis*. (See p. 388.) Echinococcus of the

liver usually contains grape-sugar, and renal echinococci sometimes contain crystals of uric acid, calcium oxalate, triple phosphate, and other earthy urinary constituents. The sediment of echinococcus fluid consists microscopicly of small vesicles: the so-called brood-capsules.

The brood-capsules are local formations of the inner membrane of the mother-cyst: *i.e.*, of the germinal layer. They have thin walls, about 0.004 mm. thick. In these also two layers can be distinguished: a delicate, sharply defined internal cuticula, which lines a cavity, and an external, which has the same structure as the germinal or parenchymatous layer of the mother-cyst. Both these layers, there-

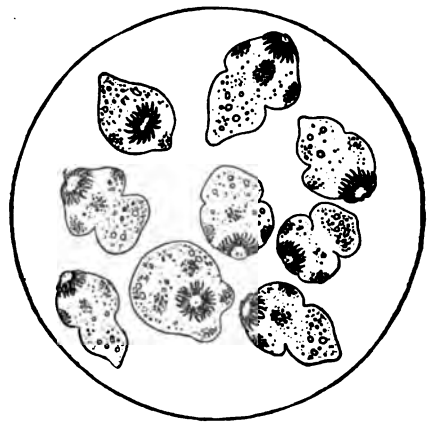

Fig. 177.—From an echinococcic cyst. × 350. (After *Lenharts.*)

fore, occupy a position the reverse of what is observed in the layers of the mother-cyst; they are, therefore, inversions (invaginations) of the latter. According to Leuckart, echinococcus heads develop from the external layer of the brood-capsules: the external layer becomes thickened, forms a protuberance or bud, gradually increases in size and length, and finally attains a cylindric, club-, or pear- shaped form. These protuberances are not solid, but hollow; the canal in the interior communicates directly with the cavity of the brood-capsule. At a later stage of development of the club- or pear- shaped protuberance into an echinococcus head, the latter is invaginated into the cavity of the brood-capsule and is now situated in the interior of the brood-capsule, being connected with the inner surface of the latter by a thin, muscular pedicle. As a rule, not one animal—one tape-worm head—is found in one brood-capsule, but a colony of them.

In the mature state the echinococcus head is an elongated structure in which three portions can be distinguished: anteriorly, the short

rostellum with wreath of hooklets, in the middle a broad segment with four suckers, and posteriorly a cylindric portion, somewhat rounded at the base, which forms the neck of the subsequent tape-worm, and which is attached to the brood-capsule by a slender, muscular pedicle. In the

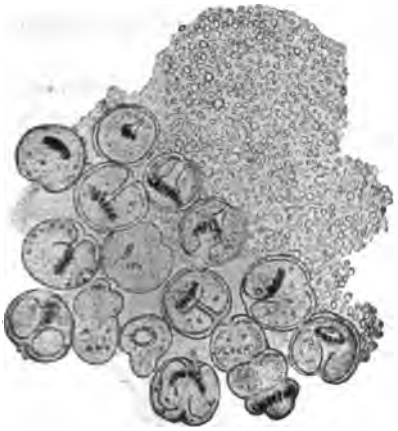

Fig. 178.—Echinococcus heads from a brood-capsule, still partly adherent; slightly enlarged. (After *Langerhans.*)

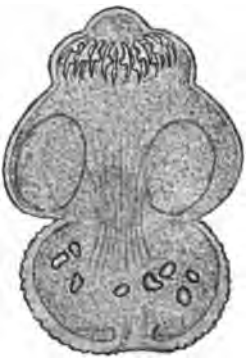

Fig. 179.—Developed echinococcus head. (Zeiss Apochr., 8; Comp. Ocul., 8. Reduced ⅓. After *Langerhans.*)

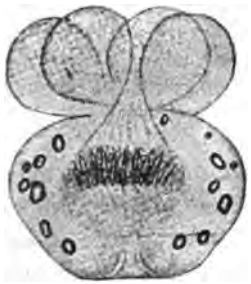

Fig. 180.—Echinoccocus head with retracted wreath of hooklets; suckers not retracted. (Zeiss Apochr., 8; Comp. Ocul., 8. Reduced ⅓. After *Langerhans.*)

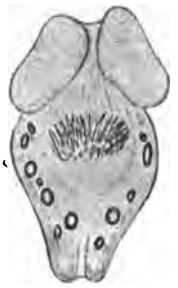

Fig. 181.—Echinococcus head with retracted wreath of hooklets; suckers not retracted. (Zeiss Apochr., 8; Comp. Ocul., 8. Reduced ⅓. After *Langerhans.*)

extended state the length of the whole echinococcus head is 0.3 mm. Invagination of the anterior portion (*i.e.*, the anterior head and armed rostellum) into the posterior portion usually occurs as soon as the echinococcus head—the subsequent scolex of the tape-worm—is fully developed. In this manner an almost round formation, about 0.18 mm.

in diameter, is produced. The points of the hooklets are then usually directed upward and outward. (See Figs. 180, 181, 182, 183, inclusive.)

The hooklets are about one-sixth the size of the cysticercus hooklets. The posterior segment of the head, which often appears to be separated from the middle segment (with the suckers) by a circular constriction, usually contains numerous, highly refractive calcareous granules.

While *Cysticercus cellulosæ* is always solitary, the echinococcus occurs in colonies, a number of cysts being inclosed within each other.



Fig. 182.—Echinococcus head with two retracted suckers and obliquely placed, but well developed wreath of hooklets. (Zeiss Apochr., 8; Comp. Ocul., 8. After *Langerhans*.)

Fig. 183.—Young tape-worm head with muscular pedicle at the base. Only the suckers are invaginated, not the hooklets. Rostellum is very distinct and somewhat protruded. (Zeiss Apochr., 16; Comp. Ocul., 8. Reduced ⅓. After *Langerhans*.)

Echinococcus multilocularis occurs almost always in the liver, rarely in the brain, spleen, and suprarenals, and is composed of vesicles, ranging to the size of a pea, separated by liver tissue. Little is known of its development. It is characterized by the fact that only a small portion forms scolices, the majority remaining sterile. The growth may attain the size of a child's head.

The echinococcus cysts grow slowly, but constantly. After eight weeks they are about 1 to 1¼ mm. in size. The first brood-capsules appear upon the inner surface of the germinal layer after about five months. Echinococcus cysts of walnut- to apple- size are most frequently observed; sometimes, however, they attain enormous dimensions, provided a disturbance which causes their early death does not occur. Dead echinococci atrophy and finally calcify. On the other hand, they may suppurate, occasionally penetrate the intestinal canal

or lungs, and in the latter instance be expectorated. A portion of the liver tissue atrophies as the result of pressure of the echinococcus cysts.

The importance of the echinococcus for the human organism essentially depends upon the location, the size, and the manifold secondary

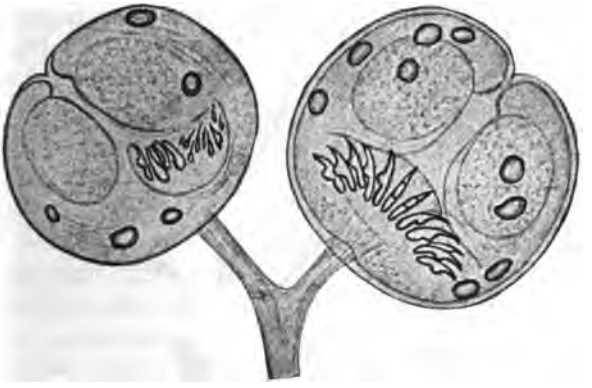

Fig. 184.—Two echinococcus heads united by a muscular pedicle. The larger echinococcus head is well developed; wreath of hooklets and suckers are invaginated. The smaller echinococcus head, to the left, has a poorly developed, obliquely placed wreath of hooklets consisting of rudimentary hooklets. (Zeiss Apochr., 8; Comp. Ocul., 8. After *Langerhans.*)

disturbances. If the cyst ruptures internally, violent inflammations result; if it ruptures into the vascular system, embolic metastases are formed. Suppuration, in which the whole cyst is usually involved, is

Fig. 185.—Anterior portion of an echinococcus head with rudimentarily developed wreath of hooklets. Rostellum large and protruded. (Zeiss Apochr., 8; Comp. Ocul., 8. Reduced ⅓. After *Langerhans.*)

followed by partial or general peritonitis if the echinococcus is seated near the peritoneum. In other cases suppuration is localized and sometimes terminates in healing. In dead and suppurating echinococcus cysts it is often very difficult to recognize the condition. The demonstration of the small hooklets, if present, is easiest, since these are very

resistant and last to disappear; it is often, however, very hard to demonstrate the hooklets, especially when they are atypical in form and manifest deviations, such as are illustrated in Figs. 184, 185, and especially Fig. 186.

Sparganum proliferum, a cestode worm inclosed in a spheric or ovoid capsule, about 1 to 2 mm. in size, sometimes larger (2.5 mm. in

Fig. 186.—Echinococcus hooklets of which only the first five are developed and normal; the remainder are pathologic, rudimentary; those in the last row are scarcely recognizable as echinococcus hooklets. (Zeiss Apochr., 8; Comp. Ocul., 8. After *Langerhans.*)

width and 8 mm. in length), situated in the corium, subcutaneous and intermuscular tissues. It produces an acne-like lesion. The chief peculiarities are its "irregular shape and reproduction in the larval stage by formation of supernumerary heads which may become independent and wander through the tissue." (Stiles.) The heads have no suckers. Two cases have been observed: one, a man, 48 years of age,

Fig. 187.—Two concentricly lamellated lime-corpuscles from an echinococcus head. (Zeiss Apochr., 16; Comp. Ocul., 12. After *Langerhans.*)

living in Florida; the other a woman, 33 years of age, living in Japan. In the man the infection had existed for twenty-five years; in the woman for over three years. The life history and mode of infection are unknown.

Dibothriocephalus latus, *Tænia lata* (Linné, 1748), *Bothriocephalus latus* (Bremser, 1819), Swiss or broad tape-worm, looks like a tape-worm, and for this reason was formerly called *Tænia lata.* The head is without hooklets, knob-like in shape, somewhat flattened, and has two

fissure-like suckers upon its lateral margins. The neck is long, thin, and thread-like. The segments are broader than long, and measure up to 12 mm. in breadth. The genital opening is situated in the middle, upon the surface, not on the margin. It is the longest tape-worm, measuring up to 9 m. (28 feet) or more in length. It occurs in Europe, Africa, Japan, and North America. In Europe, Russia, Norway, and western Switzerland (Lake Geneva, etc.) especially, are the localities where many persons suffer from *Dibothriocephalus latus*. The cysticerci of dibothriocephalus are found principally in fish (pike, salmon, perch, sea-trout, etc.). Man is infected through ingestion of raw or insufficiently cooked fish. Drinking-water is considered a means of conveyance. It causes nervous and gastric disturbances, and not infrequently profound anemia. The latter is said to be due to a toxin secreted by the worm. (See Fig. 190.)

Fig. 188.—Two proglottides of Dibothriocephalus latus. Enlarged 8 times. (After *Langerhans*.)

Another variety, known as **Dibothriocephalus cordatus** (Leuckart, 1863), infests the inhabitants and the walrus, seal, and dog of Iceland and northern Greenland. The larvæ are found in fish.

Dibothriocephalus mansoni (Cobbold, 1883), found by Manson at autopsy in the peritoneum and abdominal cavity of a Chinaman in Amoy.

Fig. 189.—Two ova of Dibothriocephalus latus. *a*, with lid; *b*, without lid. The contents have been partly expelled from the latter. (Leitz Obj., 6; Ocul., 3. After *Langerhans*.)

Tape-worm generally irritates the wall of the intestine. This irritation of the intestinal nerves may cause various reflex actions, *e.g.*, salivation, dilation of the pupil, vomiting of watery or slimy masses, sometimes even convulsions. The irritation is always functional, *i.e.*,

upon the nerves, never nutritive or formative in nature. Hence, anatomic alterations of the intestine never occur.

The **protozoa** are microscopic animals in which no structure of tissues or organs can be made out. In man occur: ***rhizopoda, flagellata, sporozoa,*** and ***infusoria.***

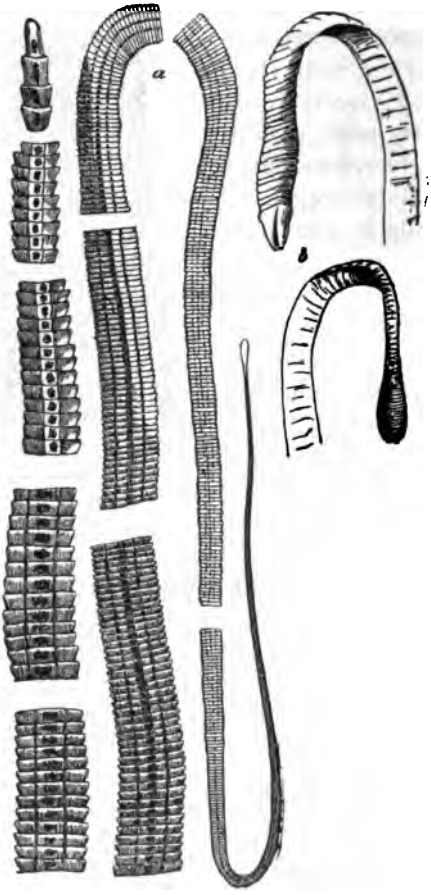

Fig. 190.—Dibothriocephalus latus. *a*, worm, in sections; natural size; *b*, head, lateral and front views. (After *Leuckart.*)

The **rhizopoda** are represented by *Entamœba coli* (*Vulgaris mitis, dysenteriæ*). The amebæ are the simplest forms of animal life. They are small masses of protoplasm, with a clear vesicle as nucleus, which possess the ability to undergo changes of form consisting of protrusions and withdrawals of substance: ***pseudopodia,*** and in this manner secure the power of locomotion.

Entamœba (*amœba coli*) *dysenteriæ* (Loesch, Councilman and Lafleur) is from 20 to 30 μ in diameter. It is frequently demonstrated in tropic and subtropic regions as the cause of chronic (tropic) dysentery. If hepatic abscesses follow this form of dysentery, as not infrequently is the case, the same amebæ are found also in the pus (Kartulis, Councilman and Lafleur). In the intestine propagation of the ameba occurs by simple division; transmission to other hosts probably occurs by encysted forms, in which the nucleus divides into a number of parts, each surrounded by its own protoplasm.

Entamœba histolytica, a species described by Schaudinn, is regarded by many as identical with *Entamœba dysenteriæ.*

Entamœba tetragena occurs in South America, southwest Africa, India, and Egypt.

Dysentery has been produced in cats by rectal inoculation with both *Entamœba histolytica* and *Entamœba tetragena.* As pure cultures of these

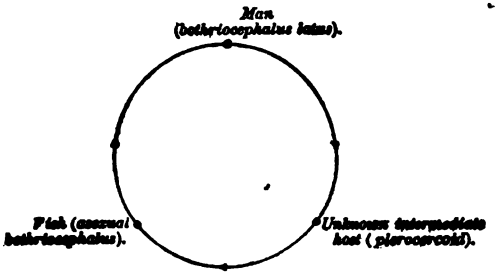

Fig. 191.—Diagram of hosts of Dibothricephalus latus. (After *Bollinger.*)

amebæ have not as yet been obtained, the experimental results must be accepted with a certain degree of reserve.

Mixed infection with bacilli and amebæ is not infrequent.

Flagellata s. mastigophora.—*Trichomonas vaginalis* (Lambl, 1837), *s. intestinalis, s. pulmonalis:* ovoid or pear-shaped body with three or four flagella upon one extremity and an undulating membrane running spirally across the body. Propagation occurs by fission. It occurs at all ages in the vaginal mucus; in young girls especially in catarrhal vaginitis. It is said to occur also in the oral cavity, stomach, small intestine, and colon (*Tr. intestinalis*), in the male urethra, and also in the lungs (*Tr. pulmonalis*). Drinking-water is supposed to be the medium through which it is introduced into man, probably causing diarrhea.

Lamblia intestinalis (Lambl, 1859), *Megastoma entericum* (Lambl, 1859), *Cercomonas intestinalis,* is a parasite regarded by many as pathogenic in man. It has a pear-shaped body, a kidney-shaped cavity at the thick anterior end, and four pairs of flagella: three pairs on the

body and one pair at the pointed extremity. It occurs in the small intestine of rats, rabbits, cats, dogs, sheep, and man.

Cercomonas hominis (Davaine, 1854). The body is pear-shaped with a long flagellum at the rounded end. It occurs in the intestine and air passages, and has been found in the sputum, in pleural exudates, and echinococcus cyst of the liver.

Monas pyophilia is a flagellate, resembling a large spermatozoön, found by Grimm in the sputum and pus in a case of abscess of the lung and liver.

Trypanosomata. —The trypanosomes, which belong to the flagellata, were observed by Gluge, in 1841, in the blood of frogs, and named by

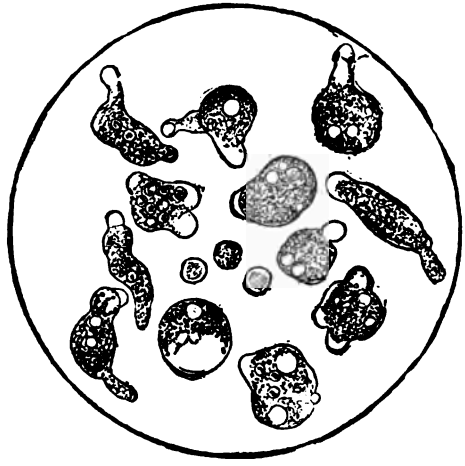

Fig. 192.—Amœba coli. From dysenteric stool. (Zeiss Apochr., 1; oil immersion, 1/12. (After *Lösch.*)

Gruby, in 1843. They subsequently were found in the blood of a number of warm- and cold- blooded animals, in the pathology of which they play an important rôle. Within recent years they have been demonstrated to be the cause of tropic affections of man (trypanosomiasis). (For Fig. 193, see Plate IV, Fig. 4.)

The trypanosomes have an undulating membrane running along the edge of the body, a large nucleus near the center of the body, a chromatin mass called centrosome, micronucleus or blepharoplast, near the anterior pole, and upon the posterior pole a long, slender flagellum, which originates in the blepharoplast. Propagation occurs by longitudinal fission and also sexually by union of macrospores and microspores—gametes. They require an intermediate host for continuance of their existence. The following species are of most importance:—

Trypanosoma lewisi was observed in 1878, in India, by Lewis, in the blood of rats. According to Prowazek, transmission from rat to rat takes place by a species of louse. More recent investigation shows that the rat-flea (*Ceratophyllus fasciatus*) can transmit the trypanosoma from infected to noninfected rats. This trypanosome has been artificially cultivated in the condensation water of blood-agar by Novy and McNeal. Serum of infected rats protected white rats from infection.

Trypanosoma brucei, discovered by Bruce, causes the tsetse disease, or nagana, in horses, donkeys, cattle, mules, cats, buffalo, and swine. Transmission occurs through species of the tsetse fly (*Glossina mor-*

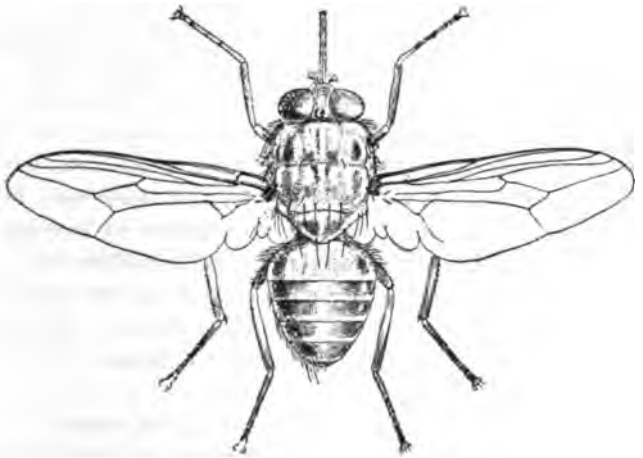

Fig. 194.—Glossina morsitans. (After *Daniels.*)

sitans, furca, and *pallidipes*). Antelopes are said to be the host of this species of trypanosome.

Trypanosoma evansi, discovered by Evans, in 1880, causes the disease known as "surra," which occurs in India and the Philippines in horses, donkeys, camels, caribou, and elephants. Transmission is said to occur through species of gadfly (*Tabanidæ*) and storm fly (*Stomoxys calcitrans*).

Trypanosoma equiperdum (Rouget, 1894) causes dourine, or equine syphilis, in northern Africa, western Asia, and southeastern Europe.

Trypanosoma equinum (Elmassian, 1901) occurs in South America and causes the disease known as "mal de Caderas," or sacral paralysis of horses.

Trypanosoma theileri occurs in cattle in South Africa.

Trypanosoma dimorphon occurs in horses and cattle.

Trypanosoma gambiense (Dutton) occurs in man. It is the cause of sleeping sickness (*trypanosomiasis*), the habitat of which is in the swamp regions of equatorial Africa—Congo States, Portuguese West Africa, and along the Niger and Congo Rivers in Central Africa.[1] From there it has spread toward the Albert Nyanza, British East Africa, Uganda, and Victoria Nyanza. While the disease is widely prevalent among negroes, the white race is not exempt. Castellani was the first to discover trypanosomes in the cerebrospinal fluid of victims of sleeping sickness. The infection assumes a chronic course, and is characterized by anemia, erythema, headache, fever, vertigo, and lassitude. Emaciation, glandular swellings, edema of the body and extremities, and enlargement of the spleen subsequently develop. In addition to excitation stadia, epileptiform seizures are observed, and in the last stage an almost uninterrupted sleep. Symptoms of the disease may not occur until after a number of years. In most cases the disease terminates in purulent cerebrospinal meningitis. Transmission takes place by a biting fly, the *Glossina palpalis*. Streptococci have been abundantly found in the lumbar fluid and in the brain tissue, and these may be assumed to play a rôle in the meningitis and other symptoms of sleeping sickness. *Trypanosoma gambiense* can experimentally be transmitted to rats, mice, rabbits, dogs, and monkeys, usually with fatal result, but it has thus far been impossible to produce in any of these animals a disease like the sleeping sickness of man. It is probable that cattle and certain antelopes may act as hosts.

Trypanosoma (*Schizotrypanum*) *cruzi*.—Quite recently C. Chagos[2] found in Brazilian houses a bug, called *Conorhinus megistus*, the blood of which contained trypanosomes. The insect bites the face of man, mostly at night. Fever, edema, and swelling of the lower eyelids occur. The disease generally terminates fatally. Trypanosomes are found in the blood of patients.

In **kala-azar** (black fever), febrile **tropic**, nonmalarial **splenomegaly**, peculiar small formations, designated as Leishman-Donovan bodies, or corpuscles, are found within the endothelial cells of the capillaries of the liver, spleen, bone-marrow, and lymph-glands, and occasionally also free in the blood and within the white blood-corpuscles.

[1] According to Scheube (see footnote, p. 567), the first report of the sleeping sickness in negroes was given in 1793 by Winterbottom, in "An Account of the Native Africans in the Neighborhood of Sierra Leone." Subsequently reports were issued of its occurrence in negro slaves in the Antilles and in other parts of the west African coast. The marked spread of the malady and its appearance in East Africa led, toward the end of the past and the beginning of the present century, to the sending of medical expeditions to investigate the disease, first by Portugal, then by England and Germany.

[2] Brazil medico, April 22, 1909.

Inoculated upon blood-agar these bodies develop into trypanosome-like, flagellated, actively motile structures, which increase by longitudinal division, but do not possess an undulating membrane. Fever, at first intermittent, later continuous; gastrointestinal disturbances, swelling of the liver and spleen, edema, anemia, and exhaustion are the chief symptoms. Hemorrhages into the skin, brain, and mucous membranes, and sometimes ulceration of the oral mucous membrane and of the intestine also occur. The disease is assumed to be transmitted by biting insects.

Leishman-Donovan bodies are found in the tissues also in so-called Delhi sore, oriental boil, tropical ulcer, which is characterized by the successive formation of a papule, pustule, and painless, indolent ulcer upon surfaces exposed to insect stings. The usually multiple ulcers heal slowly, leaving radiate, pigmented cicatrices. Occasionally the ulcers are the seat of violent inflammation.

Sporozoa.

The sporozoa are unicellular protozoa with cuticula and nucleus, without organs of locomotion (*i.e.*, without pseudopodia, flagella, cilia). They perpetuate themselves by endogenous spores. Several suborders may be distinguished: *coccidia, gregarinida, hæmosporidia, sarcosporidia,* and *myxosporidia.*

The **coccidia** are ovoid and spheric bodies which, in their early stages, are membraneless, protoplasmic masses and inhabit epithelial cells; later, when developed, they are surrounded by a capsule and form spheric and rod-shaped endogenous spores. The latter are set free by death of the cells and rupture of the capsules, and enter other epithelial cells.

The coccidia develop by alternation of generation, *i.e.*, by sexual and asexual increase. Asexual development is completed within the host (endogenous increase: *schizogony*), by which the original germ (*schizont*) forms young individuals (*merozoites*) by simple fission. Sexual development occurs outside the host upon the ground (exogenous increase: *sporogony*), in which the sporont produces young individuals (*sporozoites*) by sporulation. The merozoites are distinguished from the sporozoites by the presence of a karyosome (nucleolus). The merozoites produced by schizogony do not, as a rule, escape outward, but reinfect new epithelial cells and so forth until exhaustion of asexual propagation. Then the merozoites in the epithelial cells begin to form sexual individuals (*gametes*); the males (*microgametocytes*) have a clear, the females (*macrogametes*) a coarsely granular, protoplasm. The microgametocyte elements consist essentially of nucleus and two flagella (the *microgametes*), which copulate with the macrogametes. After the latter have cast out a part of the karyosome, karyogamy of both sexual nuclei and the formation of a membrane around the parasites occur. In this manner originates the sporozont or the *oöcyst.* In these, when they reach the outside, develop four encysted sporoblasts, which, in turn, produce each two sickle-formed

sporozoites. If these now enter the intestine, they infect the epithelial cells and become schizonts.

In rabbits (**Eimeria stiedæ**) *Coccidium cuniculi* (*oviforme*) produces large, yellow nodules in the liver, causing icterus, interstitial hepatitis, and, finally, death. This parasite occurs very rarely in the human liver. Other species which have been observed in man are: *Coccidium hominis* and *C. bigeminum.*

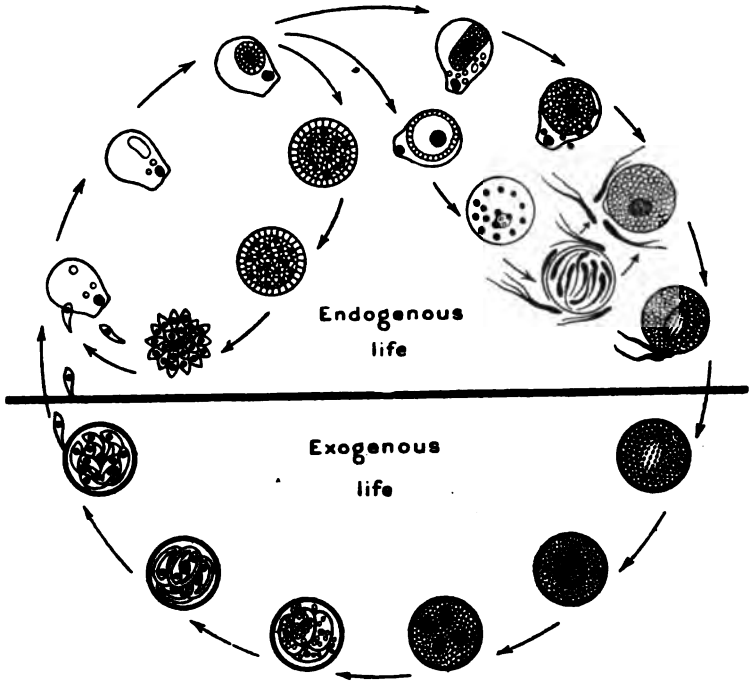

Fig. 195.—Coccidia. (After *Daniels.*)

The *gregarinida* are minute, round, or elongated formations inhabiting the cells of worms and echinoderms.

The *hæmosporidia* are about the same size and shape as the gregarinida, and are found within the red blood-corpuscles of crows, owls, woodpeckers, and frogs. In man they are the cause of intermittent or malarial fever.

HÆMOSPORIDIA; MALARIA.

Although malaria occurs almost everywhere in a zone of 40 south to 60 north latitude, it is essentially a disease of warm countries. Only elevations in which the temperature is too low for the development

of mosquitoes and perfectly dry regions, like the Sahara and the deserts of the western parts of the United States, are exempt. In the temperate zone the disease occurs chiefly in midsummer and autumn; in hot countries the beginning and especially the end of the rainy season are the chief periods. Unlike the majority of infectious diseases, malaria is never directly conveyed from man to man. It is, therefore, in no sense contagious. In order for a healthy person to be infected, the blood from an individual suffering from malaria must artificially be injected into the blood-channels, or the causative agent introduced through the sting of an insect in the manner subsequently to be described.

It is doubtful whether the malaria parasite passes from mother to fetus. Pepozoulos and Cardamatis[1] examined most thoroughly six newborn of malarial mothers. The blood of the placenta on the maternal side contained numerous plasmodia, but none was found on the fetal side. The same results were obtained also in the umbilical cord. These authors were thus able to confirm the statements of Bignami and Sereni, to the effect that malarial infection of the mother exerts no influence upon the development of the fetus. (See p. 408.)

Until a short time ago malaria was considered to be the type of a so-called miasmatic disease. Swamps were supposed to be its breeding place; the virus was believed to enter the human body from the soil through the agency of drinking-water, but principally with the air inhaled. This view of the significance of the atmospheric air as the carrier of the disease was so dominant for ages that the malady was designated as malaria, *i.e.*, "bad air."

The living nature of the malarial virus was discovered by Laveran, in 1880. He found in the blood of a remittent fever patient not only the asexual ameboid forms of the parasite, which he called *"corps spheriques pigmentes,"* but also the sexual forms—the crescents—and particularly flagellate forms. Owing to the flagellate forms, Laveran first called the malarial parasite *Oscillaria malariæ*, but soon abandoned this name as inappropriate. Laveran's discovery was confirmed by Richard, in 1882. The Italians, Marchiafava and Celli—to whom Laveran had demonstrated his discovery in 1882—after much opposition finally admitted that the microbe designated as *Plasmodium malariæ*[2] was the parasite of malaria, and that probably it increased by segmentation. Golgi, however, was the first clearly to demonstrate, in the autumn of 1885, the developmental process of the quartan parasite, and in the following year amplified his investigations by the discovery of the tertian parasite and its relation to the course of the fever. In 1890, Marchiafava and Celli recognized the much smaller parasite of estivoautumnal fever as the cause of the true tropical fever and distinguished it from the larger tertian and quartan parasites. In 1897 the sexual forms of the parasite and the significance of the flagella were first correctly interpreted by MacCallum.

The malaria parasites are transparent, unicellular animals, staining with dyes such as methylene-blue. The stained protoplasm shows a nucleus surrounded by an uncolored, so-called

[1] Grece médicale, Oct. 1 and 15, 1906; Ref. Fortschritte der Medizin, 1907, p. 38.
[2] Parasite of quartan fever.

achromatic zone (vesicular nucleus). They belong to the family of protozoa, probably to the class of sporozoa, suborder hæmosporidia, and are true cellular parasites. The minute globular, or disk-shaped, mass of protoplasm, of which they are composed, manifests more or less active ameboid movement, and when brought into the blood attaches itself to a red blood-corpuscle, enters it, grows quite rapidly, sooner or later loses its ameboid movement, and consumes the attacked corpuscle, transforming the red coloring matter—the hemoglobin—into a granular, blackish pigment: melanin. When grown, the parasite divides by segmentation of the nucleus into a limited number of

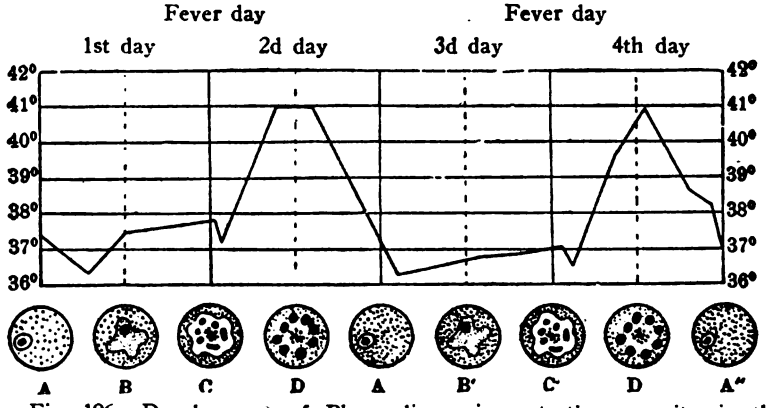

Fig. 196.—Development of Plasmodium vivax, tertian parasite, in the red blood-corpuscle, A, B, C, D, etc., in its relation to the temperature curve of the patient. Schematic. (After *Doflein.*)

parts, varying from 6 to 30 in different varieties—so-called merozoites or schizonts—which enter the blood, attack new red blood-cells, again undergo in them the development already described, and, finally, divide into a similar number of daughter-cells. This cycle of **asexual development** or **schizogony** is repeated again and again, and each outswarming of merozoites and invasion of new red blood-corpuscles always corresponds to a febrile paroxysm. (See Fig. 196.)

Up to the year 1897 there was no knowledge of the manner in which these parasites entered the blood. In 1898, Ronald Ross discovered that a typical malaria of sparrows was always conveyed by the bite of mosquitoes, and he was the first to advance the view that probably human malaria also was disseminated by mosquitoes. The Italian, Bignami, had almost synchronously arrived at the same conclusion in another way. P. Manson also considered mosquitoes to be conveyors of malaria, but he believed that after gorging themselves with malarial blood and

depositing their ova in water they decomposed and thus infected persons who drank such water.[1] The experiments of Ross and Manson upon the rôle of mosquitoes in the propagation of malaria were continued by B. Grassi, and it is principally through his researches, aided by those of a number of other investigators, that we now are fully informed that not any kind of mosquito, but only such as belong to the genera of the *Anophelinæ*, seem capable of conveying the malaria of man. Numerous investigations by Grassi and others showed that mosquitoes of this genera—*Anopheles claviger, quadrimaculata,* or *maculipennis,* etc.—convey malaria only after a certain time: about from ten to thirteen days after it has sucked malaria germs with the blood. (See pp. 402 and 405.)

With the recognition of the definitive host of the parasites and of the life cycle through which they pass in its body, the important rôle played by the sexual forms, until then regarded simply as degeneration products, was at once revealed. The sexual forms alone convey malaria to the mosquito, sexually multiply in it, and, after a certain period of development, wander into man through the bite of the mosquito. This process of sexual propagation in the mosquito is called **sporogony (amphigony).** (See p. 405.)

Among the mosquitoes which are of interest in this regard are to be distinguished the genera *culex* and *anopheles.* Culex is our ordinary mosquito; anopheles the common mosquito of tropical countries. Both are distributed in numerous species over the greater portion of the known regions of the globe. The *culex* species convey the malaria of birds; the *anopheles*[2] convey human malaria from diseased to healthy individuals.

Very numerous species of anopheles are distinguished. According to Grassi, in Italy there are principally four species, the most widely distributed being *Anopheles maculipennis,* then *A. superpictus, A. pseudopictus,* and *A. bifurcatus;* in tropical Africa, the *A. funestus;* in the forest districts of South America, the tiny *Anopheles Lutzii,* all distinguished from each other principally by different spots upon the anterior margin of the brownish wings, and their angular resting posture upon a vertic surface, which are chief characteristics of them. (See Fig. 197.)

[1] Nuttall has shown that much earlier there prevailed in various malarial countries the popular belief that mosquitoes were in some way connected with malarial infection, and Noth, of America, in 1848, asserted that mosquitoes bore a relation to malaria. R. Koch also relates in his reports of his expedition that the negroes of the East African Usambara range called malaria *Albu* or *Mbu,* and that they associate it with mosquitoes, which also they call *Albu.* Likewise, it has recently been demonstrated that the inhabitants of Ceylon have, since ancient times, referred this disease to the bite of certain mosquitoes.

[2] This mosquito was called anopheles, *i.e.,* "no use," by the Swedish naturalist, Linné, one hundred and fifty years ago. According to Craig, of this genus the following have experimentally been shown to transmit the malarial parasite:—

In Africa: *A. costalis, A. paludis, A. funestus.*
In India: *A. sinensis, A. rossii, A. culicifacis, A. theobaldi, A. barbirostis.*
In Europe: *A. superpictus, A. maculipennis, A. bifurcatus.*
In America: *A. maculipennis, A. argyrotarsus.*

The anopheles are easily distinguishable from culex in the egg, larval, and adult forms. The eggs of anopheles are laid singly; the larvæ lie parallel with the surface of the water. As all mosquitoes require water for their development, malarial *prophylaxis* is concerned with the destruction of ponds, pools, or marshes of stagnant water.

Of all biting flies and mosquitoes, only the females suck blood and hence transmit diseases. The males are harmless vegetarians. The females also can live for a long time on vegetable nourishment, but when they have become sexually mature and ready to deposit their ova they require under all circumstances a richly albuminous food, such as blood.



Fig. 197.—*A*, culex at rest; *B*, anopheles at rest.

If the blood of a person who has suffered with malaria for at least eight days is sucked by an anopheles, the asexual malarial germs (schizonts) are digested in the digestive tract along with the red blood-corpuscles. This is not the case, however, with the sexual forms of the parasite (gametes), which appear in the blood of a malarial person from the eighth to the tenth day after onset of the fever. In tropic malaria these appear as crescents and in tertian and quartan fever as large spheres with granular contents, completely filling the attacked red blood-corpuscles. The development of the gametes, which occurs principally in the spleen, bone-marrow, and brain, is slower than that of the schizonts. In the latter the nucleus consists of the intensely staining karyosome and the faintly or non- staining alveolar seam which surrounds it. The cytoplasm of the parasite is extremely finely reticulated. On further growth a clear vacuole appears alongside the nucleus, and the attacked red blood-corpuscle may be stippled, probably by precipitation of a substance digesting it. The ameboid movements of the plasmodium increase; pigment granules appear as excretory products in its interior; the nucleus becomes vacuolated and at first divides by mitosis, later by amitosis. According to the species of plasmodium, from 6 to 30—average 16—daughter-cells are formed, which become free, attack new red blood-cells, develop in them, and asexually divide by fission into the same number of schizonts.

The **gametes,** or **sexual forms,** of the parasite in tertian and quartan infections appear in two forms, namely, as male and female. The latter, the **macrogametes,** are somewhat larger, finely gran-

ular, possess a small chromatin granule, and usually stain more deeply than the **microgametocytes,** or **"sperm cells,"** which, with the same staining, appear paler, possess a large chromatin nucleus, and are strikingly rich in nuclear substance, and, therefore, poor in cytoplasm. In the blood of a malarial person they circulate passively without undergoing any further change, waiting only to be taken into the digestive tract of the mosquito. When this has occurred, that is, when a mosquito has filled its stomach with blood, they are digested along with the red blood-cells. This occurs also in anopheles, but it generally digests only the asexual forms. As long as the temperature is not too low—not below 18° C., in other forms a minimum of 16° C.—new life comes into the thus-far resting gametes. Within ten, at most twenty, minutes after the blood has left the warm body of a malarial person for the relatively cooler stomach of the mosquito, the microgametocytes,

Fig. 198.—Wing of female Anopheles maculipennis, highly magnified, showing spots. The wings of culex are not spotted.

or sperm-cells, shoot forth each six delicate, actively motile threads of living plasma provided with several enlargements. These soon become free, and, as the true **microgametes,** or m a l e s, very actively seek the resting **macrogametes,** or f e m a l e s.[1] The latter have in the mean time protruded some of the nuclear substance as the so-called polar body and present to the microgametes, which they chemicly attract, the "c o n c e p t i o n n o d e." When the fecundating microgamete enters, it is imbedded in hyaline substance, male pronucleus and ovum nucleus coalesce, and cell cleavage begins. Although the macrogametes are always more numerous in the blood than the microgametocytes, all of them are fecundated by the greater number of microgametes thus separated from the microgametocytes.

The fecundated cell very soon becomes spindle-shaped and m o t i l e ; therefore, it has been named o o k i n e t. With the pointed end it bores into or between the epithelial cells of the mosquito's stomach, where it develops by cleavage into a round or spheric body—o o c y s t—about the size of a red blood-corpuscle, which protrudes more and more toward the outer surface. Up to 200 such oöcysts

[1] This process can be observed also in fluid blood preparations on the warm stage of the microscope.

have been observed in a single mosquito stomach. The oöcyst rapidly increases to six to eight times its original size, and within it appear a number of small, round bodies, daughter-cysts or sporoblasts, within which develop great numbers of sporozoites or sickle spores. In the interior of each oöcyst up to 10,000 sporozoites, or sickle spores, named from their shape, are formed: 200 x 10,000 = 2,000,000 in a single mosquito! When ripening of the oöcyst is completed it bursts as a result of the internal pressure of its contents and the sickle spores (young generation of plasmodia) enter the body cavity of the mosquito. From there they are drawn, probably by chemotactic action, into the trilobed salivary

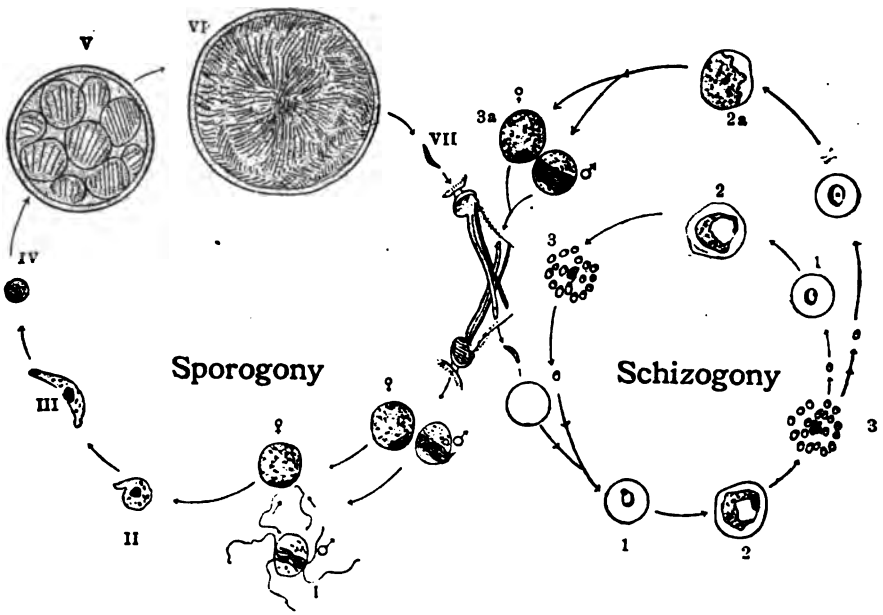

Fig. 199.—Double development of the tertian parasite in human blood and in anopheles. 1-3, development of asexual forms; 1a-3a, development of sexual forms, female ♀ and male ♂; I-III, development of the parasite in the mosquito stomach; I, copulation; the microgametes set free from the microgametocytes; each unites with a female macrogamete. II and III, development of oökinetes; IV and V, development of oöcyst in the stomach wall of the mosquito; VI, cyst with sickle spores; VII, single sickle spore from the salivary gland of the mosquito, entering with the saliva of the mosquito into the blood circulation of man, where development begins anew. (After *R. Ruge.*)

gland of the mosquito, where they temporarily remain imbedded in the cells of the glandular parenchyma until they are injected with the saliva through the hollow, needle-like hypopharynx of the mosquito into the blood-channels of the person bitten. Here the small, actively motile sickle spores enter the red blood-corpuscles, soon swell up in them, at first become ovoid in shape, and after three hours, at latest, are exactly like the asexually developed schizonts. From now on they begin their asexual segmentation in the manner already described.

The spread of malaria occurs, therefore, as it were, in the form of a chain formed alternately by two links, namely, man (or mammal or bird, which also have their particular malarial parasite), and the blood-sucking female mosquito. (See Fig. 199.) The malarial individual, or malarial animal, infects the respective mosquito, and this again infects a healthy man or animal. From a zoölogic standpoint we have to deal, in malaria, with a so-called alternation of generations (*metagenesis*), that is, a sexual generation produces an asexual. This metagenesis, furthermore, is dependent upon a change of host. As the asexual form is adapted to a life in the blood of a warm-blooded animal and dies outside it, the sexual form, on the other hand, requires removal from the blood-channels and transference to the intestines (mesenteron) of a certain species of mosquito in order to copulate and thus complete its cycle. The former process is called **schizogony;** the latter **amphigony** (designated as **sporogony** in the *schema* of Ruge).

The whole process of amphigony, or sexual propagation, of the malarial germ in the mosquito takes place in tropical malaria in eight days at an optimum temperature of from 28° to 30° C.; at lower temperatures more slowly—in from ten to twelve days; in other words, eight days, or from ten to twelve days after an anopheles female has sucked the blood of a malarial person, its sting can convey malaria, and, as has repeatedly been demonstrated, a single bite of an infected anopheles suffices to infect a healthy man with malaria. When the invading germs have sufficiently increased, the first malarial paroxysm begins, after an incubation period of from ten to thirteen days.

Insufficiently treated malarial persons who were infected during the previous summer provide the infectious material for the mosquitoes for the first new infections[1] (malarial parasite carriers).

Mosquitoes convey malaria only in localities where malarial persons are a source of infection, for the malarial parasites die outside the body of the mosquito and are never transmitted to its offspring.

According to numerous investigations, three well-characterized forms of malaria are observed in man, which are produced by specific, but closely related, parasites:—

1. First, the **Plasmodium præcox,** by far the smallest but most malignant form, produces the pernicious malaria of the tropics

[1] In 53 out of 146 persons free from all indications of malaria, G. Ianni (*Il Policlinico,* xvii, No. 49) found malaria plasmodia in the blood. When the parasites were lodged in the internal organs, a therapeutic dose of strychnine caused them to appear in the peripheral circulation within from one-half to one hour.

and the subtertian or **estivoautumnal fever** of the subtropics. Only the young germs of the plasmodium manifest ameboid movements. A number of them (up to five) may attack a single blood-cell, but very soon they come to rest and then usually assume a ring form. The parasite grows to only about one-third the size of the red blood-cell and forms but little pigment. The attacked blood-cell is never paled or enlarged; on the contrary, it is rather shrunken, becomes almost angular, and acquires a peculiar brassy color. After from twenty-four

Fig. 200.—Plasmodium præcox, the parasite of malignant, so-called pernicious, malaria in three different stages of development, inclosed in red blood-corpuscles. (After *Mannaberg.*)

to forty-eight hours the parasite segments into from six to thirty spores, which, becoming free, begin a new cycle. Segmentation occurs almost exclusively in the internal organs, principally in the finest arterial branches of the spleen, brain, and bone-marrow, and intestinal mucosa. After eight days' sojourn in the human blood it forms the sexual forms, the **crescents,** first described by Laveran, which occur in no other form of malaria, and are, therefore, pathognomonic of this variety. The microgametocytes are, in general, somewhat smaller and stain paler

Fig. 201.—Sexual forms of the same; characteristic crescents. Left, two rudimentary crescents inclosed in red blood-corpuscles; the remaining are free, because the attached corpuscles have been consumed. (After *Mannaberg.*)

than the macrogametes. Owing to their development in the internal organs, the segmenting forms of the parasite of this malarial fever, called also **tropic fever,** are seldom found in the peripheral circulation. Ordinarily, they appear here only when these very small rings have become larger. However, a collection of small, delicate rings, which are only one-sixth to one-eighth as large as a red blood-corpuscle, is always pathognomonic of tropic malaria. The most certain are the crescents. (See Fig. 201.)

The *Plasmodium præcox* is constantly endemic only in the tropics; in southern Europe it occurs only during the hottest period, from July to September, for which reason the fever caused by it is called estivo-autumnal. The beginning of this severe form of malaria is usually apparently benign, manifested less by chills than by dull headache and languor, though severe symptoms may very quickly develop from it. The febrile paroxysms then occur not only every two days, but very often every day, so that one speaks of a quotidian, and last considerably longer than in the other forms of malaria, in severe infections even for from thirty-six to forty-eight hours. In the individual attacks the fever does not fall to normal, but lasts as a *continua,* with short remissions. Marked swelling of the spleen and great exhaustion occur, and to these may be added convulsions, syncope, vomiting, and diarrhea, with jaundice, intestinal hemorrhage, long persistent stupor, until finally the patient succumbs to the infection.

In certain regions, such as west and east Africa, but not in India, if quinine is taken prophylactic in large doses for a long time—at least half a year—destruction of the red blood-cells may occur so rapidly after onset of this severest form of malaria that the liver is no longer able to transform the large amount of hemoglobin liberated in the blood into bile-coloring matter; therefore, a greater part of it is excreted through the kidneys, producing hemoglobinuria. The urine voided during the course of the fever then appears dark red to black: **black-water fever.** As a result of the enormous solution of red blood-cells, the renal tubules, on further course of the disease, become completely occluded and no urine can be secreted. Autointoxication of the body; chills, vomiting, and diarrhea set in and death occurs.

After recovery from the first paroxysms there are recurrences and new infections, until finally a chronic malaria, or malarial cachexia, develops, in which, in addition to marked tumor of the spleen, swelling of the liver with icterus, continuous irregular fever, severe digestive disturbances, and increasing anemia, with general debility, occur.

In children this form, like other malarial attacks, often begins with high continued fever, accompanied by convulsions, the characteristic type of disease appearing only after a time. In old persons, on the other hand, the severe form often progresses with only moderate fever; but in spite of this, great drowsiness and exhaustion very rapidly occur, which may often unexpectedly and rapidly cause death.

The dark-skinned native, especially adult negroes, is much less susceptible to the severe form, as well as to any form of malarial infection, than Europeans. This was believed to be due to immunity acquired in the course of many generations; we now know, however, that this is incorrect. The adult blacks are immune only because they

have had the disease in childhood, and thus have acquired immunity.

The mortality of pernicious malaria is very high among Europeans, and may reach 50 per cent.; from 20 to 30 per cent. is said to be the average mortality. Malarial women abort very often; for example, it is said that 46.6 per cent. of pregnancies in India are interrupted by malaria.

2. The **Plasmodium vivax (tertian parasite)** is the largest of the three species of malarial plasmodia. It usually singly attacks a red blood-corpuscle, which it finally consumes. It grows rapidly, shows active ameboid movements by protrusion of pseudopodia, forms a large amount of finely granular pigment, and strongly distends the



Fig. 202.—Plasmodium vivax, parasite of tertian fever. In the upper row and on left of lower row, various stages of intracorpuscular development; the two last figures in lower row are free sexual individuals, microgametocytes (sperm cells) which are about to set free the microgametes or males. (After *Reinhardt.*)

invaded red blood-cell, which shows changes in staining properties—when stained with methylene-blue it has a pale-green color. A new generation is developed every forty-eight hours, whereby the mother-cell at the beginning of the febrile paroxysm—in the chill stage—divides into from eighteen to twenty-four daughter-cells: so-called schizonts. This development occurs also in the internal organs, principally in the spleen and bone-marrow, though, in contradistinction to the tropic form, numerous segmenting stages are found also in the peripheral blood, so that the growth of the parasite can be followed from beginning to end in preparations made from the blood of the patient. As the parasite causes a febrile paroxysm every third day, this form is called tertian fever. On microscopic examination of the blood the finding, in enlarged red blood-corpuscles, of plasmodia presenting pseudopodia is proof of the tertian parasite. Eight days after infection the sexual forms, or gametes,

PLATE IV

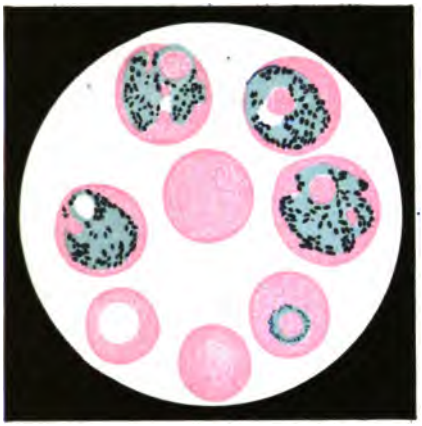

Fig. 1

Fig. 2

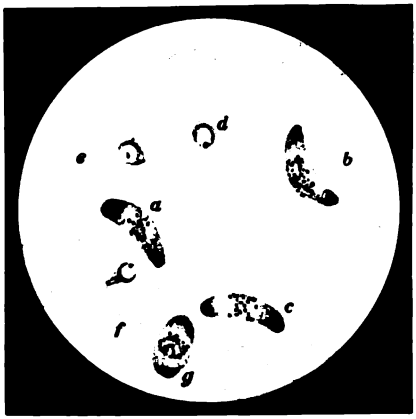

Fig. 3

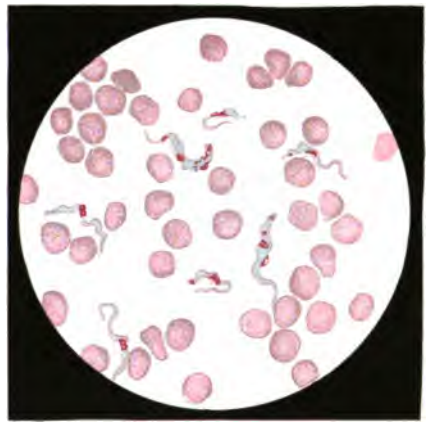

Fig. 4

Fig. 1.—Malaria plasmodia, tertian type; Plehn-Chenzinsky stain. Zeiss Comp. Ocul., 8; Apoch. × 1000. (After *Lenhartz-Brooks.*)

Fig. 2.—Malaria plasmodia, tropic form; Plehn-Chenzinsky stain. Composite picture from several microscope fields. × 1000. (After *Lenhartz-Brooks.*)

Fig. 3.—Malaria plasmodia, tropic form; rings and crescents. Composite picture of four microscope fields, viz.: *a* and *b* were in the first field; *c* and *d* in the second; *e* and *f* in the third, and *g* in the fourth. Besides rings (*d, e, f*) and free crescents (*a, c, g*) one with a hood-like protoplasmic remnant of the attacked red blood-cell. × 800. (After *Lenhartz.*)

Fig. 4.—Trypanosomes. Specimen made from spinal fluid from a case of sleeping sickness. One field. Giemsa stain. × 500. (After *Lenhartz.*)

appear, always in the form of very richly pigmented spherules. The female gametes, in general, appear somewhat larger and more deeply stained than the males, which stain paler, but have a larger chromatin body. In this form also the process of development of the gametes is completed in the body of anopheles in eight days at a temperature of 28° C. Further development is impossible at a temperature of 17° C., or lower. This fact corresponds with the distribution of *Plasmodium vivax,* which, outside the tropics and subtropics, may extend during the warm periods of the year over the temperate zone.

3. The quartan form of malaria is produced by the **quartan parasite,** discovered by Laveran, and called by him **Plasmodium malariæ.** This form is difficult to cure, and occasionally gives rise to pernicious attacks. It is much more sluggish, and grows slower than either of the other varieties. The spheric young parasite attacks



Fig. 203.—The asexual development of Plasmodium malariæ, quartan parasite: 1-4, in red blood-corpuscles; 5, schizonts arranged radiately, the corpuscle completely destroyed, only a central clump of melanin granules remaining; 6, single schizonts separating from each other. (After *Golgi.*)

a red blood-cell, within which it grows slowly and without distinct motility. From it sometimes develop small bands, which gradually become broader, and are provided with partly actively oscillating pigment-granules. The attacked blood-corpuscle is not enlarged, and stains like a normal cell. The development stages of the parasite can very easily be followed in the peripheral blood. The growth of the sexual parasite is ended in seventy-two hours, and it, therefore, produces a febrile paroxysm every fourth day; hence, this fever is called quartan fever, or *quartana.* Segmentation of the developed quartan parasite begins three hours before the expected febrile paroxysm, and may not be completed until several hours after appearance of the fever. Only from eight to twelve young parasites (spores) are formed, the pigment, consisting of the blood-crystals, as remains of the digested red blood-cell, generally collecting in a cluster in the middle (daisy form), less often anywhere at the margin, of the young parasite (spore) group. The digested blood-corpuscle then bursts, the young parasites disperse and attack new red blood-cells, whereby the febrile paroxysm originates. The pigment cir-

culates in the blood until it finally is arrested in the capillaries of the spleen and liver, where it is deposited and rendered harmless.

The sexual forms, the gametes, appearing at earliest ten days after the first febrile attack, occur in this form quite sparingly. Like the previously described variety, they are spheric, never crescentic. Here, also, the microgametocytes stain less intensely than the macrogametes, whose chromatin body is smaller. Their fecundation and further development in anopheles progress at a temperature of 18.5° C., but not at 30° C.; therefore, the area of distribution of this form of malaria most often extends toward the poles, and much less toward the equator than the previously described more severe forms. It is the form of malaria usually observed in south Europe, United States (?), and is found sporadicly even as far north as the Tundra of Lapland and Siberia.

According to the number of infections, many generations of the same form, or different forms, of malaria may coexist in the blood of one patient. Strange to say—probably because they were inoculated from the anopheles into the human body at the same time at evening—they are usually about twenty-four hours apart in their development. Thus, in **double tertian** and in **triple quartan** a febrile paroxysm occurs every day; in **double quartan** a paroxysm occurs on two successive days, but none on the third day. Occasionally tertian and quartan forms occur in the same individual, producing quite complicated febrile curves and symptom-complexes.

Of all these varieties of malaria the tropic form is the most frequent, not only in the tropics, but also in the subtropics. The tertian variety is almost as frequent there, while the quartan form is relatively very rare. For example, the lowlands of India gave the following ratio of relative frequency, based upon a large amount of clinic material:—

Tropic	48	per cent.
Tertian	46	" "
Quartan	3	" "
Mixed infection of tertian and tropic	3	" "

Here, therefore, the most malignant forms of the disease are most frequent. In the subtropics, on the other hand, tertian and quartan are more frequent; in the most northern malarial countries quartan, owing to its relatively slight demands of temperature for the development of its sexual forms in the mosquito, preponderates by far.

One can very easily be convinced of the enormous injury which even a relatively benign malarial infection exerts upon the blood of the infected person. Even after a few febrile attacks the number of red blood-corpuscles falls considerably. From 5,000,000 per cubic millimeter they finally sink to half this number and lower; indeed, in extreme cases the number of red blood-corpuscles has been observed to fall as low as 500,000 per cubic millimeter, which, of course, is incom-

patible with further life of the infected individual. The most destructive is the tropic form. Dionini observed that a single paroxysm of this form in man destroys upward of a million red blood-corpuscles per cubic millimeter; 200,000 per cubic millimeter appears to be the average destruction in a severe paroxysm. This enormous destruction of blood-corpuscles is not produced solely by disintegration of all the red blood-corpuscles attacked by the plasmodia; the plasmodia also exert a specific toxic action upon the blood-cells through toxic metabolic products. The toxic action is so far reaching that the so-called chemotactic leucocytosis, observed in other infectious fevers as a defensive measure, here plays only an insignificant rôle. The enemies are too numerous and the defensive leucocytosis too slight. While it is true that the malaria plasmodia are taken up in the spleen and bone-marrow by the so-called macrophages and thus rendered harmless, the new formation of parasites is so active and rapid that the disease, in the absence of specific treatment, does not in the majority of cases spontaneously subside. Nevertheless, mild cases occur in which the body overcomes the malady without intervention, even after a few febrile paroxysms. If the malarial person leaves the malarial region in which he was inoculated and goes to a nonmalarial district where anopheles do not exist (elevations above 3500 feet), the malarial plasmodia, after a longer or shorter series of asexual segmentation, will be transformed into gametes or sexual forms and must then pass through the mosquito in order again to become virulent and capable of producing the fever.

Patients with pernicious malarial infection who return to a nonmalarial climate after a time harbor in their blood almost only crescents, *i.e.*, the sexual forms of the malignant *Plasmodium præcox*. If the patient is not too debilitated, he will slowly recover from the infection and the crescents gradually disappear from the blood, as well as from the internal organs. According to R. Koch, an immunity to new infection develops after years of duration of the disease, so that even inhabitants of malarial districts are insusceptible to new attacks in spite of the sting of infected anopheles. This immunity is acquired by numerous dark-skinned races. For acquisition of this immunity, however, it is necessary that the natural course of the disease remain uninterrupted by administration of quinine, in order that the natural immunizing processes may completely take place in the blood.

R. Koch has demonstrated that in all localities where the adult natives are, so to speak, immune to malaria the children invariably are attacked by the disease. They invariably pass through febrile attacks and always have malarial parasites in their blood, often abundantly. The natives know neither quinine nor any similarly acting drug for controlling the malady. They allow it to take its course, and numerous children die of the disease; those who survive, however, are immune for the rest of their lives, that is, in spite of the sting of infected anopheles, they no longer offer a good soil for the malarial plasmodia, and hence the latter are incapable of development in their blood.

In addition to disintegration of the red blood-corpuscles, an acute increase of the pulp-cells of the spleen is observed in every acute attack of intermittent fever (quotidian, tertian, quartan, etc.), as a result of which this organ is considerably enlarged: acute spleen tumor. The capsule is always extremely tense. On incision, the grayish-red, pap-like pulp wells up upon the cut surface. The spleen is very friable in this stadium; indelicate handling of whatever nature suffices to disintegrate it.

Besides enlargement of the spleen, cloudy swelling of the myocardium, kidneys, liver, and peptic glands of the stomach usually is found at necropsy. In chronic intermittent fever the spleen loses its

Fig. 204.—Miescher's sac. × 50. (After *Leuckart.*)

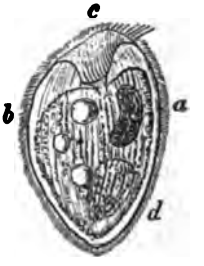

Fig. 205.—Balantidium coli. *a*, nucleus; *b*, vacuoles; *c*, peristoma; *d*, food particles. × 300. (After *Lehmann.*)

friable character, the other constituents of the organ beginning to proliferate. The spleen gradually becomes larger and denser, and may finally attain a size and hardness such as usually are seen in splenic leukemia. While in leukemic spleen the follicles are generally very large and distinct, the cut surface, therefore, having a peculiar grayish, often mottled appearance, the incised surface of chronic spleen tumor of intermittent fever is characterized by a brownish-red color and the absence of enlarged follicles. In malarial cachexia, dropsic conditions, hemorrhages, icterus, and sometimes amyloid degeneration are present.

In very severe acute attacks an enormous amount of brown pigment—ferrous melanin (hemozoin) and ferrous hemosiderin—is present in the urine, kidneys, spleen, liver, and even in the vessels of the intestine and brain, so that many vessels appear to be filled with pigment.

Melanin, which contains iron in firm combination and therefore does not give the reactions for inorganic iron, is characteristic of malaria. It is found in the

Synopsis of the Animal Parasites Most Frequently Observed in Man.

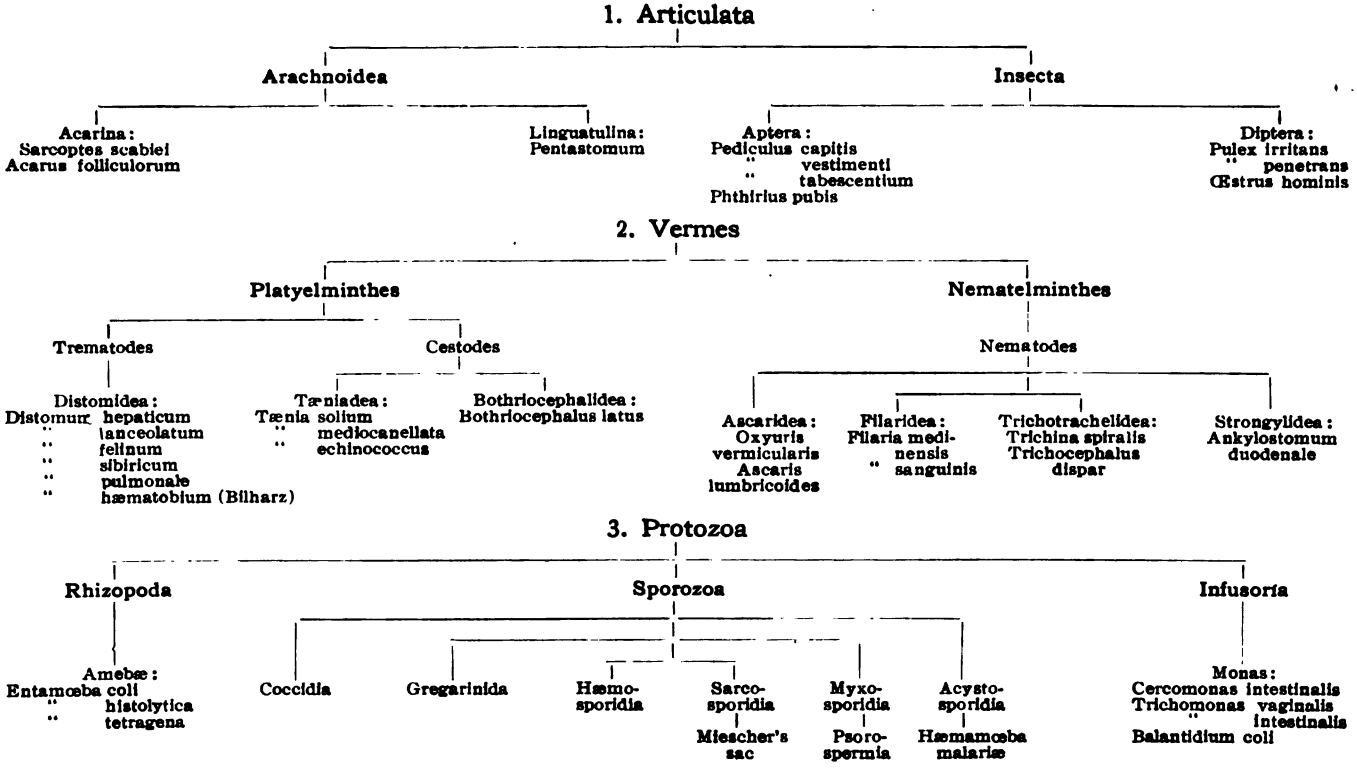

parasites, leucocytes, connective tissue of the liver, the parenchyma cells of the spleen, and occasionally in the nuclei of the endothelia of the capillaries of the brain, suprarenals, liver, etc. The pigment may be found years after an attack, then usually only in the fibrous stroma of the spleen. In many cases, in addition to a yellow pigment, the exact nature of which is obscure, there are observed in the parenchyma cells of the liver, kidneys, and spleen (and also in other conditions associated with hemolysis) granules in which the iron is loosely combined and gives with potassium ferrocyanide a blue reaction.

Myxosporidia are found in worms, amphibia, and fish (psorospermia).

Miescher's, or Rainey's, tubes (see Fig. 204), sausage-shaped bodies containing innumerable rod-like and spheric spores within a capsule, are caused by sarcosporidia. They occur in the striated musculature of the ox, swine, sheep, goat, horse, deer, hare, etc. Sarcosporidia have been observed several times in man.

The last group of animal parasites are the **infusoria:** animals with cilia or flagella as organs of locomotion. These are represented by:—

Balantidium (paramæcium) coli (Malmsten, 1857): a large, thick infusorium without flagella, but densely covered with cilia, and provided with oral aperture. (See Fig. 205.) It occurs in the large intestine of man and the rectum of pigs, from which it is said to be transmitted to man. According to some authorities, it causes profuse and obstinate diarrhea in man, and often diphtheritic ulceration of the intestinal mucosa. The parasites are sometimes found in the lymph- and blood- vessels—capillaries and veins—and in the liver (hepatic abscess). It is probable, however, that bacteria are responsible for this ulcerative colitis, and favor[1] the entrance of the protozoa which render the process obstinate.

II. THE ALTERATIONS PRODUCED BY THE VEGETABLE PARASITES, INCLUDING THE INFECTIOUS DISEASES.

General Remarks upon the Vegetable Parasites (Fungi).

All vegetable organisms occurring as parasites in man are achlorophylous fungi. These form[2] the second class of thallophytes, which, in turn, belong to the first division of the cryptogams[3] (flowerless, spore-bearing plants).

---

[1] Some observers assume that they are pathogenic *per se.*
[2] According to Eichler's system.
[3] The 24th class of the Linnean system.

The following are parasitic in man:—

1. Molds (branching fungi).
2. Yeasts (budding fungi).
3. Bacteria (fission fungi).

1. The **molds** (**hyphomycetes**) form long, branching, cellular threads which enlarge by apical growth. They are also jointed and are visible to the naked eye. Two varieties of jointed threads are differentiated: one forms the *mycelium*, which serves for the appropriation of nourishment; the other forms the threads (*thallus* or *fruit hyphæ*), which are adapted to fructification and carry the spores. The mycelium develops first; from this the hyphæ grow straight out. The latter do not develop within the moist tissues; the spores are lacking. Aside from development by spores, the plant can be perpetuated also by means of individual fragments of the fungus. Accordingly, transmission of the fungus may, on the one hand, take place through the agency of spores, and, on the other hand, in the absence of sporulation, by means of segments of the plant. Both modes of transmission may, of course, coexist.

THE POSITION OF BACTERIA IN THE VEGETABLE KINGDOM. (AFTER EYRE.)

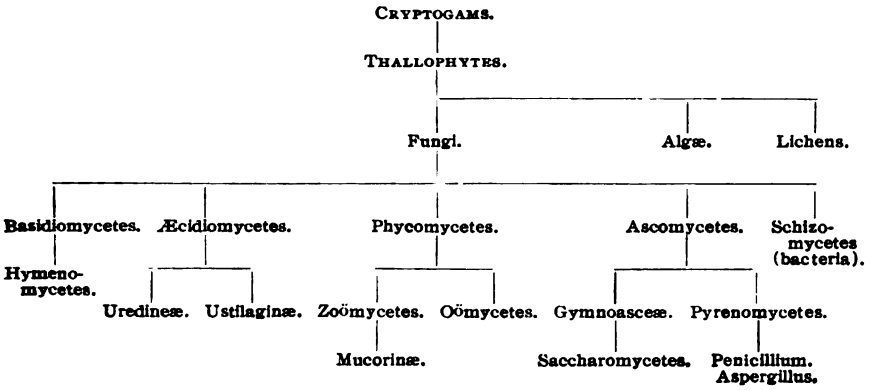

While the mycelial segments are very delicate, slender threads, the fruit hyphæ are broader and segmented. In the individual segments an internal nitrogenous layer and an external cellulose membrane can generally be distinguished. Glistening, fat-like droplets, which probably have the same significance as nuclei in cells, are sometimes observed in the interior. The spores also possess an external cellulose membrane and an internal nitrogenous layer. They are small, round, oval, cylindric cells from which the new-formed parts, the so-called "germinal sheaths" (*Keimschläuche*), develop. These subsequently grow into

mycelia. Owing to their hard outer covering the spores are very resistant to external influences (chemic reagents, drying, etc.), and they remain alive and unaltered for a long period, and, finally, develop further under favorable conditions (moisture and warmth). By virtue of this permanent power of resistance, they are called "lasting-spores" (*Dauersporen*). Some of them possess cilia, by aid of which they are set in motion: swarm spores.

The mold fungi are found almost exclusively upon superficial parts (skin, digestive tract, respiratory passages, auditory canal, etc.). Because of their great requirements for oxygen, they apparently occur in the internal organs only under especial conditions. Many cannot grow upon or within the human organism, because the body temperature is too high and hinders their development.

The most common of molds are the "brush molds" (*penicillii*), and their most frequent representative is the common mold: *Penicillium glaucum.* This fungus at first forms a white growth, which, in time, becomes green. The hyphæ are branched and divided at the ends (see Fig. 206) into a large number of small, short stems or bristles (hence, brush mold): *basidia,* upon the free ends of which the spores are arranged in chains. As the common mold cannot grow at the temperature of the human body, it is nonpathogenic in man.

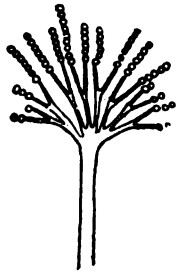

Fig. 206.—Penicillium glaucum.

Fig. 207.—Mucor.

Fig. 208.—Aspergillus.

To the pathogenic molds belong certain species of mucors: *Mucor corymbifer* and *rhizopodiformis,* and of aspergillus: *Aspergillus fumigatus, flavescens,* and *niger.*

The **mucors** have straight, single or divided fruit hyphæ, which bear at their extremities, upon an arched plate: *columella,* the *sporangium*—a spheric capsule filled with spores. (See Fig. 207.) *Mucor corymbifer* produces a snow-white growth; *Mucor rhizopodoformis* is characterized by the development of black sporangia. One of the most

common molds after *Penicillium glaucum* is the nonpathogenic *Mucor mucedo,* whose growth is yellowish brown and the fruit hyphæ black.

In the **aspergilli** the fruit hyphæ become club-shaped at the

Fig. 209.—Mucor corymbifer. × 350. (After *Lenhartz.*)

Fig. 210.—Aspergillus fumigatus. × 350. (After *Lenhartz.*)

extremities, and are provided with a great number of small, delicate, straight, almost radiately arranged intermediate fruit carriers (*sterigmata*), from which the spores or conidia are formed by constriction. (See Fig. 208.) *Aspergillus fumigatus* forms a greenish-gray growth. The spores are round or oval, and mostly colorless. *Aspergillus flavus,*

or *flavescens,* produces a yellowish or yellowish-green growth; the spores are yellowish brown. *Aspergillus niger* produces a chocolate-colored growth; the spores are black.

The pathogenic mucors and aspergilli have rarely been found in the lungs in *pneumonomycosis aspergillina,* in inflammations of the middle and the external ear (otomycosis, myringomycosis), etc. They grow at a temperature of from 30° C. to 40° C. (86° to 104° F.).

To these is to be added a series of other pathogenic thread fungi which are of more frequent occurrence in man, but to which no definite position in the botanical system can as yet be assigned.

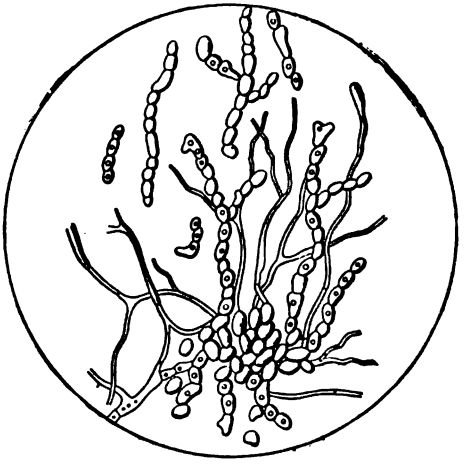

Fig. 211.—Achorion schönleinii. × 400. (After *Bizzozero.*)

Here belongs *Achorion schönleinii* (see Fig. 211), the pathogenic fungus of favus (*Tinea favosa*). It forms a network of septulate and sheathless, bent threads with numerous sprouts arising at right angles to the stem. The contents of these threads is homogeneous and granular. Especial fruit formation is lacking. The terminal segments of the threads frequently contain round or oval, strongly refractive bodies resembling nuclei. These are separated as spores which are sometimes arranged in rosary-like chains. On entrance of this fungus into the skin, a fungous growth forms in the epidermis which, when it spreads superficially, has a certain resemblance to a honey-comb (*favus:* a honey-comb). This phenomenon is produced by contact of the individual fungous foci in polygonal form. The fungous foci lie above the rete Malpighii, and are covered by the horny layer, forming spaces occupied entirely by proliferating fungous threads and spores. The greater

the accumulation of fungous masses, the more the neighboring tissues are irritated, and as a result inflammatory phenomena develop. The fungous threads grow into the hairs; hence, these assume a lusterless, withered appearance and readily fracture. As favus develops principally upon the hairy portions of the head (scalp), multiple circumscribed alopecia is produced. The external appearance of favus is characterized by yellow, umbilicated disks about the size of a dime and larger (*scutula:* a little dish), the centers of which are generally penetrated by one or more hairs. Exfoliation of these scutula exposes a moist, red surface which may again become covered by horny epidermis or undergo cicatrization. Favus sometimes affects the nails: *onychomycosis favosa.* In this affection the fungus penetrates the nails, where

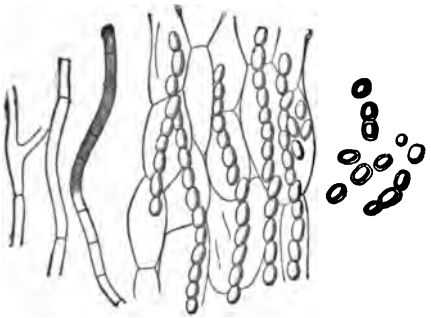

Fig. 212.—Trichophyton tonsurans—threads and chains of spores. × 400. (After *Bizzozero.*)

it develops and produces yellow spots, or it causes uniform thickening and loosening of the nails from the matrix.

The pathogenic thread fungus of **herpes**, or **tinea tonsurans,** is *Trichophyton tonsurans*—a fungus which, morphologicly, very closely resembles *Achorion schönleinii,* but differs markedly from the latter in artificial pure cultures. (See Fig. 212.) This fungus penetrates the shafts of the hairs of the scalp, and causes them to fall out. Round, bald spots which have a gray, dusty appearance (result of scale formation), and are surrounded by a reddened, or slightly pigmented, area, are produced.

The same fungus causes dense infiltration and suppuration in the bearded portions of the face: *sycosis parasitaria,* **"barbers' itch"** (*mentagra*). The development of *eczema marginatum* in localities where cutaneous surfaces are in contact and subjected to friction, *e.g.,* inner aspects of the thighs, perineum, etc., is also due to the presence of *Trichophyton tonsurans.* Eczema marginatum forms red, elevated spots

covered with vesicles and scabs, which spread peripherally and heal from the center with deposition of pigment.

Reddened spots with small vesicles, which rapidly dry and produce scabs, develop upon nonhairy portions of the body **(ring-worm)**, ***herpes circinatus.*** The inflamed areas generally have a discoid or circular form: ***herpes tonsurans vesiculosa.***

Pityriasis (tinea) versicolor is a purely local mycotic process of the skin, a squamous exanthema with yellow to brown discoloration, occurring especially upon the thorax. The most striking alteration is the color. This is essentially due to the fungous formations in the

Fig. 213.—Microsporon furfur. × 350. (Wax-paper drawing from a photomicrograph.) (After *Lenhartz.*)

superficial layers of the epidermis. Slight nervous phenomena are sometimes associated with it. The pathogenic fungus is the *Microsporon furfur,* a branched trichophyte, the mycelium of which contains more or less large groups of spheric spores. (See Fig. 213.)

If the pathogenic fungi associated with the last-named skin diseases present difficulties as to their botanic position, this is much more so in the case of the soor, aphthæ, sprue, or thrush fungus (*Oïdium albicans*). The former may, with some degree of certainty, be classed with the molds, but as regards soor this is doubtful.

The **soor,** or **thrush, fungus** (see Fig. 214) forms long, branched, and often bent threads composed of cells of varying length, joined end to end. In the interior of the threads are glistening, spheric granules. The ends of the threads are rounded. Upon the extremities of the individual cells spores develop from which, in turn, new threads

are produced. This fungus, which formerly was classed as a species of oïdium[1] under the name of *Oïdium albicans,* grows and behaves in a richly saccharine nutrient medium like yeast fungi. Hence, this fungus cannot, without further distinction, be classed with the thread or mold fungi. Nevertheless, it is described here because, under certain conditions, it manifests the characteristics of the molds.

Thrush, soor (aphthæ, *stomatitis exsudativa*), occurs almost exclusively upon mucous membranes covered with lamellated squamous epithelium, particularly in the pharynx, esophagus, and vagina. By growth of the soor fungus into the lamellated pavement epithelium, foci called

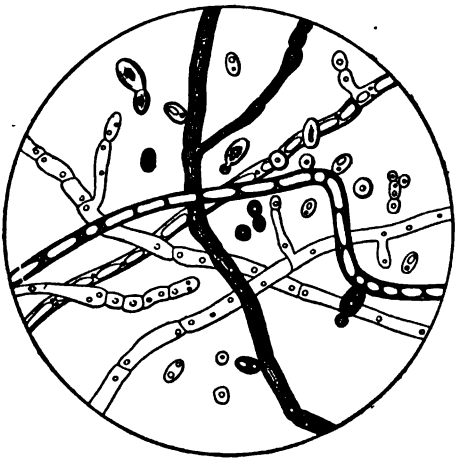

Fig. 214.—Soor (thrush) fungus (Oïdium albicans). × 350. (After *Lenhartz.*)

aphthæ are produced. These are small, punctiform, solid, yellowish-white patches which gradually enlarge and coalesce to form a kind of fungous pellicle (pseudomembrane), which may be completely exfoliated. The pseudomembrane consists not only of fungi, but also of the superimposed epithelial cells, innumerable bacteria, and (in the pharynx) particles derived from the food. Exfoliation of this pseudomembrane produces an excoriation with a dark-red base.

Soor attacks principally infants and elderly persons suffering from great debility (especially muscular debility) as the result of prolonged illness. The fungus may acquire great importance if the lumen of the esophagus becomes filled with fungous masses and exfoliated epithelium, rendering deglutition impossible. In children it sometimes produces acid decomposition in the stomach, which may result in violent

[1] The best known is *Oïdium lactis,* which is demonstrable in almost all milk. In *Oïdium lactis,* also, especial form of fructification is lacking.

and often fatal gastrointestinal catarrh. Such a diarrhea ceases only with removal of the fungus.

It has often been stated that the soor fungus causes ulceration; but this is improbable or, at least, infrequent, because the fungous threads do not extend beyond the youngest cellular layer of the epithelium. Although soor is sometimes observed upon ulcerated surfaces, this is usually due to the fact that the threads extend to pre-existing (*e.g.*, tuberculous) ulcerations. In this case they may enter the vessels and be carried to other parts by the blood-current.

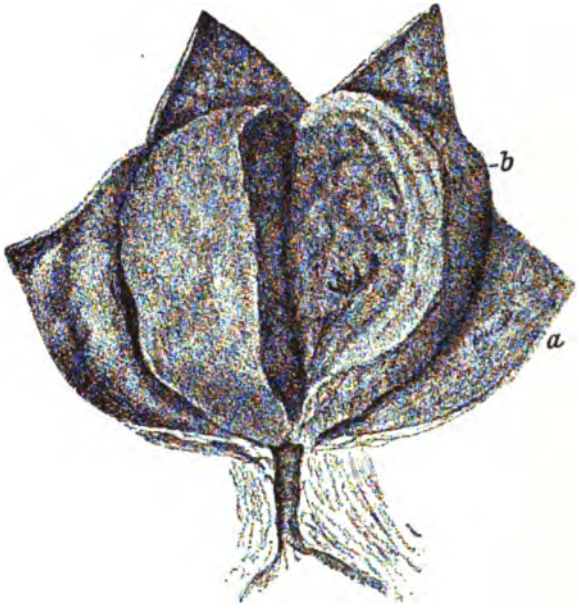

Fig. 215.—Mycosis uteri. *a*, wall of uterus; *b*, uterine contents composed of firmly coherent masses of fungus. (After *Langerhans*.)

This fungus never independently develops in the stomach, because it cannot secure lodgment in the single layer of cylindric epithelium; soor masses, however, are easily swallowed, and may then be found in the stomach contents. On the other hand, in rare cases the soor fungus may enter (by aspiration) the alveoli of the lungs and cause pneumonic processes: **soor pneumonia,** ***pneumoniæ mycotica.***

An exceptional occurrence is the presence of large masses of soor fungus within the cavity of the uterus. The accompanying illustration (Fig. 215) represents the uterus of an old woman which was completely filled with masses of soor fungus and bacteria. The cavity of the uterus was strongly dilated by the fungous accumulation, and the walls were

very greatly thinned; the mucosa was almost entirely destroyed and presented a granulating surface.

2. The occurrence of **yeast,** or **budding fungi (blastomycetes),** is associated with fermentation. The yeast fungi are microscopic (in size, between the molds and thread fungi), spheric, or oval cells, with thin membrane and granular protoplasm. They increase by budding, forming more or less long chains. In the process of budding the membrane is elevated at a certain point, forming button-shaped protrusions, which develop into new, independent cells and become separated from the parent cell by constriction. Mycelia and organs of fructification are lacking. Consequently, yeast fungi are not sessile, but infusorial, and can act perniciously upon the human body only in so far as they induce injurious decomposition processes, *e.g.,* in the gastric contents. Here much depends upon the nature of the ingesta. The fermentative fungi never produce fungous pellicles within or upon the surface of the tissues. What is claimed to be a variety of yeast produces a blastomycotic disease of the skin (*dermatitis blastomycotica*). As this fungus forms mycelia in cultures, its position among the yeasts may be questionable.

Of the great number of yeast fungi, only a few well-known examples will be discussed here.

Saccharomyces, or *Cryptococcus, cerevisiæ* causes alcoholic fermentation, saccharine solutions being split up into alcohol and carbonic acid as the result of its action. The spores of top yeast (scum) form chains; the spores of bottom yeast are separated by constriction.

Saccharomyces ellipsoides (wine yeast) has an elliptic form. It is the cause of vinous fermentation.

Saccharomyces mycoderma (*Mycoderma cerevisiæ et vini*) is oval, elliptic, or cylindric in form. It produces the fungous pellicle upon fermenting, especially strongly acid, liquids, and is the cause of acetic acid fermentation.

3. The **fission fungi, schizomycetes,**[1] or **bacteria** are the smallest of all vegetable organisms. They are so minute that they can be distinctly seen only with the strongest lenses (immersion lenses). They consist of a nitrogenous protoplasm and an enveloping membrane or capsule, which is very resistant to the action of acids and alkalies. The membrane often possesses the property of swelling and forming a kind of gelatinous envelope. To this is due the peculiar tendency of many vegetable micro-organisms repeatedly to appear in uniform arrangement

[1] σχιζάω = cleft, fissure; μύκης = fungus.

(in masses, chains, etc.). The bacteria contain no chlorophyl; only a few have a chlorophyloid coloring matter called bacteriopurpurin, a brown, red to violet pigment. The bacteria have a constant form; one species cannot be converted into another.

According to their external form are distinguished:—

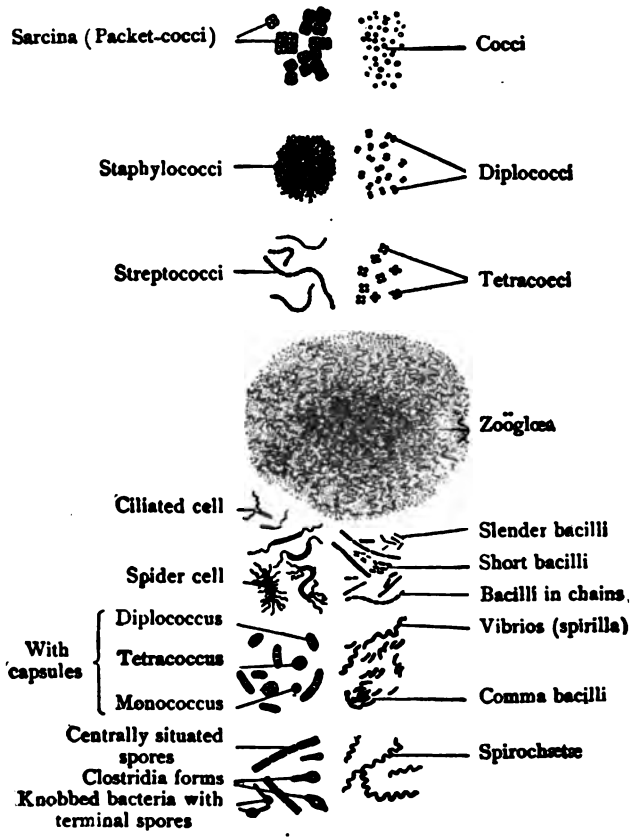

Fig. 216.—Forms of bacteria. (From *Schenk.*)

1. **Micrococci**[1]: spheric and ellipsoid cells (*spherobacteria*), which are arranged either in pairs (*diplococci*[2]) or in groups of regular (*sarcina, tetragenus*) or irregular order (*staphylococci*[3]), or in long chains (*streptococci,*[4] chain-cocci).

---

[1] μικρός = small; κόκκος = kernel, berry.
[2] διπλόος = double; κόκκος = berry.
[3] σταφυλή = bunch of grapes; κόκκος = berry.
[4] στρεπτός = twisted; κόκκος = berry.

2. Bacilli[1]: first, short rods (bacteria in a narrow sense), and, second, the true bacilli: rod-shaped, cylindric cells (rod-bacteria), which not infrequently form long threads.

3. Spirilla: *vibrio, spirillum, spirochæte* (screw-shaped, spiral cells, *spirobacteria*), which show a partial, a whole, or more than one spiral turn like the thread of a screw.

4. Pleomorphous fission fungi, thread bacteria (*leptothrix*,[2] *streptothrix, cladothrix*,[3] *actinomyces*).

All schizomycetes are generally classed under the term: **bacteria,** because the rod form is decidedly most common. Many of the bacilli and spirilla possess the power of locomotion—independent motility—through the agency of fine cilia and flagella. These are situated over the whole surface (up to 12 or more), as in the typhoid bacillus, or at the end (pole), as in the spirilla and the comma bacilli of Asiatic cholera; in the spirilla a wisp of cilia is present;

Fig. 217.—Forms of bacilli, showing spores. (From *Oertel,* courtesy of P. Blakiston, Son & Co.)

in the comma bacillus a polar flagellum. Movements are either rotatory (around the long axis) or undulating in character. The micrococci usually manifest only a trembling or dancing movement (Brownian molecular movement); some of them, however, are provided with flagella, and are, therefore, capable of independent locomotion.

Very little is known of the finer structure of bacteria. The interior usually appears homogeneous; sometimes it contains oil-like granules, and only in very rare instances (*e.g.,* anthrax bacillus) is it possible to follow within the rods further differentiation into smaller divisions or compartments.

Bacteria increase by division (fission); in the bacilli this always takes place in a transverse direction.[4] After fission the daughter-cells

---

[1] *Bacillus* = little stick.

[2] λεπτός = slender; θρίξ = hair.

[3] κλάδος = branch; θρίξ = hair.

[4] The multiplication of bacteria by binary fission has for result, if nothing occurs to interfere with the most favorable conditions, the invasion of the medium by an incredible number of these little beings, of which we can form an idea only by calculation.

"Let us suppose," says Cohn, "that a bacterium divides into two in the space of an hour, then in four at the end of a second hour, then into eight at the end

may become separated or remain united in threads, chains, masses, etc. Under appropriate conditions some bacteria form spores. According to the mode of sporulation, two kinds of bacteria are differentiated, namely, endosporous and arthrosporous. (See Fig. 217.) In the former the spores develop within the interior as round or oval, strongly refractive granules which behave differently, toward staining matters, from the bacteria (*i.e.*, they possess no affinity for the basic aniline dyes); in the latter, certain segments of a chain of bacteria are transformed into spores. From the spores, which are characterized by their great resistance to external influences, new bacteria develop under favorable conditions. To these favorable conditions belong, in addition to appropriate nutrient media,[1] which supply the bacteria with the necessary nutrient materials, heat,[2] moisture,[3] and oxygen. The requirements for oxygen are very variable. Some bacteria grow only in the presence of air: aërobic (*e.g.*, anthrax bacilli); others grow only in the absence of air: anaërobic (tetanus bacillus); others, again, constitute in a measure transition forms in so far as their growth is better in the presence of air, but is not wholly arrested upon its exclusion: facultative aërobes and facultative anaërobes.

Many chemic substances prevent the development of bacteria and

---

of three hours; in twenty-four hours the number will already amount to more than sixteen millions and a half (16,777,220); at the end of two days this bacterium will have multiplied to the incredible number of 281,500,000,000; at the end of three days it will have furnished 47,000,000,000,000; at the end of about a week, a number which can be represented only by 51 figures..

"In order to render these numbers more comprehensible, let us seek the volume and the weight which may result from the multiplication of a single bacterium. The individuals of the most common species of rod bacteria present the form of a short cylinder having a diameter of a thousandth of a millimeter, and in the vicinity of one-five-hundredth of a millimeter in length. Let us represent to ourselves a cubic measure of a millimeter. This measure would contain, according to what we have just said, 633,000,000 of rod bacteria without leaving any empty space. Now, at the end of twenty-four hours the bacteria coming from a single rod would occupy the fortieth part of a cubic millimeter; but at the end of the following day they would fill a space equal to 442,570 of these cubes, or about half a liter. Let us admit that the space occupied by the sea is equal to two-thirds of the terrestrial surface, and that its mean depth is a mile; the capacity of the ocean will be 928,000,000 cubic miles. The multiplication being continued with the same conditions, the bacteria issuing from a single germ would fill the ocean in five days." (Magnin and Sternberg. Bacteria. New York: Wm. Wood & Co., 1884, p. 124 *et seq.*)

[1] Most bacteria flourish best upon a neutral or faintly alkaline, richly albuminous nutrient medium.

[2] For all bacteria there is a maximum (average 55° C.) and a minimum temperature at which development is still possible, and also a definite temperature at which development is most favorable for growth (for many pathogenic bacteria about 37° C. = 98.6° F.), the temperature of the body.

[3] Most bacteria, but not the spores, are destroyed in a short time by drying.

others kill them. To the former belong their own products of metabolism; to the latter the ordinary disinfecting agents.

Some of the bacteria, especially the nonpathogenic, are characterized by the constant production of coloring matter (*e.g., Bacillus prodigiosus, Bacillus violaceus, Staphylococcus aureus, Bacillus pyocyaneus,* etc.), but not chlorophyll; others by the development of gases (colon bacillus, *Bacillus capsulatus aërogenes,* etc.); others, again, by their property of luminosity (phosphorescence).

For practical purposes the **bacteria** are divided into **pathogenic** and **nonpathogenic.** Both forms occur as parasites in man. To the nonpathogenic bacteria belong all those which are incapable of development at the temperature of the body. The true parasites, on the contrary, grow best at the body temperature. All those which grow only in the intestinal contents or upon the surface of the body are of subordinate importance. On the other hand, those which penetrate deeper into the body and multiply there, are strictly pathogenic. Increase within the body is possible only when the tissues offer a favorable soil for the bacteria in question. If the bacteria which gain admission find an unfavorable nutrient medium, they cannot multiply or exert their action. The immunity of certain individuals and whole animal species toward certain species of bacteria is due principally to this cause. If, on the other hand, the bacteria find an appropriate soil in the animal or human body and begin to multiply, an action is exerted upon the animal or human tissues which is followed by certain changes in the tissues which may be designated as **reaction.** This alteration or reaction on the part of the tissues is the first sign of beginning or existing **infection.** The reaction may be confined to the point of bacterial invasion, or become manifest in the rest of the body. When the process is due principally to metabolic products of bacteria, toxic action by union of the toxic products with the tissues (according to the affinity between tissues and toxic substance) is predominant, and is manifest either locally or in distant parts of the body—in other organs. When, on the other hand, the reaction of the body is manifested chiefly by accumulation of round cells (pus corpuscles) or by death of cells or tissue areas, we then speak of infectious processes in a strict sense.[1] Here also, however, the phenomena are due

[1] A minute amount of the infectious material suffices in time to produce marked effects. Absorption occurs especially from necrotic, gangrenous, putrid foci. The germs enter the body, attack the tissues, and produce local and general disturbances. Toxins and bacteria enter the blood and thus reach all parts of the body: **general sepsis, septicemia.** A malady thus produced is called an **infectious disease.** Many diseases, such as small-pox, measles, scarlatina, are undoubtedly infectious in nature, although the causative agents are still unknown. When transmission of the germs occurs directly or indirectly (*e.g.,* by fomites)

principally to chemic (chemotactic) action, the bacterial products disturbing or injuring the nutrition and integrity of the cells, paralyzing, killing, or exciting them to formative processes. The destruction of pathogenic bacteria in the human body also is due to chemic processes: either the nourishment of the bacteria is withdrawn by inappropriate nutrient media (alteration of the same during infection) and their vital and reproductive energy thus diminished or destroyed or the bacteria are dissolved or destroyed by a species of enzymotic action exerted by the tissue juices and cells. Under certain conditions, incorporation of the bacteria by cells may occur (*e.g.*, gonococci, meningococci).

The fact that bacteria are found within cells and may die within them has given rise to the **phagocytosis theory** of Metchnikoff, according to which healing of infectious diseases is due to phagocytic action exerted upon pathogenic agents which have entered the body. If a mild infection is thus overcome, the phagocytic power of the cells is said to be increased.

Nonpathogenic parasitic schizomycetes are *Leptothrix buccalis* and *Sarcina ventriculi.*

Leptothrix forms a fungous growth which covers the papillæ of the tongue. It is a harmless and constant inhabitant of the mouth, growing into long, nonbranching threads.

Sarcina ventriculi consists of sixteen and more segments arranged in bale or packet form.

In addition to these are innumerable bacteria which occur in the contents of the stomach and intestine, but which, owing to their harmlessness, command but little attention.

The pathogenic bacteria are the most important of all vegetable parasites. To be distinguished are the saprophytes, which grow principally in or upon dead substances, and the specific pathogenic parasites which develop principally upon or within the living animal body. To the saprophytes belong those bacteria which

---

from man to man, the disease is designated as **contagious.** Scarlatina, small-pox, measles, cholera are contagious. Not all infectious diseases, however, are contagious. For example, malaria is not immediately transmitted from man to man. The transmission of micro-organisms from the mother to the fetus *in utero* has been proved in many diseases. On the one hand, the entrance of the pathogenic germs from the intervillous (maternal) blood-spaces into the fetal (placental) villi has been directly observed (*e.g.*, anthrax and tuberculosis); on the other hand, fully developed infectious diseases have been demonstrated in the newborn (*e.g.*, typhoid, pneumonia, variola, pyogenic coccus infection, tuberculosis, syphilis). It was first assumed that transferrence of infectious germs could occur only in abnormal placentas, since the blood-channels of the mother and fetus are separate. Insignificant necroses (small infarcts) in the placenta are not rare, however, and the micro-organisms may then grow by continuity into the fetal tissues from the intervillous spaces in which they lodge. It is doubtful whether infection of the germinal cell **(conceptional infection)** occurs.

cause putrid (σαπρος = putrid) disintegration of dead parts (*gangræna humida*). They lead through putrid decomposition to the development of chemic poisons which act on all parts of the body, and may produce severe disturbances (convulsions, paralysis, choleraic states).

As already stated, the action of the true, specific **pathogenic bacteria** is always chiefly chemic in nature. It is not the bacteria as such which cause the characteristic symptoms of **infection,**[1] but the products of their metabolism—soluble, diffusible toxins: exotoxins, *e.g.,* tetanus and diphtheria—or the proteid substances of which their bodies are composed: endotoxins, *e.g.,* typhoid fever, lobar pneumonia, etc. (See Anaphylaxis, p. 323.) In this respect infectious diseases and intoxications possess a certain similarity. In intoxication, however, the poison which enters the body never increases, while in infection continued reproduction of the toxic substances takes place as a result of multiplication of the bacteria.

Bacterial infection generally takes place by the reception of very small quantities of the infecting microbe. These increase within the body during the period of incubation until an amount sufficient to produce local and general phenomena of disease is reached. In general, multiplication of pathogenic micro-organisms does not cease here, but continues as long as the process has a tendency to spread. Extension occurs either by continuity, the infection spreading to neighboring parts *per contiguitatem* (in *erysipelas migrans,* phlegmon, and many other processes), or by discontinuity, infectious germs being in some manner (*e.g.,* through the blood- or lymph- current) transported from a disease focus to other organs, where they form metastatic foci (in puerperal and other affections). In some cases the infection is local (furuncle); in others it is general, and spreads more or less throughout the body (septic, pyemic processes).

Within the animal body the bacteria are located outside the cells in the tissue spaces, as well as upon or within the cells, and either within or upon the surface of the tissues. In pus, for example, micro-organisms occur in the intercellular liquid and upon and within (infiltration) the pus-corpuscles (*e.g.,* gonococcus, meningococcus). The process is generally as follows: The microbes occur first in the liquid, then upon the surface of the cells, and, finally, they enter or are taken up by the cells.

As a rule, bacteria can reach the internal organs of the body only by way of the blood-current. Hence, direct transportation from without

---

[1] By infection (*inficere:* contaminate, corrupt), in general, is understood the reactive alteration of the natural state or character of the tissues by the presence of injurious materials capable of reproduction, not only bacteria, but cells also, *e.g.,* tumor cells.

(*e.g.*, through a slight cutaneous injury) must be differentiated from indirect transportation by means of the blood. In certain infectious diseases the pathogenic micro-organisms occur only in the blood: the spirillum of recurrent fever is always found in the blood-plasma, while the *hæmamœbæ* apparently very quickly invade the red blood-corpuscles. In contrast to these cases stand those in which the fungus vegetates only upon the surface, *i.e.*, is, in a strict sense, an epiphyte. To the latter belongs the *Leptothrix buccalis*. So long as these fungi remain upon the surface they are not injurious; when, however, they penetrate into the depth, *e.g.*, into the crypts of the tonsils and lingual follicles, decomposition of the masses accumulated in the crypts may sometimes occur and cause inflammations. Caries of the teeth is usually due to the entrance of such fungi into the dentine substance. If a portion of the enamel is broken off, the dentine is exposed and subject to invasion by the fungi. At first discoloration and a change in consistency extending to the pulp cavity are observed at the site of exposure. The affected area gradually softens as the result of disappearance of the lime. Hence, dental caries is rather a softening than a caries comparable with caries of bone. The fungi, which are demonstrable in the dentine at an early period, enter through the dentine canaliculi.

A certain **antagonism** exists between the pathogenic bacteria and the living animal tissue. Both influence each other in an unfavorable sense, but the relation is inconstant. The influence of bacteria upon animal tissues depends upon the peculiar character of the tissues as well as upon their virulent properties. Not all pathogenic bacteria are equally active in all animals. The **susceptibility** of different animal species to the same pathogenic bacteria is very variable; for example, white mice, guinea-pigs, cattle, and sheep are extremely susceptible to anthrax, while white rats are but slightly so, and dogs, birds, and amphibia are entirely immune. Under certain conditions, however, even immune animals, *e.g.*, the frog (by exposure to high temperature), can be rendered susceptible to anthrax, so that they succumb to it. In the case of the slightly susceptible white rat, the protection against anthrax invasion has been shown to be due to the marked alkalinity of the blood. These examples demonstrate that all animal tissues do not offer equally favorable conditions for the development of pathogenic bacteria, and that under certain conditions animals which usually are immune to a pathogenic fungus may be infected. Furthermore, certain bacteria are not equally virulent for all representatives of the same animal species (white rat: anthrax), and in the same animal species there are certain individual variations in susceptibility or immunity to the

same infectious disease. This is shown by the history of anthrax in man. In general, man is susceptible to anthrax, but not every individual who is infected dies of anthrax; often only a local process is established which heals under appropriate treatment. This is further exemplified by the history of tuberculosis, which, as is known, attacks principally individuals with "hereditary taint," *i.e.*, those born of "consumptive" parents and possessing an inherited susceptibility to tuberculous processes, while others under exactly the same hygienic conditions remain wholly immune and, as a rule, become tuberculous only under especially unfavorable circumstances.

In this connection the observation that nonpathogenic bacteria also manifest pathogenic properties under certain conditions, namely, when inoculated along with other bacteria (symbiosis), is of especial interest. Probably the jointly inoculated bacteria, through the agency of their metabolic products, aid the otherwise nonpathogenic by furnishing more favorable conditions, particularly a more favorable soil, and, perhaps, also by reducing the resistance of the tissues. Possibly the remarkable tendency of certain individuals, manifesting not the slightest disposition to tuberculous affections, to succumb to tuberculosis after recovery from syphilis or while suffering from florid syphilis is thus to be explained. The syphilis apparently created conditions favorable to the tubercle bacillus.[1]

On the other hand, however, an antagonism often exists between bacteria (not only the pathogenic), the metabolic products of one destroying the power of development of the other. Thus, anthrax in susceptible animals has been cured by inoculation of the cocci of erysipelas. To this antagonism is probably due the fact that, after death of the individual, certain pathogenic bacteria lose their infectious properties in the cadaver, and that only a limited number of infectious diseases—*i.e.*, pathogenic bacteria—retain their virulence also in the

[1] This view is denied by some authorities, according to whom syphilis does not seem either to predispose to tuberculosis or to protect from it. It is even stated that tuberculosis in old syphilitics runs a much more benign course than in other subjects. High blood-pressure and the general tendency to fibrosis in late syphilis have been suggested to account for this as follows: "Syphilis is one of the causes of arteriosclerosis with its consequent high blood-pressure, and if the left ventricle finds increasing difficulty in pumping the blood out into the aorta there must be a diminution in the ease with which blood is removed from the pulmonary veins. The pulmonary blood-pressure would thereby be raised, and, by analogy with mitral stenosis, in which a similar rise of pulmonary blood-pressure occurs and in which phthisis is comparatively rare, it has been thought that consumption is staved off in late syphilis in this way. The argument, however, would not hold good in cases where there is no arteriosclerosis or no increase in systemic blood-pressure. Even in such cases, however, phthisis tends to run a very chronic course. Hence it seems more likely that the general tendency to sclerosis in late syphilis is at least as important as is increased blood-pressure in causing the chronicity of the tuberculous lesions." (*The Hospital*, June 13, 1908, p. 282.)

cadaver. To the latter belong particularly the *contagium vivum* of diphtheria, syphilis, small-pox, glanders, anthrax, tetanus, scarlatina, and the pyogenic bacteria. It is very probable that the loss of pathogenic action is intimately connected with the metabolic products of the rapidly developing putrefactive bacteria, for the greater the putrefactive phenomena, the more quickly the specific virulence of many bacteria is lost.

The specific virulence can be attenuated in another manner: For attenuation of the anthrax bacillus, for example, the direct action of sunlight,[1] increase of air pressure to 6 to 8 atmospheres, the action of a temperature of from 42° to 43° C. during a period of about twenty-four days, and the transitory residence of the bacilli within the body of immune animals, *e.g.*, the frog, suffice. So far as is known, attenuation is due essentially to alteration of the products of metabolism; attenuated anthrax cultures elaborate alkaline, while the virulent generate acid products.

This attenuation of the virulence of pathogenic bacteria has an eminently practical interest, because it is possible through inoculation of attenuated pathogenic bacteria artificially to produce immunity to infectious diseases. Upon this principle rests Jenner's protective inoculation against small-pox (vaccination), for in all probability the animal or cow- pox, as well as the humanized lymph used for this purpose, contains the attenuated *contagium vivum* of variola. Why the animal body, after subjection to protective inoculation, remains for a considerable period immune to certain infectious diseases is still unknown. Perhaps inoculation with the attenuated *contagium vivum* eliminates from the body a substance which is essential for the development of the pathogenic microbes. It must be admitted, however, that we have not the slightest knowledge of the existence of such special nutrient substances in the body. On the other hand, it is most probable that in vaccination the micro-organisms stimulate the body cells to elaborate a substance (antibody) which inhibits the development of the pathogenic microbes. (See Immunity, p. 15, and Vaccine Therapy.)

The ability of the body to kill pathogenic bacteria is due principally to the so-called leucocytes. The colorless blood-corpuscles of immune animals are capable of taking up virulent bacteria; those of susceptible animals take up only attenuated or dead bacteria. (See Opsonins, Bacteriolysins, Antibodies.)

Pathogenic micro-organisms which have entered the animal body can be excreted as virulent microbes—and herein resides the power of

[1] Pure cultures of the tubercle bacillus are killed within a short time by this means.

communicability—or they perish within the body if the individual survives. Infectious germs may be eliminated from the body with the dejecta (typhoid, cholera[1]), urine, sweat, saliva, sputum (pneumonia, tuberculosis), and the epidermis scales; under certain conditions also with the secretions from ulcerated surfaces (syphilis), with catarrhal products (from the conjunctiva in Egyptian eye disease; from the vagina and urethra in gonorrhea, etc.), and, finally, with the blood in recurrent and intermittent fever. By introduction of these microbes discharged from the diseased body, the disease may be communicated to other individuals.

Introduction may occur in the following four ways:—

1. Through the surface of the external skin, including the conjunctiva, etc.
2. Through the intestinal canal.
3. Through the respiratory tract.
4. Through the genitourinary canal.

Some of the infectious diseases are communicable from a diseased to a healthy individual only by immediate, rarer by intermediate contact (use of the same clothing, lavatories, privies, eating utensils, by letters, etc.). These constitute a subdivision —the so-called contagious[2] diseases. Here belong syphilis, smallpox, scarlatina, diphtheria, anthrax, glanders, suppurations, erysipelas, etc. In the other infectious diseases (formerly called miasmatic), the air (for tuberculosis), water (for typhoid fever, dysentery, cholera, bilharziosis, etc.), animal parasites (for plague, yellow fever, malarial, trypanosome, and filarial diseases) and soil (helminthiasis) are the chief carriers or agents of infection. The dividing line between the contagious and the remaining infectious diseases is by no means sharply defined. On the contrary, there are a number of infectious diseases which, in a measure, occupy an intermediate position (cerebrospinal meningitis, influenza, articular rheumatism, and others), and in which it is not known how infection takes place. Probably positive information regarding all these infectious diseases will not be gained until we have become accurately acquainted with the *contagium vivum*, for many peculiarities of the infectious diseases, especially their mode of transmission and spread, are evidently dependent upon the biologic conditions of the

[1] Not all persons in whom cholera bacilli find lodgment become victims of cholera; many remain healthy, although the bacilli are discharged with the stools. Such persons are called "bacilli-carriers," and are of great importance in the spread of cholera. (See also "Bacilli-carriers" in typhoid.)

[2] In this connection it must be remembered that it is not necessary for trauma always to be present at the point of entrance of the bacteria. The bacteria can enter the body also through the uninjured skin and mucous membranes, *e.g.*, be rubbed in.

infectious agents, *i.e.*, of the pathogenic schizomycetes and protozoa. Why cholera is endemic only in certain countries and only occasionally gives rise to devastating epidemics in other lands through the agency of infected individuals coming from the original habitat of the disease; why diphtheria sometimes occurs sporadically, sometimes as an epidemic, and why syphilis is conveyed only by contact—these and other questions are still unsolved problems.

Thus far specific pathogenic micro-organisms have been universally accepted as the *causa externa* in only a comparatively small number of infectious diseases. According to Koch, a micro-organism may be considered as pathogenic for a given infectious disease when it is demonstrable in all cases of this disease, occurs in such numbers and distribution as to explain all the morbid phenomena, and when the same infectious disease is always produced by inoculation with a pure culture of the micro-organism in question. These demands have thus far been met only by the *Bacillus tuberculosis* (Koch) in tuberculosis, the *Bacillus anthracis* (Koch) in anthrax, the *Bacillus mallei* (Löffler-Schütz) in glanders, the *Bacillus tetani* (Kitasato) in traumatic tetanus, the *Bacillus typhi abdominalis* (Eberth-Klebs) in typhoid fever, the *Bacillus lepræ* (Hansen-Neisser), the *Bacillus dysenteriæ* (Shiga-Kruse), the *Spirillum obermeieri* (spirochæta) in relapsing or recurrent fever, *actinomyces* (cladothrix) in actinomycosis, the *Bacillus pestis* (Kitasato and Yersin) in bubonic plague, the *Streptococcus erysipelatis* (Fehleisen) in erysipelas, the *Gonococcus* (Neisser) in gonorrhea, and the *Staphylococcus pyogenes aureus, albus,* and *citreus* and the *Streptococcus pyogenes* in suppuration.

In other infectious diseases pathogenic bacteria or protozoa have been demonstrated which, although not fulfilling all the above requirements, may, nevertheless, with much certainty be accepted as the cause of the disease in question. This is the case in Asiatic cholera (Koch's *Vibrio choleræ asiaticæ,* or comma bacillus, or *Spirillum choleræ asiaticæ*); in influenza (Pfeiffer's *Bacillus influenzæ*); in gaseous phlegmon, *Bacillus aërogenes capsulatus* (Fraenkel-Welch), malaria, trypanosomiasis, diphtheria (Löffler), epidemic cerebrospinal meningitis (very probably: *Diplococcus meningitidis* [Weichselbaum] *sive intracellularis* [Jäger]), fibrinous pleuropneumonia (*Diplococcus lanceolatus* [Fraenkel-Weichselbaum]). Following closely upon these are whooping-cough (probably bacillus of Bordet-Gengou) and syphilis (probably: *Spirochæta pallida,* Hoffmann and Schaudinn); Malta fever (*Micrococcus melitensis*); yaws, or frambesia (*Spirochæta pertenuis*). The statements regarding specific pathogenic bacteria in these diseases are, for various reasons, not universally accepted.

Still more doubtful is the testimony regarding pathogenic microbes in small-pox, rhinoscleroma, scarlatina, measles, typhus fever, rabies (hydrophobia, lyssa), trachoma, varicella, parotitis epidemica, coryza, cholera nostras, and yellow fever.

GENERAL REMARKS UPON THE INFECTIOUS DISEASES.

In their beginning and course the **infectious diseases** exhibit manifold differences. Only the larger group of acute general infectious diseases[1] manifest certain points of resemblance. All these begin acutely, *i.e.*, suddenly, usually without preceding disturbances, with general symptoms, high fever, chills, and disturbances of the nervous and digestive systems, etc.; not until then do the local phenomena develop. Most acute infectious diseases pursue a quite typic course, and when no complications or sequelæ occur generally end in recovery. An unfavorable issue (death) is most frequent in complications, but such may occur also in cases running a perfectly typic course if the local affection is very severe and extensive, the general phenomena (continued, very high fever, etc.) very intense, and the affected individuals are in a low state of resistance (after recovery from other diseases, *e.g.*, in the stage of convalescence; also in childhood, advanced age, etc.). In these cases, aside from the local alterations, fresh spleen-tumor (from hyperplasia of the pulp cells) and cloudy swelling of the parenchymatous organs, especially of the large glandular organs of the abdomen (liver, kidneys, stomach) and of the myocardium, are almost constantly observed at necropsy. Sometimes the local alterations are entirely obscured and the general changes predominate, especially in septic, puerperal, and diphtheritic processes. This may be so pronounced that nothing but parenchymatous clouding and spleen-tumor are found *post mortem*. If icterus also is present, as is not infrequently the case in septic processes, the pathologicoanatomic findings closely resemble those observed in phosphorus poisoning. The only difference is that phosphorus poisoning is never accompanied by swelling of the spleen, and that hemorrhages are generally absent in septic processes. These important differential points, however, may be lacking, since in phosphorus poisoning hemorrhage and, in very acute sepsis, swelling of the spleen may sometimes be absent. On the other hand, under certain conditions, namely, after malarial affection, etc., chronic splenic tumor[2]

[1] Malarial affections also belong here. (See Animal Parasites, p. 399.)

[2] This is more dense than acute spleen-tumor. The cut surface is smooth and red, while in acute spleen-tumor the hyperplastic pulp bulges upon the incised surface. (See Spleen.)

may be found also in phosphorus poisoning. Often in such cases a positive conclusion can be reached only after consideration of all the conditions (clinic history, chemic examinations, etc.).

These acute infectious diseases accompanied by general phenomena stand in marked contrast to those beginning slowly, insidiously, and often quite latent: syphilis, scrofula, tuberculosis, gonorrhea, cerebral abscess, etc. In these affections general symptoms, high fever, chills, etc., are usually absent, but under certain unfavorable conditions they may become manifest.

Some infectious diseases are characterized by their chronic and usually unfavorable course, *e.g.*, chronic tuberculosis; others by their usually local, circumscribed course (abscess, furuncle, gonorrhea). In some, one attack of the disease generally protects against subsequent invasion (small-pox, scarlatina, measles); in others the disposition to new attacks is increased (diphtheria, malaria, eye diseases, la grippe, etc.).

Tuberculosis.

The term **tubercle** is employed to designate not every nodule, as frequently is the case in works on descriptive anatomy, but only a small infectious, usually multiple, inflammatory, tumor-like nodule—a nonvascular, true neoplasm, an irritative cellular proliferation —which develops from tissue belonging to the group of connective substances. The young growth consists of two zones—a central and a peripheral. The latter is composed of small, delicate cells possessing great resemblance to lymphoid cells.[1] They are transparent, slightly granular round cells with a small homogeneous, or large, slightly granular, nucleus which occasionally contains a nucleolus. The central zone consists chiefly of so-called epithelioid cells. These are, as the name indicates, large, somewhat flattened epithelial-like cells derived from connective-tissue cells and endothelia,[2] and possess one or several large oval (vesicular) nuclei with distinct nucleoli. Between these cells a fine fibrillated network can sometimes be seen, which is composed partly of the pre-existing fibrous tissue of the region, partly of prolongations of the new-formed cells. In young tubercles fibrin is said to be present. At about the junction of these two zones, usually, however, within the central zone, are found either one or more so-called **giant cells** of Langhans (Fig. 218). These are large, polymorphous cells characterized by the presence not of two or four nuclei, as often is the case in epithelioid cells, but of a great number of nuclei (often more than

[1] A small number of leucocytes also are present as a result of emigration.
[2] They may be derived also from true epithelial elements.

100), which assume a quite definite arrangement. The nuclei are usually oval and so distributed as to occupy only a part of the cell, forming a cluster, a crescent, or a nearly complete circle, the rest of the cell being entirely free of nuclei. The nonnucleated portion of the giant cell is usually finely granular, like liver or kidney cells in a state of cloudy swelling; but it may also present a different aspect, *e.g.*, be more or less intensely filled with fat. In the nucleated portion of the giant cell the nuclei are closely packed together and usually so arranged that their greater (long) diameters are almost parallel and sometimes radiate. As a rule, the center and periphery of these cells are free of nuclei. The cell-body is provided with very numerous prolongations which can be

Fig. 218.—Tubercle of the liver, showing giant cell. The liver-cells are indicated by shaded areas. (Zeiss Apochr., 4; Comp. Ocul., 4. After *Langerhans.*)

seen to unite with the reticulum of the tubercle structure. These elements can be recognized in most tubercles at a certain stage of development, *i.e.*, in the fully developed stage. When the tubercles are younger or older, certain deviations from the above-described typic structure occur.[1]

[1] Aside from those forms observed in tuberculosis, giant cells are found chiefly surrounding foreign bodies (foreign-body giant cells). In addition to their presence in granulation tissue, giant cells occur also in the chorionic villi (syncytial cells), in syphilitic foci, in sarcoma (giant-celled sarcoma: epulis), and occasionally in carcinoma (epithelioma). Where bone is destroyed, giant cells, designated as osteoclasts, occur which consume it. In bone-marrow are found giant cells the bodies of which are of great size and contain a single, very large, peculiarly shaped and often lobulated nucleus (megalokaryocytes, myeloplaxes). So-called giant cells are observed also in Hodgkin's disease. H. Steindl states (*Wien. klin. Woch.*, No. 49, 1910, p. 1752) that he has found giant cells in the urine sediment in urotuberculosis. No tubercle bacilli were found, however.

In these tubercles are always found definite vegetable micro-organisms—Koch's tubercle bacilli, usually in considerable numbers—which are often arranged in small groups. The giant cells generally contain a number of tubercle bacilli.

The **tubercle bacillus**[1] (Plate VI, Figs. 1 and 2) is a slender, slightly bent rod 1.5 to 2.5 μ[2] in length. It grows in artificial cultures, best in meat-pepton-agar with 6 per cent. glycerin, at a constant temperature of 37° to 38° C. (98.6° to 100.4° F.). Its growth ceases at a temperature under 30° C. (86° F.). It is very resistant to drying, high temperatures, strong disinfectants, putrefactive action, etc., but under the influence of direct sunlight it perishes in a very short time.

Almost all warm-blooded animals are susceptible to the action of the tubercle bacillus, though in regard to the susceptibility of individual species there are very wide differences according to the origin of the infecting tubercle bacilli. For example, according to Koch and Baumgarten, the bovine species and rabbits are not at all, or only slightly, susceptible to the bacillus of human tuberculosis (*"typus humanus,"* Kossel and Weber), while guinea-pigs are exquisitely susceptible to this bacillus; on the other hand, bovines, rabbits, guinea-pigs, and mammals in general are very susceptible to the bacillus of bovine tuberculosis (*"typus bovinus,"* Kossel and Weber), toward which, on the other hand, man, especially adults, is quite resistant (Baumgarten). Birds in general are immune to both the human and bovine tubercle bacillus; on the other hand, they are highly susceptible to the bacillus of avian tuberculosis; the parrot, however, is susceptible to the bacilli of human, bovine, and avian tuberculosis. Cold-blooded animals are entirely immune to the bacillus of human, mammalian, and avian tuberculosis; on the other hand, they are susceptible to the bacillus of tuberculosis of cold-blooded animals ("fish tuberculosis"), while man, mammals, and birds are immune to this bacillus.

The distribution of tubercle bacilli and their entrance into the human body take place, on the one hand, by inhalation (aërogenous infection), sputum containing tubercle bacilli becoming dried and the bacilli entering the respiratory passages along with rising dust; and, on the other, through the agency of oral secretions containing bacilli ejected by tuberculous subjects during speaking, coughing, etc.[3] Furthermore, infection

[1] This bacillus was described also by Baumgarten independently of Koch (A. Predöhl: "Die Geschichte der Tuberculose," 1888, p. 347). Koch, however, was the first to isolate it in pure culture (*Berlin. klin. Woch.*, 1882, p. 221).

[2] $\mu = 1/1000$ millimeter $= 1/25000$ of an inch.

[3] According to Aufrecht (*Berlin. klin. Woch.*, 1910, No. 40, p. 1829), the route of invasion in pulmonary tuberculosis is by way of the tonsils, cervic and lymph-glands. More advanced pathologic alterations in the lungs and bronchial glands than in the cervical lymph-glands are not convincing proof that these lesions are

PLATE V

Cutaneous reaction, showing the various results with concentrated and diluted tuberculin. Taken forty-eight hours after inoculation by Dr. Henning, at the clinic of Escherich. (After *Fischer*.)

may occur through the gastrointestinal canal, including the oral cavity (tonsils, diseased teeth), by ingestion of material containing tubercle bacilli (milk, etc.); also through the urogenital canal during coitus, and, finally, through the visible mucous membranes (conjunctiva) and the skin in localities which have been injured or perhaps deprived only of epithelium, on contact with parts upon which tubercle bacilli are present.[1]

Inoculation tuberculosis is not rare. Here belong tuberculosis of the skin of the hands of individuals who handle tuberculous material, and cases of tuberculous infection of wounds, *e.g.*, of the prepuce after ritual circumcision, and tuberculous infection of the female genitalia through coitus.

When tubercle bacilli have entered the human body in this manner and given rise to infection, the process is at first entirely local. Further extension is due to increase and dissemination (metastases) of the bacilli in the body.

Tuberculin (cutaneous) reaction. The von Pirquet tuberculin test has rapidly become the favorite in general practice, no doubt owing to the ease with which it can be applied, and also because, unlike the other forms of diagnostic tuberculin application—the conjunctival (Calmette) and subcutaneous (Koch) tests—it is unattended by unfavorable results. Unfortunately, however, its value has been overestimated.

A positive von Pirquet is simply the expression of the altered power of reaction of the organism ("Allergy"), or, in other words: every individual with a tuberculous focus generally gives the reaction, no matter whether the process is active, latent, or obsolete. This is shown by the great number of positive reactions, which Hamburger estimates as 95 per cent. in children 13 years of age, and von Pirquet as 68 per cent. in children over 10 years of age. The variations are very great and referable partly to modifications of the reaction, to differences in concentration of the tuberculin employed, to the frequency of the inoculations (repeated application with negative result), and to difference of the material. Blümel's[2] experience with older children and adults shows the frequency of tuberculosis to be almost as high as that determined by Naegeli in cadavers (97 per cent.). In 53 per cent. of necropsies on children of from 11 to 14 years of age, Hamburger observed tuberculosis as a concomitant (*i.e.*, not as the cause) of death. It must, therefore, be assumed

---

older. Weichselbaum (VI Int. Tub. Conferenz, Wien, 1907) says that deglutition tuberculosis in man, especially in childhood, is much more frequent than most investigators of the past have believed. In this mode of infection invasion may occur not only by way of the stomach and intestine, but also by way of the oral, nasal, and pharyngeal cavities, and synchronously from all these localities, no matter whether the bacilli enter these cavities with the food or other ingesta, with the inspired air, or in any other manner.

[1] In children, injury to the head, without separation of continuity, is sometimes followed by tuberculous meningitis. Here the tubercle bacilli did not enter the body through the trauma; they probably were already present (latent) in the body, *e.g.*, in the lymph-glands, and settled in the injured part made more susceptible to infection with the bacilli.

[2] Fortschritte der Medizin, 1911, No. 11, p. 248.

that, beginning with 1 per cent. in the first year of life, tuberculosis has infected in the period up to the fifteenth year about all who are attacked; that tuberculosis is, as Schlossmann says, a disease of childhood and affections in adults are only reinfections.

The von Pirquet reaction has led to entirely new and important conceptions as to the distribution of tuberculous foci in man; but as to whether the tuberculosis thus rendered so apparent is in every instance active, it alone offers no reliable information.

The character of the reaction in clinicly healthy and actively tuberculous individuals has been compared with the view to applying the difference in intensity and course of the test in diagnosis. The so-called "torpid" or "late reaction," *i.e.*, a reaction occurring only after twenty-four hours or longer, has been regarded as a sign of an inactive tuberculosis; on the other hand, very extensive, intensely hyperemic inoculation papules with vesicle formation are accepted as evidence of an active process. The quality of the reaction, however, by no means always stands in such direct connection with the disease process as to permit from its intensity alone a conclusion as to the activity or inactivity of a tuberculosis. Hamburger justly calls attention to the many sources of error in the application of the cutaneous reaction, emphasizing that its issue depends upon the nature of the wound made, the variable vascularity of the skin, and, in general, upon the individual power of resorption.

In order to decrease the number of positive reactions, different concentrations of tuberculin have been employed; but the avoidance of reaction also in inactive tuberculous subjects has not always been obtained. If at all, it appears that in this way only are we able to determine whether the individual in question is ill or only infected with tuberculosis.

It can only in a general way be said that a very intense reaction is rather an indication that the individual in question is ill with tuberculosis; on the other hand, it must be remembered that scrofula, which is a relatively torpid form of tuberculosis, reacts very actively to inoculation.

The specificity of the reaction must be admitted, even though every positive reaction is not confirmed at necropsy. It must be assumed that in examination, which usually is macroscopic, very small foci may be overlooked. Thus, in Feer's clinic, in 120 necropsies, mostly upon infants, among 24 Pirquet-positive cases there were 2 with negative necropsy findings as regards tuberculosis; 90 cases with negative Pirquet were negative also at necropsy; while in 6 cases with negative reaction and positive necropsy findings, cachexia, tuberculous meningitis, or miliary tuberculosis was found. In the cases just mentioned, as well as in chronic general tuberculosis and measles, the reaction is quite constantly negative (owing to deficiency of antibodies to call it forth); occasionally also in inactive tuberculosis, and after introduction of large doses of tuberculin. In the latter case the reappearance of the reaction is used as an indicator for reapplication of specific therapy. (Jochmann.) Unfortunately, this is one of the few possibilities where the Pirquet can be used as a distinguishing diagnostic feature; here as an indication of the reappearance of tuberculin sensitiveness.

The diagnostic significance of a positive reaction is shown in the first and second year of life. Here the Pirquet is, so to say, decisive, because at this period inactive tuberculosis is rare. For example, Mallinckrodt found in necropsies upon 20 Pirquet-positive infants only fresh tuberculosis. In later childhood and in adults the Pirquet reveals so many inactive healed tuberculoses

that a positive result is not decisive, but is to be accepted with the greatest reserve. For example, in clinicly healthy children Feer found positive reactions in 11 per cent. in the third year, in 22 per cent. in the fifth to seventh year, and in 38 per cent. in the tenth to fifteenth year. The reaction here indicates rather that anatomic alterations are present in the body as residua of a usually healed tuberculous process, but it scarcely enables us to make a clinic diagnosis.

To what diagnostic errors the Pirquet may lead in surgical diseases if it is relied upon to decide as to the tuberculous nature of a bone or articular lesion is shown by an example. In 50 surgical cases diagnosticated as tuberculosis, Makowsky found a positive reaction in every instance, but he found it also in 60 per cent. of his clinicly nontuberculous patients. It is equally as grave a diagnostic error in percussional and auscultatory abnormalities in the apices of the lungs to conclude that a positive Pirquet alone proves the tuberculous nature of the disease or alteration in question. Sufficient erroneous diagnoses have been made here without the Pirquet. The Pirquet has increased these errors and thus augmented the number of nonclinicly tuberculous subjects in sanatoria for pulmonary diseases.

A negative reaction, especially in the second inoculation and with due regard for the exceptions above mentioned, indicates very definitely that the individual in question is not affected with active tuberculosis. In children a negative reaction may often dispel the suspicion of tuberculosis. This estimation of the negative reaction is quite uniformly accepted. The scratch test has been recommended also to determine the sensitiveness to horse serum (diphtheria antitoxin).

Tuberculosis of cattle, pearl disease ("Perlsucht"), which forms large nodules the size of a hemp seed and larger, often arranged in a chain resembling a string of pearls, is probably caused by the same bacillus. In affection of the udder of the cow the "Perlsucht" bacilli enter the milk, and, if the milk is ingested raw, reach the gastrointestinal canal of man in a viable state. According to recent investigations, the assumption that tuberculosis not infrequently is transmitted to man through the milk of tuberculous cows is very probable. This question, however, has by no means been settled.[1]

As inoculation with tubercle bacilli invariably produces tuberculosis in susceptible animals, and as all tubercles (in a strict sense) contain tubercle bacilli, the tubercle bacillus is accepted as the specific pathogenic micro-organism of tuberculosis. Tubercle bacilli, however, occur in the human body not only in typic tubercles, but also in scrofulous lymph-glands, in fungous arthritis, in lupus, and in caseous hepatization. All these processes, therefore, will be discussed in connection with tuberculosis.

In the majority of cases tuberculosis is not congenital—not intrauterine acquired—but acquired after birth. In the passage of the ovum

[1] Experiments carried out by the British Tuberculosis Commission definitely prove that the bacilli found in certain human cases are capable of producing in cattle a disease clinicly indistinguishable from tuberculosis of the bovine type. Furthermore, typic bovine bacilli were discovered in several cases of tuberculosis in man.

through the Fallopian tubes into the uterus and of the spermatozoön from the testes through the vas deferens into the urethra, bacillary action may be exerted upon the sexual cells from the side of the parents. Such action is possible in urogenital tuberculosis in the male. In this case it is not a question of heredity, but of infection of a ready-formed, motile sexual cell previously present in the sexual glands. The fertilized ovum within the uterus may be infected by the mother through the placenta: placental transmission.

Bergman,[1] in the years 1904-1908, observed 108 cases of congenital tuberculosis in calves, of which four were feti and the rest not more than 3 days old. For confirmation of the diagnosis microscopic and bacteriologic examination of the foci as well as animal inoculations were made. A detailed report is given of the pathologic findings in the four feti, in all of which tubercle bacilli were demonstrated. In all 108 cases the portal lymph-glands were involved. The mediastinal lymph-glands were involved 63 times, the bronchial glands 43, the liver 18, and the lungs 10 times. In some cases it was observed that the bronchial lymph-glands and lungs were involved without demonstrable tuberculous foci in the posterior mediastinal glands, and that the lungs were involved without a demonstrable focus in either the bronchial or posterior mediastinal glands. Tuberculosis of the serosa was very rare. In only 1 case were tuberculous neoplasms of the same appearance and structure as those seen in older animals observed upon the costal pleura. Osseous tuberculosis was observed twice. The foci were situated in the spongiosa. Strange to relate, the twin of one calf which was tuberculous showed no signs of tuberculosis. In the placenta of three of the feti examined tuberculous foci were found at the junction between the placenta materna and fœtalis, so that tubercle bacilli could enter the circulation of the fetus from this source. For this reason and because the portal lymph-glands were involved in all cases and often contained foci with much more advanced regressive changes than foci in other parts, it may be assumed that in all these cases the tubercle bacilli were transmitted from the mother to the fetus through the placental circulation. The fact that all the calves and feti were normally developed speaks against germinal infection.

In tuberculous infection h e r e d i t y plays the greatest rôle, not in the sense that all individuals with an inherited taint must necessarily die of tuberculosis, or that only those with inherited taint die of consumption or tuberculosis, but when all those cases which have succumbed to consumption or tuberculosis are investigated as to their descent from tuberculous parents or grandparents it is found that a very high percentage had hereditary taint, and only a very insignificant percentage had no such history. Hence, h e r e d i t y plays the most important rôle.[2] Tersely stated, these inherited peculiarities consist therein that the tubercle bacillus finds in individuals with congenital taint better conditions for lodgment and propagation, or, in other words, a better soil.

[1] Centbl. f. Bakt., Orig., Bd. 52, Heft 2, p. 193.

[2] Quite recently the view has been advanced that descendants of families with tuberculous history gradually acquire through succeeding generations a natural immunity!

What this difference is is still unknown. On the other hand, however, it is known that individuals who have no hereditary taint also may acquire disposition to tuberculosis as the result of influences which injure or weaken the body. To these influences belong, first of all, change of climate, syphilis,[1] general unfavorable hygienic environment (unhealthy dwellings, badly ventilated work-rooms, improper clothing, defective nutrition), and, second, a number of diseases which unfavorably influence the metabolism of the body and diminish the powers of resistance. Dissemination of the bacilli occurs essentially through the sputum of phthisic or tuberculous individuals.

The already described nodules characterized by the presence of tubercle bacilli have no constant size. They are generally described as miliary (*milium:* millet seed); but this is seldom appropriate, because the tubercle is usually the size of a poppy seed or slightly larger; they are, therefore, ordinarily submiliary, *i.e.*, smaller than a millet seed. Very young tubercles of the arachnoid, serous membranes, liver, and omentum are often so small that they can be distinguished only with a loupe, or they appear like minute, transparent-gray dewdrops. These young forms usually contain no giant cells. The older the tubercles the larger they become until, finally, they reach submiliary (arachnoid, mucous membranes, liver), more rarely miliary, size (in the bile-ducts, serous membranes).

With further growth an occasionally pale-yellow, usually a whitish, cloudy center appears within a gray-translucent nodule, the fluid constituents being absorbed and a dry, amorphous, dead (cheesy) albuminous mass resulting from inspissation. This caseous metamorphosis is almost the rule, but is not pathognomonic of tubercle, since caseation occurs often in pathology as the final stage of proliferations and inflammations. Furthermore, caseation is not the only form of retrogressive metamorphosis in tubercle; in addition to caseation more or less intense, often very marked fatty metamorphosis, and usually only partial fibrous degeneration or retrogression also occur. Fatty and fibrous metamorphosis are found chiefly in tubercles which persist for a long time (*e.g.*, in the serous membranes), and do not disintegrate like tubercles of the mucous membrane. A moderate degree of fatty metamorphosis very often occurs also near extensive caseation; it is then limited (*e.g.*, in tubercles of the kidney and liver) to those areas in old tubercles which have undergone retrograde metamorphosis, where the central, caseated zone (the region of epithelioid cells) joins the small-celled, noncaseated periphery of the tubercle. All tubercles, how-

[1] See footnote, p. 431.

ever, do not become caseous; some (*e.g.*, in the submucosa and liver) occasionally undergo complete fatty metamorphosis, and may finally disappear by absorption. This process is very rare; incomplete fatty metamorphosis is most frequent, especially in the periphery of the nodules.

The further history of tubercle varies greatly according to its location. Superficial tubercles, particularly those of the mucous membranes of the respiratory, urogenital, and digestive tracts, which are subjected to much irritation, generally break down very early, often before caseous metamorphosis is distinctly visible, disintegration starting at the surface. Caseated tubercles disintegrate by softening and liquefaction of the caseous material by absorption of water. The margins of this primary ulcer are, at first, still caseous. By progressive destruction of the tubercle, however, the ulcer gradually becomes cleansed and a characteristic, flat, lenticular ulcer (*ulcus lenticulare*) develops; as a rule, this lenticular ulcer, typic of disintegration of a tubercle, very early loses its characteristic form by confluence with other tuberculous ulcers as soon as new tubercles develop in its neighborhood, base, and margins, and form secondary ulcers by disintegration. The secondary (corroding) ulcer (*ulcus rodens*), in contradistinction to the simple lenticular ulcer, has irregular, ragged, excavated margins, and an uneven base. Small caseated tubercles often can be recognized with the naked eye in the walls and floor of the ulcer. On the other hand, the primary (lenticular) and the secondary (corroding) ulcers may combine with other ulcers (*e.g.*, follicular) arising from follicular abscesses, whereby the form of the ulcer (*e.g.*, in chronic intestinal tuberculosis) is rendered more complex. In other cases they may become cleansed and cicatrize.

Cicatrization is always attended by retraction, which, in mucous canals (intestine), may result in decided narrowing of the lumen (stenosis). Frequently cicatrization is incomplete, only a portion of the ulcer cicatrizing, the other portion spreading by eruption of new tubercles, or new eruption of tubercles occurs in the cicatrix itself.

Tubercles of serous membranes, the omentum, arachnoid, choroid, retina, testes, and liver, with exception of tubercles of the bile-ducts, do not ulcerate, but may undergo partial resolution by absorption and fibrous degeneration.

If infection occurs in any of the localities mentioned, *i.e.*, if tubercle bacilli have found lodgment and excited a local tuberculosis, further invasion of the body may take place by certain channels or routes. These are, first, the lymph- and blood- channels; second, the remaining

ducts and canals of the human body. In general, it is observed that tuberculosis extends chiefly in the direction of the lymph-stream. Extension by the blood-current seems to depend upon opening of blood-channels, injury to vessels. In some cases, *e.g.*, in disintegration of tuberculous bronchial glands, when the process involves the wall of a

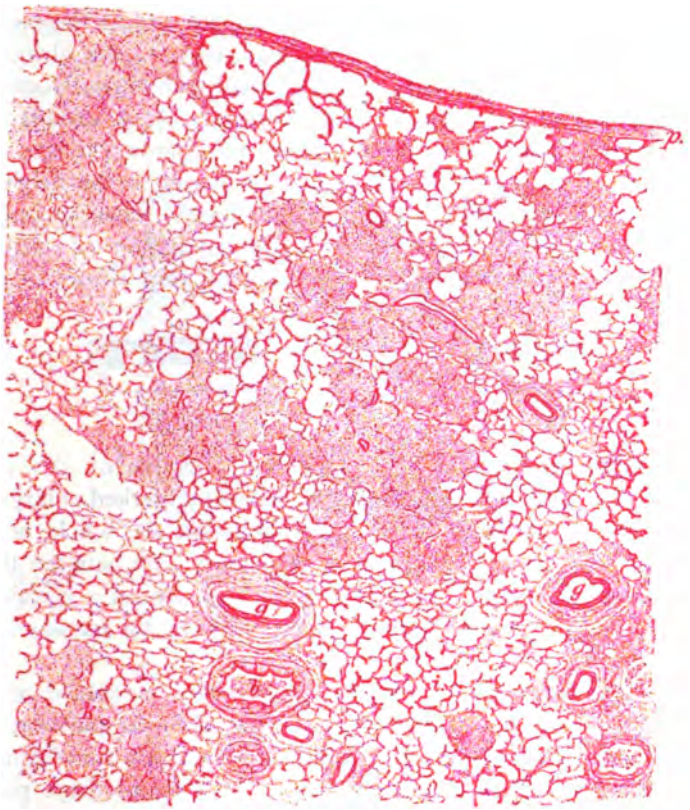

Fig. 219.—Tubercular bronchopneumonia. The foci are partly bronchopneumonic, partly resorption tubercles. Nodules about the bronchi, in places confluent, as at *k*. *i*, aërated parenchyma; *b*, large bronchiole; *g*, vessels; *p*, pleura. Orcein stain. × 20. (After *Smaus*.)

bronchus and material containing tubercle bacilli is discharged from the lymph-gland into the bronchus, tubercle bacilli may be disseminated into the area supplied by this bronchus.

The formation of tubercle is frequently associated with inflammatory processes of neighboring parts: *e.g.*, tubercles of the pleura with fibrinous pleuritis. These processes are not necessarily interdependent, for tuberculosis of the pleura can exist without, as well

as with, pleuritis. Inflammation may stand in co-ordinate relation to tubercle formation, *i.e.*, the tubercle may originate first and inflammation follow, or inflammation may be primary and tubercle formation occur in the inflammatory product, *e.g.*, in pleuritic adhesions. In the first instance (Fig. 220) the tubercle (*a*) is situated in the pleura, (*b*), and the exudate (*c*) covers the pleura; in the second instance (Fig. 221) the tubercles (*a*) are located in the exudate (*c*) of the pleura (*b*). In the latter case vascularization and organization of the fibrinous exudate had already begun, and the tubercle bacilli subsequently entered the new-formed capillaries with the blood-current. At a certain stage of development of tubercle, especially when retrograde changes are distinctly visible, inflammation is almost never absent in the neighborhood of the tubercles (pneumonia around pulmonary tubercles, peritonitis around tubercles of the peritoneum). Inflammation of surrounding parts is frequently lacking only in eruption of very young tubercles.

Fig. 220.



Fig. 221.

By **scrofulosis** is understood a definite affection of the lymph-glands. This disease is usually characterized by marked enlargement of the lymph-glands of the neck; as a consequence, the whole neck often swells to such an extent that the lines of demarkation between the lower jaw and breast disappear. In this manner is produced a certain resemblance to the short, thick neck of the swine. Hence, the name scrofula (from *scrofa*: a sow).

The swelling of the lymph-glands is almost always of a secondary nature, the result of local alterations in the root area of the lymph-vessels, especially of the skin and mucous membranes (dermatitis, catarrhal inflammations, ulcers, etc.). From these points the tubercle bacilli are conveyed by the lymph-current to the lymph-glands, where they are, as it were, filtered out and cause inflammatory hyperplasia of the gland-cells. Not every swelling of the submaxillary, jugular, cervical, and mesenteric glands is designated as scrofula, but only such as is more intense than the original local affection in the root area of the lymph-vessels, is of chronic duration, and, therefore, generally manifested more as an independent affection of the glands. In fact, the primary alteration is very frequently sought in vain. This pronounced involvement of the lymph-glands after quite insignificant primary affections in the root area of the lymph-vessels can be explained only by an especial vulnerability of the lymph-glands.

As a result of hyperplasia of the lymph-gland cells, scrofulous lymph-glands often swell ten, even fifteen, fold; through the uniform swelling quite soft, somewhat flabby tumors originate. The new-formed cells possess no stability, but, like the cells of tubercle, soon perish by caseous metamorphosis and, certain parts becoming firmer and denser, produce a dry, necrotic proteid mass which remains *in loco*. The gray or grayish-red, moist, glistening cut surface, which at first is quite uniform, thus acquires in certain areas a yellowish-white or white, opaque, and dry appearance. Sometimes the whole, sometimes only part, of the gland is altered in this manner. In scrofula, therefore, the primary—

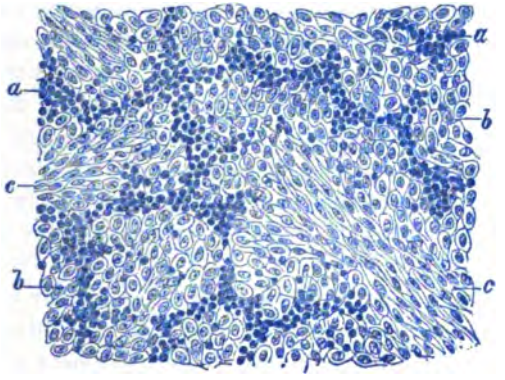

Fig. 222.—Tuberculous large-celled hyperplasia of lymphatic gland. *a*, remnants of lymphadenoid tissue; *b*, large round-celled tissue; *c*, spindle-celled tissue. × 150. (After *Ziegler*.)

hyperplastic—stage is generally followed by the second, namely, the stage of caseous metamorphosis.

The caseous material may either remain *in loco* or, by softening and liquefaction, give rise to the so-called granular detritus. In the latter instance inflammation and suppuration in the neighborhood are not infrequent. By mixture of the pus with the liquefied caseous masses, so-called "cold abscess" develops. With advancing disintegration, this may rupture externally and produce a scrofulous ulcer, which heals always with the formation of a radiate, retracted cicatrix. Sometimes diminution in the size of the gland occurs as the result of partial absorption without rupture externally. The remnant of the gland then becomes surrounded by a dense connective-tissue capsule and may calcify. In rare instances scrofulous glands may disappear entirely by marked fatty metamorphosis and absorption.

Tubercle bacilli are found in scrofulous glands, but not in such

numbers as in tubercle. They are sufficiently numerous, however, almost always to be detected without great difficulty.

There are three points of predilection for scrofulous alterations of the lymph-glands: the cervical region, the region of the bronchial glands and of the anterior and posterior mediastinum, and the mesenteric glands. All these regions stand in a dependent relation to the local alterations in the respective lymph-vessel root area.

To those regions from which the scrofulous glands receive the tubercle bacilli belong the eye (scrofulous eye diseases, e.g., *conjunctivitis phlyctænulosa* and *keratitis phlyctænulosa*), the nose (ozena, a purulent rhinitis characterized by a foul odor, which in severe cases is associated with ulceration), carious teeth, the crypts of the tonsils, the pharynx (*pharyngitis granulosa follicularis;* sometimes the tonsils and lingual follicles are involved: *angina scrofulosa*), the intestine (*enteritis follicularis scrofulosa,* scrofulous intestinal catarrh), and the skin (scrofulous exanthemata). All these diseases are called scrofulous when and because they are immediately connected with glandular affection. They develop chiefly in childhood, and are characterized by chronicity and a tendency to recur.

Tuberculosis and **scrofula,** therefore, are similar in many respects. In both, tubercle bacilli are found; in both, the process begins with proliferation; the new-formed cells in the periphery of a tubercle and of the swollen glands are similar, *i.e.,* possess the character of lymphoid corpuscles; in both, the new-developed cells are of inferior stability and manifest a great disposition to undergo caseous degeneration. In the lymph-glands, however, the process concerns normal tissue which increases markedly in amount—an hyperplastic lymphoma; and in tubercle connective tissue does not develop in the connective tissue, but a lymphatic formation, *i.e.,* an heteroplastic lymphoma. From an anatomic standpoint, therefore, it is incorrect to consider both processes as identic, as is often the case. It is incorrect, also, from a clinic standpoint; for as nearly as scrofula and tuberculosis are related they, nevertheless, manifest decided differences in their clinic course and issue. Above all, it is of essential significance for prognosis whether an individual has tuberculosis or scrofula. Very many persons who were scrofulous in their youth fully recover from their affection in later life; at any rate, very many more than tuberculous cases which regain health.

Scrofula is chiefly a disease of childhood—of the immature, still growing tissues, while tuberculosis, on the average, begins somewhat

later, frequently with the advent of puberty. That, on the other hand, both affections are nearly related also from a clinic standpoint, is shown by the quite frequent coexistence of both diseases; furthermore, by the fact that, in both, the local disposition (for this only is inherited and not the disease itself) is of very great significance; that general bad hygienic surroundings as well as antecedent diseases favor the outbreak, and that tuberculosis quite often follows scrofula.

In adults the bronchial glands are rarely affected by tuberculosis except in connection with disease of the lung; in children, however, they are regarded by some as a very common site of primary tuberculosis. The tubercle bacillus may gain entrance to the bronchial glands through the tonsils or the pharyngeal, tracheal, or bronchial mucosa without any visible lesion in these parts or any affection of the lung. In cases resulting in general miliary tuberculosis the bacillus may enter the circulation from the glands either through the thoracic duct or by penetration of a vein by a softened gland. Direct infection of the lung from the bronchial glands may occur: (*a*) through a branch of the pulmonary artery, resulting in miliary infection of the part of the lung affected; (*b*) Aufrecht believes the bacilli may pass from a tuberculous gland through a healthy vessel wall; (*c*) through the lymphatics at the hilus. Infection follows first the peribronchial lymphatics, leaving the bronchial lumina and the alveoli intact. The bronchial walls are thickened and distorted; their lumina narrowed. When the disease invades the bronchial lumen the sputum becomes purulent and contains the bacillus and elastic fibers. Hemoptysis may occur. Rupture of a softened gland into the mediastinum, pleural cavity, the trachea, or bronchi may occur, especially in children.

As today there can be no doubt of the pathogenetic relation of the tubercle bacillus to scrofula as well as to tuberculosis, the question arises: Why, in one case, does the body react with scrofulous alterations, in the other with the formation of tubercles? This question cannot as yet be conclusively answered. Possibly the virulence of the tubercle bacillus is not always the same; it is more probable, however, that the reason is to be found in the greater or less disposition—in an altered chemic state of the tissues—of different individuals. The fact that many persons who manifest no disposition to tuberculosis and who, in spite of frequent opportunity for infection with tubercle bacilli, never become tuberculous or scrofulous, speaks in favor of this view. Although the exact reason why scrofula originates in one instance and tuberculosis in another is still unknown, it is always necessary to separate the two processes; just as in syphilis, gummous and interstitial processes, and in pulmonary consumption tubercular processes and caseous hepatization can and must be differentiated.

Just as human individuals react differently toward the tubercle bacilli, so also the various tissues manifest a greater or less disposition or immunity to tuberculosis. The parts most frequently attacked by tuberculosis are the mucous membranes of the

respiratory tract and intestinal canal. In the latter, the mucous membrane of the esophagus, which is covered by stratified squamous epithelium, manifests the least tendency to the formation of tubercles, and only a slight tendency is shown by the mucous membrane of the stomach and duodenum. Tubercles are of rare occurrence in the anterior portion of the mouth; in the pharynx and tonsils they are somewhat more frequent. Points of predilection are the small and large intestine, tubercle occurring oftener in the ileum than in the jejunum, and in the cecum and ascending colon more frequently than in the transverse colon, and in the latter more frequently than in the descending colon and rectum. Tuberculous processes, therefore, belong more to the lower portion of the digestive canal, *i.e.*, to the region that is chiefly involved in typhoid fever. Next to the mucous membranes the parts most frequently involved are the serous membranes, the omentum, spleen, bone-marrow, arachnoid, kidneys, suprarenals, middle ear, brain, uterus and Fallopian tubes, testes, and urinary bladder. The salivary glands, thyroid, mammæ, ovaries, musculature, panniculus adiposus, and cartilage are relatively immune.

Primary tuberculosis occurs most frequently in the respiratory passages, much rarer in the digestive canal (usually secondary to swallowing of sputum containing tubercle bacilli), and somewhat more frequently in the skin, bones, and joints, the urogenital canal, the serous membranes, and tonsils. Secondary tuberculosis is observed especially in the intestine, lymph-vessels, lymph-glands, serous membranes, liver, spleen, urinary bladder, etc.

Primary tuberculosis develops through the action, at the point of entry—*i.e.*, at the primary focus of infection—of tubercle bacilli which have gained admission to the body from without. Secondary tuberculosis, in contradistinction to the former, is always to be looked upon as metastatic, *i.e.*, bacilli from the primary focus entering the immediate neighborhood or are conveyed to distant parts and organs with the lymph- or blood- stream. The best example of metastasis is acute general miliary tuberculosis. This is characterized by simultaneous eruption of tubercles in all nonimmune organs of the body. The eruption produces symptoms similar to severe typhoid, with which it often is confused, and invariably causes death within a short time. At necropsy usually only slight retrogressive metamorphosis is present in the disseminated nodules. There are generally no signs of inflammation in the periphery of the tubercles. Miliary tuberculosis is always due to transportation of tubercle bacilli with the circulating blood, and usually follows softening of caseous masses containing tubercle bacilli: softened caseous lymph-glands, caseous hepatizations, or

other caseated parts. The focus from which the body is deluged with tubercle bacilli cannot be found in every case. Acute general miliary tuberculosis comparatively often follows hemoptysis. It is conceivable that, when a blood-vessel bursts and the blood-current stirs up the tuberculous caseous masses present in an ulcerated pulmonary cavity, tubercle bacilli from this material may enter the blood-channels and produce

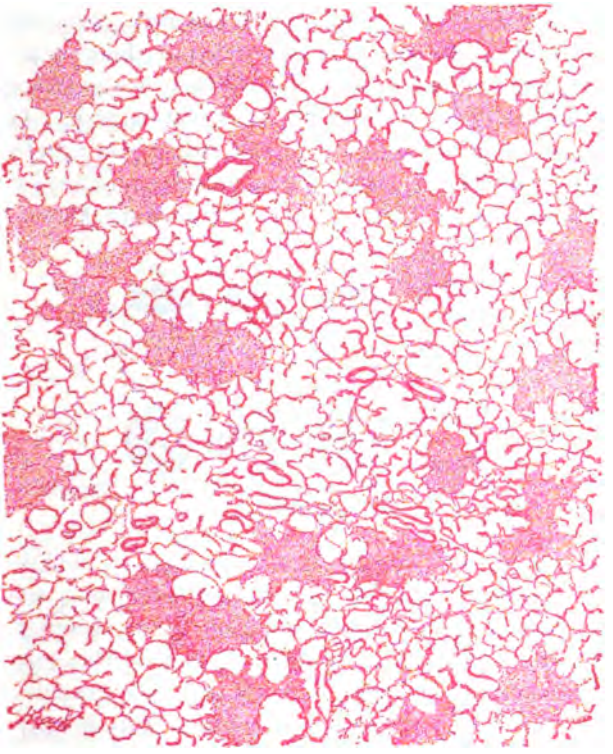

Fig. 223.—Acute miliary tuberculosis of the lung. Disseminated tubercles. Orcein stain. × 20. (After *Smaus.*)

metastases in all other organs. It is equally as comprehensible that acute miliary tuberculosis develops when a softened caseous lymph-gland ruptures directly into a blood-vessel (vein) or caseous material is conveyed to the blood through the thoracic duct; when a bloody operation is performed upon tuberculous bones or joints, or when a gibbus or curvature of the spine, in which caseous masses lie, is forcibly straightened. In very rare instances large tubercles upon the cardiac valves, endocardium, intima of the aorta or other arteries may, in the same manner, cause acute general miliary tuberculosis.

In contrast to acute general miliary tuberculosis stands chronic tuberculosis of individual organs.

In chronic tuberculosis of the respiratory system —**pulmonary consumption** in a strict sense—the affections of the bronchi and of the true lung parenchyma must be differentiated.[1]

Observation is rendered difficult by the fact that, in addition to genuine tubercles, there are other nodules which, upon superficial examination, may easily be mistaken for tubercle, but, in a strict sense, do not directly correspond to tubercles. These are pathologicly altered bronchi, the sequelæ of a usually old bronchial catarrh. The bronchial changes may occur in various forms: as true tuberculous bronchitis (*bronchitis tuberculosa*), caseous bronchitis (*bronchitis caseosa*), and fibrous bronchitis (*bronchitis fibrosa*).

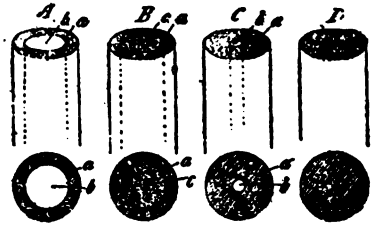

Fig. 224.

In tuberculous bronchitis, submiliary nodules—tubercles —develop in the mucous membrane of the bronchus, which, like all tubercles of mucous membranes, soon disintegrate, leaving tuberculous ulcers (*ulcera tuberculosa*). Eruption of new tubercles generally occurs in the neighborhood, whereby the mucosa becomes strongly swollen and undergoes caseous degeneration; the lumen is thus greatly diminished. (Fig. 224, *C, b.*) When altered in this manner the smaller bronchi (of submiliary size) appear on section almost like a caseated tubercle. Upon more careful examination, however, a small opening—the lumen of the bronchus—can, in the majority of instances, be seen in the center of the nodule. (Fig. 224, *C, b.*) If there is any doubt, it is necessary only to place a little blood upon the locality; this collects in the center —within the narrowed lumen—as a small, red spot.

---

[1] In pulmonary tuberculosis it frequently is a question whether the bacilli enter the lung directly with the air (aërogenous infection) or through the blood from other parts of the body (hematogenous infection), or whether the lymph-channels are the route of transport (lymphogenous infection). To reach a decision in this respect all features of the case must carefully be considered.

Intimately related to tuberculous bronchitis is caseous catarrhal bronchitis: *bronchitis catarrhalis caseosa* (Fig. 224, *B*), an originally purely catarrhal affection of the bronchus—an inflammatory swelling of the mucous membrane with secretion of catarrhal material. When the latter is tenacious and mucopurulent in character, retention and occlusion of the small bronchi may easily occur. The next step is gradual inspissation and caseous metamorphosis of the contents of the bronchus. (Fig. 224, *B, c.*) On section such a bronchus may still more readily be mistaken for a caseated tubercle, since no lumen (Fig. 224, *B, c*) can be recognized. Usually, however, differentiation is not difficult, because these bronchitides—the tuberculous, and especially the catarrhal—simultaneously attack a number of small bronchi which form branches of a large bronchus. (Fig. 225, *A.*) Consequently, grape-like groups of small caseous nodules are seen upon section. (Fig. 225, *B.*)

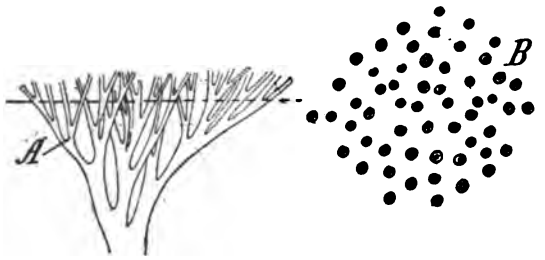

Fig. 225.—Schematic drawing of caseous bronchitis. *A*, longitudinal section; *B*, transverse section. (After *Langerhans.*)

In obliterating fibrous bronchitis: *bronchitis fibrosa obliterans* (Fig. 224, *D*), connective-tissue growth occurs within the wall and partly also in the periphery of the bronchus as a result of chronic catarrhal conditions. This new-formed connective tissue gradually condenses and retracts, and finally produces complete obliteration of the lumen. Upon section such bronchi appear like groups of small, submiliary, gray, translucent nodules resembling quite fresh, noncaseated tubercles. On incision it is found that the apparent nodule is a solid, fibrous cord (Fig. 224, *D*) connected with the adjacent bronchi. The center of such a group is usually the seat of slaty induration.

Occlusion of the lumen with caseated exudate and fibrous obliteration usually involve only small bronchi with a diameter of submiliary size. The medium-sized and large bronchi, the trachea, and the larynx generally present only the changes of ulcerative tuberculous bronchitis.

In the **larynx,** in addition to flat tuberculous ulcers which destroy more or less the inner surface of the epiglottis, the false and true vocal cords, deep ulcers are found situated chiefly upon the vocal proc-

esses of the arytenoid cartilage. In the base of these ulcers eroded cartilage—the arytenoid cartilage deprived of perichondrium—is generally observed. These deep ulcers develop as the result of purulent arytenoperichondritis which ruptures toward the larynx at the vocal process. When the changes are severe, complete destruction of large portions of the larynx occurs: the true and false vocal cords, the whole epiglottis, and the aryepiglottic folds. The process then always involves the pharynx also, and destroys the region of the *aditus ad laryngem*, especially the base of the tongue and the tonsils.

In connection with these different forms of bronchitis pneumonia frequently develops in those portions of the lung belonging to the affected bronchi. The alveoli become filled with a fibrinocellular



Fig. 226.—Bronchitis fibrosa obliterans multiplex. *b*, obliterated fibrous bronchi; *k*, group of small caseous nodules (caseous bronchitis) with slaty, indurated center. (Natural size. After *Langerhans.*)

material which may undergo the same alterations as are possible in other pneumonic processes (fatty metamorphosis and resolution, suppuration, gangrene), though in the majority of instances it becomes denser and drier by inspissation: caseous hepatization. The area of caseous hepatization frequently corresponds to the terminal area of a small bronchus—a lobule—but it may be smaller, *e.g.*, about miliary size, only the center of a lobule being involved. It is then designated as miliary caseous hepatization. This pneumonia is not, however, caseous from the beginning; a caseous exudate is not formed, but caseation is only the termination of the catarrhal or fibrinous or mixed fibrinocatarrhal pneumonia.[1] Therefore, in a strict sense, we can speak

[1] Fibrinocatarrhal bronchopneumonia is the most frequent form of pneumonia in chronic pulmonary consumption.

only of a caseous hepatization, but not of a caseous pneumonia.

In acute pulmonary phthisis large areas and even whole lobes are generally found in a state of caseous hepatization, numerous adjacent lobuli becoming involved and altered in the same manner and forming large foci by confluence. Under certain conditions, however, a lobar hepatization which originally was fibrinous may undergo casea-

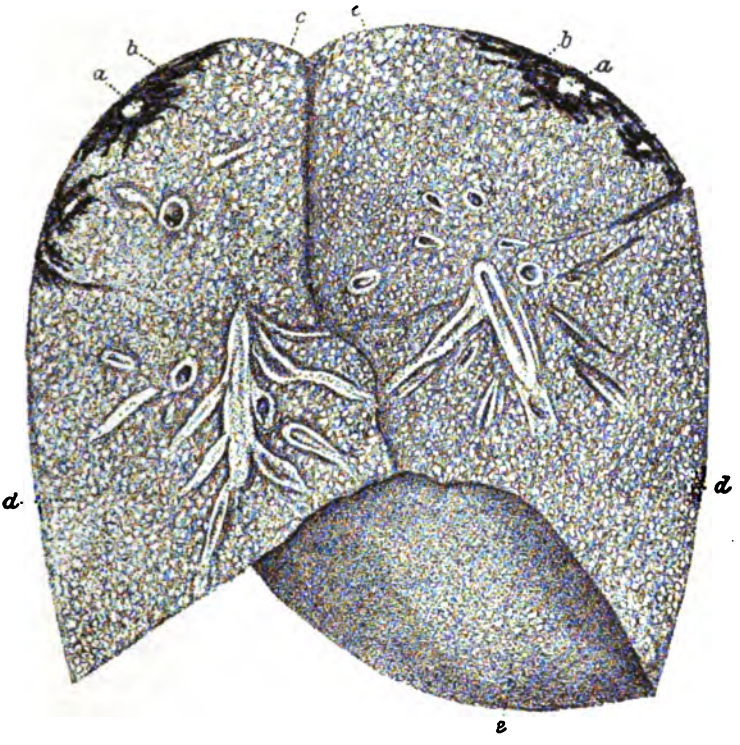

Fig. 227.—Acute pulmonary miliary tuberculosis (cut surface of the lung). *a*, so-called obsolete tubercle (old encapsulated caseous focus); *b*, induration; *c*, caseous, partly agminated nodules (transverse section of caseous bronchi); *d*, submiliary, noncaseated tubercle in the true lung-tissue; *e*, tubercle of the pulmonary pleura. ½ natural size. (After *Langerhans.*) (See Fig. 235.)

tion, namely, when an old caseous focus containing tubercle bacilli is present in the same lobe or apex of the lung. In these cases typic lobar fibrinous pneumonia is the first clinic manifestation, because the older caseous focus generally causes no symptoms until the establishment of the pneumonia. Simple softening or purulent liquefaction of the extensive caseous hepatizations produces the typic picture of *phthisis florida*, or galloping consumption.

As tubercle bacilli are almost always found in these caseous hepatizations, the term tubercle has been applied to them also. Nothing, however, is better calculated to obscure a clear conception of these processes than this inaccurate and inappropriate designation, for there certainly is a very decided difference whether a tumor nodule develops in the tissue or an exudate forms upon the surface! Nor should we be misled by the fact that the subsequent course of caseous hepatization is always disintegration and cavity formation. In caseous hepatized areas the circulation is very soon arrested by strong distention of the alveoli with exudate and by compression of the capillaries; the plugs of exudate adhere firmly to the alveolar wall; the latter is rendered totally anemic, and, becoming necrotic, finally forms with the caseous plugs a quite uniform, coherent, dead mass. Softening and disintegration of the caseous hepatized area then result in the formation of an ulcerated cavity. On the other hand, cavities develop also from tuberculous bronchitis and caseous catarrhal bronchitis: in the former by the formation and disintegration of tubercles which gradually destroy the bronchus and attack successively the adjacent lung tissues; in the latter, by disintegration of the contents of the bronchus and development of a purulent process in the mucous membrane which gradually extends into the depth. In all three instances disintegration involving the true lung tissue—the alveoli—as well as the bronchi and vessels, is always finally established.

The ulcer cavity (*caverna ulcerosa*) may rapidly increase in size by hepatization, coalescence, and softening of adjacent alveoli, or it enlarges through development at the junction of the healthy lung tissue of a so-called pyogenic, or granulation, membrane which secretes more or less pus, and gradually breaks down by suppuration. The superficial red granulation layer being destroyed, sometimes under formation and disintegration of tubercles, so-called rice-bodies—*corpora oryzoidea*—are produced. These are small, whitish-gray flocculi composed of necrotic, disintegrated tissue. At the same time a new, quite dense layer may develop in the periphery as the result of new round-celled proliferation and vascularization, only the adjacent alveoli being involved, the rest of the lung tissue remaining temporarily healthy. This is a very chronic process, which may persist for years, often be arrested, and sometimes become circumscribed, scar tissue taking the place of the granulation tissue (cavities with smooth wall).

By combination of all these processes the most varied and often most puzzling changes are produced in the lungs in chronic phthisis. In many cases, therefore, it is often impossible, macroscopicly, to determine whether a caseous nodule corresponds to a tubercle or a bronchus.

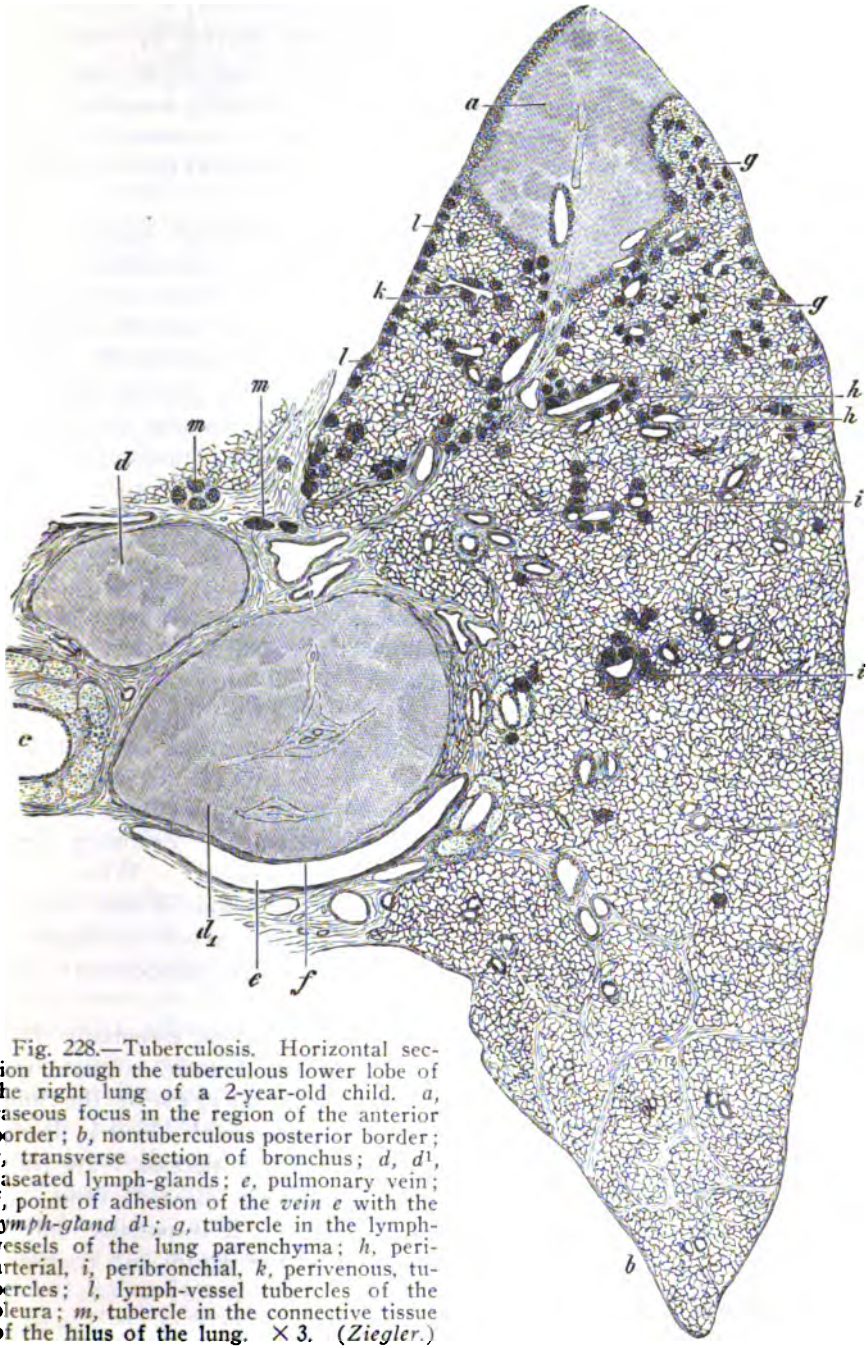

Fig. 228.—Tuberculosis. Horizontal section through the tuberculous lower lobe of the right lung of a 2-year-old child. *a*, caseous focus in the region of the anterior border; *b*, nontuberculous posterior border; *c*, transverse section of bronchus; *d*, d^1, caseated lymph-glands; *e*, pulmonary vein; *f*, point of adhesion of the *vein e* with the *lymph-gland* d^1; *g*, tubercle in the lymph-vessels of the lung parenchyma; *h*, periarterial, *i*, peribronchial, *k*, perivenous, tubercles; *l*, lymph-vessel tubercles of the pleura; *m*, tubercle in the connective tissue of the hilus of the lung. × 3. (*Ziegler.*)

While new destruction occurs in the neighborhood of cavities and enormous and irregularly shaped cavities often develop by coalescence of the ulcerations, slaty pigmented indurations and thickenings, with obliteration of the aërated parenchyma, are generally associated with the chronic bronchitic affections, as a result of chronic interstitial proliferations. This produces the slaty induration (*induratio pigmentosa*) so frequently observed.

In large cavities the arteries resist the ulceration longest. The veins very early become thrombosed and then are destroyed by the advancing ulceration. The arteries, on the other hand, often remain relatively intact even when all the surrounding parts have disintegrated, the strong media (muscularis), composed of smooth muscle-cells, longest resisting the processes associated with caseation. The arteries then form cords radiating from the hilus of the lung and running through the center or upon the surface of the ulcerated cavity; finally, these also are involved in the disintegration, and not infrequently they are destroyed before the vessel-lumen has been occluded by a firm thrombus. Then fatal hemoptysis generally occurs from the larger vessels. Small hemorrhages from erosion of the smaller vessels are not, as a rule, fatal; indeed, they may frequently recur. After ulcerative destruction of larger arterial vessels, if the hemorrhage has not been fatal, the stumps often remain visible for a long time upon the surface of that side of the cavity toward the hilus of the lung. This is an important diagnostic point in deciding whether a cavity originated by ulceration or not.

In almost all cases of chronic pulmonary consumption, old and fresh pleuritic alterations occur, principally exudative processes, which result in the formation of adhesions. When, as is often the case, these frequently recur *in loco*, adhesions of very variable thickness (1 cm. or more) and quite characteristic, almost cartilaginous, hardness gradually develop and sometimes undergo calcification: *pleuritis callosa.*

Chronic pulmonary phthisis, therefore, develops essentially from affections of the bronchi. A characteristic feature is that, with few exceptions, the process begins in the apices of the lungs and from there extends more or less slowly downward. If it is desired to learn how the process began and advanced, it is necessary always to examine the youngest, hence generally the lowest, diseased zones. In localities where ulceration has already occurred, it is possible only in rare instances to obtain a clear conception of the nature and course of the process.

The question whether the *Bacillus tuberculosis* alone is responsible for the symptoms observed in patients with pulmonary tuberculosis or whether these symptoms are not mainly due to an associated, more or less chronic infection or septicemia caused chiefly by pyogenic or other cocci is an important one. Bacteriologic examination of the contents of the cavities *post mortem*, or of the walls of the cavities, is open to the objection that the bacterial flora may have gained access during or shortly after death. Investigation of the pulmonary juices extracted by puncture during life has been used, but is not free from objections. Finally, bacteriologic examination of the circulating blood has often been made in tuberculous subjects. According to Baduel,[1] combining the results of all these methods of investigation, 25 authors have found streptococci in tuberculosis, 23 have found staphylococci, and 15 have found Fraenkel's diplococcus or some closely related bacterium. Some authors attribute the majority of the symptoms observed in pulmonary tuberculosis to these secondary infections, which, they claim, convert tuberculosis into phthisis or chronic septicemia. Others adhere to the view that Koch's bacillus and its toxins can produce all the signs and symptoms unaided, the former thus upholding the "duality," the latter the "unity," of phthisis. According to the "dualists," most of the symptoms (fever, hemoptysis, emaciation, sweating, gastric and nervous disturbances) and the spread of the tuberculosis in the lungs are mainly due to the associated cocci. Thus, association of the *Bacillus tuberculosis* with streptococci produces a rapidly progressive type of pulmonary phthisis, with much destruction of lung-tissue; diplococcic infection leads to the production of the bronchopneumonic type of phthisis, and, in particular, to the occurrence of hemoptysis; staphylococcic infection, to a more slowly advancing type of phthisis, with lesions mainly at the apex. Baduel has taken blood-cultures from 42 patients with not too advanced pulmonary tuberculosis at various periods in the evolution of their disease. He was unable to find the *Bacillus tuberculosis* in their blood. In 35 out of the 42 patients he cultivated Fraenkel's diplococcus from the circulating blood; in 7 the blood appeared sterile; in addition *Staphylococcus pyogenes albus* was grown in 2 of the 35 cases, and a streptococcus in 2 more. In a further series of 3 patients with chronic pulmonary tuberculosis, coming into hospital with miliary tuberculosis, this author was able to isolate the diplococcus from the circulating blood.

Tuberculosis of the digestive tract is limited principally to the small and large intestine. Tuberculosis of the stomach occurs, but is rare, and consists only in the development of a few small ulcers. Tuberculosis of the esophagus is still rarer. On the other hand, tuberculous affections of the tongue are more frequent, not only at the base (see p. 454), but also in the middle and anterior portions, chiefly at the margins, less often upon the upper surface (dorsum).

In intestinal tuberculosis: *enterophthisis tuberculosa*, large ulcers develop from lenticular ulcers (see p. 444) by progressive new formation and disintegration of tubercles. As a rule, these have a tendency to spread at right angles to the long axis of the intestinal lumen, in the direction of the lymph-vessels, and often to form more or less annular ulcers: *ulcera annularia*.

[1] Ref. The Med. Chron., March, 1910, p. 389.

If tuberculous intestinal ulcers are very numerous, they generally occur close together, very little unaltered mucosa remaining between them. With further advance of ulceration, the tendency to the formation of annular ulcers is usually still quite marked, although gradual progression in the direction of the long axis of the intestine also occurs, the spaces between the individual ulcers becoming smaller and smaller until confluence of numerous adjacent ulcers finally takes place. As constantly enlarging ulcer surfaces thus develop and the unaltered mucosa is more or less encroached upon, often being reduced to small islands within the large, flat ulcerations, the annular form of the ulcers gradually disappears. These severe forms of tuberculous ulceration are generally very early associated with follicular ulcers and abscesses.

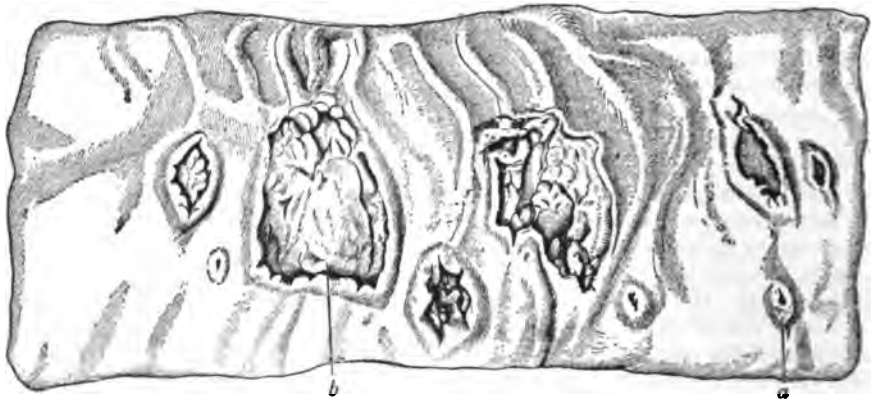

Fig. 229.—Tuberculous intestinal ulcer. *a*, small follicular ulceration; *b*, large ulcer. (After *Ziegler*.)

The coexistent catarrhal secretions (diarrhea) do not arise primarily from the ulcerated surfaces, but essentially from the uninvolved portions of the intestinal mucosa. The latter is always in a state of acute or chronic catarrhal inflammation: acute or chronic catarrhal enteritis.

Partial cicatrization of tuberculous intestinal ulcers is not infrequent; complete cicatrization, however, is rare. Cicatrization is always accompanied by narrowing of the lumen, which is sometimes so marked as to cause stenoses with their sequelæ (dilation of the upper portion, rarely symptoms of incarceration).

Ulcerative tuberculous enteritis is almost always associated with tuberculous lymphangitis, as a result of thickening of the walls of the lymph-vessels and formation of tubercles within them; tuberculous lymphadenitis of the mesenteric glands is also usually

present. Tubercles of the lymph-vessels are most distinct in the subserosa of the intestine, *i.e.*, upon the outer surface of the bowel; they are often arranged in delicate chains, resembling a string of pearls. (Fig. 231.) The peritoneum is strongly thickened in this locality, most markedly at that point where the process has existed longest, *i.e.*, over the center of the ulcer. The vessels of the serosa are frequently very intensely congested in the region of the change.

Tuberculous intestinal ulcers generally extend only to the submucosa; in severe and very chronic cases, however, the muscularis also

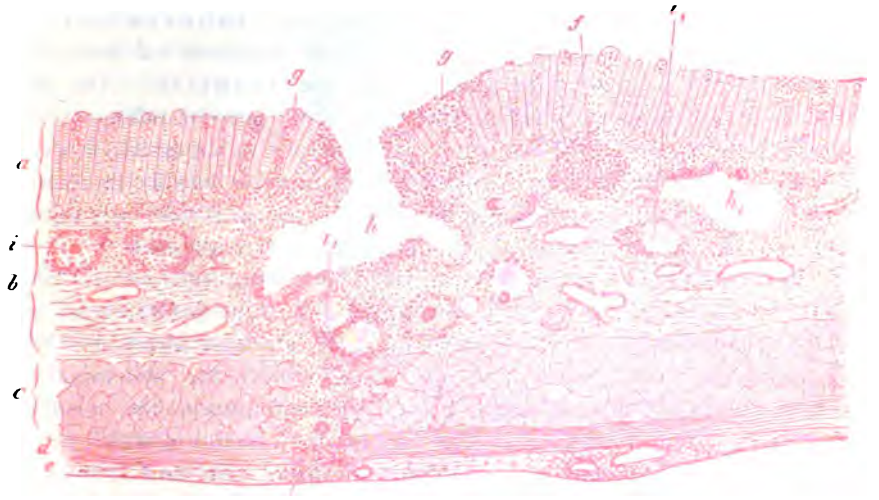

Fig. 230.—Tuberculosis of colon. *a*, mucosa; *b*, submucosa; *c*, muscularis interna; *d*, muscularis externa; *e*, serosa; *f*, solitary follicle; *g*, cellular infiltration of the mucosa; *h*, ulcer; h_1, submucous focus of softening; *i*, fresh, and, i_1, caseated, tubercle. × 30. (After *Ziegler*.)

may be totally destroyed, and with it the subserosa, the tubercle formation in the muscularis following the connective tissue provided with lymph-spaces and appearing as small, yellowish-white striæ. In this case partial adhesive peritonitis usually develops, which may result in complete adhesion of adjacent intestinal coils before the serosa is destroyed. Sometimes, however, perforation and fatal peritonitis occur as the result of rapid, even gangrenous, disintegration, including the layers of superficial exudate.

Perforation not infrequently occurs also after adhesion of adjacent intestinal coils. In this case, however, perforation does not produce fatal peritonitis, but communication with contiguous intestinal coils. Often a large number of these free communications are observed in an

individual. These severe forms of tuberculous intestinal ulceration involving the deeper structures are usually early associated with quite extensive and often general fibrinous peritonitis which finally causes adhesion of all the abdominal organs, sometimes develops insidiously, and is not, as a rule, the cause of death, in contradistinction to perforating peritonitis occurring suddenly, in which countless micro-organisms are simultaneously distributed over the whole peritoneum.

In chronic adhesive peritonitis the relation of the peritoneal tubercles to the intestinal ulcers is readily recognizable by the local distribution of the tubercles.

In contrast to this there is a generalized tuberculosis of the peritoneum and omentum without evidence of inflammation, and also a general tuberculous peritonitis. The first form is observed as an accompaniment of acute general miliary tuberculosis, or independently of it, in which instance it is impossible in every case to say from what source infection with tubercle bacilli (dissemination) originated. In this condition the tubercles are, as a rule, very minute —*i.e.*, young—and present only slight evidence of retrogression.

Tuberculous fibrinous peritonitis (*peritonitis tuberculosa fibrinosa*), which is characterized by the diffuse occurrence of tubercles and not by local eruption in the neighborhood of intestinal ulcers, is either the result of other tuberculous affections within the abdominal or thoracic cavity, or it develops as an independent disease, the portal of entry being unrecognizable. In this process the omentum, which in the normal state is freely movable over the intestinal coils and follows all movements of the intestine, is always and often first and most intensely involved: *omentitis tuberculosa chronica.* It gradually becomes shorter and thicker, being from time to time (with movements of the intestine, *i.e.*, passively) thrown into folds which, owing to the adhesive, fibrinous exudate, stick together and form adhesions. As this process often recurs, marked shortening and thickening occur, resulting in the formation of a dense, sausage-shaped band which usually lies above the transverse colon. The sequelæ of this tuberculous peritonitis, as regards the peritoneum itself, vary greatly according to whether at the same time fluid is exuded into the abdominal cavity or not. If no fluid is exuded (*peritonitis tuberculosa fibrinosa*), agglutination and organized adhesion of contiguous surfaces rapidly occur, so that the abdominal cavity as such disappears within a short time: *obliteratio cavi abdominis.* On the other hand, if fluid is present in the abdomen (*peritonitis tuberculosa hydrofibrinosa*), various consequences may occur. First, agglutination and organized adhesion of certain parts of the peritoneum may occur in spite of the presence of fluid, especially when the latter is not

very abundant, so that progressive diminution of the abdominal space finally results; second, the adhesions are very few in number, and now begins at those places which are nonadherent or nonorganized, but are covered with fibrin, a slowly progressive substitution of the fibrin by connective tissue, which, like all pathologic new-formed connective tissue, gradually undergoes cicatricial contraction. In this manner shrinking of the abdominal organs occurs, which is most marked where the resistance is least: that is, in addition to the omentum, already described, particularly the intestine and radix mesenterii. The consequence of this is that upon the strongly cicatricially contracted, very hard radix lies a very compact convolution of very narrow, firm, strongly kinked, usually somewhat slaty-

Fig. 231.—Secondary tuberculous lymphangitis in the external surface of the intestine after tuberculous ulceration of the mucous membrane. *l*, lymphatic vessel with closely arranged tubercles. At * chronic thickening of the peritoneum at the points over the ulcers of the mucous membrane. (After *Langerhans*.)

gray colored intestinal loops which, on attempt to move or loosen, tears everywhere, especially in the region of the strongly thickened serosa up to the muscularis.

The reason why in one case there is abundant exudation of watery fluid (ascites) and in the other case none is to be found, in part at least, in the state of the omentum (partly also in disturbances in the portal circulation). The exudation of watery fluid occurs principally from the omentum. Hence, in early obliteration of the omentum the exudation of watery fluid sometimes ceases.

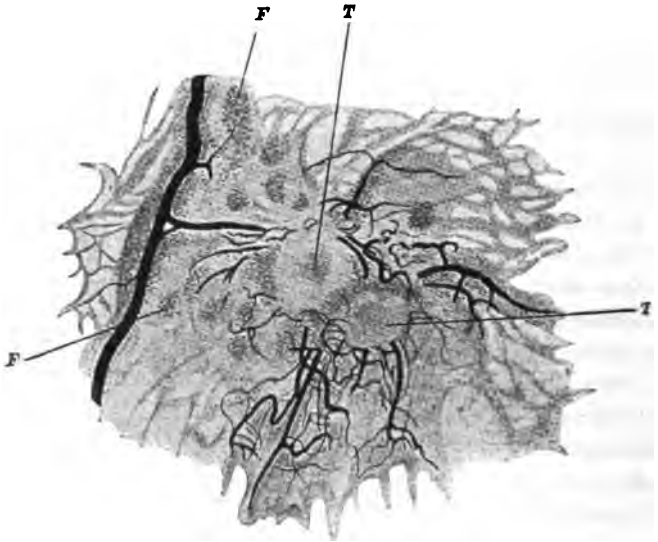

Fig. 232.—Two tubercles in an atrophic omentum. *T*, tubercle; *F*, atrophic fat lobuli. (Leitz Obj., 1; Ocul., 2. Reduced ⅓. After *Langerhans*.)

Tuberculous peritonitis, unlike purulent peritonitis, is not the direct cause of death. As a rule, death occurs only after a protracted period as a result of general debility. Hence, these are usually chronic processes, which do not progress by one attack (*uno actu*), but by recidives, often recurring a number of times. With each recidive, in connection with new eruption of tubercles, fibrin is exuded which, like the fibrin first exuded, becomes organized. By increase of these organized masses of exudate, progressive thickening and cicatricial contraction of the peritoneum result. The tubercles do not disintegrate, but undergo gradual retrogression. Hence, tubercles of various size can often be seen side by side—very young, gray, translucent, and centrally caseated, with whitish or whitish-yellow center, when fatty metamorphosis predominates, and smaller, more whitish fibrous foci. The caseous masses

are probably carried off during retrogression and absorption, principally by the giant cells which are here very numerous, and partly also the fatty material, for the giant cells are often almost entirely filled with fat. Finally, in pronouncedly chronic cases only the fibrous metamorphosed parts of the tubercles remain.

The changes of the **pericardium** and **pleura** in tuberculosis (*tubercula pericardii, tubercula pleurarum*) and in tuberculous inflammation (*pericarditis tuberculosa fibrinosa* and *pleuritis tuberculosa fibrinosa*) so closely resemble the changes described in connection with the peritoneum that the latter may be referred to for the general features. It may, however, be remarked that, as the omentum cannot co-operate with these surfaces, partial adhesion or obliteration usually occurs quite early, especially in the pericardium. In other respects recurrences with new eruption of tubercles,

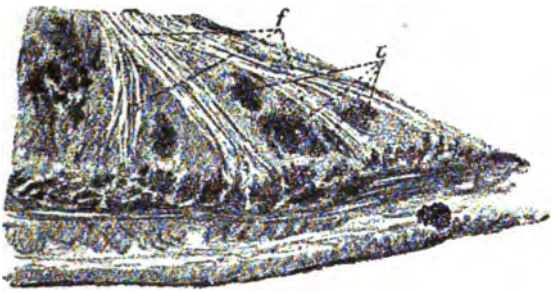

Fig. 233.—Chronic tuberculous pericarditis. *t*, tubercles, caseated at the center; *f*, fibrous bands, enlarged 8 times. (After *Langerhans*.)

formation of new exudates, and metamorphosis or retrogression of the older layers of exudate occur in similar manner also in these serous membranes.

It has already been stated (see p. 445) that, in addition to tuberculous inflammation of serous membranes, there also is a tuberculosis of serous membranes without inflammatory phenomena. Chronic tuberculosis of serous membranes, however, never occurs w i t h o u t inflammation. Hence, in tuberculous inflammation there must be a definite connection between inflammation and tubercles; at all events, inflammation is absent only in fresh eruption of tubercles. In chronic tuberculosis, however, especially on occurrence of retrogressive metamorphosis, inflammation begins in the immediate neighborhood. This can be observed also in the lungs and kidneys. Hence, there is no simple c h r o n i c tuberculosis w i t h o u t inflammation.

There are, however, cases in which tuberculosis undoubtedly follows pre-existing alterations of serous membranes. In these cases, which are not rare, but are often difficult to interpret, the inflammatory or

subsided affection of the serous membranes is primary and the eruption of tubercles secondary: *tubercula adhesionum.* There are cases, for example, in which death occurs as a result of tuberculous arachnitis, although no trace of older tuberculosis can be found anywhere. When these persons have previously suffered from a single attack or recurrent attacks of inflammation of serous membranes, *e.g.,* a perityphlitis or a unilateral pleuritis, tubercles are found, in addition to those present in the arachnoid, only in those localities where remains of the subsided

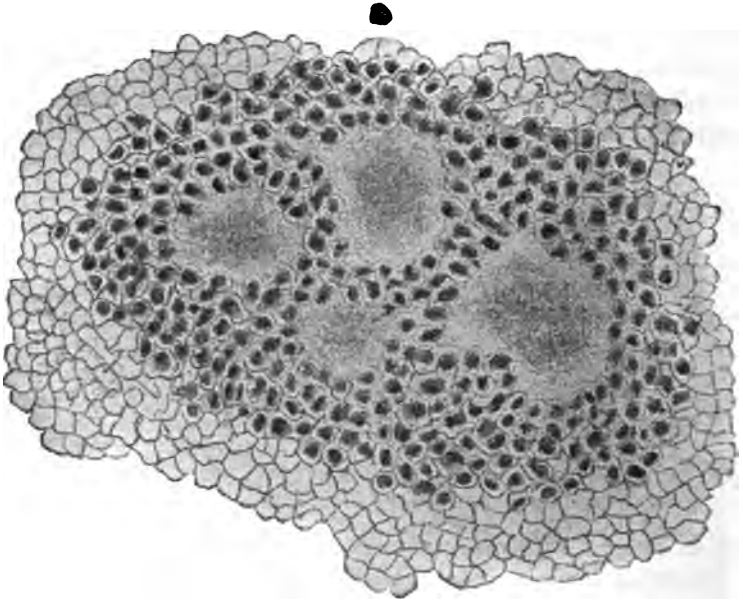

Fig. 234.—Fibrinous hepatization in the vicinity of four tubercles in very slight tuberculosis (very small numbers of tubercles in the lungs). Fresh section. (Zeiss Apochr., 16; Comp. Ocul., 4. After *Langerhans.*)

inflammation still persist, *i.e.,* within the old adhesions. This shows, first, that cryptogenetic tuberculous arachnitis may be hematogenous in origin, and, second, that tubercle bacilli by preference settle in localities where some form of nutritive or circulatory disturbances has already developed as the result of older processes. These cases, however, also permit the conclusion that the tubercle bacilli circulating in the blood must have been present everywhere, but that tubercles developed only at those points where a greater disposition on the part of the tissues (arachnoid) existed or had been produced by old disturbances (adhesions).

Tuberculosis of the arachnoid always progresses under the form

of tuberculous arachnitis.[1] Here, also, it cannot be denied that the primary eruption of tubercles occurs perhaps without inflammatory phenomena, since the first clinic manifestations do not appear until about the end of the third week (seldom earlier) after injection of tuberculous material into the vessels; the lodgment of the bacilli and the first reactive phenomena on the part of the tissues, however, must have occurred long before in the interval. There is no doubt, however, that inflammatory changes are always demonstrable at necropsy. These consist in exudation of watery-fibrinous or fibrinopurulent masses in the tissue meshes of the arachnoid (not upon the free surface). Tuberculous arachnitis is often an accompaniment of a general acute

Fig. 235.—Section from lung, Fig. 227. *t*, tubercles.

miliary tuberculosis, but it occurs also without this condition in connection with acute or chronic phthisic and tuberculous processes of other organs, or, as has already been shown in tuberculosis of serous membranes, it develops apparently independently of other tuberculous processes as a primary disease (cryptogenetic). In these cases also it must be assumed that a focus existed somewhere in the body whence the tubercle bacilli became mobile and entered the blood circulation, even though the focus cannot be demonstrated in every case—as is frequently rendered difficult at the necropsy from consideration for the relatives.

[1] Contrary to general opinion, tuberculous meningitis is not rare under two years of age. Lafarcinade (*Med. Press and Circ.*, April 19, 1911, p. 414) has collected over 40 cases in infants under this age. Cases of this nature in suckling infants are usually classed as eclamptic or hemiplegic. In the latter form more or less complete hemiplegia develops, followed by localized or general convulsions, stiffness of the neck, bulging of the fontanelles, exaggerated reflexes, and finally coma. In the somnolent form progressive emaciation, instability, and irregularity of the pulse; often vomiting and diarrhea, which may lead to an erroneous diagnosis of gastroenteritis; ocular catalepsy, and progressive somnolence culminating in deep coma are observed. The disease is always fatal and generally terminates in eight to ten days.

Tuberculous arachnitis involves the whole arachnoid. Certain localities are more involved than others, however, in so far as the tubercles are first and easiest recognized there. These localities are the base of the brain, and especially the region of the optic chiasm and olfactory nerves. Tubercles in the Sylvian fissure, although they are often very numerous in this locality, are less distinctly recognizable, because preparations must usually first be made, and confusion with other conditions may thus readily occur. On the other hand, tubercles in the region of the great longitudinal fissure and upon those surfaces of the cerebrum and cerebellum which are in contact with the tentorium may easily be recognized.

The smaller the number of tubercles present in the arachnoid, the more difficult is the recognition of the inflammatory (infiltrating) exudate. The smaller the tubercles, the more watery-fibrinous is the exudate; the more numerous, larger, and more cloudy (older) the tubercles, the more abundant and fibrinopurulent is the exudate. Hence, here also the dependence of the exudate upon the development of tubercles becomes distinctly manifest.

In all cases in which this affection is strongly manifest, tubercles can be recognized also in the tela chorioides: tuberculous choroiditis (*chorioiditis tuberculosa*). Here also are to be found the same gradations as in the arachnoid: a few small and numerous larger nodules with distinctly cloudy center. In the first case the ventricle fluid is always decidedly increased: acute internal hydrocephalus (*hydrocephalus acutus internus*), but not yet cloudy; in the second case the hydrocephalus is more intense and the fluid distinctly clouded, rich in round cells: acute purulent internal hydrocephalus (*hydrocephalus acutus internus purulentus*).

Tuberculous encephalomeningitis (*encephalomeningitis tuberculosa*) follows the pure form of tuberculous arachnitis. In this process the brain substance is always involved, as the name indicates. Here the process is characterized by the occurrence of somewhat large, old, and often confluent caseous foci situated partly in the arachnoid, partly in the gray cortical substance, but sometimes, however, they extend also into the white medullary substance. In contradistinction to general tuberculous arachnitis, this change always occurs in focal form, *i.e.*, locally circumscribed; there may be only one focus or several foci. The question which part was first involved—whether the brain or meninges—cannot be determined in every case. In those cases, however, in which large, coherent, caseous masses are present in the brain, it is probable that the tuberculosis of the brain was primary, and that

the arachnoid was secondarily involved in the progressive enlargement of the caseous masses. This process is usually accompanied by circumscribed but very violent inflammatory phenomena and innumerable small, punctiform hemorrhages (*encephalomeningitis tuberculosa hæmorrhagica*), so that partial red softening of the brain sometimes results. The old caseous focus then forms the center; in the periphery are seen the punctiform hemorrhages, which are sometimes scanty, sometimes numerous, and in the arachnoid itself, besides uniform, yellowish clouding (exudate), more or less numerous and often very large tubercles. These are frequently the largest forms of tubercle observed in the arachnoid.

Only large, conglomerate tubercles, so-called solitary tubercles, which greatly resemble caseated scrofulous glands, occur in the

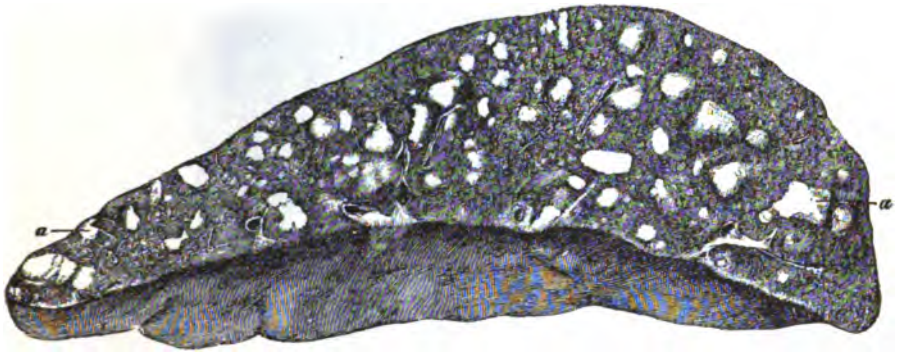

Fig. 236.—Chronic tuberculosis (tuberculous splenomegaly) with formation of large caseous nodules, *a*, in a child. Natural size. (After *Ziegler.*)

brain. These solitary tubercles originate from small beginnings—individual tubercles—gradually develop into larger and continually increasing nodules by apposition of new tubercles, a soft, gray or grayish-red granulation layer developing in the periphery, from which new caseous nodules constantly develop and coalesce with the large, older caseous focus. This apparently simple solitary tubercle, therefore, is composed of a large number of small, submiliary tubercles. The larger nodules contain not only caseous material, but also fibrous tissue, and are, therefore, hard. Sometimes the above-described tuberculous encephalomeningitis follows or develops synchronously with these nodules. Solitary tubercles are quite often multiple, especially in children, and sometimes are very numerous; they may attain the size of a walnut or larger. They often are an accidental finding at necropsy, *i.e.*, they may develop quite latent, even in vital parts, *e.g.*, in the pons.

Tuberculosis of the lymph-glands almost always progresses in the form of inflammation: tuberculous lymphadenitis. The gland is swollen, soft, moist, reddish, or reddish gray. The tubercles may be so closely arranged as to partly coalesce. In chronic cases the glands may gradually become firmer as the result of formation of connective tissue, and the tubercles often show the same retrogressive changes as the tubercles in chronic tuberculous peritonitis.

Harbitz, Weichselbaum, and Bartel have recently shown that the tubercle bacillus not infrequently may cause an increase in the lymphocytes in the lymph-glands—*i.e.*, a lymphatic hyperplasia—and that in experiment animals tubercle bacilli can be demonstrated in such lymph-glands. They designate this latent tuberculosis as *lymphoid* tuberculosis, and assert that from this source tuberculosis may subsequently develop in other localities.

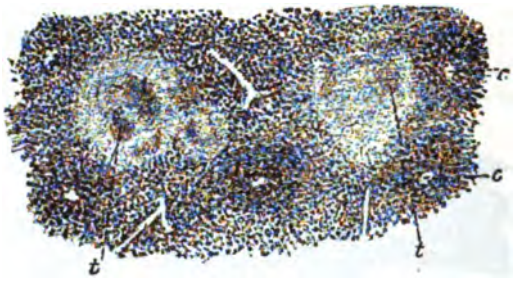

Fig. 237.—Two small tubercles of the liver. The darker areas, *t*, correspond to giant cells filled with fat. Fatty infiltration in the center of the acini. (Zeiss Obj., 2; Ocul., 6. After *Langerhans.*)

The **spleen** belongs to the predilection organs of secondary tuberculosis. The true seat of tubercles is the pulp. The latter contains either innumerable very small tubercles, especially in acute miliary tuberculosis, or only solitary but large conglomerate, hemp-seed or pea-sized, rarer larger, caseous nodules; the rest of the spleen tissue is always hyperplastic.

Tubercles of the liver (Figs. 237 and 238) are nearly always secondary, and are almost always present in intestinal tuberculosis and in general miliary tuberculosis. They are characterized by their minuteness (are usually microscopic) and by their slight disposition to retrogression, particularly caseous metamorphosis. **Tubercles of the bile-ducts** are an exception to this. They are larger, usually bile-stained, but very much less numerous than the true liver tubercles. These may occur in all parts of the acini, though they are located chiefly in the peripheral zone, seldomer in the middle, and seldomest in the central zone. Sometimes almost all tubercles of a liver contain giant cells (Fig. 238); sometimes

only isolated tubercles contain them. Occasionally the tubercles are so closely arranged that they coalesce and form large nodules: so-called conglomerate tubercles. These may vary in size, but rarely attain the size of a walnut. Solitary tubercle of the liver and gall-bladder is very rare.[1]

In scrofulous subjects ulcerative tuberculosis of the **middle ear** (*otitis media tuberculosa*) is probably the cause of the frequent otorrhea, the perforation of the tympanum, and carious destruction of the petrous bone.

In the **kidney** two forms of tuberculosis must be differ-

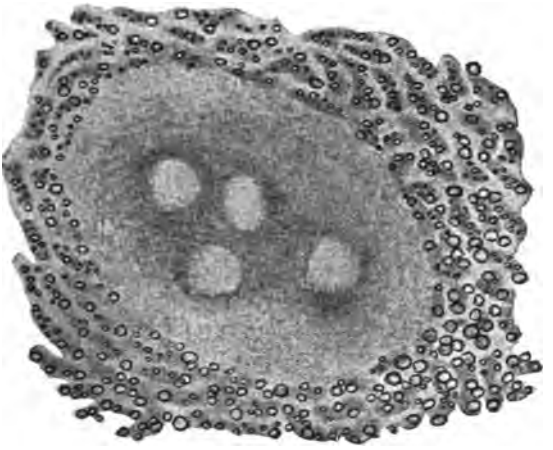

Fig. 238.—Liver tubercle with four giant cells in the peripheral zone of an acinus with peripheral fatty infiltration. Fresh section. (Zeiss Apochr., 16; Comp. Ocul., 8. After *Langerhans*.)

entiated, namely, *nephrophthisis tuberculosa ulcerosa* and miliary tuberculosis. The latter is always observed in acute general miliary tuberculosis; it frequently occurs also in connection with other tuberculous processes, and occasionally constitutes the so-called tuberculous infarcts which are caused by dense eruption of tubercles in a wedge-shaped cortical area. All these tubercles, which may be particularly abundant in the cortex, where they generally have an almost round form—in the medulla, on the contrary, elongated, linear-shaped (corresponding to the course of the vessels and straight urinary tubuli) —are always due to inoculation with tubercle bacilli through the blood-channels, *i.e.*, always a secondary (metastatic) phenomenon. The tubercle bacilli entering the kidney with the blood are taken up by the capil-

[1] Pester Med. Chir. Presse, 1911, No. 25, p. 197.

laries of the cortex, medulla, and especially the glomeruli, where they are retained or pass the glomeruli, enter the urine, and thus reach the medulla: excretion tuberculosis.

On the other hand, **nephrophthisis** (Figs. 239 and 240) is a pronouncedly chronic tuberculosis which slowly ascends from the collecting tubules of the medullary pyramids toward the cortical substance. Very

Fig. 239.—Tuberculosis of the left kidney. Longitudinal section. *a*, smaller; *b*, larger caseous nodules; *c*, softened caseous focus; *d*, softened caseous focus communicating with the renal pelvis, *e*. (¼ natural size. After *Ziegler*.)

dense eruptions and coalescence of tubercles produce what frequently is called tubercular infiltration. Caseation and disintegration of such an area result in the formation of a more or less large ulceration in the renal calyx, and new, closely arranged groups of tubercles develop in the adjacent higher area of the kidney (in a direction toward the cortex). In this manner new formation and disintegration finally advance to the surface of the cortex, where further invasion is

temporarily arrested by inflammatory thickening of the capsule. Finally, however, in some cases the capsule also is involved. This change may involve one, several, or all the medullary pyramids, and occurs sometimes in one, sometimes in both kidneys. It develops either in connection with tuberculosis of other organs (especially of the lungs), virulent bacilli entering the kidney with the blood-stream and lodging there (hematogenous), or rarely as the result of an ascending inflammation which may originate in the prostate and seminal vesicles, and extend upward through the bladder, ureters, renal pelvis, and calices.[1] In this ascending and in the descending form the renal calices and pelvis, ureter, and urinary bladder may be affected in the same manner.

Fig. 240.—Chronic ascending ulcerative caseous tuberculous nephrophthisis and chronic ureteritis tuberculosa caseosa gravis. (⅔ natural size. After *Langerhans*).

In tuberculosis of the vertebræ the kidney may be involved by continuity; on the other hand, tuberculous processes of the kidney have been known to ulcerate into the duodenum. Mixed infection (*Bacillus coli,* staphylococci, and streptococci) may cause extensive destruction. Acute general tuberculosis may develop from renal tuberculosis by way of the renal vein.

The character of the urine varies according to the degree of involvement of the urinary tract. While in the initial stage of renal tuberculosis the urine may be clear, according to J. Israel blood is present in 25 per cent. of the cases. In extensive involvement the urine may contain an abundance of pus, necrotic detritus, and occasionally blood. Tubercle bacilli are not constantly present; often, however, they are so numerous that they are grouped in

[1] Some authorities claim that an ascending form of tuberculosis never occurs. The experiments of Bauereisen (*Zeitsch. f. Gynäk. Urol.*, Bd. 2, H. 3, 1910) seem to support Baumgarten's descendance theory of urogenital tuberculosis. Intraureteral ascending renal tuberculosis probably does not occur in uninterrupted flow of urine. In marked tuberculosis of the bladder an ascending infection of one or both ureters, which finally may extend to the kidney, may occur by way of the lymphatics. Jores (*Wien. klin. Woch.*, No. 44, 1910) says ascending tuberculosis occurs. Primary tuberculosis of the kidney probably does not occur.

S-formed, serpentine masses or in tufts which, in stained preparations, may be visible to the naked eye. This peculiar grouping of the bacilli is an important feature in differentiation from smegma bacilli, which in some instances may be mistaken for tubercle bacilli. (See Fig. 241.)

If genital tuberculosis (seminal vesicles, prostate, epididymis, uterus, Fallopian tubes) coexists, the process is designated as **urogenital tuberculosis,** which may be primary or secondary to tuberculous alterations of other organs, and is more frequent in males than in females.

Tuberculosis of the bladder and ureters[1] occurs most frequently in males, chiefly as a concomitant of urogenital tuberculosis (usually of the kidney and renal pelvis), but sometimes without genital tuberculosis in connection with tuberculosis of other organs, *e.g.,* of the lungs. The seat of predilection in tuberculosis of the bladder is at the opening

Fig. 241.—Impression preparation from a culture of tubercle bacillus. (After *von Jaksch.*)

of the ureter. (See Fig. 242.) In this condition either isolated ulcers occur, in the base and periphery of which new nodules sometimes develop, or the tuberculous process extends backward from the colliculus seminalis, in connection with seminal and prostatic tuberculosis, also descending from the kidney to the bladder, causing extensive destruction of the mucous membrane of the bladder and ureters. The ulcers enlarge by progressive disintegration at the periphery and by coalescence of contiguous ulcers. The tuberculous process is usually arrested at the muscularis, this structure rarely being involved. In the severe forms the ulcerated surface of the urinary bladder is often incrusted with salts, especially triple phosphate. A quite active mucous or mucopurulent catarrh is always present. In the severe forms of the process the ureters are usually considerably thickened.

Tuberculosis of the prostate is most frequently secondary to tuberculosis of adjacent parts of the urogenital apparatus,[2] but it occurs also

[1] Tuberculosis of the ureters is probably always the result of extension from the renal pelvis or bladder.

[2] Von Baumgarten and Kraemer found that tuberculosis of the bladder or urethra in guinea-pigs might lead to disease of the prostate, but not of the vas deferens, testes, ureters, or kidneys.

as a primary affection, often beginning in the center of the organ. The occurrence of disseminated nodules and large caseous foci must be differentiated. The former are observed principally as an accompaniment of acute general miliary tuberculosis, while caseous tuberculous prostatitis (*prostatitis tuberculosa caseosa*) occurs essentially as a concomitant of urogenital tuberculosis. These usually large foci manifest a marked tendency to undergo purulent softening, so that, finally, a caseous abscess: *prostatitis tuberculosa caseosa ulcerosa purulenta,* develops which finally ruptures either into the prostatic urethra, the bladder, or the rectum, and sometimes in the form of multiple fistulæ. The urethra may be involved throughout. In addition to tuberculosis of the prostate, tuberculosis of the seminal vesicles and epididymis are usually present.

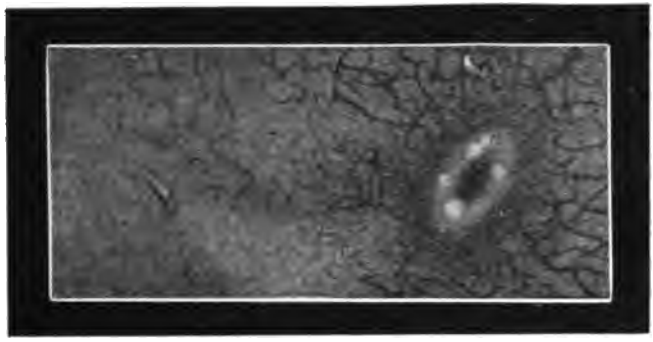

Fig. 242.—Cystoscopic view of base of bladder in a case of tuberculosis of the left kidney. (After *Wyatt.*)

Tuberculosis of the seminal vesicles (*spermatocystitis tuberculosa*) is an accompaniment of urogenital tuberculosis. It may be primary or secondary to tuberculosis of other organs. As a rule, at least one epididymis also is affected. The condition is always a chronic process in which the seminal vesicles undergo considerable thickening. On incision the lumen is found completely filled with caseous masses which extend almost to the external surface; sometimes the caseous masses are very dry; sometimes in a state of purulent liquefaction. Both seminal vesicles are almost always affected, though often to an unequal degree.

Of the **testes** and **epididymis,** the latter is more frequently affected with tuberculosis: *epididymitis tuberculosa caseosa.* The process occurs in childhood as well as in later years, and usually starts in the wall of the vas deferens. In the epididymis large caseous foci develop accompanied by very considerable swelling. This change also is gen-

erally an accompaniment of an extensive urogenital tuberculosis, in the absence of which it is seldom observed. In the vas deferens and in the tubuli of the epididymis, the caseous masses, as is always the case in tuberculosis of narrow canals, remain *in loco* and occlude the lumen; later, the caseated tubuli in the epididymis coalesce to a coherent, cheesy mass. The testis at first remains passive. After prolonged duration and extensive caseation of the epididymis, however, submiliary nodules—

Fig 243.

Fig 244.

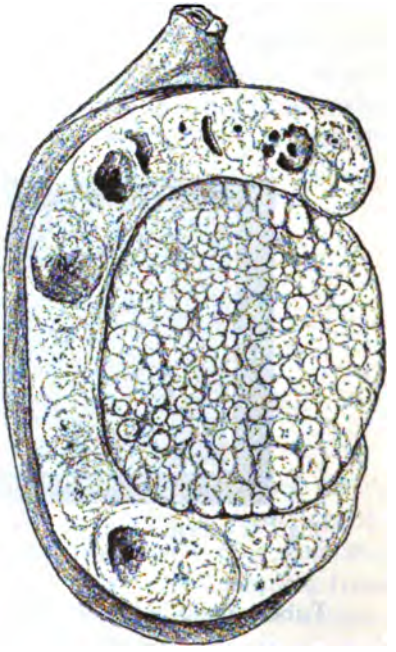

Fig. 243.—Caseous cavernous tuberculosis of the epididymis.

Fig. 244.—Rare form of tuberculosis of the epididymis and testis. (After *Kaufmann.*)

tubercula testis—become visible also in the testes, first in the rete testis. When the caseous masses in the epididymis soften, they may break externally through the skin of the scrotum and thus produce so-called seminal fistulæ, through which, after a time, fungous granulations grow forth as *fungus benignus.* The testis may gradually atrophy: *atrophia testis.* Primary tuberculosis of the testis is sometimes observed in small boys, rarely in adults.

Tubercle bacilli have been found in the seminal tubules and seminal vesicles of tuberculous subjects, and tuberculous epididymitis has experimentally been produced in rabbits by crushing the testes after injection of tuberculous sputum into the abdominal cavity. Tuberculosis of the testis has been produced by injection of tubercle bacilli into the vas deferens.

In the **female genital apparatus** the Fallopian tubes and uterus are most frequently affected, rarely the vagina, vulva, and, in extremely rare cases, the ovaries.

In its course tuberculosis of the Fallopian tubes, *salpingitis tuberculosa,* possesses a certain resemblance to tuberculosis of the vas deferens and seminal tubules; it is not, however, an accompaniment of an extensive primary or secondary urogenital tuberculosis, but occurs without tuberculosis of the urinary passages. It is usually secondary to pulmonary or peritoneal tuberculosis, rarely an independent, primary affection. Here also are observed the same changes as are always seen in tuberculosis of narrow canals lined with mucous membrane (analogous to the small bronchi); tubercles develop in the mucous membrane and caseate and disintegrate; new eruptions of tubercles, which undergo the same changes, take place in the base of the ulcers; the lumen becomes completely occluded, and at the same time a portion of the tube or the whole tube is distended. In many cases large sacs entirely filled with caseous material develop and give rise to extensive adhesions to the neighboring parts. Sometimes purulent softening occurs. The abdominal as well as the uterine ostium is usually soon occluded. If occlusion of the ostia does not occur, the process may extend to the peritoneum and uterus. In the latter case tuberculosis of the endometrium of the body of the uterus: tuberculous endometritis, occurs secondarily to the tubal affection. This is the usual course. While the tuberculosis may be primary in the uterus and secondarily involve the tubes, this is not the rule, but the exception. In the uterus either small tuberculous ulcers or very severe caseous ulceration extending over almost all the mucous membrane are observed. In this case the tubercles are often so closely arranged that the individual nodules cannot be differentiated with the naked eye.

In addition disseminated, nondisintegrated nodules are sometimes found in the uterus as well as in the tubes, in which the chronic affection is generally bilateral.

In **tuberculosis of the mammary gland** an intracanalicular granulation tissue is produced which gradually causes narrowing and obliteration of the lumina of the excretory ducts: obliterating tuberculous mastitis. The granulation tissue usually is limited to the immediate neighborhood of the lobuli and excretory ducts. The epithelium is comparatively resistant, manifests slight tendency to proliferation, and rarely if ever forms giant cells. It is found as cell-detritus mixed with lymphocytes, granulation cells, and fibrin in the lumina of the ducts, and an adhesion of the surfaces deprived of epithelium occurs. Finally, large areas of the glandular tissue of the mamma are transformed into tuber-

culous granulation tissue with a tendency to necrosis, the former structure being recognizable only by special staining for elastin.

Tuberculosis of the **salivary glands,** including the **pancreas,** is repeatedly observed, most frequently in acute miliary tuberculosis. As a rule, it is scarcely or not at all visible to the naked eye. In small children extensive caseation and even softening of the caseous masses are said to have occurred in a few cases.

Tuberculosis of the thyroid gland has thus far been observed only in the form of disseminated, submiliary nodules as an accompaniment of other tuberculous processes.

In **tuberculosis** of the **voluntary skeletal musculature:** *myositis tuberculosa,* the process is essentially a tuberculosis of the connective tissue of the musculature. The latter is only passively involved, in that it dies by retrogressive metamorphosis. It generally occurs as the result of extension from local alterations of adjacent organs, especially of bones and joints (*e.g.,* in gravitation or burrowing abscess), and sometimes of the mucous membranes (*e.g.,* of the tongue). The striated musculature, therefore, behaves in tuberculosis similar to the smooth musculature, which also is essentially passive. As a metastatic affection muscle tuberculosis has only very rarely been observed in connection with other tuberculous processes, especially of the lungs.

Tuberculosis of the tendon sheaths is rarely an independent affection, and as such is most frequently observed in the forearm. On the other hand, tuberculosis of the tendon sheaths in connection with fungous articular inflammations is a quite frequent affection, which essentially progresses under the form of fungous or fungous-purulent inflammation: *tendovaginitis tuberculosa fungosa sive tuberculosa purulenta.*

The fascias behave like the tendon-sheaths.

The synovial bursæ also may be secondarily involved as a result of extension of a tuberculous affection of neighboring tissues, especially of the joints: *bursitis tuberculosa.*

In the nerves also tuberculosis is observed only as the result of extension of tuberculous processes from neighboring parts to the connective-tissue sheaths—the perineurium and neurilemma.

Tuberculosis of the suprarenal capsules is a quite frequent affection which is often observed[1] in *morbus addisonii* (bronzed-skin disease, *melasma suprarenale,* suprarenal capsular disease, suprarenal cachexia, **Addison's disease),** and is, therefore, said to be the etiologic factor in this affection. As, however, Addison's disease

[1] According to Lewin, in 74 per cent.

occurs also independently of tuberculosis of the suprarenals and, *vice versâ,* tuberculosis of the suprarenals without Addison's disease, the relation has not as yet been sufficiently elucidated. As a rule, the process is characterized by the formation of large, thick, caseous nodules in the suprarenals which manifest no disposition to disintegrate. Disseminated miliary tuberculosis of the suprarenals is much rarer than caseation of larger areas. Occasionally the whole organ may be transformed into a dense, cretaceous mass, or into a cavity containing a creamy fluid.

Tuberculosis of the bones begins in the medullary portion of the spongiosa and usually progresses as *osteomyelitis tuberculosa,* rarer as simple tuberculosis. Points of predilection are the articular surfaces of the long tubular bones and of the vertebræ; in children, sometimes the bones of the skull. In tuberculous osteomyelitis each tubercle is surrounded by a red inflammatory zone. As a result of this the yellow fatty marrow is transformed into red, inflammatory, lymphoid bone-marrow. The primarily small, light-gray tubercles grow larger, caseate, coalesce, and, finally, fill the small medullary spaces of the spongiosa. With this is always associated an inflammatory irritation of the periosteum which, in the tubular bones, leads to deposition of new osseous lamellæ, *i.e.,* to swelling of the bone, and in the vertebræ sometimes results in purulent periostitis. The latter, in the caseous as well as in the purulent form, may give rise to prevertebral abscess, the so-called congestion, or gravitation, abscess (psoitis). With further advance of the process the compact bone substance in the interior of the bone is transformed either into a soft tissue infiltrated with tubercles: tuberculous ostitis, or, what is more frequent, the osseous trabeculæ—the bone tissue inclosed by caseous material—die, just as the lung tissue dies in caseous hepatization. In the vertebræ the osseous trabeculæ are destroyed and

Fig. 245.—Pott's disease. Kyphosis of dorsal vertebræ, the result of caseous tuberculous periostitis and osteomyelitis. Destruction of three thoracic vertebræ. Two-thirds natural size. (After *Langerhans.*)

disappear by *carionecrosis interna.* In the neighborhood of the necrotic masses a reactive inflammation develops which, in small and more centrally located parts, results in a dense connective-tissue capsule; in larger and more superficially located foci, on the other hand, an active suppuration develops which generally breaks externally, either into the joint or through the external skin. In the first instance *arthrocace* develops; in the second a fistula is produced through which all caseous and necrotic parts may be discharged, so that, finally, vesicular cavities (*spina ventosa*) develop. The common termination of vertebral tuberculosis is kyphosis. (See Fig. 245.)

Tuberculosis of the joints is either a primary affection manifesting a great tendency to involve the contiguous bones, or secondary to tuberculous affection of the bone. In some cases in which tuberculous joint and bone affections coexist, it can scarcely be decided whether the joint or the bone was primarily affected. If the tuberculosis starts in the joint, the synovialis is always first affected: tuberculous synovitis. From this point the process extends to the ligaments, the joint capsule, cartilage, bone, and the adjacent soft parts. A characteristic feature of this joint tuberculosis is the formation of so-called fungous masses: *arthritis fungosa;* these are soft, fungoid, usually very moist, gray- or grayish- red masses which consist essentially of granulation tissue. Typic tubercles, usually in small numbers, are found in these masses, often as punctiform, small, cloudy spots. These masses are sometimes focally, sometimes diffusely, caseated and disintegrated: *arthritis fungosa caseosa.* As at the same time the cartilage is destroyed by fibrillation of the basement substance and new fungous masses develop, a picture often difficult to interpret is produced.

In many cases suppuration is frequently added to these fungous processes: *arthritis fungosa purulenta.* In this event extensive destruction of the ligaments and joint cartilage occurs, so that finally these may entirely disappear and the bone be denuded of cartilage. In connection with the simple fungous or caseous, as well as in the purulent, form, gravitation abscesses with rupture externally and subsequent formation of fistulous tracts occur; the latter are more or less long, and usually quite narrow channels lined with granulation tissue, which manifest little tendency to heal. New bone masses develop in the neighborhood as a result of stimulation of the periosteum, which may cause considerable swelling of the joint. In favorable cases the termination of the process is ankylosis. The position the bones then assume in relation to each other depends upon the extent of the antecedent destruction and the degree of the resulting cicatricial shortening in the neighborhood.

Tuberculous inflammations of the joints are chiefly affections of childhood and usually attack the larger joints. In many cases tuberculous affections of the skin, glands, mucous membranes, and seldom of the lungs, precede. Sometimes fungous arthritis is the first visible and demonstrable indication of a tuberculous affection. These cases often give relatively the best prognosis.

A genuine **tuberculosis of the skin,** in which typic tubercles are formed, is almost never observed, except at the margins of mucous membranes by extension of tuberculous ulcers of the mucous membranes to the skin. The process induced by tubercle bacilli is called

Fig. 246.—Spina ventosa. (*Sheffield.*)

lupus (wolf). Most forms of lupus begin with swelling due to proliferation in the cutis. In *lupus fibrosus* simple inflammatory thickenings develop; in *lupus granulans* or *cellulosus,* cellular proliferations in the form of granulation masses. Both forms result in the formation of nodules: *lupus tuberosus.* Later, the surface may become smooth: *lupus lævis;* sometimes it is soft and intensely reddened: *lupus hypertrophicus* or *tumidus.* Sometimes the swelling begins as small, red, quite flat spots: *lupus maculosus;* sometimes more in the form of papules: *lupus papulosus;* sometimes more as genuine nodules: *lupus tuberosus.* In the last instance the nodules remain separate and are quite large, even the size of a walnut. The surface is covered with small, desquamated epidermis scales: *lupus exfoliatus,* or is exceedingly thin, glistening, and very susceptible to injury.

The proliferative process begins in the surface of the cutis and generally extends in depth through the whole cutis, sometimes into the subcutaneous adipose tissue and even to the bones. On the other hand, it may advance to the mucous membrane of the nose and mouth, and there form nodules consisting of proliferated connective tissue.

In the skin flat ulcers develop which become covered with crusts, beneath which the process—the destruction of the granulation tissue—advances farther in depth, resulting in the formation of deep ulcera-

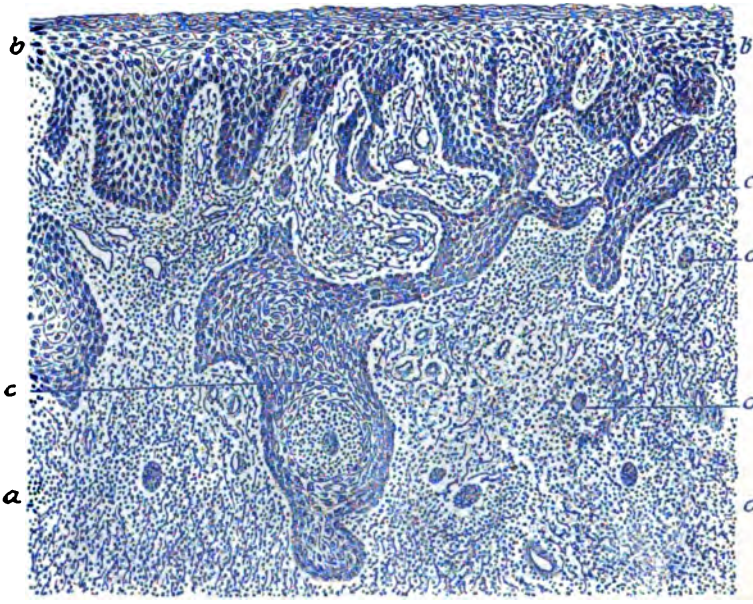

Fig. 247.—Lupus of the skin from region of the knee, showing atypic epithelial proliferation. *a*, corium converted into tuberculous granulation tissue; *b*, epidermis; *c*, epithelial papillæ; *d*, tubercles. × 50. (After *Ziegler*.)

tions: *lupus vorax, exedens.* Sometimes healing by cicatrization with retraction occurs: *lupus non exedens, esthiomene.* Usually, however, the process creeps farther: *lupus serpiginosus,* and, under partial strongly retractive cicatrization, results in terrible deformities, contractions, distortions, and disfigurements of the face, extremities, etc.

Lupus erythematosus most nearly approaches tubercle formation. Very small granulations which form bright-red, smooth, itching spots, but not nodules, and which, without ulceration by disintegration of the granulations, are transformed into whitish, scar-like thickenings, develop in the cutis.

The principal seat of lupus is the face, the region of the nose, cheeks, and forehead. Generally there is but one focus which spreads peripherally. The neighboring lymph-glands (submental and submaxillary) are usually swollen, but contain no tubercles. Lupus is always a local affection unaccompanied by general symptoms, and attacks preferably young females.

Actinomycosis.

The fungus of actinomycosis: *actinomyces* (*cladothrix*), first described in animals by Bollinger, in 1878, and subsequently studied in man by Israel, Ponfick, and especially by Boström, consists of a dense

Fig. 248.—Actinomyces hominis (lung). × 350. (*Lenhartz-Brooks.*)

network of fine, partly branching threads which, in man, cattle, horses, and swine, is surrounded by elongated, club-shaped, glistening bodies arranged in radiate manner (hence, ray-fungus). These large, refractive, clubbed forms have not been observed in pure cultures thus far obtained, but they reappear when actinomycosis is experimentally produced in animals by inoculation with the pure cultures. It is a very remarkable fact that the virulent pure cultures do not always consist of threads (*mycelium*), but only of short rods (bacilli). Recent investigations have shown that the fungi described by Israel and Boström, at first regarded as identic, are two different species. The Boström species (*Streptothrix actinomyces*) is essentially aërobic, forms a multiple branching reticulum, and is not transmissible to animals. The Wolf-Israel species is chiefly anaërobic and pathogenic for animals. Descriptions given by Bruns seem to indicate that there probably

are more than two species. Berestneff says there are forty different species which can be cultivated from straw.[1]

Actinomycosis, produced by the ray-fungus, is a quite frequent affection of cattle, which occasionally is transmitted to man. Cattle probably receive the fungus with their food (hay, beards of grain), for the maxillary bones (a myelogenous and periosteal form is distinguished) and tongue (wooden-tongue) are the most frequent seats of the disease. More or less dense, sarcomatoid tumors, in which small, yellowish granules, the size of a grain of sand, can readily be

Fig. 249.—Actinomyces drusen in sputum. × 350.

recognized with the naked eye, develop in these localities. These granules can easily be pressed out upon the cut surface of the growth, and are composed of actinomyces "rays." Within the body these ray-fungus granules are surrounded by round or so-called epithelioid cells and giant cells, and beyond these by dense fibrous connective tissue. Actinomyces tumors grow slowly, and in the jaw give rise partly to intense swelling, partly to complete disappearance of the bone, causing very marked deformities (lumpy-jaw). The process may occur also in the intestinal canal, lungs, liver, and other internal organs. In many cases amyloid degeneration is present.

In man, actinomyces infection assumes more the type of a

[1] Zeit. f. Hyg., xxix. 1898; Münch. med. Woch., 1899, p. 1256.

Fig. 5

Fig. 6

PLATE VI

Fig. 1.—Tubercle bacilli and Micrococcus tetragenus in sputum; Gabbet's stain. *a*, tubercle bacilli; *b*, Micrococcus tetragenus. × 750. (After *Lenhartz-Brooks.*)

Fig. 2.—Tubercle bacilli in spinal fluid of tuberculous meningitis; Gabbet's stain. Zeiss, IV; oil immersion, 1/12. × 500. The preparation contains large lymphocytes, mono- and polymorpho- nuclear leucocytes, and fibrin. (After *Lenhartz-Brooks.*)

Figs. 3 and 4.—Actinomyces from abscess pus. Both are section preparations from carefully hardened abscess pus. Fig. 3, mycelia stained with Weigert; nuclein stain with lithium carmine. Zeiss, II; Obj., DD. × 250. (After *Lenhartz.*) Fig. 4, mycelia stained with Weigert without nuclear stain. Zeiss, II; oil immersion, 1/12. × 400. (After *Lenhartz.*)

Fig. 5.—Anthrax bacilli, culture; Loeffler's stain. × 350. (After *Lenhartz-Brooks.*)

Fig. 6.—Glanders bacilli in pus; Loeffler's stain. Leitz, III; oil immersion, 1/12. (After *Lenhartz-Brooks.*)

PLATE VI

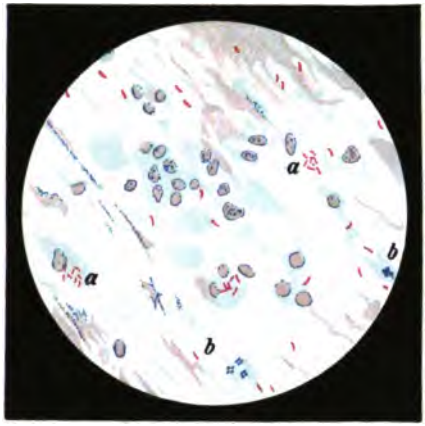

Fig. 1

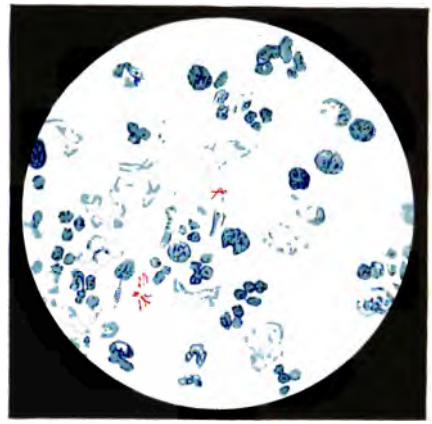

Fig. 2

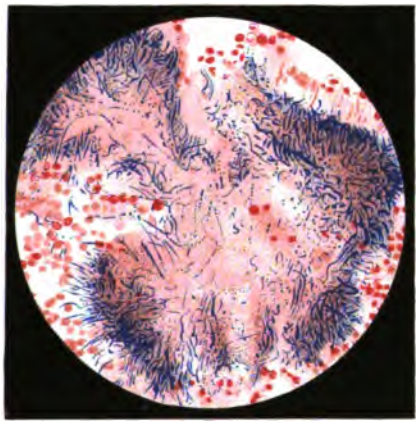

Fig. 3

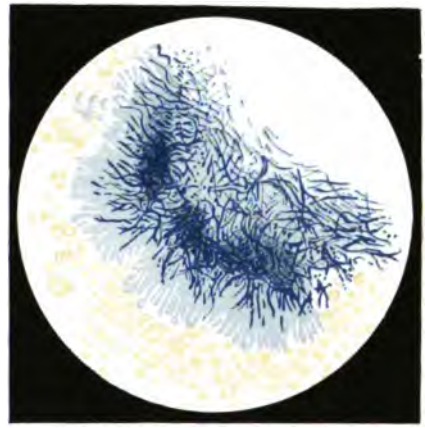

Fig. 4

Fig. 5



Fig. 6

suppuration. The process begins most frequently in the oral cavity from carious teeth, causing board-hard infiltration in the lower maxilla, in the region of the angle, and spreading peripherally in the form of purulent fistulæ and gravitation abscesses, *e.g.*, as prevertebral gravitation abscess. The disease may penetrate the bones at the base of the skull and cause actinomycotic meningitis and encephalitis. Not rarely the affection begins in the respiratory passages, producing fetid bronchitis, peribronchitis, and bronchopneumonic foci, as well as purulent and sometimes also serous pleuritis and peripleuritis, pericarditis, and mediastinal processes. From here the process usually attacks the thoracic wall; in some cases, however, the affection appears to start from the ribs. In other instances it occurs as a local cutaneous affec-

Fig. 250.—Same as Fig. 249; greater magnification. × 700.

tion, slight injuries of the skin forming the starting point of the disease, especially when foreign bodies, such as splinters of wood, barley beards, straw, etc., containing the fungi have penetrated the skin. Occasionally the process develops in the abdominal cavity, in which case ulceration and rupture into the intestine and appearance of actinomyces pus in the stools may occur. The disease may occur also primarily in the vulva, esophagus, stomach, or intestine (and appendix: *appendicitis actinomycotica*), and extend from there to the internal organs: liver, spleen, kidneys, ovaries, etc. General metastases, due to venous thrombosis and dislodgment of infected emboli, are rare.

The pus of actinomyces is characterized by the presence of small, yellow, sand-grain to poppy-seed sized granules, usually of caseous consistency, composed of fatty degenerated pus-cells and actinomyces "rays."

Madura foot, or **mycetoma,** an affection resembling actinomycosis and due to the *Streptothrix maduræ,* occurs in India, China, Egypt,

North and South America, etc. It frequently attacks the foot, which swells considerably. The process has its seat in the subcutaneous adipose tissue, in the musculature, and in the bone; develops slowly and appears in the form of granulation nodules which undergo purulent softening and abscess formation, resulting in a fetid state with fistulæ and induration. From the fistulæ is discharged offensive pus which contains brown to blackish, fish-roe or shot-like granules. The granules contain the pathogenic agent in the form of densely intertwined threads radiately arranged at the periphery; a club-shaped swelling at the extremities of the peripheral threads, as in actinomyces, is lacking. Histologicly, the granulation nodules simulate those of actinomycosis; in the periphery of the fungus is a deposit of ferruginous pigment.

Sporotrichosis.

Sporotrichosis is a subacute or chronic ulcerative, more commonly nodular, usually painless, afebrile affection caused by one or more species of sporotricha (*Sporotrichum schenkii, s. dori, s. de beurmani*). In most cases the skin and subcutaneous cellular tissues are affected, but the muscles, bones, and joints, the mucous membranes of the nose, fauces, tonsils, and larynx, and occasionally the conjunctivæ and epididymis may be involved. The malady was described first by Schenk,[1] and later fully worked out by De Beurmann and Gougerot.[2] While the process may begin insidiously and the point of entry of the fungus be undiscoverable, it generally originates in connection with trauma.

De Beurmann divides cutaneous sporotrichosis into three forms, as follows:—

1. With multiple disseminated subcutaneous gummatous foci;
2. With large multiple subcutaneous abscesses (Dor), and
3. Nodular gummatous sporotrichotic lymphangitis.

1. In the first form a few nodules appear upon various parts of the body, which may be palpated by the fingers, but cannot be perceived by the eye. Gradually they attain a diameter of from 2 to 3 cm., the larger ones assuming a red-violet or brownish-blue color, and fluctuating consistency. The number of nodules varies; there may be from twenty to thirty up to one hundred or more. At first they are limited to certain regions; soon, however, they spread over the entire body. Some of the nodules soften and burst; others remain soft without undergoing disintegration. The nodules pass through the various changes up to softening in from five to six weeks. Sometimes the skin over the nodules is destroyed. On bursting or after incision they evacuate a watery,

[1] Johns Hopkins Hosp. Bull., 1898, p. 286.
[2] Ann. d. derm., 1906; also The Post-Graduate, Sept., 1910, p. 925.

slightly viscid, sand-like, seropurulent, or serosanious fluid. The edges of the ulcers thus formed are flaccid and undermined; the base is discolored. The ulceration spreads evidently under the influence of inoculation of the edges by the sporotricha. Sometimes fistulous passages develop. The lymph-glands may or may not be enlarged, rarely become painful, and do not ulcerate.

2. The second form has thus far been observed only by Dor,[1] and is characterized by the formation of multiple abscesses, some of which may be very large and contain 500 grams of pus.

3. The nodular gummatous lymphangitic form of sporotrichosis generally originates from an injury. The initial lesion takes the form of an ulcer—so-called sporotrichotic chancre—beginning either as a pustule which bursts and ulcerates, or as an ulcer which extends and assumes various forms. From this point nodules develop, following the course of the lymph-vessels centripetally, spreading to distant regions of the body. Between the tumors indurated lymph cords of uniform consistency can be felt, which also here and there become softened and pass through the same phases as the nodules.

Although the affection, particularly the third form, usually pursues a benign and afebrile course with no general manifestations, the disseminated form sometimes is associated with symptoms of an acute general infection (sporotrichemia), and occasionally terminates in death, especially in debilitated subjects.

Histologicly, the nodules present the structure of tuberculous and syphilitic granulomata. The central portions consist of epithelioid cells, among which are scattered large and small groups of polymorphonuclear leucocytes and also giant cells. The epidermis and papillary stratum are unaltered.

The fungus, of which De Beurmann distinguishes three varieties—*alpha, beta,* and *gamma*—has thus far not been found in the tissues, fluid, or pus from the lesions in man, but can be obtained from the pus by culture upon various culture media. Microscopicly, the fungus consists of straight and curved, slightly intertwined mycelia separated into segments of from 40 to 50 micra in length, and from 3 to 4 micra in width. The oval spores are either free or adherent to the mycelia by short hyphæ.

Cultures.—Upon agar there appears, after about six days, a delicate, slightly raised, whitish, dull opalescent or faintly blue-tinged growth surrounded by a fine radiately striated zone. After another four to six days the colony attains a diameter of from 5 to 6 mm., and the central portions look like a map in relief surrounded by a border of delicate

[1] Presse médicale, April 14, 1906.

white rays. Still later the color becomes dark to black-brown. On glycerin-agar the dark color occurs later, and after a few generations the culture remains white. According to De Beurmann, if the growth be again transplanted upon glucose-agar it regains its former darker color. The pigment is diffusely contained in the spores and is insoluble in alcohol, ether, acetone, chloroform, and mineral acids, and is free from iron. (Stein.) Dryness, addition of sugar, admission of light and air favor its development.

Inoculation of animals of various species, especially rats, with culture products gives, in many cases, a pathologic picture identic with that of sporotrichosis of the skin. Similarly to glanders inoculation in guinea-pigs, rats invariably show upon injection into the peritoneal cavity a pronounced pathognomonic inflammation of the seminal cord, testes, and epididymis. The scrotum in many cases ruptures, and the animal perishes from the effects of the inoculation. At necropsy all organs: liver, lungs, kidneys, bones, etc., are found to contain virulent tuberculoid foci. Rats spontaneously suffer from sporotrichosis.

Saline suspensions of the spores are agglutinated by the serum of patients one year after recovery in dilution of 1:500 to 1:800.

Streptothrix asteroides is a fungus isolated by Eppinger from the pus of a cerebral abscess.

Anthrax.

Anthrax, or **malignant pustule** (*charbon, furunculus malignus*), was the first infection proved to be of bacterial origin. It is principally an affection of cattle, sheep, deer, etc., rarely in the horse and swine, due to a specific micro-organism—the anthrax bacillus. In animals the bacillus enters the intestine with the food, produces intestinal anthrax, and then invades the blood, in which it was first observed by Pollender, in 1849. The disease is comparatively rarely transmitted to man. Great epidemics in man are unknown; it always occurs sporadicly. Apparently, the danger of transmission from man to man is slight. Those persons who come in contact with animals affected with anthrax, especially the fresh flesh (cattlemen, veterinary surgeons, butchers, etc.), hides, wool, and hair (tanners, furriers, upholsterers, etc.), are most frequently attacked.

The pathogenic micro-organism (*Bacillus anthracis,* Pollender and Davaine, 1849-50), first cultivated and accurately studied by R. Koch, in 1876-78, is a comparatively large, nonmotile bacillus. (See Plate VI, Fig. 5.) It develops at from 16° to 45° C. (60.8° to 113° F.), best at 37° C. (98.6° F.), requires a free supply of oxygen, and forms very permanent and resistant spores outside the animal body. The bacilli are often joined end-to-end in the form of a chain. In stained

specimens, and occasionally also in unstained preparations, a clear space can be seen at the point of union of the segments, due to cupping of the extremities of the rods. In the dry state the spores may remain virulent for years. The bacilli stain readily with all the ordinary aniline dyes. According to Koch, this bacillus is a saprophyte and only occasionally enters the human or animal body as a "facultative parasite." The development is not dependent upon the human or animal organism.

In susceptible animals the bacilli are found principally in the blood, the spleen, and exudations. In man, also, the blood-vessels and adjacent tissues are especially characterized by the presence of large numbers

Fig. 251.—Colony of anthrax bacilli, slightly magnified. (After *Flügge.*)

of the bacilli. The bacilli are not taken up by the colorless blood-corpuscles (leucocytes).

Transmission of the bacilli by insects (biting flies, etc.) is very probable in animals. In man infection takes place by way of almost all surfaces, especially the skin of the neck, face, and hands (often through insignificant excoriations which are easily overlooked), the small and large intestine, and not rarely through the respiratory tract (''wool-sorters' disease'').

The phenomena of infection begin after a variable, but usually short, period of incubation, and not infrequently even after a few hours. In the majority of cases a carbuncle—a gangrenous nodule of the skin—develops. A distinction is made between the ordinary, simple, primary carbuncle located at the point of infection or inoculation, and the secondary foci which may form at various points in the skin after general infection with septic character.

The local infection generally begins by the formation of a small, red, itching spot with a blackish, punctiform center. This swells to a papule and becomes painful; the swelling increases and a wheal with a vesicular elevation about the size of a lentil develops. This contains at first a clear, later a dark-red, hemorrhagic material: *pustula maligna*, anthrax pock. After abrasion or rupture, the excoriated surface dries and forms a blackish scab.. The surrounding parts become edematous and intensely hyperemic. In the immediate neighborhood of the scab new vesicles develop which undergo the same changes. At the same time the hemorrhagic-edematous infiltration extends to the deeper parts, and forms a more or less dense nodule, which gradually dies—becomes necrotic. While desiccation takes place upon the surface, disintegration occurs in the deeper structures. The gangrenous nodule—*sphacelus*—may become limited and be cast off by a dissecting suppuration, leaving an ordinary wound surface which cicatrizes by granulation. In other cases the process spreads and involves a larger area. Phenomena of severe general sepsis are usually present. Sometimes the local affection is very slight, while the general phenomena assume an extremely violent and threatening character. Death sometimes occurs within twelve hours after infection, but, as a rule, not until after the second day.

If the anthrax bacilli enter the body from the intestine, severe gastrointestinal symptoms develop, which are due to local hemorrhagic sloughing of the mucosa of the small intestine and partly also of the large intestine. The lentil- to bean- sized hemorrhagic foci usually have a discolored center. In the periphery the mucosa and submucosa are the seat of intense edematous and hemorrhagic infiltration.

In infection through the air passages, edematous and hemorrhagic inflammations of the lung also occur, which are generally associated with hemorrhagic pleuritis. The thoracic lymph-glands are swollen, hemorrhagic, and very succulent.

In all cases of anthrax infection the tendency to hemorrhage is very pronounced, and in almost all cases the adjacent lymph-glands are greatly enlarged, edematous, and the seat of hemorrhagic infiltration.

The spleen[1] is usually swollen, sometimes greatly, but occasionally only to a remarkably slight degree.

Glanders.

Glanders, *malleus* (farcy, *equinia*[2]), is an infectious disease occurring in whole-hoofed animals, which is communicable to man and

[1] The disease receives its name "splenic fever" (Milzbrand) from the intense tumefaction and consequent friability of the spleen in animals.

[2] Lat.: *equus:* a horse.

is due to the presence of the *Bacillus mallei*—a slender rod similar to, though somewhat shorter and thicker than, the tubercle bacillus. As branching forms of this micro-organism have been observed, some authorities class it with the streptothrixiæ.

The bacillus of glanders (see Plate VI, Fig. 6), discovered and described by Löffler and Schütz (1882), grows between 25° to 42° C. (77° to 107.6° F.). It belongs to the facultative anaërobic fungi, is non-motile, and probably forms spores. Temperatures of 55° C. (131° F.) and over kill cultures of it in ten minutes. The bacillus of glanders does not occur in the blood, but, on the other hand, is frequently located in the lymph-channels. In the tissues the bacilli generally are isolated, rarely in pairs or groups, and are seen free between the cells, but often also within them.

Glanders of man reproduces glanders in horses. Glanders attacks those persons who come in contact with horses, particularly coachmen, veterinarians, hostlers, etc. In man, the points of entrance of the bacilli are the unprotected portions of the body, especially the head, including the nasal mucosa and conjunctiva, and the upper extremities, generally through cutaneous abrasions. After a period of incubation lasting for from three to five days, an erysipelatous swelling develops at the point of inoculation, which becomes covered with vesicles, grows dark red, and advances to gangrene (*erysipelas gangrænosum*) or suppuration. This local affection may heal with the occurrence of febrile phenomena and local recidives, which diminish in intensity. Generally, however, the period of eruption of true glanders follows an intermediate febrile stadium which is ushered in by chill. The further course is sometimes acute, sometimes chronic, in character. In acute glanders, vesicular and pustular exanthemata, phlegmonous inflammation of the subcutis, muscle abscesses, and the characteristic glanders nodules in the mucosa of the nose, larynx, trachea, and bronchi appear, accompanied by increasing pyrexia of a typhoid character. With increase of the fever and gradual loss of strength, death follows from exhaustion in from three days to four weeks. Lymphangitis and lymphadenitis, from which genuine metastases originate, generally occur at the primary focus of infection. The metastases manifest a disposition to infect the neighboring tissues. In addition to mucopurulent, sometimes hemorrhagic, discharges (hence, "snot," Rotz), the peculiar glanders nodules develop in the nasal mucosa. These are small, spheric, yellowish, pinhead-sized swellings which have an intensely red areola and possess a certain resemblance to pustules. The latter do not, however, contain pus, but a quite dry, amorphous, cloudy, whitish or yellowish-white material. These nodules suppurate, burst, and leave a

quite deep, crater-like ulcer with sharply defined margins. By eruption and ulceration of new nodules, large ulcerated surfaces with serrated and excavated edges are produced. This ulceration of the nasal mucosa is generally associated with an erysipelatous swelling of the whole nose and neighboring parts: the eyelids, etc. A severe conjunctivitis, resulting in agglutination of the eyelids, occurs. Sometimes large areas of the nose are completely destroyed within a short period of time. (See Fig. 252.)

Formation of glanders, nodules, and abscesses occurs in the internal organs, especially in the lungs, kidneys, spleen, lymph-glands, and testes, and rarer in the liver, joints, and serous membranes.

In chronic glanders, or **farcy**, nodules of marked density form, which persist for a long time. These are often arranged in wreath or vermicular form, and by ulceration often produce deep, sinuous ulcers, which heal with difficulty. Chronic glanders begins and progresses in-

Fig. 252.—Glanders nodule of the left lower turbinate bone of a hostler aged 39 years. *a*, glanders nodule; *b*, hyperemic-hemorrhagic areola in the vicinity of the glanders nodule. Natural size. (After *Langerhans.*)

sidiously. Remissions sometimes occur; nevertheless, the prognosis is not much more favorable than in the acute form.

Foot and Mouth Disease.

Foot and mouth disease, an infectious process occurring in cattle, may be transmitted to man. In the human subject it occurs in the form of an intense glossitis and vesicular stomatitis. The causative agent, which is unknown, is present in the contents of the vesicles and must be very minute, since the virus can be removed only by filtration through very dense filters. In children, ingestion of milk from infected cows is followed by febrile digestive disturbances and the above-mentioned vesicular stomatitis (cheilitis, glossitis). Infection may occur also in adults.

Tetanus.

By spasms (*spasmi, convulsiones*) is understood muscular contractions of unusual intensity and violence. These motoric excesses are always referable to disturbances in the nervous apparatus. There are to be distinguished persistent, continuous muscular contraction,

or *spasmi tonici*, and short, repeated contractions: *spasmi clonici*, or true convulsions. To the tonic spasms belong tetanus and trismus (tetanus of masseters). Tetanus is characterized by long-continued contractions with momentary intervals.

Tetanus can be experimentally produced in animals by inoculation with the bacillus of traumatic tetanus[1] (lockjaw, trismus), discovered by Nicolaier, in 1884, and cultivated by Kitasato, in 1889. This bacillus is a large, slender, actively motile, strictly anaërobic rod with polar spores. (See Fig. 253.) It can be found in earth and dust. No characteristic organic lesions are found in man after death. Rigor mortis, however, is unusually persistent. In inoculated animals

Fig. 253.—Bacillus tetani. × 1000. (After *Fränkel and Pfeiffer.*)

which have died of tetanus, the bacillus is found only at the point of inoculation.[2] This quite clearly demonstrates the toxic action, which is exerted principally upon the nervous system. The filtrate of bouillon cultures of the bacilli acts upon guinea-pigs the same as the bacilli.

Erysipelas.

The pathogenic micro-organism of erysipelas[3] (St. Anthony's fire, wildfire, rose) is the *Streptococcus erysipelatis*, discovered by Fehleisen and Koch (1881). It is a small, non-motile, facultative aërobic coccus, arranged in chain form, which is found in the human body partly within and partly between the cells. When

[1] A tetanoid state is produced also with strychnine.

[2] Quite recently it is said to have been found also in the blood and internal organs of animals. (Centralblatt f. Bakt., etc., Orig., Bd. xlix, p. 583.)

[3] ἐρυθρος = red; πέλλα = skin.

this micrococcus gains admission to wound surfaces, or enters through some small epithelial defect in the apparently intact skin, it produces in these parts a violent inflammatory swelling of the true skin accompanied by intense fever and grave general phenomena: intense edematous and slight cellular infiltration. The inflammatory edema is often so intense that the epidermis of the cutis is raised in vesicles: *erysipelas vesiculosum,* or *bullosum.* In rarer cases gan-

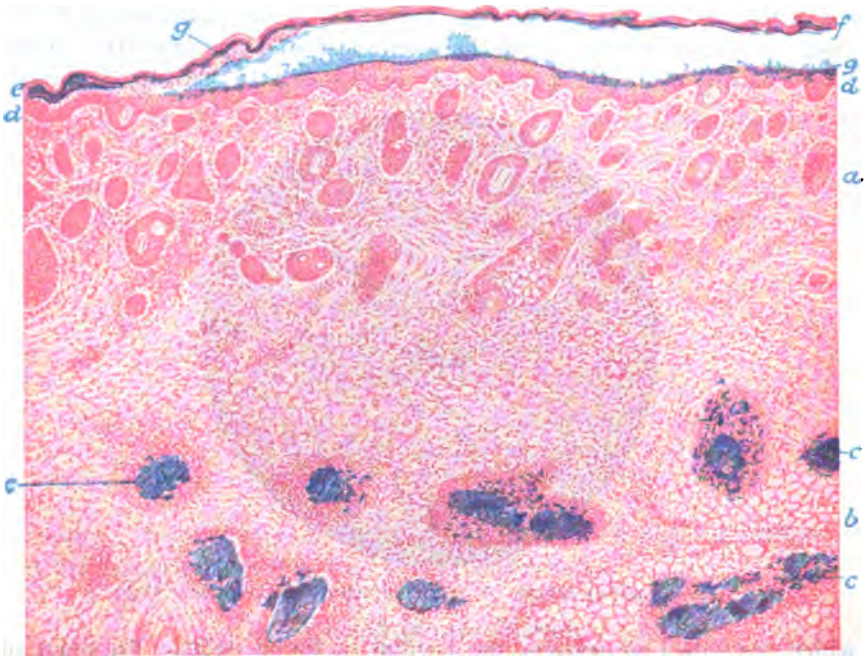

Fig. 254.—Ectogenous streptococcus infection. Eczema and erysipelas of the scalp in a child 1 month old. (Bacteria carmine stain.) *a,* cutis; *b,* subcutis; *c,* lymph-vessels filled with streptococci, surrounded by an inflammatory area; *d,* epithelial covering; *e, f,* elevated horny layer; *g,* streptococci. × 50. (*Ziegler.*)

grene of the affected parts occurs: *erysipelas gangrænosum.* The most frequent seat of erysipelas is the head: *erysipelas faciei.* In hairy parts the hairs may become loosened from the root-sheaths and the hair-bulb be lifted from the papillæ as the result of edematous swelling. Then, as a rule, after the subsidence of the inflammatory phenomena, *defluvium capillorum* occurs. Upon the head, erysipelas very frequently begins in the neighborhood of the nose (usually in connection with a coryza), gradually spreads from this point, and sometimes extends slowly over

the whole head, the older portions healing. This extension is often more distinctly manifest in erysipelas of the extremities: *erysipelas migrans* (wandering erysipelas), and ceases only at the junction of the extremities with the trunk. Facial erysipelas seldom extends to the neck. The lymph-glands belonging to the affected area are always swollen. A suppurative, phlegmonous, or gangrenous inflammation of the subcutis is sometimes associated with erysipelas (*erysipelas phlegmonodes, gangrænosum*), especially when the patients have already suffered severely from the erysipelas. Reduction of the swellings and decline of the fever usually occur within one or two weeks. The fever generally begins with the appearance of local alterations, though it may precede or follow these. In unfavorable cases, death occurs as the result of the continued pyrexia (through action upon the musculature of the heart), or from complications: purulent meningitis, bronchitis, pneumonia, pericarditis and pleuritis, hemorrhagic nephritis, etc. In the mucous membranes inflammatory edema occurs, which, in part, at least, is due to other causes. On the other hand, erysipelas may extend to the pharynx and larynx, and cause edema of the glottis, which usually very quickly causes death: *laryngitis erysipelatodes, œdema glottidis erysipelatodes.*

Gonorrhea (Blennorrhea).

The pathogenic micro-organism of gonorrhea, or, vulgarly, clap, is the *gonococcus,* discovered by Neisser, in 1879. It invariably occurs in diplococcus form. It is distinguished from other cocci by the fact that the apposed surfaces are flattened. (See Plate VII, Fig. 1.) It is always found in the gonorrheal secretion, partly inclosed in cells (leucocytes or pus-corpuscles), partly upon the epithelium, partly free. In cultures it very quickly perishes. Media made with human blood-serum are best adapted to their growth.

Gonorrhea is an acute inflammation of the male and female urethra and of the female genital canal, especially of the cervix uteri, which is generally associated with purulent secretions. In these localities the gonococcus is found not only in the epithelium, but also in the superficial layers of the mucous membrane, which is densely infiltrated with round cells.

In the male urethra the inflammation is first confined to the anterior section—the *pars cavernosa urethræ,* but gradually extends to the posterior portion—the *pars membranacea* and *prostatica,* and the *sinus prostaticus.* When the inflammation is very intense and of long duration, or irritating injections have been used, ulcerations develop, which, by retraction, form cicatrices and terminate in the much-dreaded

strictures. In very protracted cases, a noninfectious catarrh sometimes persists after the virulent stadium has passed and gonococci have disappeared. In this case the mucous membrane appears thickened and finely granular. The strictures are narrowings of the lumen which are sometimes confined to a limited area, especially the *pars membranacea;* but occasionally they extend throughout almost the whole urethra. In the latter instance the mucous membrane is atrophic, quite smooth, and in many places fibrous and cicatrized. Occasionally the cicatricial contraction is so considerable that the urine can be voided only in drops. In general, gonorrheal affections of the urethra are comparatively harmless. Under certain conditions, however, the gonococcus may cause alterations which render prognosis decidedly unfavorable (septicemia, peritonitis).

As in all infectious diseases, individual differences occur also in gonorrhea. In many patients the process remains confined to the mucous membrane of the urethra; in others, further disorders very soon appear, the catarrh, which is usually purulent, rapidly extending to the passages lined with mucous membrane: through the seminal vesicles and vas deferens to the epididymis and even to the tunica vaginalis propria of the testes (periorchitis); furthermore, through the excretory ducts of the prostate to the glandular ducts of the prostate itself, occasionally also to the mucous membrane of the bladder, etc. Spermatocystitis, epididymitis, prostatitis, acute gonorrheal catarrhal cystitis, etc., occur, all of which are characterized by a violent course and great disposition to recidives. Sometimes periurethritis is associated with the urethritis, as the result of extension of the process to the deeper parts. Here, as well as in the prostate, large abscesses, which may rupture externally or into the urethra, not infrequently develop. In many cases complications are probably the result of mixed infection.

In the female the acute catarrhal process may spread to the vagina, the cervix and corpus uteri, and the Fallopian tubes (colpitis, endometritis, gonorrheal salpingitis), and even produce chronic perimetritis. The process is sometimes confined to the cervix uteri and vagina; in other cases the cervic endometritis and colpitis are decidedly obstinate. In chronic cases indurations occur in the mucous membrane of the uterus and vagina, which result in smooth atrophy (*colpitis lævis*). In this condition the vagina assumes a hard, smooth, leathery consistency, and loses almost all its folds. An acute metritis often accompanies the endometritis, which, however, is not usually demonstrable *post mortem*, since the chief symptom—intense uterine hyperemia—disappears with death. Purulent gonor-

rheal salpingitis occasionally extends to the peritoneum, and produces general purulent peritonitis.

Transference of gonorrheal virus to the eyes, and true metastases are very much to be dreaded. If gonorrheal secretion reaches the conjunctiva, a very violent conjunctivitis, with inflammatory edema and intense cellular proliferation, develops in less than twenty-four hours. At first a thin, watery, later a thick, purulent, exudate is secreted in which gonococci can be demonstrated. The danger of *conjunctivitis blennorrhœica s. gonorrhœica* (*q.v.*) lies in the extension of the process to the cornea: purulent keratitis (*q.v.*), which may appear from the third day onward. In favorable cases a circumscribed purulent infiltration of the cornea develops, which terminates in small ulcerations. In the severe form a rapidly progressive suppuration with complete destruction of the cornea results. As a rule, mothers suffering from gonorrhea infect their offspring during parturition: *ophthalmia neonatorum* (*q.v.*). This form of conjunctivitis may be obviated by prophylactic measures, or a generally mild conjunctivitis and keratitis, with only slight ulcerations, may develop.

True gonorrheal metastasis[1] occurs as so-called muscular or articular rheumatism, and consists of acute inflammations of the joints (gonorrheal arthritis, *q.v.*) and tendon-sheaths (gonorrheal tendovaginitis), in which, as a rule, only a small amount of pus is formed. The knee-joint is most often affected (gonorrheal gonitis), and next in frequency the ankle- and wrist-joints. Occasionally, however, purulent inflammations develop in various joints and tendon-sheaths, and in many internal organs: the kidneys, lungs, liver, heart [most frequently as endocarditis (*q.v.*), rarely as myocarditis or pericarditis], the voluntary skeletal muscles, etc. The process then progresses as acute pyemia and usually ends in death.

Bubonic Plague (Black Death).

Bubonic plague is endemic in Asia (Bombay, Ungada, Persia, Thibet, West Coast of Arabia, eastern Siberia), and is only occasionally imported into Europe and other countries.

The following forms are differentiated: the bubonic or ganglionic, which is most frequent; the septicemic, the pneumonic, and the intestinal. The pneumonic form is most fatal.

The onset is usually sudden. The principal feature of plague infection is regional tumefaction of the lymphatic glands,

[1] Gonorrheal conjunctivitis is said to occur also by metastasis (see Gonorrheal Conjunctivitis).

most frequently the inguinal and crural glands; next the axillary and cervic glands. If the swollen glands are superficial, they produce the so-called plague buboes, which may rupture externally. The pus from these contains large numbers of the specific bacilli. Swelling of the spleen, which is sometimes very marked, and numerous small, punctiform hemorrhages of the skin, mucous and serous membranes accompany the glandular tumefactions; furthermore, cloudy swelling of the internal organs, and sometimes hematuria, rectal hemorrhage, pneumonitis, and, occasionally, pulmonary infarctions occur. Carbuncles also develop, most frequently upon the inferior extremities. Panophthalmitis, followed by total blindness, may occur within twenty-four hours. Keratitis, and meningitis, secondary to the pneumonic form, occur. Occasionally bubonic plague is a *morbus multiplex,* being combined with small-pox, leprosy, small-pox and leprosy, chicken-pox and relapsing fever, measles and erysipelas, etc.

The bacillus of bubonic plague, or *Bacillus pestis,* was discovered synchronously, in 1894, by Kitasato and Yersin, in Hong Kong. In it is a small, short, nonmotile rod, 1.5 to 1.75 μ in length, and 0.5 to 0.75 μ in breadth, with rounded ends, often appearing as a diplobacillus or coccobacillus, and not rarely in short chains. No spore formation has been observed. It is often found in enormous numbers in the affected organs, in the sputa of pneumonic cases, in the blood in the septicemic forms, and *post mortem* in almost all tissues of the body. Possibly the urine also contains the bacilli. The intestinal discharges are said to be free of bacilli, though this is questionable. The bacilli multiply in the lymphatics.

Transmission occurs most frequently through small cutaneous injuries and through the lungs (inhalation). It may occur also through the intestinal canal. Extension of an epidemic is said frequently to be favored by vermin, especially rats (also mice). It is believed to be transmitted to man by fleas that have infested plague-stricken rats and ground squirrels. The Bombay Plague Commission showed that fleas from rats dead of plague can transmit plague to rats, guinea-pigs, and monkeys, and Liston found the rat flea upon the body of a patient dying of plague. In California the ground squirrel has been proved to be a host.

The Purulent and Putrid Processes and the Pyogenic Bacteria.

In purulent, phlegmonous, and septic processes the specific pyogenic micrococci: *Staphylococcus pyogenes aureus, albus,* and *citreus,* and *Streptococcus pyogenes* (see Plate VII, Fig. 2),

in addition to other still partly unknown species of bacteria, are very frequently found.

Staphylococcus pyogenes aureus is a very small coccus which produces grape-like (σταφυλή = a grape) colonies which, after a time, generate an orange-yellow or gold-yellow coloring matter. Staphylococcus aureus thrives best at a temperature of 37° C. (98.6° F.); it grows also in the absence of air, but less luxuriantly, and is very resistant to dryness. In man it invariably induces suppuration when it gains entrance to a wound or is rubbed into the uninjured skin (hair-follicle). In animals abscesses are regularly produced by inoculation into the skin; by injection into the abdominal cavity, severe purulent peritonitis is mostly obtained, and by injection into the blood-current, disseminated (metastatic) suppurations are generated in the joints, the heart muscle, kidneys, liver, etc. If the cardiac valves or bones are injured before injection of the cocci into the blood-vessels, typic malignant ulcerative endocarditis, or an acute osteomyelitis, respectively, is produced.

Purulent inflammations do not always occur; on the contrary, there is sometimes no reaction on the part of the tissues. The success of the experiment depends upon the quantity and virulence of the micrococci injected, the state of the tissues (intentional and accidental injuries, *e.g.*, of the aortic valves, increase the disposition), and also upon the nature of the material in which the injected staphylococci are suspended. If, for example, metabolic products, with which the pyogenic action appears primarily to be associated, are also injected with the cocci, the result is more certain than when the cocci are suspended in pure distilled water. The metabolic products alone, like certain chemic substances, also may produce suppuration without participation of the bacteria. In all cases, therefore, the process depends not only upon the presence of the bacteria, but also upon the accompanying conditions and upon the state or disposition of the tissues.

Besides the bacterial metabolic products excreted into the surrounding fluids, there are present within the bacterial cells chemic (proteid) substances which can artificially be extracted and possess toxic action for man. (See Anaphylaxis, p. 322.) Therefore, whenever pathogenic bacteria enter the body two forms of action occur: (1) the action of the bacteria *per se:* infection; (2) the action of their metabolic products, *i.e.*, chemic substances: intoxication. In some instances the primary focus of infection may heal and in spite of this the phenomena of general infection develop. It may then be impossible to discover the point of entry of the bacteria; the condition is then designated as **cryptogenetic septicopyemia.**

Pure cultures of *Staphylococcus pyogenes albus* and *citreus* are distinguished from *Staphylococcus aureus* solely by the fact that the first produces no coloring matter, while *citreus* generates a lemon-yellow

color. Both act very similarly to the *Staphylococcus pyogenes aureus*, but they occur more rarely.

Streptococcus pyogenes greatly resembles the *Streptococcus erysipelatis*. It is not improbable that these two micro-organisms are identic, and that the suppurations so frequently associated with erysipelas are caused by the same micrococcus, the latter entering the subcutaneous adipose tissue. Experimental suppurations obtained with the *Streptococcus pyogenes* manifest a great tendency rapidly to spread, while suppuration produced by the staphylococcus generally remains circumscribed.

The **Streptococcus pyogenes longus** is observed in erysipelas, disseminated suppurations, puerperal fever, septic endocarditis, pneumonia, etc. It frequently gives rise to secondary infections, especially in diphtheria, in which it often induces fatal sepsis. The unfavorable termination in some cases of pulmonary tuberculosis also appears to be due to this micro-organism. It has been described in fatal cases of choleriform enteritis, and its presence in septic processes occurring in the course of scarlatina is well known. The cocci grow readily in all nutrient media, forming long and short chains which stain with the ordinary aniline dyes, and also by Gram's method.

The **Streptococcus viridans** (Schottmüller) is distinguished from **Streptococcus longus** by its slower growth and the production upon blood-agar of blackish-green colonies surrounded by a grass-green areola. This coccus not infrequently causes subacute and chronic endocarditis, which runs a protracted course and almost always terminates fatally.

The **Streptococcus mucosus** (Schottmüller) is of rare occurrence. On agar it forms colorless, slimy colonies, and upon blood-agar a gray-green growth. It has been observed in septicemia, peritonitis, otitic meningitis, and other suppurative affections.

A strictly anaërobic streptococcus, first described by Krönig and recently designated by Schottmüller as **Streptococcus putridus**, grows in long and frequently twisted chains. The cocci stain with all aniline dyes, and also by Gram's method. The affections caused by it are always putrid in character. It has been found in meningitis, putrid endometritis, salpingitis, otitis media, sepsis with thrombophlebitis, pulmonary gangrene, etc.

In septic processes, especially in puerperal sepsis and in metastatic suppurations—the so-called pyemic processes in a strict sense—streptococci are most frequently found in the purulent foci and in the blood. In furuncles, carbuncles, cerebral abscesses, purulent peritonitis, ulcerative endocarditis, and phlegmons, staphylococci, as well as streptococci and other bacteria, are found.

Under the designations **sepsis, septicemia** (σεπτικός = make putrid; αἷμα = blood), are included a large group of different infections which are distinguished in common, not so much by the prominence of the locally infected focus as by the predominance of severe general phenomena. The latter must, in great part, be referred to the direct action upon the body of the toxic metabolic products of the most varied and still partly unknown bacteria. As a rule, these are decomposition products closely related to putrefactive substances. These are not, however, introduced into the body from without (as are the probably allied sausage and cheese poisons, etc.), but are formed within the body itself. Therefore, a kind of putrid autointoxication occurs, septic, putrid substances being continuously absorbed from foci of putrefaction.[1] Sometimes the latter cannot be demonstrated after death. This form of infection occurs most frequently in puerperal women: **puerperal sepsis,** and may originate from placental remnants undergoing putrefactive decomposition, from thrombophlebitic conditions at the point of placental attachment, or in the parametrium, and from purulent, diphtheritic, and gangrenous affections of the fresh wound surfaces. It is most closely related to intoxication. This is probably the reason why, in the severest cases running a very acute course, often nothing characteristic is found at the necropsy—not even swelling of the spleen, which is so characteristic of infections. All traces of a local focus, *e.g.,* in the uterus, may be absent; the countless bacteria in the blood, the unusually rapid appearance of decomposition, the peculiar fluid character of the decomposing blood, and slight clouding of the extremely flabby organs offer the only clue to the processes which took place during life.

In other cases alterations characteristic of the severe infectious diseases are observed, especially great swelling of the spleen, parenchymatous degeneration (albuminous and fatty) of the heart-muscle, liver, kidneys, and stomach, and very often, also, in addition to numerous small hemorrhages, intense icterus, and sometimes intestinal diphtheria.

When large local purulent, phlegmonous, or ichorous foci exist, similar metastatic foci frequently form in the lungs, joints, myocardium, liver, kidneys, intermuscular connective tissue, upon the valves of the heart, etc. These cases with metastatic formations by the way of the lymphatic channels or blood-vessels (in the latter instance: embolic) are often designated as purulent infection or pyemia. By this, however, is **not** meant that the blood has been contaminated by,

[1] Sepsis, called also septic infection, signifies not simple putrefaction, but infection with putrid substances, *i.e.,* substances containing bacteria; hence, infection with putrid substances is nothing else than infection with bacteria and their toxins. It is possible that in the infected parts necrotizing, gangrenous putrefactive processes also occur, though this is not necessary.

or mixed with, pus as such. As the septicemic and pyemic effects often are inseparable in purulent processes, the term **septicopyemia**[1] also is employed.

In septic and pyemic processes, acute decomposition of albuminous substances generally occurs. In consequence of this tyrosin is deposited *post mortem*—after necropsy on contact with the air—upon the surface of the organs (most frequently upon the pancreas) in the form of countless small, chalk-white points. These are located partly upon, partly within, the surface, and, therefore, can only partially be rubbed off. They consist of sheaves of minute needles (see Fig. 255), which have a brownish-gray color by transmitted light. This is an interference phenomenon, caused by the rays of light being broken up an



Fig. 255.—Tyrosin. *a*, by transmitted light; *b*, by reflected light. (Zeiss Apochr., 4; Comp. Ocul., 4. After *Langerhans*.)

innumerable number of times by the densely arranged groups of tyrosin needles. By reflected light they are chalk-white.

Febris Recurrens, Relapsing Fever, Famine Fever, Famine Typhus, Typhus Recurrens.

Recurrent, or relapsing, fever is a general infectious disease, occurring usually in two, also three, rarely four or five, paroxysms, beginning with a chill and attended by high fever. The first paroxysm generally lasts for from five to six days, and is followed by an afebrile stadium (apyrexia) of about seven days. Then a second paroxysm begins, which is of about the same duration. After a somewhat longer period of apyrexia, other paroxysms may follow which, as a rule, are very much shorter and of less intensity. Recurrent fever is the first infectious disease in man in which a parasite was discovered in the blood.

[1] That is, the coincident occurrence of toxic action and metastatic foci.

During the paroxysms there is always found in the blood a spiral-shaped, actively motile bacterium (the *Spirillum,* or *Spirochæta, obermeieri*[1]) 16 to 40 μ in length, with from 10 to 20 spiral turns. It is ¼ to ⅓ as thick as the comma bacillus. (See Fig. 256.) It very quickly dies outside of the human body. As far as is known, it does not form spores. It has not as yet been artificially cultivated. Recurrent fever can be produced in healthy persons and monkeys (Koch, 1879) by inoculation with blood containing the spirochætæ. This has been experimentally demonstrated also by the Russian investigators, Muench and Motschutkowski. Metchnikoff even inoculated himself, and five days later he had genuine recurrens with several paroxysms, and spirochætæ were found in his blood.[2] No spirochætæ can be demonstrated in the apyrexial periods. In all cases the spleen is enormously enlarged. After every attack innumerable spirochætæ are found in the spleen, partly inclosed in cells.

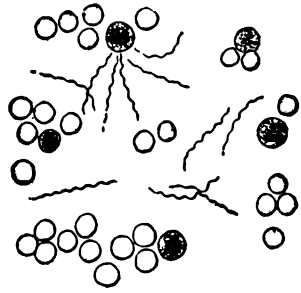

Fig. 256.—Spirochæta obermeieri. (After *von Jaksch.*)

Those affected with the disease are almost always individuals who live crowded together in small huts and bad barracks, inmates of prisons, etc.

Koch[3] has shown that a disease occurs in east Africa which appears to be identical with, or, at least, very closely related to, European recurrens. In this African form a species of tick, *Ornithodorus moubata,* which lives in the native huts and in the shelters erected for travelers on the caravan routes, conveys the spirochætæ to man.

When the ornithodorus tick emerges from the ovum it is no larger than the head of a pin, flat, gray, roughened externally, and quite actively motile. It sucks itself full of blood, sheds after a time, and then has attained double its former size. This process is repeated until the animal has grown to about the size of a lentil. It is then sexually developed. Mating then takes place, after which the female again sucks herself full of blood. She becomes as large as a small bean, then creeps into

[1] Centbl. f. d. med. Wiss., 1873; Berlin. klin. Woch., 1873.
[2] Koch: Berlin. klin. Woch., 1906, p. 183; Post-Graduate, Aug., 1906, p. 770.
[3] *Ibidem.*

dry soil, and there deposits her eggs in several clusters, each of which is composed of about 40 to 50 eggs. According to Koch, the *Ornithodorus moubata* is the only tick in east Africa infesting man. During the day it lies quite deep in the soil; during the night it emerges, creeps to the sleeping person, sucks his blood, and then quickly re-enters the soil.

In general, African recurrens runs the same course as European recurrens, with the difference that the paroxysms are of much shorter duration. Koch observed as many as 24 paroxysms, but none of them lasted longer than three days. A further difference is in the smaller number of spirochætæ present in the blood. In other respects the two forms resemble each other so closely, both as regards complications and sequelæ, that, at most, the African type can be regarded only as a variety of recurrens.

Regarding the pathologicoanatomic changes in man in the African variety of the disease, nothing is known. In monkeys, however, which had died of experimental recurrens, marked enlargement of the spleen was quite constant, and splenic infarcts were almost always present. Phagocytosis, which is particularly characteristic of European recurrens, also was present.

According to Koch, the spirochæta of African recurrens is somewhat longer than those observed in the European form, and consists of a very delicate, quite regularly formed spiral, which actively and continuously turns upon its axis and makes comparatively little progress. Very frequently two spirochætæ are seen to intertwine so closely as to form a spiral of double thickness. Contrary to the statements of Schaudinn, Koch and Zettnow were unable to find anything which could be interpreted as a blepharoplast, a nucleus, or a marginal flagellum. Zettnow did not observe any characteristics in them which would permit him to conclude that they are related to the trypanosomes. He found only transverse, but no longitudinal, fission. He observed also that the spirochætæ have at each end a small appendage which resembles a flagellum, but differs from the flagella of bacteria in that it stains with methylene-blue.

Transmission of the spirochætæ: Koch examined, from day to day, a number of ticks which had sucked recurrens blood under natural conditions and also such which had sucked blood from monkeys affected with recurrens. He found that on the first and second day no change occurred as regards the spirochætæ; they did not increase or assume any other form or shape. On the third day they were decidedly less numerous; their form, however, remained the same; they sometimes disappeared on the third day, but on the fourth day they had entirely disappeared. Although he never found them in the stomach after this time, they had not disappeared from the ticks, for he was able to find considerable numbers in the ovaries, often in dense groups and tufts. It must, therefore, be assumed that if they reach that far an increase occurs. In smear preparations of the ova of ticks which had sucked recurrens blood, spirochætæ were found. Only isolated ticks are infected, and not all of their ova, but only a portion—about ¼ or ⅕—contain the organisms. The spirochætæ are found a short time after the ova are laid, at first few and isolated; later they gradually come together and form tufts. Where they finally

lodge, whether in certain organs, *e.g.*, the salivary glands or in the proboscis, is still undecided; nevertheless, the young ticks are infectious after they leave the ovum, since, according to Koch, Kudicke, and Dutton and Todd, monkeys have been experimentally infected by them.[1]

That the disease can be produced through the agency of young ticks unquestionably proves that the tick is the intermediate host of African recurrens and conveys the infection from diseased to healthy individuals.

Infected ticks are found in huts in which there are no recurrens patients, although the inhabitants are often bitten by ticks. This can be explained, according to Koch, in no other way than that the native is exposed to the infection in early childhood. He then recovers from the disease as those persons in temperate countries recover from measles, or those in tropic countries recover from malaria. Children are thus early rendered more or less immune. It is possible that many ticks become infected from children or from persons who have recovered from the disease, but still harbor a few spirochætæ for a greater or lesser period, perhaps for years. It is known that similar conditions exist in various diseases in which such an intermediate host plays a rôle, *e.g.*, in the trypanosome and piroplasma diseases, partly also in malaria. There is still another possibility, namely, mice and rats may serve as hosts.

As regards the etiology of African recurrent fever, the following conclusions may be drawn:—

Man is infected through the agency of ticks and probably chiefly, perhaps solely, through young ticks. In the infected districts the disease is contracted in childhood, and immunity is thus acquired. The tick must become infected either from fresh cases or from persons who still harbor a few spirochætæ; perhaps also from another source.

Asiatic Cholera.

The *Spirillum,* or *Vibrio, choleræ asiaticæ,* discovered in Egypt, in 1883, by R. Koch, is accepted as the pathogenic micro-organism of Asiatic cholera. It is a quite thick, curved rod, half as long as the tubercle bacillus, belonging to the class of spiral-formed bacteria: the so-called *"comma bacillus."* (See Plate VII, Fig. 3.) Frequently two bacilli are united in S-form, resembling somewhat the groove of a screw. The comma bacillus possesses a flagellum at one extremity, which serves as an organ of locomotion. It is feebly resistant to external influence, dies quickly at a temperature above 50° C. (122° F.), upon action of acids (*e.g.,* hydrochloric acid) and dryness, and is easily overgrown by other, especially putrefactive, bacteria. It develops in artificial cultures at a

[1] According to Balfour, Egyptian spirochætosis differs from the form caused by *S. duttoni.* It is said to be due to *S. berbera* and to be conveyed by lice.

temperature of from 15° to 42° C. (59° to 107° F.), most luxuriantly at the temperature of the body.

The comma bacillus occurs only in the intestine—*i.e.*, in the intestinal contents, in the cylindric epithelium, and in the superficial layers of the mucous membrane. Quite similar bacteria occur also in cholera nostras. Therefore, microscopic demonstration of the comma bacillus by no means suffices for diagnosis. By pure cultures alone can a decision be reached, since pure cultures of the bacteria found in cholera nostras differ from those of the so-called comma bacillus.

All animals appear to be only slightly, or not at all, susceptible to *cholera asiatica hominis.*

While the mode of infection in cholera has not yet been positively determined, it is extremely probable that the virus enters the intestinal canal with the food (drinks, especially water) and there exerts its specific action. Consequently, the characteristic alterations are connected with the intestinal canal. During the period of digestion an extremely violent attack of vomiting and purging develops. As a result the whole digestive tract soon becomes emptied of fecal matters, so that only secretions of the mucosa are found in, and discharged from, the lumen of the bowel. These secretions consist of water (not serum, for albumin is almost totally absent), salts, and exfoliated epithelial masses. These, taken collectively, constitute the characteristic rice-water stools, in which no bile is demonstrable. The bile is not retained, but its secretion is entirely suspended. Complete acholia exists.

The rice-water dejecta sometimes assume the color of meat-juice from admixture of blood. Exfoliated epithelial masses (occasionally whole villi are cast off) are demonstrable only in the fresh stools, because they rapidly disintegrate as the result of decomposition. The watery portion is derived from the blood. Since enormous amounts of water are generally excreted, a gradual thickening of the blood occurs as a result of dehydration. Hence, in the cadaver, the blood (in the heart) often has a syrupy consistency. The hyperemic, light-red intestinal mucosa is always intensely swollen and succulent, in certain localities infiltrated with cellular growths and more or less deprived of epithelium. Owing to intense injection of the smaller vessels, the serosa is rose-red in color, sometimes slightly bluish red, and has a sticky feel. In the cadaver, fat retention in the villi and chyle retention in the mesenteric glands are very frequently observed. All the follicles of the intestinal mucosa are swollen and occasionally surrounded by a strongly hyperemic area. Excavations are often found in the follicles, as a result of which the Peyer patches sometimes assume a

cribriform appearance. This is a purely cadaveric phenomenon, which is caused by absorption of water, swelling, and synchronous maceration, bursting, and partial emptying of the follicles.

The second variety of alteration in the cholera bowel is the diphtheritic[1] process favored by the epithelial defect. This occurs not only in the colon, as in dysentery, but often throughout the whole gastro-intestinal canal; it is much more extensive, but in certain localities less intense than in dysentery. The most severe alterations are found in the hemorrhagic form of cholera. In all cases the colon is the most markedly involved by the diphtheritic process. The diphtheritic cases, however, represent the minority of those ending fatally. In general, cholera manifests but a slight disposition to ulcerative processes. The localities denuded of epithelium become covered slowly, the epithelial repair advancing gradually from the adjacent parts. Parenchymatous nephritis, corresponding to the early occurrence of anuria, is very frequently found at the necropsy; also, hyperemia of the mucosa of the renal pelves, of the arachnoid, of the cortic substance of the brain, of the serous membranes (these, also, are said frequently to have a sticky feel), of the uterine mucosa (often hemorrhagic hyperemia: pseudo-menstrual condition, *e.g.*, in old women), and, when death occurs at a later stage, fatty metamorphosis of the heart and liver, spleen-tumor, occasionally bronchitis, pneumonia, erysipelatous and purulent processes, etc. Some of these changes belong to the great realm of sequelæ, and are, therefore, not characteristic of Asiatic cholera.

The cholera vibrio can be demonstrated in the excreta for a considerable period after recovery—for from fifty-five to ninety days. It undergoes in the human body biologic and morphologic alterations which cause it to deviate from the type of cholera bacillus, and it may lose completely its agglutinability. These alterations frequently render it impossible to obtain the vibrio from undoubted cholera cases. Their disappearance from the intestinal canal and the alterations which they undergo depend in great measure upon the associated flora. If protected from air, the vibrios may retain their vitality in the excreta outside the body for from seven to nine months. If air is admitted they die sooner. As the agglutinability of the vibrio is very variable, every vibrio obtained from the excreta during or at the beginning of an epidemic must be regarded with suspicion, even though it does not agglutinate.

Typhus Abdominalis, Typhoid Fever.

The pathogenic micro-organism (Eberth-Gaffky, 1881-84) of *typhus abdominalis* is a small, slender, Gram-negative bacillus (*Bacillus typhosus*) having very numerous lateral flagella as organs of locomotion. It develops readily upon all culture media in the presence as well as in the

[1] Compare p. 526 *et seq.*

absence of air. Under unfavorable conditions so-called "polar granules" (not spores, but probably involution phenomena) form at the extremities. It grows best at the temperature of the body. It is quite resistant to dryness. The bacillus probably reaches the intestine with drinking-water and food (green vegetables, shellfish, milk, etc.), and manifests its deleterious action after it has entered the mucous membrane and the blood. The bacilli are later found in the intestinal follicles, mesenteric glands, spleen, kidneys, liver, skin (rose spots), and blood, and are excreted with the feces and often in the urine.[1] The toxins appear to be associated essentially with the bacilli themselves *i.e.*, endotoxins.

The alterations peculiar to typhus abdominalis are connected with the follicular apparatus of the intestine. The follicles



Fig. 257.—Typhoid bacilli (pure culture). (After *Schenk.*)

of the small intestine occur partly isolated as the so-called solitary follicles, partly in groups, *i.e.*, either as smaller or larger so-called Peyer's patches. In the normal state they are only slightly elevated above the surface. The Peyer patches are situated opposite to the attachment of the mesentery, and always have a greater length than diameter (the long diameter running parallel to the long axis of the intestine). The large Peyer patches are most constantly involved in typhoid, and next in order the small patches and solitary follicles. In the large intestine only the solitary follicles can become altered, since Peyer's patches do not occur here.

The usual seat of abdominal typhus is the region in front of and behind the valve of Bauhin (ileocecal valve), especially the lower portion of the ileum (hence, **ileotyphus**) and the valve of Bauhin, rarer the whole small intestine or the large intestine alone (**colotyphus**). In

[1] The typhoid bacillus is found in the urine in about 25 per cent. of the cases, and, while it may be detected at the period of eruption of the rose spots, it usually is observed in the later stages after defervescence or late convalescence.

addition, the vermiform appendix and the mesenteric glands belonging to the affected portion of the intestine are invariably involved in the same manner.

The characteristic lesion of abdominal typhus is an intense hyperplasia of the lymph-corpuscles of the follicles and infiltration of the



Fig. 258.—Typhoid bacilli (spider cells). × 1100 times. (After *Löffler.*)

Fig. 259.—Typhoid swelling of Peyer's patches and solitary glands of the intestine. (After *Green.*)

adjacent tissues with the same type of cells. Various large, round cells (endothelia), which usually contain a large nucleus and nucleolus, develop. The nucleus as well as the cell body is quite transparent. Between these cells, multinucleated round cells, and sometimes typic giant cells, are observed. With the development of these the highest

Fig. 260.—*A*, ileum seen from the surface; *a*, Peyer's patches; *b*, solitary follicle; *c*, small follicle group; *d*, medullary swelling in a Peyer patch; *e*, medullary swelling of a small follicle group; *f*, medullary swollen solitary follicle.

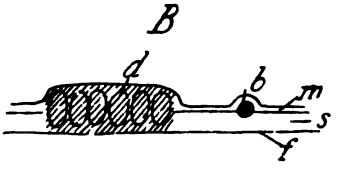

Fig. 261.—*B*, ileum in section; *d*, medullary swollen Peyer's patch; *b*, nonswollen solitary follicle.

stadium of medullary proliferation—the acme of the local process (second week)—is generally attained. This is the first stage of typhoid—not an ordinary inflammation, but an enormous accumulation of large lymph-corpuscles. Small lymphatic tumors thus develop which, upon incision, have a medullary, marrowy, reddish-

gray (as long as the vessels are strongly injected) or whitish-opaque character. Hence, this process is called medullary swelling: *intumescentia medullaris* (medullary infiltration). In the state of medullary swelling the follicles become much more prominent. This is due partly to enlargement of the follicles, partly also to the fact that the tissues in the neighborhood of the follicles always participate in the medullary swelling (extrafollicular swelling), *i.e.*, are altered in the same manner as the follicles and coalesce with these into a uniform, medullary mass. (See Figs. 260 and 261.) In consequence of this the medullary proliferation extends through the whole submucosa to the fibrous layer which separates the submucosa from the muscularis.

Sometimes a whole Peyer patch, sometimes only isolated follicles of the patch, are altered in the manner described. In the former instance the whole patch is transformed into a uniform, medullary mass; the Peyer patch then forms an enormously swollen, medullary plaque, which,

Fig. 262.—*f*, medullary follicle.

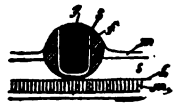

Fig. 263.—*f*, follicle; *g*, sphacelus; *s*, dissection space.

Fig. 264.—*f*, medullary infiltrated margin; *u*, typhoid ulcer; *r*, steep margin.

on strong contraction of the intestine, sometimes has a wrinkled surface. More often, however, only a portion of a Peyer patch is involved.

The rest of the mucosa surrounding the follicles is almost invariably in the state of catarrhal enteritis. Since irritation of the liver, which leads to polycholia, usually coexists, this intestinal catarrh furnishes the characteristic diarrheal, intensely bile-stained, and therefore pea-colored typhoid stools. Only in relatively few cases is diarrhea entirely absent: *typhus siccus.*

When the stadium of medullary swelling has reached its acme, the retrogressive stage (*stadium decrementi*) begins, which may terminate in ulceration or resolution. In the first instance the whole focus in time becomes somewhat cloudy and assumes a yellowish-white, corroded appearance. The alteration is always more marked in the central than in the peripheral portions, so that the focus acquires a large, central plug (see Fig. 262, *g*) which gradually becomes more and more separated from the surrounding whitish infiltration, in that it grows more opaque, dull, dry, and yellow. The yellow material is the dead, necrotic part: typhus slough or sphacelus. This at first remains connected with living parts at its periphery; later, limitation takes

place, a reactive inflammation occurring in the surrounding tissues, as in the periphery of all necrotic parts, which limits and loosens the mortified mass by dissecting suppuration. As a result of the dissection a small cleft (see Fig. 263, *s*) is produced, which extends to the immediate neighborhood of the fibrous layer. At the same time imbibition of the dead part with intestinal contents, especially with bile-coloring matters, takes place, so that the slough acquires a yellowish, brownish, or green-



Fig. 265.—A typhoid ulcer of the intestine. (After *Green.*)

ish color. In addition, the surface becomes fissured and gradually softened as the result of putrid decomposition. Loosening of the sphacelus begins at the surface and advances toward the deeper portions. Finally, the slough is completely exfoliated and an ulcer with medullary infiltrated (see Fig. 264, *f*), perpendicular (not undermined) margins (see Fig. 264, *r*): *ulcus typhosum,* is produced. The base of this deep, true submucous ulcer (*ulcus profundum*) is usually clean, and the parallel striations of the muscularis can be rec-

Fig. 266.—*u*, ulcus depuratum; *r*, slightly overhanging margins. (After *Langerhans.*)

Fig. 267.—*f*, medullary follicle; *i*, medullary swelling of the subserosa; *h*, line of connection along the vessels. (After *Langerhans.*)

ognized through the fibrous fascia. The size of the ulcer depends upon the number of follicles; several ulcers are often seen in one Peyer's patch, but adjacent mortified follicles always form only one ulcer after separation of the sphaceli.

If a whole Peyer patch is exfoliated, a large ulcer is produced, the margins become relaxed and slightly overhanging (see Fig. 266, *r*); in contradistinction to the tuberculous annular ulcer. In the reactive process of dissection, the margins and the parts immediately surrounding the sphacelus assume a reddened appearance; sometimes hemor-

Fig. 268.—Typhoid infantum in a 2-year-old boy. *a*, solitary follicle; *b*, small agminated gland; *c*, Peyer's patch. General medullary infiltration; no ulceration. Natural size. (*Langerhans.*)

Fig. 269.—*a*, *f*, *e*, medullary swollen follicles; *x*, mesenteric glands; the shaded are medullary swollen. (After *Langerhans.*)

rhagic infiltration and extravasation in the form of diapedesis occur. If the dissecting process extends into the depth—*i.e.*, into the submucosa—arterial and venous vessels in these parts may be injured, especially when the typhoid slough is forcibly dislodged. If at the time of dislodgment of the slough these vessels have not been occluded by thrombosis, severe hemorrhages occur.

With gradual cleansing by resolution and absorption, the ulcer margins become relaxed and slightly overhanging (see Fig. 266, *r*); an *ulcus depuratum* thus develops which gradually cicatrizes —at about the end of the sixth week. Cicatrization does **not** produce any marked constriction of the intestinal lumen; the cicatrix itself is usually a small, white area between the slaty pigmented follicles.

The medullary swelling sometimes extends along the course of the vessels through the fibrous fascia and muscularis into the submucosa, where it spreads, accompanied by swelling of the peritoneum (see Fig. 267)—a proof that only the beginning, but not the extension, of the affection is connected with the follicles. In this case a circumscribed peritonitis always develops in the serosa. This heteroplastic medullary swelling is especially dreaded, because sloughing of the focus in the subserosa, *i.e.*, exfoliation into the abdominal cavity, results in **perforation of the intestine** and **general peritonitis. Intestinal perforation** may occur also when mortification and ulceration are complicated by gangrenous processes; less often when, in addition to typhoid ulcers, recidives

occur; also in consequence of improper nourishment, and, finally, as a result of accumulation of gas in the intestines. The last stage of perforation is always a rupture, which is produced by a mechanic process (exertion, blow).

According to the statistics of H. Curschmann, based on 577 necropsies, the location of the ulcers was as follows:—

Ileum	510	88.39 per cent.
Cecum (often involving appendix)	247	42.81 " "
Colon	184	31.89 " "
Jejunum	41	7.10 " "
Rectum	12	2.08 " "

Out of the total number perforation with consecutive peritonitis occurred in 13 per cent. Out of 64 cases the site of perforation was:—

Upper part of ileum	5
Lower part of ileum	39
Region of ileocecal valve	7
Appendix	1
Colon	11
Rectum	1

The stage of medullary swelling is not always followed by mortification and ulceration; indeed, resolution is more frequent. In many cases there is no ulceration: *typhus mitior.* In children, at the age of from 2 to 10 years, who have died of *typhus infantum,* ulceration is almost never found, only medullary swelling (see Fig. 268), and even in adults only a small proportion of the medullary-swollen follicles undergoes sphacelation; the remainder return to the *status quo ante,* ulceration being avoided by absorption.

Resolution is the more frequent the greater the distance from the ileocecal valve, and almost always in the mesenteric glands. In the mesenteric glands the medullary swelling, which resembles the swelling of the follicles, begins upon the intestinal—the convex—surface, where the glands receive the lymph from the intestine. The cortical portion is always first involved. (See Fig. 269.) When mortification occurs in the lymph-glands, the affected areas possess great resemblance to cheese, which condition in the intestine is obscured by imbibition with bile-coloring matters, etc. As a rule, only puncta of mortification occur in the lymph-glands. If, however, a large necrotic focus lies immediately beneath the surface, as exceptionally is the case, then, as in the intestine, rupture externally may take place after dissection, with the difference only that exfoliation into the abdominal cavity occurs, followed by peritonitis.

These processes in the intestine are always associated with high fever, but the latter has no constant relation to the stage and extent of the local affection. There is a certain transient connection only between the rise of the fever curve and the local eruption. In a few cases fever is entirely absent: *typhus ambulatorius*[1] (a typhoid in which the patients walk about: "walking typhoid"). Consequently, the whole affection should not be referred solely to the local process.

In addition to the intestinal alterations, changes are always found in other organs which indicate that the process is a severe general affection. The **spleen** is principally involved and is always very intensely swollen; the pulp-cells are increased in number and the follicles greatly enlarged. The spleen becomes markedly friable, is at first hyperemic, and later anemic, if the swelling increases greatly. Rupture of the spleen occurs more frequently than is clinicly recognized,[2] and probably, as in intestinal perforation, is caused by muscular effort.

In fatal cases the necropsy reveals parenchymatous inflammation (degeneration) of the myocardium, kidneys, liver, stomach, and, what is particularly characteristic of typhoid, of the skeletal musculature. This degeneration of the musculature is the cause of the quite frequent h e m a t o m a of the r e c t u s a b d o m i n i s m u s c l e. Furthermore, diffuse bronchitis is almost constantly present, and less often pneumonia, which occurs rather as a sequela. Follicular ulceration and diphtheritic processes are accidental complications. On the other hand, the alterations which occur at the margins of the epiglottis and the aryepiglottic ligament are wholly similar to the typhoid processes in the intestine. In these localities proliferation of the follicles and subsequent necrosis and ulceration occur —a process which is usually designated as a form of decubitus. Perichondritis laryngea profunda and diphtheritic processes in the pharynx, larynx, and bronchi are sometimes observed.

Acute hemorrhagic nephritis is a rare complication in t y p h o i d f e v e r. In some cases the onset of the disease is marked by this complication, the eruption occurring later.

There is a septicemic form of typhoid fever due to secondary action of the streptococcus: streptotyphoid infection. (Vincent.) The staphylococcus also has been observed in typhoid in cases characterized by rubeoliform, scarlatiniform, and polymorphous erythemata. Indeed, Senger asserts that relapses in typhoid fever are nothing more than septicemias. He claims that the intestinal alterations enable other germs than the typhoid bacillus to exert a pernicious influence, which is too often

[1] In some cases of "walking typhoid" the temperature is high (104° F.), and the process frequently pursues a severe course when the patient takes to bed.

[2] Bryan has collected 29 cases (*Ann. of Surg.*, Nov., 1909).

ascribed to a recrudescence of the primary disease. To say the least, this theory is in harmony with general pathologic data.

Endocarditis, usually of the mitral valve, is a rare complication which is somewhat more frequent before the fifteenth year than later. The condition may be associated with myo- or peri- carditis, and usually is due to strepto- and staphylo- cocci, rarely to the typhoid bacillus.

Eberth's bacillus has been found in spleen abscesses (typhoid), purulent pleuritis, pulmonary abscess, peritonitis, and osteomyelitis secondary to typhoid.

According to recent research,[1] abdominal typhus is wrongly considered to be a pathologic and anatomic entity. There are cases which clinicly and etiologicly are quite certainly typhoid, but with no anatomic lesions. This being the case, the anatomic lesions are not characteristic of typhoid. On the other hand, there are cases which clinicly resemble typhoid and show, in part, the anatomic lesions, but have no etiologic factors of the disease: *e.g.,* paratyphoid cases, the symptoms of which are identic with infection with the Eberth-Gaffky bacillus. It may be objected that the paratyphoid bacillus is merely a modified form of the typhoid bacillus; the cultural characteristics of this organism, however, are as distinct as those of the *Bacillus typhosus* or *coli.* Certain cases of meat poisoning are observed which are difficult to differentiate from typhoid. These show an organism similar to this group of paratyphoid (especially paratyphoid B), except in some agglutination differences. Inasmuch as the paratyphoid bacillus produces anatomic changes which belong partly to sepsis, partly to dysentery, and partly to typhoid, so also the organism causing meat poisoning may belong to the typhoid-colon group.

Many so-called colon diseases clinicly resemble paratyphoid and anatomicly dysentery, in which the organism found is the *Bacillus coli.* It would seem, therefore, that, while the Eberth-Gaffky bacillus is the most common etiologic factor, abdominal typhoid may be caused by numerous bacteria, namely, *Bacillus typhosus, Bacillus paratyphosus* A and B, and bacteria of meat poisoning, *i.e.,* colon group. Coccus infections, acute miliary tuberculosis, or the plague bacillus or one of the pyocyaneus group may cause symptoms closely resembling abdominal typhoid.

The portal of entry is in the gastrointestinal tract, probably also in the tonsils. If the latter hypothesis be assumed, the primary symptoms of typhoid, which are of a general nature, would be explained. According to Brion and Kayser, in the beginning of the disease the typhoid bacillus is found in the blood in 94 per cent. of the cases. It is, therefore, in a certain sense a septicemia. From the blood- and lymph- vessels the bacilli enter the organs and there produce the well-known foci, depositions, local inflammations, metastases, etc.: in the brain, lungs, serous membranes, and in the roseola spots of the skin. All organs may be involved, but especially the lymphatic apparatus, though, as already stated, involvement of Peyer's patches may be absent, particularly in children.

[1] Deutsches Arch. f. klin. Med., lxxxv, p. 552.

In the late stages the bacilli are difficult to find in the blood; they disappear gradually. They then almost always take up their abode in the gall-bladder, which they are said to enter through the liver.[1] Under certain conditions the process may persist in the gall-bladder for weeks, months, or even years, the bacilli be discharged with the bile into the intestine and appear in the dejecta ("bacilli-carriers").

By the designation "**Bacilli Carriers,**" is understood those individuals who, although usually manifesting no subjective or objective symptoms of disease, harbor typhoid bacilli in their intestine and gall-bladder (*cholecystitis typhosa*). As already stated, the micro-organisms may persist for many years and in some instances even for life. Dean reports a case of typhoid cholecystitis of twenty-nine years' duration. The bacilli may occur also within gall-stones.

Of 400 convalescents, Lentz found 13, or 3 per cent., became chronic carriers. Linger examined 1700 persons and found 15 carriers, varying in age from 18 months to 60 years; 11 had no clinic symptoms either before or after examination, and only 4 were found to be chronic carriers. Out of a further 482 cases examined during convalescence 11.4 per cent. became chronic carriers. Of 604 convalescents examined, Sacquepee found 80 temporary carriers (70, or 11.6 per cent., intestinal, and 10, or 1.7 per cent., urinary); 6, or 1 per cent., became chronic carriers. Urotropin cured all temporary carriers. Bruckner found 12 carriers out of 316 persons who had had typhoid some years previously. Semple and Greig found 10 patients out of 86, or 11.6 per cent., excreting bacilli in the urine or feces for periods longer than six weeks after defervescence. Aldridge found 6 out of 190 men, or 3.1 per cent., excreting the bacilli more than six months after defervescence.

In the United States there annually occur about 400,000 cases of typhoid fever, with a mortality of approximately 10 per cent.[2] About 1 in 20 after recovery become urinary or intestinal carriers.

By far the largest number of chronic carriers are females. Children appear to form a large proportion of transitory, but only a small proportion of chronic, carriers. Forster found that out of 173 chronic carriers who excreted bacilli for from one to thirty years after the primary attack 79 per cent. were women, 17 per cent. men, and 4 per cent. children.[3] This preponderance of female over male chronic carriers suggests an analogy to the relative gall-stone incidence in the female and male. The question as to whether gall-stones in some cases result from typhoid fever or whether the bacilli attach themselves to preformed stones is not yet settled.

It would seem that a preponderant number of contact infections take place during the early period of typhoid infection, that is, that the typhoid patient is most dangerous during the incubation period. Apart from gall-bladder trouble,

---

[1] According to Forster, typhoid bacilli are regularly excreted with the bile into the intestine in cases of typhoid. The bacilli which have reached the bile from the liver enter the gall-bladder and there multiply. Therefore, it is reasonable to assume that the biliary passages are the natural nidus of the typhoid bacillus in typhoid-bacilli carriers. From here they are constantly discharged and, according to their virulence and varying external conditions, continually find, through subsequent infection of healthy individuals, new foci of development and produce new germ carriers. The same holds good also in paratyphoid fever.

[2] Keefer, *loc. cit.*

[3] J. C. G. Ledingham, "Report to the Local Government Board on the Enteric Fever 'Carrier,'" Wyman & Sons, London, 1910.

the typhoid carrier apparently is little inconvenienced by his condition. In some cases periodic intestinal disturbances have been observed in carriers of the intermittent type.

As a rule, the serum of bacilli carriers produces agglutination of the specific bacilli in dilution of from 1 to 50 to 1 to 100. About from 2 to 4 per cent. of typhoid patients become bacilli carriers (Forster).

Leucopenia is the rule in uncomplicated typhoid. According to Leydhecker,[1] the average in 11 carriers was 6800; 6 had distinct leucopenia (average, 5806), and 5 showed higher values (average, 7752).

In the further course of the disease there appear in the body juices substances produced by bacterial irritation of the body cells (so-called agglutinating and specific bactericidal bodies). The following two phenomena are dependent upon the action of these specific substances:—

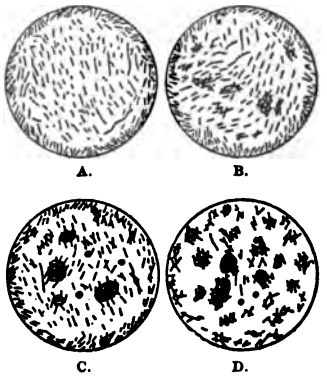

Fig. 270.—Stages in Widal reaction. (After *Robin.*)

Pfeiffer's reaction, bacteriolysis, the rapid disintegration of typhoid bacilli in the peritoneal cavity of a normal guinea-pig, when the bacilli are introduced with the serum of a typhoid-immune animal.

Agglutination Test, Gruber-Widal Reaction.—When the serum of a typhoid-immunized individual, a typhoid patient, or a typhoid convalescent is brought into contact with typhoid bacilli, the latter are rendered nonmotile and agglutinated. (See Fig. 270.) This agglutinative power of the serum may be retained for years and is manifested in very high dilutions.

Antityphoid Vaccination.—In the artificial production of typhoid antibodies, three injections of dead typhoid bacilli are given at intervals of ten days. The initial injection is 500,000,000 dead bacilli; the second and third injections are 1,000,000,000 each. The vaccine used by the United States Army is sterilized at 56° C., a small percentage of disin-

[1] Wien. klin. Rundschau, Jahrg. xxv, No. 25, p. 389.

fectant added to insure keeping, and then placed in sealed tubes. Usually within three to four hours after injection redness, swelling, soreness, some headache, backache, feverishness, and malaise develop. In 36,000 doses less than 1 per cent. showed serious reactions. In two-thirds no persistent reaction was observed. The reaction lasts for from four to forty hours.

In 1908 the British Army vaccinated about 6000 soldiers in India and maintained nearly an equal number of unvaccinated men under similar conditions. It was found that seven times as many nonvaccinated contracted typhoid fever and eleven times as many died. Moreover, all but four of the vaccinated men who contracted typhoid fever received but one dose, while these four had quite mild attacks. As many of the nonvaccinated died of the fever as were taken sick among the vaccinated individuals.[1]

Up to October 1, 1910, 13,000 officers and men in the United States Army had been vaccinated with no bad results in a single case.[2] Among these, but 5 cases of typhoid fever developed, of which 4 were so mild as to raise a doubt as to the correctness of the diagnosis. In the rest of the army there were 418 cases, whereas, assuming that the conditions were otherwise identic, there should have been, at this rate, 70 cases among the vaccinated men, or fourteen times as many as actually occurred.[3]

According to experiences in the British Army, protection from vaccination lasts for about from two to three years.

Paratyphoid Fever.

Paratyphoid fever, described by Schottmüller, is an affection clinicly and anatomicly resembling typhoid (*q.v.*), caused by bacilli similar to the typhoid bacillus—paratyphoid and metatyphoid bacilli—of which there are several species. The pathologicoanatomic changes in the lymphatic apparatus are not so characteristic, and the prognosis is more favorable than in genuine typhoid. Many cases of paratyphoid are nothing more than poisoning meat (*Bacillus enteritidis*). In dried feces, paratyphoid bacilli may retain their vitality for four years.

---

[1] According to Keefer, only 1 case in 143 has typhoid fever a second time.

[2] According to the *N. Y. State Jour. of Med.*, 1912, p. 2, in the report of the Surgeon-General to the Secretary of War, it is stated that since vaccination was inaugurated and up to July, 1911, 45,680 men had been vaccinated, with only 2 cases of typhoid and no deaths. The remainder of the troops who had not been vaccinated had a case incidence of from 0.28 to 3.03 per cent. In the Navy statistics, there were 2 deaths among 2752 vaccinated men.

[3] Keefer, The Military Surgeon, March, 1911, p. 290.

Colon Bacillus (Bacterium coli commune).

Colon bacilli are not a sharply defined species of bacteria, but rather a group of related bacilli, which may be contrasted with the typhoid group. Both groups of bacilli possess many biologic resemblances. The typic representative of the colon bacilli, the *Bacillus coli communis,* which occurs in the normal intestinal canal of man and animals, is morphologicly indistinguishable from the typhoid bacillus and also is Gram-negative. It is, however, somewhat less motile, owing to the small number (4 to 6, rarely 12) of flagella. In contradistinction to the typhoid bacillus the colon bacillus forms indol (red coloration of bouillon after addition of sodium nitrite and sulphuric acid), ferments grape-sugar (gas formation), coagulates milk, strongly acidulates litmus milk, and decolorizes and produces fluorescence in neutral-red nutrient media, none of which effects are produced by the typhoid bacillus.

When completely desiccated and protected from light, the *Bacillus coli* survives for at least ten days. Experiments seem to indicate[1] that direct sunlight and marked variations in temperature have a very harmful influence, while drying and exposure to diffuse sunlight have much less marked effects.

In many cases of terminal infection, this organism is recovered from the blood before death. Hartwich[2] reports a case of tuberculosis of the kidneys, spleen, liver, intestine, and brain in which the colon bacillus was found in the spinal fluid ten days before death.

Under certain conditions this bacillus manifests marked pathogenic action, which is exerted principally upon the peritoneum, the biliary passages, and urinary tract. It may enter the abdominal cavity through intestinal preforations or even pass through the uninjured wall of the intestine (*e.g.,* in incarcerated hernia, circulatory disturbances in the wall of the intestine from occlusion of the mesenteric vessels, etc.). In these cases it is rarely found in pure culture. It may enter the gall-bladder and bile-channels either from the intestine or the blood, and in conjunction with other bacteria (pyogenic cocci) cause cholangitis, cholecystitis, pyelophlebitis, and consecutive hepatic abscess.[3] In the formation of biliary calculi and appendicitis it plays an important rôle. It reaches the urinary apparatus usually from the genitalia, though infection may occur also through the blood; here it excites cystitis (with acid reaction of the urine), an ascending catarrh, and severe pyelonephritis. From the renal pelvis it enters the renal parenchyma and produces a diffuse

[1] Centralbl. f. Bakt., etc., Orig. Bd. lii, Heft 3, p. 326.
[2] Berlin. klin. Woch., May 1, 1911, p. 795.
[3] The colon bacillus may cause a true pyemia with metastatic abscesses.

suppurative nephritis. The micro-organism may be found also in bronchopneumonia, meningitis, and other inflammations.

General infection (coliemia) is comparatively rare in view of the great frequency of this micro-organism in local inflammatory processes. In 50 cases collected by L. Jacob,[1] the portal of entry is given as follows:—

Intestine	11
Bile channels	15
Urinary tract	13
Genitalia	9
Unknown	2

The bacillus enters the blood less frequently from the bladder than from the renal pelvis. It has been found also in traumatic infection, in angina and diphtheria, and in meningitis following otitis media in none of which, however, was general infection observed.

Purulent metastasis in general infection also is comparatively infrequent. In this respect the observations of Lenhartz and others give the following figures:—

In	55	cases	of	staphylococcus	sepsis,	metastases in	92.7 per cent.
"	160	"	"	streptococcus	"	" "	35.0 per cent.
"	20	"	"	pneumococcus	"	" "	25.0 per cent.
"	49	"	"	coli	"	" "	22.5 per cent.

The endocardium was most frequently affected (5 cases); then the liver and kidneys, lungs, meninges, and once the thyroid.

In comparison with staphylococcus and streptococcus sepsis, the prognosis is more favorable, as shown by the following table:—

Staphylococcus	infection		88.2 per cent. mortality
Streptococcus	"		83. per cent. "
Pneumococcus	"	(including pneumonia)	51.7 per cent. "
Coli	"		40.5 per cent. "

Bacterium Lactis Aërogenes.

The *Bacterium lactis aërogenes* (Escherich) resembles in many respects the *Bacterium coli commune*. It occurs in the form of short, quite thick, nonmotile, nonsporulating, Gram-negative bacilli, which not infrequently are united in pairs, presenting the appearance of a diplococcus. It is constantly present in the feces of infants and often in the stools of adults, and occasionally it manifests pathogenic properties. Heyse demonstrated it in a case of pneumaturia, and Lenhartz observed this bacterium in a protracted case of cystopyelitis occurring in the first months of pregnancy.

Shiga-Kruse Bacillus, Bacillus Dysenteriæ.

The *Bacillus dysenteriæ* has been constantly demonstrated in certain cases of dysentery by Shiga, Kruse, Flexner, and others. According to Shiga and Kruse, this bacterium is a plump, moderately motile, Gram-negative bacillus closely related to the typhoid bacillus and bacterium coli, with which it is morphologicly identic. This bacterium has been isolated also from the dejecta in summer diarrhea of infants.

[1] Deutsch. Arch. f. klin. Med., Bd. xcvii, p. 339.

Mediterranean, or **Malta, fever,** *febris undulans,* a febrile affection characterized chiefly by anemia, constipation, and rheumatoid pains, which frequently lead to the incorrect diagnosis of rheumatoid arthritis, was first observed in Malta and subsequently in other Mediterranean countries, China, India, Africa, West Indies, Brazil, United States, etc. It usually lasts for a protracted period (six months to two years), sometimes causes death, and is due to a diplococcus, the *Micrococcus melitensis* (Bruce, 1886). The specific micro-organism is found in the blood and spleen, lymphatic glands, and may be present also in the urine. Goats also are affected with this fever, and their milk and urine contain the micrococcus. The disease very probably is conveyed to man from these animals.[1] The fever is usually of a remittent type, runs a week or two, followed by several days of absolute or relative apyrexia, to again return.

Dengue, or Dandy Fever.

Dengue is an infectious contagious disease, of unknown etiology, closely related to the acute exanthemata, occurring principally in the warm regions of Europe, Asia, Africa, and America, and attacking all ages and both sexes. According to Scheube,[2] the period of incubation is most often from one to two days, frequently only a few hours. The prodromata are general malaise, dizziness, frequently yawning, gastric disturbances, etc. The disease generally begins suddenly with fever, usually of the remittent type, which at the acme may reach 42° C. or over and sometimes is preceded by chilliness, rarely by distinct chill. These symptoms are rapidly followed by violent cephalalgia, myalgia, arthralgia, boring pains in the bones (hence, **break-bone fever**), and a diffuse erythematous exanthem (initial exanthem) of brief duration (one to twenty-four hours) distributed over a greater or lesser area of the body, most marked upon the face, where it may be macular. The skin is dry, the face and eyelids swollen, the conjunctivæ congested. Photophobia and lachrymation and increase of nasal secretion also are present. Prostration is sometimes marked. Certain portions of the body may be more or less hyperesthetic or anesthetic, and delirium, maniacal paroxysms, and, in children, convulsions are not uncommon. The liver is enlarged, but not the spleen. Albuminuria is rare. Immediately or several days after convalescence from the first stage of the disease, which usually lasts about three days, a second exanthem (terminal exanthem) appears, principally upon the face, hands, arms, and chest, which, according to Scheube, may present manifold characters, resembling the eruption of

[1] The milk of infected cows also conveys the infection.

[2] "Die Krankheiten der Warmen Länder," 4te Auf. Jena, G. Fischer, 1910, p. 425.

measles, scarlatina, or urticaria, or occur in the form of lichen, roseola, petechiæ, vesicles, blebs, or pustules. The glands of the neck, axillæ, and groin are sometimes swollen and painful. The duration of the exanthem is from several hours to two or three days.

Complications are pneumonitis, pleuritis, pericarditis, parotitis, orchitis, various affections of the eye, and rarely hemorrhages from the nose, stomach, bowels, bladder, etc.

The termination of the disease is usually favorable, except in small children, the aged, and in subjects suffering from severe chronic affections.

Convalescence is often protracted.

According to Scheube, the disease is conveyed by infected as well as by healthy individuals, and also by fomites.

Influenza, La Grippe.

Since 1892 the influenza bacillus, discovered by Pfeiffer, has been accepted as the pathogenic micro-organism of influenza. It is a short rod, with rounded ends, which grows best upon blood-agar at the body temperature. (See Plate VII, Fig. 4.)

Influenza, or *la grippe,* is an epidemic infectious disease which usually begins with very violent symptoms. In vigorous individuals it generally runs a benign course and assumes a fatal type only in those subjects whose resistance has already been reduced by other affections or advanced age. When death occurs early, often very little is found at the necropsy. Indeed, aside from cloudy swelling, only viscid-mucoid, less often mucopurulent inflammation of the air passages and numerous minute bronchopneumonic foci, which manifest a marked disposition to suppuration, are observed.

Influenza is characterized by epithelial desquamation and submucous edema; clinicly by sudden onset of fever, malaise, mental depression, profuse perspiration, and usually great prostration. With recurrent attacks the virulence diminishes. The duration of the purulent secretion, the slight tendency to recovery, the rise of temperature after slight bodily exertion are then characteristic. In a certain group of cases the attack begins with swelling of the tonsils and pharyngeal follicles; while this soon subsides, the nose, accessory sinuses, and bronchi are involved. An abundant purulent discharge from the nose, violent cough with mucopurulent expectoration, and bronchial râles appear. In the nose there is edematous swelling of the middle turbinate. The protracted duration of the affection, the marked prostration and perspiration often arouse the suspicion of tuberculosis.

Very severe secondary diseases of other organs, which often end in death even in young and vigorous individuals, quite frequently follow influenza. (See Otitis Media.)

Various forms of dermatitis and eruptions may occur in association

PLATE VII

Fig. 1.—Gonococcus in urethral discharge; Loeffler's stain. *a*, [illegible] groups; *c*, the same inclosed in cells. Leitz, 1: oil immersion. [illegible] (After Lenhartz-Brooks.)

Fig. 2.—*a*, streptococcus and *b*, staphylococcus in pus. Methylene blue stain. Leitz, 1: oil immersion, $\frac{1}{12}$. (After Lenhartz-Brooks.)

Fig. 3.—Cholera bacilli; mucous rake preparation. Carbol fuchsin stain × 800. (After C. Fraenkel.)

Fig. 4.—Influenza bacilli; sputum preparation. Dilute carbol-fuchsin stain. Bacilli mostly with thickened ends, chiefly inclosed in cells. Leitz, 1: oil immersion, $\frac{1}{12}$. (After Lenhartz-Brooks.)

Fig. 5.—Diphtheria bacilli; preparation from tonsillar deposit; Loeffler's stain × 800. (After Lenhartz-Brooks.)

Fig. 6.—Pneumococci; sputum preparation. Wolf's double stain. *a*, isolated cocci, *b*, in chain form. Leitz, 1: oil immersion, $\frac{1}{12}$. (After Lenhartz-Brooks.)

PLATE VII

Fig. 1.—Gonococcus in urethral discharge; Loeffler's stain. *a*, free cocci in groups; *b*, the same inclosed in cells. Leitz, I; oil immersion, 1/12. (After *Lenhartz-Brooks.*)

Fig. 2.—*a*, streptococcus and, *b*, staphylococcus in pus. Methylene-blue stain. Leitz, I; oil immersion, 1/12. (After *Lenhartz-Brooks.*)

Fig. 3.—Cholera bacilli; mucous flake preparation. Carbol-fuchsin stain. × 800. (After *C. Fraenkel.*)

Fig. 4.—Influenza bacilli; sputum preparation. Dilute carbol-fuchsin stain. Bacilli mostly with thickened ends, chiefly inclosed in cells. Leitz, I; oil immersion, 1/12. (After *Lenhartz-Brooks.*)

Fig. 5.—Diphtheria bacilli; preparation from tonsillar deposit; Loeffler's stain. × 800. (After *Lenhartz-Brooks.*)

Fig. 6.—Pneumococci; sputum preparation. Wolf's double stain. *a*, isolated cocci; *b*, in chain form. Leitz, I; oil immersion, 1/12. (After *Lenhartz-Brooks.*)

PLATE VII

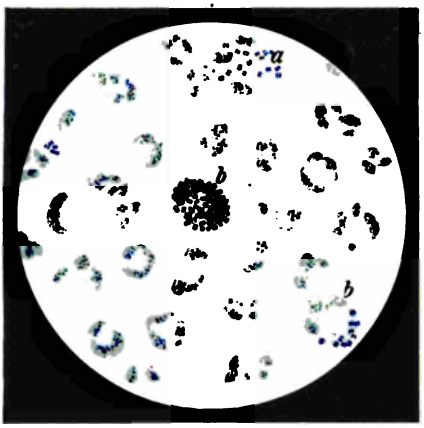

Fig. 1

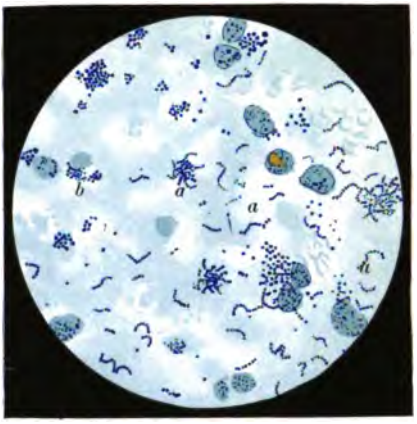

Fig. 2

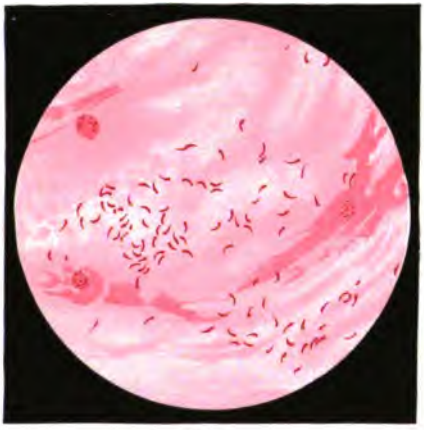

Fig. 3

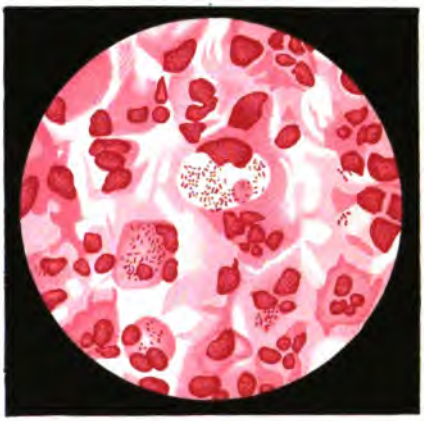

Fig. 4

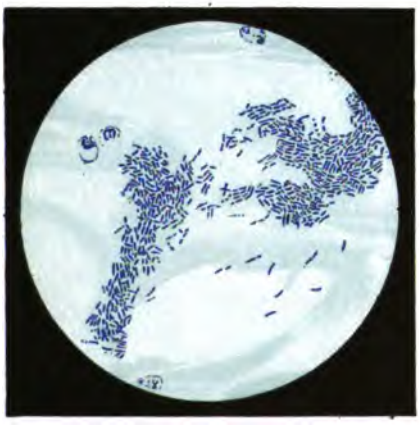

Fig. 5

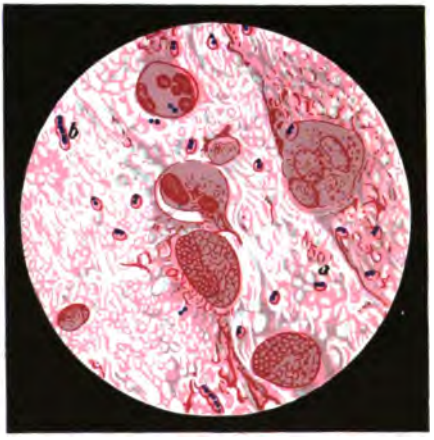

Fig. 6

with influenza, *e.g.*, morbilliform, scarlatiniform, and erysipelatous eruptions; urticarial, papular, and polymorphous erythema; hemorrhagic purpura, herpes, pemphigus, suppurative and serous dermatitis, pigmentary changes, etc.

The Diphtheritic Processes.

Diphtheritic processes[1] occur upon almost all mucous membranes and upon wound surfaces. They present certain peculiarities according to their location and the anatomic arrangement of the surface involved, but they everywhere correspond in their essential features.

Diphtheria is a superficial mortifying process which always ends in ulceration by separation of the dead tissues in the form of a true membrane. It is produced by the entrance of micro-organisms (Löffler's diphtheria bacillus and others) into the superficial tissue layers, which become necrotic as the result of the local multiplication and spread of these microbes. The whole mortified area is exfoliated by a demarkating and dissecting inflammation of the subjacent tissues and produces the diphtheritic membrane (*inflammatio membranacea*). An outward loss of substance, an ulceration with quite regular, smooth base, is thus caused. This usually involves only the mucosa—not the submucosa—and therefore is a superficial ulcer: *ulcus superficialis.* The action of the micro-organisms is further expressed by the development of intense catarrhal or fibrinous exudative inflammation in the neighborhood of the true diphtheritic area. In this connection it should be emphasized that catarrhal states provide an especial disposition to diphtheritic infection. It is, therefore, necessary to distinguish between a primary catarrh and such as develops as a result of, and increases with, diphtheria.

Since fibrin has been recognized as the essential constituent of the diphtheritic membrane, there can be little doubt that it originates from the serous constituents

[1] In this section only the mortifying and not the exudative fibrinous processes will be discussed. Formerly it was customary not to separate the mortifying processes from the exudative fibrinous processes, but, following the precedent of Bretonneau, to class them both as diphtheria. Bretonneau, in 1821, described as diphtheria an epidemic disease observed by him, characterized by the formation of skin-like membranes upon the mucous membranes of the throat and air passages and which usually caused death by suffocation. The same affection was designated by Aretæus as *ulcera syriaca.* According as affection of the throat or air passages predominated, the condition was sometimes called *angina maligna, gangrænosa, scorbutica,* sometimes croup, *morbus suffocatorius,* Garotillo. Bretonneau first recognized the identity of these various clinic forms, the common feature in which was the presence of membranes upon mucous surfaces. Trousseau completed the clinic description and added the designation malignant diphtheria, corresponding to the septic form of present-day writers. He regarded diphtheria as a general infection with pronounced local changes. Although modern research supports Bretonneau's view as to the local nature of the affection, the name diphtheria, chosen by Trousseau, is today in general use.

transuding from the vessels. This abundant transudation of fibrinoplastic substances is one of the specific effects of the diphtheria bacillus, which, as the result of necrotization of the superficial layers, enters the epithelium. The formation of the exudate begins upon the mucous membrane of the pharynx beneath the superficial layers. With continuation of the exudation the deeper layers also are elevated, so that the membranes may attain a thickness of several millimeters. They then consist of lamellated masses of fibrin inclosing partly hyaline degenerated, partly still preserved epithelium as well as numerous round cells, especially in the advanced stages. According to Goldmann and Middledorf, the membranes upon the tracheal mucosa originate in a similar manner. The membrane is sharply demarkated externally by the basal membrane and progresses into the excretory ducts of the glands and lymph-spaces. Fibrin coagula are found also in the adjacent connective tissue and in the neighboring lymph-glands. Necrotic processes are confined essentially to the epithelium, and isolated foci are observed in the connective tissue. In opposition to the authors mentioned, Oertel assumes that most of the membranes originate directly from the contents of necrobiotic foci situated in the connective tissue beneath the submucosa, which elevate the epithelium, rupture and discharge upon the surface of the mucous membrane (secondary membrane).

Fig. 271.—Transverse section of colon.

The description of the clinic conditions and the lack of exact bacteriologic statements render it not improbable that Oertel's description of the mode of origin of the membranes forming in septic diphtheria complicated with streptococcic invasion is appropriate, and that the deep necrobiotic foci are due not so much to general diphtheritic intoxication as to entrance of streptococci.

Gangrenous processes (gangrenous form of diphtheria) are sometimes associated with diphtheria, extensive putrid decompositions developing beneath the diphtheritic infiltration or upon the base of the ulcer. When these are accompanied by hemorrhagic states, the color may be very markedly and variously influenced. These secondary hemorrhagic states should not, however, be confounded with the primary, which, in many localities, especially in the colon and bladder, precede the true diphtheritic affection and, as it were, prepare the soil for it.

In all cases the neighboring lymphatic glands are swollen, hyperemic, intensely edematous, and sometimes phlegmonous.

Diphtheria always begins upon prominent parts: in the pharynx, especially upon the tonsils, uvula, and the follicles of the tongue, etc.; in the small intestine, upon the surface of the rugæ (*valvulæ conniventes Kerkringii*); in the colon, upon the crest of the folds produced by the strong muscular layers, the *tæniæ* (see Fig. 271), and the *plicæ sigmoides*,

PLATE VIII

Case A.—Common type of diphtheria. Child 3 years old. Seen on fourth day of illness. Exudate covering tonsils, pharynx, and uvula. (After *Fischer.*)

Case B.—Follicular type of diphtheria. Child 7 years old. Seen on second day of illness. The membrane involved the lacunæ of the tonsils. Note the close resemblance to follicular tonsillitis. (After *Fischer.*)

Case C.—Hemorrhagic type of diphtheria. Child 7½ years old. Seen on sixth day of illness. Tonsillar and postpharyngeal exudate. Severe nasal and postpharyngeal hemorrhages during exfoliation of membrane. (After *Fischer.*)

Case D.—Septic type of diphtheria. Child 8 years old. Seen on the fifth day of illness. The pseudomembrane in this case covered the hard palate and extended in one large mass down the pharynx, completely hiding the tonsils. (After *Fischer.*)

PLATE VIII

A

B

C

D

which form the sacculi (haustra). Especial points of predilection are the uppermost and lowermost segments of the digestive canal, namely, the pharynx and the rectum. Diphtheria frequently attacks also the larynx, trachea and bronchi, and the female genital tract, chiefly during the puerperium; next the conjunctiva (*q.v.*), the bladder; less frequently the ileum; more rarely the gall-bladder, esophagus, etc. Hospital gangrene—diphtheria of wounds—is, owing to antisepsis, at present extremely rare. (See p. 572.)

In the **pharynx** it is customary to distinguish an idiopathic and a symptomatic form. The former is the dreaded, independent, contagious, frequently epidemic and in many cities endemic affection which, owing to the constant occurrence of follicular swelling, is called angina, or *pharyngitis tonsillaris sive follicularis diphtheritica*, or, tersely, diphtheritis[1] (*angina membranacea maligna*, membranous croup). It occurs principally in children from 2 to 5 years of age, among whom in certain localities almost half the total mortality



Fig. 272.

Fig. 273.

is due to diphtheria and croup. This pharyngitis, like soor (thrush), begins with aphthous eruptions—small, cloudy, gray or yellowish-gray spots, which, however, are not, like the fibrinous masses in fibrinous pharyngitis (see Fig. 272, *a*), located upon the mucosa, but in the latter (see Fig. 272, *b*), and, therefore, cannot be wiped off. These small foci usually rapidly increase in size and become confluent. With further extension, the process does not advance to the oral cavity, but spreads to the larynx, trachea, bronchi, and nose, involving also the uvula. Owing to its thick and dense epithelial covering, the esophagus is very seldom involved. On the other hand, the *aditus ad laryngem* or the larynx itself is quite frequently invaded. Here, however, the accompanying fibrinous laryngitis predominates, a secondary fibrinous inflammation developing almost everywhere except in the neighborhood of the vocal cords, which are not, however, exempt from the diphtheritic process.

Among the **complications** the most common are bronchitis and pneumonia and tracheal and bronchial diphtheria. The latter frequently persists after exfoliation of the membrane and is especially dangerous in small children. Small lobular pneumonic foci usually are observed in the posterior and lower portions of the lungs.

[1] Diphtheritis, in a strict sense, always means the diphtheritic process in the pharynx: *pharyngitis diphtheritica*, due to the pressure of the Klebs-Löffler bacillus or its toxins.

The symptomatic form of diphtheritis progresses anatomicly the same as the idiopathic, and differs only in so far as it occurs as a symptom of other diseases. To the latter belongs, first of all, *diphtheria scarlatinosa,* which often appears in scarlatina epidemics as the sole symptom of scarlatinal infection; furthermore, variolar diphtheria, especially in fatal cases of small-pox, usually as a *causa mortis,* and, finally, metastatic diphtheria, which sometimes occurs suddenly when wounds assume a malignant nature.

Fig. 274.— Croupous enteritis, diphtheritic colitis, ⅔ natural size. (*Langerhans.*)

Diphtheritic pharyngitis is not infrequently followed by paralyses, which sometimes assume a very serious character. These paralyses usually develop very gradually, steadily increase, and generally disappear after a time. The process is an affection of the peripheral nerves.

Diphtheria of the rectum: *colitis diphtheritica,* likewise occurs idiopathicly and symptomaticly. The idiopathic form usually occurs epidemicly as an acute infectious disease, and is designated as dysentery.[1] This affection begins as a violent catarrhal inflammation of the rectum and sigmoid flexure, and may be confined to these parts. In severe cases, however, it generally involves a large portion of the colon or extends throughout its whole length. It is distinguished from other forms of colitis by the occurrence of hemorrhagic infiltrations upon the surface of elevated parts (upon the tæniæ, etc.), and also by the fact that the process is always complicated with ulceration. The ulcers may develop from diphtheritic foci within the hemorrhagic infiltrated parts or from follicular abscesses. Accordingly, diphtheritic and catarrhal dysenteries are differentiated. Sometimes both forms of ulceration—diphtheritic and follicular—coexist.

The diphtheritic ulcers are situated in the mucosa, are flat,

[1] Dysentery is a clinic designation, based upon the sum of two clinic symptoms: namely, tenesmus and diarrhea.

and have a broad opening (see Fig. 273, *a*); the others extend deep into the submucosa and have only a small, narrow opening, and are sinuous (see Fig. 273, *b*). As the diphtheritic process is first and principally confined to elevated parts, the colon acquires a certain resemblance to maps of mountain ranges. (See Figs. 274 and 275.) In very severe acute and in chronic cases the diphtheritic process first extends over a large portion of the surface, sometimes over the whole mucosa, and subsequently invades even the deeper parts down to the submucosa.

The follicular ulcers usually appear collapsed; if water is poured upon the narrow ulcer opening, the whole ulcer is distended. It is not uncommon in dysentery, especially in chronic cases, for adjacent follicular ulcers to become confluent by undermining of the edges in the region of the submucosa, a kind of passage being thus produced beneath the mucosa, the latter forming bridges. In some instances this may be

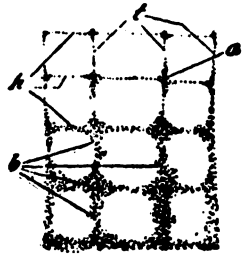

Fig. 275.—Colon laid open. *t*, tæniæ; *h*, plicæ sigmoides; *a*, small diphtheritic foci (beginning diphtheria); *b*, confluent diphtheritic surfaces which resemble a map of a mountainous country. (After *Langerhans.*)

so extensive as to separate the mucosa over a considerable area from its base, and occasionally to cause large portions of mucous membrane to be exfoliated.

The ulcerations usually terminate in healing; consequently, in chronic cases cicatrization as well as ulcerations are observed. Cicatrization is always accompanied by retraction, which may cause very dangerous stenoses, especially in the sigmoid flexure. The ulcers sometimes assume a more permanent character, while the intervening mucosa returns to the normal state. The diarrhea then ceases, but the ulcers still secrete purulent material.

The diarrheal discharges consist chiefly of richly albuminous, watery fluids which are sometimes mixed with mucoid and sometimes with fibrinous masses. Cells, especially pus-corpuscles, are always present in the stools, and, though few in number, they are more numerous than in any other affection of the colon.

Dysentery is distinguished as red and white according as the stools are mixed with blood or not.

A symptomatic form of diphtheria of the colon is observed in poisoning with mercury (see Poisoning, p. 326); also in Asiatic cholera (sometimes extends throughout the whole digestive tract), and in severe septic infections.

The pathogenic micro-organisms found in the diphtheritic process are not always the same; the streptococcus pyogenes and pneumococcus also may cause pseudomembranous fibrinous inflammation. The patho-

Fig. 276.—Bacillus diphtheriæ. × 1000. (Drawing by *E. L. Oatman, M.D.*)

genic microbe of diphtheria in a strict sense is a slightly curved, nonmotile, facultative anaërobic bacillus (*Bacillus diphtheriæ*) discovered by Klebs (1883) and accurately studied by Löffler.[1] It is about the same length, but twice as thick, as the tubercle bacillus, and the ends are very frequently markedly clubbed. Spores are not known. (See Fig. 276.) The bacilli do not stain by Gram's method, are very resistant to drying, and invariably die at 50° C. (122° F.). The bacilli may inhabit the healthy pharynx.[2] The diphtheria bacillus is almost constantly present in large numbers upon the mucosæ and in the pseudomembranes of diph-

[1] Mitt. a. d. Kaiserl. Gesundheitsamt, Bd. ii; Deutsch. med. Woch., 1890, Nos. 5 and 6.

[2] Diphtheria bacilli carriers are not uncommon and are found at all ages and in both sexes. The virulence of the bacilli is retained (in the ear, nose, and throat)

theria patients and generally remains confined to the affected area. By way of the blood- and lymph- vessels it may enter the internal organs, where it is said to be rapidly destroyed. Escherich cultivated it from the kidneys at necropsy, and Fresch demonstrated it in the brain, liver, spleen, kidneys, heart blood, pericardial and pleural fluids. The secretions and membranes from an infected case can directly give rise to new infections when transmitted (by kissing, coughing, etc.) to the mucous membranes of susceptible individuals, or it may indirectly be conveyed by fomites, upon which the virulence may be retained for months or even years. Lastly, virulent bacilli may remain in the mouth for days and weeks after subsidence of the malady, and they frequently have been demonstrated in the pharynx of apparently healthy subjects.

Löffler's assumption that the multiplication of the bacteria at the point of infection is accompanied by the development of a toxin which is profoundly injurious to the body has been universally confirmed. A further danger from the activity of the bacilli is the epithelial necrosis produced by them, which opens the way for the entrance of other bacteria, especially streptococci. (See p. 524.) The diphtheria toxin exerts a marked action upon the vessels, which are dilated; upon the heart, liver, nervous system, and kidneys (albuminuria). Motor paralyses usually occur only after subsidence of the acute intoxication.

There are at present only very few observations upon the cause of dysentery. The affection is attributed partly to bacteria (diphtheria bacilli), partly to animal micro-organisms. (See *Amœba coli dysenteriæ*.) As regards the symptomatic form, it is assumed that the primary injurious factor is not introduced from without, but is conveyed to the locality with the blood.

Vincent's Angina.

Vincent's, or **spirochetobacillary, angina, Plaut-Bernheim ulcer** (*angina diphtheroides s. ulceromembranacea*), to which attention was almost synchronously directed by Vincent and Bernheim in 1898, was fully described clinicly and bacteriologicly by Plaut in 1894. The process is usually a benign, pseudomembranous, necrotizing inflammation of the throat accompanied by subfebrile movement and mild local glandular involvement. The slough separates slowly and may take from ten to fourteen days or longer. It is most frequently observed in young subjects between the age of 3 and 10 years, though it occurs also later in life. It is observed in two forms: 1. One tonsil presents a gray-white, ulcero-

for from four to eight months. As the *Bacillus diphtheriæ* is essentially a human parasite (transference from animal to human is rare), the control of diphtheria depends upon control of the carrier. Milk, water, eating utensils, etc., contaminated by infected individuals may serve as media of conveyance. Diphtheroid affections of the mucous membranes are not infrequently observed in domestic animals; these processes, however, are produced by other micro-organisms.

membranous, rarely a diphtheroid, fibrinous, deposit, on dislodgment of which only a slight, necrotic wound surface remains. 2. In the more frequent ulcerative form the membranous deposit is more gray and thin, soon disappears, and leaves a necrotic ulcer several millimeters in depth. In the great majority of cases the process is unilateral, but it may affect both tonsils and extend to the palate, uvula, and pharynx, causing much destruction. Occasionally it is attended by marked glandular swelling (sublingual and submaxillary adenitis) which may result in abscess. In rare cases albuminuria, a polymorphous exanthema, arthritic effusion, suppurative bronchopneumonia, and pleuritis may occur, which may terminate in death from toxic absorption. These probably are secondary affections favored by the ulceration.

The etiologic factor is regarded as a large fusiform bacillus (*Bacillus fusiformis*) which, in the majority of cases, is associated with long, slender spirochætæ. (See p. 572.) The bacilli are observed in the fibrinous deposit and sometimes also in the depth, especially in the ulcerative form of the process; while the spirochætæ are found chiefly superficially. In the early stage of the affection both micro-organisms occur pure; later they are mixed with other bacteria, principally micrococci.

Leprosy.

The pathogenic micro-organism of leprosy is assumed to be the lepra bacillus (Hansen-Neisser, 1879). It is a delicate, slender rod, greatly resembling the tubercle bacillus, but is distinguished from the latter by its constant occurrence in the diseased tissues in large, often massed collections. It stains with Gram and in fresh tissues with the ordinary aniline dyes, especially fuchsin and gentian violet; in preserved tissues it is often difficult to stain except by methods employed to stain the tubercle bacillus. The bacilli are located partly within, partly outside, the cells. Pure cultures have recently been obtained.[1]

Leprosy is a disease which, in great part, has disappeared from Europe. It is still of frequent occurrence in Norway and southern Russia, rarer in southern Spain, Italy, Turkey, and in certain parts of the United States. It is very prevalent in South America, south Africa, Australia, and Asia, especially in India, China, and Japan. While it is still doubtful whether it is transmitted directly from man to man, it is certain that it can be introduced by man into previously free districts. Sanders[2] and Long[3] suggest insects and vermin (fleas, lice, bedbugs) as modes of infection. It most frequently begins from the 20th to the 30th year.

[1] Philip, Jour. of Sci., sec. B, No. 6, p. 403.
[2] Brit. Med. Jour., Sept. 2, 1911, p. 469.
[3] *Ibidem*, p. 470.

Two forms are distinguished: a **tuberous** and an **anesthetic** form.

In tuberous leprosy (*lepra tuberosa*) nodules develop in the skin and partly also in the subcutis, especially upon the unprotected portions of the body, most frequently upon the face and hands. The disease begins with macular hyperemia and swelling. The swollen and reddened areas may disappear temporarily, then recur and remain stationary, become more strongly swollen, and, growing harder and redder, finally attain the form of nodules the size of a hazelnut or walnut.

After a time the redness and tension of the skin subside, and a brownish or dirty-yellow pigmentation appears. The consistency becomes lax and flabby, sometimes almost fluctuating. The sweat and sebaceous glands atrophy and the hairs fall out (with exception of the hairs of the head: eyebrows, beard, etc.). The nodules are seldom isolated. They are usually arranged in groups, partly in contact, partly separated by small interspaces. They originate by proliferation, forming a very richly cellular granulation tissue, which extends to the unaltered epidermis and deep into the subcutis in the form of trabeculæ and bands. The most intense development occurs in the neighborhood of the hairs and the vessels. The tissue lying between the bands is either unaltered or the seat of simple proliferation. The proliferated cells are partly round, lymphoid, partly stellate, and spindle-formed, and contain the above-mentioned bacteria.

These nodules manifest no disposition to undergo softening and disintegration, and ulcerate only under especially unfavorable external influences. *Ulcus leprosum* forms dry, dirty scabs. In contradistinction to lupus and syphilitic alterations, the nodules are generally quite persistent. The above-mentioned laxity and flabbiness of the nodules which gradually develop is due to partial fatty metamorphosis and resolution. Complete resolution never occurs; on the contrary, as leprosy has a progressive character, new nodules usually develop in the neighborhood.

In *lepra maculosa*—the milder form—the peculiar tubercular formation is absent. A dark-brown pigmentation of the rete Malpighii develops (*morphœa nigra*) when the hyperemic swelling has subsided and the skin has become somewhat denser, or a scar-like condition associated with anesthesia, atrophy, indentation, and condensation occurs in the skin: *morphœa alba*. This process generally advances peripherally. *Morphœa alba* often develops directly into *lepra anæsthetica*.

In leprosy of the mucous membranes (eyes, nose, mouth, pharynx, larynx) nodules develop which are quite similar to those observed in the skin, but which are distinguished from the latter by their tendency to ulceration. In consequence of this, perforation of the cornea, to

which the process frequently extends, occurs, and also prolapse of the iris, staphyloma, etc. In the nose the ulcerations generally extend to the bone, and in the tongue to the musculature. In healing, dense, hard cicatrices and marked stenoses develop.

Lepra anæsthetica is a leprous affection of the nerves. Generally, spindle-shaped swellings develop as the result of the proliferations. Sometimes, however, the process progresses also in the form of a chronic inflammation: *perineuritis chronica leprosa.* The anesthetic form begins with hyperesthesia; then anesthesia gradually develops. In the swollen portions of the nerves proliferations are observed, which correspond to the proliferations in the skin, and take their origin from the interstitial tissue of the nerves (perineurium); an alteration of the nerve-sheath—the neurilemma—is also frequently observed. The proliferation is usually followed by fatty metamorphosis of the granulation cells and atrophy of the primitive nerve-fibers.

Bullous exanthemata often occur as *sequelæ* of *lepra anæsthetica. Pemphigus leprosus* develops: vesicles as large as a hen's egg, which often develop rapidly, burst and usually leave an ulcerating surface. These produce new irritations which cause condensation and retraction of the skin. The skin atrophies; beneath it the adipose and muscle tissue, the sebaceous and sweat glands, and even the bones atrophy. The skin becomes smooth, glistening, dry, and brittle. Later, purulent and necrotic inflammations supervene, which may extend deeply and cause necrosis and separation of bone. In this manner individual phalanges and even the greater part of the hands and feet may be destroyed. These extensive destructions generally heal by good cicatrization, since they proceed not from true leprous tissue, but from secondary inflammations, and in their nature closely approach the so-called neuroparalytic inflammation following anesthesia.

Leprosy is generally confined to the regions described and but seldom extends to the internal organs. According to accumulated experience, other parts most frequently affected are the spinal cord; rarely the joints, muscles, testes, etc. Swelling of the neighboring glands is always present, although this is sometimes very slight.

Fibrinous Pneumonia, Lobar Pneumonitis.

Fibrinous pneumonia is an acute, infectious endemic, and occasionally epidemic, disease frequently beginning with a chill. (See p. 541.)

Probably several micro-organisms are pathogenic factors in this disease, especially the *Diplococcus lanceolatus* (Fraenkel-Weichselbaum)

and *Friedlaender's pneumobacillus.*[1] The former is of chief importance, since it is found in about 90 per cent. and over of all cases of fibrinous pleuropneumonia. This diplococcus has a lancet-shaped form (for this reason it is regarded also as a short bacillus) and almost always occurs in pairs. The segments of the pairs are not absolutely round, but somewhat elongated, the distal ends frequently being pointed; occasionally, however, the pointed ends are in apposition, while the free ends are rounded. This coccus is subject to various changes in morphology, especially when grown upon solid media, and sometimes it forms chains. In the sputum or in the blood of infected

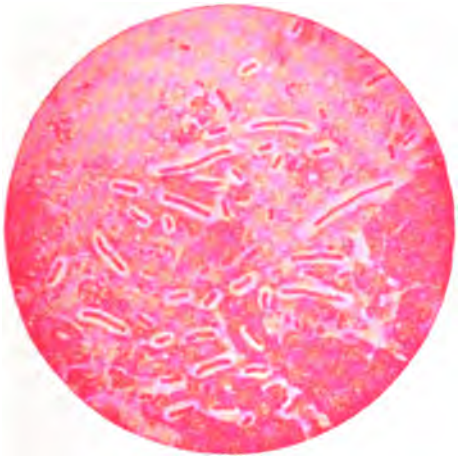

Fig. 277.—Friedlaender's pneumobacillus in pneumonic sputum. × 1000. (After *Fraenkel and Pfeiffer.*)

animals, it is surrounded by a distinct oval capsule which is slightly pointed at the ends. This capsule is rarely absent under these circumstances, but is very seldom seen in artificial cultures except in liquid media (milk or Löffler's serum). Guarnieri, by the use of a special nutrient medium, and Schmidt, by the use of sterile pneumonic sputum,

[1] The **bacillus of Friedlaender** (see Fig. 277) does not play a very important rôle in either local or general infections. As a local excitant it is observed in affections of the lungs (pneumonia), nose, mouth, pharynx, middle ear, intestinal canal, urogenital tract, and, under certain conditions, also in the liver and biliary passages. In all these localities it occasionally excites suppurative inflammations which in rare instances may result in general septic infection, and the bacillus may then be demonstrated in the blood. A hemorrhagic form of sepsis is extremely rare. As in other forms of sepsis, metastases occur in about one-third of the cases. The metastases have most frequently been observed in the liver, kidneys, and meninges, but they have been found also in the joints, ear, and muscles. Recovery from Friedlaender's sepsis may occur (Rolly, *Münch. med. Woch.*, Jan. 3, 1911, p. 19). Apparently, Friedlaender's bacillus may in rare instances cause septic endocarditis.

obtained growths with capsules.[1] (See Fig. 278.) This organism was first observed by Pasteur and Sternberg, in 1881, in large numbers in the blood of rabbits inoculated with human sputum, and described by them as the coccus of "sputum septicemia." A. Fraenkel subsequently (1886) discovered it in the rusty sputum of fibrinous pneumonia; also in a number of cases of empyema, and in the pial exudate in a case of meningitis following pneumonia. Fraenkel's observations were confirmed by Weichselbaum[2] and Netter. The *Diplococcus lanceolatus* is a nonmotile facultative

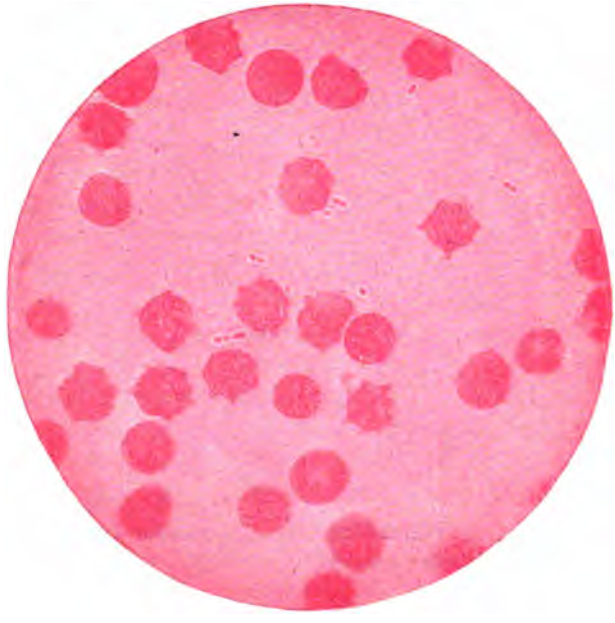

Fig. 278.—Diplococcus pneumoniæ in the heart's blood of a rabbit. × 1000. (After *Fraenkel and Pfeiffer.*)

anaërobe, grows between 24° and 42° C. (therefore not at room temperature), best at 37° C., upon a faintly alkaline nutrient medium. Pure cultures invariably die in a few days. Within the lungs the *Diplococcus lanceolatus* is found almost exclusively in the pneumonic exudate. Fraenkel's diplococcus is found in every expectoration without affection of the nose, mouth, and bronchi necessarily being present. It may, therefore, be assumed that through some cause or other the

[1] According to Hiss, capsules can be demonstrated in cultures grown upon nearly all nutrient media if beef or rabbit serum is used in making the spreads for staining.

[2] Hence called also diplococcus of Fraenkel-Weichselbaum.

bacteria wander toward the lungs and there excite inflammation, or else they reach these parts from other organs.

Aside from its etiologic rôle in acute lobar pneumonia, the pneumococcus also enters the pleural cavity and blood, and often is found in various inflammations: peritonitis, meningitis, otitis, pericarditis, endocarditis, conjunctivitis, corneal ulcer, arthritis (hip, ankle, elbow, clavicle), etc. Little is known of the specific toxin of this coccus. Efforts to obtain active soluble toxins have not been very successful. The essential pneumotoxin is of endocellular type (endotoxin).

Among the **predisposing causes** of pneumonitis the influence of variations in temperature is of primary importance. The frequency of the affection in the first and second quarters of the year and its relative rarity in the third quarter are well shown by the following table after Rolly and Blumstein[1] based on analysis of 1048 cases:—

Year	Jan.	Feb.	Mch.	Apr.	May	June	July	Aug.	Sept.	Oct.	Nov.	Dec.
1905	24	15	22	19	16	16	6	9	12	9	13	5
1906	13	16	24	37	23	19	8	7	5	8	17	18
1907	40	25	23	25	27	14	10	8	13	7	15	10
1908	42	46	22	23	15	13	15	9	13	15	30	10
1909	32	33	25	31	22	13	9	10	13	17	7	6
Total	151	135	116	135	103	75	48	43	56	56	82	49

This table demonstrates that 402 (38 per cent.) occurred in the first quarter of the year, 313 (29.9 per cent.) in the second quarter, 147 (14.0 per cent.) in the third quarter, and 187 (17.8 per cent.) in the fourth quarter. Only one-seventh of the cases occurred in the third quarter, in the first half more than two-thirds, and in the second half-year only one-third.

According to the following table from the authors just mentioned, age also seems to have a certain influence upon the morbidity, in so far as the greater number of cases occurred between the 21st to 30th year:—

Age	Number of cases
Up to 10 years	46, *i.e.*, 4.4 per cent.
From 11 to 20 years	210, *i.e.*, 21.1 per cent.
From 21 to 30 years	274, *i.e.*, 26.1 per cent.
From 31 to 40 years	192, *i.e.*, 18.3 per cent.
From 41 to 50 years	140, *i.e.*, 13.3 per cent.
From 51 to 60 years	105, *i.e.*, 10.1 per cent.
Over 60 years	81, *i.e.*, 7.7 per cent.

The male sex was 2⅜ times more frequently attacked than the female, since of the 1048 cases 783 were men and 245 women. This may be explained by the fact that men, owing to their activities, are more exposed to external influences, such as cold, exertion, etc., than women. This view is supported by the observations of Grisolle, according to whom the number of cases of pneumonia in localities where women do the same labor as men is the same in both sexes. Age exerts a marked influence also upon the termination of pneumonia, as shown by the following table:—

[1] "Klinische Beobachtungen bei kruppöser Lungenentzündung," Fortschritte der Medizin, July 13, 1911, p. 650.

Age	Male	Died	Female	Died	Total	Died	Total Mort.
Up to 10 years	29	2	17	1	46	2	6.5 per cent.
From 11 to 20 years	155	17	55	3	210	20	8.8 per cent.
From 21 to 30 years	214	22	60	7	274	29	10.1 per cent.
From 31 to 40 years	150	40	42	10	192	50	25.8 per cent.
From 41 to 50 years	103	32	37	18	140	50	36.3 per cent.
From 51 to 60 years	75	33	30	13	105	46	44.1 per cent.
Over 60 years	57	41	24	18	81	59	74.0 per cent.

Fibrinous pneumonia has two prestadia: a catarrhal and a hemorrhagic. Both are usually included as the stage of con-

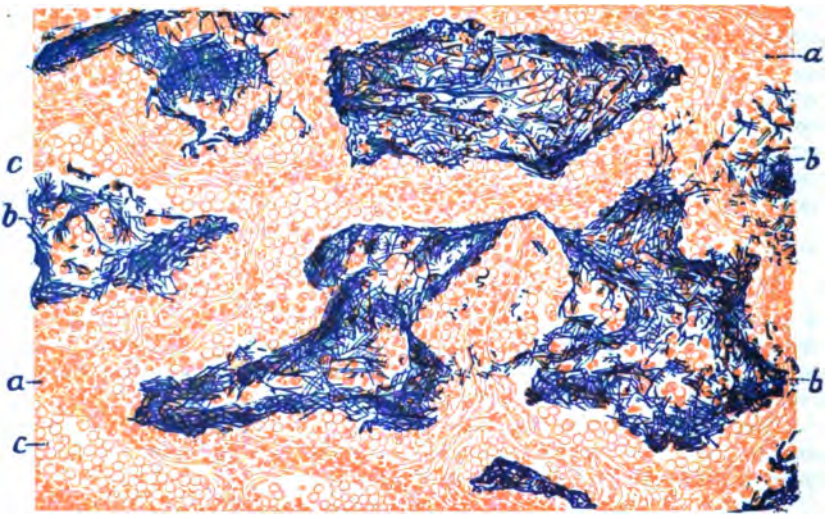

Fig. 279.—Croupous pneumonia. Red hepatization of the lung (alcohol, carmine, fibrin stain). *a*, infiltrated alveolar septa; *b*, fibrinous exudate; *c*, red blood-cells. × 200. (*Ziegler.*)

gestion or engorgement (engoulement). The lungs in such parts show very little that is characteristic. They are dark red, still contain air, but are slightly firmer in consistence, and resemble mostly a beginning hypostatic pneumonia. Without the aid of the microscope it can be anatomicly diagnosticated best when fibrinous hepatization is to be seen immediately adjoining it.

The hemorrhagic prestadium is followed by the stage of red hepatization (*hepatisatio rubra*); the alveoli become filled with red blood-corpuscles and fibrin. On coagulation of the fibrin the hemorrhagic contents of the alveolus become a quite firm, red plug. The cut surface of red hepatization is red and slightly granular. The latter appearance is chiefly due to the small plugs, composed of coagulated

exudate, which fill the alveoli. The slightly granulated, red, cut surface gradually changes to grayish red and, in part, grayish yellow.[1] This is due to solution of the blood-corpuscles, diffusion of the blood coloring matter, and exudation of new fibrin masses and partly also of cellular elements into the alveoli. The hepatized area thus attains a volume as in deep inspiration, with the difference, however, that instead of air a firm exudate occupies the alveoli, which produces anemia of the lung-tissue by pressure upon the vessels. The lungs, therefore, appear paler, larger, and more voluminous than usual, and do not collapse when the sternum is removed. The individual plugs (in the alveoli) are distinctly elevated above the cut surface as quite large granules,

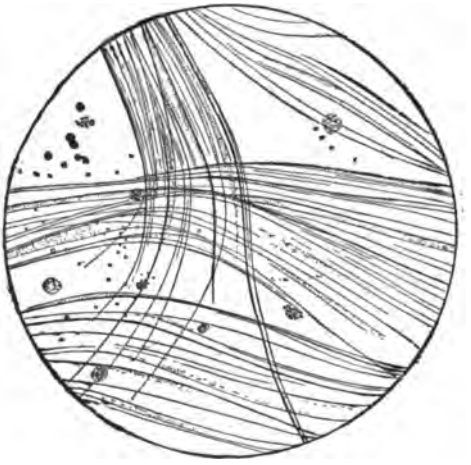

Fig. 280.—Delicate fibrin coagulum (from croupous pneumonia). × 350. (After *Lenharts-Brooks.*)

because the intensely distended elastic tissue, relaxed by the incision, retracts at the point where the cut is made. This is the stage of complete hepatization. If the edge of a knife is held at a slant and scraped across the cut surface, grayish-yellow granules are obtained, which are composed of a dense network of fibrin inclosing a moderate number of colorless blood-corpuscles and a few desquamated alveolar epithelia.

The cut surface gradually becomes smoother and redder, and the solid consistency gives place to a more relaxed condition. If the cut surface now be scraped with the edge of a knife, a cloudy fluid, partly mixed with solid masses, is seen, which consists, microscopicly, of finely granular detritus, disintegrated cells, and a few large, still coherent

[1] The color may be greatly modified by more or less lung pigment: anthracosis.

clumps or plugs. (See Fig. 282.) These plugs contain chiefly round cells and only a slight amount of fibrin. This is the stage of resolution.[1] In this stage a strong flow of fluid occurs from the greatly engorged blood-capillaries into the exudation plugs; the fibrin undergoes granular disintegration and the cells degenerate by fatty metamorphosis. The masses no longer remain fixed in the alveoli, as did the fibrin plugs, but form a movable exudate which may be partly expectorated, partly absorbed.[2]

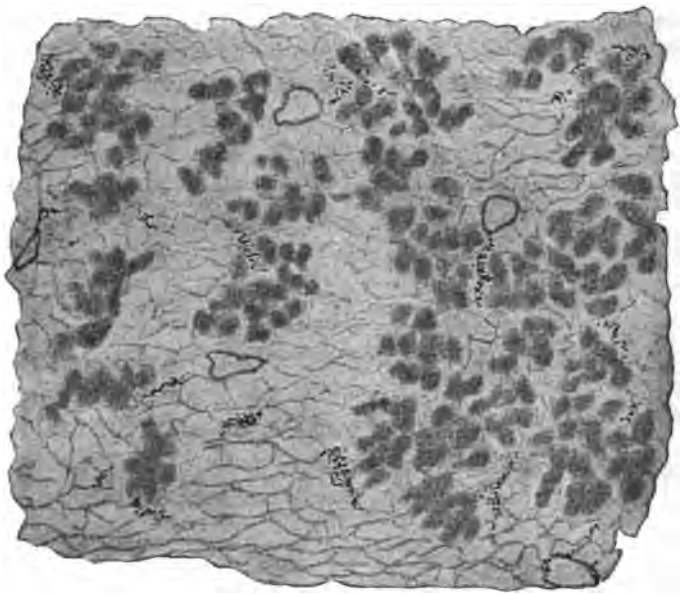

Fig. 281.—Fibrinous hepatization. Numerous fibrin plugs *in situ;* near them many empty alveoli from which the fibrin plugs have been washed out. Fresh section. (Zeiss Apochr., 2; Comp. Ocul., 4. After *Langerhans.*)

According to Fiessinger and Bauble (*Rev. d. méd.*, 4, 1910, p. 273), the fibrinous exudate is resorbed by a fermentative, proteolytic process. The fibrin is transformed into albumin, this into albumoses, peptone, and finally into amido-acids, and these subsequently are eliminated with the expectoration, urine, and perhaps also in other ways. To the polynuclear leucocytes is attributed the production of the salutary ferment. The leucocytes appear shortly before the crisis in considerable numbers in the blood (this leucocytosis goes hand in hand with rise of temperature and the other precritic symptoms), collect around the pneumonia focus, disintegrate, and thus liberate their ferment. This process can be followed in the expectoration, the urine, and blood.

[1] **Resolution** signifies, in general, loosening, solution, softening, *i.e.*, transformation from the solid to the fluid state. Autolysis likewise indicates solution, but it means also that the solution is effected by the substance itself without the intervention of other substances.

[2] Most of the exudate is absorbed.

A certain amount of relaxation or looseness of the tissues remains for some time after removal of the exudate from the alveoli.

If fibrinous pneumonia terminates unfavorably, this may be due, aside from complications (empyema, etc.), solely to the extensiveness of the process, to cardiac weakness, to toxic action, or to new involvement.

Fibrinous pneumonia generally involves but one pulmonary lobe, more frequently the lower lobe, and the right lung more often than the left. (See p. 541.) Sometimes both lungs and several lobes are involved at the same time, but more often invasion is successive, *i.e.*, affection of one lobe is followed by involvement of another. If a whole side is hepatized, the condition is spoken of also as peripneumonia (according to Celsus:



Fig. 282.—Two isolated fibrin plugs from a fibrinous hepatization. *a*, pure fibrinous plug; *b*, plug infiltrated with cells. Fresh preparation. (Zeiss Apochr., 4; Comp. Ocul., 4. After *Langerhans*.)

περι = around and around—wholly and completely, *totus pulmo afficitur*). In these cases there is intense collateral hyperemia of the nonhepatized area, because the hepatized parts are always anemic in the stage of complete hepatization. The collateral fluxion very easily gives rise to a fatal pulmonary edema as soon as the strength of the heart begins to weaken as a result of the increased resistance and the injury caused by the high fever.

Wherever fibrinous hepatization extends to and involves the pleura, an extensive fibrinous pleuritis develops. This is a constant accompaniment of fibrinous pneumonia whenever the latter occurs in lobar form, *i.e.*, involves the pleura to a marked degree. Hence the frequent use of the term fibrinous pleuropneumonia.

Every fibrinous pneumonia is attended by a violent bronchitis—acute catarrhal in the large bronchi and often fibrinous in the smaller—which may occasionally lead to filling and occlusion of the bronchi and bronchioli.

The bronchial glands of the affected side and the spleen are always markedly swollen in consequence of acute hyperplasia of the pulp-cells. At the necropsy the heart, liver, stomach, and kidneys are invariably found to be in the state of cloudy swelling.

The enormous amount of fibrin exuded during the course of fibrinous pleuropneumonia is not derived from the blood (for the blood contains more fibrin than usual and, as is known, is incapable of producing fibrin), but from the inflamed and altered parts of the lungs and pleura; the fibrin is elaborated by the irritated tissue-cells, and is partly thrown out upon the surface, partly conveyed by the lymph to the blood.

A not infrequent complication, which sometimes remains undetected, is fibrinopurulent arachnitis. This appears to stand in the same relation to Fraenkel's *Diplococcus lanceolatus* as does fibrinous pneumonia. (See p. 592.)

Whether the rare termination of fibrinous pleuropneumonia in purulent softening also depends upon the diplococcus or is due to other injurious influences has not been positively decided. In some instances no other bacteria can be demonstrated. The beginning of purulent softening is recognized by the following features: The firm consistency gives way to flabbiness; the incised surface is no longer granular or only partly so, and exudes a creamy, turbid, pus-like material. Furthermore, the color of the whole cut surface is more yellow than usual; the more pus there is formed, the more greenish yellow the color becomes; the softer and more relaxed the consistency, the more pus exudes from the cut surface. Finally, the hepatization can no longer be recognized; in its place there is found a purulent sac containing, in addition to pus, firmer fragments which, however, can be recognized as remains of lung-tissue only by the aid of the microscope.

In some cases fibrinous pleuropneumonia is accompanied by a purulent pleuritis in which the *Diplococcus lanceolatus* is usually found. Sometimes, especially in topers and when putrid processes previously existed in the lungs, pneumonia goes on to gangrene. Rarely the fibrinous exudate becomes organized—replaced by connective tissue—so that the lung-tissue contains no air and assumes a flesh-like appearance: carnification. Very little is known as to the cause of this change. The connective tissue does not develop from the true lung parenchyma, but from the connective tissue present in the lung.

Under certain conditions fibrinous pneumonia may terminate in caseous hepatization, especially when tuberculosis or caseous processes pre-existed in the affected lung and tubercle bacilli can be disseminated from these foci.

Persons who have once had pneumonitis appear to possess a greater susceptibility after recovery than those who have not been attacked. Among Rolly and Blumstein's cases,[1] 159 (14.2 per cent.) had had pneumonitis several times, and among these 3 had six attacks and 4 had five attacks. Among 46 cases of pneumonitis in children, 8 (17.4 per cent.) had had the disease several times. Therefore, it would appear that, on the one hand, there is established in the lungs after recovery from pneumonitis a *locus minoris resistentiæ*, whereby entrance of the infectious agents is favored, and, on the other hand, that a specific alteration of the organism (allergy) is produced, in consequence of which, in renewed infection, invasion by the infectious agents occurs more readily than in first attacks.

As regards the **clinical manifestations** of the disease, the inflammation began acutely with violent chill in 59 (4 per cent.) of the cases. The well-known *sputum crœcum*, in which the pneumococcus could easily be demonstrated, was usually observed on the second day. In pneumonia of the upper lobe, in pneumonia of old persons, and in cases complicated with delirium trements, expectoration was lacking. In the minority of cases the disease began with vomiting, diarrhea, marked dyspnea, meningitic symptoms, and in children often with convulsions.

In 270 cases the **fever** subsided by crisis. In the great majority the temperature declined by lysis. In 243 cases crisis occurred between the fourth and tenth day. and in 103 on the seventh to eighth day, as shown by the following table:—

Day	Number	Day	Number
1	0	10	20
2	1	11	15
3	12	12	1
4	21	13	6
5	33	14	2
6	30	15	1
7	58	16	0
8	45	17	3
9	36	20	1

A distinct decline by lysis, lasting for from two to three or more days, was observed 267 times. In 176 cases (66 per cent.) lysis occurred between the sixth to tenth day; in the majority of the remainder, on the eighth to ninth day.

The **site of the pneumonia** was on the right side in 52.6 per cent.; on the left in 38.1 per cent., and on both sides in 9.3 per cent. The infiltration was present in 72.8 per cent. in the right lower lobe; in 0.9 per cent. in the middle lobe; in 11.4 per cent. in the right upper lobe; in 4.3 per cent. in the right lower and middle lobes; in 2.5 per cent. in the right upper and middle lobes; in 2.19 per cent. in the right upper and lower lobes, and in 8.6 per cent. in the whole right lung. Of the left lung the upper lobe was involved in 3.7 per cent.; the lower lobe in 26.4 per cent., and the whole left lung in 8 per cent. Both lungs were involved in 9.3 per cent.; both lower lobes in 3.1 per cent.; both upper lobes in 1.1 per cent., and one lower lobe and one upper lobe in 1.0 per cent. The process was located elsewhere in 4.1 per cent. The lower lobes, therefore, were involved in about three-fourths of the cases and the middle lobe least. The **pulse** was in all cases greatly accelerated, and in advanced age this appears to possess a certain prognostic significance, since in those patients who were over 60 years of age and in whom the pulse rate exceeded 120 per minute 94 per cent. died.

[1] *Loc. cit.*, p. 651.

Albuminuria was observed in 339 (32.1 per cent.) of the cases. This is apparently a toxic manifestation which disappears with subsidence of the fever and has no further influence upon the prognosis or course of the disease. In many cases a diminished excretion of sodium chloride in the urine was determined. In the majority of cases peptonuria was demonstrable during the affection.

In 132 cases herpes was observed in the region of the mouth, nose, and cheeks, and occasionally upon the eyelids and cornea.

Of the **complications**, pleuritis is most frequent. It certainly is more frequently present than is clinicly demonstrable. According to the authors above quoted, the different forms occurred with the following frequency in 1048 cases:—

	Cases	Mortality
Pleuritis sicca	78	61.5 per cent.
Pleuritis serosa	47	40.4 per cent.
Pleuritis purulenta	61	65.6 per cent.

In 13 cases the pneumonia resulted in pulmonary abscess. Of these, 4 died. Pulmonary gangrene was observed in 4 cases, all females. In 11 cases chronic interstitial pneumonia resulted, 2 of which followed pulmonary abscess. Serofibrinous and purulent pericarditis occurred in 15 (1.4 per cent.) cases, 11 (73.3 per cent.) of which died. Fresh endocarditis was found in 14 patients, and myocarditis in 5; of the former, 4 (28.6 per cent.) and, of the latter, 2 (40 per cent.) died. Pneumococcic meningitis occurred as a complication 7 times, 4 of which died. In 33 cases delirium tremens was observed, 11 (33.4 per cent.) of which died. In 47 cases (4.5 per cent.) acute nephritis, due to the pneumococcus or its toxins, developed; of these, 9 (19.2 per cent.) ended fatally. Seventy-eight cases were accompanied by icterus, 12 of which came to necropsy. In all cases the biliary passages were patent; therefore, the icterus was due to toxic influence upon the liver-cells. As 31 (39.8 per cent.) of the 78 icteric cases died, the presence of bile coloring matters in the urine is an unfavorable prognostic sign. Especially unfavorable appear to be those cases in which albumin and bile coloring matters occur together in the urine. In 40 cases this condition was present, and the mortality was 50 per cent. Other complications observed by Rolly and Blumstein were:—

	Males	Deaths	Females	Deaths
Catarrhal and follicular angina	17	0	8	1
Otitis media	6	0	4	0
Metastatic ophthalmia	0	0	1	1
Parotitis	4	1	2	0
Phlegmonous strumitis	1	0	0	0
Sepsis (with metastases)	14	11	2	1
Papillitis	0	0	1	0

According to this table, the prognosis is very bad in pneumococcic sepsis, as the mortality was 75 per cent. Coexistence of emphysema (mortality 75 per cent.), cardiac valvular lesions (mortality 30 per cent.), and arteriosclerosis (mortality 66.6 per cent.) render the prognosis grave. Tuberculosis exerted no essential influence upon the termination or course of the affection.

In view of the fact that various authorities state that the mortality of pneumonia varies in different years, it is interesting to present the authors' tabulation, which shows that the variation of the mortality in different years is not very great:—

PLATE IX

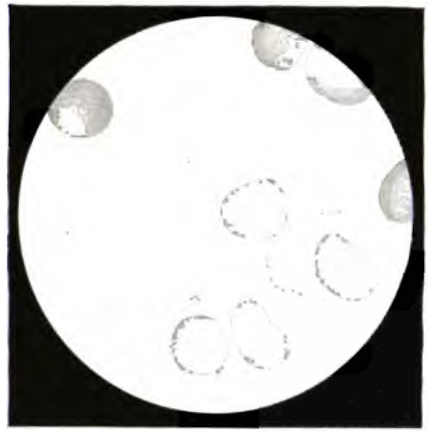

Spirochætæ pallida in smear from secretion of a fresh hard chancre. The red blood-cells are gray, the spirochætæ dark rose. × 1000. (After *Lenhartz.*)



Skin of a congenital syphilitic child, with Spirochæta pallida (Treponema pallidum). Wide distribution of spirochætæ in the epithelium, the cutis, and the papillary bodies. (Levaditi method. After *Buschke.*)

	Males	Died	Mort. %	Females	Died	Mort. %	Total	Died	Total Mort. %
1905	134	26	19.4	32	7	21.9	166	33	19.9
1906	137	38	27.7	58	16	27.6	195	54	26.3
1907	165	34	20.6	52	15	28.8	217	49	22.5
1908	178	42	28.4	75	18	24.0	253	60	23.7
1909	169	47	27.9	48	14	29.2	217	61	27.3
Total	783	187	23.8	265	70	26.4	1048	257	24.1

Syphilis, Lues Venerea.

Syphilis[1] belongs to the pure contagious diseases which are transmitted exclusively from man to man, the specific syphilitic products (*e.g.*, from a disintegrated gumma) finding a favorable *locus minoris resistentiæ* in wounds or the smallest abrasions.

Recent investigations seem to justify the belief that the cause of syphilis is an extremely delicate, faintly refractive, very actively motile spirochæta, with pointed ends (*Spirochæta pallida,* or *Treponema pallidum*), discovered by Schaudinn and Hoffmann.[2] The length of the *Spirochæta pallida* varies between 4 and 14 μ, usually 7 μ, It is possible that it does not belong to the bacteria, but to the protozoa. In physiologic salt solution the organism remains motile for six hours. It is provided with numerous (4 to 20) sharp, narrow spiral turns, and is visible only after employment of special methods of staining or with the dark-ground illumination apparatus. It has been found not only in the tissue juices and secretions of primary and secondary lesions (papules, chancres, mucous patches, condylomata, etc.) and in almost every organ and tissue in congenital syphilis, but also, though rarely, in tertiary lesions: syphilitic aortitis, gumma of bone, cutaneous lesions. In malignant syphilis, however, it has thus far not been detected. The micro-organism has been observed also in experimental lesions produced in apes. Until pure cultures of the *Spiro-*

[1] The etymologic invention of the term "syphilis" appears to be due (incorporated in myth) to a Veronese physician, named Hieronymus Fracastorius, born at Verona about the year 1483. He wrote a poem entitled: *"Syphilis, sive morbus gallicus"* (The Philmar Co., St. Louis, Mo., 1911), therein relating how a herdsman of the King Alkithous, Syphilis by name, was afflicted with the disease by Apollo in punishment for paying divine homage to the king instead of to the god.

According to Buret ("La Syphilis adjourd'hui et chez les anciennes"), the word is derived from the Greek σὺν and φιλειν (love), *i.e.*, "companion of love."

Captain Dabry ("La médecine chez les Chinois," Paris, 1863) states that in the year 2367 B. C. the Emperor Hoang-ty ordered all manuscripts to be collected, and from these Dabry learns that the Chinese recognized and treated syphilis with mercury.—C. T. Baxter, Middlesex Hosp. Jour., ix, No. 6, p. 241.

When syphilis was introduced into Germany at the end of the fifteenth century, it was called "cancer," because at that time cancer was considered to be a kind of ulceration. The original significance of the word cancer (carcinoma)—a tumor—was subsequently restored.

[2] Arb. a. d. Kais. Gesundhamt., H. 2, Bd. xxii, pp. 527,534; Deutsch. m. Woch., 1905, 18, pp. 711-714; Berlin. klin. Woch., 1905, No. 22, p. 673, and No. 23, p. 726.

chæta pallida are obtained, and inoculations made into man,[1] the question of its specific etiologic relation to syphilis must remain in doubt.

According to O. T. Schultz,[2] the presence of the *Spirochæta pallida* is the only criterion for the diagnosis of congenital lues. In living and stillborn infants there occur with relative frequency chronic inflammatory changes which render the histologic diagnosis of syphilis extremely difficult. The essential lesion, in congenital as well as in acquired lues, is the vascular involvement. This begins with localization of the parasites in the perivascular lymphatics, which leads, first, to proliferation and infiltration of the adventitia, and then to extension of the inflammatory process inward toward the lumen of the vessel, and outward into the perivascular tissues. In the congenital form of the disease the diffuseness of the interstitial inflammation may obscure the more essential and characteristic vascular involvement.

It is very doubtful whether the *Cytorryctes lues,* described by Siegel,[3] an organism belonging to the protozoa and found in the blood-vessel walls and certain tissues, has any etiologic significance.

The *contagium vivum* of syphilis retains its virulence for a certain period after death. The length of this period depends upon various conditions, and very probably is influenced by the action of the metabolic products of the putrefactive bacteria. The more rapidly the phenomena of putrefaction appear, the earlier is the specific action of the contagium annihilated. (See General Remarks upon the Infectious Diseases, p. 431.)

The local change observed in syphilis occurs in two forms: a mild and a severe. The first consists of a simple, irritative, hyperplastic process, which manifests nothing specific. The severe form corresponds to gumma formation. Different varieties are distinguished: fibrous, medullary, colloid, and caseous gummata, all of which agree in so far as they develop from granulation tissue and manifest great disposition to undergo fatty degeneration. The difference consists mainly in the local diversity of the matricular tissue.

Syphilis generally begins with an entirely local affection as a

---

[1] H. Noguchi (*Jour. Amer. Med. Assoc.,* July 8, 1911, p. 102) has recently cultivated the *Treponema pallidum* in fluid and solid media. Inoculations into the testicles of rabbits "set up the typic lesions." According to Noguchi, the previous experiments of Sowade (*Deutsch. med. Woch.,* No. 15, 1911) and J. Schereschewsky (*ibid.,* No. 20, 1911, p. 929) are questionable.

Hoffmann (*Deutsch. med. Woch.,* Aug. 24, 1911, p. 1546), by inoculation with pure cultures of *Spirochæta pallida* from human syphilis, has produced the disease in rabbits and recultivated the spirochætæ from the testicular lesions. He, therefore, asserts that the chain of proof of the etiologic significance of the *Spirochæta pallida* in the production of syphilis is complete. He also states (*Münch. med. Woch.,* Aug. 15, 1911, p. 1769) that it is an error to designate the micro-organism of syphilis as spirillum. The proper names are *Spirochæta pallida* (Schaudinn), *Spirochæta luis* (Hoffmann), and syphilis spirochæta (Hoffmann).

[2] Jour. of Infect. Dis., 1910, No. 8, p. 18.

[3] Münch. med. Woch., July 11, 1905, p. 1321, and Jan., 1906, p. 63.

hard chancre[1] at the point where the virus first gained admission. The period of time (incubation) which elapses between exposure to the virus and the appearance of the chancre averages twenty-one days, but it may extend from ten to sixty days or longer. Transportation of the virus to the neighboring lymph-glands produces an alteration of these structures—generally within a few days after the appearance of the chancre—which is designated as buboes. From here, after the manner of metastasis formation in tumors, the poison is distributed throughout the system and affection of remote parts and the internal organs occurs.[2] The primary lesion, therefore, forms a focus of infection for the same body and also a point of contagion for other individuals. The time which elapses between the appearance of the primary lesion and the secondary phenomena (average from forty to forty-five days) is consumed by the virus in order to increase and disseminate in the body. The primary focus—the hard chancre—corresponds in its histologic characters and course to a gumma nodule.

By *lues hereditaria tarda* is understood that form of hereditary syphilis in which the subject for a long time after birth—up to puberty and even beyond—may be latently syphilitic, then manifest symptoms belonging to the late period of syphilis. It is manifested chiefly by osseous deformities, parenchymatous keratitis, arthritis, and involvement of the glands.

In **bone,** hyperplastic as well as gummous formations occur. These develop, on the one hand, from the periosteum, and on the other from the bone-marrow, namely, from the spongy portion. Simple and gummous periostitis begin principally in parts where the bone lies near the surface (beneath the skin) and is especially subjected to external influences (blows, friction, chilling, etc.). The products of simple periostitis are exostoses and hyperostoses.

In the long tubular bones, most frequently the tibia, quite marked swellings may thus develop which, at first, are sclerotic, but later are usually converted into cancellous structure. Although this simple periostitis has no specific character, it is, nevertheless, in certain cases, classed with syphilis, because experience has shown that specific gummous periostitis also begins as simple periostitis, and that, in addition to gummous formations, exostoses and hyperostoses almost invariably develop as a product of simple irritation. (See Fig. 283.)

Gummous periostitis generally begins in the deeper layers of the periosteum, most frequently upon the frontal bone, and leads to the

---

[1] French: chancre; German: schanker; Latin: cancer.

[2] Furthermore, amyloid degeneration occurs as a nonspecific change, which in some cases is diagnostic of syphilis.

formation of more or less soft or hard gummous tumors. In the first case a rapidly proliferating soft tissue is produced which has a tenacious, sticky character, consists of a colloid, partly fibrillated basement substance and of small and large round and spindle-shaped, proliferated cells which usually possess a large, strikingly bright, almost homogeneous nucleus. In the other case the basement substance is fibrillated, quite dense; the cells are round, spindle-shaped, or stellate-formed. In addition to very early, progressive but incomplete retrograde fatty metamorphosis, these gummata undergo partial caseous transformation, whereby the nodules acquire a yellow, opaque, nontransparent appearance. These dead masses may persist for a shorter or longer time, but finally disappear by absorption. As the uppermost osseous lamellæ also are involved in the process in periostitis gummosa, a depression which sometimes extends deep into the bone occurs in this locality as a result of absorption. On maceration, such bones appear roughened as if suppuration had existed. Since, however, suppuration is always absent, the process is called *caries sicca.* The diagnosis is often facilitated by the fact that gummous formations, exostoses, and hyperostoses are to be found in the neighborhood of the depressions.

Fig. 283.—Syphilitic hyperostosis of the left femur. Reduced ⅜. (After *Ziegler.*)

Osteomyclitis gummosa starts in the spongiosa. Here also gumma formation, fatty and caseous degeneration, and, finally, necrosis of the altered osseous tissue occur. Condensations always develop in the neighborhood as the result of osteosclerosis.

In **congenital syphilis** a pathognomonic change of the chondro-osseous junction—an *osteochondritis syphilitica*—is frequently observed, which appears as a yellow-white line at the epiphysodiaphyseal junction. This line corresponds in its position to the "zone of provisional calcification." (See Fig. 284.) In healthy children the latter

forms a very small, scarcely visible line of demarkation between the epiphysis and diaphysis. This small zone is transformed by hereditary syphilis into a broad, distinctly visible line which likewise consists of calcified but dead cartilaginous tissue, for the calcification occurring in syphilis is a definite variety, a kind of petrification which corresponds to a necrotic process. The dead cartilage excites proliferation in the neighborhood, which, under certain circumstances, may lead to complete dissection of the cartilage from the bone, so that a kind of fissure is formed between them. In the **skin** and mucous membranes, aside from the roseola, which is essentially a hyperemic phenomenon, chiefly gummatous formations develop which, in contradistinction to the periosteal growths, are characterized by great tendency to ulcerate. To these belongs, first of all, the primary focus of infection.

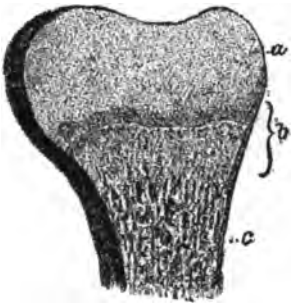

Fig. 284.—Syphilitic osteochondritis in a 13-month-old boy. *a*, cartilage; *b*, altered parts. The light line corresponds to osteochondritis; downward, sclerosis of the spongiosa; *c*, unaltered spongiosa. Natural size. (After *Langerhans.*)

Hard chancre is a gumma—granulation tissue—which disintegrates and forms an ulcer. Sometimes a vesicle first develops which bursts and leaves a small wound surface which subsequently becomes infiltrated and indurated. The surface of syphilitic ulcers secretes essentially disintegration products (not pus). The so-called phagedenic forms have an especially eroding character and great disposition to necrosis. Of course, all chancres, even the soft varieties, manifest this tendency to a slight degree; hence the name chancre, from cancer. Gummata similar to those at the primary focus of infection may later appear at various localities in the skin, especially in the scars of former ulcers. Sometimes true nodules, partly solitary, partly in groups, develop in the skin of the forehead, the extremities, and the trunk. These also ulcerate, and, under appropriate treatment, heal with marked stellate cicatricial retraction.[1] Those gummata which develop from old, indurated cicatrices are usually very firm, hard nodules—so-called keloids.

Condyloma latum (see Figs. 285 and 286) is an incomplete gumma which still preserves certain peculiarities of the matrix. It develops in localities with delicate epidermis, usually at the anus and introitus vaginæ, as a flat-rounded swelling of the cutis with enlargement of the papillæ and smooth epidermis covering. As a result of intense granulation

[1] Radiate scars upon the lips, apparently remnants of papular efflorescences, are particularly characteristic of congenital lues.

formation, swelling, and loss of epidermis, this condyloma is converted first into a wet, then suppurating, and finally disintegrating, ulcer: true condylomatous ulcer.

Similar condylomatous proliferations occur upon the mucous membranes, *e.g.*, at the margin and on the inner surface of the epiglottis; on the tongue, upon and on the under surface of the vocal cords; in the trachea, and in the bronchi. They are readily confused with simple hyperplastic states of the follicles of the pharynx, base of the tongue, etc., have a firm consistency and a pale, whitish-gray appearance.

In intense proliferation, ulceration or even retrogression and absorption occur, so that, *e.g.*, the follicles at the base of the tongue disappear and a smooth atrophy (*atrophy lævis radicis linguæ*) of

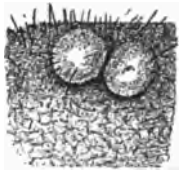

Fig. 285.—Condyloma latum ani. Natural size. (After *Langerhans.*)

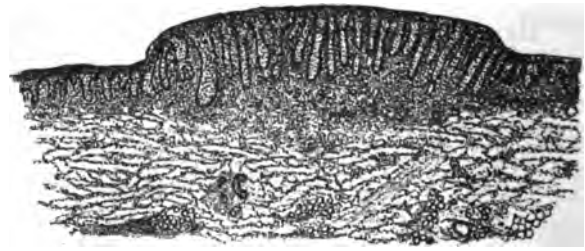

Fig. 286.—Condyloma latum ani. Section from Fig. 285. × 8. (After *Langerhans.*)

the base of the tongue occurs under cicatricial induration. In other cases chiefly the edges of the tongue are altered, or deep cicatricial bands develop which give to the surface of the tongue a lobulated appearance. (See Fig. 287.)

Genuine condylomatous proliferations almost invariably ulcerate, at first forming quite flat ulcers, then gradually extending to the deeper tissues, which are destroyed by gummous proliferations. When the ulceration reaches the perichondrium of the laryngeal cartilage, a gummous or purulent perichondritis with necrosis and sequestration of individual portions of cartilage develops; deep, sinuous cavities form which produce incontinence of the epiglottis and stenosis as a result of cicatrization. The process frequently involves the vocal cords, producing hoarseness or aphonia.

In the **gastrointestinal canal** gummous nodules are not very frequent, but they may form considerable tumors; they usually produce, through ulceration and cicatricial contraction, radiate scars which, in narrow canals, especially in the upper portion of the esophagus and rectum, seldomer in the ileum and colon, may result in narrowing

and strictures. Syphilitic ulcers in the rectum occur almost always in females: *proctitis ulcerosa;* they develop as the result of discharge of infectious exudate from the vagina during dorsal position. Simple thickenings or gummata develop in the neighborhood of the rectum, which disintegrate and involve the rectum. Purulent inflammations and abscesses usually coexist, which rupture into the rectum and leave fistulous passages: *paraproctitis apostematosa.*

In the **lymphatic glands** two changes are differentiated: simple lymphadenitis, which develops in the immediate neighborhood of the primary focus, sometimes resulting in suppuration, and secondary indolent buboes, which are distributed over almost the whole body. These indolent buboes form the point of origin of a gummous lymphadenitis. The process begins with hyperemia and granulation proliferation; this is followed by partial retrograde fatty metamorphosis and inspissation, which result in the formation of small caseous nodules, while the greater part of the gland undergoes fibrous induration. The glands remain enlarged, but do not exceed the size of a walnut.

Fig. 287.—Syphilitic cicatrices of the epiglottis and tongue. Natural size. (After *Langerhans.*)

The syphilitic changes of the **liver** are *perihepatitis fibrinosa recurrens, hepatitis interstitialis,* and *hepatitis gummosa.* The latter is preceded by a partial, chronic, interstitial hepatitis, the product of simple irritation, which produces cicatricial bands and trabeculæ; gummata

secondarily develop in these. The point of predilection of this syphilitic change is in the region of the suspensory ligament, *i.e.*, that part of the liver which is most often subjected to insults, traction, tension, etc. The gummous nodules are very variable in size, usually larger than tubercles, have a yellowish color and great density, and are usually not rounded but angular in outline.

The characteristic form of syphilitic hepatitis is the so-called

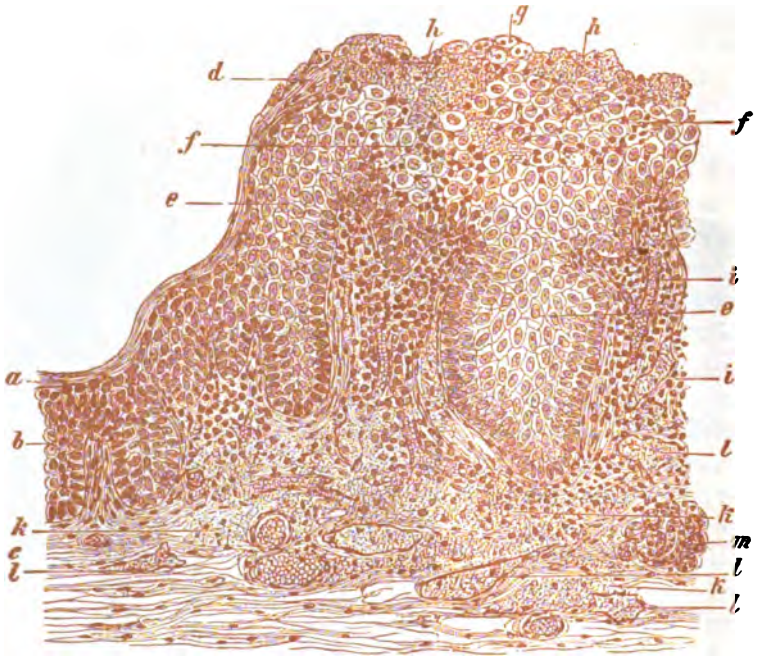

Fig. 288.—Section through a condyloma latum of the anus. *a*, horny layer of the epidermis; *b*, rete Malpighii; *c*, corium; *d*, swollen horny layer infiltrated with round cells; *e*, swollen cells of the rete Malpighii; *f*, swollen and cellular infiltrated epithelium; *g*, epithelia into the degenerated interior of which round cells have entered; *h*, granular coagulated masses; *i*, swollen cellular infiltrated papillary bodies; *k*, corium infiltrated with cells and fibrin; *l*, lymph-vessels; *m*, sweat-glands. × 150. (After *Ziegler.*)

lobulated liver, *hepar lobatum*. (See Figs. 289 and 290.) In this condition both large lobes of the liver appear to be divided into a number of smaller lobes by deep, cicatricial furrows. In addition to this partial interstitial inflammation, a general, diffuse interstitial hepatitis is often observed which, however, possesses no characteristic signs of syphilis.

Perihepatitis is partly an accompaniment of interstitial hepatitis, partly an independent inflammatory process with exudation of fibrin. The exudate results either in adhesions or, through organization and



Fig. 289.—Hepar lobatum. Section through the liver. In the center a cicatricial band which divides the liver into two parts. Besides, five large gummatous nodules. ½ natural size. (After *Langerhans.*)

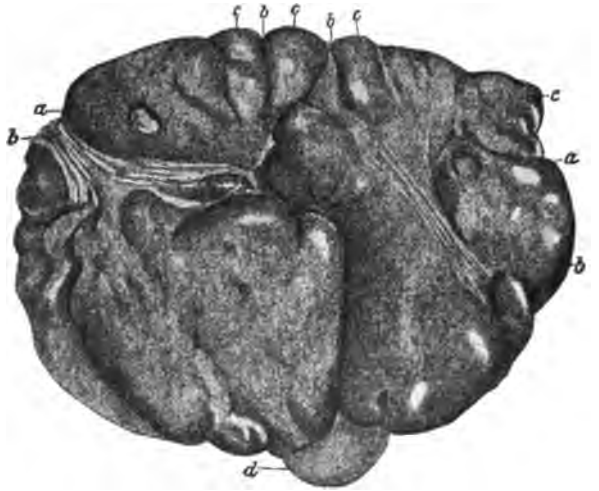

Fig. 290.—Hepar lobatum. Surface of the liver. *a*, gummatous nodules; *b*, cicatricial bands; *c*, small constricted lobuli; *d*, gall-bladder. (After *Langerhans.*)

unusually intense retraction (scar-like), in partial atrophy of the liver, cicatricial indentations occurring very early upon the surface from shortening of the capsule.

In congenital syphilis there is sometimes only a simple interstitial hepatitis; more frequently, however, marked proliferation—the formation of miliary gummata—in which retrograde fatty metamorphosis can usually be recognized, occurs in several localities. Large nodules which sometimes may be white and fibrous, sometimes reddish, soft, and richly cellular, are rarer.

In the **testes** syphilis usually causes interstitial fibrous orchitis, a partial or general interstitial inflammation starting from the rete and the septa between the seminal canals, and terminating in fibrous induration. A proliferating periorchitis frequently coexists (sometimes also alone) in which the albuginea is indurated and often of cartilaginous consistency, or an exudative inflammation is present

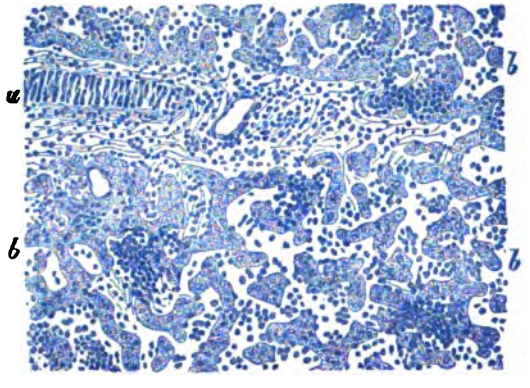

Fig. 291.—Syphilitic hepatitis in the newborn. *a*, richly cellular peritoneal connective tissue (longitudinal section through an artery); *b*, gland tissue infiltrated with cells. × 100. (After *Ziegler.*)

which may result in adhesion and finally in complete obliteration of the serous sac.

Not infrequently hard, fibrous gummata of dry and somewhat yellowish appearance develop secondarily within the fibrous indurations of the testes: *orchitis gummosa.* The sequelæ of these syphilitic changes of the testes are aspermia and sterility.

Syphilis of the musculature also progresses as a simple interstitial—*myocarditis interstitialis*—or as a gummous process: *myocarditis gummosa.* In the heart gummata are rarer than the fibrous and usually multiple indurations resulting from interstitial myocarditis. The largest gummata occur as spindle-shaped swellings of the long skeletal muscles in the region of their points of insertion; they consist of small-celled proliferation between the primitive bundles with transition into amorphous, richly fatty masses: *myositis gummosa.*

In the **vascular system** (aside from the heart) **gummatous formations** belong to the greatest rarities; on the other hand, thickening of the walls of the small arteries is very frequently observed. This thickening consists in proliferation of the adventitia, which, secondarily, extends to the other coats and, in contradistinction to other syphilitic proliferations, is characterized by great permanency. Sometimes the involvement of the intima—the endoarteritis—is so marked that the lumen is almost completely occluded. As a result, apoplectic attacks may occur in the brain which, however, not infrequently are rapidly and even completely compensated. In the large

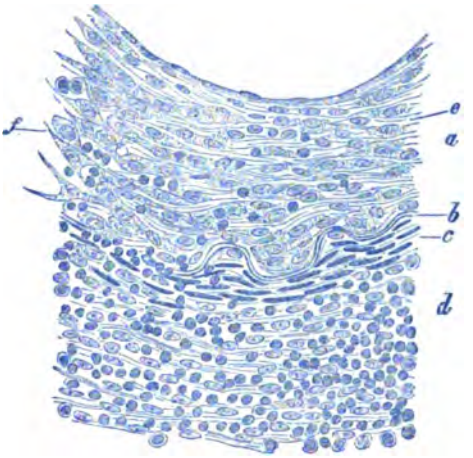

Fig. 292.—Syphilitic arteritis of the arteria fossæ sylvii. *a*, enormously thickened intima; *b*, membrana fenestrata, at the left broken through; *c*, muscularis; *d*, adventitia; *e*, cellular fibrous tissue; *f*, cellular new formation. × 150. (After *Ziegler*.)

vessels, also (*e.g.*, in the aorta), proliferations in the intima and aneurismal formations are sometimes referred to syphilis.

Gummata of the dura start either from the inner—meningeal—or the outer—periosteal—portion. The latter may occur as a diffuse process or as circumscribed external gummatous pachymeningitis. This progresses as a gummatous periostitis, leads to formation of exostoses, hyperostoses, gummata, and caries sicca. In diffuse external syphilitic pachymeningitis the external portion of the dura becomes a granulation layer which likewise undergoes fatty and caseous metamorphosis. In addition, atrophy of the internal table occurs. Both the diffuse and circumscribed form are usually very soon followed by gummatous osteomyelitis with necrosis and caries. At the same time chronic

thickening of the meningeal layer develops and, when the process advances, adhesion with the arachnoid and signs of encephalitis occur.

Meningeal gummata of the dura are situated either flat upon the dura or more in the parenchyma. They are rounded, hemp-seed- to walnut- sized nodules with a fibrocaseous center and a fibrous or gray-translucent periphery. These nodules are found upon the convexity or in the neighborhood of the sella turcica, rarely in the falx. Internal hemorrhagic pachymeningitis or adhesion with the arachnoid usually coexists, and ultimately extension of the gummata to the arachnoid and brain.

Syphilis of the arachnoid sometimes begins with an *arachnoiditis partialis fibrosa—i.e.,* with induration and small gummatous, caseous deposits. In this condition the adjacent cerebral structure is either softened or sclerotic. Large gummata of the arachnoid (up to the size of a hen's egg) develop at the base, namely, in the region between the optic chiasm, the pons and the crura cerebelli. When these large nodules exist, the brain and dura are always affected.

Furthermore, there occurs at the base a pure syphilitic hyperplasia of the arachnoid which is usually limited to the region of the optic chiasm and rarely extends farther. Quite soft growths, several millimeters thick and without retrogressive metamorphosis, may develop as a result of this proliferation. When the proliferation is extensive it almost always advances to the cortical layer and causes encephalomeningitis and atrophy of the cortex.

In the **brain** chiefly gummata are observed. These are usually situated in the periphery, most frequently at the base, rarely in the interior. They start from either the cerebral membranes or the neuroglia. It is often very difficult to decide where the tumors originated, as they generally rapidly extend and involve neighboring parts. Thus, it is not rare for the brain, arachnoid, dura, bones, and nerves to be simultaneously involved by the gummatous change.

Gummata of the brain are situated chiefly in the periphery and the large ganglia. They are usually solitary nodules with a caseous center and a periphery composed of soft, gray-transparent, sometimes colloid granulation tissue. The surrounding brain substance is sometimes in a state of softening. These nodules may be very firm, almost hard, sclerotic, and inclose small caseous deposits. Then the line of demarkation between the brain is indistinct, and the process progresses more in the form of an encephalitis.

In the **spinal cord** proliferations and gummata develop from the membranes in a manner analogous to the process in the brain and partly involve the spinal cord. The process in the nerves is quite similar.

In the eye small, soft gummata occur in the iris (*iritis gummosa*, q.v.).

Syphilitic alterations of the lungs are found in congenital syphilis as well as in the later acquired form. White hepatization occurs only in congenital syphilis, and is caused by intense proliferation of the alveolar epithelium. The epithelia are dislodged by the young proliferating cells, lie free in the alveoli, fill the latter more or less completely, and are generally in an incipient state of fatty metamorphosis. At the same time marked cellular proliferation, which starts in the connective tissue, is frequently observed, and sometimes genuine gummata.

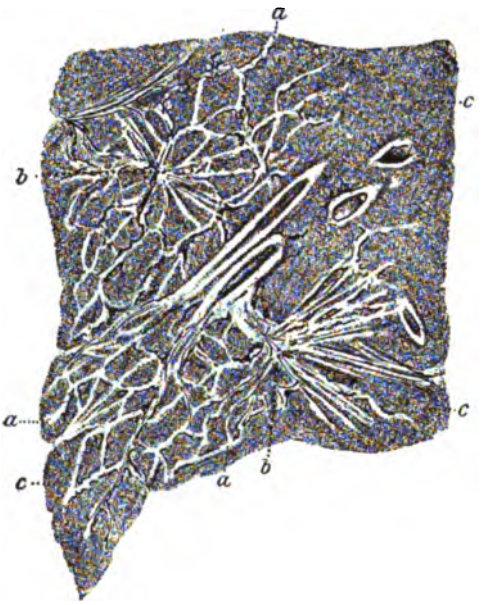

Fig. 293.—Interstitial interlobular fibrous pneumonia with cicatricial contraction of the pleura at various points. *a*, interlobular strongly thickened connective-tissue bands; *b*, the same with stellate cicatricial retraction; *c*, lung-tissue containing air. Natural size. (After *Langerhans*).

In adults the syphilitic changes affect the interlobular, peribronchial, subpleural, and pleural connective tissue and the bronchia. There is a gummatous bronchitis which cannot readily be differentiated from tuberculous processes. Sometimes two to four or more nodules, which lie in the central portion—not in the apices—are observed in otherwise healthy lungs. The center of such a nodule is occupied by a bronchus, the lumen of which is greatly narrowed and the walls more or less swollen in fusiform shape. The surrounding lung-tissue is not compressed, but gradually merges with the large nodule by a narrow, translucent, gray zone. The nodule consists of very firm, almost hard, sclerotic, gray-white tissue mottled with black-pigment inclusions. The center often contains a fatty-caseous, yellowish-white mass; this is distinguished from the caseous material occurring in the lungs in tuberculous processes by its firmer consistency and the quite smooth, slightly glistening cut surface. At the junction with the lung-

tissue it is seen that not only the connective tissue, but also the lung-tissue itself—the alveolar structure—is the matrix of the granulation layer.

Another change is a chronic interstitial pneumonia without formation of gummata. An increase in the width of the lobular septa and progressive induration of the lung parenchyma occur as a result of proliferation and swelling of the connective tissue. The connective tissue in the neighborhood of the vessels and bronchi also is involved, often to a marked degree, so that the bronchi appear to be surrounded by a wall of dense, grayish-white connective tissue: *peribronchitis interstitialis fibrosa chronica.* Wherever the interlobular process reaches the pleura, the latter also is indurated and usually cicatricially contracted, so that the surface at that point is dense, firm, radiately scarred, and somewhat flattened.

Fig. 294.—Interstitial pneumonia and three gummatous nodules. Natural size. (After *Langerhans.*)

In the **uterus** syphilis quite frequently produces a fibrous endometritis. The mucous membrane is thus completely destroyed and transformed into a fibrous, whitish mass of connective tissue with smooth surface. This change is usually most marked immediately above the internal os.

Gummata not infrequently occur in the **spleen.** Chronic, quite dense, and often markedly pale spleen-tumor is almost always observed. Sometimes firm cicatricial bands run transversely through the spleen.

Partial hyperplasias of the interstitial connective tissue are characteristic of syphilis of the **kidneys.** This change occurs in the form of multiple interstitial nephritis, and by subsequent contraction results in the formation of smaller or larger scars—*cicatrices renum*—which possess great resemblance to the scars occurring after hemorrhagic infarcts. Therefore, differentiation may be difficult

when valvular lesion of the heart coexists and no fresh proliferations are demonstrable. The recent hyperplasias at first appear as small, pale, gray-translucent foci; later, as more gray-white or grayish-red, slightly depressed areas. These scars usually affect only the cortical substance. Gummata are rare in the kidneys and usually quite small.

Malignant syphilis, owing to the great diversity of opinion among authorities, cannot be sharply defined. According to Lesser, it includes all cases manifesting a more or less acute character and in which recidives occur in rapid succession; the secondary period is absent or very brief; tertiary manifestations appear early in the form of cutaneous ulcerations which, in contradistinction to ordinary tertiary syphilis, are usually more diffusely distributed over the body, and most frequently assume a circular, rarer a serpiginous, character. As a rule, these ulcerations do not, as in ordinary tertiary syphilis, originate from genuine gumma-

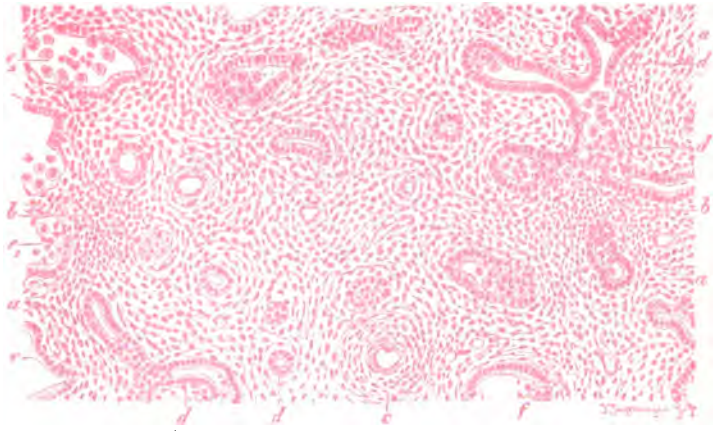

Fig. 295.—Alterations of the lungs in congenital syphilis. *a*, richly proliferating stroma; *b*, richly cellular granulation foci; *c*, artery with thickened adventitia; *d*, d_1, gland-like bronchi which in part (d_1) contain desquamated epithelia and round cells; *e*, e_1, alveoli which in part (e_1) contain desquamated epithelia and round cells. × 40. (After *Ziegler.*)

tous infiltrations, but from papulopustulous efflorescences which undergo simple disintegration. The general disturbances, especially fever, are more marked than in ordinary syphilis. Severe destructive alterations of the internal organs, nerves, osseous system, and mucous membranes analogous to those of tertiary syphilis are not infrequent even in the early stage. In spite of the frequency of the relapses and the severity of the local affections, complete recovery may result in the course of years, provided death does not result from injury of an important organ or from affections to which the greatly debilitated organism can offer no resistance.

Etiology.—It is not due to the intensity of the virus, for both benign and malignant syphilis may arise from the same source of infection, and the case from which a malignant form may develop need not be malignant in type. That there is some form of predisposition is undoubted, but its nature is still unknown. The

ordinary predisposing factors, such as alcoholism, tuberculosis, anemia, and general debility, are unquestionably of great importance, but they are not the decisive factors, since it is by no means rare for vigorous individuals to acquire it. Finger has drawn attention to the fact that individuals of generations that have long been comparatively free from syphilis acquire this severe form. On the other hand, according to the experimental investigations of Ehrlich, it is questionable in how far immunity to infectious diseases is transmissible; in syphilis especially, Profeta's law of immunity is scarcely applicable, or at most only in the first months of life, and thus far we have much less support for the assumption that corresponding inheritance in the organism still can be transmitted to further generations.

A. Buschke[1] was unable in 23 cases to find *Spirochæta pallida* in the typical developed ulcerative secondary efflorescences, either in sections, with the Giemsa method, or the dark field apparatus. Most authorities explain the nonoccurrence of spirochætæ in the lesions of tertiary syphilis by the assumption of the existence of a still unknown developmental form of the spirochætæ.

Haslund distinguishes between **galloping** and malignant syphilis. In galloping lues severe tertiary affections very rapidly develop in the internal organs, upon the mucous membranes and skin, and sometimes death occurs in the early stage, while in malignant syphilis only the skin and mucous membranes are affected, and the cutaneous lesions are to be regarded not as tertiary, but as secondary. According to Neisser, malignant syphilis is characterized by early localization in the internal organs, or the acute course is aggravated by complication with other affections. The views of other authorities, such as Mauriac, Fournier, etc., waver between these various conceptions. A few authorities distinguish as malignant syphilis those cases which are with difficulty or not at all influenced by mercurial treatment. This distinction, however, is inadmissible, because in the course of the disease in the same individual the reaction to mercury may vary. Buschke[2] differs from Lesser only in so far as he does not regard the disease phenomena as tertiary.

VARIOLA, SMALL-POX.

Small-pox belongs to the acute, contagious, general infectious diseases. The incubation stage is about two weeks. The *contagium vivum* is still unknown.[3] Probably the infectious agent first enters the blood-channels. After a febrile prodromal stage of about four days, the skin affection, the variola exanthema—a characteristic efflorescence—appears, first upon the face, later on the trunk and extremities, in the form of small, hard nodules or papules, the size of a millet seed and larger, with strongly reddened (hyperemic) periphery. The nodules are converted into pustules by the formation of fissures and cavities resulting from intense edematous imbibition of the epithelium. The nodules first contain serum; later, when the edema increases and emi-

[1] Berlin. klin. Woch., No. 1, 1911, p. 9.

[2] *Loc. cit.*, p. 6.

[3] C. Fraenkel (Krehl and Marchand's "Handb. d. allg. Path.," Bd. i, 1908; "Allg. Ætiolog.," p. 330) is inclined to accept as the cause of variola the so-called parasitic cellular inclusions minutely described by Guarnieri, in 1892, and further exhaustively investigated by von Wasielewski, in 1902.

Fig. 296.—Mild discrete small-pox in an unvaccinated girl. Note absence of lesions upon the trunk. (After *J. F. Schamberg.*)

gration of leucocytes occurs, pus is present and sometimes blood. The surface of each pustule acquires a characteristic central depression (umbilication), the depth of which depends upon the degree of suppurative involvement of the rete and cellular necrosis; usually only the epidermis and the uppermost layer of the rete are affected. If the pustule is not ruptured, desiccation begins about the twelfth day. Brown scabs develop, after exfoliation of which reticulated scars can be seen wherever the suppuration had attacked the true cutaneous tissue. Not infrequently there is intense inflammation and tissue destruction also in the papillæ and the superficial layer of the cutis, which result in necrosis and retracted whitish cicatrices: pock marks, "pitting."

Hemorrhagic variola, black small-pox, belongs to the severest cases; it is distinguished from the other form by the fact that, in the beginning of suppuration, hemorrhage occurs into the pustules.

During the period of eruption, small swellings develop in the mucosæ of the mouth, pharynx, and larynx; seldom in the trachea, bronchi, esophagus, and stomach. These are not pustules, but only analogous formations—so-called papules—solid swellings, which sometimes have a yellow color and, therefore, may easily be mistaken for pustules. The papules, which are located in the mucous membrane and are covered with a soft, loosely adherent epithelial mass, are the seat of a diphtheritic infiltration, which usually is due to cocci and not the diphtheria bacillus. In each papule a diphtheritic ulcer develops: *pharyngitis diphtherica variolosa.* (See Diphtheria, p. 525.)

The difference between the affection of the mucous membranes and the skin is that, in the external skin, owing to the denser and more resistant epithelial covering, especially of the *stratum corneum,* ulceration does not occur, but only pustulation.

The majority of fatal cases of small-pox are due to this diphtheritic pharyngitis and laryngitis, and to pulmonary affections resulting from aspiration.

CHICKEN-POX.

In **chicken-pox** (varicella) small papules with hyperemic periphery develop, accompanied by moderate fever, after a febrile prodromal period of twenty-four hours. The papules terminate in vesiculation, and also in pustulation as in genuine variola; sometimes umbilication also can be noted. After a time, however, the vesicles desiccate, usually without resulting cicatrization. Varicella also belongs to the contagious infectious diseases, the etiology of which is unknown. It frequently occurs epidemicly.

PLATE X

Mottled eruption from the arm of same case.

Severe case of scarlet fever, showing eruption at its height.
(After *Fischer.*)

SCARLET FEVER AND MEASLES.

Scarlet fever (scarlatina) and measles (rubeola, morbilli) belong to the contagious infectious diseases. Nothing is known as to the specific infectious agents.[1] The characteristic changes in scarlatina and measles consist in hyperemia of the skin, which usually disappears with death. In the severe hemorrhagic forms the hemorrhages are demonstrable also after death.

In scarlet fever the exanthema occurs in the form of countless small, closely arranged, flat or slightly elevated, round or elongated, deep-red puncta or maculæ, which are usually not larger than the head of a pin or a lentil, and surrounded by less intensely reddened zones. The eruption appears first upon the neck, quickly spreads over the trunk, upper arms, and thighs, and, finally, the whole body, the maculæ becoming confluent and imparting to the skin a diffuse dark-scarlet color. In contradistinction to measles, the face is seldom involved, and when affected the region of the mouth and chin always remain free. (Leube.) The skin is also somewhat swollen. The desquamation occurring on subsidence of the affection is partly bran-like, partly lamellar, in the latter form large sheets and even casts of the fingers and toes being exfoliated. Atypic forms of the exanthema are *scarlatina papulosa* (from this the vesicular form, *scarlatina vesiculosa,* develops) and hemorrhagic, or septic, scarlatina, in which blood is extravasated into large areas of the skin.

Scarlet fever is accompanied by catarrh of the upper respiratory passages, and often by a *pharyngitis diphtherica scarlatinosa* (see Diphtheria, p. 525), pneumonia, and not infrequently also by a nephritis. A common sequela of the pharyngeal catarrh is otitis media, which often becomes chronic and results in deafness. Occasionally endocarditis is observed, and rarer arthritis. The nephritis begins after subsidence of the exanthema, usually in the third week, and is distinguished from the ordinary parenchymatous nephritis occurring in other infectious diseases by especial intensity of the change. At the acme of scarlatinal nephritis the very characteristic phenomenon is hemorrhage. The hemorrhages usually occur into the glomerular spaces and lumina of the urinary tubules; sometimes, however, also into the substance of the kidney (parenchymatous hemorrhage). The

[1] By some authorities (Baginsky and others), streptococci are regarded as the etiologic factors. From the lymph of the axillary and inguinal lymphatic glands of 7 cases of scarlet fever, Vipond (*Arch. of Pediat.*, July, 1911, p. 564) has isolated a long, slightly motile, actively sporulating bacillus with rounded ends which stains variably with Gram's. Inoculation of the bacilli into monkeys and rabbits was followed by "typic scarlet fever, including the rash, enlarged nodes, and desquamation."

interstitial tissue is almost always involved to a certain degree, as can be recognized by the very marked relaxation, flaccidity, and laxity of the parts, whereby hemorrhagic scarlatinal nephritis is quite easily differentiated from other forms of hemorrhagic nephritis. Even when, as sometimes occurs, the hemorrhages are either entirely absent or so slight that they are easily overlooked, scarlatinal nephritis has, in many cases, something peculiar. In addition to the flaccidity already mentioned, the distinguishing feature is often a very marked degree of succulence, and sometimes—not always—a peculiar pale, almost white, marrow consistency, and frequently enormous swelling. In many cases these phenomena are due to intense emigration of round cells into the stroma, without abscess formation. When death does not take place, fatty metamorphosis of the renal epithelia occurs—in the *stadium decrementi*—from which granular atrophy may develop. Rarely scarlatinal nephritis is followed by a *pyelonephritis apostematosa.* Besides, there is always more or less intense swelling of the spleen—large, fresh spleen-tumor—sometimes *splenitis lobularis,* and frequently suppuration of the cervical lymph-glands.

Icteric discoloration of the skin is almost constantly present in scarlatina, most marked at the acme of the eruption, and then gradually declines. Urobilin and its chromogen are almost constantly present in the urine, usually most abundant about the fifth to the sixth day of the disease. Excretion of bilirubin is rare. Icterus and urobilinuria are probably closely associated. They are referable, on the one hand, to injury to the liver and, on the other, to increased disintegration of red blood-corpuscles in the skin. Thyroiditis is a rare complication.

A comparative study of old and recent statistics by Nagel[1] shows that scarlatinal ear affections have decreased in number and the character of scarlatina has become less malignant in recent years. Nagel's statistics include 750 cases. Middle-ear involvement occurred in 23 per cent., simple acute nonperforative catarrhal otitis media being most frequent, acute middle-ear suppuration, which generally was unilateral, occupying the second position. In 11.2 per cent. of the cases of middle-ear suppuration mastoid involvement, necessitating operation, occurred; only 1 of these cases, which was complicated with sinus thrombosis, terminated fatally. The prognosis of scarlatinal ear affections *quoad functionem* is unfavorable: in 81 per cent. of the cases there was permanent injury of hearing. In 2 cases labyrinthitis resulted from middle-ear suppuration without separation of continuity, simply as a result of migration of the inflammation through the diseased annular ligament of the stapes and the membrane of the round window. Aside from these two observations no parotitis, or sequestration of the labyrinth, or facial paralysis occurred among the 750 cases.

Smith[2] has collected from the literature 4771 preventive inoculations against

[1] Zeitsch. f. Ohrenhlk., Bd. 57, H. 2 and 3, p. 157.
[2] Boston Med. and Surg. Jour., 1810, clxii, 242.

scarlatina with a vaccine made from a bouillon culture of a streptococcus isolated from a case of scarlet fever and killed by heating to 60° C., according to the method described by Gabritschewsky.[1] These vaccines were used in epidemics of scarlatina in which from 15 to 70 per cent. of the uninoculated were attacked with the disease. None of those that had received 3 doses of the vaccine was affected; of 2737 others who had received 2 or more vaccinations, only 2 were attacked. Most of the cases that had received vaccine treatment ran an exceedingly mild course. Three injections of the vaccine are supposed to confer immunity for about one and one-half years.

C. Pastia[2] describes as a sign of scarlatina a very marked linear exanthema, at first rose-red, later wine-red, upon the flexor surfaces of the elbows. Usually there are several (2 to 4) such lines, between which the skin manifests the ordinary scarlet coloration. They occur early and disappear slowly, leaving a pigmented line. Apparently the lines are minute ecchymoses. The author regards this symptom as of much greater diagnostic significance than Koplik's spots in measles.

In **measles** there is an acute catarrhal affection of the nose, conjunctiva, and upper air passages: rhinitis, conjunctivitis, laryngitis, tracheitis, acute catarrhal bronchitis, which very probably stands parallel to the cutaneous exanthema. This acute catarrh often results in bronchopneumonia and frequently extends through the Eustachian tube to the middle ear, and produces a purulent otitis media.

The incubation period is about ten days, and the prodromal stage from three to five days. The exanthema accompanied by fever, occurs first upon the forehead and temples and soon extends to the neck, trunk, shoulders, and extremities. It appears in the form of rounded, discrete, flat or slightly elevated, bluish to yellowish-red spots the size of a lentil and larger, which blanch on pressure, showing yellowish maculæ (*morbilli læves*), or fine red papules limited to areas corresponding to the follicular openings develop (*morbilli papulosi*). The exanthema attains its acme on the first or second day after eruption (about the fifth to sixth day of the affection), remains at this stage for from twelve to twenty-four hours or less, and then fades, leaving yellowish or brownish maculæ. This is followed (beginning of the second week) by bran-like desquamation, sometimes accompanied by intense pruritus, and often continues for fourteen days from the time of eruption. Vesicular, confluent, and hemorrhagic forms also occur.

Koplik's spots upon the oral mucosa—punctiform or stellate red maculæ, from six to twenty in number, rarely more, with a bluish, slightly elevated, rounded center—are often an early diagnostic sign of measles. Biehler[3] has examined more than 1000 cases of measles for this symptom and is convinced that the spots precede

[1] Centralbl. f. Bakt., 1906, xli, 719 and 844.
[2] La Tribune méd., 1910, No. 46, p. 726.
[3] Arch. d. méd. des enf., Jan., 1911.

the eruption and are pathognomonic. They are sometimes very pale and require careful examination for their detection. In the author's cases the spots appeared as follows: 864 on the first, 42 on the second, 18 on the third, 12 on the fourth, 4 on the fifth, 2 on the sixth, 1 on the tenth, day before eruption, and 3 had none on the second day after eruption.

Sequelæ are ulcer of the cornea, nephritis, gangrene, and tuberculous meningitis and pneumonitis, the latter frequently the result of exacerbation of a latent tuberculous process.

Rubella, Rötheln, or German Measles.

Rubella is an acute febrile exanthematous infectious disease, distinct from measles and scarlet fever, the incubation period of which is from ten to twenty-one days. Three-fourths of the cases occur between the months of March and June. It was described by Bergen, in Germany, in 1752, and in England, by Maton, in 1815. While it occurs most frequently in young children, it is observed in older children, adolescents, and rarely in infants a few days old. In most instances the eruption is the first manifestation; sometimes this symptom is preceded by moderate fever (100° to 101° F.), slight catarrhal symptoms, and rarely by vomiting. Tumefaction, but not suppuration, of the cervical and mastoid lymphatic glands is the rule, and occasionally other superficial lymphatic glands are involved. The eruption, which begins on the face in the form of discrete, pale-pink spots, rapidly spreads over the body, where it usually is confluent. At first it resembles that of measles, assuming a scarlatiniform character by the second day, and generally disappearing after the third or fourth day. Desquamation, which may be absent, is of the branny type and is more profuse than in measles. The etiology is unknown.

WHOOPING-COUGH (PERTUSSIS).

Whooping-cough, *tussis convulsiva s. strangulans, s. pertussis,* is an infectious (through the sputum), contagious affection of the air passages, characterized by a peculiar paroxysmal, convulsive, stridulous cough. There are usually found, anatomicly, in addition to mild tracheitis (with very tenacious mucus upon a reddened and slightly swollen mucous membrane), bronchitis and bronchopneumonic foci. Lymphocytosis is said to be a characteristic feature in the early stage.[1] As improvement sets in, the polymorphonuclear leucocytes increase and eosinophilia is present. Statements regarding the *contagium* of this disease are insufficiently confirmed.[2]

There are three stages of the affection which are more or less distinct. The catarrhal stage not infrequently begins with coryza,

[1] Barach, Brit. Jour. of Child. Dis., May, 1910, p. 235.

[2] The Bordet-Gengou bacillus of *tussis convulsiva* has lately been reinvestigated by Menschikoff (Ref. *Der Kinderarzt,* May 5, 1910, p. 108), who found this bacterium in the sputum up to the sixth to eighth week of the disease. Moreover, the bacillus was agglutinated by the sera of pertussis convalescents.

conjunctivitis, pharyngitis, and laryngitis, and lasts for from eight to twelve days. In the convulsive stage, which lasts for from four to six weeks, the paroxysms of coughing increase in intensity and are accompanied by profuse secretion of tenacious glairy mucus, which often is tinged with blood. Epistaxis and subconjunctival hemorrhage not uncommonly occur, more rarely hemorrhage from the ear, due to rupture of the tympanum. In the third stage (*stadium decrementi*) the paroxysms of coughing become less violent and give place to a simple catarrhal cough, with more or less purulent expectoration, which lasts for from two to three weeks.

Complications which may occur are pulmonary and cutaneous emphysema, pneumothorax, bronchiectasis, otitis media, nephritis, tuberculous pneumonitis, and occasionally miliary tuberculosis (from preexisting tuberculous foci). Hemorrhagic meningitis, encephalitis and myelitis, and polyneuritis rarely are observed.

TYPHUS FEVER.

Typhus exanthematicus, petechial typhus (typhus, spotted, maculated, hospital, jail, ship, or putrid fever), is a severe epidemic, contagious, infectious disease of unknown origin,[1] which resembles typhoid fever only in the depressive states of the nervous system. Typhus, or petechial, fever derives its name from the countless cutaneous hyperemic foci and *petechiæ* occurring upon the trunk, and especially the extensor surfaces of the extremities; these are much more numerous than in typhoid fever. Except the alterations occurring in the acute infectious diseases in general (spleen-tumor, degeneration of the myocardium, etc.), typhus fever is accompanied by no characteristic anatomic changes. Aside from other complications (pneumonia, nephritis, etc.), a very violent acute catarrhal enteritis is sometimes observed. The disease occurs principally under especially unfavorable hygienic conditions, and is, therefore, called "hunger typhus" and "war typhus."

Brill's disease[2] is a fever of short duration in which the Widal reaction is absent and no specific micro-organisms have been found. It has been suggested that it is a mild form of typhus. "The erruption, the abrupt beginning, the duration, the abrupt or rapid ending and short convalescence, all point to an invading organism which is soon destroyed and does not linger for weeks or months like the typhoid bacillus."

[1] A diplobacillus which is agglutinated by the patient's serum has recently been described by M. Rabinowitsch (*Centbl. f. Bakt.*, Orig.. Bd. 52, p. 173). Some authorities assert that the infectious material is conveyed by the bite of the body louse.

[2] Amer. Jour. Med. Sci., April, 1910.

ROCKY MOUNTAIN, SPOTTED, OR TICK, FEVER.

Rocky mountain fever is an acute, noncontagious, infectious exanthematous disease, the causative agent of which is unknown, occurring at an average altitude of from 3000 to 4000 feet in the States of Idaho, Montana, Nevada, Oregon, and Wyoming, especially in the Bitter Root Valley of Montana. It is said to be conveyed by the bite of a species of tick: *Dermacentor (salmoni) occidentalis*[1] (see Figs. 297 and 298) in a manner similar to African recurrent fever (*q.v.*). Statements asserting the etiologic factor to be a parasite, designated as *Piroplasma hominis*, invading the red blood-corpuscles have not been confirmed. Animal



Fig. 297.—Dermacentor occidentalis. Male. Dorsal aspect. (After *Castellani and Chalmers.*)

experiments of Ricketts,[2] however, seem to indicate that the virus is intimately connected with the blood. The blood is deprived of its virulence by heating to 50° C., drying in vacuum for twenty-four hours, and filtration through a Berkefeld filter. Ricketts and Gomez[3] found in the ticks and their ova enormous numbers of bipolar bacilli resembling the bacilli of hemorrhagic septicemia.

The disease occurs principally in the spring and early summer, attacking persons of from 15 to 50 years of age who work in the open and are, therefore, exposed to the bites of ticks. The period of incubation is between three and ten days. The onset occurs either suddenly or after

[1] H. T. Ricketts, Jour. Amer. Med. Assoc., xlix, 1907, Nos. 1 and 15; lii, No. 5.
[2] *Ibid.*
[3] *Ibid.*

a variable prodromal period, with chill followed by high fever of remittent type, severe drawing pains in the limbs and muscle tenderness, articular swelling, epistaxis, and constipation. Icterus of mild or moderate degree is also present. In severe cases gangrene of the fingers, toes, and scrotum may occur, and in fatal cases violent vomiting and lobular pneumonia.

The fever reaches its acme (39.5° to 41° C.) between the eighth and twelfth day, then gradually declines, reaching normal or subnormal on the fourteenth to eighteenth day. The temperature generally remains subnormal for a few days after decline of the fever. Consciousness is usually retained throughout the affection, and even in fatal cases up to a few hours before death.



Fig. 298.—Dermacentor occidentalis. Female. Dorsal aspect. (After *Castellani and Chalmers.*)

Eruption. Mild cases may progress without the exanthema. Usually, however, it appears on the third day, first upon the wrists and knuckles, then the arms, legs, forehead, back, and chest, and last upon the abdomen. At first bright-red, pinhead- to pea- sized, nonelevated maculæ are observed, which soon become darker, sometimes almost purple, giving a marbled appearance to the skin. After six to ten days the maculæ assume a petechial character. While the eruption begins to disappear with defervescence, remnants of it can be noted for weeks and months. Desquamation, which usually is mild, begins with convalescence and extends over the whole body.

The blood shows reduction of the red blood-corpuscles and increase of the leucocytes, especially the mononuclear forms.

Convalescence may be very protracted (ten to twelve weeks or longer).

The mortality is high; according to Scheube,[1] about 70 per cent. in 121 cases in the Bitter Root Valley region. Death generally occurs on the sixth to twelfth day. In Nevada, Idaho, and Oregon the disease is not so severe as in Montana.

CEREBROSPINAL MENINGITIS.

Epidemic cerebrospinal meningitis (*meningitis cerebrospinalis epidemica*) is a purulent inflammation of the arachnoid of the brain and spinal cord. The affection is generally regarded as a primary (genuine or idiopathic) process, though on questionable grounds, since the same causative agent often is found at the same time in the lungs, nasal and tympanic cavities, and, therefore, it should be designated rather as a transmitted or metastatic inflammation. The exudate is seropurulent, fibrinopurulent, or purely purulent, follows the sulci and veins, and occurs most intensely at the base in the region of the pons, medulla, and spinal cord, while the ordinary purulent meningitides occur chiefly upon the convexity. It sometimes extends along the vessels and pial sheaths into the brain substance, where it produces inflammatory edema and softening (meningoencephalitis), and occasionally abscess. If it extends to the choroid plexus, the ventricles also become filled with exudate.

It is an acute endemic disease which may become epidemic. The causative agent of the epidemic form is the *Diplococcus meningitidis sive intracellularis* (Weichselbaum-Jäger). Fränkel's *Diplococcus lanceolatus, Staphylococcus aureus, Streptococcus pyogenes* and *mucosus* are found in the exudate of some of the sporadic cases and have been designated as the etiologic factors, though these probably are secondary infections. The *Diplococcus* (*meningococcus*) *intracellularis,* which in intracellular grouping, morphology, and staining properties resembles the gonococcus, is observed chiefly in the exudate (often within the polynuclear leucocytes), but occasionally also in the circulating blood, in the nasal cavity and accessory sinuses, and in the metastatic suppurations which not infrequently occur in this disease. As in typhoid and diphtheria, there are also healthy "cocci-carriers."

CHOLERA.

Cholera nostras, *cholera morbus, enterocatharsis,* and *cholera infantum* are affections occurring usually in the hot summer months, often epidemic, which attack chiefly small children. They are acute disorders of the gastrointestinal canal which, in their most violent forms, may so closely resemble the clinic course and anatomic findings of Asiatic cholera that the latter can be differentiated only by demonstration of the cholera bacillus. At necropsy on children there is found, in addition

[1] "Die Krankheiten der Warmen Länder," 4te Auf., p. 498. Jena: Gustav Fischer, 1910.

to slight swelling of the intestinal mucosa, only somewhat intense tumefaction of the follicles and of the mesenteric glands.

The cause of *cholera nostras* probably is not invariable; at all events, the specific comma bacillus does not occur in this affection. In *cholera infantum* it is very probable that the enormous increase of saprophytes occurring in the summer months in the milk employed in the feeding of children results in decomposition and the formation of toxins, which suffice to produce all the phenomena. The Shiga-Kruse bacillus has been isolated from the feces in cases of summer diarrhea in infants.

RABIES.

Rabies, *hydrophobia, lyssa,* canine madness (water-fright), is an infectious disease, usually of rapid onset, which almost always terminates fatally, and is transmitted to man by the wolf, dog, fox, swine, cat, sheep, cow, etc. The centers of respiration and deglutition especially are attacked, resulting in spasms or paralysis. The period of incubation varies from ten days to a year, perhaps longer, the average being about one to two months. Two types are observed: an excited or furious form; a quiet, silent, or paralytic form. Except the Negri bodies described below, no characteristic anatomic or histologic changes are found at necropsy or in sections. The meninges, brain, and spinal cord are congested, and the cerebrospinal fluid increased. Infiltration with round cells is observed around the motor nuclei of the pons and cord, constituting the "rabic tubercles" of Babes, which, according to this authority, are diagnostic. The peripheral ganglia also show degeneration. Exceptionally the blood of rabic animals has been found to be pathogenic. The blood- and lung- juices of dogs are said to show a relative polynucleosis, the blood showing 90 per cent. Noguchi[1] cultivated very minute pleomorphic chromatoid bodies, the smallest just visible with a Zeiss apochromatic 2 mm. lens. Round or oval nucleated bodies, 1 to 12 μ in size, surrounded by a membrane also were obtained, which multiplied by division or budding and exhibited the characters of protozoa. Inoculation of these bodies produced rabies. Experimentation has shown that the poison is connected principally with the nervous system, especially the spinal cord. It is propagated from the nerve-endings along the nerve-trunks to the central nervous system, where it attacks and finally destroys the nerve-cells. An extra- and intra- cellular toxin also is said to be produced, to which, according to several authorities, some of the clinic phenomena are due.

The virus[2] of rabies is of two kinds: "street" virus and "fixed"

[1] Jour. Exp. Med., 1913, xvii, p. 314.

[2] "Facts and Problems of Rabies." A. M. Stimson. Bull. No. 65, Hyg. Lab. U. S. Pub. Health and Mar.-Hosp. Serv., Wash., p. 20.

virus. "Street" virus is virulent nervous tissue as met with in the natural disease. Its virulence is very variable, and when inoculated subdurally into rabbits it produces the symptoms of rabies at a variable period of more than fourteen days, as a rule. The "fixed" virus is modified from the "street" virus by passage through a long series of rabbits. In this way the virulence is increased for these animals, so that they finally take the disease after a certain "fixed" period of incubation. This form of the virus, after attenuation by desiccation, is used in the Pasteur treatment.

Negri[1] found within the nerve-cells in various portions of the central nervous system (cord, cerebrum, cerebellum, pons, basal ganglia, sometimes also in the spinal ganglia) of animals which had died of rabies sharply defined, round or oval "micro-organisms" (*Neuroryctes hydrophobiæ*) from 1 to 25 μ, average 4 to 10 μ, in diameter, which he considered to be sporozoa, with which view Golgi and Grassi concur. They consist of a mass of protoplasm containing inner bodies which segment and form "spores." They are of constant occurrence in all stages, and generally regarded as peculiar to this affection. Negri bodies were found in all animals, whether they had died of the natural or artificially induced infection (bite of a rabid animal or laboratory experiment), but they were not demonstrable in normal animals or in such as had died of other infections. They were observed also in brain-tissue that had undergone putrefactive changes or had been placed in glycerin. In subdural infection they were found most frequently in Ammon's horn, within the cells or their protoplasmic processes. The bodies were not observed, however, in all portions of the nervous system—a fact which led Negri to assume that the parasites probably occur in another form in these localities. Negri found these so-called sporozoa also in the brain of a woman who had died of rabies.

Keirle[2] states that these bodies of Negri have no causal relation to rabies, but are only the large phagocytes (macrophages) of M. Metchnikoff which remove worn-out nerve-tissue.

GASEOUS EMPHYSEMA.

Gaseous phlegmon, or **emphysematous gangrene,** is a phlegmonous process due to a specific bacillus. It is characterized especially by gaseous distention of the affected tissues, with which frequently are associated suppuration, gangrenous disintegration, the formation of large blebs filled with bloody serum, and the presence of a sweetish,

[1] Soc. med. chirurg. di Pavia, 24, iii, 1903; cited in Centbl. f. Bakt., Abt. I, Referate, 1903, xxxiii, p. 613.

[2] "Studies in Rabies," Baltimore, 1909, p. 328.

foul odor. Extension occurs by direct continuity, and in some instances may be so rapid as to cause death within from three to four days after infection. In pure infection the connective and muscular tissues are loosened and distended with gas, and elastic and crepitant on palpation; if, however, as often is the case, the bacillus is associated with other bacteria, *e.g.*, pyogenic cocci, purulent inflammation predominates. Cloudy, thin-purulent, foamy exudation occurs also in pure infection with the bacillus alone, *e.g.*, in meningitis and peritonitis.

The cause of gaseous phlegmon is the *Bacillus aërogenes capsulatus* (Welch), *Bacillus phlegmonis emphysematosæ* (E. Fränkel), a short, thick, obligate anaërobic, encapsulated, nonmotile, spore-bearing, Gram-positive rod resembling the bacillus of anthrax and, like the latter, often is arranged in chains. This microorganism was independently discovered almost synchronously by Welch (1892) and E. Fränkel (1893)—by the former in connection with post-mortem gas formation in the blood within the heart and vessels; by the latter in connection with gaseous phlegmon. In cultures it produces an inflammable gas composed of H, CO_2, and N. Inoculation into certain animals (rabbits, guinea-pigs, etc.) produces "gaseous phlegmon." The bacillus also manifests hemolytic action. Outside the body the bacillus is found in the soil, dust, upon splinters of wood, etc.

The bacillus may gain admission to the body from the intestinal canal (through ulcers of the mucosa), or through cutaneous lesions, especially in complicated trauma. In infection of the gravid or puerperal uterus, it may enter the uterine cavity and distend this viscus with gas: *tympania uteri*, and also invade the fetal tissues and the walls of the uterus. Likewise, it may invade the urinary tract and also the tissues of the vagina (lymph-vessels) and produce gas cysts: *colpohyperplasia cystica*. Although the richly oxygenated blood offers unfavorable conditions for the development of the bacillus, it has been isolated from this source (in puerperal infection, etc.).

In certain cases at necropsy, especially after abdominal operations, many organs and tissues are found filled with gas vesicles or large bubbles and present the condition designated as "foamy organs," *i.e.*, emphysematous infiltration of the parenchyma of the spleen, liver, kidneys, brain, the mucous membranes of the stomach, intestine, particularly the ileum, and the region of the urinary bladder, etc. If the bubbles are very small, they appear as minute, white puncta and may be mistaken for miliary pathologic foci; if they are large, the organs crepitate on palpation. The blood also, particularly in the veins, is frequently foamy. In these instances a gas-forming bacillus, most frequently the *Bacillus aërogenes capsulatus*, must have been present and rapidly spread to all parts of the body after death. The bacillus may enter from the bile passages, the intestinal mucosa, or the genitourinary tract, but invasion occurs chiefly by the blood-channels. It is a question, however, how far invasion takes place during life, during the agony, or *post mortem*. Gas formation in the tissues may be due also to the *Bacillus coli* and *proteus*.

Chronic gaseous emphysema, *pneumatosis cystoides*, is a form of gaseous emphysema which develops slowly and generally persists for a long time. A. Nowicki,[1] after examination of 7 cases of emphysematous colpitis and 3 cases of

[1] Virchow's Archiv, Bd. 198, p. 143.

gas cysts of the digestive tract, concludes that separation of continuity occurs as a result of entrance of gas principally into the vessel and lymphatic spaces, and also into the true tissues. The gas vesicles, the characteristic constituents of vesicular emphysema, originate chiefly from lymphatic spaces formed by laceration of the tissues by the gas. The peculiar giant cells present are, according to this author, derived from endothelium of these spaces; less often, perhaps, they may originate from the epithelium of the *portio vaginalis*. Of the origin of the gas the author speaks with reserve; he does not regard it as a product of anaërobic gas-forming micro-organisms. The development of gaseous emphysema is favored by circulatory disturbances, especially passive hyperemia—for example, from cardiac insufficiency—or by local causes, as in pregnancy (in the vagina) or in vascular occlusion due to torsion, volvulus of the intestine, etc. The process may disappear in time, leaving only cicatricial thickenings of the attacked tissue.

Fig. 299.—Vincent's bacilli fusiformes and spirilla. (Leitz oil immersion, 1/12; ocular, iv.) × 1000.

A peculiar form of traumatic infection is **hospital gangrene,** *gangræna nosocomialis,* an inflammatory process, rapidly followed by gangrenous destruction of tissue, which may occur in connection with very small wounds, *e.g.,* after leech-bites. In preantiseptic days it frequently resulted in death from general infection. The margins of the wound become gangrenous, putrid, and transformed into a dirty, yellow-gray, discolored mass.

The etiologic factor is assumed to be a large fusiform anaërobic

bacillus occurring in symbiosis with spirochætæ. The bacilli are irregular in size, from 6 to 12 μ in length and 1 to 1.5 μ in width, mostly straight, sometimes slightly bent, and frequently pointed at both ends: spindle-shaped; hence *Bacillus fusiformis.* They can be cultivated in fluid and solid media containing human blood-serum, upon which they grow slowly with development of a fetid odor. According to Gross and Graupner, the bacilli are motile, each bacillus, according to the latter authority, being provided with four flagella. It usually is Gram-negative. Stained with carbol-fuchsin, numerous light points are seen in the interior which are regarded as involution changes. The spirochætæ are actively motile, very delicate, often very long, show numerous spiral turns, and stain faintly. They also can be cultivated upon the same media as the *Bacillus fusiformis.* (See Fig. 299.)

The same findings—fusiform bacilli and spirochætæ—are observed in certain cases of ulcerative stomatitis, designated as Vincent's angina or Plaut-Bernheim ulcer (see p. 529), and also in noma (see p. 753), pulmonary gangrene, putrid pleuritis, dental and other abscesses, chronic otitis media, meningitis, suppurative periostitis, tropic phagedenism, in syphilitic ulcers, ecthyma, furuncles, phlegmonous processes, and in conjunction with the diphtheria bacillus in mixed cases of angina and diphtheria. It is observed also in otherwise healthy persons with carious teeth, upon the gums (dental tartar) and pharynx. Outside the body the bacilli are said to occur in the soil.

MALIGNANT EDEMA.

Malignant edema is really a disease of certain animals (guinea-pigs, mice, etc.) and very rarely is observed in man in connection with traumatism, especially in debilitated subjects. It is chiefly an affection of the subcutaneous tissue, manifested by progressive edema, putrid, gangrenous disintegration, and emphysema due to the development of a foul-smelling gas. The latter phenomenon is said not to be due to the specific bacillus described below, but to the *Bacillus aërogenes.* (See p. 571.) The fatal action is regarded as a toxic effect.

The causative agent is a slender, actively motile, Gram-positive, anaërobic, gas-forming, sporogenous bacillus (*Bacillus œdematis maligna*), which often forms long chains. The spores are both central and polar. The bacilli are found in the disease focus, generally associated with other micro-organisms. Outside the body the bacilli or their spores are abundant in garden earth, street dust, etc. They are found also in the normal intestinal contents, whence, in the unopened cadaver, they may enter the adjacent tissues and the blood. Pure cultures inoculated subcutaneously into guinea-pigs produce edematous sanguinolent infiltration of the tissues.

RHINOSCLEROMA.

Rhinoscleroma is a very chronic, probably contagious, endemic, nonsuppurative infectious granulation process (infectious granuloma), resulting in diffuse thickening, cicatrization, and stenosis of the respiratory passages, which finally produce death by suffocation. In severe cases the whole larynx may be infiltrated and converted into a rigid stenosed canal. Membranous cicatrices also may develop. The disease generally begins in the nasal mucous membrane, extending slowly to the skin of the nose and upper lip, and to the mucous membranes of the nasopharynx, larynx, trachea, and, occasionally, also to the bronchi. In the larynx the lower portion usually is symmetricly involved. The changes are manifested either in the form of hard, grayish-white or pale-red, roughened, nodulated or lobulated elevations or as a smooth, diffuse, uniform infiltration. The neoplasms manifest a tendency to cicatricial contraction, producing irregularities and dense induration of the parts. The epithelial structures in the deeper parts of the affected areas undergo atrophy, while the superficial epithelium may proliferate atypicly or be transformed into the squamous variety (in the bronchi).

Microscopicly, the neoplasms are composed of numerous small, round cells with which are mingled large spheric or oval, clear hyaloid (degenerated), so-called Mikulicz cells, which characterize the histologic structure. These Mikulicz cells, which are said to owe their morphologic characters to the action of specific bacilli, appear distended with a clear protoplasm penetrated by a fine reticulum, and possess a dark, serrated, and often eccentricly located nucleus; they sometimes are grouped in large numbers beneath the epithelial covering of the mucous membrane. The scleromatous tissue not infrequently contains also quite numerous "hyaline cells," *i.e.,* cells inclosing so-called Russell bodies.

The cause of the disease is very probably the *Bacillus rhinoscleromatis* (von Frisch), which closely resembles Friedlaender's pneumobacillus, and, like the latter, may possess a capsule. The bacilli are found in the affected tissues, especially within Mikulicz's cells, and also in the adjacent lymph-glands.

MUMPS.

Parotitis epidemica, mumps, *cynanche parotidæa,* is a primary idiopathic, contagious, generally benign infectious disease occurring epidemicly and sporadicly, affecting children and young adults, chiefly boys. Infants and the aged are exempt. The affection generally progresses with mild fever and is characterized by violent catarrhal inflammation of the excretory duct and acute serous or cellular inflammation

of the interstitial tissues of the parotid as well as of the surrounding structures. This causes a doughy, usually bilateral, swelling of the parotid gland and adjacent parts which, after a time (eight to twelve days), almost always returns to the normal state. Occasionally, the left parotid is alone or more markedly affected. Rarely, the other salivary glands (submaxillary and sublingual) are involved. The process rarely terminates in suppuration, gangrene, or chronic thickening. The affection probably is caused by a small streptococcus which, very likely, enters from the oral cavity through Steno's duct. Mumps sometimes produces a similar metastatic affection of one or both testes: *orchitis parotidæa,* especially in adults, rarely in boys, and also of the ovaries, mammæ, and female external genitalia. The testis usually shows mild hydrocele; rarely it atrophies. Parotitis has been observed also after ovariotomy.

The epidemic form is distinguished from metastatic (secondary) parotitis (*parotitis phlegmonosa*), which occurs in various infectious diseases (pyemia, diphtheria, scarlatina, Asiatic cholera, typhoid fever, etc.), streptococci and staphylococci entering from the mouth or in emboli, and usually terminates in suppuration, rarer in resolution. The process may originate also by propagation from an inflammation in the oral cavity or adjacent organs (lymph-glands, maxillary articulation, etc.). The inflammation generally extends to the surrounding parts, and the whole region is infiltrated and intensely indurated. There is usually a purulent catarrh of Steno's duct, often with occlusion, and cellular proliferation in the stroma of the gland. The interstitial tissue is frequently the seat of phlegmonous infiltration, and circumscribed abscesses and sequestration of the parenchyma sometimes occur. Not rarely after breaking down of the fascia, cribriform perforation occurs through the skin, usually anteriorly. Occasionally, the inflammation extends to the facialis, causing paralysis of this nerve after healing, or the inflammation, following the facialis, enters the middle ear (resulting in deafness) or along the trigeminus to the organs within the skull. Sometimes phlebitis occurs in connection with abscess, which may extend to the jugular and the sinuses at the base of the skull, especially the cavernous sinus.

CORYZA.

Coryza, *rhinitis,* catarrh or common cold, is a pronouncedly contagious affection, an acute catarrhal inflammation of the nasal mucous membrane, frequently accompanied by fever and headache. The process begins with hyperemic swelling of the nasal and neighboring mucosæ (conjunctivæ, etc.), followed by a partly serous, partly mucoid, exuda-

tion, to which gradually are added desquamated epithelia and leucocytes. The primarily watery secretion later becomes thick and viscid. The irritant action of the secretion causes swelling of the nostrils and upper lip, and sometimes erosions, which become covered with scabs. The inflammation often extends to the adjacent mucous membranes, especially of the neighboring cavities of the nose, pharynx (Eustachian tube to middle ear), and larynx.

The question whether coryza is always an infectious disease cannot as yet be answered with certainty. It is known that coryza occurs in "colds" of various kinds, on internal use of iodine, and also after the action of various mechanic, thermic, and chemic influences. The presence in the normal nasal cavity of pathogenic bacteria (pneumococci, streptococcus and staphylococcus pyogenes, pneumobacillus, etc.), which ordinarily are locally harmless, is of importance from an etiologic standpoint, since these micro-organisms may acquire aggressive properties when the circulatory and secretory conditions of the mucous membranes are altered by any form of irritation. From this point of view a "cold" may be regarded as at least a predisposing factor in the development of coryza. One attack produces a greater susceptibility to new attacks. (See Influenza, p. 522.)

PELLAGRA.

Pellagra,[1] maidism,[2] Asturian leprosy, Alpine scurvy, is a chronic, usually nonfebrile affection characterized by cutaneous, gastrointestinal, and nervous manifestations which appear in the spring and summer, subside more or less in the winter season, and recur the following spring and summer. The remissions and exacerbations may recur annually for from ten to fifteen, even thirty, years or longer. The disease may run a rapid course and end fatally within from two to three years; as a rule, however, it is an affection of long duration. While the disease may affect all classes and occur at all ages, from infancy (rare) to old age, it is almost always observed in field laborers between the ages of 20 and 50 years. Jews are said rarely to be attacked. According to Sambon, it may be acquired *in utero.*

The malady is endemic in southern Europe, especially upper Italy (Lombardy, where, in 1881, the number of cases was 56,000); north Africa, Asia Minor, India, Australasia, South America (Brazil, Argentina), West Indies, and Mexico, and within recent years has been recognized in certain parts of the United States.

---

[1] *Pella:* skin, *agra:* rough; or πέλλα: skin, ἄγρα: seizure.
[2] *Maidis:* maize.

According to Sandwith, the disease appeared in the Old World about 1700,[1] with the introduction of American corn.[2] Frapolli, however, writing in 1771, states that it was described as early as 1578 under the name of *Pellarella.* In 1762 it was described in Spain as *"Mal de la Rosa,"* by Casal, who stated that the disease had been endemic in Ovideo since 1735. In 1830 it was well known in France, and in 1833 it appeared in Roumania, and more recently in Hungary, Russia, Portugal, and the island of Corfu (1839). In the United States cases were reported by Tyler and Gray, in 1864, and by Sherwell, in 1883; its occurrence in this country being definitely established by Harris, in 1902. In 1906 an epidemic occurred in the Mt. Vernon (Ala.) State Hospital for Colored Insane, of which a most excellent description was given by Searcy,[3] and cases were later observed in a number of other Southern States. Inquiries made in 1908 by C. F. Williams, Health Officer of the State of South Carolina, revealed that over 1000 cases of the disease had been recognized in thirteen States, of which about 500 were in South Carolina, 250 each in Georgia and Alabama, 75 in North Carolina, and a lesser number in Tennessee, Florida, and Mississippi. Cases have been reported also from New York (King's Co.), Pennsylvania (Dixmont), Kansas (Topeka and Parsons), and Illinois (Cook Co.). In August, 1909, about 175 cases were observed in the Peoria (Ill.) State Hospital, and a few cases also in the Elgin (Ill.) State Hospital. At the present time (1914), it may be stated that there is reason to believe the disease exists in at least 26 States, and that the total number of cases amounts to 20,000.

The affection begins with general weakness, capricious appetite, headache, vertigo, mental hebetude, pain in the spine and joints, and gastrointestinal disturbances (constipation, gastralgia, abdominal distention, eructation of gas, nausea, and vomiting). The tongue is at first coated, but later desquamation of the epithelium occurs, producing a reddened and raw appearance. This condition often extends to the buccal mucous membrane, gums (gingivitis), palate, and esophagus, and is attended by profuse salivation and not infrequently mucous patches. The gums frequently are swollen and bleed readily. The primary constipation subsequently gives place to diarrhea and in some cases dysentery, with which amebæ often are associated, whether accidentally or etiologicly is still unsettled. As the disease progresses, disturbances of

[1] According to Castellani and Chalmers ("Man. of Trop. Med.," Wood & Co., 1910, p. 906), Ramazzini described the disease, in 1700, in his treatise: "Diseases of the Working Classes."

[2] Columbus brought maize to Spain about the year 1520. Indeed, there is historic evidence that maize was cultivated in the Old World centuries before the discovery of America. A representation of the plant found in an ancient Chinese book in the royal library in Paris and the alleged discovery of some grains of it in the cellars of ancient houses in Athens have led some to suppose that it is a native of the East. It is said, furthermore, that maize was brought to Spain by the Arabs in the thirteenth century; that it had been cultivated from a very ancient period in the Asiatic islands ("Corn of Asia"), and that it was received thence into China, and so passed westward into India and Turkey ("Turkey Corn"). Gerhard thinks it came from the East and was reintroduced into Europe from America.

[3] Jour. Amer. Med. Assoc., July 6, 1907, p. 37.

the cerebrospinal system become manifest. In the terminal stages colliquative diarrhea, great exhaustion, emaciation, paralysis, and stupor occur which end in death.

A severe acute form, characterized by marked hyperpyrexia, delirium, trismus, torticollis, and opisthotonos, is described as "pellagra typhus," which may cause death within a few days.

The **cutaneous disturbance** (dermatitis), which appears quite suddenly shortly after onset of the disease, is erythematous in type, and manifest chiefly upon those portions of the skin exposed to the air and light—face, neck, arms, and hands, principally the backs of the latter, sometimes the palms, and also the dorsal surfaces of the feet in those who go barefoot, though covered parts (legs and chest) also may be involved. The dermatitis closely resembles that caused by severe sunburn, and is accompanied by a sensation of burning, formication, and pruritus, which are greatly aggravated by exposure to the rays of the sun; hence, the name: "sun disease" sometimes applied to the malady. The skin is sometimes swollen and tense, and small, punctate hemorrhages occasionally are observed. Vesicles containing a clear, cloudy, or blood-tinged fluid of alkaline reaction may develop and not infrequently rupture, leaving a weeping surface which may become infected and heal by scabbing. The erythematous areas are irregular in outline, usually darker at the periphery than in the central portions, and characterized by a remarkable symmetry, corresponding regions on both hands or arms or on both sides of the face or neck being involved to an almost equal extent. (See Fig. 300.) The eruption usually subsides in about two weeks, after which time desquamation, in the form of squamæ, large flakes, or lamellæ, occurs, leaving the skin indurated, roughened, fissured, and brown in color. The pigmentation in some cases may be extensive and resemble in intensity the discoloration observed in Addison's disease. The skin may also undergo atrophy and assume a parchment-like character. Bromidrosis is noted in some cases.

A form of the disease without cutaneous lesions has been described as *pellagra sine pellagra.*

The disorders of the **nervous system** are manifest by cerebrospinal symptoms: sensory disturbances (paresthesias, hyperesthesia); increased tendon reflexes, especially the plantar and patellar, which are manifest at an early stage; muscular tremors and spasms; muscular atrophy; epileptic and cataleptic phenomena; hallucinations of vision and hearing; Babinski sign, especially in pellagrous dementia, but also in chronic pellagra without psychic disturbance. In the later stages general paralysis, mental disorders (mania, melancholia with suicidal tendency, especially by drowning, "hydromania"), and complete dementia supervene.

Fig. 300.—Mild erythema involving the hands, forearms, and neck. (From *Bull. Ill. State Board of Health.*)

Aside from atrophic, fatty, and pigmentary degeneration, the internal organs show no specific changes *post mortem*. The intestinal mucosa is congested, and the lower portion of the ileum presents evidence of folliculitis. The colon frequently is the seat of ulcers which may perforate and cause death from peritonitis. Of 18 cases coming to necropsy in the Peoria (Ill.) State Hospital, 12, or 66⅔ per cent., presented colonic ulceration. As protozoa (amebæ, flagellata, and encysted forms) were found in the feces in 84.8 per cent. of the 175 cases observed in this institution, it is possible that the intestinal ulcerations were amebic in origin. In the nervous system, leptomeningitis, perivascular round-celled infiltration, degeneration, and pigmentation of the brain and spinal cells, and degeneration of the posterior and lateral columns of the spinal cord have been described. Changes are said regularly to occur in the suprarenal glands. Cultures from the blood, spinal fluid, and spleen are negative. Microscopic examination of the blood is said to show increase in the number of large mononucleated leucocytes.

The **etiology** is obscure. It has been ascribed to syphilis, alcohol, insolation, bad water, garlic, etc. It has been compared to beriberi (see p. 581), in the belief that it is due to defective diet: insufficient proteid. By many authorities the disease has long been regarded as due to improperly cured corn, to the defectively prepared meal, or to toxins present in fermented corn. This view, however, is untenable, because the areas of pellagra endemicity and maize culture do not correspond. Others state that the causative factors are species of aspergillus (*A. fumigatus* and *flavescens*) and penicillium (*P. glaucum*) growing upon maize. Two species of penicillium are described, one of which is said to cause the chronic variety of the affection, the other the subacute forms. The *Aspergillus fumigatus* is said to produce those symptoms characteristic of pellagrous typhus. These fungi are supposed to produce progressive intoxication through the agency of toxins liberated in the gastrointestinal tract, and the occurrence of the affection in the spring and summer is explained on the ground that the *Aspergillus fumigatus* loses its toxicity in winter. Other investigators attribute the disease to toxins elaborated by the action of micro-organisms (*Bacillus coli*) upon corn foodstuffs in the intestinal canal, and also to autointoxication. Quite recently[1] it has been stated that the malady is caused by a protozoön transmitted by the bite of an insect: *Simulium reptans* (Sambon).

According to L. Sofer,[2] pellagra, like fagopyrism (the occurrence of pathologic alterations in white and spotted animals that have been fed on buck-

[1] British Medical Journal, May 21, 1910, p. 1255.
[2] Die Heilkunde, Nov., 1910.

wheat and at the same time exposed to sunlight), belongs to those diseases in the development of which the influence of light seems to be necessary. Since the discovery by Tappeiner of the photobiologic sensibilisators, it is assumed that such substances play a rôle in the origin of pellagra. It is possible that a sensibilisator is introduced into the body from without with the food and then manifests its action. Pellagra and fagopyrism probably belong here (exogenous sensibilization). Further, sensibilisators (endogenous sensibilization) originate in the organism. Probably both factors play a rôle in pellagra. Finally, it is possible that toxins are formed under the influence of the sensibilisators. Experiments made by Raubitschek upon several hundred white and colored mice showed that animals that had been kept in the dark were able to endure without injury all forms of food, but that all white mice that received only maize or rice and were exposed to light emaciated and died. Animals that had already sickened under the influence of food and sunlight readily recovered when placed in the dark without change of diet. Raubitschek, therefore, concludes that feeding with maize of good or poor quality does not of itself exert pellagrogenous action, but that under the influence of light and preponderance of maize diet a toxin develops, probably from the alcoholic constituents of the grain.

BERIBERI (KAKKE).

Beriberi,[1] or kakke (*"polyneuritis epidemica"*), is a specific peripheral neuritis,[2] characterized particularly by disturbances in sensation, motility, and circulation. It occurs among all classes and at all ages, but chiefly between the 15th to 30th year, in China, Japan, India, Africa, the Philippines, Panama, and other tropic and subtropic countries.

The history of kakke can be traced with certainty only to the sixth century, the word kakke not coming into general use until about 750 A. D. In Japan the word was first used about the seventh century. The earliest records of beriberi reached Europe about the seventeenth century, but scientific investigation of the disease did not begin until about thirty years ago, when Baelz and Scheube recognized it as a polyneuritis.

Beriberi and kakke were shown by Scheube, K. Miura,[3] and the Japanese Commission to Batavia to be clinicly and pathologicoanatomicly identic. Koch, however, was of the opinion that they are two etiologicly different diseases, because in his experience in Batavia and Africa the acute cases of beriberi almost without exception died within a short time, while the mild and slowly developing forms took an entirely different course. Nocht also regards beriberi as a group of affections due

[1] According to K. Miura, the name beriberi has hitherto been referred to the Hindostani "beri": sheep. Dürck, however, quotes Hoffman, according to whom the word "beri" signifies to "fetter" or "shackle," because beriberi patients walk as though they were fettered. The Japanese word "kakke" comes from China and signifies "foot vapor" or "foot disease," since it was assumed that a gaseous pathogenic agent first entered the legs.

[2] Recent investigations in Japan have shown that, to a certain extent, the alterations in the nerves are mainly secondary to changes in the vascular system.

[3] "Ergebnisse d. inn. Med. u. Kinderhlk.," iv, p. 282.

to different causes. Whether the so-called "epidemic dropsy" is identic with beriberi is still undecided. According to F. Pearse, the two diseases cannot with certainty be clinicly and pathologicoanatomicly distinguished, because both are accompanied by edema, cardiac disturbance, and affection of the peripheral nerves. Manson, however, claims that an eruption occurs in "epidemic dropsy," which is not the case in beriberi. McLeod regards epidemic dropsy as a distinct disease.

Disturbance of **sensation.** The hypesthesia in beriberi develops in four different regions of the body in the following order of frequency:—

1. Upon the dorsum of the feet or upon the legs the hypesthesia usually extends upward, sometimes only on the inner or on the outer side, more frequently, however, on both the outer and inner side, and apparently without accurately following the region of nerve distribution. The hypesthesia sometimes extends nearly to the inguinal fold, and peripherally toward the soles of the feet.

2. In the finger-tips the hypesthesia generally begins in the ball of the finger, and, spreading to the wrist-joint, reaches the dorsum of the hand, forearm, and rarer the upper arm. Exceptionally, it starts from the dorsal surface of the thumb and remains for a long time stationary.

3. In the region of the navel the hypesthesia begins with preference during pregnancy or *post partum,* but is present also in other cases. It extends upward, dome-like, toward the epigastrium and chest, and may ascend to about the second rib, while below it reaches the region of the pubis and inguinal fold.

4. In the region of the mouth the hypesthesia begins in the lower and upper lips and remains limited to the outer skin and the red of the lips, or it spreads outward over the face. Sometimes there is hypesthesia of the eyebrows and scalp.

The hypesthetic areas in the above-mentioned four localities are usually separated by more or less intact areas; rarely they merge. Paresthesia also is often observed in the hypesthetic areas.

Disturbance of **motility** is first shown by heaviness of the legs, tension in the calves, and shaking of the knees. The patient hobbles along, readily stumbles, and must aid himself with the hands. The motor paralysis is followed by atrophy, and when the edema disappears emaciation becomes marked.

Paralysis of the fingers and hands occurs in severe cases, and generally is less frequent than in the toes and feet. In the severest paralysis neither the hand nor the fingers can be flexed dorsally. In other cases the middle and ring fingers are flexed volarward, the index

and middle fingers remaining extended. If the paralysis lasts for some time, contractures of the muscles develop, shortening of the muscles of the calf and of the tendo Achillis being most frequent.

In convalescents with paresis or paralysis of the dorsal flexors of the foot a typic gait is observed: The patient on lifting the leg lets the foot hang and touches the ground first with the tip; as the foot is loose in the joint, the gait of such a patient, observed from behind, suggests an effort to shake something from the foot. If, however, contraction of the muscles of the calf exists, the patient walks, as in *pes equinus,* upon the toes without touching the ground with the heel.

Of the muscles of the trunk, the *serratus anticus* is most markedly involved; the shoulder-blades stand out like wings, as in progressive muscular dystrophy. Of the cerebral motor nerves the facial, abducens, trigeminus, vagus, and recurrens are most frequently paralyzed; rarer the hypoglossal.

Disturbance of **circulation.** Beriberi patients very early experience, on slight bodily exertion, palpitation and, consequently, shortness of breath and distress in the chest. The heart sounds are increased, and, without evidence of congestion, edema appears in the lower extremities. The frequency of the pulse (80 or 90 or more) and accentuation of the heart sounds increase from day to day; the radial pulse is moderately large, quick, and soft; the systolic sound at the apex is not pure, or, on further increase of heart action, assumes a peculiar tinkling character. Murmurs similar to those in Basedow's disease and aortic insufficiency are heard in the peripheral arteries, especially the femorals. The blood-pressure in the early stage deviates but slightly from the normal; later there is slight increase to 120 or 130 mm.; finally, in unfavorable cases it falls below normal.

The **edema** occurs at first in the subcutaneous tissue of the lower extremities, sometimes in the muscles of the calf. A second point of predilection for the edema is the larynx, in which it often is manifest when other parts of the body are not markedly edematous. Later, in markedly debilitated subjects the edema is general.

The **blood.** Takasu found nucleated erythrocytes, especially in severe cases, in the acute stage; the number of erythrocytes and the amount of Hb are not decidedly below normal (usually 3,500,000 and 85 per cent., respectively); of the leucocytes, sometimes the polymorphonuclear neutrophiles, sometimes the lymphocytes, were increased. The leucocytes were increased to 18,000 in severe cases, the polymorphonuclear neutrophiles generally predominating.

At **necropsy** the heart is greatly dilated and hypertrophied; the auricles and ventricles contain large quantities of fluid and semi-

coagulated blood. The myocardium is either normal or clouded. Microscopicly, the heart muscle may be transformed into a homogeneous hyaline mass, and the muscle-cells divided longitudinally into a number of fine bands. The papillary muscles present yellow striate and macular mottling. Aside from punctiform hemorrhages, the endo- and pericardium are essentially intact.

The lungs. Edema and catarrhal pneumonia are frequent. In acute cases the capillaries are congested and protrude more or less into the alveoli, which are filled with dislodged alveolar epithelia and round cells.

In the larynx edema is very frequent, usually in the *plica aryepiglottica* and false vocal cords. Sometimes fatty degeneration of the muscle-fibers is observed.

The liver is enlarged by congestion and presents the appearance of nutmeg liver. There is often fatty degeneration in the center of the acini, while the periphery is usually free. Edema of the gall-bladder, which contains but little bile, is frequent.

The spleen is only slightly enlarged and shows no distinct change aside from hyperplasia of the pulp and relative smallness of the Malpighian corpuscles.

The mucous membrane of the gastrointestinal tract is cyanotic, due to engorgement of the veins in the submucosa and of the capillaries between the glands. The gland-cells are well preserved. According to K. Miura,[1] inflammatory signs are lacking. Wright, however, regards gastroduodenitis as constant, which Daniels denies.

The kidneys are congested, but normal in size and weight. Circumscribed clouding is seen in the cortical layer or columns of Bertini. The glomeruli are strongly congested and the epithelia of the convoluted tubules so swollen as to render the lumen barely visible; the epithelial cell-body is cloudy, but the nucleus distinct. The veins and capillaries between the straight tubules are dilated to the width of the renal tubuli. M. Miura usually found glomerulonephritis, while Yamagiwa and Simmonds found parenchymatous changes.

The nervous system. The alterations of the peripheral nerves consist in disintegration of the medullary sheaths and axis cylinders; transformation of whole nerves or whole secondary bundles into a richly nucleated protoplasmic mass. This tissue is regarded by Baelz and K. Miura as collapsed substance of Schwann with increase of the nuclei. Dürck has shown that the tissue belongs to nervous tissue and is not a secondary ingrowth of connective tissue. Quite recently

[1] *Loc. cit.*, p. 305.

alterations have been observed in the anterior and posterior roots as well as in the ganglion cells of the spinal cord. M. Miura, Tsunoda, Wright, and Dürck noted changes in the posterior columns, and Rodenwaldt observed degeneration in Goll's and Burdach's columns; Dürck noted changes also in the lateral cerebellar tracts. The brain almost always remains intact.

So-called **acute pernicious beriberi** is characterized by the predominance of the circulatory and respiratory disturbances, vomiting, cyanosis, and jactitation. Several days before death the pulse becomes rapid, small, and weak; the blood-pressure begins to fall; the fingers, toes, lips, and ears become cyanotic; respiration is frequent and of greater amplitude. In addition, paralysis of the respiratory muscles, especially of the diaphragm, occurs, and, finally, pulmonary edema or hypostatic catarrhal pneumonia and accumulation of transudates in the pericardium, pleura, etc., supervene.

The **etiology** of beriberi is still unsettled. There are two views as to the causation: 1. Toxic. 2. Infectious. The adherents of the toxic theory seek the injurious agent in certain species of fish (*scomberidæ*), in badly preserved or spoiled rice, or in preserved foods. It was assumed that oxalic acid formed in cooked rice and caused beriberi; according to another view, there is in rice a substance, called arsin, which is toxic and is neutralized by the addition of bran.

Most authorities claim that the disease is due to deficiency of certain vitamines in the food, since it usually is seen only in those who eat as a staple article of diet rice[1] deprived of its pericarp, which is rich in phosphorus, especially soluble organic compounds of that element (phytin). It would seem that there is some basis for the belief that berberi can be introduced by persons affected with the disease. According to Shimer, beriberi appeared on the Isthmus of Panama in 1887, with the importation of Chinese and African laborers. The rôle of insects and vermin in the transmission of the disease does not appear to be well supported.

Beriberi in **sucklings** is produced through the milk of beriberi mothers. The symptoms resemble those observed in beriberi in adults, *i.e.*, vomiting, increased pulse and respiration (without fever and bronchitic symptoms), cyanosis, edema, arterial murmurs, and enlargement of the heart. Disturbances of sensation appear to be almost absent. Of motor disturbances, only aphonia, ptosis, and paresis of the soft palate have been observed. Consciousness is clear until a few minutes before death. Improvement occurs within from one to four days after weaning, and if the disease is not too far advanced the patient recovers within from three to fourteen days. The phenomena of severe beriberi in nursing infants occur not only in mild beriberi of the mother, but also

[1] Other articles of food are said to cause this disease.

at a time when she apparently is free of it. This is explained by the assumption that the supposed poison is drawn off by the suckling with the milk, so that the child sickens and the mother remains well. In other cases the mother sickens, while the child remains well, because the toxin produced by the mother is retained and very little or none enters the milk. This hypothesis has been supported by the experiments of Inagagis on the effects of beriberi milk upon the frog's heart.

YELLOW FEVER, BLACK VOMIT, AMERICAN TYPHUS.

Yellow fever is an acute infectious disease, progressing with marked icterus[1] and hemorrhages, caused by an unknown pathogenic agent transmitted by the mosquito[2] (*Culex fasciatus, Stegomyia calopus s. fasciata*) in a manner similar to the mode of infection in malarial fever (*q.v.*). As far as is known, infected mosquitoes are the only medium of conveyance of the virus. The disease is endemic in the warm parts of the western hemisphere (West Indian Archipelago, a great part of the Mexican Gulf coast, Brazil, etc.), and also upon the west coast of Africa. It occurs epidemicly, especially in seaports or in cities situated on large rivers, and usually is confined to regions at or near sea level, though it has been observed in localities at an altitude of 3500 meters (11,480 feet). The period of incubation varies from one to thirteen days, depending upon the constitution of the individual; most frequently it is five days. To the marked icterus of internal and external parts the malady owes its name: "yellow fever."

The active virus is contained in the fresh and defibrinated blood and such as has been passed through a Pasteur-Chamberland B filter. Heating for from five to ten minutes at 55° C. renders it inactive. It is said to be present in the living blood only during the first three days of the affection, since mosquitoes which have sucked blood from patients after the fourth or fifth day do not convey the disease. Like the malaria parasite, after entering the mosquito the virus requires from two to three weeks or longer for development. The infected mosquito may transmit the virus for as long a period as fifty-seven days after sucking infected blood. The active agent is said to be transmitted also to the offspring (next generation) of infected mosquitoes.

That the causative agent of yellow fever is present in the patients' blood was shown, according to Scheube,[3] by the inoculation experiments of the American expedition sent to Cuba, under the direction of Reed, for the investigation of this

[1] The icterus is always most marked in the cadaver. In many cases terminating fatally within two to three days, icterus is absent.

[2] This mode of infection was first suggested for both malaria and yellow fever by Noth, in 1848 (Anders's "Prac. Med.," 6th ed., p. 79, Saunders, 1903), and later by Finlay, in 1881 (*Ann. d. la Réal Acad.*, xvii, p. 147-161; Ref., *Arch. de méd. nav.*, Jan., 1883).

[3] *Op. cit.*, p. 466. (See footnote, p. 568.)

disease.[1] The experiments were made upon 12 nonimmune persons—American soldiers and Spanish immigrants—7 with fresh or defibrinated blood, 3 with filtered blood, and 3 with defibrinated and heated blood. Of the first series 6 experiments, of the second 2 experiments, gave positive results, while the third series was negative. In the blood employed in the experiments, which was taken from patients during the first three days of the disease and injected subcutaneously, no bacteria were found either microscopicly or bacteriologicly. From this it may be concluded that the virus of yellow fever is either a micro-organism so small that it is invisible with the best optic instruments and passes through a Chamberland filter or that it is nonorganized, perhaps a toxin. These experiments were confirmed by the French and German commissions sent to investigate the subject. Schaudinn suggests that yellow fever may be a spirochæta infection.

The disease generally attacks individuals between the 20th to 40th year. No race is immune; negroes, however, manifest the least disposition. One attack generally confers immunity to subsequent infection. The malady usually progresses in three stages: a febrile stage, a stage of remission, and a collapse stage. It generally begins suddenly with severe chill followed by high fever, dizziness, headache, epistaxis, dorsal pain, vomiting, and icterus (at the end of the first stage, frequently later), and great depression. Herpes of the mouth and nose, and occasionally other exanthemata: roseolar, maculopapular, urticarial, pustular, scarlatinoid, and erysipelatoid eruptions, occur. In some cases a fetid or repulsive sweetish odor develops on the first or second day. Hemorrhages occur into the skin, muscles, and kidneys (cortic and subcapsular) and from the intestine (''black vomit stools''), stomach (''black vomit,'' usually in the collapse stage), and other organs: mouth, nose, uterus, kidneys, bladder, and occasionally the eyes and ears. Abortion in pregnant women is the rule, and signs of infection of the fetus have been observed.

The fever generally lasts for from two to three days. About the third day there is amelioration of all symptoms, and the disease passes into the second, or remission, stage, which varies in duration from a few hours to two days. The temperature declines and may reach normal; the pulse falls to 40 or lower. If not already present, albuminuria now appears. In mild cases this stage is followed by convalescence. More frequently, however, aggravation of the symptoms occurs and the patient passes into the third, or collapse, stage. Diarrhea sets in; the vomiting, which had diminished, becomes more violent. The primarily watery vomited matter soon becomes streaked with blackish blood, and finally, usually on the fourth or fifth day, the ejected matter may assume the character of coffee grounds or be homogeneous and

[1] Boston Med. and Surg. Jour., 1901, No. 14; N. Y. Med. Rec., Aug. 10, 1901; Jour. of Hyg., April 1, 1902.

blackish in appearance: black vomit. Rarely red blood is vomited. Anuria sets in, and death generally occurs from uremia or cholemia.

In violent cases death may occur within from twenty-four to thirty-six hours after the onset of the affection.

The mortality varies in different epidemics. In thirty-three epidemics occurring in New Orleans during the years 1847-97 the mortality varied from ½ (1897) to 85 (1853) per cent. In an epidemic observed by Roux, the mortality was 94 per cent. In 269 cases analyzed by Sternberg, death occurred in all cases in which the temperature exceeded 41.5° C.

The chief **necropsy findings** are intense icterus (hence, yellow typhus, *typhus icteroides*) and cloudy swelling of all organs except the spleen, which usually is unaltered; hemorrhages into various organs (pulmonary infarction, pleuritic ecchymoses), fatty degeneration of the myocardium, blood-vessels, kidneys, and liver. The state of the liver is said by some authorities to resemble that of acute yellow atrophy, though this is questioned by others. The stomach and intestines contain more or less blackish, thick fluid, often tar-like blood, and the mucosæ are the seat of numerous ecchymoses. The gall-bladder is almost empty.

FRAMBESIA (YAWS).

Frambesia, or **yaws,** is a chronic, endemic, contagious general infectious disease of the tropics characterized by raspberry-like cutaneous papules and due to a specific spirillum, the *Spirochæta pertenuis.* It is communicable from man to the higher as well as to the lower monkeys. Inoculation with glands and organs is followed by generalization. Animals affected with syphilis are susceptible to frambesia; the two affections must, therefore, be different.

NERVOUS SYSTEM.

MEMBRANES OF THE BRAIN AND SPINAL CORD.

So long as the skull grows, the **dura mater** is firmly united with the bone; it is really not a membrane of the brain, but forms the internal periosteum; it has, however, certain relations to the brain. This is best seen at the point of transition of the cerebral to the spinal dura mater; in the spinal canal there is no connection between the bone and dura mater, but both parts are separated by adipose tissue and the periosteum of the vertebræ. The spinal dura mater, therefore, has not the function of periosteum, but at the point of transition to the brain it becomes periosteum, though not everywhere, for as the falx and tentorium it again is only brain membrane. Therefore, in the skull an external (periosteal) and an internal (meningeal) portion are distinguished. The latter is continuous with the spinal dura. Anatomicly, however, there is no line of demarkation, since both parts cannot be separated. A similar relation exists also between the sinuses and the dura; the sinuses have no especial wall. Hence, all pathologic processes in these regions are not sharply limited and affections of the dura generally extend to the sinuses. Diseases of the periosteal portion of the dura have, in fact, nothing to do with the brain; the process, however, is propagated into the meningeal portion and finally acts also upon the brain by its products.

Inflammation of the periosteal portion is analogous to a periostitis. So long as the skull grows, new layers of bone are deposited externally upon the bony skull capsule; internally old layers are absorbed. This relation may be interfered with by a periostitis or external ossifying pachymeningitis. Also in later life new formations of bone, starting from the dura, are always pathologic. The milder degrees of this change correspond to the quite frequent cases in which an especially intimate connection exists between the skull and dura. In early life, especially as long as the fontanelles are still open, this intimate union is physiologic; later, after conclusion of growth, it is pathologic, for after completion of growth the connection between the dura and the skull is normally so loose that both parts can easily be separated.

If so-called osteophytes (*q.v.*), hyperostoses, or exostoses are found upon the inner surface of the skull, these are always products of an external ossifying pachymeningitis.

An internal **ossifying pachymeningitis**—the formation of bone—which sometimes may be very large, occurs on the inner surface of the dura as a result of inflammatory irritation. This is most marked where there is no connection of the dura with the bone, namely, at the falx. Indeed, no bone formation should occur in this region at all. The dura, therefore, possesses the ability to form bone in two directions, not in its interior, but externally.

If bone occurs in the interior, that is, in the substance of the dura, this belongs in the category of pure neoplasms—of pure osteomata: *osteomata duræ.*

Internal hemorrhagic pachymeningitis. There is an independent inflammatory process upon the inner surface of the dura (*i.e.*, the meningeal portion), especially over the cerebral convexity, which produces a flocculent or extensive fibrinous exudate. It is usually bilateral, but sometimes only one hemisphere is involved. The fibrinous pseudomembrane has its seat of predilection in the region of the middle meningeal artery. In its first stage it forms a quite thin, transparent layer, which is easily overlooked and visible only when a clean knife is carefully scraped over it. By ingrowths of new-formed vessels into the granulation tissue developing from the dura, vascularization occurs which extends radiately into the exudate. The fibrinous pseudomembrane is thus transformed into an organized, connective-tissue membrane. Every intense congestion involving the new-formed, very delicate, thin-walled, and relatively wide vessels easily leads to hemorrhage, which organizes under the formation of granular (hemosiderin) and crystalline (hematoidin) pigment, and contains new vessels which, in turn, may give rise to hemorrhages and recidives. The vascularization is usually so rapid and abundant that the new-formed membrane often contains more vessels than the dura. The recidives result in the development of lamellæ, the oldest of which are situated upon the dura and, on longer duration, become so firmly adherent to it that it finally can no longer be separated. The process progresses very slowly, and at first is usually entirely latent. On longer duration, when the new-formed lamellæ encroach more and more upon the skull space, disturbances often develop. The greater the number of lamellæ formed, the more intense the hemorrhages usually are. (See *Hæmatoma duræ matris.*)

These blood extravasates always occur between the dura and arachnoid, and, when they are small, within the new membrane; when they are large, also free between the membrane and the arachnoid. They are then often almost indistinguishable from other intermeningeal hemorrhages—the traumatic and those caused by vascular anomalies. In the traumatic there are, as a rule, coincident injuries of the cranial

bones and frequently also of the brain. In these cases the hemorrhage is usually more extensive, extending over almost the whole periphery of one or both hemispheres, while in hemorrhagic pachymeningitis no blood is, as a rule, to be seen at the base. How far trauma is concerned in the hemorrhages caused by vascular anomalies is yet undetermined. The vascular anomaly consists therein that veins of the arachnoid do not, as usual, empty directly into the longitudinal sinus, but pass to the dura at some distance from the middle line, and run to the sinus upon the inner surface of the dura, as it were, superficially. In these cases the source of the hemorrhage is almost invariably the point of transition from the arachnoid to the dura, while the source of traumatic hemorrhage is most frequently the middle meningeal artery with its branches.

The accumulation of large amounts of clear fluid between the newformed layers of connective tissue and the production of a cystic space are exceptional occurrences in internal fibrinous pachymeningitis. This cyst is called *hygroma duræ matris.*

Acute **purulent processes** occur in the dura and the sinuses after caries of the cranial bones, injuries, and in connection with infectious processes in the neighborhood, principally of the ear (otitis media), next of the eye, seldom of the frontal sinuses. As a rule, the purulent process in the dura begins—*e.g.,* after otitis media—before the tissue of the petrous bone is destroyed. Owing to the slight vascular supply, the exudate upon the dura is usually moderate. Marked accumulation of discolored pus upon the surface and purulent disintegration of the vessels entering the bone, with spontaneous separation of the dura from the bone, occur only after long duration. In such localities the bone is eroded and, like the outer surface of the dura, discolored (dirty greenish). The dura mater itself is always strongly indurated by purulent infiltration. Upon the inner surface inflammation may be absent at first; as soon, however, as the dura is completely infiltrated, a slight amount of fibrinopurulent exudate is always found also upon the inner surface. The inner surface frequently appears to be dry. The process, therefore, progresses continuously from without inward. (See Epidemic Cerebrospinal Meningitis, p. 568.)

On the basis of bacteriologic, histologic, and anatomic examination in 56 cases of otitic meningitis, Neumann and Ghon[1] conclude that: 1. Meningitis is essentially a reinfection, no matter if the causative otitis be acute or chronic. 2. Meningitis following chronic suppurative otitis media is predominantly the sequela of an acute exacerbation. 3. Meningitis following acute otitis is due especially to the diplococcus and the *Streptococcus mucosus,* to a less extent to the *Strepto-*

[1] Int. Centbl. f. Ohrenhlk., No. 6, 1910.

coccus pyogenes. This is noteworthy, because in the bacteriologic examinations of the middle-ear exudate, in 90 cases of acute otitis, made by Ruttin, the *Streptococcus pyogenes* was found in 60 cases as compared with the diplococcus (13) and the *Streptococcus mucosus* (9). Among the 56 cases examined, in only 9 were mixed cultures grown from the meningitic exudate; in 8 of these chronic middle-ear suppuration was the cause of the meningitis, 1 case only being referable to acute otitis media. All these cases were associated with another cranial complication, such as sinus disease, labyrinthine suppuration, or brain abscess. To the naked eye, all these meningeal inflammations appeared more or less diffuse, the exudate never being limited to the convexity alone. In a few cases it occupied the base exclusively; often it was found uniformly distributed over the base and macular on the convexity. In the majority of the cases the exudate was serofibrinopurulent, with very numerous polynuclear leucocytes and a small number of macrophages.

According to Schlesinger,[1] three forms of meningitis occur in pneumococcic pneumonia: 1, serous meningitis with sterile cerebrospinal fluid; 2, serous meningitis with pneumococci in this fluid, and, 3, purulent meningitis with or without diplococci. The first type is known also as meningismus. In aged individuals the meningitic phenomena, particularly the rigidity at the back of the neck and Kernig's symptom, are apt to persist for several weeks after subsidence of the inflammatory process in the lungs. Purulent meningitis usually terminates in death after a few days. The onset may be apoplectiform; or acute, but not apoplectiform; subacute, or insidious. In contradistinction to tuberculous meningitis, the abdominal coverings are not retracted or only temporarily. Pneumococcic meningitis may occur in the course of an affection of the respiratory tract, an attack of endocarditis, in acute otitic or cranial disease, and also independently. In the late stages of the disease separation of membranes has been noted in the aspirated spinal fluid.

By extension of the purulent and putrid processes of the dura to the sinuses, purulent and ichorous thrombophlebitis develop. Simple bland thrombosis, so-called marantic thrombosis of the sinuses, is most frequently observed in small, poorly nourished children (marasmus), rarely in adults, and then, as a rule, in connection with severe affections (profound anemia) which rapidly lead to exhaustion. Sinus thrombosis may occur also in general infectious diseases, tumors, trauma of the cranial bones. Passive congestion, edema of the brain, pia, and arachnoid, and frequently extensive hemorrhagic infarction of the contiguous cerebral tissues are sequelæ. Bland thrombi are exceptionally found in those veins which enter the dura at some distance from the longitudinal sinus, namely, at the point of transition. All thrombi of the sinuses and *venæ arachnoidcs* result in intense congestion of the collateral capillary area, which finally terminates in red softening.

In the spinal cord purulent pachymeningitis is observed most frequently as an extension process in tuberculous and purulent caries of

[1] Wien. med. Woch., No. 1, 1911.

the vertebræ. Here, however, the pachymeningitis must be differentiated from affections of the periosteum and of the extrameningeal adipose tissue, for there is also an internal spinal periostitis, an extrameningeal phlegmon, and an acute external or internal spinal pachymeningitis.

The **arachnoid** (ἀραχνο - εἰδης: spider-web-like) is a very thin, translucent, delicate, richly vascular membrane which uniformly covers the surface of the brain and spinal cord, sends prolongations into all sulci, and extends into the ventricles as *tela chorioides* and *plexus chorioidei.* It is inseparable from the pia mater—rather identic with the latter—and consists of a single membrane (see Fig. 301), not of two; hence, unlike the serous membranes, it does not form a sac. The arachnoid can neither macroscopicly nor microscopicly be separated into two layers, as is often assumed. Nowhere is there a line of demarkation justifying separation into two membranes; separation here is just

Fig. 301.—*A,* arachnoid (intentionally drawn thicker); *g,* gyri. (After *Langerhans.*)

as impossible as the differentiation of two layers in the periosteum—a richly vascular internal and a poorly vascular external layer.

Edema of the arachnoid, a very frequent necropsy finding, consists in infiltration of the tissue with clear, transparent fluid. The most intense edematous infiltration is found over atrophic, depressed gyri (*hydrops ex vacua*) and in atrophy of the whole brain. In certain localities accumulations with vesicular, cystic character sometimes develop.

In the spinal canal the arachnoid is united with the dura by small, poorly vascular connective-tissue strands, while in the brain the only union of both membranes is provided solely by the *venæ arachnoideæ* emptying into the sinuses. Edema of the spinal arachnoid is not confined to the true tissue of the arachnoid, but extends into the loose, reticulated tissue between the arachnoid and dura as far as the dura. This edema is called *hydrorrhachis externa.*

Wholly analogous to edema the acute inflammatory processes of the arachnoid (arachnitis, leptomeningitis) elaborate no free exudate upon the surface, a proof that the arachnoid is not to be compared with the serous membranes. The exudates, which are always found within the meshes (small spaces) of the arachnoid, are usually mixed,

fibrinopurulent, and may contain quantitatively more fibrin. Sometimes the whole cerebral and spinal arachnoid are equally involved, as in acute epidemic cerebrospinal meningitis and in very extensive tuberculous arachnitis; more frequently only certain regions are altered, *e.g.*, only the convexity (in *trauma cerebri*) or only the base and spinal cord, or only circumscribed areas at the base (region of the chiasm of the optic nerve in beginning tuberculous basilar meningitis; region of the middle or posterior cranial fossa, or of both, in beginning purulent arachnitis after otitis media). The purulent affections of the spinal arachnoid (in tubercular caries of the vertebræ, after *decubitus profundus,* injuries, operations, etc.) have a great disposition rapidly to spread to the base of the brain.

In chronic arachnitis two forms must be distinguished: a superficial and a deep. In the first the upper, somewhat less vascular layer of the arachnoid becomes thickened, so that the membrane, which is scarcely visible in the normal state, becomes very distinct, assuming a whitish color and a dense consistency. The thickening extends either uniformly over the whole surface, or it involves only small areas (*e.g.*, in *pachymeningitis interna ossificans,* in consequence of friction against the newly formed bone), or it occurs from the first in the form of small, circumscribed, warty nodules alongside of the longitudinal sulcus.

The last form corresponds to *arachnitis verrucosa* or to the Pacchionian granulations; they are nearly a physiologic phenomenon, since they are almost never absent in elderly individuals. These granulations are fibromata, the size of a millet seed and larger; they grow through the dura and finally produce deep, atrophic indentations in the internal table, sometimes even in the external table of the calvarium. Within the more uniform thickenings of the arachnoid, partial calcifications and sometimes also true osseous lamellæ (*arachnitis ossificans*) may occur. In all these cases the arachnoid can readily be separated from the surface of the brain, often more easily than in the normal state, since it tears less easily as a result of the thickenings.

In contrast to this superficial form, it is extremely difficult to separate the arachnoid in *arachnitis chronica profunda.* As a rule, separation is incomplete, loss of cortic substance always occurring upon the summit of the gyri, so that the surface appears eroded. This phenomenon is due to the intimate, firm union of the cortic layer with the arachnoid as a result of thickening of the cortex, especially in the region of the vessels coming from the arachnoid and entering the surface of the brain at a right angle. If a normal arachnoid is stripped off, countless very small, densely arranged vessels are seen on the under surface when water is poured upon it; they impart to the surface an almost

velvety appearance. *Arachnitis profunda* develops as a result of chronic thickening of the sheaths of all these vessels. The process always begins in the anterior portion of the brain and gradually extends backward from this point. It is clear that this thickening of the vessel-sheaths can progress only at the expense of the uppermost cortic layer; that, therefore, it is accompanied by atrophy of the uppermost layer of the cortex, especially of the tangential medullated nerve-fibers and of the ganglion cells. Accordingly, *arachnitis profunda* is usually observed in persons in whom disturbances of the central nervous system existed during life; hence, encephalomeningitis, in conjunction with chronic hydrocephalus and granular ependymitis, constitutes the almost constant finding in progressive paralysis of the insane. Chronic superficial arachnitis, on the other hand, is quite frequently observed without the existence of symptoms during life, especially in advanced age. It is always present in chronic edema of the arachnoid, *e.g.*, in consequence of atrophy of the brain. Superficial and deep chronic inflammations of the arachnoid are, therefore, very different in their importance. As a rule, the arachnoid does not appear to be thickened in *arachnitis profunda;* usually the finer vessels are somewhat more intensely congested, so that the arachnoid is quite uniformly reddened.

The blood content of the arachnoidal vessels is very frequently unequal in the cadaver. After removal of the skullcap, the deeper parts are usually intensely congested by hypostasis. The larger veins are situated chiefly upon the surface and in the depth of the sulci; the arteries are more in the middle. In chronic diseases associated with congestion, intense engorgement and tortuosity of the dilated superficial veins are sometimes observed. As a rule, slight edema and slight thickening of the arachnoid coexist. True inflammatory hyperemia of the arachnoid is very seldom seen in the cadaver; when present, the superficial veins are not very strongly congested, but principally the capillaries. The latter are unrecognizable with the naked eye; therefore, the diagnosis of inflammatory hyperemia can be made only when the arachnoid is uniformly intensely red.

As is known, the arterial blood is conveyed to the brain through both internal carotids and both vertebrals. The latter unite to form the *basilaris cerebri,* whose principal branches (the two posterior cerebral) are united with the carotids or their principal branches (the middle cerebral) by the posterior communicating, while the two other branches of the carotid (the anterior cerebral) are united by the anterior communicating just in front of the optic chiasm. The circle of Willis is formed at the base of the brain by the three communicating arteries. The three

principal trunks given off from this circle to supply the large brain are the two anterior cerebral, the middle cerebral, and the posterior cerebral. All coarser changes, *e.g.*, obliteration, emboli, arteriosclerosis, syphilis, etc., involving the circle of Willis are, by virtue of the collateral channels, easily compensated. Beyond this point, however, no such anastomoses exist; indeed, for certain regions it is assumed, with Cohnheim, that the arteries are so-called terminal arteries and do not communicate with any other arterial vessels. Therefore, all injuries involving the vessels beyond the circle of Willis must exert an entirely different effect.

Two areas are distinguished according to the vascular arrangements: the basilar area and the cortic area. The arteries of the basilar area enter the brain substance at the base at a right angle, and supply the peduncles, the large ganglia, etc. The others traverse the arachnoid for a greater or lesser distance, giving off numerous branches, finally also entering the brain at a right angle to supply principally the cortic layer.

The changes involving the arteries beyond the circle of Willis are arteriosclerosis, thrombosis, embolism, and aneurism.

Thrombosis is usually a sequela of sclerosis (atheroma) or aneurism, and may give rise to embolic processes.

Emboli originate by far most frequently from the left heart, especially from the aortic orifice, though they may be derived from thrombi in the pulmonary veins. The result differs greatly according to the size of the occluded vessel. If one of the large vessels is completely occluded, apoplectiform death sometimes occurs; if smaller vessels are the seat of emboli, yellow softening occurs in the brain region supplied by the vessels occluded. Emboli are most frequently found in the region of the middle cerebral arteries, while in arteriosclerosis the three double principal trunks are usually quite uniformly altered. The sequelæ of sclerosis are the same as in emboli; in arteriosclerosis, however, several and different sized foci, quite fresh alongside of older, are more frequently observed. Sometimes the finer vessels are so markedly indurated and calcified by arteriosclerosis that they offer considerable resistance to the knife—are often not cut through, but torn out by the knife, remain hanging to the knife or project above the surface as small, rigid spicula. Furthermore, the small arteries and capillaries may form branched, solid lime cylinders. (See Fig. 302.)

Among the aneurisms the so-called *miliary aneurysmata* of the smaller arteries (see Fig. 305) within the brain (namely, in the region of the large ganglia, particularly in the area of the lenticulostriate artery, which forms the almost right-angled continuation of the internal carotid

and, therefore, as has been experimentally determined, is under a higher pressure than most of the other cerebral arteries) are of especial importance, because they are frequent and, by rupture, form the ordinary cause of large cerebral hemorrhages.

On the other hand, aneurisms of the arachnoid produce severe intrameningeal and intermeningeal hemorrhages, which often are fatal.

In poorly nourished individuals, children and adults, and also in the aged, fatty metamorphosis in the walls of the vessels—of the arteries and capillaries (without inflammation)—is a quite frequent phenomenon which, however, has no connection with larger cerebral hemorrhages.

Fig. 302.—Calcified cerebral vessels. Fresh crush preparation. (Zeiss Apochr., 16; Comp. Ocul., 4. After *Langerhans.*)

BRAIN AND SPINAL CORD.

The average weight of the brain of a fully developed man is, in Europeans, about 1370 grams; that of the female 1240 grams. The brain of the newborn weighs about 450 grams. In adults a weight of less than 900 grams is pathologic, and generally permits the assumption of idiocy. This state of microcephalia is most frequently due to premature synostosis of the sutures of the skull.

The weight of the brain is important, but must be accepted with reservation. According to Ernst, the following order shows the decrease in weight of the brain with age: 3d decade: 1409 Gm.; 4th decade: 1413 Gm.; 5th decade: 1366 Gm.; 6th decade: 1346 Gm.; 7th decade: 1324 Gm. The subjoined table from Ernst of the comparative weights of the brains of eminent men is very instructive:—

Turgenjeff	65 yrs.	2012 Gm.	Cromwell	59 yrs.	2000 Gm.
Cuvier	63 "	1861 "	Byron	36 "	1807 "
Bismarck	83 "	1807 "	Abercrombie	67 "	1780 "
Thackeray	52 "	1660 "	Napoleon II	65 "	1500 "
Gauss	78 "	1492 "	Broca	65 "	1485 "
Dupuytren	57 "	1440 "	Mommsen	86 "	1425 "
Helmholtz	73 "	1420 "	Liebig	70 "	1350 "
Ludwig II	41 "	1349 "	Gambetta	45 "	1314 "
Menzel	89 "	1298 "	Bunsen	88 "	1295 "
Tiedemann	79 "	1254 "	Döllinger	71 "	1207 "

From the capacity of the skull were reckoned:—

Dante, 56 years: 1420 Gm.; Kant, 80 years: 1650 Gm.; Schiller, 46 years: 1580 Gm. That the weight of the brain alone offers no basis for estimating its power is shown by the fact that the heaviest known brain, weighing 2850 grams, was that of an idiot 21 years of age. Slight epileptic tendencies are often associated with great intellectual endowment (Mohammed, Cesar, Napoleon I, Helmholtz, Menzel).

The cortex of the brain consists, aside from the vessels, principally of nerve-cells and their, in great part, nonmedullated processes. It, therefore, appears gray. The medullary substance owes its white color to the myelin of the medullated nerve-fibers. In the newborn child the color of the medullary substance is not white, but gray, because the nerve-fibers are still poor in myelin.

The stroma, or connective-tissue supporting structure, is composed of neuroglia (nerve cement)—of stellate cells which anastomose by their processes and thus form a tissue which is closely related to, but is not identic with, reticulated connective tissue.

In rare instances these neuroglia cells are the point of origin of an independent process—**congenital interstitial encephalitis**— an increase of these cells occurring by proliferation which is followed by retrogressive fatty metamorphosis. Apparently this affection occurs most frequently in congenital syphilis. This should not be confounded with another state which is not pathologic, but physiologic, in so far as it is never absent in children up to the end of the first three months. This physiologic state is one in which countless cells in the brain, not only the neuroglia cells, but also numerous round cells, contain fat. The round cells are seen in more or less large numbers, especially within the lymph-sheaths of the vessels. In children with a slight amount of adipose tissue and who are poorly nourished and poorly developed, this physiologic state persists longer; as a rule, it is still found in the fourth month and often also even later.

While in the physiologic process fat cannot be macroscopicly recognized, in the pathologic form—*encephalitis congenita neonatorum*—

certain cells are markedly altered, becoming more and more opaque and finally assuming a pale, yellowish-white appearance. These foci may disintegrate and thus produce the condition of yellow softening of the brain. That the process is of an active inflammatory nature is shown by the fact that the neuroglia cells divide, and that the axis cylinders undergo change, first becoming varicose, swollen, and then disintegrating. This encephalitis is frequently observed after affection of the mother with small-pox, scarlatina, and syphilis; it is probable, however, that these diseases do not exhaust the etiology.

In the brain of adults an inflammation occurs which is characterized by numerous small hemorrhages. The processes are usually circumscribed and not very extensive affections in which, in addition to hemorrhages, only round-celled accumulations in the neighborhood of the vessels and varicose dilations of the medullated nerve-fibers can be seen.

In the domain of interstitial encephalitis belong **cerebral abscesses** —purulent processes which destroy a more or less large portion of the brain and transform it into a pus-cavity.

Abscesses in which gradual transition to healthy tissue without definite lines of demarkation occur, and others which are sharply defined by a quite dense, newly formed membrane, must be differentiated. In the first instance the course of the process is acute; in the second it is chronic.

In acute cerebral abscess the pus has either a laudable, thick, creamy, somewhat ropy consistency, or it is liquid, discolored, ichorous; it sometimes acquires a somewhat brownish color from hemorrhagic admixtures. In the neighborhood of the liquid pus—the true abscess-cavity—a still nonliquefied, but already purulent infiltrated, layer is found; this is followed further outward by an edematous zone with hemorrhagic hyperemia (punctiform hemorrhages) and gradual transition into the unaltered brain-tissue.

If the spread of the abscess assumes a chronic course, a distinct membrane which possesses all the characteristic features of a pyogenic membrane forms at the point between the pus and healthy tissue. The inner surface of this membrane, *i.e.*, that portion directed toward the pus-cavity, is formed of soft granulation tissue, while the external portion is highly vascular, reddish, occasionally also dark red. In the neighborhood of this capsule the brain-tissue is reddened, strongly vascular, and edematous. Development of the pyogenic membrane is always accompanied by the constant new formation of pus; the process, therefore, is not arrested. On the contrary, the abscess grows, the surrounding edematous zone gradually being drawn into the inflammatory process of softening. In contradistinction to the

acute abscess, which produces death within from a few days up to about one month, the course of the chronic abscess is very slow; it often develops quite latent, persists for years, and produces death only as a result of intense pressure which it gradually exerts upon the brain (complete flattening of the gyri, etc.), or by rupture into the ventricles or by final extension to the arachnoid, a purulent arachnitis supervening.

Cerebral abscesses occur solitary and multiple. When the latter pursue a chronic course they may become confluent. The form of the abscesses is usually somewhat wedge-shaped. The abscesses may attain considerable size—the dimensions of a hen's egg and larger; sometimes one hemisphere of the cerebellum is almost completely suppurated.

From an etiologic standpoint, purulent inflammation of the middle ear (*otitis media purulenta*) occupies the first position; the next most frequent causes of the abscesses are caries, septic processes, injuries, operations, and infectious diseases. In purulent otitis media (*e.g.*, as a result of pearl tumor: cholesteatoma) with caries of the petrous bone, the inflammation of the dura and arachnoid is generally decidedly local as compared with the very large and usually ichorous cerebral abscess. The suppuration rapidly spreads chiefly in the white substance; the gray substance and arachnoid become more or less extensively involved in the purulent process only after long duration of the affection.

A peculiar alteration the etiology of which is usually unknown occurs in the spinal cord in the form of an acute inflammatory process which affects the whole diameter of the spinal cord: **transverse myelitis.** According to the location are distinguished a *myelitis transversa cervicalis, dorsalis,* and *lumbalis,* respectively. The nature of the process consists in a change similar to that occurring in *encephalitis interstitialis neonatorum,* i.e., an inflammatory swelling and proliferation of the neuroglia cells with subsequent fatty metamorphosis and cloddy disintegration of the medullated nerve-fibers. In the fresh state such an area is somewhat softer than normal; on incision the nerve substance wells forth strongly; the markings of the gray horns are indistinct or completely obliterated. Such an area may sometimes assume a faint-yellow color as a result of fatty metamorphosis.

In so-called **compression myelitis** also a kind of softening of the whole diameter of the cord occurs at some point, although the gray substance remains distinctly recognizable. It is very probably not a true inflammatory process, but only a simple atrophic change, the result of nutritive disturbances, and on long duration a secondary proliferation of the neuroglia. The most frequent causes are chronic inflammatory, especially tuberculous and carious, alterations of the bodies of the vertebræ with subsequent breaking down of the destroyed ver-

tebræ and forward displacement of the superimposed healthy vertebræ; furthermore, tumors which, like chondroma, develop partly from the intervertebral cartilages, partly, like lipoma, angioma, carcinoma, etc., within the vertebral canal.

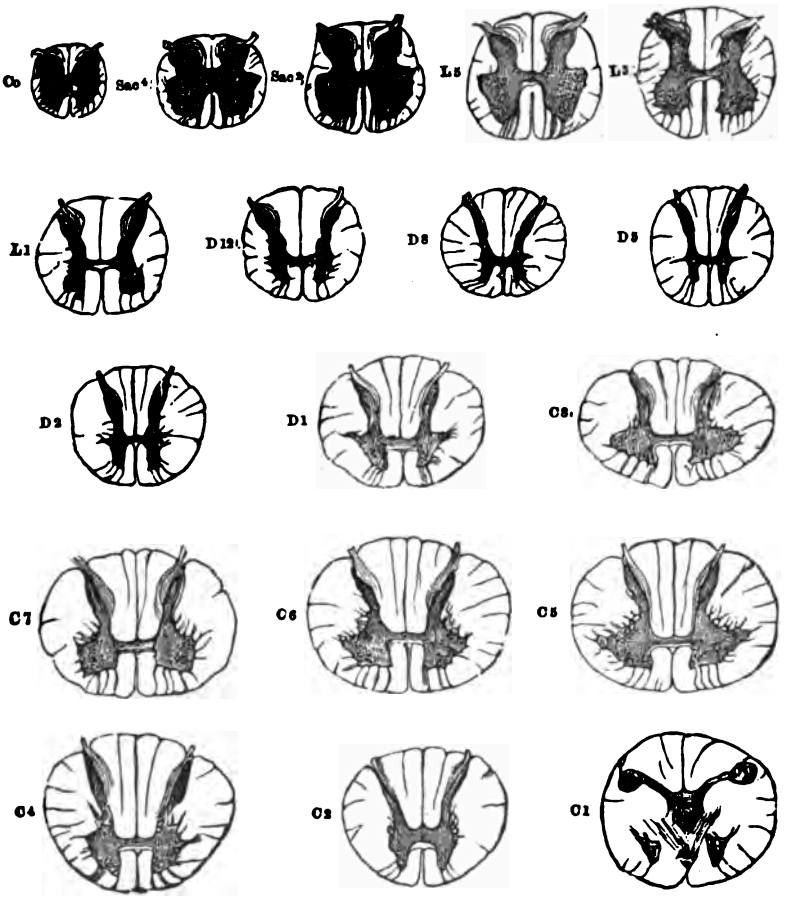

Fig. 303.—Sections of the cord at different levels. The letters and figures indicate the spinal nerves, the exits of which correspond to the respective sections. (*Quain.*)

On sudden intense compression of the spinal cord by trauma, more or less complete destruction may occur. Best known is compression of the medulla oblongata by the dental process of the axis resulting from luxation of the atlas and axis (breaking of the neck).

Acute poliomyelitis, Heine-Medin's disease, infantile paralysis. [1]

[1] This designation is erroneous, as the disease occurs also in adults.

In the spinal cord there is sometimes observed, almost exclusively in children between 1 and 5 years of age,[1] a not very extensive acute infectious inflammation: *poliomyelitis spinalis anterior acuta infantum* **(infantile paralysis),** involving principally the gray anterior horns. This is a partly diffuse, partly focal, interstitial inflammatory process which may extend throughout the cerebrospinal axis, though, as a rule, it is most intense in the region of the cervic and lumbar enlargements. The results are atrophy of the ganglion cells and of the anterior and posterior roots and degeneration of the peripheral nerves (with paralysis). In the spinal cord the region of the vessels (*arteriæ sulcocommissuralis*) is most intensely altered; here accumulation of round cells and small, occasionally also large hemorrhages, which may result in hemorrhagic softening of the anterior horns, are not infrequently found.

There are no characteristic lesions outside the nervous system.

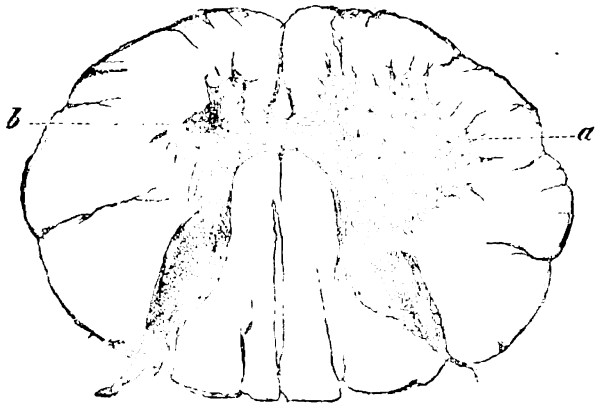

Fig. 304.—Poliomyelitis. Sclerosis and cicatricial atrophy of the left anterior horn of the fourth cervic nerve after acute anterior poliomyelitis. *a*, normal anterior horn with ganglion cells; *b*, atrophic anterior horn. Child 3½ years old; death eight months after occurrence of paralysis. × 7. (After *Ziegler.*)

Zappert[2] distinguishes three types of acute poliomyelitis: (1) a spinal form (most frequent); (2) cerebral form, which is located especially in the pons and medulla oblongata; (3) an abortive form with general febrile and gastrointestinal symptoms, without manifestations on the part of the central nervous system.

Small globoid, intracellular bodies or minute micro-organisms have been cultivated from the central nervous system and described by Noguchi. Amoss[3] also has found the same bodies in blood smears and also cultivated them from the blood of infected monkeys. Epidemics are not uncommon. One attack generally confers immunity.

[1] In the New York epidemic of 1907, 90.5 per cent. of the cases occurred in the first six years. In the epidemic occurring on the island of Nauru, in 1910, the majority of cases were in adults. (See Frost, *loc. cit.*, p. 17.)

[2] Jahrb. f. Kinderh., Bd. 72.

[3] Jour. Exp. Med., xxxii, No. 1, and Sept. 1, 1914, p. 249.

The virus is present in the spinal cord, brain, mesenteric and salivary glands, and nasal and pharyngeal mucosæ and readily passes through Berkefeld and Chamberland filters. The strength of the virus is unimpaired by glycerinization, drying for a week, and exposure to a temperature of—2° C. for forty days. Subdural, intraperitoneal, intravascular, intraneural, and subcutaneous injections and also inoculation of the scarified pharyngeal mucous membrane are followed in monkeys by symptoms and anatomic changes resembling those observed in the human subject. Animals (monkeys) which have recovered from the effects of the virus are immune to subsequent inoculations.

Infection seems to take place through the mucous membrane of the nasopharynx. The virus reaches the nervous system probably through the cerebrospinal fluid. Some authorities believe that it passes along the vessels, affecting the interstitial tissues and then the ganglion cells. There may be so-called "carriers." According to Pierson,[1] the disease may be related to several kinds of "distemper" occurring in dogs in the Yukon and Tanana valleys, and be transmitted from these animals to the human subject. He and Rosenau suggest stable flies (*Stomoxys calcitrans*) as carriers of the infection.

In 266 cases observed by Zappert, chiefly in children, the mortality was 10.8 per cent. Wickman[2] gives the mortality at different ages in 842 cases as: 0 to 11 years, 592 cases, 71 deaths, or 12.2 per cent.; 12 to 32 years, 250 cases, 69 deaths, or 27.9 per cent. Death usually occurs during the first week, most frequently from respiratory paralysis.

The cause of **progressive spinal muscular atrophy** also depends upon atrophy and complete disappearance of the ganglia of the gray anterior horns, particularly in the cervic cord; the peripheral nerves belonging thereto, as well as the gray anterior horns, also are atrophied. If the atrophy of the ganglion cells is limited to the nerve-nuclei of the medulla oblongata (chiefly the hypoglossus; also the vagus, accessorius, facial, and glossopharyngeal nuclei), without further involvement, the same changes and clinic symptoms as are comprised under the name of **progressive bulbar paralysis** exist.

Atrophy of individual ganglion cells of the gray anterior horns occurs also after loss of peripheral nerves, *e.g.*, by amputation.

Atrophic states in the central nervous system develop only to a minimum degree upon an inflammatory basis. Senile atrophy causes diminution in the size of the brain, especially of the gyri. The gyri are narrow; the sulci gape widely; the arachnoid is strongly edematous. Sometimes the atrophy involves only certain lobes.

Senile dementia manifests no special features deviating from senile atrophy.

---

[1] Jour. Amer. Med. Assoc., Feb. 28, 1914, p. 678.

[2] "Beiträge zur Kenntniss der Heine-Medinschen Krankheit (Poliomyelitis acuta und verwandter Erkrankungen)," Berlin, 1907, S. Karger. Cited by Frost: "Acute Anterior Poliomyelitis," U. S. Pub. Health and Marine-Hosp. Serv. Bull., No. 44, p. 46; Washington, D. C., 1911.

Partial atrophies, in which small areas of the gyri lie at a deeper level—as it were, depressed—are usually due to disturbances in the vascular system. In this category belongs also porencephalia (porencephalus). By this is meant a more or less funnel-shaped defect—a porus in the substance of the hemispheres (usually in the region of the middle meningeal artery)—which is either shut off from the ventricles and arachnoid or is connected with both or only with the ventricle.

Little is known as to the etiology; it is assumed that hemorrhages, thrombosis, emboli produce this destruction, because blood-pigment very frequently is found in the cicatricial mass separating the brain from the porus. By far the majority of cases may be traced to intra-uterine disturbance. The secondary disturbances observable during life: mild psychic and motor disturbances up to the most pronounced idiocy—wholly aside from children incapable of living—vary according to the size of the defect.

A further atrophic process of the central nervous system is **multiple sclerosis,** as a result of which the white medullary substance of the brain and spinal cord is always altered in the form of numerous, very small to quite large, gray foci. These foci are situated in the brain, chiefly in the region of the *corpus callosum*, in the latter itself, and in the walls of the lateral ventricles; more rarely in the pons and in the medulla oblongata; more numerous in the most varied localities in the spinal cord, very rarely symmetric. The essential change is an inflammatory proliferation of the neuroglia with secondary disappearance of the medullary sheaths. The proliferated neuroglia cells die partly by fatty metamorphosis; the axis-cylinders are at first still preserved; later they disappear and are replaced by a dense fibrillated tissue. Multiple sclerosis pursues a slow, insidious course.

Diffuse sclerosis of the brain also is closely related to inflammatory processes, and constitutes, as it were, a chronic diffuse interstitial encephalitis. The neuroglia cells and the cells in the neighborhood of the vessels proliferate; the brain is markedly firm in consistency, cuts hard, offering considerable resistance to the knife. It is unaccompanied by fatty metamorphosis.

In **tabes dorsalis** (consumption of the spinal cord, **locomotor ataxia,** spinal atrophy, posterior spinal sclerosis, Duchenne's paralysis or disease) the essential change is ascending gray degeneration of the medullated sensory nerve-fibers: *degeneratio grisea funiculorum posteriorum.* This atrophy, however, in contradistinction to multiple sclerosis, is confined to the spinal cord (posterior columns, horns, and roots), and involves individual

central nerves only after long duration: *nervi opticus, oculomotorius, acusticus.* It always attacks symmetricly the sensory conduction tracts of the spinal cord, principally those parts which enter the posterior columns from the posterior roots. The process usually begins in the posterior root area of the lower dorsal and upper lumbar portions of the cord. At first there is usually nothing to be recognized. The spinal cord appears thin and flattened on the posterior periphery only when a large area of the posterior columns is already atrophic. The peculiar gray and often somewhat gelatinous consistency of the posterior columns can then be recognized even on inspection of the arachnoid. The arachnoid is usually intensely thickened as the result of inflammation, especially at the posterior surface. Microscopicly, disappearance of the myelin and sometimes fatty metamorphosis of the neuroglia cells are observed in the affected parts. In the lumbar portion of the cord the middle and posterior segments of the posterior columns are usually grayish degenerated, only the anterior segment remaining for some time intact; in the dorsal portion of the cord the external part of the posterior segment also is unaltered, and in the cervic portion of the cord principally the columns of Goll are first altered.[1] The extent of gray degeneration is, of course, subject to certain variations according to the intensity and duration of the affection. Within the affected portions of the spinal cord countless *corpora amylacea* frequently form: spheric, somewhat glistening bodies with distinctly lamellated structure, which stain blue on addition of iodine. These, however, are not characteristic of tabes; on the contrary, they occur also in other pathologic processes of the central nervous system, especially when nerve substance is destroyed. From an etiologic standpoint, syphilis plays a not unimportant rôle in tabes dorsalis, in so far as a large percentage (about 60 per cent.; in the opinion of many authorities even 100 per cent.) of all tabetic individuals have suffered from syphilis.[2]

The posterior columns are composed chiefly of fibers which enter from the posterior roots and are partly given off to the gray substance and partly ascend within the posterior columns to the medulla. In each segment of the cord the fibers entering the posterior columns from the posterior roots lie in the lateral portions of the posterior columns alongside the posterior horn. In the next higher segment they pass medially, being pushed aside by entrance of new fibers. As this displacement of the posterior-column fibers is repeated in each segment of the cord, the

[1] See p. 606.

[2] Tabes is very rare in full-blooded negroes, yet syphilis is almost universally prevalent among them (*Jour. Amer. Med. Assoc.*, June 3, 1911, p. 1646).

long posterior-column fibers in their ascent are directed more and more medially; hence, those fibers which originated from the posterior roots of the sacral, lumbar, and lower dorsal cord are found in the cervic region in the median portion of the posterior column at both sides of the posterior septum and separated from the remainder of the posterior column by the paramedian septum. They are here designated as the columns of Goll. The lateral portion of the posterior column, which receives its fibers from the roots of the upper dorsal and cervic cord, is here called the column of Burdach. This division into Goll's and Burdach's columns exists only in the upper dorsal and cervic cord.

As tabes dorsalis usually begins in the lower dorsal and upper lumbar cord, *i.e.*, in the fibers derived from the posterior roots of these regions, in beginning tabes sections through these portions show on each side an area of degeneration alongside the posterior horn. As the fibers entering here are, after their ascent, situated in the columns of Goll, sections through the cervic cord in fresh cases show degeneration of Goll's column. If the process involves also the root areas of the lower, *i.e.*, of the remaining, lumbar and sacral portions of the cord, the whole diameter of the posterior column in this region is altered, because the fibers derived from the deeper level and lying more in the center also are involved. If the process subsequently advances upward, *i.e.*, involves also the root areas of the dorsal and cervic cord, lateral areas of degeneration, in addition to degeneration in Goll's column, appear at these levels. Furthermore, as the posterior horns receive fibers from the posterior roots, they also become poorer in fibers. Among those fibers which enter the posterior horns from the posterior columns are also reflex fibers which pass on to the anterior horns; the reflex tract for the knee reflex is at the level of the first to the second lumbar nerves; since tabes dorsalis early occurs at this level, the early disappearance of the patellar tendon reflex in this affection is thus explained. (Smaus.)

In severe cases symmetric, gray degeneration of the sensory tracts of the lateral columns also is found in tabes. The latter, however, occurs also without tabes as an independent disease. This begins in the inner portions of the lateral columns—in the so-called lateral pyramidal tracts—and in its further course is combined with atrophy of the large ganglia in the gray anterior horns and with atrophy of the muscles belonging thereto (**amyotrophic lateral sclerosis**) The atrophy extends upward to the pyramids of the medulla oblongata, sometimes through the pons, the crura cerebri to the internal capsule, and in some cases to the large ganglion cells of the cen-

tral convolutions. By involvement of the nerve-nuclei located in the medulla oblongata (hypoglossus, vagus, accessorius), atrophy of the lips, tongue, etc., develops. Such patients die with bulbar symptoms, usually from aspiration pneumonia.

Landry's paralysis (acute ascending paralysis), described by Landry in 1859, is a rapidly progressive paralysis beginning in the extremities, extending to the trunk and arms, and, finally, to the respiratory muscles. It occurs most frequently in males between the 20th and 30th year. The majority of cases terminate fatally. The toxic theory of the pathogenesis has been insufficiently established, or, at least, the origin and mode of action of the toxins are still obscure.

Some authorities regard Landry's paralysis as a form of acute polyneuritis, others class it as anterior poliomyelitis associated with bulbar poliomyelitis. Von Leyden states that many cases of Landry's paralysis are of polyneuritic origin. He recognizes two forms: (1) the bulbar or medullary, corresponding to the Landry type (flaccid paralysis, no disturbances of sensibility, no degenerative muscular atrophy, no reaction of degeneration); (2) the neuritic form, in which, in connection with a polyneuritis, spinal-cord inflammations rapidly develop (parenchymatous inflammations, swollen axis-cylinders with thinning of the medullary sheaths, etc.). Oppenheim asserts that Landry's paralysis cannot be identified with polyneuritis or poliomyelitis.

According to Bolten,[1] Landry's paralysis is a sharply defined pathologic process differing from polyneuritis and poliomyelitis by the absence, even in slowly progressing cases, of muscular atrophy, reaction of degeneration, and of manifestations of sensory paralysis. He holds that the typic cases are due to intoxication; the paralyses are the result not of anatomic destruction, but functional elimination of the spinal and bulbar centers. The toxins appear to leave the sensory neurons intact and to suspend exclusively the function of the motor neurons without attacking the structure. All examples in which reactions of degeneration and degenerative muscular atrophy are manifest are cases of very rapidly progressive polyneuritis (with or without the parenchymatous inflammations of the spinal cord described by von Leyden), or of very far advanced poliomyelitis which extends to the bulb. According to Bolten, all cured cases of Landry's paralysis show complete *restitutio ad integrum.*

E. Leschke[2] found intra- and extra- cellular so-called Landry's corpuscles, 0.1 to 0.2 μ in size, in the anterior horn cells in sections and smears from the spinal cord. The virus was filterable. Cultures obtained by the method employed by Noguchi for spirochætæ, poliomyelitis, and rabies virus were carried to the second generation, and when inoculated into 5 monkeys produced, after an incubation

[1] Berlin. klin. Woch., Jan. 16, 1911, p. 113.
[2] Berlin. klin. Woch., April 27, 1914, p. 783.

period of from seven to twenty-three days, acute paralysis and death within a few hours. The disease could be transmitted from monkey to monkey.

The **filling of the vessels of the brain** is subject to great variations in spite of the bony skull capsule. This is made possible by the fact that the cerebrospinal fluid in the communicating ventricular and canal system also is subject to the same variations, but in a contrary sense, *i.e.*, in increased filling of the blood-vessels, the rapidity of outflow of the lymph is augmented at the neck, as has been proved experimentally.

The **vascularity of the brain** is judged according to the size and number of the blood-points which can be seen upon a fresh section of the white medullary substance. A true uniform capillary hyperemia of the white substance is observed only in small children in whom relatively little myelin is as yet developed. In adults the white substance is slightly mottled, very pale rose-colored in the state of capillary hyperemia. On the other hand, if the larger vessels are intensely congested very numerous, quite closely arranged, large drops of blood appear very quickly upon the freshly cut surface, while in anemia only isolated and very small droplets gradually become visible, sometimes none.

The relation is different in the cortic substance and the large ganglia: In anemic states the gray cerebral substance has a pale-gray, in hyperemic states a reddish-gray, occasionally a grayish-red (hortensia), color. Usually, hyperemia of the gray substance is not uniform, but macular. Pronounced cerebral anemia is generally a concominant of a general anemia.

Edema of the brain is recognizable by the moist and glistening appearance of the freshly cut surface, which ordinarily has a slightly moist or a non-glistening character. In edema a watery fluid escapes from the tissues and accumulates in more or less visible amounts upon the cut surface. Slight edema is quite frequently observed without an explanation therefore being found in every instance. More marked degrees of edema occur as a result of venous engorgement (in cardiac and pulmonary diseases), in anemic states, and as a result of still unknown causes. Intense cerebral edema may be a cause of death: *apoplexia serosa*. Partial edema is very frequent in the neighborhood of inflammatory affections especially abscesses, hemorrhages, and tumors.

According to origin and extent, two forms of cerebral hemorrhage must be distinguished, namely, **punctiform** and **profuse cerebral hemorrhage.** The latter occurs as a result of rupture of an arterial vessel (not from capillaries). The source of the hemorrhage cannot always be found, but may often be revealed on careful examination. The vessels from which large hemorrhages originate are usually characterized by the formation of miliary aneu-

risms—small, 0.2 to 1 mm. in size, seldom larger, spindle- or spheric-shaped, rarer sacculated dilations of the smaller and minute arteries. As a rule, it is just within these aneurismal foci that rupture occurs. The blood pours into the brain-tissue, destroys the tissue, and forms a cavity in which it coagulates (it never remains liquid). Numerous small, closely arranged, red spots—punctiform hemorrhages—can be seen in the neighborhood. (See p. 596.)

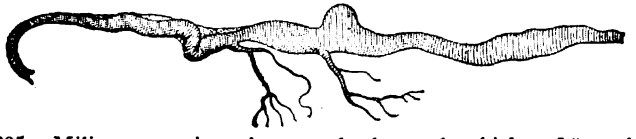

Fig. 305.—Miliary aneurisms in a cerebral vessel. (After *Löwenfeld.*)

The typic site of these profuse hemorrhages is the region of the large ganglia, especially the corpus striatum and the lenticular nucleus. The arteries which supply these parts with blood come from the base, where they enter the brain at a right angle; they are terminal arteries in the sense of Cohnheim, and, therefore (especially the *arteria lenticulostriata*), according to the experimental investigations of Mendel, are under higher pressure than other arteries, because they form, in a

Fig. 306.—Dissecting aneurisms on a cerebral artery. (After *Löwenfeld.*)

measure, the direct continuation of the internal carotid. If the hemorrhage is very large, it may rupture into the adjacent part of the lateral ventricle and fill all ventricles with blood. More rarely the hemorrhage extends to the arachnoid.

More or less large hemorrhages are observed also in highly vascular tumors. Here the newly formed, delicate-walled vessels are always the source of the hemorrhage.

As the larger hemorrhages are associated with a rapid, sudden, transitory or permanent suspension of the function of the brain and the affected individual is suddenly prostrated as by a blow, the term

apoplexy [1] is generally employed to designate this condition. Apoplexy signifies only the symptomatic violence of the onset; it is purely a clinic expression, not an anatomic conception, for when anyone has died we can no longer speak of a visible apoplexy, but, at most, of an apoplectic focus.

Death may occur suddenly as a result of interruption of the functions of the brain, the heart, and lungs. In every case one may justly speak of an apoplexy (cerebri, cordis, or pulmonum), but, as a rule, apoplexy cordis and pulmonum occur without hemorrhage.

In the brain the following apoplexias must be distinguished:—

1. *Apoplexia hæmorrhagica:* a large hemorrhagic focus.

2. *Apoplexia hypercæmica:* without local hemorrhage, only excessive engorgement of the vessels.

Both these forms are caused by blood; hence, *apoplexia sanguinea.*

3. *Apoplexia anæmica:* due to interruption of the blood-current from anemia:—

(*a*) Embolic form.

(*b*) Vascular occlusion from other causes: compression from without, obliteration from endoarteritis, etc.

4. *Apoplexia serosa:* in total obstruction to the outflow of venous blood: acute hydrocephalus (from tumors, changes of the vena magna Galeni).

5. *Apoplexia nervosa,* or shock: the old "stroke" without demonstrable anatomic change.

When death occurs as a result of hemorrhage, bloody imbibition in the neighborhood of the hemorrhage is not infrequently found at necropsy. This is always a cadaveric process which may occur also subsequently, *i.e.,* after necropsy. If, however, death does not occur, imbibition of the surrounding parts develops of necessity during absorption; the red blood-corpuscles are gradually dissolved, the blood coloring matter penetrates the neighboring parts and is from there carried off by the circulation. While post-mortem imbibition is usually very intense, imbibition occurring during life is never marked, because the coloring matter is too rapidly carried away by the circulating fluids.

When absorption is ended, a somewhat smaller cyst, which at first contains a cloudy, brownish, watery fluid that later gradually becomes clearer, is found in the locality formerly occupied by the cavity filled with blood-coagula. The walls of such cysts consist of cicatricial tissue with abundant admixture of brown, granular or crystalline blood-pig-

[1] ἀποπληξία, to strike down.

ment. After very small hemorrhages only small, brown-pigmented cicatrices, but no cysts, are later found.

Profuse hemorrhages may occur also in other localities than in the large ganglia, *e.g.*, in chlorosis, influenza, hemorrhagic diathesis; but these are rare. If the pons is the seat of hemorrhage, then, if the hemorrhage is not immediately fatal, all those symptoms which gradually appear in atrophy of the ganglionic nuclei of the pons, in progressive bulbar paralysis, occur suddenly.

The spinal cord is only very exceptionally the seat of a large hemorrhage.

The second form of cerebral hemorrhage is punctate hemorrhage (*hæmorrhagia punctata*); numerous small, almost always submiliary, rarely miliary, red points, which cannot be rinsed off, are seen upon the cut surface of the substance. These correspond to small extravasations from the small vessels, which have either entered the lymph-sheaths surrounding the blood-vessels or have occurred into the brain substance itself after rupture of the lymph-sheaths.

Punctiform hemorrhages develop: (1) as the result of trauma, especially on the external (arachnoidal) and internal (ependymal) surfaces; (2) in inflammations, namely, in the neighborhood of abscesses; in purulent and tuberculous arachnitis; in *poliencephalitis acuta hæmorrhagica superior* (Wernicke) in the region of the oculomotor nuclei; (3) through alterations of the vessels—the arterial (embolic) as well as the venous (thrombotic in sinus thrombosis, thrombosis of the *vena magna Galeni*); (4) in the general hemorrhagic diathesis already mentioned (see p. 63); (5) in severe anemic states and in leukemia; (6) in cachectic individuals, and (7) in severe general infectious diseases (sepsis, influenza, etc.). The hemorrhages mentioned under 1 to 3 are more circumscribed; the others are more diffuse. Hemorrhagic states are most frequent in embolism, trauma, and thrombosis of the sinuses. In this condition, however, it is usually a question not only of a number of punctiform hemorrhages, but of states closely resembling hemorrhagic infarction of the lungs—of so-called red softening of the brain.

Telangiectases, which are quite frequent in the brain, may be mistaken for punctiform hemorrhages.

Three forms of softening of the brain are differentiated: red, yellow, and white.

In red softening the tissue between the closely arranged and partly confluent, punctiform hemorrhages has a diffuse, more or less intense red color, and is surrounded by an edematous, lemon-yellow-colored area. In this infarct-like state the brain substance is loose and

soft in consistency. Besides embolism, especially contusions, thrombosis, and hemorrhagic encephalitis cause red softening of the brain. In traumatism, softenings in the surface of the brain, which have originated by bursting of smaller vessels, are found beneath depressions and fissures of the bone. In these also three zones are recognizable: a central, diffuse, red zone; beyond this a punctate, red zone, and a peripheral, edematous, lemon-yellow zone. These three zones correspond to the different grades of extravasation: in the lemon-colored zone the blood-corpuscles are scattered and gradually dissolved, the tissue at the same time imbibing the blood-coloring matter; the punctate zone corresponds to the area of stronger action, and the diffuse, red zone to the area of strongest action.

In trauma not only a direct softening at the point of the acting force, but also an indirect softening through so-called *contrecoup*, frequently occurs, the concussion being transmitted through the firm parts; indeed, the soft parts, the bone and the adjacent parts of the brain at the point of direct action, may manifest no or slighter changes than the brain surface at the point of *contrecoup*, i.e., at the point of the brain directly (diagonally) opposite. This old view has recently been replaced by other theories, according to which the punctiform hemorrhages are referable to strong oscillations in the cerebrospinal fluid. According to one view (Duret), in trauma which affects directly the head, the fluid is quickly and suddenly displaced toward the fourth ventricle, and the hemorrhage is caused by the impact of the fluid. According to the other view (A. Miles), it is assumed that the cerebrospinal fluid, which in the lymph-sheaths, under normal conditions, exerts a counterpressure to the blood-pressure, in trauma is suddenly overcome, and that the counterpressure, until then exerted by the liquor upon the blood-pressure, is thus suddenly suspended and now numerous small vessels burst in consequence of the excess of blood-pressure.

The cortic red softenings caused by contusion usually do not extend far into the depth; only the uppermost layer of the gyri is destroyed. The softened parts are capable of involution, the blood-corpuscles dissolving and the cellular material being rendered absorbable by fatty metamorphosis. The fatty metamorphosis involves principally, and, perhaps, solely, the neuroglia cells, since the ganglion cells, even in advanced fatty metamorphosis of the neuroglia cells, are still distinct and but slightly altered. Ganglion cells, in general, appear to possess little or no tendency to undergo fatty metamorphosis. In those localities where some violent action has previously occurred, dead, calcified ganglion cells with well-preserved contour are frequently found.

The further the absorption of the hemorrhagicly softened material advances, the more the surface is depressed at this part, so that finally only yellow and brown lamellæ (*plaques jaunes*) of connective tissue covered by arachnoid are found at the slightly depressed point upon the surface: *cicatrices fuscæ corticales cerebri.*

Yellow softening of the brain owes its color to fatty metamorphosis of the neuroglia cells and to numerous round cells filled with fat (wandering corpuscles). Softening of the nerve-fibers progresses without especial morphologic change, only varicose swelling and segmentation of the myelin sheath occurring. The cause of yellow softening is

Fig. 307.—Calcified ganglion cells from the cerebral cortex after a healed fracture of the skull. Fresh section from the under surface of the left frontal lobe. (Zeiss Apochr., 16; Comp. Ocul., 8. After *Langerhans.*)



Fig. 308.—A calcified ganglion cell from the cerebral cortex after healed fracture of the skull. At * noncalcified location of nucleus. (Zeiss Apochr., 4; Comp. Ocul., 8. After *Langerhans.*)

insufficient nutrition through interference or interruption of arterial blood-supply, whether an embolus occludes the lumen or the lumen is compressed by a tumor or is altered by proliferation (*arteriosclerosis*). Yellow softening occurs also as a secondary change in red softening.

The third form of softening, **white softening of the brain,** is a purely cadaveric process—a post-mortem softening of the brain substance resulting from maceration (not putrefactive). It occurs most frequently in acute internal hydrocephalus through entrance of watery fluid in the region of the ventricles. The consistency of the parts is thus loosened; they become separated, disintegrate, and soften. The principal seat of this change is the *corpus callosum.*

The **ependyma** is the lining membrane of the ventricles. It is not simple connective tissue in the ordinary sense of the word, for it contains no fasciculi and no curly fibrillæ; but it belongs to the type of connective substances: it is the same as the neuroglia—the interstitial tissue of the brain—merges immediately with this, and differs from the true neuroglia only in so far as it forms upon the surface of the ventricles a thick layer without medullated nerve-fibers. The ependyma is an almost vascularless membrane, and cannot, therefore, be a true secreting membrane. There is a parallelism between the cerebral cavities and articular cavities in so far as both possess a nonvascular (ependyma, cartilage) and a vascular portion (*velum chorioides* and *processus chorioideisynovialis*). The **velum,** or the *tela chorioides,* does not form with the processus chorioidei a true covering of the surface, but is rather loosely attached and is separated only with some difficulty from the *corpora quadrigemina.* In chronic hydrocephalus a chronic inflammatory process: *ependymitis chronica,* develops in the ependyma, which results in a somewhat irregular thickening of the ependyma, such as is normally present at the *stria cornea* at the margin of the *corpus striatum.* By proliferation of the glia cells small superficial swellings develop, as in arteriosclerosis, which are as delicate and transparent as dew-droplets. These consist of a richly cellular, soft, somewhat colloid tissue, not of accumulations of fluid. Through further growth the droplets become larger and the surface assumes a warty appearance: *ependymitis verrucosa.* With progressive growth true tumor formation: glioma, finally occurs.

The granular and warty thickenings are nonvascular. In the course of this ependymitis, partial agglutinations and adhesions, especially in the anterior and posterior horn of the lateral ventricle, quite frequently develop, similar to what occurs in chronic endocarditis.

In alterations of the vascular portion of the ventricles, secretion of albuminous fluid may occur: *hydrocephalus internus.* This fluid usually is uniformly distributed in all the ventricles, although it is most distinctly manifest in the lateral cavities. According to the rapidity with which the secretion is formed are distinguished acute and chronic hydrocephalus. The first is due to acute inflammatory processes in the *velum chorioides* and the *processus chorioidei;* the ependyma is unaltered. In suppurative inflammations of the choroid plexus the secreted fluid is clouded by pus-corpuscles and may finally become more or less purulent. Inflammatory changes of the choroid plexus are intimately connected with inflammations of the arachnoid. (See p. 593.)

Chronic hydrocephalus may be congenital or acquired. If the affection begins in an early embryonic period, before the brain

is fully developed, malformation results. On the other hand, if the brain is developed, dilation of the ventricles results. The brain distends; the skull yields and grows to a marked degree. The intenser grades always develop after birth. The ependyma is thickened; the *corpora striata* and *thalami optici* are widely separated and flattened; the large cerebral hemispheres are thin, the gyri flat, the sulci more or less obliterated; the skull (in very high degrees even the whole head) is strongly distended and tends to assume a spheric form, the bones, owing to the pressure, becoming farther separated and the suture substance increasing in breadth (grows). Upon the inner surface of the skull, which is always very thin, the *impressiones digitatæ* are distinctly developed as a result of atrophy of the inner table; the inner surface of the bone is uneven, lusterless, rough through osteoporosis; the carefully palpating finger feels countless small, delicate spicules. So long as this roughness persists arrest has not occurred; as soon, however, as the hydrocephalus ceases to increase, the internal table again becomes smooth.

In the most marked degrees the vault of the skull as well as the thickness of the large hemispheres are as thin as paper, while the cerebellum suffers comparatively little. Principally the white substance atrophies; the gray substance is less affected. Therefore, the defect of the mental, cerebral function is usually not very great. The higher degrees always terminate fatally as a result of pressure and atrophy of the brain substance. The causes cannot always be discovered; chronic thickenings of the *velum chorioides* frequently point to a chronic inflammatory process.

If a chronic ventricular hydrocephalus develops at a period in which the brain has completed its growth, the causes are easier to recognize. These are almost always processes which obstruct or arrest the outflow of blood through the *vena magna Galeni* (e.g., *hydrops cysticus glandulæ pinealis,* cysticerci, true tumors, etc.).

Accumulation of fluid and dilation may occur also in the spinal canal. Hydropsic partial ectases in partial adhesions of the narrow canal are most frequent. In milder degrees (not rarely in the cervic cord) no marked disturbances result; in higher degrees, however, atrophy of the spinal cord, exceptionally also complete interruption, occurs, as in the brain. Through partial adhesions of the central canal apparent duplication of the canal sometimes develops.

Elongated cavities filled with fluid, which have originated through tissue destruction, are sometimes found also outside of the central canal: *syringomyelia.* Some of these cavities communicate with ectases of the central canal.

Among the tumors[1] of the central nervous system, glioma, gliosarcoma (see p. 241 *et seq.*), and solitary tubercle (see p. 469) predominate. Sarcomata start most frequently from the dura mater, especially spindle-celled sarcoma (see p. 250); carcinomata, pearl tumors: cholesteatomata (see p. 281), and lipomata from the arachnoid; glioma frequently from the ependyma. Among the secondary metastatic tumors carcinoma and the melanotic tumors are first of all to be mentioned. The most frequent animal parasite is the cysticercus. This often occurs multiple in the arachnoid.

As an appendix to the brain, the **hypophysis,** or pituitary gland, composed of two lobules, lies in the *sella turcica.* The structure of the anterior, larger lobule resembles that of the thyroid gland; the smaller, posterior portion is very rich in nerves, and forms the bulbous end of the infundibulum—the *filum terminale anterius.*

In simple enlargement of the hypophysis the anterior portion only is always involved; the follicles become larger and richer in cells, so that the gland is more prominent as a result of the hyperplasia. This is the same process which, in the thyroid, leads to struma: *struma pituitaria.* Colloid accumulation also is observed. Enlargement of the hypophysis often occurs in acromegalics, and is, therefore, frequently brought in causative relation with acromegaly.

Primary tumors (carcinoma, sarcoma, lipoma) sometimes start from the hypophysis.

The hypophysis possesses interest also in regard to organ correlation. It undergoes a certain hypertrophy when the thyroid gland is extirpated (rabbits) or atrophies (*i.e.,* in myxedema). It is also frequently hypertrophied in acromegaly. Hypophysial tumors, which produce hemianopsia by pressure in the region of the chiasm, are often tissue hyperplasias or adenoma. The surmise that affection of the hypophysis is the cause of acromegaly appears to be supported by improvement of the malady after extirpation of the hypophysis. In this disease loss of the hair, also upon the pubes, and atrophic disturbances in the genital sphere occur.

The **pineal gland** (*glandula pinealis*) lies in the flat depression between the anterior tubercle of the *corpus quadrigeminum,* and is very loosely connected with the posterior commissure. It is characterized by its richness in brain sand (*corpora arenacea*), which is found principally at the base. The *corpora arenacea* are concentricly lamellated bodies which differ from the *corpora amylacea* by the fact that they give no iodine reaction; they never occur in the interior of the nervous apparatus, but only within the cerebral membranes. Under pathologic conditions they are sometimes observed in lymph-glands and in the serous membranes. The most frequent changes of the pineal

[1] For gumma, see p. 554.

gland consist in swelling (struma), cystic degeneration, and abscess formation.

According to Raymond and Claude,[1] 5 cases of tumors of the pineal gland are recorded. Their growth is attended by adiposity, growth of hair upon the face and pubes, abnormal development of the genital organs, acute hydrocephalus, amaurosis, bilateral hemiplegia, paraplegia, and cerebellar symptoms.

Topographicly, it may briefly be stated that the cortic substance of the anterior and posterior central convolutions (see Fig. 309) forms

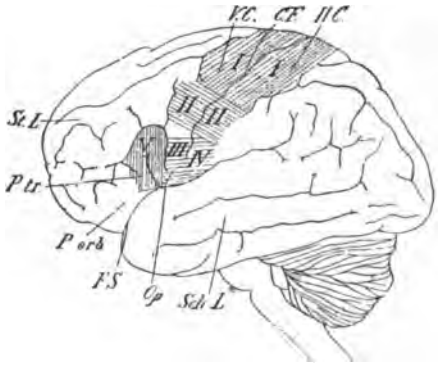

Fig. 309.—*C F*, central fissure, or fissure of Rolando; *V C*, ascending frontal convolution; *H C*, ascending parietal convolution; *P tr*, pars triangularis; *St L*, frontal lobe; *Sch L*, temporal lobe; *Op*, operculum; *F S*, fissure of Sylvius. (After *Langerhans.*)

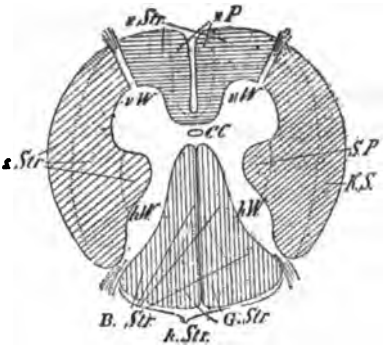

Fig. 310.—*C C*, central canal; *v W*, anterior roots; *h W*, posterior roots; *v Str*, anterior columns; *v P*, anterior pyramidal tract; *s Str*, lateral columns; *K S*, lateral cerebellar tract; *S P*, lateral pyramidal tract; *h Str*, posterior columns; *B Str*, columns of Burdach; *G Str*, columns of Goll; ≡, motor region; ||||, sensory region; ////, mixed region. (After *Langerhans.*)

motor centers, namely, the uppermost portion of both (left) central convolutions (I) the center for the (right) lower extremity; the middle portion (II) for the upper extremity, and the lowermost portion (III and IV) the operculum for the facialis.

In destruction of one of these portions, paralysis occurs in that region of the body belonging thereto.

By destruction of the internal capsule all conducting tracts may be interrupted, and the same is true in affection of the *pedunculus cerebri* and of the pons.

---

[1] Bull. de l'Acad. de Méd., March 15, 1910.

The occipital lobes form the center of vision, the temporal lobes the center of hearing.

In the spinal cord the anterior columns (see Fig. 310, *v Str*) form the motor tracts, the posterior columns (*h Str*) the sensory tracts, and the lateral columns (*s Str*) mixed, motor, and sensory tracts. The lateral cerebellar tracts (*K S*) are motor inhibitory tracts (in disease of the same the patellar reflex, for example, is increased); the lateral pyramidal tracts (*S P*) are, likewise, motor. The areas between the lateral cerebellar tracts and the lateral pyramidal tracts are purely sensory tracts.

PERIPHERAL NERVES.

As soon as the peripheral nerves are separated from the central nervous system by section, ligature, a contused wound, etc., atrophy of the peripheral portion occurs, the myelin of the medullated fibers first becoming segmented and coagulated in clumps and drops. The axis-cylinder remains longer intact, but in most cases finally also degenerates. Of the central portion only a small part is lost.

Atrophic processes also follow central disturbances, *e.g.*, in atrophy of the large motor ganglion cells in consequence of acute anterior poliomyelitis, and are always to be found in *tabes dorsalis*, and, indeed, as a rule, very early.

When the continuity of the nerves is interrupted by section, reunion not infrequently occurs, new formation of medullated and nonmedullated nerve-fibers taking place in the central stump. These newformed nerve-fibers grow toward the peripheral stump of the nerve, and, after union has previously occurred through young connective tissue, sometimes result in restoration of contact and conductivity by union of both stumps. If, however, the stumps are too far apart or have suffered from other processes (suppuration, etc.), the budding nerve-fibers do not reach the peripheral stump or they grow in a false direction and are destroyed in the cicatricial tissue.

New formation of nerve-fibers in the central stump can best be observed in amputation stumps. Here smaller and also larger tumors —genuine neuromata—composed of medullated and nonmedullated nerve-fibers, almost invariably develop. If a number of nerve-trunks lie side by side in the amputation stump, union of the individual nerve stumps frequently occurs as a result of proliferation.

Inflammations of the peripheral nerves always affect first the interstitial tissue—the perineurium and the neurilemma. The true parenchyma of the nerves—the nerve-fibers—are only secondarily involved by atrophy. *Neuritis interstitialis* may lead either to suppuration,

though only as a result of extension from neighboring parts, *e.g.*, in suppurating, ichorous wounds, or to chronic induration as a result of hyperplasia of the connective tissue.

Besides the scar and amputation neuromata already mentioned, true hyperplastic, fibrillar, and cellular neuromata also occur in the peripheral nerves under other conditions. In contrast to these stand the false neuromata, the myxomata, and gliomata. Among the metastatic tumors, the carcinomatous and the epitheliomatous forms especially occur within the nerves, often extending far beyond the zone of the immediate lesion. (See Optic Nerve.) These frequently give rise to recidives.

SUPRARENALS (ADRENALS, SUPRARENAL BODIES, OR CAPSULES).

The suprarenal glands owe their name solely to their close proximity to the kidneys, each suprarenal capping, as it were, the upper pole of a kidney. Otherwise they have no recognizable connection with the kidneys. Nothing is known of the function of the suprarenals, and there is no unanimity of opinion as regards their anatomic structure.

Three zones are differentiated: the external, or cortic, layer has a certain resemblance to the thyroid gland; it is yellow and formed of radiately arranged follicles, the cells of which are filled with numerous fat-droplets. In healthy newborn subjects, whose adrenals are comparatively large (almost as large as the kidneys), this fatty state is absent; the cortex appears very thick, grayish red. The inner zone, or medullary layer, stands in more or less intimate relation to the nervous apparatus.[1] It is composed, aside from the numerous vessels, principally of ganglion and neuroglia cells. The middle zone, or intermediary substance, likewise has a follicular structure; it is, however, characterized by brown pigmentation of the follicle cells. This layer is subject to the greatest variations in breadth and extent, and is almost always absent at the somewhat narrow margin of the organ.

In atrophic states resulting from anemia, cachexia, senile marasmus, the fat content diminishes; the cortex becomes narrow and acquires a grayish-red color. Sometimes the atrophy markedly alters certain portions, so that small, yellowish granules persist and easily create the impression of tubercles. In the higher degrees of atrophy the medullary substance also is always distinctly involved.

Hyperplasia of the cortic substance develops as a result of proliferation of the follicle cells; this involves either the whole cortex or

[1] See Chromaffin System, p. 345.

only small, isolated areas of the same. In the latter case swellings up to the size of a walnut, of yellow or (when the intermediary layer also is involved) of brown color, develop. This condition, owing to the resemblance to *struma thyreoidea,* is designated as *struma suprarenalis.*

In the medullary substance also nodules as large as a cherry are

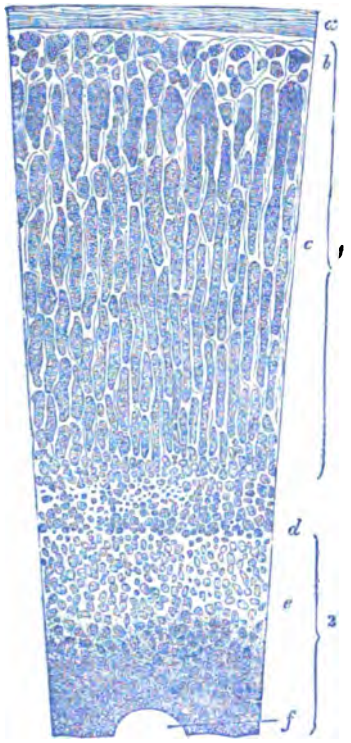

Fig. 311.—Vertic section of suprarenal body. 1, cortic substance; 2, medullary substance: *a,* capsule; *b,* zona glomerulosa; *c,* zona fasciculata; *d,* zona reticularis; *e,* groups of medullary cells; *f,* section of a large vein. Magnified. (After *Eberth.*)

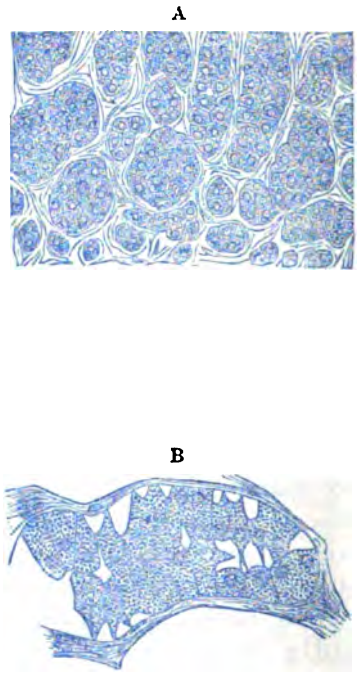

Fig. 312.—*A,* Cells and cell-groups from the outermost layer of the cortic substance of the suprarenal body; *B,* a small portion of the medullary part of the suprarenal capsule of the ox. (After *Eberth.*)

sometimes observed—partial hyperplasias resulting from proliferation: so-called *gliomata suprarenalia.*

In extensive amyloid degeneration of the abdominal organs the suprarenals also are usually affected. (See Fig. 313.) They are then enlarged, inelastic, very firm, almost stiff, and glassy gray. Here also

the amyloid substance appears first in the small vessels, especially in the region of the intermediary zone.

Parenchymatous, hemorrhagic, purulent, and chronic interstitial inflammations, as well as cystic[1] formations, are sometimes observed. Since very little is known of the etiology and significance of these processes, they are only briefly mentioned here.

The primary and secondary tumors occurring in the suprarenals are, first of all, carcinomata, especially melanotic carcinomata. Sarcomata are rare. Animal parasites (echinococcus, etc.) are of extremely rare occurrence.

In conclusion it may be mentioned that efforts have repeatedly been made to bring the suprarenals in intimate connection with the



Fig. 313.—Amyloid degeneration of the suprarenal gland. Fresh-cut surface treated with iodine. The amyloid parts colored red by the iodine are shown in black in the illustration. From a case of syphilis. (After *Langerhans.*)

sympathetic and the central nervous system, because in Addison's disease,[2] in which changes are so frequently found in the sympathetic, the suprarenals are often diseased, caseous degenerated (see p. 478), and because in monsters, especially anencephalia, the suprarenals are frequently only incompletely developed or absent. Worthy of consideration as these findings are, a constant relation between affection of the suprarenals and disease of the sympathetic, on the one hand, and monster hypoplasia or defect and suprarenal hypoplasia or defect, on the other hand, has not thus far been demonstrated.

[1] British Medical Journal, June 27, 1908, p. 1558.

[2] In Addison's disease a function of the suprarenals which neutralizes the toxic products causing endogenous proteid disintegration, and which cannot be regulated by adrenin, is said to be disturbed. In the urine there has been found a very small amount of a coloring matter, classed with the melanins, which is soluble only in dilute alkalies and ammonia and contains neither iron, sulphur nor nitrogen.

VASCULAR SYSTEM.

HEART.

Pericardium.

THE **pericardium** is a serous membrane consisting of two apposed layers, namely, the visceral (epicardium) and the parietal layers. Between these, in the normal state, there is always a very slight, scarcely measurable amount of clear, yellowish or slightly greenish fluid. Marked increase of the pericardial fluid without inflammatory phenomena is called hydropericardium, which most frequently is a sequela of chronic cardiac and renal affections, though it occurs also in grave general conditions affecting the blood and circulation. The limits between the physiologic state and hydropericardium are often difficult to determine, because the amount of fluid is very frequently increased without the existence of a true hydrops. A certain increase (15 to 30 c.c., occasionally more) appears to be an agonal phenomenon, since it is very frequently found. The fluid of hydropericardium resembles lymph. (See p. 686.) On contact with the air, coagulable fibrinogen substance is separated; it thus forms a lymphatic hydrops.

Small, punctiform hemorrhages are frequently found in the pericardium, especially upon the posterior surface of the heart near the base. These develop *sub finem*, during the agony, when death occurs from suffocation; they may occur, however, independently of the agony in severe infectious diseases (diphtheria, etc.), in certain intoxications (*e.g.*, phosphorus poisoning), and in general hemorrhagic diathesis. Larger free hemorrhages between the layers of the pericardium (hemopericardium) are observed in rupture of the heart, bursting of an aneurism of the coronary arteries, of the sinus Valsalvæ, or of the aorta; in trauma (namely, stab and gunshot wounds), and in hemorrhagic inflammation of the pericardium. The amount of blood poured into the pericardial sac—which always coagulates very quickly—may be so large as to more or less intensely distend the visceral pericardium, and by pressure cause arrest of the heart's action.

The **exudative inflammations** of the pericardium are either local—circumscribed—or they involve the whole pericardial sac, *i.e.*, both layers of the pericardium. In the first instance either only one surface of the pericardium—as a rule, the visceral pericardium—is

affected or both apposed and contiguous surfaces are involved. The exudate may vary:—

1. Fibrinous, watery-fibrinous: fibrinous or hydrofibrinous pericarditis.

2. Fibrinous-hemorrhagic: fibrinous-hemorrhagic pericarditis, or, when the exudate in comparison to the extravasate is insignificant: hemorrhagic pericarditis.

3. Fibrinopurulent or purely purulent: fibrinopurulent pericarditis, purulent pericarditis.

Fig. 314.—Fibrinous pericarditis; pericardium turned back to show the surface of the heart covered with fibrinous formation. (*Orth.*)

4. Ichorous: ichorous pericarditis.

Points of predilection of partial fibrinous inflammation are the *conus arteriosus* of the right ventricle, the apex of the left ventricle, and both auricles.

When very little fibrin is exuded, this usually lies firmly upon the surface and is not recognizable as fibrin; in this case, however, the surface has a characteristic, dry, cloudy, and somewhat rough appearance; by scraping and scratching with a clean knife, some fibrin can be removed from the surface. If, on the other hand, much fibrin and only little watery fluid are exuded, the fibrin is distinctly recognizable,

and, in part, easily lifted from the surface; and, owing to friction of the apposed surfaces of the pericardium, forms peculiar figures which, upon the anterior surface of the heart, correspond to ridges and undulations, upon the posterior surface to villi: *cor villosum.* (See Fig. 314.) This peculiar accumulation of the fibrinous exudate is due to the direction of heart movement and the amount of fluid exuded at the time.

Hemorrhagic pericarditis generally develops in connection with a fibrinous inflammation; in a measure, it is an augmentation of fibrinous inflammation, but it may have a hemorrhagic character from the beginning, *e.g.,* in scorbutus.

Fibrinopurulent or **purulent pericarditis** is usually a process resulting from extension from adjacent parts, either the myocardium (after metastatic abscesses of the myocardium in severe infectious diseases) or the pleura (after empyema in pulmonary phthisis, purulent pleuritis, in connection with severe pneumonia) or the peritoneum (in sacculated suppuration in connection with perforation of the stomach, abscess of the liver, purulent perityphlitis, etc.).

An ichorous exudate occurs in the pericardium as a metastatic affection in severe ichorous processes in other organs, and as the result of extension of ichorous pleuritis after perforation of an esophageal carcinoma, etc.

When only the visceral pericardium is affected, partial fibrinous inflammations result after a time, by organization of the exudate, in the formation of whitish, tendinous thickenings: the so-called *maculæ tendineæ;* when both apposed and contiguous surfaces elaborate fibrinous exudate, partial adhesions result. These are at first more flattened, but if they are confined to small areas they may in time become cord- or thread- like as a result of continued traction. Complete, flat adhesion of both pericardial surfaces always results from general fibrinous pericarditis. In this case the whole cavity of the pericardium is obliterated: *obliteratio pericardii.* At first the adhesions can quite easily be separated with a blunt instrument; later, the union of both layers may be so intimate and firm that they can no longer be separated.

When fibrinous pericarditis becomes chronic, frequent recidives occurring, the adherent pericardial layers thicken more and more, the new masses of exudate also becoming organized. This finally results in the formation of very thick, and also, as a rule, very firm, almost solid indurations in which, under certain conditions, when the process ceases, lime-salts may be deposited in greater or lesser amount. From this smaller and larger lime-plates develop, or sometimes even an almost completely calcified capsule, which incloses the heart, results.

Aside from the inflammatory irritation, every marked exudation

in the pericardium is a mechanic impediment to the movements of the heart and, therefore, favors degenerative changes of the heart substance, and may even cause arrest of the heart's action by pressure.

Every adhesion embarrasses the cardiac movements, increases the resistance, and the amount of labor of the heart, and, therefore, usually results in hypertrophy. This is generally the stronger the more extensive the adhesion, the thicker the adhesions become in the course of recurring pericarditis, and the greater the number of synechiæ existing between the parietal pericardium and adjacent parts (pleura).

Chronic recurrent fibrinous pericarditis is frequently complicated with tuberculosis. The younger eruption of tubercles is then found in the more recent layers of exudate undergoing organization, the older in the older exudation lamellæ. (See p. 465.)

In rare cases air or gas is found in the pericardium: *pneumopericardium.* This can occur only as a result of perforation of the parietal pericardium, when no adhesions exist, *e.g.*, in stab or gunshot wounds, or in perforation of a gastric ulcer or carcinomata, etc., into the pericardium, or on entrance of gas-forming micro-organisms.

Myocardium.

Between the visceral pericardium and the musculature there is a layer of fat, which is greater or less in amount according to the state of nutrition. In individuals who manifest a marked disposition to obesity (polysarcia), also within the skeletal musculature, a very thick layer of fat is frequently found beneath the pericardium. This condition is unattended by permanent harm; as soon, however, as the interstitial connective tissue of the heart muscle is involved in the formation of fat-tissue, an irreparable pathologic state develops: **fatty heart,** in a strict sense. As in this condition the musculature is degenerated, this change is designated as **fatty degeneration,** or *lipomatosis myocardii,* because the fat-tissue, as in lipoma, permanently increases. This proliferation of the adipose tissue always begins at the pericardium, extends from there toward the endocardium, and is invariably more intense in the external than in the internal portions of the myocardium. The connective tissue is not destroyed by this process, but transformed into, or displaced by, adipose tissue. This metaplasia offers mechanic resistance to the contraction of the muscle, and, furthermore, causes the heart-muscle to atrophy as a result of nutritive disturbances, the young proliferating fat-tissue appropriating the nutritive material. The more fat produced, the greater is the atrophy of the muscle, so that the whole thickness of the wall at the right border of the heart finally

consists only of fat-tissue. The right ventricle is usually more frequently and intensely involved than the left.

The state of atrophy of the myocardium is always caused by malnutrition, *i.e.*, nutritive disturbances. Three forms may be differentiated:—

1. *Atrophia simplex*, simple atrophy. In this condition the muscle-bundles become smaller in diameter without any other visible alterations and without diminution in the number of cells or muscle-bundles.

2. *Atrophia fusca.* In this state two phenomena really coexist—atrophy and pigmentary degeneration. Both are usually included under



Fig. 315.—Fatty degeneration of the heart (lipomatosis). (Zeiss Apochr., 16; Comp. Ocul., 4. Reduced ⅓. After *Langerhans.*)

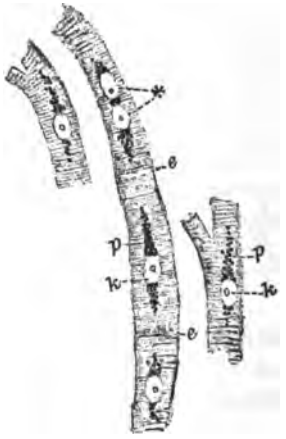

Fig. 316.—Pigment atrophy of the heart. *k*, nuclei; at * two nuclei in one cell; *e*, Eberth's cement lines; *p*, pigment at the poles of the nucleus. (Zeiss Apochr., 4; Comp. Ocul., 4. After *Langerhans.*)

the term **"brown atrophy."** This also is attended by diminution of the diameter of the muscle-bundles, but, in contradistinction to simple atrophy, is characterized by pigment formation. The pigment occurs at both ends of the muscle-nuclei in the form of very small, brown, amorphous, somewhat irregularly shaped granules. Brown atrophy is, first, the result of severe general nutritive disturbance, an accompaniment of a general macies (emaciation); second, a frequent manifestation in old age. Pigmentary degeneration of the cardiac musculature sometimes is found also in hypertrophied hearts (in arteriosclerosis, chronic nephritis). In these cases the process cannot justly be called brown "atrophy," because the musculature is hypertrophied, even though the pigment, as a

dead mass, affects the cells and has taken the place of the functionable parenchyma. The designation then employed is pigmentary degeneration, or brown degeneration, of the heart muscle.

3. **Necrobiotic atrophy.**[1] This is caused by fatty metamorphosis of the musculature and develops first by the formation within the transversely striated musculature of most minute, finest fat-droplets (like sun-dust) arranged partly transversely (corresponding to the transverse markings), partly longitudinally (rosary form). These fat-droplets subsequently become larger and then are arranged less regularly. With this change the transverse markings become indistinct and finally totally disappear, besides the fat-droplets only a slight amount of albuminous fluid remaining. On tearing of the muscle, a fatty detritus exudes.

Fatty metamorphosis may be d i r e c t, primary after nutritive dis-

Fig. 317.—Small fragments of the heart muscle in advanced stage of fatty metamorphosis in severe parenchymatous nephritis. (Zeiss Apochr., 4; Comp. Ocul., 4. After *Langerhans.*)

turbances, *e.g.*, after embolism of the coronary arteries, in passive dilation, in pernicious anemia, or i n d i r e c t, secondary to antecedent inflammation: *myocarditis parenchymatosa.* The latter begins with swelling due to overaccumulation of proteid material. The muscle-bundle is thus enlarged, especially the transverse diameter. While the newly absorbed material is proteid substance, it differs from the constituents of the muscle and, owing to the inflammatory disturbance, is not assimilable. It appears indistinctly granular; the transverse markings are not so clearly defined as normal, but somewhat obscured, indistinct, cloudy; hence, the whole muscle, as far as it is involved, has a cloudy, m o t t l e d appearance. If a little dilute acetic acid is added to such a heart muscle, clearing at once takes place; the transverse markings are thus again rendered distinct and sharp. When the process advances farther, fatty metamorphosis begins, fat occurring inside the muscle-bundles in the form of very minute fat-droplets. The affected portion thus acquires macroscopicly a pale-yellow color.

[1] See p. 116.

Parenchymatous inflammation affects either the whole heart muscle or, what is more frequent, it occurs in mottled, disseminated form. The left ventricle, which performs most of the labor of the heart, is more frequently altered than the right. As a rule, the affection begins in the papillary muscles: *myocarditis parenchymatosa papillaris.* In the mottled form the boundaries of the individual cloudy areas are never sharp; on the contrary, transition is rather gradual. On the other hand, in direct fatty metamorphosis due to nutritive disturbance, *i.c.*, in the passive form, the lines of demarkation are quite sharp and distinct, so that the affected—fatty metamorphosed—parts appear as short, yellow striæ—striate form. (See Fig. 318.)



Fig. 318.—Striate fatty metamorphosis of the cardiac musculature, of the anterior papillary muscles in the left ventricle, and of the adjacent trabeculæ in pernicious anemia. *P*, papillary muscle; *t*, trabeculæ. Natural size. (After *Langerhans.*)



Fig. 319.—Fragmentatio myocardii in a strongly clouded heart of a toper. *a*, fragments within strongly clouded areas; *b*, less clouded and nonfragmented areas. (Leitz Obj., 2; Ocul., 0. After *Langerhans.*)

Recovery is possible only in affection of small areas, the fatty material disappearing by absorption. If large portions are altered, the individual dies from cardiac weakness, cardiac paralysis.

As regards etiology, of chief importance are certain chemic poisons

(*e.g.*, phosphorus, mineral acids) which alter the heart muscle (anatomic heart poisons), while others indirectly influence the heart by their action upon the nerves (physiologic heart poisons). In addition to these poisons, the acute infectious diseases (typhoid, scarlatina, diphtheria, puerperal fever, etc.) produce a general parenchymatous myocarditic alteration terminating in fatty metamorphosis. Probably here also the changes are partly referable to poisons, namely, toxic metabolic products of bacteria.

By **cardiac insufficiency** or **cardiac weakness** is understood defective power of the heart, *i.e.*, weak and incomplete contractions. If an extreme degree of cardiac weakness is produced by the action of noxious influences, a condition designated as **collapse** or **syncope** develops, which, in its sequelæ, may more or less approach, or be a precursor of, sudden arrest of the circulation. By paralysis of cardiac activity the arterial system is incompletely filled; the blood-pressure in the arteries sinks and finally is insufficient to force the blood through the capillary area, the circulation congesting in the latter; the skin becomes pale and cool, and, owing to its elasticity, clings to the subjacent parts, thus producing the "peaked" appearance of prominent parts of the body: the nose, etc. (*"facies hippocratica"*). This state reacts upon the heart; the coronary arteries are no longer supplied and, therefore, nutrition of the myocardium ceases; finally, cessation of respiration and asphyxia occur.

Compensatory disturbances of an hypertrophied heart are frequent causes of cardiac weakness. Here, at first, the cardiac hypertrophy, by overcoming the resistance, postpones the heart weakness; not until the hypertrophied heart no longer can meet the increased demands does insufficiency secondarily occur. This is the case when the same impediments as were described as the cause of hypertrophy exist, but in too high degree, or when the general state of the organism is at too low an ebb for cardiac hypertrophy to develop.

In other cases alterations of the heart itself embarrass its action, principally degenerations and their sequelæ: myocardial connective-tissue indurations which diminish the contractility, insufficient nutrition of the heart due to disease or occlusion of the coronary arteries. Thus, thrombosis of a chief coronary artery suddenly causes collapse of the heart and death. The activity of the heart may be interfered with also by displacements of, and compression by, adjacent organs.

In some cases alteration of cardiac activity is due to the action of poisons or to influence upon the ganglia and nerves regulating cardiac action. As in irritation of the accelerator nerves, direct or reflex paralysis of the inhibitory nerves (of the vagus) must be followed by increased cardiac action and *vice versâ*.

Those states of the heart designated as tachycardia and bradycardia are referable to toxic and nervous influences. In **tachycardia** (increased rapidity of the heart beat) there is first increase in the velocity of the blood-current with augmentation of pressure. If, however, the tachycardia assumes a serious character, slowing of the current finally occurs, because the intervals between the ventricular contractions are insufficient for diastolic filling of the ventricles. Tachycardia usually occurs in fever and in marked psychic disturbances. **Bradycardia** (slowing of the heart beat) has the same effect as tachycardia toward the end, in so far as it is of marked degree from the beginning. Besides the pulsations of the heart, the rhythm also may be altered. The power of cardiac action is usually decreased with alteration of the pulsations. Change in the rhythm occurs principally coincidently with an isolated bradycardia of the ventricle. In these cases either a nervous disturbance is present, *e.g.*, of cerebral nature, or the conduction path (the so-called conduction system: bundle of His) along which the contractions of the auricle are conveyed to the ventricle is interrupted. The ventricles then beat slower and not synchronously with the auricles: dissociation. This state is designated as **heart block.** Here belongs especially the so-called **Stokes-Adams symptom-complex,** in which the rhythm of the ventricles is independent of the auricle; "the ventricles may be beating 27 times per minute and the auricles 90" (Ott).

All these states of cardiac insufficiency have severe sequelæ. In most conditions of cardiac insufficiency and collapse, fall of the blood-pressure is the chief element, as is shown by the favorable effect which frequently can be produced in cases of collapse by subcutaneous infusion of salt solution, simply by increasing the pressure. In consequence of fall of blood-pressure the pulse-wave is in many cases lowered. The defective emptying of the heart, however, renders more difficult the flow of blood from the large venæ cavæ into the right auricle. If the right ventricle is incompletely emptied, congestion of the blood in the right auricle immediately occurs—*e.g.*, in lesions of the tricuspid valves. Rhythmic swelling of the veins, due to impediment to the inflow into the auricle, which is repeated with every ventricular systole, or even actual regurgitation pulse-wave, the so-called **venous pulse** may develop. Owing to the width of the pulmonary capillaries and the diminished pressure under which the blood flows into the pulmonary circulation, the congestion, in defective emptying of the left ventricle, extends also into the left auricle, through the pulmonary circulation into the right heart and vena cava.

If weakening of cardiac activity with incomplete emptying of the heart is persistent, overdistention of, and increased pressure in, the venous system develop which extend to the finest branches and capillary area and lead to cyanosis, dropsy, congestive hemorrhages, cyanotic induration of the organs, congestive catarrhs of the respiratory and digestive tracts, etc.

Another change of the heart muscle, which is extraordinarily frequently associated with the affections of the parenchyma, is *fragmen-*

tatio myocardii, myocardite ségmentaire. (See Fig. 319.) In this condition the muscle-bundles disintegrate into small fragments. The latter do not correspond to the cellular elements (between two Eberth's cement lines) of the muscle-bundles; on the contrary, they occur irregularly and are variously outlined fragments, of unequal length, originating by segmentation of individual muscle-bundles. The original view (Rénaut), that the points of rupture correspond to Eberth's cement lines, is incorrect, since these cement lines are found in the middle between two muscle-nuclei and run parallel with the transverse marking, while the points of rupture are often seen immediately beside the nuclei and frequently possess irregular, serrated margins. The fragments are sometimes smaller than the diameter of a muscle-bundle, *i.e.*, shorter than a muscle-cell segment. The lines of segmentation of neighboring muscle-bundles often lie in an almost equal plane; thus, the impression of undulating lines, similar to those seen with great distinctness on macroscopic inspection of primary fatty metamorphosis, is not infrequently produced. (See Fig. 318.)

Fragmentation never occurs as an independent process, and is always limited to those portions of the heart muscle which are cloudy or in a state of fatty metamorphosis. In mottled, cloudy swelling, the parts most markedly altered are usually the seat of fragmentation.

The softer, more flabby and friable the heart muscle, the more extensive, as a rule, is the fragmentation. Hence, a correct diagnosis can often be made without the aid of the microscope. On stroking the cut surface of the fragmented parts with a knife, countless minute fissures can be recognized, which are not observed in the absence of fragmentation.

As regards the significance of fragmentation, opinions are greatly at variance. Some authorities believe that fragmentation may be a cause of death; others consider the whole change to be an agonal phenomenon. At all events, fragmentation is found after sudden death, as well as after prolonged agony, and in arrest of the heart in diastole, as well as in firmly contracted hearts.

Calcification of the heart muscle is a rare change, which usually occurs in striate or mottled form, and attacks principally the papillary muscles. The infiltration with lime-salts occurs in the form of homogeneous calcification, in the same manner as the ganglion cells calcify; it is always a concomitant of other changes, and does not occur until the affected muscle-bundles are dead.

Rupture of the heart occurs through the action of external force (stab, shot, compression), or it is the result of alterations of the heart muscle from internal causes. The second form is closely connected with

fatty metamorphosis, the latter rendering the muscle at some point incapable of function and less resistant, and finally causing it to rupture during contraction as a result of the high pressure (through passive distention). Rupture is by far most frequently observed in the left ventricle; the causes of the alterations of the myocardium are embolism of the coronary arteries and alterations of



Fig. 320.—Calcification of the heart muscle in a case of chronic lead poisoning. *a*, slightly clouded musculature; *b*, calcified muscle-bundles. (Zeiss Apochr., 16; Comp. Ocul., 4. After *Langerhans*.)

Fig. 321.

Fig. 322.—Myocarditic induration. *P*, pigment. (Zeiss Apochr., 16; Comp. Ocul., 4. After *Langerhans*.)

the coronary arteries themselves, particularly arteriosclerosis with thickening of the wall and stenosis formation. Spontaneous rupture generally occurs only in advanced age, most often in old women. The altered portion of the muscle does not occupy a large area, but, as a rule, forms a peculiar, zizzag line. (See Fig. 321, *E*.) This is due to the fact that the muscle change progresses slowly and gradually.

Smaller traumatic, penetrating wounds may cicatrize, and are not necessarily fatal.

Change of the interstitial tissue of the heart: **interstitial myocarditis** (*myocarditis interstitialis*), occurs in two forms: first, as chronic fibrous, and, second, as acute purulent, myocarditis. Chronic fibrous interstitial myocarditis (*myocarditis interstitialis chronica fibrosa*) begins with cellular proliferation; very firm, dense, hard, fibrous scar-tissue is thus produced through formation of intercellular substance. The parenchyma gradually disappears by atrophy. Whitish-gray bands, which may extend from the endocardium to the pericardium, develop within the musculature. The more musculature thus transformed into connective tissue, the thinner becomes the

Fig. 323.—*A*, aneurism; *F*, myocarditis fibrosa; *M*, intact musculature.

Fig. 324.—Aneurism of the base of the left ventricle. ⅓ natural size. (After *Langerhans*.)

wall of the heart. The newly formed connective tissue is incapable of taking part in the contractions; it yields to the strong pressure within the heart and bulges outward. This results in partial dilation: *aneurysma* (*partiale*) *cordis*. (See Figs. 323, *A*, and 324.) This aneurism is most frequently observed in the left ventricle, which probably is due to the fact that greater demands are made upon it and, therefore, all changes become more manifest. Points of predilection are the anterior and posterior wall, and the thin portions at the apex of the heart. In contrast to these partial aneurismal dilations stands *dilatatio universalis*, which, as soon as it is associated with marked hypertrophy, produces the phenomenon of boucardia[1]: *cor bovinum*. In partial dilation there is only a comparatively slight deviation of the external form, not so marked as in aneurism of the arteries. The dilation visible

[1] *βους* = an ox; *καρδια* = the heart.

upon the inner surface may be diminished, as it were, compensated, by partial thrombosis. These thrombi are sometimes very extensive and, when dislodged, may occlude the abdominal aorta. The phenomenon of paraplegia is then produced.

Fibrous myocarditis (*myocarditis fibrosa*), fibrous interstitial myocarditis, occurs principally in syphilis; further, in arteriosclerosis of the coronary arteries, after trauma and in marked *abusus spirituorum*. Callous formations sometimes occur in the heart muscle without recognizable primary interstitial inflammation, apparently solely as the result of progressive atrophy of the musculature. This change is frequently observed in fibrous degeneration of the upper segments of the papillary muscles.

Myocarditis suppurativa sive apostematosa (*myocarditis interstitialis acuta*) results in abscess formation. It is comparable with metastatic abscesses in other organs, for there is no idiopathic purulent myocarditis! The metastases in the heart muscle are of embolic nature and sometimes caused by an aortic endocarditis, when infectious materials dislodged from the aortic valves enter the adjacent orifice of the coronary arteries and become arrested at some point. The process may originate directly by embolism by way of the blood in infectious diseases with formation of septic infarcts. If suppurative myocarditis extends to the pericardium, purulent pericarditis (*pericarditis purulenta*) develops. On the other hand, acute myocarditis may originate from pericarditis.

Hypertrophy of the heart, like cardiac atrophy, indicates altered nutritive conditions. In hypertrophy the individual muscle-bundles are thicker and capable of greater function.

The thickness of the muscular wall of the heart is the greater (and the heart-cavity the smaller), the more complete the last contraction of the heart, and the more incomplete the last contraction, the less is the thickness in relation to the cavity of the heart. The contracted state should be distinguished from true hypertrophy, and, likewise, the dilated state from diastole of the heart. (See p. 52.) The closed fist of the cadaver serves as a criterion in judging the size of the whole heart; the heart and fist should about correspond in size. If the heart is larger, dilation or hypertrophy exists. Causes of hypertrophy are alterations of the heart wall (*e.g.*, interstitial fibrous myocarditis); further, affections of the heart valves (insufficiency, stenosis) and increase of resistance in the arterial vascular area (arteriosclerosis, aneurisms, and hypoplasia of the arteries, contracted kidney?). In all cases hypertrophy is due to increased demands upon the heart and augmentation of its activity. In many instances, *e.g.*, in all valvular defects,

dilation is present in consequence of more intense filling of the ventricles during diastole. More intense filling may occur when the ventricle, owing to opposed impediment (*e.g.*, stenosis of the aorta), is unable to force out all the blood during systole, the blood remaining in the ventricle being augmented by filling of the auricle. In other instances dilation develops as a result of the fact that, while in systole all the blood is forced out, in diastole more blood than normal flows in. This is the case in incompetency of the valves when these cannot sustain the recoil of the blood, and the ventricle receives in diastole blood from two sides. If the impediment to the blood-current lies outside of the heart-cavity, hypertrophy may occur without dilation (*e.g.*, in arteriosclerosis, contracted kidney?). Dilation may, however, result here also, *e.g.*, dilation of the right ventricle in chronic affections of the lungs (emphysema, ulcerative and indurative phthisis) and of the bronchi (bronchiectatic phthisis, chronic bronchitis, and coexistent adhesions of the pleuræ), in valvular lesions of the left side, in coexistent obliteration of the pleural and pericardial cavities. As long as the heart, through increased nutrition and hypertrophy, can meet the increased demands and the hypertrophy keeps pace with the stronger filling and the consequent dilation of the cavities of the heart, the impediment or alteration which causes the increased heart action is compensated. As soon, however, as the energy of the heart for any reason—through further increase of demands, through relaxation or exhaustion in consequence of nutritive disturbance—can no longer keep pace with the increased work required, degenerative processes of the myocardium occur, which finally end in death. In many cases (especially in stenosis and incompetence of the aortic orifice) a marked passive dilation of the heart (of the left ventricle) begins with diminution of the strength of the heart. In ordinary dilation, which about corresponds to hypertrophy, the papillary muscles and trabeculæ are thick, fleshy, round; the increase in length corresponds to the increase in diameter; the trabeculæ increase in number, new muscle-bundles arising from the wall. In more intense passive dilation, on the other hand, the papillary muscles and trabeculæ lose their roundness and become longer and thinner; the papillary muscles appear drawn out to a point toward the attachment to the chordæ tendineæ; the trabeculæ are flattened, sometimes thin as paper, and the whole wall of the ventricle, in comparison with the very great dilation, is markedly thin.

The cause of the cardiac hypertrophy observed in the course of chronic affections of the kidneys (renal cardiac hypertrophy) is still obscure. It is probable that several factors are operative. In such cases there is marked increase in the arterial blood-pressure which, if persistent for several weeks,

upon the inner surface may be diminished, as it were, compensated, by partial thrombosis. These thrombi are sometimes very extensive and, when dislodged, may occlude the abdominal aorta. The phenomenon of paraplegia is then produced.

Fibrous myocarditis (*myocarditis fibrosa*), fibrous interstitial myocarditis, occurs principally in syphilis; further, in arteriosclerosis of the coronary arteries, after trauma and in marked *abusus spirituorum*. Callous formations sometimes occur in the heart muscle without recognizable primary interstitial inflammation, apparently solely as the result of progressive atrophy of the musculature. This change is frequently observed in fibrous degeneration of the upper segments of the papillary muscles.

Myocarditis suppurativa sive apostematosa (*myocarditis interstitialis acuta*) results in abscess formation. It is comparable with metastatic abscesses in other organs, for there is no idiopathic purulent myocarditis! The metastases in the heart muscle are of embolic nature and sometimes caused by an aortic endocarditis, when infectious materials dislodged from the aortic valves enter the adjacent orifice of the coronary arteries and become arrested at some point. The process may originate directly by embolism by way of the blood in infectious diseases with formation of septic infarcts. If suppurative myocarditis extends to the pericardium, purulent pericarditis (*pericarditis purulenta*) develops. On the other hand, acute myocarditis may originate from pericarditis.

Hypertrophy of the heart, like cardiac atrophy, indicates altered nutritive conditions. In hypertrophy the individual muscle-bundles are thicker and capable of greater function.

The thickness of the muscular wall of the heart is the greater (and the heart-cavity the smaller), the more complete the last contraction of the heart, and the more incomplete the last contraction, the less is the thickness in relation to the cavity of the heart. The contracted state should be distinguished from true hypertrophy, and, likewise, the dilated state from diastole of the heart. (See p. 52.) The closed fist of the cadaver serves as a criterion in judging the size of the whole heart; the heart and fist should about correspond in size. If the heart is larger, dilation or hypertrophy exists. Causes of hypertrophy are alterations of the heart wall (*e.g.*, interstitial fibrous myocarditis); further, affections of the heart valves (insufficiency, stenosis) and increase of resistance in the arterial vascular area (arteriosclerosis, aneurisms, and hypoplasia of the arteries, contracted kidney?). In all cases hypertrophy is due to increased demands upon the heart and augmentation of its activity. In many instances, *e.g.*, in all valvular defects,

dilation is present in consequence of more intense filling of the ventricles during diastole. More intense filling may occur when the ventricle, owing to opposed impediment (*e.g.*, stenosis of the aorta), is unable to force out all the blood during systole, the blood remaining in the ventricle being augmented by filling of the auricle. In other instances dilation develops as a result of the fact that, while in systole all the blood is forced out, in diastole more blood than normal flows in. This is the case in incompetency of the valves when these cannot sustain the recoil of the blood, and the ventricle receives in diastole blood from two sides. If the impediment to the blood-current lies outside of the heart-cavity, hypertrophy may occur without dilation (*e.g.*, in arteriosclerosis, contracted kidney?). Dilation may, however, result here also, *e.g.*, dilation of the right ventricle in chronic affections of the lungs (emphysema, ulcerative and indurative phthisis) and of the bronchi (bronchiectatic phthisis, chronic bronchitis, and coexistent adhesions of the pleuræ), in valvular lesions of the left side, in coexistent obliteration of the pleural and pericardial cavities. As long as the heart, through increased nutrition and hypertrophy, can meet the increased demands and the hypertrophy keeps pace with the stronger filling and the consequent dilation of the cavities of the heart, the impediment or alteration which causes the increased heart action is compensated. As soon, however, as the energy of the heart for any reason—through further increase of demands, through relaxation or exhaustion in consequence of nutritive disturbance—can no longer keep pace with the increased work required, degenerative processes of the myocardium occur, which finally end in death. In many cases (especially in stenosis and incompetence of the aortic orifice) a marked passive dilation of the heart (of the left ventricle) begins with diminution of the strength of the heart. In ordinary dilation, which about corresponds to hypertrophy, the papillary muscles and trabeculæ are thick, fleshy, round; the increase in length corresponds to the increase in diameter; the trabeculæ increase in number, new muscle-bundles arising from the wall. In more intense passive dilation, on the other hand, the papillary muscles and trabeculæ lose their roundness and become longer and thinner; the papillary muscles appear drawn out to a point toward the attachment to the chordæ tendineæ; the trabeculæ are flattened, sometimes thin as paper, and the whole wall of the ventricle, in comparison with the very great dilation, is markedly thin.

The cause of the cardiac hypertrophy observed in the course of chronic affections of the kidneys (renal cardiac hypertrophy) is still obscure. It is probable that several factors are operative. In such cases there is marked increase in the arterial blood-pressure which, if persistent for several weeks,

results in hypertrophy of the heart, involving especially the left ventricle, and very soon also the right ventricle and both auricles. The blood-pressure is increased also in the pulmonary arteries. How this increased pressure is produced is questionable. While retention of water (serous plethora, owing to insufficient excretion of urine), which in many cases of nephritis must augment the blood-pressure, is to be assumed, this certainly is not present in all cases, because retention of urine often does not occur until the last stages of nephritis, and, besides, this would explain only the hypertrophy of the left ventricle. Therefore, persistent increased resistance in the small branches of the whole arterial system (vascular

Fig. 325.—Carcinomatous embolus in left coronary artery. See Fig. 326. ⅔ natural size. (After *Coffin.*)

spasm, inflammatory alterations of the vessel walls with narrowing of the lumen) has been brought forward to elucidate this. There is no positive evidence, however, in favor of persistent vascular spasm; alterations of the vessel walls, such as thickening of the intima, perhaps also of the muscularis, are demonstrable (Gull-Sutton's arteriocapillary fibrosis), but in how far these are not secondary to hypertrophy of the left heart—*i.e.*, a reaction to strong filling and pulsatile distention of the vessel wall resulting from pressure—is still unexplained. Impediment to the current developing as a result of destruction of numerous glomeruli in the kidneys is incapable alone of producing such marked increase of arterial pressure. Finally, chemic action due to retained urinary constituents also has been assumed to exist (Senator), though in many cases of very pronounced chronic nephritis retention of urine does not occur.

By **idiopathic cardiac hypertrophy**[1] is understood that form of hypertrophy in which no organic change of the heart or other organs can be found as a cause of the hypertrophy. This form of hypertrophy, usually in the left ventricle, is observed in habitual, excessive beer drinkers (Bollinger), in plethora, in athletes, and in subjects who perform very strenuous bodily labor (Leyden).

In **venous congestion** the heart muscle has a dark-red, cyanotic color; the intensely distended coronary veins are plainly visible upon

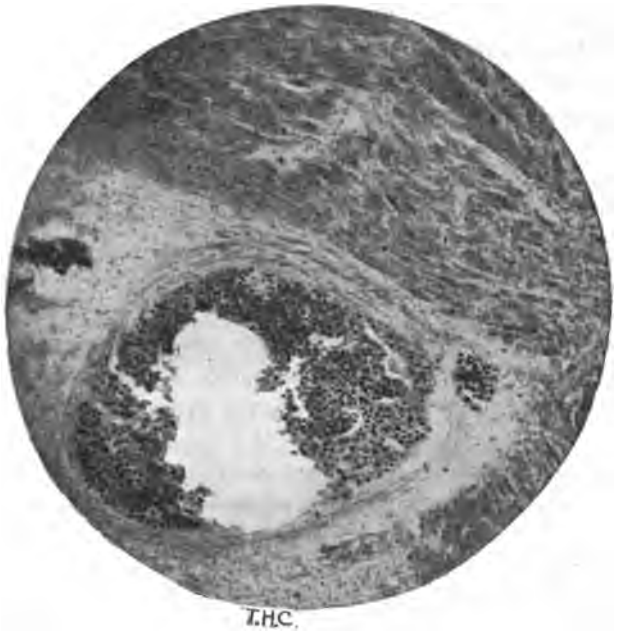

Fig. 326.—Embolus of epithelial cells in the coronary artery. From this embolus the myocardium became involved in secondary epithelioma.

the unopened heart viewed *in situ,* and there usually is a more or less high degree of hydropericardium.

In **general anemia** the myocardium is pale red, and in chronic cases not rarely atrophic. Ischemic states, which not infrequently occur as the result of sclerotic narrowing of the coronary arteries or of embolism or thrombosis, are followed by atrophic and necrotic foci in the myocardium, which later become the site of connective-tissue cicatrices.

Myocardial infarcts may follow vascular occlusion. The infarcts may later undergo softening (myomalacia), and subsequently be re-

[1] For hypertrophy in Basedow's disease, see p. 742.

placed by cicatrices. **Hemorrhages** and hemorrhagic infarcts may occur in the myocardium; also in inflammation of the heart (*e.g.*, endocarditis) and in general septic conditions (*e.g.*, puerperal sepsis).

Primary **tumors** of the heart are very rare and partly congenital. Sarcoma, lipoma, fibroma, myxoma, rhabdomyoma have been observed. The secondary tumors are chiefly sarcoma (also melano- and lymphosarcoma), rarer carcinomata, which reach the myocardium either by extension from adjacent parts or by metastasis. (See Figs. 332 and 333.)

Endocardium.

The endocardium corresponds to what in the vessels is called the intima. Intima never signifies endothelium, but, like the endocardium, the strong connective-tissue membrane, rich in elastic fibers, upon which the endothelium rests. Neither in the heart nor in the vessels is the endothelium itself the seat of independent pathologic processes. The endocardium, like cartilage, is almost entirely vascularless; it is freely provided with vessels only in the fetal state. Under certain circumstances, however, the endocardium is vascularized from the underlying tissue, most frequently at the base of the mitralis. Owing to this poor vascular supply, hyperemia and exudative processes are never observed in the endocardium. When fibrinous masses occur upon the inner surface of the endocardium, these are always precipitates from the blood: thrombi.

The changes of the endocardium occur in the substance itself, *i.e.*, they are essentially parenchymatous processes. These occur principally in localities where the vessels approach from the underlying layer, *i.e.*, not in the surface, but in the deeper layers of the endocardium.

Accordingly, thrombi and inflammations of the endocardium must be differentiated. Both frequently coexist, but are not necessarily interdependent, just as venous thrombosis may exist with and without endophlebitis.

In contrast to the inflammatory changes of the endocardium stand the pure atrophic alterations, the chief seat of which are the semilunar valves. In these it is not rare to see above the line of closure very thin places of completely transparent consistency, from which small holes develop as a result of progressive atrophy, as in fenestrated atrophy of the omentum. These fenestrated valves are a quite insignificant state for the possessor, as far as the part of the valve above the line of closure is unessential for the capability of closure of the valve, so long as this is not altered by other processes (with retraction). In strict contrast to atrophy, a cellular proliferation of the endocardium is the chief change in chronic (latent) endocarditis.

Endocarditis, like endoarteritis, in its ordinary course manifests a marked disposition to fibrous, sclerotic processes. Sclerosis takes its name from the hardness of the altered parts. This change frequently occurs focally in the form of spots and nodules, especially on the valves, as *endocarditis chronica fibrosa basilaris,* or *marginalis,* or *nodularis.* In the auricles, especially in the left, uniform thickenings occur. A single segment of a valve is almost never uniformly affected.

In the ventricles the parietal endocardium may be altered by a chronic inflammatory process: *endocarditis chronica parietalis.* This is, as a rule, the case when a severe alteration of the myocardium, especially chronic interstitial myocarditis, extends to the endocardium and finally involves the latter. Thickenings are observed also in incompetence of

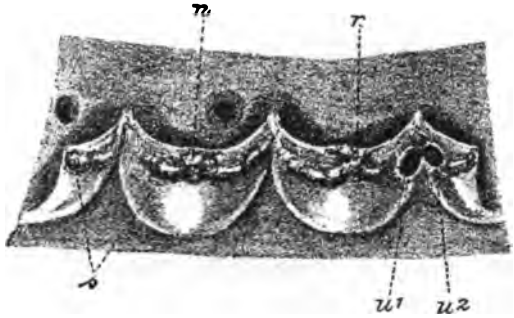

Fig. 327.—Chronic fibrous aortic endocarditis of the noduli arantii, *n*, and of the line of closure, *s*. Very slight retraction. The free margin is unaltered. At u_1 and u_2 two perforations. Natural size. (After *Langerhans.*)

the aortic orifice at those localities in the left ventricle which are especially exposed to the backward impact of the blood (attachment of the aortic segment of the mitral and septum carneum alongside of the posterior papillary muscle). Finally, there is also an independent parietal endocarditis which may occur at all points, to be seen at the left ventricle more frequently than at the right.

Every chronic endocarditis begins with increase of volume: with cellular proliferation. The new cells lead to the formation of new intercellular substance. This gradually increases in bulk, and the proliferated cells develop into long, slender spindle-cells. In proportion as the intercellular substance increases, the cells usually become less distinct, until finally fibrillated intercellular substance preponderates. This fibrillated tissue condenses more and more, acquiring an almost homogeneous consistency, which is very similar to the basement substance of hyaline cartilage, but does not contain chondrin. This thickening is associated

with retraction, which is most important for the further history of heart diseases, because as a result of this the valves are so altered that they are no longer able to perform their function—the ostia become too narrow, and the valves (the semilunar and auriculoventricular) do not close. The retraction, however, is not in all cases so great that further consequences must necessarily result. When the process—the chronic fibrous endocarditis—is arrested, the sclerotic state of the new-formed masses of connective tissue remains stationary, or calcification by deposition of lime-salts in the indurated parts follows.

Retraction in the neighborhood of the valves may have a double direction: 1, a longitudinal, *i.e.*, parallel with, but in opposite direction to, the blood-stream, in the direction from the free border toward the base of the valves, or, 2, a transverse, a direction at right angle

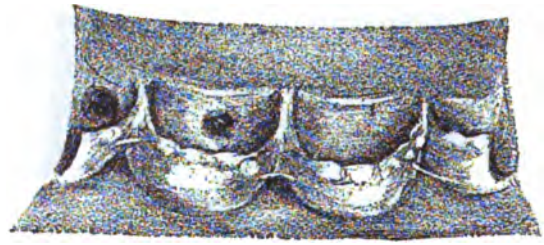

Fig. 328.—Incontinence of the aortic orifice from chronic fibrous retracting aortic endocarditis, with coalescence of the free margins and of the line of closure of the valves to form a dense, somewhat nodulated mass, with marked shortening from retraction and adhesion; coalescence of the lateral parts of the valves. Natural size. (After *Langerhans.*)

to the blood-stream, at the level of closure parallel with the free margin of the valves.

The result of retraction in a longitudinal direction is shortening with lowering of the valves: the semilunar as well as the auriculoventricular valves. As the base of the valves is always permanent, the position of the free margin must be so altered by the shortening that it is brought nearer to the base. When the inflammatory process extends from the auriculoventricular valves to the chordæ tendineæ, these also are shortened by retraction, in that they, in the same manner as the valves, are brought closer to the base of the valves; the papillary muscle is thus brought nearer to the auriculoventricular orifice. The shortening of the chordæ tendineæ is often so marked that the apex of the papillary muscle lies close to the thickened valves and scarcely any part or none of the chordæ tendineæ can be recognized.

Marked shortening of the valves in a longitudinal direction leads

from a certain stage onward to incompetence (insufficiency), *i.e.*, to the state in which the valves can no longer sustain the backward impulse of the blood (at the pulmonary and aortic orifices during diastole, at both auriculoventricular valves during systole), so that now, during diastole, blood can flow back from the aorta or pulmonalis into the left or right ventricle, respectively (regurgitation). In general, *incontinentia ostii aortici* and *pulmonalis* (in special, *i.e.*, in individual, cases certain factors may modify this general rule) occurs only when the valve is so shortened by retraction that the length of the valve is shorter than the distance from the base to the margin of closure.

In retraction of the valves in transverse direction the valves are not shortened, but the orifice is narrowed, in that

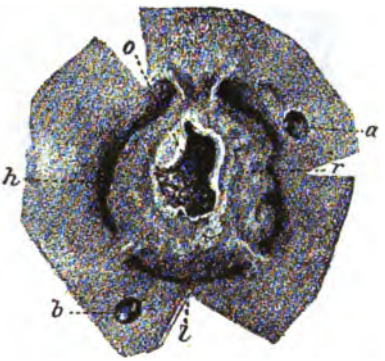

Fig. 329.—Marked stenosis of the aortic orifice. Natural size. View from the aorta. The aortic valves, calcified and adherent to each other laterally, form a rigid cone projecting into the aorta, at the point of which is located the greatly narrowed ostium. *a*, right coronary artery; *b*, left coronary artery; *o*, ostium; *r*, right valve; *l*, left valve; *h*, posterior valve. (After *Langerhans*.)

those points at the margins which are affixed must approach each other. Insufficiency also is thus produced, and, in the higher degrees of retraction, stenosis. Every stenosis offers a certain resistance to emptying of a heart-cavity: stenosis of the auriculoventricular valves to emptying of the auricles; stenosis of the aortic or pulmonary orifice to emptying of the ventricles. Consequently, congestion with dilation of the affected heart-cavity develops on the proximal side of every stenosis.

Chronic endocarditis is frequently associated with partial adhesions —synechiæ—of adjacent valvular parts (*endocarditis adhæsiva*), which, however, are not, as in adhesion of serous membranes, due to secretion and interdeposition of an exudate, because the endocardium

can produce no exudate. The adhesion occurs rather as a result of the fact that the surfaces, in consequence of the proliferative process, acquire a condition like a wound (raw) surface, a kind of granulation tissue forming, similar to what occurs in burns; these wound surfaces on the valves come in contact where they are able to touch (*e.g.*, in the semilunar and auriculoventricular valves in the region of the surface of closure, *i.e.*, between the free border and the margin of closure; in the chordæ tendineæ throughout more or less their whole extent, chiefly, however, at the apex of the papillary muscle and in the region of the valves), and finally grow together. Coalescence of neighboring valvular parts occurs partly also in the same manner as it occurs in the eyelids,



Fig. 330.—Stenosis of aortic orifice from complete adhesion of the right and left valves to form one valve with subsequent calcification (endocarditis aortica chronica adhæsiva et fibrosa retrahens calculosa). Death from ether. Natural size. (After *Langerhans.*)

the mouth, at the orifices of the uterus, namely, by gradual approximation in consequence of retraction and shrinkage.

Extensive valvular adhesions lead to incontinence and stenosis also in the absence of retraction. More frequently, however, retraction and synechiæ coexist, in consequence of which equalization—compensation—of the disturbance does not occur, but rather intensification and augmentation. Sometimes secondary, compensatory phenomena develop, the shortening of other valvular parts being gradually equalized by compensatory lengthening—elongation—of one of the normal valvular segments before an open cleft (incontinence) occurs. This elongation can occur only in parts which have been unaffected by the inflammation, never in thickened, sclerotic valves.

Sometimes two semilunar valves gradually coalesce by adhesion to form a single and, as a rule, a particularly large valve. In this case the two sinuses belonging thereto coalesce to form one sinus.

By coalescence of all three valves, a very marked degree of stenosis with a somewhat rounded opening develops. (See Fig. 329.)

Coalescence of valvular parts occurs also congenitally as *vitium primæ formationis;* the acquired endocarditic form is distinguished from this by the fact that a small ridge is still recognizable as the boundary of the originally separated sinuses of Valsalva.

Adhesion, similar to adhesion and occlusion of the palpebral fissure, always leads to narrowing. Congenital atresias and stenoses are defects in embryonal development (see p. 191), and not the product of fetal endocarditis.

The chief cause of valvular lesions is acute articular rheumatism. In 670 cases observed in the Leipzig Clinic, valvular lesions occurred in almost 60 per cent. The younger the individual, the greater the danger of endocarditic complication.

In respect to the influence of valvular lesions upon health and duration of life, the prognosis in general is, according to O. Burwinkel,[1] viewed too gloomily. Most statistics are based upon hospital observations which cannot be accepted as decisive, because patients generally do not enter the hospital until subjective symptoms are manifested by disturbed compensation. The view that valvular lesions must invariably soon cause death is erroneous, nor are sudden deaths especially frequent: they occur only exceptionally in aortic lesions. Many persons experience no disturbance for a number of years, in spite of valvular lesions, and death may finally occur from an intercurrent affection; indeed, they often are unconscious of the existence of a heart lesion. Of 150 cases of valvular lesions observed by Middleton,[2] in 24 the lesions were accidentally discovered, as they produced not the slightest inconvenience. Two-thirds of the patients with valvular lesions observed by Allyn[3] were over 50 years, 28 over 60 years, 16 over 70 years, 7 over 80 years, and 2 over 90 years of age.

Not every organic alteration of the valves is synonymous with valvular lesion; in addition to the anatomic lesion there must be functional disturbance. The functional capacity is the criterion whether the lesion is to be regarded quantitatively as indifferent or severe. Whether the circulation is actually so disturbed as unfavorably to influence health cannot be judged from the intensity of the murmur revealing the anatomic alteration. Every valvular lesion is, of course, an increased tax upon the cardiac musculature; increased cardiac action is essential for compensation, but the normal heart is ever ready to accomplish many times what is demanded in a state of rest, and without detriment it continually sustains increased demands in persons engaged in many forms of occupation.

The animal experiments of Tangl and Balint,[4] in which valvular lesions were artificially produced, showed that, while physiologic hypertrophy occurred as the result of the increased work of the heart, there were no manifestations of incompensation. At necropsy the myocardium showed neither degeneration nor increase of connective tissue. There are many individuals whose condition, in spite of a clinicly well-defined valvular lesion, does not differ from that of a healthy subject—

[1] Fortschritte der Medizin, No. 34, p. 799.
[2] Lancet, 1889, p. 846.
[3] Amer. Jour. of the Med. Sci., Nov., 1910.
[4] Deutsch. med. Woch., 1908, No. 1.

in whom medical observation for years and decades reveals neither diminished capability nor alteration of the objective state. Such ideal compensation should not be regarded as "heart disease," but at most as a cardiac defect. Unfortunately, however, the alterations of the valves are frequently so marked that the cardiac power is insufficient to regulate the impediment to the circulation. Hence, in prognosis the degree of the anatomic lesion, which may be so slight as scarcely to alter the blood-stream, but so extensive as to cause great disturbances, is of chief importance. In anatomic processes of equal intensity the reactions upon the circulation and organism are often very different. Very much depends upon body constitution, hereditary states, temperament, age, mode of life, etc. Above all, it is necessary sharply to differentiate upon what basis a valvular lesion developed. Valvular lesions of rheumatic origin acquired in youth are to be viewed far more favorably than the sclerotizing processes which extend secondarily from the aorta to the endocardium and valves. This sclerotic endocarditis tends constantly to progress and to involve the myocardium. As regards health and duration of life, mitral insufficiency is the most benign, and then aortic insufficiency; here the heart usually is able for a long time to meet all increased demands. Complete compensation is much rarer in aortic stenosis, because it usually develops in advanced age upon the basis of arteriosclerosis. Complete compensation of mitral stenosis is the exception. Here it may be remarked that there is a pure mitral stenosis without insufficiency (*rétrécissement mitral absolument pur*, Durozicz), which in character, manifestations, and clinic course is an independent valvular lesion that not rarely is overlooked. It is observed principally in debilitated, anemic women during the second and third decades. The majority die before the 40th year; the menses often are delayed and irregular; abortions or sterility are frequent manifestations. Pulmonary stenosis, which usually is congenital, generally results in death at puberty; an age of 30 years is scarcely ever attained.

Why does the hypertrophied myocardium due to valvular lesions tend to exhaustion? Why does it not permanently retain the power of accommodation? According to Burwinkel,[1] the process established first in the valves gradually extends to the myocardium, which regularly is found to be affected in the form of an endoarteritis of the small myocardial arteries, and an increase of connective tissue with extensive disappearance of muscle substance. If, as a result of this chronic inflammatory process, the myocardium has suffered in structure and nutrition, feeble, incomplete contractions, dilation of the cardiac wall, and further symptoms of disturbed compensation occur. Thus, in the prognosis of a valvular lesion the nature and severity are the chief elements to be considered; next the reserve forces of the myocardium and the adaptability of the organism, especially the state of the peripheral vessels. According to Burwinkel,[2] a most important criterion in determining in individual cases the functional capacity of the heart muscle is the amount of work which can be done without the occurrence of dyspnea. In reality, every heart is relatively insufficient; for even the strongest and most thoroughly trained individual finds a limit to his bodily exertion; if he overexerts himself, shortness of breath, increased pulse rate, palpitation, and other indications of relative insufficiency become manifest. In this respect there are great differences in different individuals, and it is not always easy to decide whether in a given case the heart is able fully to cope with the disturbed state of the circulation.

---

[1] "Die Behandlung der Herzklappenfehler," Fortschritte der Medizin, 1911, No. 34, p. 801.

[2] *Loc. cit.*

When coagula are deposited upon the endocardium during life, **thrombi** develop. According to their external configuration, three forms are distinguished in the heart (see Fig. 331):—

1. Verrucous.
2. Globular.
3. Polypous.

The first, the verrucous form (see Fig. 332), is found principally upon the valves (*thr. valvularis*); the spheric, or globular, form upon the walls of the ventricles between the trabeculæ (*thr. parietalis*); the polypous form especially in the auricles (*thr. auricularis*), next upon the valves. These thrombi, therefore, are always

Fig. 331.

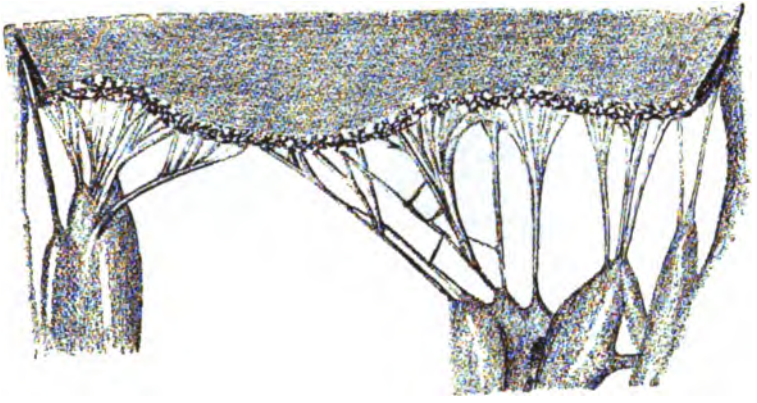

Fig. 332.—Endocarditis mitralis verrucosa. The margin of the mitral is covered with small warts. Natural size. (After *Langerhans.*)

formations derived from the blood, which grow by successive deposition of new lamina.

In the interior of the thrombi metamorphoses frequently occur: first, inspissation, from which hardening, hornification, and calcification may result, and, second, softening, puriform softening. In the latter case the thrombus may easily disintegrate and cause embolism. The spheric, parietal cardiac thrombi manifest the least tendency to fragmentation. Thrombosis of the left heart causes embolism of the peripheral vessels, and thrombosis of the right heart, embolism of the lungs.

There are two causes for the development of thrombosis of the heart (see p. 76): first, foreign substances which come in contact with the blood, and, second, the formation of mechanic inequalities in the wall (dilation, aneurysma, recessus between the trabeculæ), which bring with them the possibility of congestion, a greater sluggishness of the blood; the inequalities which develop in endocarditic affections are the most frequent cause and seat of thrombosis, and the tendency to thrombosis is the greater, the more dead substances are formed by the endocarditic process.

Thrombi form in the recessus between the trabeculæ and in dilation only when the organic integrity of the myocardium is altered, and hence its function so relaxed or encumbered by sclerosis that it no longer can contract sufficiently.

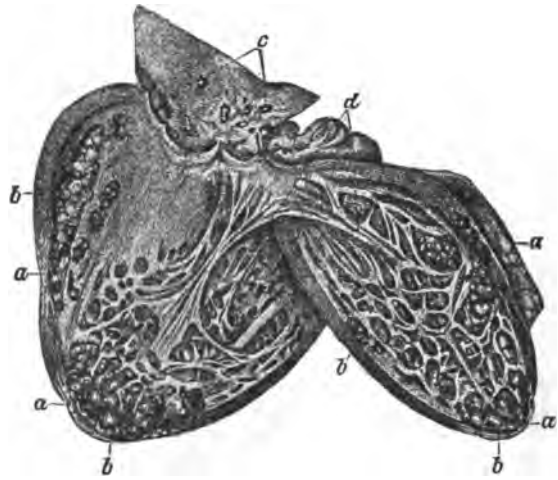

Fig. 333.—Dilation of the left ventricle due to chronic fibrous multiplex interstitial myocarditis, with numerous parietal thrombi in the ventricle and in the ascending aorta (case of syphilis). *a*, myocarditis with indurations; *b*, parietal thrombi of the heart; *c*, parietal thrombi of the ascending aorta; *d*, pointed and fibrous degenerated papillary muscle. The thrombi have a globular form. ½ natural size. (After *Langerhans.*)

Aneurisms of the valves, *e.g.*, of the aortic valves (see Fig. 334), upon the convex (*i.e.*, facing the ventricle) surface of which fibrin masses are usually deposited, are also a frequent cause of thrombosis. Rupture of such an aneurism almost always results in embolism.

Malignant endocarditis, like acute endoarteritis and endophlebitis, always begins with cellular proliferation. The latter, analogous to cloudy swelling, is soon followed by granular clouding of the whole affected

area with especial involvement of the cells. In such localities masses of fibrin are always deposited. Within the thrombi and the affected parts of the endocardium micro-organisms are regularly found, chiefly streptococci and staphylococci, upon the presence of which the malignancy



Fig. 334.—*A*, aneurysma valvulæ aorticæ; *Thr*, thrombus; *n*, nodolus arantii; *v*, valvula aortica. Schematic.

depends. The micro-organisms are in all probability derived from the circulating blood, and are deposited upon and finally within the endocardium from the blood. The result is early necrosis and disintegration

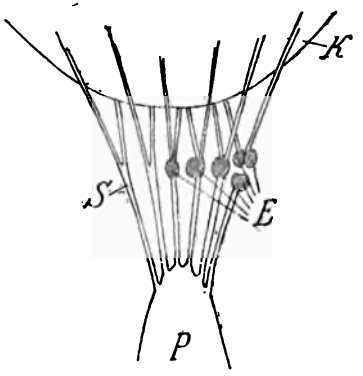

Fig. 335.—Endocarditis chordalis ulcerosa. *S*, chordæ tendineæ; *K*, valve; *P*, papillary muscle; *E*, endocarditis chordalis ulcerosa. Schematic. (After *Langerhans.*)

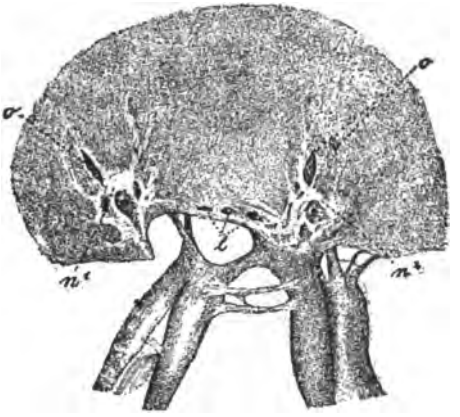

Fig. 336.— Endocarditis mitralis traumatica from a man aged 25 years who had been crushed at the age of 10 years. n^1 and n^2, cicatrices with peripheral radii. Lateral adhesion of both valves. At *o* fissure-like opening, non-adherent parts of the lateral margins. (After *Langerhans.*)

with detachment of small particles from the wall and the thrombotic masses; these are washed away by the blood-current and produce metastatic embolic foci in distant parts of the body. An ulcer surface develops in the endocardium: *endocarditis ulcerosa.* Pus, however, is

never formed; the ulcer secretes only necrotic, disintegrated masses: detritus. Such an ulceration may involve a single valve at the pulmonary or aortic orifice, and destroy it all but a small basilar remnant, or two or all three valves may be altered, but usually to an unequal degree.

Ulcerative endocarditis may be primary (so-called cryptogenetic), but usually it is secondary to acute infectious lesions. In either case it generally is accompanied by the development of multiple (metastatic) abscesses.

An especial form is *endocarditis maligna chordalis.* The chordæ extend from the papillary muscle to the valve, but before they reach the valve they divide into two parts, of which only one is inserted into the free margin of the valve, the other extending farther beyond this point. The point of bifurcation of the chordæ tendineæ manifests an especial disposition to the malignant form of endocarditis, button-like swellings (see Fig. 335) which disintegrate by necrosis and produce rupture of the tendinous cords quite often developing here. The torn parts of the cord then hang loose. If all the cords are destroyed, incompetence of the valve occurs, because this is driven back and forth by the blood-stream.

Fig. 337.—Endocarditis mitralis traumatica. The same as in Fig. 336. The surface directed toward the ventricle. At *l* apertures between partial adhesions of the chordæ tendineæ. (After *Langerhans.*)

The heart valves may be altered also by trauma (crushing of the chest, violent blow, etc.) without production of a wound; this is so-called traumatic endocarditis. This occurs chiefly at the aortic orifice, comparatively rare at the mitral. (See Figs. 336 and 337.)

Aneurisms of the aortic and mitral orifices have their entrance on the side opposite to the blood-current; they, therefore, bulge out on the side facing the blood-stream: at the aortic orifice toward the ventricle (see Fig. 334) and at the mitral toward the auricle. Here it is a question of true aneurisms—always a process associated with new formation (hyperplasia and dilation)—not one of simple dilation. When

such an aneurism is provided with an opening, there is insufficiency of the valve. This form of insufficiency differs from the ordinary form, which is caused principally by marginal sclerosis or ulceration. The ordinary valvular aneurism occupies, as a rule, the center of a valve at the aortic or mitral orifice.

Aneurism of one or several sinus Valsalvæ not infrequently occurs at the aortic orifice, particularly in arteriosclerosis and in old age. In this condition the sinus gradually enlarges in all its dimensions, and bulges outward. In very rare cases perforation into the pericardium may occur.

Aneurism of the septum membranaceum ventriculorum, close beneath the aortic orifice between the base of the right and left aortic valves, belongs to the rarer changes. In consequence of the intense pressure in the left ventricle, this aneurism bulges toward or rather into

Fig. 338.—Aneurysma valvulæ aorticæ dextræ ruptum. Endocarditis aortica verrucosa. Synechia valvulæ aorticæ dextræ et posterioris. ⅔ natural size. (After *Langerhans*.)

the right ventricle. An aperture develops through perforation only in extremely rare instances.

True **cyanosis** (*morbus cæruleus,* blue disease) is due to fetal disturbance in the region of the right ventricle with stenosis during the first third of intra-uterine life. The stenosis may occur at three points: in the region of the pulmonary artery, at the pulmonary orifice, and in front of the conus of the pulmonary artery. (See Malformations of the Heart, p. 191 *et seq.*)

Endocardial Tumors.—The majority of so-called endocardial tumors, according to Stahr,[1] belong to thrombus organizations, and a few to the genuine blastomata (myxomata, hemangiomata). The blastomatoid products of thrombus organization differ from myxomata by their poverty of cells and their richness in blood, blood-pigment, and blood-vessels; from the hemangiomata by the lesser thickness of the blood-vessels, the smaller size of the endothelia and, in general, by the absence

[1] Virchow's Archiv, Bd. 199, p. 162, 1910.

of independent cell proliferation. Differentiation between thrombus organization products and obliterating hemangiomata is most difficult and sometimes scarcely practical. No essential significance in differential diagnosis can be attributed to the mucus reaction and to richness of elastic tissue fibers. It is quite possible that, similarly to callous tumors, blastomata develop in and upon the basis of organized endocardial thrombi, and in a part of the endocardial tumors heretofore described this interpretation appears permissible. Endocardial ruptures are said to be responsible for the origin of the large, broad-based endocardial thrombi from which the blastomatoid organization products develop.

ARTERIES AND VEINS.

Arteries and **veins** are distinguished essentially by the fact that the former possess a very strong, muscular median coat, while in the

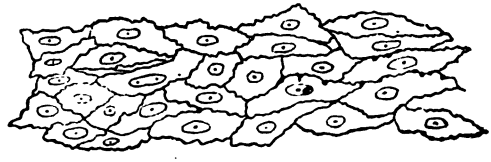

Fig. 339.—Epithelial layer lining the posterior tibial artery. 250 diameters. (After *Schaefer.*)

latter only a few muscle elements are present. Consequently, the arteries are constricted in the cadaver (by so-called cadaveric rigor mortis of the muscularis), narrow, and thick-walled, while the corresponding veins are dilated and thin-walled. The muscularis is most strongly developed in the medium-sized and smaller arteries, diminishing in amount as the arteries become larger, elastic lamina taking its place, especially in the aorta. In the arteries and veins the intima and the adventitia are connective-tissue tunics; in the larger arteries they are very rich in elastic fibers. The endothelium is a thin, single layer of flattened epithelium. The intima, like articular cartilage, is almost entirely devoid of vessels; consequently, it can neither become hyperemic (every uniform redness is a cadaveric process: imbibition with dissolved blood-coloring matter) nor produce free exudates. Every coagulum which forms upon the internal surface is always a precipitate from the blood: thrombus.

In the category of malformations (see p. 193) belongs abnormal smallness of the aorta (*aorta angusta*) and of the whole arterial arborification. All parts, including the aorta, may be markedly narrow, thin-walled, and more elastic than normal vascular structures. This deficient development (hypoplasia) is, as a rule, associated with certain irregu-

larities in the distribution of the vessels (irregular origin, excess or deficiency of the intercostal arteries, etc.) and fatty metamorphosis of the large, flat intima cells in the uppermost layer of the internal membrane of the aorta and of the next largest trunks. In the male between the 20th and 30th year, the incised ascending aorta has an average diameter of 76 mm., in the female 72 mm.; the aortic orifice in the male is 80 mm., in the female 77 mm.; the pulmonary orifice is 92 and 89 mm., respectively.

Acute inflammations of the vessel walls may result in the formation of exudates; the exuded masses, however, are never situated in the lumen of the vessel, but always in the substance of the vessel itself. The intima is impermeable for this exudate; consequently, the exudate may accumulate at the junction of the muscularis and intima, and form



Fig. 340.—Transverse section of part of the wall of the posterior tibial artery. *a*, epithelial and subepithelial layers of inner coat; *b*, elastic layer (fenestrated membrane) of inner coat, appearing as a bright line in section; *c*, muscular layer (middle coat); *d*, outer coat, consisting of connective-tissue bundles. In the interstices of the bundles are some connective-tissue nuclei, and, especially near the muscular coat, a number of elastic fibers cut across. 75 diameters. (After *Schaefer.*)

true abscesses, and the intima thus be completely elevated; nevertheless, the exudate does not penetrate the intima. When the intima is elevated from the muscularis over a large area, it finally lies as a relaxed membrane folded in the middle of the vessel and bathed in pus. If rupture of the intima occurs and the pus collects in the lumen, this is always a secondary phenomenon of mechanic origin. Every acute exudative inflammation, therefore, progresses chiefly in the middle and external vascular coats, quite irrespective of whether the inflammatory stimulus acts from without or within.

The changes caused by acute inflammation generally correspond in every way to the ordinary phenomena of parenchymatous inflammation: swelling and clouding. In intense inflammatory irritation from infectious material, exudates are produced. The latter may be homogeneous, granular, purulent, or ichorous in character. When only the vessel-

sheaths are affected, a purulent, ichorous, or an indurative periarteritis or periphlebitis, respectively, may develop. The process begins with swelling, hyperemia of the vasa vasorum, ecchymoses, edematous imbibition, and proliferation of the connective tissue. This is always the case after ligation and trauma. The affected vessel thus becomes very firmly adherent to the neighboring parts, so that it can subsequently be isolated only with great difficulty and care. The purulent and ichorous inflammations are always extension processes from surrounding parts, and occur in phlegmon, abscesses, infected wounds, etc., and also in connection with purulent inflammation of the media in infectious emboli. In the veins the purulent and ichorous processes very quickly extend to the middle and inner tunics of the vessel, and first cause thrombosis within the lumen. If suppuration or ichorous processes of the whole wall of the vein subsequently occur the thrombus also undergoes purulent or ichorous disintegration: *thrombophlebitis purulenta sive ichorosa.*

Inflammations of the media: mesoarteritis and mesophlebitis, usually begin with focal vascular injection and small ecchymoses; to these are added swelling and clouding; the wall becomes thicker, more rigid and opaque, whitish or yellowish white; the intima assumes a wrinkled or tumefied appearance. In the intenser grades of inflammation, small, pustule-like, yellowish macula sometimes develop, as a result of which the intima is easily elevated. In these cases the process is not purulent, but amorphous, granular elevations or protuberances develop which, on liquefaction, form a puriform mass. These may discharge into the lumen by rupture of the intima and mix with the blood. In other cases an adjacent abscess extends to the vessel wall and causes perforation of the intima through necrosis. The same process may occur also in connection with neoplasms (tubercle, carcinoma). Chronic inflammation of the media occurs more frequently in the veins than in the arteries. The wall becomes thicker and, in consequence of proliferation of the connective tissue, assumes a more homogeneous appearance. As a rule, this chronic inflammation is associated with a similar periphlebitis and thrombosis.

The intima is involved to a relatively slight degree in acute inflammations; it becomes slightly thickened, is a little clouded and wrinkled. As already stated, in purulent and ichorous processes of the other vessel tunics it often for a long time serves as a barrier, so that frequently thrombosis does not occur until it finally is destroyed by necrosis.

Circumscribed proliferation of the endothelium of the vessels belongs to the rarer occurrences. Thus far this has, with some degree of certainty, been observed only in the glomerular tufts in so-called glomerulonephritis; also in the central artery of the retina.

The commonest change of the vessels is simple fatty metamorphosis. This may involve all parts of the vessel. It is most rarely observed in the endothelium of the larger vessels; here, as a rule, only the result—the defect following the destruction—is noticed, the surface assuming a somewhat cloudy, dull appearance. Simple fatty metamorphosis of the cells of the capillaries, which, as is known, consist only of an endothelial layer, is seen much more frequently, especially in the brain.

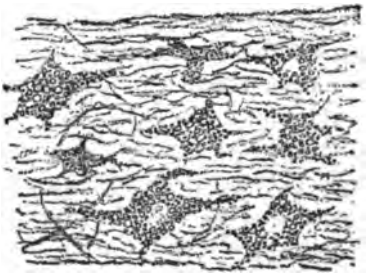

Fig. 341.—Fatty stellate cells from the aortic intima. (After *Smaus.*)

In the aorta, simple fatty metamorphosis of the intima is one of the most frequent necropsy findings; it occurs principally in anemic and chlorotic individuals. At first very small, delicate, opaque, yellowish striæ and puncta are seen; then fine, sometimes reticulated figures, with somewhat coarser nodular foci, and, finally, somewhat more marked, prominent accumulations. All these yellow markings correspond to the large stellate cells of the intima, which, as the result of

Fig. 342.—Endoaortitis chronica deformans.

fatty metamorphosis, are often distinctly recognizable, even with the naked eye. With advance of the process the limitations of the individual cells are gradually lost, the intercellular substance at the same time gradually disappearing. If the fatty metamorphosed cells are on the surface, parts may be dislodged and washed away by the blood-stream and superficial loss of substance occurs by so-called fatty erosion. Such parts have a slightly velvety appearance.

Fatty metamorphosis occurs also in the muscle-cells of the media. It is of greatest importance in the origin of dilations and ruptures, in ordinary and in dissecting aneurism of the aorta, and is frequently observed in the smaller cerebral arteries.

Simple fatty metamorphosis of the adventitia of the vessels is much rarer.

In contrast to simple fatty metamorphosis stands that form which is the termination of inflammations. This occurs principally in the intima, namely, in the deepest layer next to the vascular media (see Fig. 342, *W*); it begins with inflammatory proliferation of the intima cells. The process can best and most often be observed in the aorta. As the result of the proliferation circumscribed, less often diffuse, solid swellings develop in the intima, which at first have a swollen, translucent, gray or reddish gray, roughened appearance. The swollen areas are more succulent, partly through imbibition with watery constituents of the blood, partly through secretion of mucinous masses, and have a colloid character. In addition, areas occur which have acquired a very dense consistency and whitish color through increase and contraction of the intercellular substance. The corresponding areas in the media and adventitia are hyperemic and sometimes send newly formed vessels into the inflamed areas in the intima. As soon as the inflammatory proliferation has reached a certain degree of intensity, retrograde metamorphosis begins: the cells die by fatty metamorphosis. Out of the richly cellular thickenings produced by the proliferation true atheroma develops—an at first closed focus filled with atheroma (ἀθήρα = pap). The atheromatous material is composed of a puriform mass consisting of disintegration products, fatty detritus, amorphous tissue fragments, and cholesterin crystals. By progressive softening, bursting of the focus and discharge of the puriform mass may occur; atheromatous ulcer thus originates. The latter heals with the formation of a small, flat, often pigmented cicatrix. The cicatricial formation rarely results in constriction; in some cases, however, this is so marked as to cause stenosis.

Within the thickened sclerotic areas in the aorta calcification by deposition of lime-salts frequently occurs. This is not, however, a simple impregnation with lime-salts, but in part also a kind of ossification, since the lime-platelets contain branched, jagged cells which possess a certain resemblance to cartilage corpuscles. Such areas have a brownish-yellow tint.

Endoaortitis and *endoarteritis chronica deformans* involve chiefly those localities which are subjected to traction, distention, and stretching: *e.g.*, in the aorta at the point of insertion of the ductus Botalli, at the arch of the aorta at the point of origin of the vessels (intercostal arteries, etc.), the surface of the descending aorta attached posteriorly to the spinal column, etc. In these cases the thickening of the intima is the result of unequal tension and distention.

These changes, especially when they are strongly marked in the ascending aorta close above the aortic orifice, quite frequently extend secondarily to the valves, particularly to the base of the aortic valves, and produce a secondary endocarditis aortica chronica, which, like the above-described chronic endocarditides, may cause stenosis and incompetence of the aortic orifice.

Chronic endophlebitis is of very rare occurrence, manifests a marked tendency to calcification, but none at all to atheromatous formation.

Under certain conditions in which there is an especial disposition to calcification, *e.g.*, in advanced age, calcification of the muscularis occurs in the absence of inflammation, every muscle-cell being transformed into a lime-spindle by deposition of lime-salts. The calcifica-

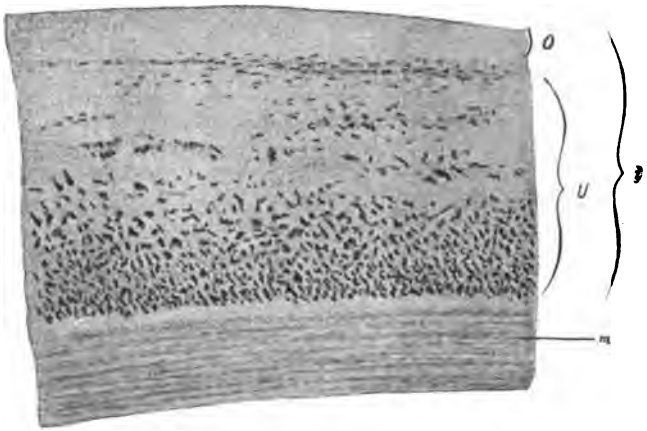

Fig. 343.—Endoaortitis chronica deformans. Thickening of the intima and slight fatty metamorphosis in the deeper layers of the intima. *m*, elastic media; *i*, intima; *o*, upper layer of the intima without fatty metamorphosis; *u*, lower layer of the intima with fatty metamorphosis. (Zeiss Obj., a_2; Comp. Ocul., 4. After *Langerhans*.)

tion sometimes extends throughout almost all the medium-sized and smaller arteries, and then also readily advances to the immediate neighborhood. The intima, as a rule, remains uncalcified; it often assumes a slightly wrinkled appearance. This calcification is a purely passive process, the constant cause of senile gangrene. The calcified media forms a rigid tube which resists slight pressure, but breaks on stronger. Adventitia and intima can, as a rule, quite readily be stripped off from the completely calcified media; but such an artery is not difficult to diagnosticate even without separation of these tunics, since the rigidity and the distinct transverse rings are easily recognizable characteristics.

Amyloid degeneration has great similarity to calcification of the media in so far as the process here also is an alteration of the smooth muscle-cells with suspension of the function. While the muscle-cells become more or less filled with amyloid substance, they swell and acquire a colorless, transparent, homogeneous appearance. This affection always begins in the muscularis of the smallest arteries, and on further progress extends to the capillaries. The swelling causes narrowing of the lumen and, consequently, ischemia. The latter is probably the cause of the atrophy of the parenchyma of the affected organs.

Inflammation of the arterial walls with new formation of connective and elastic tissues, which has received various names—endo-, meso-, and peri-arteritis—according to its principal seat in one or other

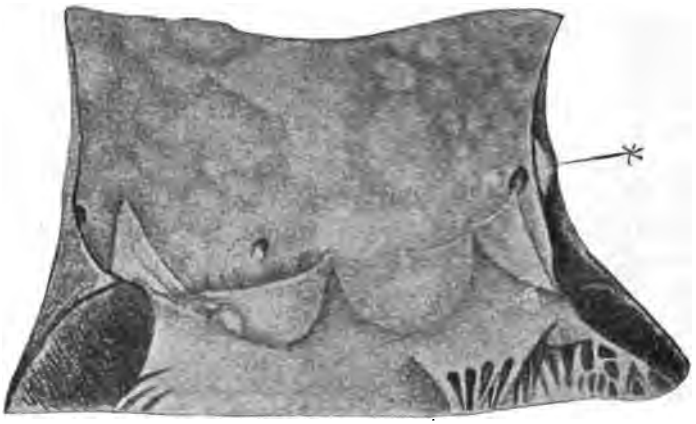

Fig. 344.—Endoaortitis chronica deformans gravis with extension to the basic portion of the aortic valves. The contiguous parts of the right and left aortic valves are markedly altered and shortened, so that aortic incontinence existed. At * small sacculated aortic aneurism. ⅔ natural size. (After *Langerhans.*)

tunic, is very frequent. In **productive** or **obliterating endoarteritis** the elements of the intima proliferate; this results in thickening, narrowing, eccentric displacement, and, finally, occlusion of the lumen. Proliferation of the endothelia, especially of the fixed cells of the intima, is the chief change, invasion of cellular elements (leucocytes) from the external coats of the vessel, *i.e.,* from the vasa vasorum, where such exist, being insignificant. If new vessels enter the cellular proliferated intima from the vasa vasorum the intima is converted into true granulation tissue and later into connective tissue. In the smallest arteries obliteration by true proliferation of the intima may occur without new formation of vessels. Productive endoarteritis occurs in increased pressure within the vessels

as well as in diminished or suspended blood-pressure, as is observed physiologicly in closure of the umbilic vessels, especially the umbilic vein. It frequently is a reaction to an irritant which attacks the vessel wall from within (hematogenous), *e.g.,* an embolus or a toxic substance, such as luetic poison, alcohol, etc., circulating in the blood, or from without, *e.g.,* in trauma, ligature, inflammation. In other cases productive endoarteritis involves the beginning of the aorta (***endoaortitis productiva***) as an extension from endocarditis.

Fig. 345.—Endoarteritis obliterans prolifera.

Affections of the elastic and muscular middle coat, which, unlike calcification and amyloid degeneration, are not attended by rigidity, but perhaps even with diminished tonicity of the coat, lead under pressure of the blood to permanent dilation: ectasis. So long as the dilation is slight, it can be compensated by secondary chronic endoarteritis. This compensation, however, is frequently insufficient, and then arterial ectases or aneurisms and phlebectases or varices develop. The more altered and atrophied the middle vascular coat, the more intense usually is the dilation.

Compensatory, connective-tissue hyperplasia of the intima and adventitia, which is always present and usually causes thickening of

the wall, cannot compensate the loss in contractile and elastic material; consequently, permanent vascular dilations are usually progressive in character. With progressive growth of these ectases the adjacent parts, in so far as they are movable, displaceable, or compressible, are displaced, and, in so far as they are immovable and fixed, are atrophied by the pressure, no matter whether they consist of soft or firm material. Even the bones, *e.g.*, the vertebræ and sternum, oppose no limitations to an aneurism of the aorta, but atrophy under the pressure.[1] This atrophy is accompanied by inflammation of the neighboring connective tissue, the products of which aid in strengthening the adventitia. Accordingly, the nature of this vascular dilation is a passive distention of the vessels after injury of the media; it is, however, associated with irritative and active processes—the connective-tissue structures are irritated through the distention and traction and proliferate. As a rule, when the dilation has advanced to a certain stage, a more rapid growth suddenly occurs. This is due partly to more extensive retrograde metamorphosis within the thickened connective-tissue wall, partly to diminished resistance of the neighboring structures, especially when the ectasis has advanced to the surface (of the external skin, serous membranes, surface of the digestive canal or of the respiratory tract, etc.) and the wall is no longer strengthened by connective-tissue proliferation in the surrounding parts. Then passive dilation with thinning of the wall begins, and, finally, rupture. The significance for the organism differs according to the size and location of the ectasis. The smallest aneurisms thus far observed occur in the brain and arachnoid. Rupture of these small aneurisms often suffices to produce fatal hemorrhage. The largest aneurisms are observed in the aorta, where they may attain the size of a child's head. They occur most frequently in the arch of the aorta, and less often in the abdominal than in the thoracic aorta. If the beginning of the aorta —the aorta ascendans—is aneurismaticly dilated, incapability of the valves to close may thus be produced without alteration of the valves. If an aortic aneurism bursts, rupture occurs either externally, after perforation of the sternum or several ribs, or internally into the trachea or bronchi, esophagus, the pericardium, etc.

According to the form and distention, the following true ectases are differentiated:—

1. **Simple ectasis:** general and uniform dilation of a vessel in thickness and length; hence, serpentine, tortuous course (vessels of the female generative apparatus in pregnancy, varicocele).

[1] By absorption in consequence of inflammatory irritation of the periosteum.

2. **Varicose ectasis:** irregular dilation of a whole vessel (namely, the arteries of the head, of the varices of the leg, struma varicosa, etc.).

3. **Ampullar ectasis:** partial local vascular dilation: (*a*) spindle-shaped, in which the whole circumference of a vessel is affected; (*b*) sacculated, in which only a part of the circumference of a vessel is involved (in the arachnoid and brain, the most frequent cause of larger hemorrhages).

In contrast to these true ectases, in which the intima, adventitia, and also the media, so long as it is present, are equally involved in the dilation, stand the false ectases, which, however, have thus far been observed only in arteries: *aneurysmata spuria.* They originate as a result of the blood breaking through the diseased intima and media at some point and making a new channel between the media and adventitia: *aneurysmata dissecantia.* In these, therefore, only the adventitia is involved in the dilation. Aneurysma dissecans, or dissecting aneurism, is observed in the upper portions of the aorta and in the smaller cerebral arteries. In the latter the points of rupture in the intima and media can scarcely ever be found; in the aorta they are, as a rule, quite small. If dissecting aneurism of the aorta exists for a long time, the inner surface of the aneurism may acquire an appearance similar to the intima of the aorta in endoaortitis deformans.

By *aneurysma per anastomosin* is understood an anastomosis of an artery and a vein as a result of traumatism. The vein becomes the seat of an inflammatory thickening of the wall in consequence of the sudden increased blood-pressure.

LYMPH-VESSELS.

As is known, the lymph, like the blood, forms coagula, but in the normal state and in the cadaver it coagulates only after contact with air. Therefore, whenever fibrin coagula are found in the lymph-vessels they always signify pathologic states: lymph thrombosis. The latter occurs in connection with inflammations of the lymph-vessels—lymphangitis, lymphangioitis—in infectious states, particularly in phlegmonous processes. The lymph-vessels are the routes by which infectious material (fluids containing bacteria, etc.) is conveyed to the nearest lymph-glands.[1] This infectious material is the cause of the lymphangitis as well as of the lymph thrombosis. The latter is a favorable event in so far as it thus prevents further extension of the infection. Lymphangitis always extends far beyond the limits of the

[1] Von Recklinghausen's view that the lymph-vessels communicate directly with the tissue-spaces has been questioned by MacCallum (*Arch. f. Anat. u. Phys.*, 1902).

true (actual) phlegmonous focus: *e.g.*, in phlegmon of the hand almost always to the axillary glands. If the inflamed lymph-vessels are located in the skin, they form slightly elevated, bright-red striæ. The termination of this lymphangitis is either ***restitutio ad integrum*** (as a rule, the red striæ disappear quite rapidly) or suppuration. In the latter case the neighboring parts are always involved to a greater or lesser extent. Occlusion of the lymph-vessels by thrombosis is usually unattended by further disturbance, owing to the numerous collateral channels. Even stenosis or occlusion of the thoracic duct is frequently readily regulated by anastomoses. General ectasis of the lymph-vessels with ***hydrops chylosis*** (hydrops + chyle) occurs only when the opening of the thoracic duct into the subclavian vein (or jugular) is impervious. Considerable lymph engorgement occurs also in mechanic interruption of the lymph-stream from compression of the lymph-glands, etc., when there is increased exudation from the blood-capillaries (*e.g.*, as the result of compression of venous trunks in the extremities). Likewise, in chronic dropsy (the result of heart, liver, and renal affections) permanent ectases (corresponding to the coexistent venous ectases) develop under the persistent increased pressure. The walls then become relaxed, inelastic, and thin, and the lumen is increased.

BLOOD AND LYMPH.

BLOOD.

Alterations of the Normal Constituents of the Blood.

THE **total amount of blood** in adults is about $\frac{1}{13}$ of the body weight. The estimation of the total amount of blood in the living subject by means of methods recently advocated for this purpose by Haldam-Smith and others is at present inapplicable for clinic purposes. The figures thus obtained vary between $\frac{1}{16}$ and $\frac{1}{30}$ of the body weight.

The **normal constituents** of the blood are the red and colorless blood-corpuscles (leucocytes), blood-platelets, and the blood-plasma. Hence, the blood may be regarded as a tissue with a liquid intercellular substance. Unlike other tissues, it does not possess the ability to preserve its integrity; indeed, no other tissue is so constantly subjected to variations in quantity and in chemic and morphologic composition. In addition to the normal and necessary constituents, there are transitory admixtures, such, for example, as the chyle, which normally enters the blood during digestion, but does not form a necessary constituent. The necessary constituents are elaborated by the blood-forming organs: lymphoid or adenoid tissue, spleen, and bone-marrow, and are continuously supplied to the blood through the lymph-stream.

The ordinary colorless blood-corpuscles[1] (leucocytes) swell slowly in water, more quickly in acetic acid. The cell is thus rendered translucent, and in the interior several (up to seven) nuclei can always be recognized arranged in horseshoe, clover-leaf, and other forms. (See Plates XII and XIII.) The nuclei have no nucleoli; the cell-body (cytoplasm) is quite homogeneous. These colorless elements originate from mononuclear, granular corpuscles, which generally are present only in small numbers in the blood. The number of leucocytes is from 5000 to 10,000 pro c.mm.[2] Therefore, the ratio of white to red blood-corpuscles varies under normal conditions from 1:500 to 1:1000. (See p. 675.)

[1] Form the chief constituents of pus.

[2] According to von Jacksch, Reinecke, Rieder, Kast, and Gütig, counts below 7000 are regarded as reduced, 7000 to 9000 as normal, and over 9000 as increased. Besançon and Labbé state the normal as 7000.

According to the size of the leucocytes, which varies between 3 and 15 μ, and the form and number of their nuclei, four different varieties are generally differentiated:—

1. Small, round, mononuclear cells, with a comparatively large nucleus and a very narrow, noncontractile peripheral mass of protoplasm (cytoplasm). These corpuscles are always smaller than the red blood-cells, and are called **small lymphocytes.** (See Plates XII and XIII.)

2. Large, mononuclear cells with pale cell-body, at least the size of a red blood-corpuscle or somewhat larger. The nucleus usually is ovoid or crescent-shaped and occasionally shows beginning lobulation. These are designated as **large lymphocytes.** (See Plates XII and XIII.)

3. **Large mononuclear cells** of Ehrlich, which are very similar to, and in fresh blood indistinguishable from, the large lymphocytes. These have a large, plump, pale, often slightly indented nucleus.

4. Cells with a somewhat more refractive, finely granular, contractile protoplasm and multiformed nuclei. The size of these cells exceeds the diameter of the red blood-corpuscles by several micra. They are called **polymorphonuclear leucocytes.** If the nucleus is so divided that the individual segments are disconnected, the cells are designated as **polynuclear leucocytes.** These two forms constitute the great majority of the white blood-cells, and they may be regarded as leucocytes in a strict sense. (See Plates XII and XIII.)

A small number of cellular forms described under No. 4 are characterized by intensely refractive coarse granulation of the cytoplasm. These are the **coarsely granular** leucocytes of Max Schultze, or the **eosinophiles** of Ehrlich. (See Plates XII and XIII.)

The following table, from Smaus and Herxheimer,[1] gives a synopsis of the various forms of leucocytes:—

1. **Indistinctly granular** mononuclear elements:—
   - (*a*) ordinary lymphocytes (over 20 per cent. of the colorless blood-cells);
   - (*b*) large lymphocytes;
   - (*c*) large mononuclear leucocytes;
   - (*d*) so-called transitional forms and
2. **Granular** leucocytes, which, according to their affinity for certain dyes, are designated as:—
   - (*a*) polynuclear and polymorphonuclear neutrophilic leucocytes (over 70 per cent. of the colorless blood-cells);
   - (*b*) polynuclear and polymorphonuclear acidophilic (eosinophilic, oxyphilic) leucocytes;
   - (*c*) basophilic leucocytes: mast-cells.

In addition, there are found in the bone-marrow and under certain pathologic conditions also in the blood early stages of (*a*), namely, mononuclear cells with neutrophilic granules: myelocytes, and of (*b*), namely, mononuclear cells with eosinophilic granules.

The so-called **blood-platelets** of Bizzozero, or hematoblasts of Hayem, are small, colorless, oval or round, discoid plates about one-third as large as red blood-

[1] Grund. d. Path. Anat., 8te Auf., p. 330.

cells. Their number is variously estimated at from 200,000 to 350,000 pro c.mm. There is no uniformity of opinion as regards the origin, nature, and significance of these bodies. There is no question, however, that the view that they are hematoblasts must wholly be rejected. Some observers attribute to them an especial rôle in the formation of thrombi. (See Thrombosis, p. 76.)

Blood-dust, or **hemoconia,** consists of very minute, highly refractive granules, about one-eighth the diameter of a red blood-cell, which manifest no ameboid movements, and float freely in the blood-plasma. Their function and nature are still undetermined.

A diminution in the number of white cells in the blood is designated as **leucopenia** (**hypoleucocytosis**). It frequently precedes a leucocytosis and is observed also in several infectious diseases, such as malaria, measles, typhoid fever, in certain cases of anemia, etc.

A simple, transitory (secondary) increase in the number of colorless (polynuclear and polymorphonuclear neutrophilic) blood-corpuscles is known as **leucocytosis,** and is dependent upon irritation of the organs concerned in hematosis. It is divided into a physiologic and pathologic form.

1. **Physiologic leucocytosis.** After every meal there is swelling of the mesenteric lymph-glands as a result of the flow through them of chyle, and at the same time an increase in the number of colorless corpuscles in the blood occurs. This is a digestion leucocytosis, in which the number of leucocytes usually does not exceed from 12,000 to 13,000 pro c.mm. It usually reaches its height in about two to three hours after ingestion of food. In like manner a progressive increase in the number of colorless blood-corpuscles within physiologic limits takes place during pregnancy, through swelling of the lymph-glands of the inguinal and lumbar regions in consequence of increased metabolism in the uterus and the accompanying dilation of the uterine lymph-vessels: pregnancy leucocytosis. So-called puerperal leucocytosis is due to absorption of disintegration products from the uterus, perhaps also the loss of blood during labor. Leucocytosis occurs also after cold baths and exertion.

Variations in the normal leucocyte count are very rapid and evanescent, while others develop slower and are more lasting. Alterations in the number of leucocytes probably are due to one of three causes: (*a*) new formation or destruction of leucocytes; (*b*) alterations in the concentration of the blood, which play only a subordinate part; (*c*) varying distribution of the leucocytes in the different vascular areas, to which the chief importance is to be attributed. Some of the physiologic variations can scarcely be due to new formation or destruction, since they occur with too great rapidity. The leucocytosis of digestion has been regarded as a true leucocytosis, *i.e.*, as due to the development of fresh corpuscles; but there is no convincing argument in favor of this view. The leucocytosis of childbirth, which increases markedly after the onset of the pains, diminishes after birth of the

fetus, and again increases during the after-pains, is assumed to be due to the associated muscular contraction. During muscular work the leucocytes may increase from 35 to 50 per cent. Variations in the leucocyte count occur also on sudden change from the erect to the recumbent position and *vice versâ:* static leucocyte reaction. The explanation offered of these changes is that, owing to the increased force of the heart's action and the greater velocity of the blood-stream produced, the leucocytes are forced from their peripheral position in the deeper vessels and hence reach the superficial capillaries in greater numbers. Physic influences also probably modify the leucocyte count through action upon the heart. Experiments upon rabbits show that injection of strophanthin causes increase in the leucocyte count.

Eosinophilic leucocytosis occurs after injection of diphtheria antitoxin and tuberculin; in various skin diseases (pemphigus, eczema, prurigo, psoriasis, etc.); in helminthiasis (ankylostoma, oxyuris, ascaris, etc.); in nervous colitis, pellagra, tetany, epilepsy, hemicrania, eclampsia; after ingestion of drugs: potassium iodide, antipyrin; in Basedow's disease, trichinosis (may reach as high as 60 per cent.). It is observed also in asthma, hay fever, and occasionally after splenectomy and in malignant growths. In worms the condition is said to be due to chemotactic attraction of the cells from the bone-marrow into the blood.[1] Ehrlich places the origin of the eosinophiles in the bone-marrow.

2. **Pathologic (inflammatory) leucocytosis** is one of the most frequent phenomena. It is the constant attendant of all affections associated with irritation of the lymphoid tissues or bone-marrow, and occurs especially in pneumonia and other infectious diseases, bacterial intoxication, and in suppurative conditions. The leucocytosis observed in chronic cachectic disturbances, such as occur after severe losses of blood, especially repeated small hemorrhages, in carcinoma, etc., is called cachectic leucocytosis. An agonal or terminal leucocytosis is observed shortly before death.

The cause of terminal leucocytosis (leucocytosis of the moribund) is not clear. Possibly the fall in blood-pressure, perhaps also the action of certain toxic products, play a rôle in its production. At all events, its occurrence is unquestionable, and to this source also may be attributed the increase in the number of leucocytes noticed toward the end of life in many cases of pernicious anemia, in which leucopenia usually exists.

The degree of leucocytosis in suppurative processes varies between 20,000 to 70,000 and over, as shown by the following tabulation by Lenhartz:—

[1] According to Moschcowitz (*New York Medical Journal,* cxiii, No. 1, p. 18), eosinophilia appears to be in some way related to anaphylaxis: "The invasion of eosinophiles in increased numbers into the organism is the expression of an active agent or the agent itself in the production of anaphylaxis." (See p. 322 *et seq.*)

Tonsillar abscess	up to	26,000.
Empyema	"	30,500-35,700.
Subphrenic abscess	"	42,900-46,000 (twice only 12,000-15,000!).
Hepatic "	"	24,400 or over.
Parametritic "	"	28,000 or over.
Puerperal thrombophlebitis	"	70,000 or over.

Inflammatory leucocytosis is observed also in acute infectious diseases in which suppuration does not occur, *e.g.*, croupous pneumonia. Here an increase is observed even several hours after the chill, which attains a height of from 20,000 to 30,000, indeed often 60,000 pro c.mm., then sometimes declines, but always remains considerably above normal until the crisis, immediately after which, or several days later, it usually falls to normal. In cases terminating fatally, the increase is sometimes not so marked. Lenhartz, however, mentions a fatal case of lobar pneumonia with a leucocytosis of 72,000! Reappearance of leucocytosis accompanied by mild elevations of temperature is often the first sign of beginning empyema.

There is also considerable leucocytosis (22,000 to 41,000) in acute nephritis. Furthermore, epidemic cerebrospinal meningitis is always accompanied by leucocytosis (25,000 to 60,000), and more or less marked leucocytosis is present also in sepsis, puerperal fever, erysipelas, acute articular rheumatism, diphtheria, recurrent fever, osteomyelitis, and, according to many authorities, also after injection of tuberculin.

Uncomplicated tuberculosis, malaria, typhoid fever, and measles are unattended by leucocytosis. Leucocyte counts of from 12,000 to 15,000 in typhoid are **always** due to complications: purulent bronchitis, otitis, pneumonitis, etc. Tropic malaria (4300 to 7600), tuberculous pleuritis and meningitis, and general miliary tuberculosis, and, according to Lenhartz, also chronic lymphomatosis, progress without any indication of leucocytosis. In tuberculous meningitis a rise of the leucocytes to 20,000 was observed by Lenhartz in only one instance. The statements in connection with scarlatina are contradictory, von Limbeck and Pick claiming never to have seen leucocytosis, while Riedel found it to be almost constant. According to Roger, scarlatina is attended by a leucocytosis which persists long after defervescence. The polymorphonuclears are slightly decreased at the beginning, becoming more numerous as the disease progresses. Kotschetkoff states that a leucocyte count of from 10,000 to 20,000 is found in mild cases, 20,000 to 30,000 in cases of moderate severity, and above 30,000 in grave cases. The polymorphonuclears constitute 85 to 98 per cent. of the total number. In average cases of moderate severity the eosinophiles progressively increase up to the second or third week (maximum 8 to 16 per cent.), and then gradually return to normal.

As regards the ratio of the different varieties of leucocytes in inflammatory leucocytosis, it is now well established that the presence of more than 80 per cent. of polymorphonuclears is indicative of purulent or inflammatory processes (peritonitis, pneumonitis, meningitis, abscess, etc.), and the reliability of this indication is enhanced with the rise in percentage. While no definite parallelism between the degree of leucocytosis and the local and general phenomena has thus far been established, there appears to be a certain relation between the degree of leucocytosis and the resistance of the organism to infection: the more marked the leucocytosis and the earlier it appears, the greater, as a rule, is the resistance. It should be borne in mind, however, that, on the one hand, in individuals with good resistance, slight infection may be unattended by leucocytosis, and, on the other hand, in persons with low resistance, even slight infection may be accompanied by more or less marked leucocytosis. The severity of the infection, it would seem, is, in a measure, indicated by the percentage of polymorphonuclears, since in cases in which the ratio count is high (90 per cent. or over) and leucocytosis low or absent the prognosis is grave.

The fact that the termination of those diseases in which inflammatory leucocytosis occurs at all is favorable when the leucocytes are considerably increased, and unfavorable when they are diminished, suggests that this process is a salutary one. A satisfactory explanation of acute inflammatory leucocytosis, however, is still lacking.

The function of the leucocytes is by no means fully understood. It is known, however, that they manifest numerous fermentative actions (fibrin ferment, proteolysis, oxidase, reduction); that they serve as recipients and carriers, and probably also as assimilative organs for numerous substances, such as fat, iron, glycogen, etc.

According to Grawitz,[1] the total number of leucocytes in the circulating blood, if collected in one place, would make an organ the size of the thyroid gland. In irritative states of the most varied kind this figurative organ possesses the ability to double or treble its cellular constituents within a very short time and thus to assume new functions which are generally regarded as protective or defensive. The question whence this great number of new cells is derived is naturally of the greatest importance in the conception of the phenomenon of leucocytosis. While under physiologic conditions there is a constant influx of lymphoid cells from the lymphatic apparatus through the lymphatic duct into the large venous trunks and an entrance of myeloid cells from the bone-marrow, in irritations of various types, especially inflammatory processes, other sources of leucopoiesis are active. Although there is a wide diversity of views among recent investigators in regard to the genesis of the leucocytes, there is considerable uniformity of opinion that in inflammatory leucocytosis lymphatic as well as granulocytic proliferation occurs in almost all organs, from which it is assumed that it is not a question simply of out-

[1] Deutsch. med. Woch., No. 15, 1911, p. 677.

wandering (chemotactic attraction) and local accumulation of blood-leucocytes, but a reviviscence of the remnants of the mesenchyme tissue distributed throughout the whole organism. This reversion is designated as lymphoid or myeloid metaplasia of the tissues. Inflammatory leucocytosis, therefore, is due not only to increased ubiquitous leucopoiesis, but to entrance into the blood of cells formed at the focus of inflammation.

Inflammatory leucocytosis is a biologic reaction and an accompaniment of the numerous reactive processes established in the organism in opposition to the entrance of pathogenic agents and their toxins. It makes little difference whether this phenomenon is intimately connected with phagocytosis, which is most probable, or with the formation of antibodies or stimulins. It occurs in every case of inflammation with the regularity of a natural law. As the immediate result of an infection the leucocytes circulating in the blood, and those in reserve which have not yet entered the circulation, are called upon.

The question whether inflammatory leucocytosis deserves the attention given to it is variously interpreted. According to Sonnenburg,[1] who has devoted a number of years to a study of this subject in connection with numerous surgical conditions, inflammatory leucocytosis has eminent diagnostic and prognostic significance and, therefore, a practical value. According to him, leucocytosis explains the degree and virulence of the infection and the toxicity of an inflammation, and in its further course reveals their increase and decrease. It also is an index of the degree of resistance. As regards prognosis, it may be said in general that high leucocyte counts indicate a favorable, low, subnormal, and extremely high counts an unfavorable, termination. Occurrence of new foci and suppurations is revealed earliest by reincrease of the number of leucocytes, and frequently these can be discovered in this way, even when the pulse and temperature are unaltered. Leucocytosis often manifests individual variations independently of age and sex, in this respect acting similar to the temperature. In many patients fever in infectious diseases runs higher or lower than in others; likewise, in infections many patients react more energeticly than others by more marked increase of the number of leucocytes. The individual variations, however, lessen the value of the initial leucocytosis just as little as they lessen the value of the temperature.

It must be borne in mind, however, that leucocyte counts can be correctly interpreted only by comparison with the symptoms.

The significance of leucocytosis in infectious inflammatory diseases observed in internal medicine is much more difficult to interpret than is the case in surgical inflammations. While in the group of infectious diseases the behavior of the leucocytes is variable, it may, according to Grawitz,[2] be stated as a general rule that a pronounced leucocytosis is present whenever hemolyzing toxins are active, while inflammatory infiltrates do not, without further changes, produce leucocytosis. Therefore, all septic infections, that is, such as are produced by the various pyogenic agents, progress with high leucocytosis, even when local inflammations are by no means extensive. On the other hand, in typhoid, in spite of extensive inflammatory infiltration of the intestinal and mesenteric glands and of the spleen, not only no leucocytosis, but rather a diminution of the number of the leucocytes—leucopenia—is present. While various moments play a rôle here, it is worthy of note that in septic affections the severest hemolytic effects are exerted

[1] *Ibid.*, p. 673.
[2] *Ibid.*, p. 679.

upon the red blood-corpuscles, which, in puerperal sepsis for example, often result in a few days in a reduction of the erythrocytes to a fourth of their number and lower; while in uncomplicated typhoid a slight diminution of these cells in consequence of the protracted fever and undernutrition is observed, but never actual deleterious effects. This finds expression in the rapid convalescence of typhoid patients, as compared with those chronic severe injuries of the organism, especially of the blood-mixture, after recovery from sepsis.

Arneth Theory.—Arneth refers leucocytosis not to pure chemotactic processes, but to organic activity, principally to a biologic reaction of the bone-marrow. He was able to demonstrate, in addition to new formation of leucocytes, a greater consumption of leucocytes in infections. Having demonstrated that the numeric ratio

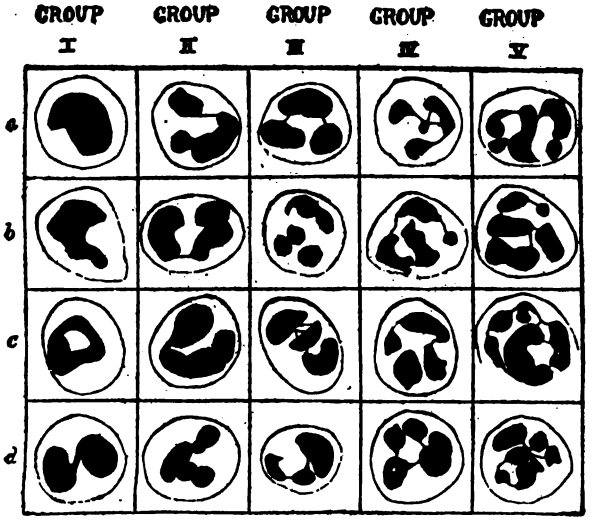

Fig. 346.—Arneth theory.

of the neutrophilic cells is constant in health and changes in infections in a quite definite manner, Arneth grouped the neutrophiles according to the character of the nucleus and assigned especial pathologic and diagnostic significance to blood-pictures in which the mononucleated cells preponderate over those with multilobulated nuclei. According to Arneth, the cells developmentally most advanced—the multinucleated leucocytes—decrease in favor of the younger, mononucleated forms and finally disappear in high grades of infection, the neutrophilic blood-picture undergoing a so-called displacement to the left. (See Fig. 346, Group I.)

Arneth and others assume that increased destruction of multilobulated, old cells and preponderance of the young, mononucleated forms is to be interpreted as an unfavorable prognostic sign. The more violent the conflict between the invading infectious agents and the leucocytes, the greater the number of leucocytes destroyed and the greater, of course, the change in Arneth's blood-picture. In the conflict of the organism against the infection, the entrenched forces advance first against the invaders, assembling, according to the virulence of the infection, all available forces; finally, when these no longer suffice, the reserves—the young, mononucleated cells—advance. The greater the number of reserves that appear,

the more unfavorable the combat for the organism. A verdict of the virulence of the infection and an understanding of inflammatory leucocytosis are thus obtained. For example, in severe septic peritonitis the low leucocyte counts are due to enormously augmented destruction of leucocytes which the bone-marrow, in spite of active proliferation, is unable to compensate.

Sonnenburg distinguishes a hypo-, normo-, and hyper- leucocytosis, and designates the normal as "iso," and displacement toward the left as "aniso." Increase of the number of leucocytes without essential alteration of the percentage ratio of the individual categories is called "isohyperleucocytosis"; if, owing to the virulence of the infection, the percentage ratio of the cells diminishes, that of the younger elements of the blood-picture increasing, but the number of leucocytes constantly remaining high, the state is called "anisohyperleucocytosis." If, however, the reserves are insufficient to combat the infection, a diminution of the leucocytes occurs, which is called "anisohypoleucocytosis."

Kothe, of Sonnenburg's clinic, has simplified the Arneth method by taking the percentage of the mononuclear neutrophiles as an expression of the alteration of the blood-picture. He counts only the mononuclears, ignoring the difference between the myelocytes and cells with slightly or deeply indented nucleus. For estimation of the change of the neutrophilic blood-picture the numeric ratio of the cells in the first class—that is, the mononuclears—is employed exclusively. According to Sonnenburg, this simplification of the method has proved to be practical.

Kohl[1] divides the displacement of the blood-picture to the left into different degrees. He designates 11 to 25 per cent. as aniso of the first, 25 to 45 per cent. as aniso of the second, 45 to 60 per cent. as aniso of the third, degree, and over 60 per cent. as aniso of the fourth degree.

Arneth's method has not found general recognition, and also has met much opposition; but Sonnenburg[2] regards it as clinicly reliable and of practical value. The fact that the infection causes an alteration of the blood-picture cannot be denied, and it is practically unimportant whether the individual cell groups are placed in this or that category. The main point is to correctly interpret and apply the constantly occurring alterations.

Grawitz[3] combats Arneth's theory on the ground that the idea of the origin of all these cells from the bone-marrow is untenable today, and that the single form of the nucleus by no means indicates a younger age of the cells in so far as they are encountered in the circulating blood. It is unproven that these forms or the large mononuclear and transitional forms observed in the blood develop into ripe neutrophiles with lobulated nuclei; it is more conceivable that these developmental forms of leucocytes have certain functions to perform and do not pass beyond this stage of development. Of two cells of equal age, one may very rapidly ripen into a polynuclear neutrophile, the other remain in the stage of transition; hence, it would be incorrect to regard as younger the one that had not reached the final stage of development. If, therefore, many neutrophiles with single nucleus are continuously found in a given infection, it can be said only that in this disease many leucocytes in this stage of development are active; whether these differ in age it is impossible to state.

In the extreme multiplicity of the physiologic functions of the leucocytes and

[1] Mitteil. a. d. Grenzgb. d. inn. Med. u. Chir., 1911, Bd. 22, H. 4, p. 542.
[2] *Loc. cit.*, p. 674.
[3] *Loc. cit.*, p. 678.

the manifold tasks which fall to them in the various inflammatory affections, it is comprehensible that the morphologic character of the leucocytes must vary in individual cases. It must be assumed that all blood-leucocytes, whether small or large lymphocytes, large mononuclear, transitional forms, neutrophiles or eosinophiles, exert certain functions. In the group of neutrophiles especially, so many differences, aside from the structure of the nucleus, can be seen in the number and arrangement of the granula and in their affinity for the various dyes that it seems only rational to accept the differences as an expression not only of age and developmental stadia, but also of different functions.

In order to obtain an insight into the nature of inflammatory leucocytosis experimentation has been resorted to. Von Limbeck saw intense leucocytosis after injection of cultures of bacteria, especially those of staphylococcus; Binz and Meyer mention the occurrence of considerable increase in the leucocytes after the administration of ethereal oils; Pohl, after spices, etc. The observations of Buchner and others render it probable that it is not the toxic (decomposition) products of the bacteria, but chiefly or exclusively their proteins (albumin substances), which produce so-called positive chemotaxis—that is, an attraction of the leucocytes. The fact that nucleated red blood-cells and a considerable leucocytosis are observed after extirpation of the spleen, as well as in the above experiments, speaks somewhat in favor of an irritative action exerted upon the "blood-forming" organs. Be this as it may, the increase of leucocytes in the blood could be produced also by the entrance of wandering cells or as the result of rapid cell division within the blood-channels. (Löwit.) The first hypothesis would be entirely contrary to Ehrlich's theory, since, according to him, only mononucleated cells are supplied to the blood; nevertheless, the great majority of the colorless cells found in acute leucocytosis are unquestionably of the polymorphonuclear variety. However, it is known that transformation of mononuclear into polymorphonuclear cells takes place quite rapidly.

In contrast to leucocytosis, **leukemia**, or **leucocythemia**, which is due to alterations in the blood-forming organs, is, in a measure, a progressive leucocytosis, a persistent increase in the number of colorless elements with coincident progressive diminution in the amount of hemoglobin (oligochromemia) and the number of red blood-corpuscles (oligocythemia), so that, finally, red and colorless blood-corpuscles may be present in nearly equal numbers, the white elements occasionally exceeding the erythrocytes. The decrease in the number of red corpuscles is probably due to cessation of production, no more erythrocytes being transformed into red cells. The increase in the number of colorless cells in the blood in leukemia is in direct proportion to the hyperplasia of the elements of the bone-marrow and lymphoid tissues.

The red blood-cells are paler than usual, and not rarely of variable size. Blood-plates are usually more numerous than normal. According to numerous authorities, a little practice will suffice to diagnosticate, by careful examination of the fresh blood alone, the particular form of leukemia according as participation of the spleen, bone-marrow, or lymphatic glandular system preponderates. If those colorless corpuscles, which are about as large as a normal erythrocyte, are chiefly increased, it may safely be concluded that the glandular system is principally involved: "lymphatic form"; on the other hand, if the large cells appear in the majority, participation of the bone-marrow and spleen must be thought of: "myelogenous" and "splenic" forms, and the spleen should be suspected when there appear in every field of the microscope a large number (from 3 to 5 and more) of cells filled with strongly refractive, spheroid granules, while involvement of the bone-marrow is rendered probable especially by the presence of large mononucleated leucocytes.

A rare manifestation in leukemic blood is the presence of isolated Charcot-Leyden crystals. This phenomenon has no diagnostic significance, for, as a rule, they are found in decomposed leukemic blood, though they may appear in the absence of such a change.

Formerly, three varieties of leukemia were differentiated: lymphatic, splenic (Virchow), and medullary or myelogenous. (See Plates XII and XIII.) Following the classification of Ehrlich, who claims there is no form of leukemia characterized by specific splenic elements, there is now a tendency to admit only a lymphatic and a myelogenous form, and to eliminate the so-called splenic form of Virchow. The first is referred to lymphatic and the second to myeloid tissue alterations.

In the **lymphoid,** or **lymphatic,** form (lymphemia), two varieties of which are distinguished, namely, acute and chronic, the lymphocytes, which are derived from the lymph-glands and the lymphoid portions of the spleen, bone-marrow, and mucous membranes, are the predominant white elements, and may finally displace all other types. In the acute form large lymphocytes predominate, and in the chronic form the small lymphocytes. (See Plates XII and XIII.) Hyperplastic proliferation is observed in the lymphoid structures in both forms, but is most marked in the chronic type.

In the **myeloid, myelogenous,** or **mixed** form of leukemia (myelemia) there occur, aside from polymorpho- and poly- nuclear leucocytes, early stages of the polymorphonuclear leucocytes (granular mononuclear leucocytes, myelocytes), derived from the bone-marrow; also numerous eosinophiles, basophiles (mast-cells), and atypic forms; likewise mitoses, nucleated red cells, cells inclosing red corpuscles, microcytes, and disintegration products of blood-cells. While here the bone-marrow may be regarded as the chief seat of formation of the myelocytes, it is assumed, on the basis of the investigations of Dominici, Frese, and others, that the spleen, which is always and usually enor-

mously enlarged, and the lymph-glands (which, however, frequently are not involved or enlarged) also elaborate these cells, either an autochthonous myeloid transformation (metaplasia) occurring, or myeloid tissue is metastaticly deposited in these parts. (Kaufmann.)

Owing to the increase of the colorless elements and the coincident arrest in the formation of red corpuscles, the blood gradually acquires a characteristic reddish-white, reddish-yellow-white color,[1] and is cloudy as though mixed with pus or fat. The cadaveric coagula (in the heart and larger vessels) are whitish, light yellow, or yellowish green in color, much softer than normal, and consist chiefly of leucocytes. The spleen is always enlarged, sometimes enormously. In almost every case the bone-marrow of the long bones is involved. Sometimes it alone is altered: myelogenous or medullary form. In such instances the bone-marrow has a decidedly pale-red, almost milk-white-red appearance, consists principally of myeloid cells, and always contains numerous nucleated red blood-corpuscles. So-called Charcot-Leyden (-Neumann) crystals (Plate XIV) (slender, elongated octahedra), which are observed also in the sputum in various pulmonary diseases (asthma crystals), occasionally are found in the blood, bone-marrow, and spleen. These are usually, if not always, the result of decomposition. The lymphoid structures throughout the body (chiefly in the chronic form) are more or less involved (lymphoid swelling or leukemic lymphoma). Circumscribed or more or less diffuse accumulations of the same kind of cells as are increased in the blood are very frequently found in the different organs, particularly in the liver, kidneys, and retina (leukemic infiltration). This is a kind of metastasis, as the result of which the liver and kidneys are sometimes not inconsiderably enlarged.

The disease usually terminates fatally within from one to two years, some cases, as stated above, being very acute and ending within a few weeks. The majority of cases occur in males between the 30th and 40th year. Among the causes chronic infectious diseases, such as syphilis and malaria, and chronic enteritis, alcohol, and trauma have been mentioned. Ehrlich regards a specific toxic action as the etiologic factor. Some authorities hold the *Bacillus tuberculosis* responsible for the process.

The causes of the alterations in the blood in leukemia have thus far not been explained. The question whether the process is an independent disease of the blood, with retarded disintegration of the more resistant leucocytes (Löwit), or whether the blood-forming organs themselves have become permeable and are no longer capable of preventing the premature escape of unripe corpuscular elements (Virchow), is still unsolved. Perhaps both views are correct, and the process is

[1] Hence the name λευκον = white, and αἷμα = blood.

one in which there is hyperplasia and abnormal permeability of the blood-forming organs as well as a diminished destruction of leucocytes in the circulating blood. It is certain, however, that a very active formation of cells by division can be observed in those localities in which blood formation occurs (Bizzozero)—a fact which militates against Löwit's theory. Likewise, in almost every case of leukemia there is to be found a more or less advanced hyperplasia of the three blood-forming organs: the spleen, the lymphatic glands, and the bone-marrow. The latter is greatly altered, particularly in the long tubular bones and sternum, but also in the ribs and vertebræ. According to Neumann, the marrow appears either pus-like (pale greenish) or of a more homogeneous raspberry-red color and of pyoid or lymphadenoid form. As a rule, the varieties of leukemia observed are mixed types in which all blood-forming organs present alterations, the intensity of the pathologic process varying in different localities, one place showing less advanced, another intensely progressive, changes. The question as to which organ is most affected can generally be decided by the blood-findings.

The case of Leube and Fleischer, which at necropsy showed lymphadenoid changes in the bone-marrow, but no alterations in the spleen and glands, is usually cited in support of Löwit's theory. This observation, however, by no means offers a firm basis for his theory, for it does not explain why in this case a d e p o s i t i o n of the leucocytes accumulated in the blood did not occur in the spleen and glands—a phenomenon which, according to Löwit, always occurs secondarily in leukemia. That medullary alterations may be entirely absent, even in leukemia of intense degree, has been demonstrated by Fleischer and Penzoldt (Lenhartz-Brooks).

Leukanemia (Leube) is a condition in which the blood changes of pernicious anemia and leukemia are combined. As mixed forms of leukemia are not infrequent, there seems to be no necessity for this name.

In so-called **anæmia pseudoleukæmica infantum** (von Jaksch's anemia), a chronic anemia of children, apparently due to a number of diseases productive of anemia, the development of myelogenous tissue in the liver, spleen, pancreas, kidneys, lymph-glands, etc., is frequently very decided. The number of red corpuscles is very markedly diminished (1,000,000 and even less), and the leucocytes, especially the polymorphonuclears, increased (20,000 to 100,000). Numerous normoblasts and, occasionally, megaloblasts also are present.

In the majority of cases **anæmia splenica infantum** is secondary principally to gastroenteritis combined with disturbances of nutrition. There are primary cases, however, in which antecedent causes are not demonstrable and, consequently, the etiology is obscure. The age of the children affected varies between 6 months and 2 years. The characteristic features are: great pallor, olive-green discoloration of the face, tumefaction of the spleen without enlargement of the liver, and peripheral lymphatic glands. The blood findings are: oligocythemia, oligochromemia, poikilocytosis, anisocytosis, lymphocytosis, presence of myelocytes and erythroblasts. The prognosis is grave.

Pseudoleukemia, lymphomatosis, Hodgkin's disease. The clinic alterations observed in this affection not infrequently present a striking resemblance to genuine leukemia. Although there is often marked hyperplasia of numerous noncaseated lymph-glands, and not rarely considerable enlargement of the spleen and tenderness of the bones, examination of the blood shows, especially in the beginning, either no deviation from the normal or, later, a reduction of the erythrocytes to from 1,500,000 to 2,000,000, according to the degree of anemia, with only a slight increase of the leucocytes. There may be leucopenia of from 3000 to 3500. The hemoglobin is decreased in proportion to the diminution of the red blood-cells. The changes correspond, therefore, with the signs present in secondary anemia.

Pseudoleukemia is from two to three times more frequent in males than in females, and may appear at any age. The assertion of many authorities that it may develop into true leukemia has not been confirmed. Sternberg's view that Hodgkin's disease is tuberculous in nature has recently received support by the investigations of Fraenkel and Much. It is, therefore, possible that a modified form of the ordinary tubercle bacillus, or else an antiformin-fast micro-organism related to the tubercle bacillus, may be the causative agent.

The mature **red blood-corpuscles**[1] are feeble, unstable constituents, and must constantly be replaced by new elements which originate in the bone-marrow by gradual metamorphosis of erythroblasts. In fetal life the red blood-cells are formed also in the spleen and liver. The primary red blood-corpuscles are derived directly from the embryonal formative cells of the ovum; they possess nuclei, and during the early months are capable of multiplication by division. Later, the nuclei disappear; they subsequently reappear only under pathologic conditions (in pernicious anemia, leukemia, after profound hemorrhage, etc.). The

[1] Virchow's statement: *"Die Geschichte der rothen Blutkörper ist immer noch mit einem geheimnissvollen Dunkel umgeben"* (the history of the red blood-corpuscles is still enshrouded in mysterious obscurity), is, unfortunately, still true today. The view that the red and colorless blood-cells are from the beginning two separate cell-groups is the most worthy of consideration. According to the older view, which has recently been defended by H. Müller, the red and colorless blood-cells originate from a single variety of colorless cells, which develop into leucocytes as well as erythrocytes—in the latter instance by the reception of hemoglobin. On the other hand, Denys and Löwit assume the existence of two different kinds of colorless elementary cells (leuco- and erythro- blasts) and differ in their views only as to the locality in which the transformation of the colorless into colored corpuscles occurs. According to Denys, who attributes karyomitosis (indirect nuclear division) to both types, the transformation takes place only in the bone-marrow; according to Löwit, only in the circulating blood. Hayem, however, considers the hematoblasts (blood-plates) as the sole antecedents of the red blood-corpuscles, while Neumann and Bizzozero reject all these views and assert that the red blood-corpuscles originate entirely through mitosis of young, nucleated red cells within the bone-marrow.

cell-body of both the nucleated and nonnucleated red blood-corpuscles has a distinctly yellow color, due to the presence of hemoglobin. The normal number of red blood-corpuscles in adults is about 5,000,000 pro c.mm., the number in females being somewhat less than in males.

After severe hemorrhage and in diseases attended by injurious effects upon the blood, three different sizes of red blood-cells are often seen, namely, ordinary sized (normocytes), abnormally large (megalocytes), and abnormally small corpuscles (microcytes). Not infrequently the form also is altered: anvil-, dumb-bell-, pear-, and crescent- shaped forms are observed (poikilocytes). Marked variation in the size of the red blood-cells is designated as anisocytosis. In some blood affections regeneration forms (nucleated cells: erythroblasts) are seen. Nucleated red blood-cells the size of a normal red blood-corpuscle are called normoblasts; those several times as large as a normal red cell are known as megaloblasts; the latter are indicative of defective blood formation in the bone-marrow. Numerous red blood-corpuscles may acutely be withdrawn from the circulation, as in severe losses of blood (*e.g.,* in typhoid and other hemorrhage), or large numbers of cells may be destroyed in the circulation, as in malaria and the so-called blood poisons. In certain diseases, such as malignant tumors, syphilis, hemorrhagic diathesis, lead and mercury poisoning, etc., and in so-called primary or essential blood diseases (leukemia, pernicious anemia, chlorosis), oligocythemia may chronicly be established.

In intermittent (malarial) fever (see p. 410) the red blood-corpuscles are directly destroyed by the action of the *Hæmamœbæ malariæ* (Grassi) and the hemoglobin transformed into small, brown and blackish-brown, aferrous pigment (hemozoin) granules. This produces the condition known as melanemia. Immediately after a paroxysm these pigment-granules swim freely in the blood-plasma; they are later taken up by the colorless corpuscles and epithelial elements, and finally are deposited in the spleen and partly also in the lymph-glands, liver, and bone-marrow, or, when large amounts of melanin are present, they are excreted with the urine: melanuria.

Hemoglobinemia is due to the passage of hemoglobin from the red blood-corpuscles into the blood-plasma, in which it is held in solution. It is observed in certain poisonings (by bismuth subnitrate, sulphonal, phenacetin, antifibrin, antipyrin, naphthol, arseniureted hydrogen, glycerin, carbolic acid, toluylendiamin, pyrogallous acid, sulphuric acid, phallin, helvellic acid, etc.), in septic processes (bacterial toxins), in acute and chronic infectious diseases, such as typhoid, scarlatina, syphilis, malaria (not always), after the action of cold, in burns, and also after transfusion

of animal (heterologous) and occasionally of human (homologous) blood. (See p. 321.) The serum is clear and ruby-red, instead of yellow, as in the normal state. If the spleen, liver, and bone-marrow are unable to transform the liberated hemoglobin conveyed to them by the circulation, the hemoglobin occurs unaltered first in the bile (hemoglobinocholia), and then in the urine (hemoglobinuria).

According to R. Koch and Kleine, the black-water fever of the tropics is a hemoglobinuria caused by the use of quinine.[1] In marked cases of hemoglobinemia icterus may occur. The escape of hemoglobin from the red blood-corpuscles is called hemolysis (see pp. 26 and 320), which frequently is preceded by agglutination or cohesion of the red blood-corpuscles. The corpuscles deprived of their hemoglobin are usually still recognizable for a short time as colorless, scarcely visible disks (so-called Ponfick's shadows).

The affection occurs also spontaneously as the so-called "paroxysmal" or intermittent form.

Especially predisposed persons are attacked by the disease after violent muscular exertion or on sudden exposure to cold. It begins with chill and great prostration, and rapidly produces apparently grave constitutional disturbances and pronounced hemoglobinuria. In the majority of instances it rapidly terminates in recovery, until, after a time, a new paroxysm is produced by similar causes. In persons suffering from "paroxysmal" hemoglobinuria, a purely local alteration of the blood can be produced. If the finger of such an individual is constricted and immersed for fifteen minutes in iced and then lukewarm water, the serum after separation will show the ruby-red shade even in a thin capillary tube (Ehrlich).

The cause of the liberation of the hemoglobin is, according to Donath and Landsteiner, a complex autohemolysin, which, on cooling and subsequent heating of the red blood-corpuscles, causes hemolysis. In addition, it has recently been shown that a certain diminution of resistance of the erythrocytes and an abnormal excitability of the vasomotors exist in the "paroxysmal" form. The blood-serum alone possesses hemolytic properties. The erythrocytes manifest a distinct diminution of resistance to free CO_2. According to Krokiewicz,[2] the action of free CO_2 at room temperature is necessary for the occurrence of hemolysis *in vitro*. With the hemoglobinuria, hemoglobinemia, solely from oxyhemoglobin, can synchronously be demonstrated; in the normal periods the serum contains no oxyhemoglobin. The influence of the vasomotor and secretory nerves appears to be of importance for the occurrence of CO_2 hemolysis. Very small amounts of atropine distinctly inhibit the attack; small amounts of pilocarpine favor it. Probably the occurrence of CO_2 hemolysis is due to the increased secretory activity of the vascular endothelia as a result of augmented activity of the nerves mentioned. The collective hematologic findings during the attack suggest a constant irritation of the blood-forming organs. During the attacks the previously increased number of lympho-

[1] Sambon, on purely theoretic grounds, regards black-water fever as a specific disease nearly related to, or identic with, Texas fever. Christophers and Bentley, however, combat this view.

[2] Wien. klin. Woch., No. 14, 1911.

PLATE XII

Fig. 1.—Progressive pernicious anemia ending fatally in six weeks, etiology unknown. Ehrlich's triacid stain. Zeiss, 1; oil immersion, 1/12. a, normocyte; b, megalocyte; c, microcyte; d, marked poikilocytosis; e, megaloblast; f, polymorphonuclear neutrophilic leucocyte. (After Lenhartz-Brooks.)

Fig. 2.—Splenomyelogenous leukemia. Young man with enormous spleen tumor. Triacid stain. Zeiss, 1; oil immersion, 1/12. a, normocyte; nucleated erythrocytes, nucleus partly eccentric; c, polymorphonuclear neutrophilic leucocyte; d, eosinophilic myelocyte. The upper eosinophilic cell [illegible] the granules [illegible]. (After Lenhartz-Brooks.)

Fig. 3.—Splenomyelogenous leukemia, man aged 34 years with marked spleen tumor. Eosin-hematoxylin stain. Zeiss, 1; oil immersion, 1/12. a, normocyte; a1, megaloblast; a2, megaloblast with anemic degeneration; b, polymorphonuclear leucocyte; c, myelocytes; d, large lymphocyte. (After Lenhartz-Brooks.)

Fig. 4.—Acute leukemia. Two pictures are from two different cases running a rapidly fatal and clinically similar course. In the upper part is shown staining with Ehrlich's eosin-hematoxylin mixture; lower part, Ehrlich-Lenzinsky stain. (After Lenhartz-Brooks.)

Fig. 5.—Myeloid leukemia; man aged 40 with enormously enlarged spleen. Jenner's stain. a, nucleated red blood-cells; b, small lymphocytes; c, mast cells; d, cells with double granulations; e, eosinophilic cells; f, large mononuclear neutrophilic cells; g, large mononuclear cells without especial granulations. × 450. (After Lenhartz.)

Fig. 6.—Hemin crystals from dried blood-spots. Leitz, 1; Obj., 7. (After Lenhartz-Brooks.)

PLATE XII

Fig. 1.—Progressive pernicious anemia ending fatally in six weeks; etiology unknown. Ehrlich's triacid stain. Zeiss, 1; oil immersion, 1/12. *a*, normocyte; *b*, megalocyte; *c*, microcyte; *d*, marked poikilocytosis; *e*, megaloblast; *f*, polymorphonuclear neutrophilic leucocyte. (After *Lenhartz-Brooks.*)

Fig. 2.—Splenomyelogenous leukemia. Young man with enormous spleen tumor. Triacid stain. Zeiss, 1; oil immersion, 1/12. *a*, normal; *b*, nucleated erythrocytes, nucleus partly eccentric; *c*, polymorphonuclear neutrophilic leucocyte; *d*, eosinophilic myelocyte. The upper eosinophilic cell bursted, the granules dispersed. (After *Lenhartz-Brooks.*)

Fig. 3.—Splenomyelogenous leukemia; man aged 34 years with marked spleen tumor. Eosin-hematoxylin stain. Zeiss, 1; oil immersion, 1/12. *a*, normocyte; *a1*, megaloblast; *a2*, megaloblast with anemic degeneration; *b*, polymorphonuclear leucocyte; *c*, myelocytes; *d*, large lymphocyte. (After *Lenhartz-Brooks.*)

Fig. 4.—Acute leukemia. The pictures are from two different cases running a rapidly fatal and clinicly similar course. In the upper half is shown staining with Ehrlich's eosin-hematoxylin mixture; lower half, Plehn-Chenzinsky stain. (After *Lenhartz-Brooks.*)

Fig. 5.—Myeloid leukemia; man aged 40 with enormously enlarged spleen. Jenner's stain. *a*, nucleated red blood-cells; *b*, small lymphocytes; *c*, mast cells; *d*, cells with double granulations; *e*, eosinophilic cells; *f*, large mononuclear neutrophilic cells; *g*, large mononuclear cells without especial granulations. × 450. (After *Lenhartz.*)

Fig. 6.—Hemin crystals from dried blood-spots. Leitz, 1; Obj., 7. (After *Lenhartz-Brooks.*)

PLATE XII

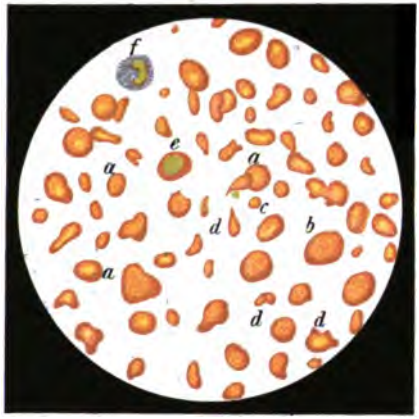

Fig. 1

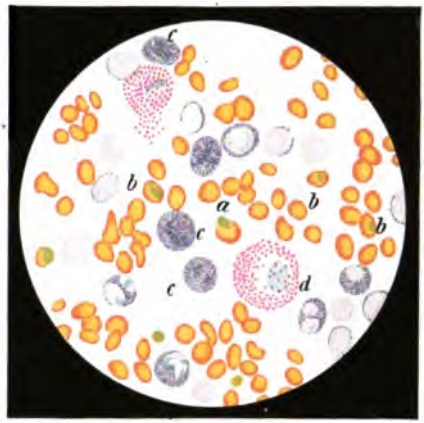

Fig. 2

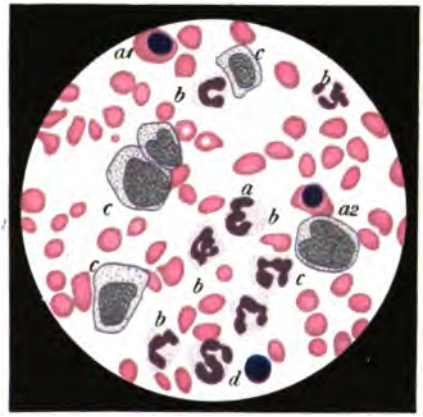

Fig. 3

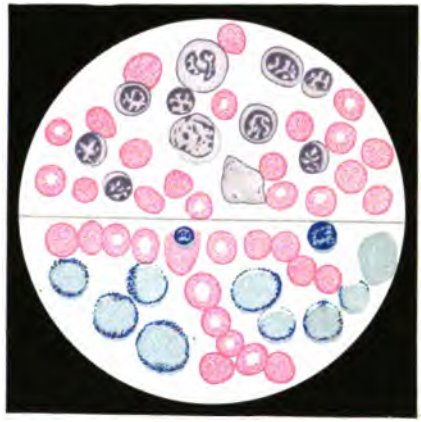

Fig. 4

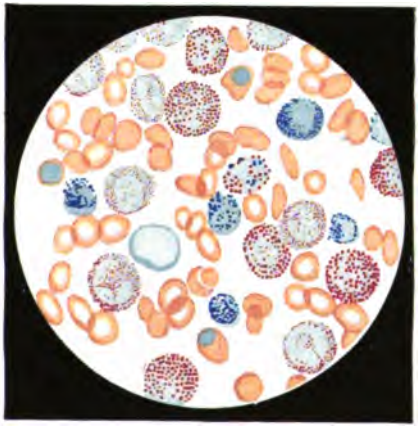

Fig. 5

Fig. 6

cytes (30 per cent.) generally falls to 10 per cent. At the same time the eosinophilic leucocytes diminish in number or disappear. The blood-pressure is increased —even before onset of the chill—and decreases at the acme of the fever.

Buhl's disease is characterized by a symptom triad, first accurately described by Buhl, namely, acute fatty degeneration of all organs, intense icterus, and usually uncontrollable hemorrhage from the navel. Hemorrhages occur also in the form of ecchymoses, gastrointestinal and cerebral bleeding. It differs from Winkel's disease (epidemic hemoglobinuria) by the absence of hemoglobinuria. Both diseases have recently been recognized as severe types of septic infection in the newborn.

Chlorosis,[1] **simple primary anemia,** or **"green sickness,"** the etiology of which is unknown, occurs chiefly in females at the age of puberty, and is usually a transitory condition. There is a slight degree of hydremia, a marked decrease in the relative amount of hemoglobin: olichromemia (usually about 40 per cent. of normal), and, consequently, a decrease in the specific gravity of the blood (average 1.040). In most cases the decided decrease in the amount of hemoglobin is the chief characteristic, the number and form of the red blood-corpuscles being only slightly below normal.

Examination of 700 cases of chlorosis by Otten, in Lenhartz's Hamburg clinic, gave the following:—

The **hemoglobin** content in 700 cases was:—

In	13	cases	(1.8 per cent.)	between	10-20 per cent.
In	86	"	(12.0 per cent.)	"	21-30 per cent.
In	153	"	(22.0 per cent.)	"	31-40 per cent.
In	170	"	(24.0 per cent.)	"	41-50 per cent.
In	142	"	(20.0 per cent.)	"	51-60 per cent.
In	75	"	(10.0 per cent.)	"	61-70 per cent.
In	61	"	(8.0 per cent.)		71 per cent. or over

In severe forms of chlorosis there may be poikilocytosis, and the number of red blood-cells may fall to 2,000,000, the hemoglobin to 15 per cent., and the specific gravity to 1.028. Marked poikilocytosis, however, is usually observed only in the severest forms, in which there is a tendency to thrombosis and a liability to dangerous accidents, such as embolism of the pulmonary artery, sinus thrombosis, etc. Megalocytes—abnormally large, red blood-cells—are relatively frequent, and in a few instances normoblasts and now and then typic myelocytes are observed.

In 151 cases of chlorosis observed by Otten, the following conditions were noted:—

---

[1] χλωρος = green, pale. So-called "Egyptian chlorosis" is due to the *Agchylostomum duodenale*. (See p. 367.)

(*a*) The number of **red corpuscles** was:—

In 1 case		1.5 to 2.0	million
In 18 cases	(12.0 per cent.)	2.0 to 2.5	"
In 22 "	(14.0 per cent.)	2.5 to 3.0	"
In 40 "	(26.0 per cent.)	3.0 to 3.5	"
In 27 "	(17.0 per cent.)	3.5 to 4.0	"
In 28 "	(17.0 per cent.)	4.0 to 4.5	"
In 15 "	(10.0 per cent.)	4.5 to 5.0	"

(*b*) **Poikilocytosis** was observed in 60 cases.

(*c*) **Nucleated erythrocytes** were present in 8 cases.

(*d*) The number of **leucocytes** varied between 4000 and 7000.

(*e*) The **specific gravity** was as low as 1.028 in the severest cases.

The decrease in the number of the red blood-cells is not due to especial frailty of the elements, but probably to early (perhaps congenitally) established insufficiency of the hematogenous organs, which are unable to meet the increased demands of evolution at the period of puberty. The condition frequently is associated with hypoplasia of the heart and arterial vascular system, and sometimes of the genital organs. (See p. 48.)

A similar oligemic condition, namely, **simple secondary anemia,** may also be acquired as a result of defective assimilation and increased waste in a great variety of diseases, *e.g.*, in all chronic affections associated with cachexia (carcinoma, tuberculosis, syphilis, bone suppurations, prolonged lactation, malaria, chronic nephritis, etc.). The blood alterations depend upon the nature and duration of the primary affection. Almost always there is diminution in the number of the red blood-cells and a corresponding decrease in the amount of hemoglobin. The form of the erythrocytes is generally unaltered; occasionally, however, decided poikilocytosis and the occurrence of nucleated red cells are observed, in which instance it may be a question whether the diagnosis of simple secondary anemia should not be rejected. Transition into the chronic pernicious form unquestionably occurs. In contradistinction to chlorosis and pernicious anemia, the number of leucocytes is often considerably increased. In some instances the blood changes are so marked as to cause confusion with pernicious anemia. According to Lenhartz, if leucocytosis is present and the nucleated erythrocytes are chiefly of the normoblast type, the secondary form of anemia may generally be assumed to exist.

Progressive essential anemia, of the Germans, *anæmia progressiva perniciosa* (Biermer), **Addisonian anemia.**—When the anemia is of higher degree and assumes a more independent character, so that the amount of blood no longer suffices to supply the tissues with nourishment and oxygen, the condition is designated as **pernicious anemia.**

(See p. 48.) This always has a progressive character. The red blood-corpuscles present the most varied forms and differences in size (macrocytes or megalocytes, microcytes and poikilocytes). The pernicious sequelæ consist principally of retrogressive fatty metamorphosis of the organs with disposition to hemorrhages. The fatty metamorphosis of the heart (myocardium) finally ends in death. Pernicious anemia may be the result also of repeated severe hemorrhages, particularly if, in the intervals of the individual hemorrhages, insufficient time has elapsed to compensate for the loss of blood by new formation.

The blood is normal in color or strikingly pale, but sometimes darker than normal, like weak coffee, or even tar colored. It is often very thin, so that it does not spread into a thin layer and dry upon the preparation-glass so well.

The number of erythrocytes is always diminished, often to an astonishing degree. Figures of from 400,000 to 800,000 are by no means rare. Quincke counted in one case only 143,000 as the minimum limit. On the other hand, the number of leucocytes remains normal, an increase being very rare.

The total hemoglobin content is reduced to 15 or even 12 per cent., but that of the individual corpuscles is not; indeed, it is not rarely increased in the latter, as is at once apparent by comparison of the figures giving in percentage the diminution in the number of erythrocytes and hemoglobin. For example, the number of red blood-corpuscles may be as low as 16 per cent., while the hemoglobin content is only as low as 20 per cent.

Microscopic examination generally shows an enormous poikilocytosis, slight tendency to the formation of rouleaux, frequent microcytes, and strikingly numerous megalocytes, and usually, also, nucleated red blood-cells. Very frequently the cells are imbedded in a pale, homogeneous (albumin?) layer, such as is otherwise not observed in stained dried-blood preparations.

In the microscopic diagnosis of pernicious anemia Lenhartz considers the excessive occurrence of abnormally large red blood-corpuscles of chief importance. A point of importance in the differential diagnosis between essential anemia and that form secondary to a malignant neoplasm is that, in the latter, the multinucleated leucocytes are in the majority of instances increased, while in the former they are rather diminished. There are exceptions, however.

Hayem always found the blood-plates greatly reduced in number, and often entirely absent. If this is found to be the rule, it might offer an explanation for the constant reduced tendency of the blood of pernicious anemia to coagulate.

Nucleated red blood-corpuscles, often of unusually large size, occur either in small or large numbers, and are but rarely absent. According to Lenhartz, anemic degeneration is rare. The behavior of the eosinophiles is wholly uncharacteristic; diminution as well as slight increase may be observed; complete absence appears to be a very unfavorable prognostic sign. Nucleated red blood-cells may occur in all severe anemias. Ehrlich ascribes an important rôle to their size; according to him, the presence of normoblasts permits a more favorable prognosis, since they are to be interpreted as an indication of an increased production of normal elements from the bone-marrow. The prominent part played by the bone-marrow in the formation of blood has been established by Neumann and Bizzozero. In severe anemias there is more or less advanced transformation of the yellow, fat bone-marrow into red bone-marrow. In this way an increased regeneration of the more readily destroyed red blood-cells is secured. From this point of view it might be assumed that the absence of nucleated red blood-cells is an indication of the nonoccurrence of the significant transformation into red marrow. This, however, is not in harmony with facts. The most advanced metamorphosis of the bone-marrow into a uniform, red, gelatinoid mass repeatedly is found in cases in which the most careful examination of blood preparations shows not a single nucleated red blood-corpuscle.

According to F. Berger,[1] it is justifiable to regard pernicious anemia as due to chronic catarrhal inflammation of a portion of or the whole gastrointestinal mucosa, in the course of which a markedly hemolytic lipoid substance is developed. So long as the bone-marrow, by increased formation of blood, can keep pace with the progressive destruction of red blood-corpuscles in the blood channels, the blood remains unaltered; with occurrence of insufficiency of the bone-marrow, however, in the earlier or later development of which the disposition of the affected individual and coexistent diseases are of importance, pernicious anemia develops.

In **aplastic anemia,** the cause of which is unknown, there is atrophy of the bone-marrow and consequent inability of regeneration of erythrocytes. In some cases complete lack of the parenchyma of the bone-marrow has been noted; in others only the erythroblastic tissue is lacking, while the leucocytic cell types are present or even markedly increased.

Splenic anemia (Banti's disease) is an affection characterized by splenomegaly, anemia, leucopenia, and later by cirrhosis of the liver and ascites. The etiology is obscure. Banti does not regard it as due to either syphilis or malaria. De Marchis[2] believes it is infectious in origin. He has tabulated 25 cases studied clinicly and pathologicoanatomicly and finds

[1] Reichs-med. Anzeiger, No. 9, 1910.
[2] Riv. crit. di Clin. med., 1909, x, p. 701.

PLATE XIII

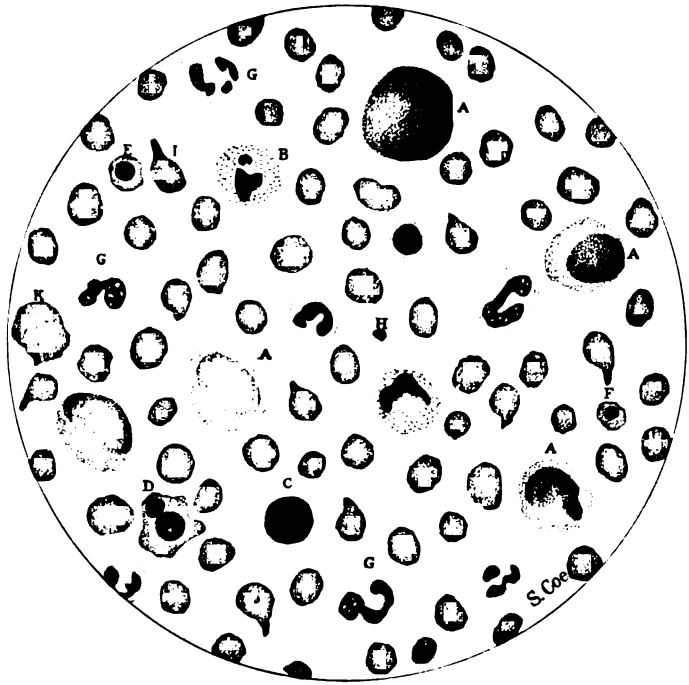

Myelogenous leukemia. *A*, myelocyte; *B*, polynuclear eosinophile; *C*, large lymphocyte; *D*, megaloblast; *E*, normoblast; *F*, microblast; *G*, polynuclear leucocyte; *H*, microcyte; *I*, poikilocyte; *K*, megalocyte with basophilic granules.



Lymphatic leukemia. *A*, polynuclear leucocyte; *B*, large lymphocytes; *C*, normoblast; *D*, eosinophilic polymorphonuclear leucocyte; *E*, small lymphocytes; *F*, megalocytes.

that, while 15 of these cases gave no history of any previous infectious disorder, 10 did—though in all the connection was remote. In 19 additional cases studied clinicly, only 7 gave previous history of infectious diseases. He also examined the blood for hemolysins, but found neither auto- or iso- hemolysins in either blood taken from a vein in the arm or in that expressed from the spleen after removal. He examined the blood by the method of deviation of complement, but the result was negative, and it was negative also when the antigen used was an alcoholic extract of a liver from a case of hereditary syphilis. He points out the fact that the splenomegaly precedes the anemia, and is unable to explain the leucopenia or the eosinophilia which also is present. The affection has successfully been treated by extirpation of the spleen. Von Jaksch states that Banti's disease may be caused by lues, tuberculosis, gout, and protozoal infection. Schmitt[1] describes an exactly similar condition due to congenital syphilis. Therefore, in those cases giving a positive Wassermann reaction, it is advisable to employ antisyphilitic treatment before resorting to splenectomy.

Certain poisons, so-called **blood poisons**, produce disturbances of function by chemic alteration of the true respiratory substance, namely, the red blood-corpuscles. The altered blood-corpuscles are then incapable of taking up or giving off oxygen. Here, for example, belong hydrocyanic acid and carbonic oxide gas (carbon monoxide hemoglobin). Other poisons cause more or less visible alterations or destruction of the red blood-corpuscles: hemoglobinemia, or melanemia, or methemoglobinemia. (See Poisoning, p. 315, and Hematic Pigment, p. 133.)

Basophilic granulation, or degeneration or granular stippling of the red blood-corpuscles, first described by Grawitz in cases of pernicious anemia, is manifested by the appearance within the red blood-cells of blue granulations after staining with polychrome methylene-blue. They are observed in many intoxications (severe anemias and leukemias), and occasionally also in normal blood, but particularly in lead poisoning, in which condition they are regarded as of decided diagnostic value. (See p. 327.)

The interpretation of basophilic granulation is still a mooted question. Blood-cells showing this change may probably be regarded as indications of a pathologic regeneration—an abnormal reaction of the bone-marrow. They may be seen in every anemia and occasionally also in chlorosis. Basophilic granulation and polychromatophilia (see p. 682) very probably belong together.

Irregular or diffuse, dirty-bluish or brownish coloration of the red blood-corpuscles, due to lack or deficiency of the acidophile property of

[1] Münch. med. Woch., 1911, No. 12.

the normal cells and increased affinity for basic dye, is called polychromatophilia. It is observed in various anemias, malaria, leukemia, etc. The **blood-plasma** possesses the property of coagulating outside the vessels and, with the exception of the capillary blood, also within the vessels after death.

The process of **coagulation** is connected with one of the fluid constituents of the blood: the fibrin. Coagulation is divided into two acts: at first a gelatinous, colloid mass analogous to that composing urinary tube-casts develops by "clotting" of the fluid drop. The colloid, hyaline, glassy state may persist, *e.g.*, in pleuritis, or pass on to the second or true coagulation stage. This consists of the formation of a fibrin reticulum and the separation of fluid (serum) by gradual contraction of the fibrillated fibrin. A characteristic feature of the fibrin fibrillæ is that they do not contract in one direction only, as is usual with connective-tissue fibrillæ.

Coagulation of fibrin varies within quite wide limits; it sometimes occurs early, sometimes late and slowly. It may be delayed or entirely prevented by the addition of salts. It is almost totally absent after death only under certain conditions, namely, in asphyxia, in certain poisonings (prussic acid, sulphureted hydrogen, alcohol, etc.), and sometimes in infectious diseases. If coagulation occurs within the vessels during life, this gives rise to thrombosis. (See p. 72.)

Hyperinosis.—The amount of fibrin in the blood is increased in many local inflammatory processes. As soon as very much fibrin is formed in an inflamed organ (*e.g.*, in erysipelas, pleuritis, or fibrinous pleuropneumonia), a portion enters the lymph and then the blood. This portion constitutes, in a measure, an excess of the fibrin produced in a given locality from the (connective) tissue, for the removal of which the lymph circulation does not suffice. Increase of fibrin (hyperinosis), therefore, depends upon a local disorder, and usually is the greater the more richly the affected organ is supplied with lymph-vessels. From this it also follows that a fibrinous exudate cannot originate simply as the result of transudation of fibrin from the blood, but that an antecedent local alteration of the tissue always is present. Enormous fibrin coagula are often found *post mortem*.

Hypinosis, or decrease in the fibrin content of the blood, occurs in typhoid fever, and poisoning by carbon dioxide (in suffocation) and monoxide and sewer-gas, hydrocyanic acid, in hemophilia, etc.

In **hydremia** the watery constituent is increased. It occurs temporarily in posthemorrhagic anemia, as a result of rapid regeneration of the watery constituent, and as a permanent condition in nephritis, hepatic and cardiac disease, and cachectic states.

Anhydremia, a relative diminution of the salts and watery constituents of the blood, is observed in cholera nostras and especially in Asiatic cholera. The blood becomes inspissated like tar.

Hyperalbuminosis is a relative increase of the albumin content of the blood (*e.g.*, in cholera).

Hypalbuminosis is the corresponding diminution, due to increased consumption or diminished supply of proteid or both.

In **plethora vera** (polyemia), or increase in the total volume of blood, the amount of hemoglobin and the number of red blood-corpuscles are generally increased. It may occur as a result of hypernutrition, and in connection with idiopathic hypertrophy of the heart.

Splenomegalic polycythemia with **cyanosis,** Vaquez's disease, erythrocythemia, erythremia, is a chronic affection characterized by splenic enlargement, cyanosis, and very marked increase in the number of red blood-cells (polyglobulism). The bone-marrow at necropsy shows a high degree of hyperplasia.

Polycythemia (polyglobulism), increase in the number of red blood-corpuscles (8,000,000 to 13,000,000 pro c.mm.), occurs as the result of physiologic influences (*e.g.*, high lands) as well as in pathologic conditions, under which a secondary and a primary form may be differentiated. The secondary form is observed in circulatory disturbances, cardiac lesions, emphysema, etc. As an apparently primary affection it occurs in two forms: as **Vaquez's disease** (*polycythæmia megalosplenica*), characterized by increase of the number of erythrocytes, cyanosis, and spleen tumor, and as **Geisbock's disease** (*polycythæmia hypertonica*), characterized by increase in the number of red blood-cells and augmented blood-pressure. In the splenomegalic form a high degree of hyperplasia of the bone-marrow is observed. According to Senator,[1] about 50 cases of splenomegalic polycythemia and about 12 cases of pure hypertonic polycythemia have thus far been recorded. In the course of one year, however, Stähelin,[2] out of 4000 to 5000 patients, observed 7 cases of hypertonic polycythemia and 4 cases complicated with emphysema, cardiac lesions, severe arteriosclerosis, or nephritis. No doubt many cases of Geisböck's polycythemia, especially those of mild degree, are either overlooked or not recorded. Many mild cases of polycythemia may progress without splenic tumor or augmented blood-pressure. In low lands patients showing 6,000,000 erythrocytes pro c.mm. may be regarded as subjects of polycythemia.[3]

Oligemia, or acute anemia, occurs immediately after severe loss of blood, as in traumatic, typhoid, or post-partum hemorrhage. In healthy individuals, compensation of a single and even quite severe loss

---

[1] Polycythämie und Plethora. Hirschwald, Berlin, 1910.

[2] Berlin. klin. Woch., Jan. 16, 1911, p. 101.

[3] According to Sahli and Sörenson, the number of red blood-corpuscles pro c.mm. in healthy women is 5,000,000, in healthy men 6,000,000. These figures, however, usually apply to young individuals. The high figures given by Sahli may be accounted for by the fact that his observations were made at an altitude of 550 meters (Bern).

of blood usually takes place in a remarkably short time, often within a few hours; in very severe hemorrhages (traumatic) within a few days, the lymph-vessels supplying fluid in increased quantity. As after hemorrhage the fluid constituents are regenerated more rapidly than the red elements, a temporary state of h y d r e m i a occurs, and, consequently, the blood is relatively poor in red blood-corpuscles (oligocythemia).

Chronic anemia is always associated with qualitative changes in the blood. (See Secondary Anemia, p. 678.)

Hemophilia, "bleeders' disease," congenital hemorrhagic diathesis, is inherited and of rare occurrence. It occurs principally in males, but is transmitted chiefly through the female members of a family. Sons of daughters whose fathers were bleeders most readily inherit the disease. The affection is characterized by the severe and even fatal hemorrhage occurring after slight injuries, which is attributed to defective coagulability (hypinosis) of the blood; a tendency of the vessels to rupture is also supposed to be responsible. (See p. 63.)

In **gout** (u r a t e m i a) an accumulation of uric acid, and in **diabetes mellitus** an increase in the sugar content of the blood is demonstrable.

After each meal the thoracic duct empties chyle into the blood circulation: **chylemia.** The fat-granules can, as a rule, still be demonstrated between the mouth of the duct and the lungs after death; from this point onward they are indistinguishable. Probably the fat is saponified by the free alkali of the blood. Sometimes, however, the condition of milky blood occurs also in the intervals of digestion (in pregnant and puerperal women, also in fasting) as a result of deficient saponification or combustion of the fat (perhaps owing to absence of free alkali, or as a result of respiratory disturbances). A large amount of fat is often found in the blood in *diabetes mellitus* and in severe congestion, especially that due to valvular lesions, in the absence of any definite explanation for the origin of the fat: **lipemia.** Upon the basis of histologic findings, Graupner[1] claims that the fat in the blood in lipemia is derived from the adipose tissues of the body.

Presence of Foreign Substances in the Blood.

Aside from the chyle, **fat** enters the blood as a foreign constituent under the following conditions: First, as the result of emptying of an atheromatous focus in a large artery; second, in extensive injuries (fracture of bones, crushing of adipose tissue, etc.), a great number of fat-cells being destroyed and the liberated fat-droplets entering

[1] Wien. klin. Woch., 1910, No. 36, p. 565.

the lacerated veins, and, third, in eclampsia. As in the latter condition small lesions are constantly present, a traumatic origin must be assumed to be the correct etiology here also. Fat may occur in the blood also in severe cases of diabetes, in which condition it may amount to 20 per cent. If the droplets of fat are few in number, they are soon consumed (saponified) in the blood without exerting any injurious effects; if, however, they are very numerous, interruption of respiration may occur as a result of obstruction of a large portion of the pulmonary vessels (fat-emboli), or edema of the lungs may supervene from collateral fluxion.

In its action **atmospheric air** possesses a certain similarity to fat. If small air-bubbles enter open vessels (at operations, venesection, etc.), they are rapidly and tracelessly absorbed by the blood; on the other hand, if a large amount of air gains admission, a foamy mass, which the heart cannot expel, forms in the right ventricle. In this event the proper supply of blood to the lungs is cut off and death by asphyxia results.

Foreign **cellular elements** enter the blood only after injuries or alterations of the vessel walls. For example, abscesses may break through the vessel walls and discharge their contents into the blood-channels. This is not the usual process, however. As a rule, thrombosis occurs before rupture takes place. Malignant tumors, especially chondroma and mixed tumors, not infrequently grow into the vessels, under which circumstances single cells may become detached and the tumor germs be conveyed by the blood to distant regions. This is not a very uncommon mode of metastasis formation. In women who have recently been confined, decidual cells are invariably found in the blood-vessels of the lungs, and in subjects of eclampsia liver-cells frequently are observed in the lungs.

In an analogous manner the blood serves as a means of transport in so-called **lime metastases.** If large masses of bone are rapidly absorbed by tumors, the blood usually becomes overladen with lime-salts, and when these cannot be excreted rapidly enough through the kidneys (*e.g.*, as a result of nephritis) they are deposited within the renal tubules and in distant parts of the body. The stomach and lungs appear to be especially disposed to these metastatic lime deposits, for it is in just these localities that calcareous metastases are most frequently found.

In long-continued internal employment of **silver-salts,** separation of reduced (metallic) silver occurs within the glomeruli. (See p. 94.) This could have been brought to these parts only by the blood-current; consequently, the silver-salts must have been retained in the blood for some time in an as yet unknown modification.

It may also be assumed that certain **pigments,** *e.g.,* carbon pigment in the spleen, have been transmitted in a similar manner and under especial conditions from the lungs to the Malpighian corpuscles of the spleen by means of the blood: secondary anthracosis.

In **melanemia,** which is observed only as a result of pernicious malaria, small granules and large agglomerations of pigment may be found in the blood either during or long after the attack.

Absorption of **bile** by the blood (see p. 135) is better known and more easily followed. In adults, only dissolved bile-coloring matter is observed in the tissues, while in the newborn, in addition to small crystalline needles, small rhombic crystals of bilirubin also have been found. Excretion of bile-coloring matters occurs in the urine.

Lower **animal** and **vegetable organisms** are occasionally observed as foreign elements in the blood. Among the animal organisms the most frequent are the hemamebæ of intermittent (malarial) fever; of the trematodes, *Schistosomum hæmatobium* (Bilharz), occurring in Egypt (causes hematuria and chyluria; see p. 375); of the roundworms, *Filaria sanguinis hominis,* in the tropics (causes chyluria), and temporarily also cysticerci of *Tænia solium* and echinococcus of *Tænia echinococcus.* (For trypanosomes and spirochæta of syphilis, see pp. 394 and 543.)

Of the lowest vegetable organisms, the first to be observed was the *Spirochæta obermeieri,* which was seen by Obermeier in the blood during an attack of recurrent (relapsing) fever. (See p. 503.) Since then the number of bacteria which have been demonstrated in the blood has enormously increased. Almost all known pathogenic micro-organisms have been found in the blood, partly free in the plasma, partly within the colorless corpuscles.

All these pathogenic micro-organisms invariably enter the blood from some focus of disease, and, as a rule, in such a manner that a continuous accretion occurs. In addition, the metabolic products of the micro-organisms also are introduced. When a pure culture of pathogenic micro-organisms is injected into the blood-vessels of a healthy animal, these microbes are rapidly eliminated without the occurrence of disorder. Something more than the simple presence of a micro-organism —usually a *locus minoris resistentiæ*—is always required for the development of disease. (See remarks on the infectious diseases, p. 427 *et seq.*)

LYMPH.

The lymph consists of the lymph-cells, already spoken of in connection with the blood, and of the lymph-liquid. The latter, like the

blood-plasma, possesses under certain circumstances the property of coagulation; but the coagulation differs very markedly from coagulation of the blood in that it never occurs within the lymph-vessels after death. The lymph, therefore, behaves like the capillary blood. It contains no fibrin, but only fibrinogen substance. This substance is continuously supplied to the blood with the lymph and then, under certain conditions, is transformed into fibrin. The fibrinogen substance of normal lymph is sometimes found in exudates, *e.g.*, pleuritic exudates. These, like the lymph-liquid, coagulate only after evacuation and on contact with the air.

The lymph coagulates also within the lymph-vessels under pathologic conditions, *i.e.*, when it has been altered by a diseased organ. This is the case, for example, in lymphangitis, and often to a very marked degree in board-hard phlegmon (woody phlegmon).

In all infectious processes, especially the phlegmonous, lymph thrombosis is a relatively favorable event, in that it checks farther extension of the process in the direction of the lymph-stream. The lymph-vessels form, as it were, the natural routes by which infectious germs are transmitted, since they stand in direct and open union with the tissues, and in infections they take up vitiated juices and infectious germs and transport them to neighboring lymph-glands. Besides coloring matters (*e.g.*, tattooing), micro-organisms, coal-dust (in the lungs), fat (in traumatism), red blood-corpuscles, etc., tumor-cells, owing to their great frequency, must also be mentioned as foreign admixtures of the lymph. Carcinomata especially manifest a marked disposition to grow into the lymph-vessels and to distribute germs with the lymph-stream to the nearest lymph-glands, or gradually to fill the lymph-vessels themselves with tumor-cells (*e.g.*, in the pleura and peritoneum), and thus transform the lumina into solid cancer-cell cords.

HEMATOPOIETIC ORGANS.

SPLEEN.

THE spleen is a quite soft organ which can very readily be crushed by incautious pressure. Size, form, and internal arrangement are subject to individual variations. The following constituents must be distinguished:—

1. Capsule: of connective tissue.

2. Trabeculæ: connective-tissue bands[1] as continuations of the capsule into the interior.

3. Pulp: consisting of pulp-cells and a small amount of yellowish-red basement substance within a fine reticulum.

4. Follicles: located in the adventitia of the smallest arteries.

5. Vessels.

The capsule is a connective-tissue membrane which sends bands (trabeculæ) into the interior and, consequently, is in continuous union with the latter and cannot be stripped off as can the capsule of the kidney.

The connective-tissue trabeculæ form a framework, *i.e.*, unite the spleen capsule with the vessels.

The gray-white or milk-white Malpighian corpuscles or follicles are seated upon the smallest arteries, in a measure as deposits within the adventitia. They occur partly isolated, partly in small groups, and are subject to individual variations in number and size.

The reticular connective tissue, the meshes of which are filled with lymph-corpuscles, forms in the periphery of the follicles a dense reticulum which is continuous with the reticulum of the pulp. Consequently, a follicle cannot be lifted out as a whole, as is the case with a tubercle; on incision the follicle is cut through, while a tubercle is usually pushed aside and afterward protrudes.

The arteries are characterized by an especial arrangement: thus, from every small branch arise a large number of terminal branches (penicilli) which have a certain resemblance to the hairs of a brush. These penicilli break up into capillaries in the pulp. From these the blood flows into the comparatively wide, cavernous veins. It is doubtful whether the pulp comes in direct contact with the circulating blood. It is often assumed that there is a portion within the spleen where the

[1] These contain also smooth muscle-cells.



Fig. 347.—Vertic section of a small superficial portion of the human spleen, as seen with a low power. *A*, peritoneal and fibrous covering; *b*, trabeculæ; *c*, *c*, Malpighian corpuscles, in one of which an artery is seen cut transversely, in the other longitudinally; *d*, injected arterial twigs; *e*, spleen-pulp. (After *Kölliker.*)

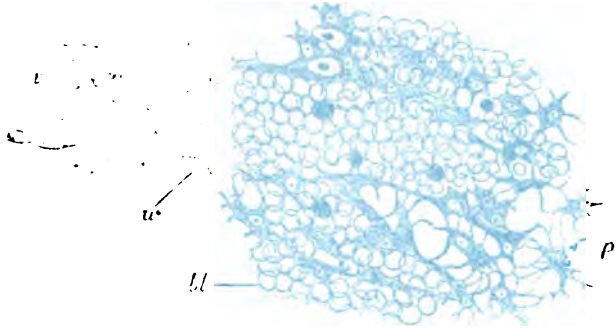

Fig. 348.—Thin section of spleen-pulp, highly magnified, showing the mode of origin of a small vein in the interstices of the pulp. *v*, the vein, filled with blood-corpuscles, which are in continuity with others, *bl*, filling up the interstices of the retiform tissue of the pulp; *w*, wall of the vein. The shaded bodies among the red blood-corpuscles are pale corpuscles. (After *Schaefer.*)

vessels lose their walls and the blood must circulate through the pulp. Hence, the conception that the spleen has no capillaries still exists. One can readily be convinced of their presence by examination of the spleen in amyloid degeneration of the pulp, because in this condition they are especially and distinctly manifest. It is quite possible, however, that a kind of interruption exists between the capillaries and the next larger vessels.

In addition to the reticulated connective tissue already mentioned and the ever-present blood constituents, the pulp is composed of a yellowish-red basement substance and the pulp-cells; the latter are large, mononucleated cells with single, granular nucleus and nucleolus.

Lymph-vessels do not traverse the pulp, but only the capsule of the spleen, in the trabeculæ and in the vessel-sheaths.

By contact with the pulp the blood is freed—as it were, filtered—from all possible foreign admixtures. This is the reason why the spleen is altered in all diseases in which injurious substances enter the blood (aside from the intoxications in a strict sense), particularly in almost all febrile infectious diseases. The injurious substances, especially bacteria, are retained in the spleen, and produce acute hyperplasia of the adjacent pulp-cells. This is a form of metastasis.

The hyperemia, which is always demonstrable at first, does not constitute the essential element of the swelling; indeed, in the higher grades of acute infectious spleen tumor it always disappears to give place to a pronounced anemia. That the spleen, nevertheless, does not appear decolorized, but retains a grayish-red color, is due to the fact that the pulp itself has a yellow-red color. Even in the most intense degrees of anemia, also without tumefaction, *e.g.*, in pernicious anemia, in death from acute hemorrhage, in cachexia, the spleen pulp always has a reddish color, never a gray hue, just as skeletal muscle, in complete anemia, retains its natural red color.

Every enlargement of the spleen, whether it develops rapidly or slowly, or is of short or long duration, is designated as **spleen tumor.** The enlargement is always due primarily to increase of the pulp, even in the chronic forms of spleen tumor. In so-called acute swelling, **acute spleen tumor,** hyperplasia of the pulp-cells occurs in a short time; consequently, the capsule is always very tense, the points of insertion of the trabeculæ into the capsule appearing like punctiform depressions. If the organ is incised, the creamy, reddish-gray pulp wells up upon the cut surface in a characteristic manner, owing to retraction of the tensely stretched trabeculæ. In this stage the spleen possesses an extreme degree of "friability"; it tears on the slightest careless manipulation. The follicles are usually not involved;

in some cases (*e.g.*, in scarlatina, typhoid), however, they are intensely altered and, as a result of enlargement, appear as distinct whitish spots.

Sometimes the alteration advances to inflammation, so that smaller or larger portions of the spleen die, a reactive, dissecting, purulent inflammation developing in the neighborhood: *splenitis lobularis* (*e.g.*, in scarlatina, typhoid, etc.). As the capsule also is involved in the necrosis, an adhesive inflammation very soon develops in the neighborhood, whereby, as a rule, the rare occurrence of exfoliation of the necrotic tissue into the abdominal cavity is avoided. If partial adhesive peritonitis cannot develop rapidly enough, general purulent or ichorous peritonitis always occurs.

When the irritation-causing acute spleen tumor repeatedly recurs (in malaria, cirrhosis of the liver, pulmonary phthisis), or when a more chronic irritation results in spleen tumor (frequent in syphilis), the swelling is usually accompanied by induration due to new formation of reticular connective tissue, of trabeculæ, and of the vessel-sheaths. In this case the cut surface is smooth, no pulp protrudes, and the color is sometimes more dark red, sometimes more pale gray-red, not rarely somewhat mottled, according to the amount of blood present; the consistency is doughy or firm, so that the spleen withstands somewhat rougher manipulation. If the swelling increases more and more (in malaria), the spleen becomes gradually harder and acquires a fleshy character. Another affection which occurs in congestion in the region of the portal vein should not be confused with this condition.

The cause of the congestion may be an affection of the lungs (emphysema) or of the heart (particularly mitral stenosis and lesions of the aortic orifice). In consequence of chronic congestion moderate enlargement of the spleen occurs through dilation of the vessels, especially the veins, and through increase of the connective-tissue structures: of the reticulum, of the vascular sheaths, trabeculæ, and capsule. The consistency of such a spleen is very firm, often hard; the cut surface is quite smooth and dark red to blackish red in color. Trabeculæ and follicles are generally very distinctly recognizable.

In **embolic** processes the **blood-infarcted area** has a wedge-shaped (pyramidal) form, corresponding to branchings of the arteries. The embolus is located at the apex, which is directed toward the hilus. The size of the infarct varies within wide limits. The fresh infarct is very firm in consistency, has a uniform, somewhat dry, blackish-red cut surface, and forms on the surface a flattened swelling. The termination of the infarct is very variable according as the material contains infectious agents or not. In the latter case the infarcted tissue dies and gradually is absorbed. The infarcted part then grows smaller,

vessels lose their walls and the blood must circulate through the pulp. Hence, the conception that the spleen has no capillaries still exists. One can readily be convinced of their presence by examination of the spleen in amyloid degeneration of the pulp, because in this condition they are especially and distinctly manifest. It is quite possible, however, that a kind of interruption exists between the capillaries and the next larger vessels.

In addition to the reticulated connective tissue already mentioned and the ever-present blood constituents, the pulp is composed of a yellowish-red basement substance and the pulp-cells; the latter are large, mononucleated cells with single, granular nucleus and nucleolus.

Lymph-vessels do not traverse the pulp, but only the capsule of the spleen, in the trabeculæ and in the vessel-sheaths.

By contact with the pulp the blood is freed—as it were, filtered—from all possible foreign admixtures. This is the reason why the spleen is altered in all diseases in which injurious substances enter the blood (aside from the intoxications in a strict sense), particularly in almost all febrile infectious diseases. The injurious substances, especially bacteria, are retained in the spleen, and produce acute hyperplasia of the adjacent pulp-cells. This is a form of metastasis.

The hyperemia, which is always demonstrable at first, does not constitute the essential element of the swelling; indeed, in the higher grades of acute infectious spleen tumor it always disappears to give place to a pronounced anemia. That the spleen, nevertheless, does not appear decolorized, but retains a grayish-red color, is due to the fact that the pulp itself has a yellow-red color. Even in the most intense degrees of anemia, also without tumefaction, *e.g.*, in pernicious anemia, in death from acute hemorrhage, in cachexia, the spleen pulp always has a reddish color, never a gray hue, just as skeletal muscle, in complete anemia, retains its natural red color.

Every enlargement of the spleen, whether it develops rapidly or slowly, or is of short or long duration, is designated as **spleen tumor.** The enlargement is always due primarily to increase of the pulp, even in the chronic forms of spleen tumor. In so-called acute swelling, **acute spleen tumor,** hyperplasia of the pulp-cells occurs in a short time; consequently, the capsule is always very tense, the points of insertion of the trabeculæ into the capsule appearing like punctiform depressions. If the organ is incised, the creamy, reddish-gray pulp wells up upon the cut surface in a characteristic manner, owing to retraction of the tensely stretched trabeculæ. In this stage the spleen possesses an extreme degree of "friability"; it tears on the slightest careless manipulation. The follicles are usually not involved;

in some cases (*e.g.*, in scarlatina, typhoid), however, they are intensely altered and, as a result of enlargement, appear as distinct whitish spots.

Sometimes the alteration advances to inflammation, so that smaller or larger portions of the spleen die, a reactive, dissecting, purulent inflammation developing in the neighborhood: *splenitis lobularis* (*e.g.*, in scarlatina, typhoid, etc.). As the capsule also is involved in the necrosis, an adhesive inflammation very soon develops in the neighborhood, whereby, as a rule, the rare occurrence of exfoliation of the necrotic tissue into the abdominal cavity is avoided. If partial adhesive peritonitis cannot develop rapidly enough, general purulent or ichorous peritonitis always occurs.

When the irritation-causing acute spleen tumor repeatedly recurs (in malaria, cirrhosis of the liver, pulmonary phthisis), or when a more chronic irritation results in spleen tumor (frequent in syphilis), the swelling is usually accompanied by induration due to new formation of reticular connective tissue, of trabeculæ, and of the vessel-sheaths. In this case the cut surface is smooth, no pulp protrudes, and the color is sometimes more dark red, sometimes more pale gray-red, not rarely somewhat mottled, according to the amount of blood present; the consistency is doughy or firm, so that the spleen withstands somewhat rougher manipulation. If the swelling increases more and more (in malaria), the spleen becomes gradually harder and acquires a fleshy character. Another affection which occurs in congestion in the region of the portal vein should not be confused with this condition.

The cause of the congestion may be an affection of the lungs (emphysema) or of the heart (particularly mitral stenosis and lesions of the aortic orifice). In consequence of chronic congestion moderate enlargement of the spleen occurs through dilation of the vessels, especially the veins, and through increase of the connective-tissue structures: of the reticulum, of the vascular sheaths, trabeculæ, and capsule. The consistency of such a spleen is very firm, often hard; the cut surface is quite smooth and dark red to blackish red in color. Trabeculæ and follicles are generally very distinctly recognizable.

In **embolic** processes the **blood-infarcted area** has a wedge-shaped (pyramidal) form, corresponding to branchings of the arteries. The embolus is located at the apex, which is directed toward the hilus. The size of the infarct varies within wide limits. The fresh infarct is very firm in consistency, has a uniform, somewhat dry, blackish-red cut surface, and forms on the surface a flattened swelling. The termination of the infarct is very variable according as the material contains infectious agents or not. In the latter case the infarcted tissue dies and gradually is absorbed. The infarcted part then grows smaller,

acquiring more and more a yellow color, and, finally, a retracted scar occupies the place of the infarct. If the infarcts were large, and if, as is often the case, a number of them were present, the spleen may acquire a lobulated form as the result of the formation of multiple cicatrices.

When the emboli contain infectious germs, the events are in accordance with the nature of the infectious agents, *i.e.*, the infarct may develop into a purulent, ichorous, or gangrenous focus. Purulent liquefaction is most frequent; owing to the disintegrated hemorrhagic masses, however, it does not produce pure pus, but a more reddish, yellowish, or brownish-yellow fluid. The extent of this softening is very variable according to the size of the occluded vessel; sometimes almost the whole spleen is destroyed in this manner. In this connection adhesive inflammation or general acute peritonitis may occur, as in *splenitis lobularis.*

Abscesses of the spleen develop also as the result of extension of a suppurative process from parts adjacent to the spleen (after perforating round ulcer of the stomach, paranephritic abscess, etc.), often after adhesion has previously occurred as a result of an adhesive process. As no hemorrhagic processes occur, the pus usually possesses its ordinary character. Occasionally, after antecedent adhesion, a splenic abscess may rupture through the diaphragm into the pleural cavity, into the lung, the stomach, intestine or externally.

Under normal conditions the pulp-cells of the spleen manifest great disposition to take up red blood-corpuscles. Why they do this is not quite clear; it is assumed that the red blood-corpuscles are about to die. Therefore, strictly speaking, the spleen must be classed rather with the blood-depurating or blood-destroying than with the blood-producing organs. Nevertheless, in the absence of any positive knowledge of the function, the spleen is generally classed with the hematopoietic organs, and many physiologic as well as pathologic phenomena speak in favor of this view. First, all affections in which the spleen pulp is permanently affected are associated with marked degrees of anemia and cachexia; second, the spleen contains a very variable number of follicles; third, a more or less large number of colorless blood-corpuscles has frequently been found in the splenic venous blood, and, finally, the peculiar red color of the pulp also speaks in favor of an especial relation to the red blood-corpuscles.

In all processes in which a portion of the red blood-corpuscles is rapidly destroyed (malaria, transfusion of animal blood, etc.), brown blood-coloring matter (hemosiderin) very quickly accumulates in the pulp. Brown coloring matter is observed also in chronic diseases accompanied by atrophy of the spleen; this then produces the condition desig-

nated as **brown atrophy,** in which the spleen is small, the capsule wrinkled, and the cut surface smooth and rusty brown.

Simple atrophy without pigmentation is more frequent. This is almost always found in general anemia resulting from chronic diseases, in cachectic states, and in senile marasmus (here, however, also pigment atrophy). In this case the spleen is strikingly small, very flabby, the capsule wrinkled, and the cut surface pale; the vessels and trabeculæ are unusually distinct, only a small amount of space being occupied by the pulp. The atrophy, therefore, involves chiefly the pulp.

Amyloid degeneration of the spleen is an accompaniment of general cachexia, and occurs principally in chronic bone suppurations, syphilis, and pulmonary consumption, seldomer in carcinoma, malaria, etc. It occurs in two forms: as **sago spleen** and as **bacon spleen.** (See p. 148.) Less frequently the follicles and pulp are amyloid degenerated at the same time. The spleen is always enlarged in this condition.

In jaundice of the newborn (*icterus neonatorum*—see p. 136), needle-shaped and rhombic bilirubin crystals occur in the spleen, while in adults only a more uniform saturation of the fluids, the vessels, and pulp-cells, with dissolved bile-coloring matter, occurs.

Pentastomum, echinococcus, and cysticercus occasionally enter the spleen with the blood-current, and are there retained. (See Animal Parasites, p. 371.)

In marked alveolar emphysema of the lungs metastatic, black lung-pigment is very frequently observed in the spleen, chiefly in the follicular tracts. This is a metastasis in the old sense, in so far as the lung black disappears from the old location (lungs).

Tumor metastases, as well as primary tumors, are rare in the spleen. Most frequent are gumma, sarcoma, fibroma, and angioma.

The **inflammatory alterations of the capsule** are partly exudative or adhesive, partly productive, in nature. An exudative perisplenitis develops after alterations of the spleen itself (infarct, abscess, splenitis lobularis, etc.); also in general peritonitis and as a result of inflammatory changes in neighboring parts, *e.g.*, in left-sided empyema, gastric ulcer, pancreas necrosis, paranephritic abscess, trauma, etc. In accordance therewith sometimes the whole capsule, sometimes only a part thereof, is affected. According to the nature of the process, fibrinous, fibrinopurulent, purulent, and ichorous inflammations are distinguished. The simple fibrinous form leads partly to adhesions with adjacent parts, partly to thickenings of the capsule.

The **productive inflammations** are usually an accompaniment of chronic exudative inflammations, and, therefore, are not always sharply to be separated from these. They usually involve one or

several portions of the capsule, less often the whole capsule, and consist in a gradual thickening of the capsule by deposition of fibrin and connective-tissue proliferations. When these changes occur in many small areas, nodules may develop which have a certain resemblance to tubercles, but which differ from these by their uniform, hard, gray-white character. The more the capsule thickens, the more sclerotic and finally cartilaginous the consistency becomes: *callus fibrosus,* as it is composed of dense, poorly vascular connective tissue. As a rule, the adjacent trabeculæ are involved in the thickening and induration, while the parenchyma atrophies more and more. The indurations may attain a thickness of about 1 cm. Sometimes, but not always, there is an abundant deposition of lime-salts, so that in some cases the spleen finally is incased in a lime shell.

Small **cysts** filled with clear, watery fluid and extending more or less deeply into the spleen substance are sometimes found in the capsule at the sharp edge of the spleen. Nothing certain is known regarding the mode of origin of these cysts. As the capsule is usually thickened, it is probable that they result from portions of dilated or constricted lymph-vessels.

On action of trauma, **rupture of the spleen** (always with laceration of the capsule) may occur, which, owing to the accompanying severe hemorrhage, frequently endangers life. If the hemorrhage ceases in time, healing may occur by cicatrization. Aside from large hemorrhages following serious injuries, hemorrhage in the spleen can only in extremely rare instances be positively diagnosticated. The difficulty lies in the vascular arrangement; under normal conditions, as is well known, there is a portion of the spleen—the pulp—in which a true vascular wall cannot with certainty be traced, where the blood probably comes in immediate contact with the tissue. So long as the blood there remains fluid and is mixed with the true spleen parenchyma, it may with certainty be assumed that hyperemia, and n o t hemorrhage, is present.

LYMPHATIC GLANDS.

The lymphatic glands are small organs introduced in the course of the lymph-vessels and interrupting their continuity. They have a bean-shaped form; the afferent lymph-vessel enters at the convex margin (see Fig. 349), ramifies and emerges on the opposite side—at the hilum. The parenchyma of the lymphatic glands consists of the follicular trabeculæ: cord-like formations which terminate, with a bulbous, rounded swelling, beneath the capsule upon the convex side. These follicles are separated by connective-tissue bands. In the interior of these follicles is

found reticulated connective tissue the reticula of which are filled with lymph-gland cells. The lymphatic vessels lose their walls in the parenchyma, so that the lymph comes in direct contact with the follicular cords. The lymphatic glands are, therefore, in a measure a filter for the lymph.

In the alterations of the blood and of the lymph it was stated that lymph-corpuscles, or colorless blood-corpuscles, are constantly conveyed with the lymph to the blood. After each meal, as well as during pregnancy, the number of these elements increases, the lymph, quantitatively and qualitatively altered by the increased metabolism, physiologicly stimulating the glands.

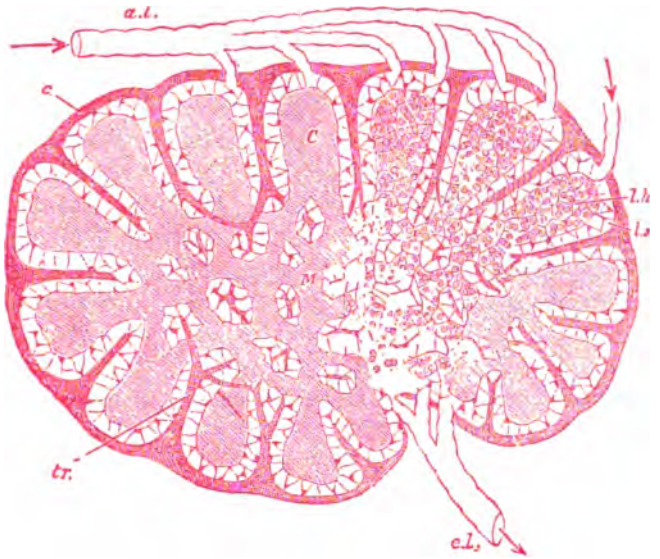

Fig. 349.—Diagrammatic section of lymphatic gland. *a. l.*, afferent, *e. l.*, efferent, lymphatics; *C*, cortic substance; *M*, reticulating cords of medullary substance; *l. s.*, lymph-sinus; *c*, fibrous coat sending trabeculæ, *tr.*, into the substance of the gland. (After *Sharpey*.)

In analogous manner there occurs under pathologic conditions through an inflammatory irritation (of a chemic and mechanic nature) exerted by the altered lymph, **swelling of the lymph-glands** due to hyperplasia of the lymph-corpuscles. This is the case especially in **infectious diseases;** for example, in fibrinous pneumonia, swelling of the bronchial glands is invariably observed; in diphtheria, swelling of the pharyngeal glands; in chancre, swelling of the inguinal glands; in erysipelas and phlegmon of the finger, hand, and arm, swelling of the axillary glands. In typhoid fever the mesenteric glands assume a marrow-like appearance, usually in consequence of intense cellular proliferation.

All these swellings usually disappear, so that the glands completely recover their normal state. In some cases the inflammation increases; the intensely swollen lymph-gland is richly infiltrated with hemorrhages, or a more or less large portion of the gland is transformed into an abscess (*e.g.*, bubo in soft chancre). Sometimes suppuration involves a whole lymph-gland (or several contiguous ones).

These severe forms are quite frequent in marked septic infections, in severe gangrenous diphtheria, in scarlatina, anthrax, and bubonic

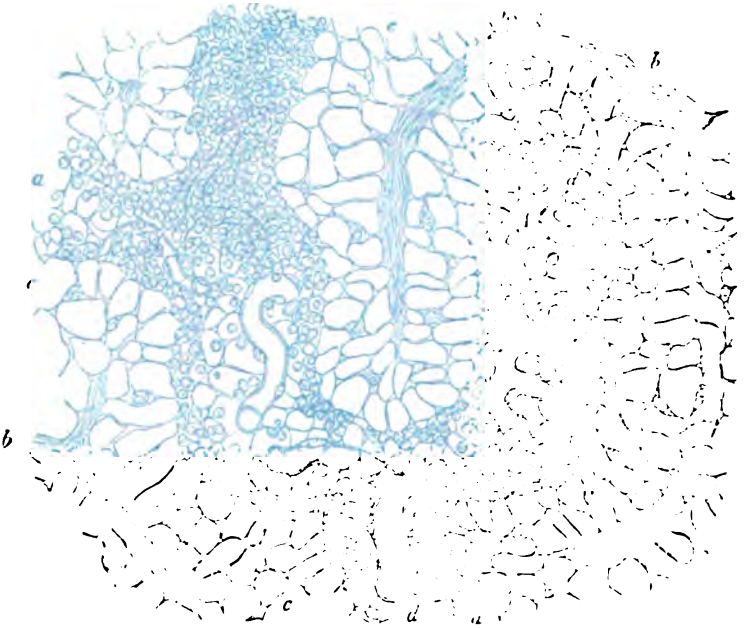

Fig. 350.—Section of the medullary substance of a lymphatic gland. (300 diameters.) *a, a, a,* lymphoid cords; *c,* lymph-sinus; *b, b,* trabeculæ; *d, d,* capillary blood-vessels. (After *Recklinghausen.*)

plague. When the foci are small, they may be confined to their original location, be transformed by inspissation into caseous material, and finally become calcified; larger foci usually have a progressive character, and either extend to the adjacent adipose or connective tissue or, in case they reach a surface (tonsillar abscess, bubo, etc.), burst and discharge their contents externally. The usual termination of medullary swelling in typhoid fever is resolution; the sphacelus almost always involves only small, punctiform foci. Complete or partial caseation of the lymph-glands is pathognomonic of scrofulosis, even though partial resolution follows the primary hyperplastic stage.

Acute inflammatory swelling of the lymph-glands in which the irritation is continuous may develop into a chronic swelling and terminate in fibrous induration. Partial induration originating from the connective tissue is frequently observed after taking up of particles, particularly inorganic substances, *e.g.*, dyes (after tattooing) or stone-dust (chalicosis in stonecutters). One of the most frequent findings is accumulation of coal-dust in the interstices of the bronchial glands: these appear mottled, black, and white, frequently entirely black. Individual lymph-glands sometimes have a yellowish or brownish appearance on incision, due to retention of pigments after hemorrhages into the region of the radicles of the lymph-vessels.

Amyloid degeneration involves the small arteries as well as the parenchyma: the lymph-cells of the follicles. The peripheral lymph-glands are always first involved, then the next following in the direction of the lymph-stream, and so on; in the individual lymph-glands also the peripheral portions at the cortic margin are always first altered. Chronic changes, usually suppurations, are always found in the radicle area belonging to the affected glands. Amyloid lymph-glands are no longer able to supply the blood with lymph-cells: blood-corpuscles; consequently, when many lymph-glands have undergone amyloid degeneration, anemia develops. This distribution of amyloid degeneration of the lymph-glands corresponds in every way with that of tumor metastases in the lymph-glands, and, consequently, justifies the view that amyloid degeneration is the result of deposition of a foreign substance introduced from without in solution. (See p. 146.)

Among the **tumors** occurring in the lymph-glands metastases preponderate. Metastatic carcinoma nodules are most frequent; next follow the soft and the melanotic sarcomata, rarer fibrosarcoma, chondroma, etc. (See Tumors.)

Carcinoma metastases offer an especially good example of the ability of the lymph-glands to act as a filter for the lymph. The nearest lymph-glands frequently become involved very early by taking up and retaining injurious substances present in the circulating lymph, whether these be cellular or fluid constituents, and thus for a time protecting the organism against further metastasis formation. As soon, however, as the carcinoma metastases in the lymph-glands have reached a certain stage of development, the involved glands in their turn form new, independent foci of infection.

Aside from leukemic tumors, principally soft and hard lymphosarcomata, seldomer myxomata and sarcomata, develop from the lymph-glands.

THYMUS.

In structure and partly also as regards its pathologic changes, the thymus is closely related to the lymphatic apparatus. Originally an epithelial organ, the epithelial elements are gradually replaced by ingrowth of lymphoid tissue, until at birth it resembles in structure the spleen and lymphatic glands. Finally, only a few epithelial remnants (the so-called Hassal bodies) remain, all else being displaced by lymphoid tissue. Its behavior is peculiar in so far as it continues to grow only up to the end of the second year of life (according to some authorities, up to the 11th to 15th year), then remains stationary for a

Fig. 351.—Lobule of thymus of a child, seen under low power. *C*, cortex; *c*, concentric corpuscles within medulla; *b*, blood-vessels; *tr*, trabeculæ.

long time and disappears, except for a small remnant, at about the beginning of, or shortly after, puberty, adipose tissue occupying its former site. In some cases the gland does not atrophy, but remains at the acquired state of development without producing any disturbance: *thymus persistens.* In rare instances it may be lacking in the newborn. Accessory thymus glands are not rare.

Knowledge of the true function of the thymus is obscure. By some it is regarded as one of the series of organs which, by elaboration of internal secretions, serve to regulate various functions. That it is an accessory organ is shown by the fact that its function can be performed by others (the spleen, thyroid gland, and testes). Simultaneous removal of the thymus and spleen in animals is said always to cause death. There is evidence to show that developmentally, anatomicly, physiologicly, and pathologicly it is closely associated with the thyroid, and it has experi-

mentally been demonstrated that the thymus is unnecessary to the economy when the thyroid is gone, and when the thymus is removed less thyroid suffices. In cases of Graves's disease, in which the thymus is enlarged, removal of the thyroid is followed by sudden death. In cretins thymectomy reduces the necessity for thyroid secretion.

The state of the thymus depends essentially upon the nutrition of the child. The atrophied gland in emaciation of the child may regenerate on restoration of the body weight. Thymectomy produces an increase in the number of red blood-cells, but no alteration in the form or number of the leucocytes. Injection of thymus extract may cause death of an animal under symptoms of decreased blood-pressure and slowing of the pulse.

Experiments made by H. Klose[1] on dogs have shown that minute remnants of the thymus left after thymectomy suffice for complete regeneration of the organ within a short time. Fourteen days after total removal a *"stadium adipositas"* of from two to three months' duration develops, followed by loss of weight, general bodily weakness, frailty of the bones, arrest of growth in spite of ravenous appetite, and frequently spontaneous fractures. This cachectic stage or *cachexia thymopriva* is accompanied by *"idiotia thymopriva"* with a terminal *"coma thymicum."* In the bones were found associated the signs of rachitis, osteomalacia, and osteoporosis. The bones of the control animals contained 65 per cent. lime-salts, those of the diseased animals only 32 to 34 per cent. In this lime impoverishment the ratio of salts was unaltered. The poverty in undissolved lime-salts was dependent upon increased acid action. The thymus is an organ which inhibits the formation of acids in the organism or neutralizes or masks an excess of acids. The (hypothetic) nucleinic acid intoxication produces in growing bone defective construction, rachitis with abnormal softness and flexibility; in ready-formed bone increased destruction, osteomalacia, and osteoporosis with abnormal fragility. The assumed acid intoxication explains why thymectomized animals cannot be cured with thymus substances, since pathogenic potency is directly added in the nuclein salts.

The thymus gland is subject to great variations in size and shape. In the newborn and small children it sometimes attains considerable dimensions: *hyperplasia thymi,* so that it exerts injurious pressure upon the respiratory organs, vessels, and nerves (*asthma thymicum*), and sometimes may cause sudden death: thymus death. (See Status Lymphaticus.) The hyperplasia acquires a tumor-like character in lymphatic leukemia, in which condition the thymus is involved in childhood as well as in later life, as *thymus persistens.* A hyperplastic *thymus persistens* sometimes gradually develops into lymphosarcoma.

Hypertrophy of the thymus may occur under various forms. It may cause sudden death, or be manifested during a considerable period by more or less intense embarrassment of respiration which suddenly produces such threatening symptoms that, unless appropriate measures are immediately adopted, death may result. Dyspnea and stridor are the chief symptoms of thymus hypertrophy. In some cases persistent cyanosis is observed. There are forms, however, which produce no

[1] Arch. f. Kinderheilk., Bd. 55, H. 1 and 2.

symptoms for a long period, respiratory disturbances occurring only occasionally. In some instances suprasternal and supraclavicular retractions are observed during inspiration, and occasionally symptoms of false croup are present. The general nutritive disturbances which occur must be attributed to insufficiency of air. It is important to note that febrile diseases may reveal a latent thymus hypertrophy, manifested by decided respiratory disturbances; in such cases an acute laryngeal affection, such as croup, may wrongly be suspected. A frequently observed indication of thymus hypertrophy is asymmetric bulging of the right sternocostal region, which in some cases is visible, in others only palpable; likewise an expiratory protrusion of the suprasternal notch. In the latter region the enlarged gland can sometimes directly be felt.

Thymus abscesses (Dubois's abscesses), observed in congenital syphilis, are peculiar cavities filled with leucocytes and surrounded by proliferated epithelia, and are, therefore, not true abscesses. True abscess of the thymus may, however, occur in phlebitis of the umbilical cord and in pyemia. In rare cases tubercles (in general miliary tuberculosis) and gummata are observed in the thymus.

Hemorrhages are observed in poisonings and sometimes in death from suffocation.

Dermoids, lymphosarcoma, carcinoma, and endothelioma are observed, and probably some tumors of the mediastinum originate in this organ. Tumors of sarcomatous nature have been observed also in *myasthenia gravis* (Erb's disease).

Status lymphaticus, or **thymicus**, is a constitutional anomaly, observed in children, in which the thymus, tonsils, prevertebral and mesenteric lymph-glands, and the follicles of the intestine and spleen are extraordinarily strongly developed. It is dependent upon simple hyperplasia of the collective lymphatic apparatus; also defective development (hypoplasia) of the heart and vessels, and, therefore, chlorosis often coexists. An explanation for this is lacking. In advanced cases lymphatic tissue appears to develop in localities where normally it does not occur: *e.g.*, numerous typic lymph-nodes are observed in the bone-marrow. *Status lymphaticus* is almost always associated with hypertrophy of the thymus, *i.e.*, hyperplasia of the medullary substance. Nothing characteristic is found at necropsy. Sudden death often occurs without apparent cause or in the course of simple intercurrent affections. In some cases the trachea shows alterations due to compression by the enlarged thymus. Numerous punctiform hemorrhages are often seen here and there on the pleura and epicardium—appearances suggesting death from asphyxiation. In other cases the trachea presents no alterations. Then there usually is found an often marked dilation and hypertrophy of the left heart, but no alteration of the myocardium. Persistence and hyperplasia of the thymus are quite frequently observed in adults in Addison's and Basedow's disease, in the latter of which affections the thymus generally lies close to the thyroid gland. No especial histologic changes are noted here. Sometimes a large thymus (*thymus persistens*) is observed in advanced age, due to lack of, or defective, retrogression.

RESPIRATORY SYSTEM.

The nasal mucous membrane in the movable parts of the nose is covered with lamellated squamous epithelium, and in the *pars respiratoria* with ciliated columnar epithelium. Likewise, the mucous membrane of the larynx, trachea, and larger bronchi is covered by stratified ciliated epithelium, which is interrupted by mucus-secreting goblet-cells. Only the posterior surface of the epiglottis, the anterior surface of the arytenoid cartilage, and the true vocal cords are covered with lamellated squamous epithelium.

The epithelium of the bronchial mucous membrane (see Fig. 352) gradually loses lamellæ until in the finer branches only a single layer of ciliated epithelium



Fig. 352.—Ciliated epithelium (obtained by careful scraping of the mucosa). × 350. *a*, from a principal bronchus; *b*, from a fine bronchus; *c*, from a bronchiole.

is present, which is continued to the beginning of the bronchioles. The ciliated epithelium, however, gradually passes over into an epithelium composed of a mixture of cubic and large nucleated and nonnucleated cells, which even in the neighborhood of the alveolar ducts consist chiefly of the large, polygonal, flat, so-called respiratory epithelium. It has been found by embryologic research that the epithelium gradually becomes flattened only after respiration has become established. In stillborn children cubic epithelium only is found in the alveoli.

Smooth muscle-fibers accompany the bronchial tubes down to the alveolar ducts and form a delicate ring at the point of origin of the alveoli. Besides these muscle-fibers the wall of the alveolar ducts is rich in elastic fibers, which are arranged as circular fibers and also surround the opening of each alveolus and from there send out branches which support the whole alveolus. By the immediate continuation of neighboring elastic-fiber rings the alveolar septa are formed. The respiratory portions of the lungs are divided by connective tissue into small and minutest lobules; in the interlobular fibrous stroma are found black pigment- and minute carbon- granules, which have been deposited there by respiration and the lymph-current. (Lenhartz-Brooks.)

THE organs of respiration, in accordance with their physiologic principle, have a greater surface development than all other organs.

This is so great in the lungs that the parenchyma in relation to the space which the lungs occupy is extremely small. Hence, the diseases of the lungs also deviate most from the diseases of other organs, while those of the bronchi, trachea, larynx, and nose more closely resemble the changes occurring in other organs covered with mucous membrane.

The nose is the organ which, for its internal lining, first received the name mucous membrane. The true lung-tissue forming the alveoli has no mucous membrane. The alveoli are nothing more than simple excavations in the tissue (comparable to finger indentations in moist clay); therefore, they have no special wall. The lung-tissue consists of a homogeneous substance traversed by elastic fibers, which are of the greatest importance for the function. The elastic parts do not

Fig. 353.—Diagrammatic representation of the ending of a bronchial tube in sacculated infundibula. *B*, terminal bronchus; *L B*, lobular bronchiole; *A*, atrium; *I*, infundibulum; *C*, air-cells or alveoli. (After *Schaefer*.)

lie directly in the surface, but are intimately connected with the surface and cannot be separated from it; hence, they are not considered as separate. The homogeneous substance belongs to the group of connective tissue; it is not, however, ordinary fibrillated connective tissue, since it does not consist of fibrillæ, but of a homogeneous mass with very few cells. It is, therefore, a *substantia propria* in which, aside from the few nerves and lymph-vessels, an unusually large number of blood-vessels course. Upon an injected section, the surface occupied by the vessels appears larger than the true lung parenchyma. Hence, every part filled with blood must appear quite red, the gray color of the true lung-tissue being obscured. Therefore, red color in the lungs does not indicate hyperemia, but gray color indicates anemia.

In the alveoli the lung-tissue is lined with a single layer of flattened epithelium which, loosened and viewed from the side, appears microscopicly as a very fine line; only at the side of the nuclei are the cells

somewhat thicker. The epithelium forms a simple protective covering, but gives to the alveoli no specific character; therefore, unlike the epithelium in the kidneys, it does not form the parenchyma. In the strict sense of the word, the true parenchyma of the lungs is formed by the capillaries which traverse the surface of the lung-tissue and sometimes even project above it, while the true lung-tissue does not directly take part in the gas exchange—respiration—and, therefore, may be looked upon as the stroma. Ordinarily, however, the term parenchyma[1] is employed to designate the true lung-tissue, and interstitial inflammations are spoken of only where true, ordinary fibrillary connective tissue occurs in the lungs. These localities are the visceral pleura, the borders of the lobuli (the interlobular connective tissue which unites the lobuli), and the regions of the bronchi and of the larger vessels—the peribronchial connective tissue which unites vessels and bronchi with the true lung-tissue. Therefore: (1) superficial, (2) parenchymatous, and (3) interstitial processes are differentiated.

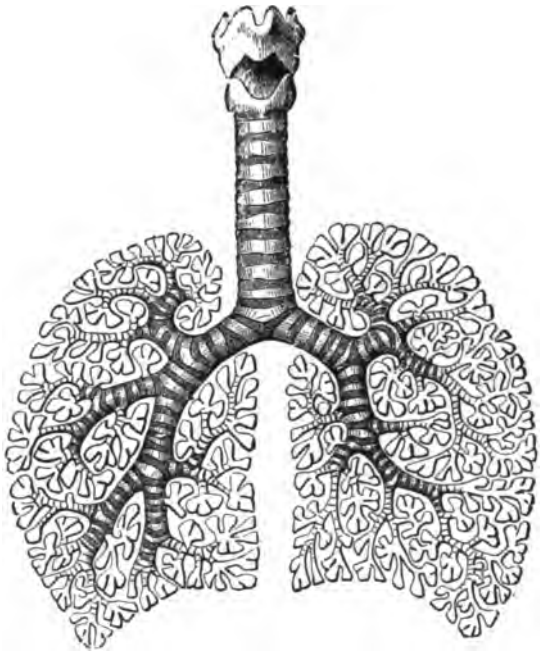

Fig. 354.—Human respiratory apparatus. It shows the branching of the bronchia in the interior of the lungs. (After *Duval.*)

The air passages have a complex structure and terminate with the

[1] *Parenchyma:* the essential or functional elements of an organ.

bronchioles, which are incapable of respiration, but temper cold and hot air and arrest particles, *e.g.*, dust, upon their sticky surface. The air passages possess ciliated epithelia, through the agency of which, under normal conditions, removal of all precipitated particles is aided.

The processes of the air passages, in accordance with the complicated structure of the latter, are more manifold than those of the true lung-tissue. All true alveolar processes are generally characterized by a somewhat more chronic course than those of the air passages; the latter are usually of an exudative nature, and produce principally sputa. Hence, the air passages can be observed just as well clinicly as anatomicly, perhaps better clinicly, while diseases of the lung parenchyma are essentially objects of anatomic observation.

The lung always contains air; normally every alveolus contains a certain quantity of air. If a number of alveoli are filled with air, the air dominates and the area in question has a bright-red appearance; on the other hand, if no air is present in the alveoli, the part, provided the vessels contain blood, appears dark red.

Before birth no air enters the alveoli; therefore, the lungs of newborn which have not breathed appear blue-red and sink in water. This state of the lungs is called **atelectasis.**[1] If air enters such a lung, it acquires a vermilion appearance (telectasis).[2] When a child has made respiratory efforts before birth, the lungs at birth, although airless, are not atelectatic, but hepatized. As, however, the alveoli need not be completely filled with the liquid contents, it may still be possible to inflate them. The possibility, therefore, of forcing air into the alveoli is not proof that atelectasis had existed. In atelectasis the alveoli must be not only airless, but totally empty. On the other hand, air may develop in atelectatic lungs in consequence of gas development through putrefactive processes; this cadaveric development of gas, however, does not occur in the alveoli, but within the tissue: either subpleural or interlobular. These putrefactive bubbles grow rapidly to pea-size, but do not produce a fine foam. On pressure a red foam, composed of large bubbles, is discharged upon the cut surface.

There is also an acquired atelectasis: *atelectasis acquisita.* In this condition the air completely disappears from a part without anything entering the alveoli to take its place.

Compression atelectasis also is an acquired atelectasis. It differs from all others in that the affected area is also anemic. The pressure, *e.g.*, by a pleuritic exudate, removes air and blood at the same time, the blood more easily than the air, which is readily retained in the bronchi.

---

[1] *Ateles:* imperfect; *ectasis:* dilation.
[2] *Tele:* far, and *ectasis.*

From this an ash-gray state results, which is associated with great flaccidity of the organ.

Ordinary acquired atelectasis develops as a result of interruption of the bronchial and alveolar air-space, most frequently through occlusion. This presupposes an exudate large enough to occlude, and is favored by muscular weakness, adynamia.[1] Owing to the muscular debility, expectoration is absent. Occlusion of the lumen may occur also as a result of a process within or outside a bronchus in the absence of asthenia. It is usual, therefore, to differentiate two varieties of acquired atelectasis, according as the local cause or asthenia[2] predominates.

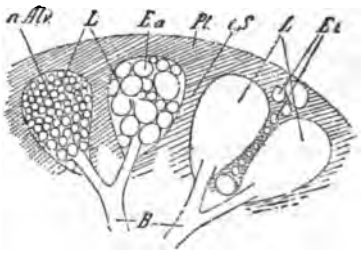

Fig. 355.—*E i*, interstitial emphysema; *E a*, alveolar emphysema; *n Alv*, normal alveoli; *B*, bronchi; *L*, lobuli; *Pl*, pleura pulmonalis; *i S*, interlobular septa. (Schematic. After *Langerhans*.)

Fig. 356.—Interlobular interstitial emphysema. Natural size. (After *Langerhans*.)

When air is retained in the alveoli by occlusion of a bronchus, it is absorbed by the blood; the lung-tissues, consequently, collapse, and contain only blood; they, therefore, appear red, and give the impression of hyperemia. This is **red atelectasis**, which is sometimes also called *pneumonia spuria*. If the atelectatic area lies upon the surface beneath the pleura, it appears retracted. While compression atelectasis occurs most frequently in the lower and anterior portions of the lower lobe and is more or less diffuse, red atelectasis is found more in the upper lobes, frequently in lobular form.

In an atelectatic part of the lung a watery secretion may occur into the alveoli. This is pulmonary edema: *œdema pulmonum*, in which, however, not a foamy, but a clear, watery, fluid can be expressed. Such

[1] *a: priv.; dunamis:* strength.
[2] *a: priv.; sthenos:* strength.

a lung area is gray-red in color and doughy in consistency; pressure of the finger-tip produces a pit. The consistency has a certain resemblance to that of the spleen, for which reason it is designated also as **splenization.**

In contrast to these atelectatic states stand those which are designated as **pulmonary emphysema.** In this state the lungs always contain a plus of air. Two forms are differentiated: *emphysema interstitiale* and *alveolare.* In the first case the air is outside the true lung-tissue, within the interlobular connective tissue (see Fig. 355, *E i,* and Fig. 356), and frequently forms rows of air-bubbles arranged like a string of pearls. Under certain conditions this air infiltration, which corresponds to traumatic emphysema of external parts, advances in a direction toward the hilus of the lung, following the connective tissue which accompanies the bronchi. From there it sometimes extends even to the mediastinal tissue, then soon appears at the lower portion of the neck above the manubrium sterni, and finally enters also the subcutaneous adipose tissue of the thorax, etc.

In the great majority of cases **interstitial emphysema** does not extend beyond the limits of the lungs, and is an unimportant phenomenon which is not found until necropsy; but it is an important indication that respiratory disturbance existed, and forced respiratory movements had been made. Interstitial emphysema can result in death from asphyxia only when it acquires the previously described distribution. It always develops as the result of rupture of alveoli in forced breathing and in violent paroxysms of coughing (*e.g.,* in whooping-cough) by penetration of air into the loose connective tissue, quite analogous to the origin of artificial emphysema of the mediastinum, which occurs at every necropsy on opening the thoracic cavity and removal of the sternum; it sometimes occurs also during unfavorably progressing operations (*e.g.,* tracheotomy).

The delicate lungs of children under 10 years of age are especially disposed to interstitial emphysema, while they very rarely present the phenomena of alveolar emphysema.

In **alveolar emphysema,** called also *emphysema pulmonum* or *emphysema verum,* the air-bubbles always occur in the interior of the lobuli. (See Fig. 355, *E a.*) Upon incision of a normal lung, besides the ordinary alveoli, isolated, somewhat larger air-spaces—the so-called infundibula—also appear. These correspond to the funnel-shaped spaces present between the bronchioli and the true lung-tissue, and which are formed by the apposed openings of the grape-like grouped alveoli. If several or many large air-spaces are visible quite close together, this is always a pathologic condition, due to loss of lung substance and com-

munication of several alveoli, which never occurs under normal conditions. Of course, small openings leading from one air-space to adjacent air-spaces exist, but these are punctiform (stigmata), so that careful scrutiny is necessary to discover them. The larger air-vesicles inside the lobuli originate as the result of an atrophic proc-

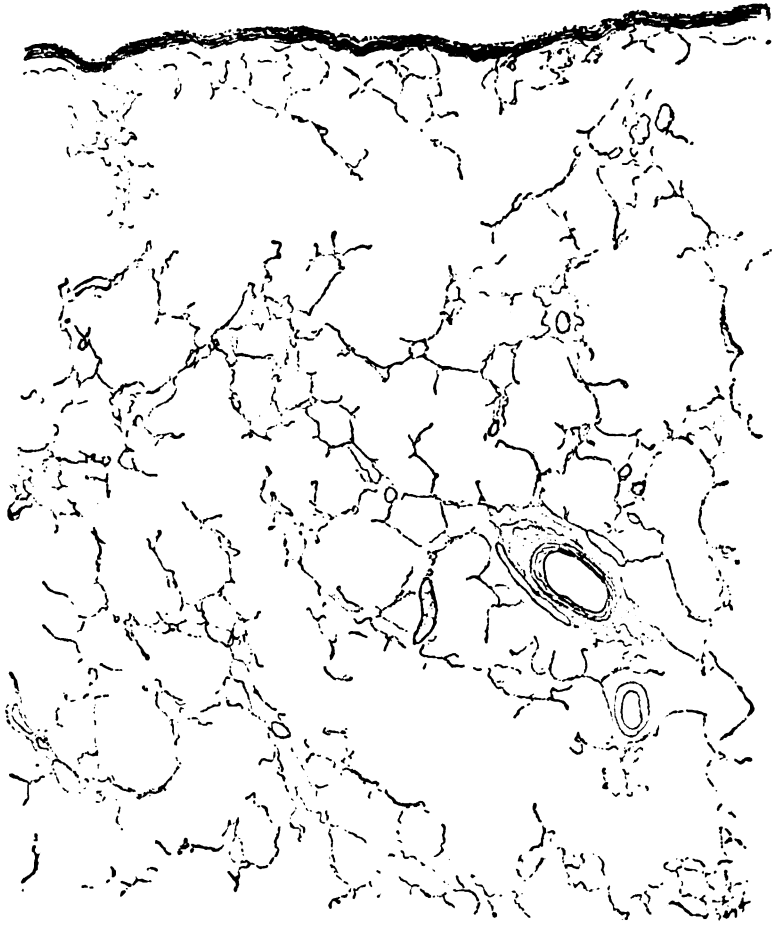

Fig. 357.—Emphysema of the lung. Infundibula dilated, alveoli flattened, lung-tissue rarefied by atrophy of many spots. × 25. (After *Smaus.*)

ess involving the lung-tissue without the presence of detritus or demonstrable expectoration of lung-tissue. These atrophic parts are removed by absorption. In this condition the black lung-pigment always disappears quite early, and it is this deficiency of black lung-pigment, which often is present only in isolated larger or small foci,

that first draws attention to the emphysema. The enlarged air-vesicles gradually become larger, more and more lung-tissue being lost, until finally the lobuli communicate: *emphysema bullosum.* It is clear that the number of alveoli is thus diminished and at the same time a loss of tissue—*i.e.*, of vessels and respiratory surface—occurs. Hence, there is dyspnea during life. Corresponding to the loss of elastic fibers the lungs lose in part their elasticity and contractility; the space which they occupy is thus greater, and the lower border of the lungs descends. This produces the condition known as *volumen pulmonum auctum,* which frequently is distinctly recognizable even after death by the great bulk of the air-distended organs on removal. It is true that such lungs sometimes are strikingly small, in that, if no adhesions exist, they strongly collapse on removal of the sternum, or, if adhesions are present, they are compressed by the hand during efforts to loosen them.

Alveolar emphysema is, therefore, the atrophic condition of the lungs which, as a rule, is due to oft-repeated nutritive disturbances, whether the cause is frequently recurring paroxysms of coughing produced by pathologic processes in the bronchi (chronic bronchitis), the whole lung being subjected to higher pressure before the cough, or whether, as in blowers, the occupation—the activity—results in frequent increase of the intrathoracic air-pressure.

In **asphyxiation** and **drowning** the lungs are found in a greatly distended state, which may easily be mistaken for pulmonary emphysema. Just as soon as the air passages are filled with fluid, paplike or solid masses, spasmodic (convulsive) respiratory movements occur; the inspirations are then more energetic than the expirations, so that the lungs are distended to the greatest possible degree—to the highest degree of inspiration. If the air passages are free, expiration position of the lungs usually is present at the necropsy on removal of the sternum and opening of both pleural cavities, the difference in the air-pressure upon the outer and inner surfaces of the lungs being equalized, and the lung-tissue retracting by virtue of its numerous elastic fibers. This expiration position of the lungs produced by retraction is impossible if the escape of the air in the large bronchi or the trachea is opposed by any foreign masses (food, foam). In this case the lungs, if they were distended to the maximum at death (*e.g.*, in drowned individuals), bulge beyond the cut surface of the ribs on removal of the sternum. The protruded lung portions are strongly distended, and soft and crepitant on palpation: not hepatized, for in death by drowning the water does not penetrate into the alveoli, but rather mixes with the air in the bronchi to form a foamy mass. This is usually easily differentiated from ordinary pulmonary edema, for the bubbles are large and are discharged

only from the bronchi. Sometimes, however, differentiation is extremely difficult and possible only by careful (also chemic) examination of the foamy fluid.

As has already been stated, the lung-parenchyma as such has a translucent gray appearance, which is modified, on the one hand, by distended blood-vessels, and, on the other, by pigment deposits. The pigment may have a very variable origin. In the newborn the lung is free from pigment; in adults large areas entirely free from pigment are found only under certain conditions, *e.g.*, inside of emphysematous parts. The ordinary black pigment of the lungs, which occurs in all adults and usually gradually increases in amount with age, is semiburned vegetable carbon that has been inspired as soot and smoke (tobacco).

In coal workers fine coal-dust[1] is often found in large amount in markedly black and hard lungs: **anthracosis**; in iron workers sometimes a reddish pigment, iron oxide: siderosis, is observed, and in stonecutters minute, gray particles of stone, especially silica-dust: **chalicosis.** These three forms of **pneumonokoniosis** are constantly associated with induration of the lungs, due to connective-tissue proliferations, and usually also with bronchitis.

Isolated areas of the lung frequently appear dark slaty to black in color, and, at the same time, are strikingly hard, sometimes almost cartilaginous, in consistency. This change is called slaty induration. As a rule, it is caused by chronic bronchitis, which results in gradual induration of a whole segment of a lung, the connective tissue proliferating and producing cicatrices. The dark, slaty color is due partly to increased deposition of black pigment at the point involved as a result of the chronic affection of the bronchi, and partly also to the fact that the connective-tissue change and cicatrization occlude the lymph- spaces and vessels, thus rendering impossible the transportation of the pigment to the bronchial glands. Slaty induration is a frequent accompaniment of pulmonary consumption (*q.v.*). Next in frequency to these pigmentations are the yellow (icteric) and the brown coloring matters derived from the blood.

[1] This coal-dust forms minute microscopic splinters with sharp angles and corners: is unburned coal. In contradistinction thereto, soot, the ordinary black pigment of the lungs, appears under the microscope as very small, almost round globules. S. Shingu (*Virchow's Archiv*, 1910, Bd. 200, p. 207) examined 22 cadavers of children of from 1 day to 9 years of age and found dust in the lungs of all those over 23 days old. The dust is first taken up in the alveoli principally by the cells, probably chiefly by the epithelia. In a child of 2 months accumulations of dust particles could be demonstrated in the perivascular connective tissue. In the tissues the dust is most frequently and abundantly deposited in the connective tissue surrounding the smaller vessels. The epithelia of the alveolar walls of all dust lungs contain a greater or lesser number of dust particles. Direct passage into the tissues without the agency of cells could nowhere be demonstrated.

A great part of all coloring matter lies deep in the tissues, chiefly in the interlobular and peribronchial connective tissue; therefore, the lungs usually have a somewhat mottled appearance. The ordinary black pigment of the lung is almost constantly found in the bronchial glands, which are often entirely black.

The yellow and brown pigments originate as a result of hemorrhage per diapedesin, particularly in circulatory obstructions in the region of the left ventricle (*e.g.*, in valvular lesions). In consequence of dilation of the large vessels the capillaries, which otherwise course in the surface, protrude far into the lumen of the alveoli. The amount of air is thus diminished, and the lung acquires a firmer and denser consistency; it is hard and indurated on palpation; this state, therefore, is called, according to the color, red, yellow, or brown induration.



Fig. 358.—Red induration of the lung. Marked protrusion of the turgid pulmonary capillaries at * fat emboli. Fresh section. (Zeiss Apochr., 4; Comp. Ocul., 4. After *Langerhans.*)

(See pp. 45 and 57.) In this condition true inflammatory phenomena are entirely absent. Whenever they are present they are complications.

By **pulmonary edema** is understood the entrance into the alveoli of watery fluid from the capillaries of the lung. The watery fluid there comes in contact with the out- and in- flowing air, with which it mixes and forms a very fine foam. This first fills the alveoli, but may fill also all the bronchi and even flow from the nose and mouth. The cause of pulmonary edema, *i.e.*, the escape of albuminous watery constituents from the capillaries, is principally diminution of the force of the heart. Pulmonary edema sometimes occurs very suddenly, and in a very short time results in death from interruption of respiration (the gas exchange being prevented, the blood becoming overloaded with carbon dioxide, and deficiency of oxygen occurring); sometimes pulmonary edema develops very slowly and insidiously. An incipient, so-called threatening pulmonary edema may resolve if cardiac remedies administered at the proper time do not fail to act; otherwise, death always

occurs. Pulmonary edema may very easily occur also in a vigorous individual with a strong heart if a vascular area is obstructed or compressed by filling of the alveoli with solid material (*e.g.*, in fibrinous pneumonitis), and collateral hyperemia occurs in the remaining portions of the lung. In this case also the danger of pulmonary edema depends essentially upon diminution in the force of the heart. In topers death often occurs in the first stage of pneumonia or even in the prodromal stage (engorgement), because the heart, being too weak to respond by greater activity to the increased demands, diminishes in force and thus leads to pulmonary edema. Pulmonary edema is recognizable anatomicly by the fine foam which flows out abundantly upon the cut surfaces of the lungs in marked pulmonary edema, and in milder degrees is discharged upon pressure.

Congestion hyperemia, **hypostatic hyperemia,** or *hypostasis pulmonum,* is frequently found in the posterior and lower portions of the lungs, especially after long confinement to bed. This occurs only in myasthenic individuals as a result of circulatory and respiratory weakness: the activity of the heart is diminished, the vessels are relaxed, and the lumina therefore larger; respiration, an essential means of promoting normal circulation, is very weak and superficial, and the blood has a tendency to accumulate more and more in the most dependent parts. If with this are associated a slight degree of atelectasis and a mild catarrhal state of the alveoli, the posterior and lower portions of the lungs are dark red, scarcely crepitant, slightly hepatized, and flabby. This state is designated as **hypostatic pneumonia.**

It should not, however, be concluded from every hypostatic reddening that a hyperemia existed during life, because hypostasis very frequently develops in the lungs also after death, since all the capillary blood, which is always liquid in the cadaver, following the law of gravity, collects in the more dependent portions of the lung. The parts situated higher are then pale gray in color. This process is exactly the same as that which occurs in the formation of the death spots (*macula cmortualis*) of the external skin. (See p. 52.)

In the respiratory organs, inflammations with mucous and with fibrinous exudates are differentiated. Inflammation of the nasal mucous membrane with mucous secretions—rhinitis, coryza,[1] or cold (see p. 575)—a genuine catarrh[2] in which flow of the exudate is visible, is most frequent. Two stages can be differentiated. In the first stage the mucous membrane is swollen, very hyperemic and thickened, firm and dry; as yet no exudate is produced.

[1] Coryza = a running catarrh.
[2] καταῤῥέω = flow down.

In the following stage a usually abundant exudation, which at first is watery and later more mucoid and tenacious in character, occurs. When the coryza subsides a large number of round cells (wandering cells, pus-corpuscles) appear in the mucous exudate, which thus acquires a cloudy, whitish, occasionally also a greenish-yellow, appearance. In connection with the nasal catarrh, catarrhal affections of the nasal accessory sinuses, the antrum of Highmore, and frontal sinuses quite frequently develop, less often of the middle ear. As the narrow channels connecting the accessory cavities with the nose become occluded in consequence of the swelling of the mucous membrane, retention of the exudate, which, as a rule, is mucopurulent, less frequently purulent, in character, generally occurs. Both these forms are usually designated as **empyema.**[1] These processes may extend to the neighboring parts and result in periostitis and even meningitic processes; they are generally chronic, though they may spontaneously subside, but contribute to make the originally acute nasal catarrh chronic.

The mucous catarrhs of the larger air passages (laryngitis, tracheitis, catarrhal bronchitis), especially of the upper portions, often produce almost pure mucous secretions with only very little albuminous material. Nasal catarrh not infrequently extends to the larynx, while catarrhal affection of the bronchi frequently occurs without involvement of the nose. The mucous membrane here also appears intensely reddened, swollen, and thickened. The mucus often adheres so firmly to the surface that a strong stream of water is required to dislodge it. Through admixture of a large number of cells, the sputum acquires a cloudy and often a pus-like appearance; even then, however, it usually consists principally of mucus.

There is no specific micro-organism associated with bronchitis; nearly every pathogenic organism appears to be capable of exciting it. The micro-organisms most commonly observed are the pneumococcus, which often produces severe recurrent nasal and bronchial catarrh with fever; streptococcus, *Micrococcus catarrhalis,* Pfeiffer's bacillus influenzæ, and Friedlaender's pneumobacillus. The relation of staphylococci to inflammatory processes in the bronchi is unsettled. Occasionally the *Bacterium coli* is found. The Klebs-Löffler bacillus and the *Bacillus typhosus* are observed in some cases of bronchitis occurring in diphtheria and typhoid fever.

Occasionally man contracts from parrots a severe fatal pneumonia: **psittacosis,** *psittacus:* parrot. In these cases an especial bacillus, *Bacillus psittacosis,* has been demonstrated.

All these mucous secretions, with and without admixture of cells, owe their origin to the activity of the inflammatorily stimulated cells of the mucous membrane. The process here is not merely a simple exuda-

[1] ἐν = within, and πύον = pus.

tion from the blood (for there is no mucus in the blood), but a local product in the formation of which not only the glandular elements, but also the whole mucous membrane, participates, since mucus is secreted also from parts without glands. Therefore, only that portion of the respiratory organs which has no mucous membrane, namely, the true lung-tissue: the alveoli, is incapable of producing mucus. Mucous masses are never found in the alveoli.

Fibrinous exudates, in contradistinction to the mucous exudates, occur everywhere; in the alveoli, however, their origin differs from that in canals lined with mucous membrane. In the first case (in fibrinous pneumonia; see p. 536) the exudate is never composed of fibrin alone, but of blood and fibrin, *i.e.*, an hemorrhagic exudate. On the other hand, in canals lined with mucous membrane, *e.g.*, in the bronchi, the fibrinous exudate is not mixed with blood, but frequently with mucus, so that both exudate masses occur side by side and merge with each other.

These fibrin masses likewise originate as the result of the activity of the cells of the mucous membrane. So different chemicly as both exudates are, there is only a difference of degree between mucus and fibrin; in mild irritation the mucous membrane produces a mucous exudate; in strong irritation a fibrinous exudate is formed.

Aside from the serous membranes, the fibrinous exudates occur most frequently in the large air passages. The larynx particularly is characterized by secretion of quite pure masses of fibrin. Clinicians call this state of the larynx diphtheria or **croup.** Croup is a purely clinic conception; anatomicly, it is designated as fibrinous laryngitis. As in this condition fibrinous pseudomembranes form upon the mucous membrane under change and loss of epithelium, clinicians have gradually become accustomed to place more weight upon the product of the process than upon the inflammation of the mucous membrane, and to designate as croupous all processes in which fibrin appears upon the surface. In this way fibrinous pneumonia has finally come to be designated as croupous, although fibrinous laryngitis and fibrinous pneumonia, according to the entirely different anatomic conditions, are essentially different processes. It is, therefore, better entirely to discard the designation "croupous" inflammation and to replace it by fibrinous. In very abundant exudation of fibrin pseudomembranes of such thickness are produced in the larynx and trachea as to form a cylinder which has only a small central lumen. The smaller the lumen of the air passage, the sooner the lumen in the cylinder disappears, so that solid fibrinous masses are found occluding even bronchi of the second and third order, especially in small children.

These fibrinous masses lie upon the mucous membrane and are, therefore, frequently expelled by coughing or vomiting. They can readily be removed *post mortem* without loss of substance except epithelium, of which only little remains intact. In these localities the mucous membrane is strongly swollen and bright red. Fibrinous laryngitis occurs idiopathicly, especially in children, but does not endanger life until the process extends through the trachea to the bronchi. As a complication it is very frequent in diphtheritic processes, etc. Fibrin coagula

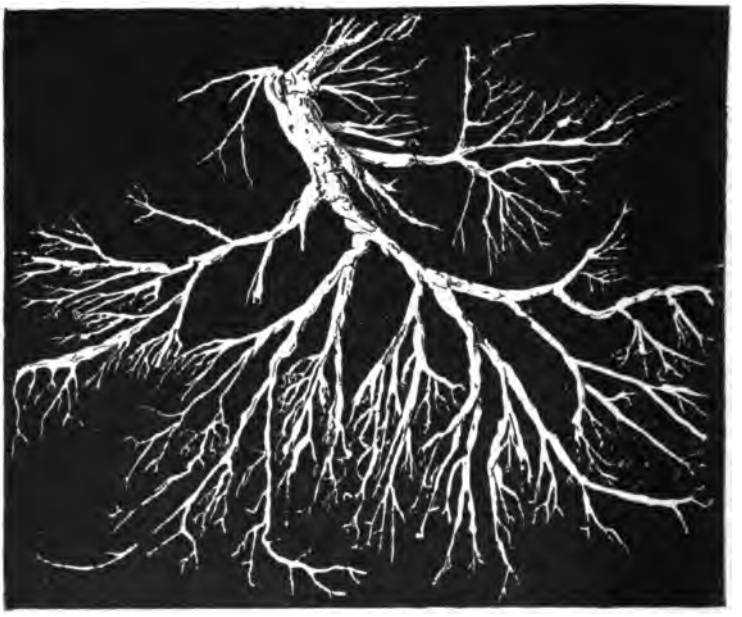

Fig. 359.—Coagulum in croupous bronchitis. Natural size. (Drawn after a photograph.) (After *Lenhartz.*)

occur in almost every case of croupous pneumonia from the third to the seventh day of the disease, *i.e.*, during the stage of hepatization. They are not infrequently dendritic. Highly characteristic coagula, in the form of so-called "bronchial trees" (see Fig. 359), appear in **croupous** or **fibrinous bronchitis.** They are most frequently tubular in form, occasionally solid or flat. Usually the lumina of the tubular forms contain air; sometimes the contents are bloody. These formations occasionally occur also in diphtheria.

True **bronchial asthma** is manifested by acute pulmonary distention ("pulmonary erection," v. Basch), prevalence of respiratory embarrassment in the expiratory phase (Biermer)—as compared with the

usually uniform distribution of the dyspnea to both respiratory phases in cardiac asthma—and by symptoms of acute capillary bronchiolitis. Characteristic of the catarrh accompanying the bronchiolitis is the production of considerable amounts of tenacious mucus, which firmly adheres to the walls of the small bronchi, is expectorated after subsidence of the paroxysm in the form of sputum containing coagula, peculiar spiral threads, **Curschmann's spirals** (see Figs. 360 and 361), **Charcot-Leyden crystals** (see Fig. 371), and epithelia, some of which are thread-like and degenerated. These spirals have nothing to do with the true nature of the asthmatic paroxysms. Macroscopicly, these spirals appear as

Fig. 360.—Curschmann's spiral with central thread. × 110. (After *Lenhartz.*)

grayish, yellow-mottled, transparent, sago-like formations about ½ to 1½ mm. thick, and from ½ to 8 cm. long. Microscopicly, they appear as delicate, twisted spirals of glassy transparency, inclosed in a transparent mucous sheath. At the extremities can often be seen the manner in which the numerous fibrillæ composing them separate and unite. In many spirals is noted a delicate, glistening, uniform, white thread (c e n t r a l f i b e r) occupying the axis of the structure, and only here and there interrupted in its course by a sharp twist (knotting) in the spiral. (See Fig. 360.) Dense collections of the above-mentioned crystals are not infrequently imbedded in the spirals, and sometimes they are so abundant as totally to obscure the spiral structure. The manner in which these spirals are produced can be only conjectured. There can be no doubt, however, that they are formed in the bronchioles, and probably are an indication of an exudative bronchiolitis. It may be assumed, also, that a more or less extensive occlusion of bronchioles with these spirals causes the increasing dyspnea,

but that the true paroxysm begins only with spasm of the bronchial circular muscular fibers (Biermer), sympatheticly induced by obstruction of the bronchioles and distention of the alveoli. Asthmatic sputum is characterized also by its rich content of eosinophile cells.

Upon the posterior wall of the trachea lie a great number of glands which are more or less involved in all catarrhal affections, but may be catarrhally affected also without involvement of the remaining mucous membrane. The cells of these glands frequently undergo mucous transformation, as a result of which stagnation, retention of the mucous masses, and, finally, cystic degeneration of the glands occur; then small, submiliary, translucent, light-gray plugs of mucus can often be seen protruding from the mouths of the glands, which, in contradistinction to



Fig. 361.—Curschmann's spiral, composed of delicately twisted mucous threads and spindle-shaped cells. × 350. In the periphery normal and swollen cylindric and ciliated cells, *fz;* also eosino- (or baso-) phile cells and Charcot-Leyden crystals, *k*. The latter, however, are from other parts of the expectoration: *i.e.,* from another field of the microscope. (After *Lenharts.*)

tubercles, can easily be wiped away. On long duration, inflammatory processes, which occasionally assume a purulent character, occur in the neighborhood of the glands, in consequence of cystic dilation. As a portion of the glands lies outside the tracheal wall between the trachea and esophagus, retrotracheal abscesses develop, which may rupture into the esophagus or trachea. In this case true pus may be discharged upon the surface of the air passages.

In chronic catarrh of the air passages (laryngitis, tracheitis, chronic catarrhal bronchitis) the same conditions exist on the whole as in the acute form. The exudate is usually more tenacious and opaque, and the surface of the mucous membrane gradually becomes somewhat granular. Especial changes occur in chronic catarrh only in and between the *processus vocales.* This is the only portion of the respiratory apparatus

which is covered with squamous epithelium. In this locality formation of papillæ and progressive thickening of the epithelial layers occur in consequence of repeated irritation. These localities, therefore, gradually become more and more prominent, thicker, sometimes wrinkled, and acquire a whitish appearance. Secondary erosions and ulcerations readily develop in these parts.

There is also a papillary form of bronchitis. Owing to the great vascularity of the papillæ, this is disposed to unusually abundant formation of watery secretions.

Catarrhal affections of the bronchi frequently extend to the true

Fig. 362.—Loosely constructed spiral and Charcot-Leyden crystals. × 110. (After *Lenhartz.*)

alveolar lung-tissue, and produce at first simple desquamation of the epithelium. If the masses are not removed, as is frequently the case, especially in states causing retention in the bronchi, a more or less intense cellular exudation into the alveoli occurs, so that the alveoli may be completely filled with these products. This is known as **catarrhal pneumonia.** (See Fig. 363.) It is almost always the result of extension of a bronchitic process, and, therefore, is designated as bronchopneumonia. This occurs principally in myasthenic individuals, children, and aged persons; otherwise (*i.e.*, in the middle, vigorous period of life), only in very exhausting diseases.

In every inflammation of the lung-tissue exudate is found in the alveoli. This may consist of cells or of fibrin. As a result of filling

of the alveoli with this exudate, the affected portion of the lung acquires a consistency similar to that of the liver. This liver-like state of the lung is called **hepatization.** According to the lesser or greater amount of exudate, flabby and firm hepatization are differentiated. The flabby forms correspond more to the lobular, catarrhal pneumonias, while the lobar fibrinous and the mixed catarrhal-fibrinous hepatizations are always firm. In catarrhal hepatization the cut surface of the lobular foci is smooth and has a reddish-gray or yellowish-gray color, which may be variously modified by the lung-pigment; in

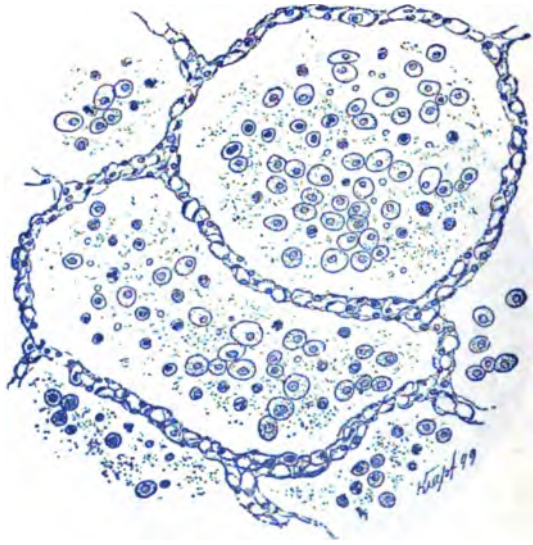

Fig. 363.—Catarrhal pneumonia. In the lumen of the alveolus there are desquamated epithelia as large cells with a light nucleus; and leucocytes, small cells with dark and in places polymorphous nuclei. Hardening methods have caused a granular precipitate in the albuminous exudate. × 250. (After *Smaus.*)

fibrinous lobar pneumonia the cut surface is granular and has a red, yellowish-red, or gray-yellow color. In only one form is the cut surface whitish, namely, in *pneumonia alba:* a congenital syphilitic affection. (See p. 555.) If this is present in extensive degree, death occurs from asphyxia immediately after birth.

Bronchopneumonia is characterized by the fact that it usually occurs synchronously in a number of lobuli: *hepatizatio lobularis.* If, as is not rare at first, hepatization occurs only in the central portion of several adjacent lobuli (see Fig. 365, *c H*), the whole section feels like a doughy mass infiltrated with numerous, firm nodules. This state

is designated as *bronchopneumonia nodosa.* If this state lasts some time, atelectasis of the peripheral parts occurs (see Fig. 366, *A*); the surface then is nodular and quite dark gray-red in color.

The termination of lobular catarrhal pneumonia is usually fatty metamorphosis of the cellular parts, as a result of which these are transformed into an easily absorbable state. In this stage the pneumonic exudate can be forced out upon the surface as a light-yellowish-

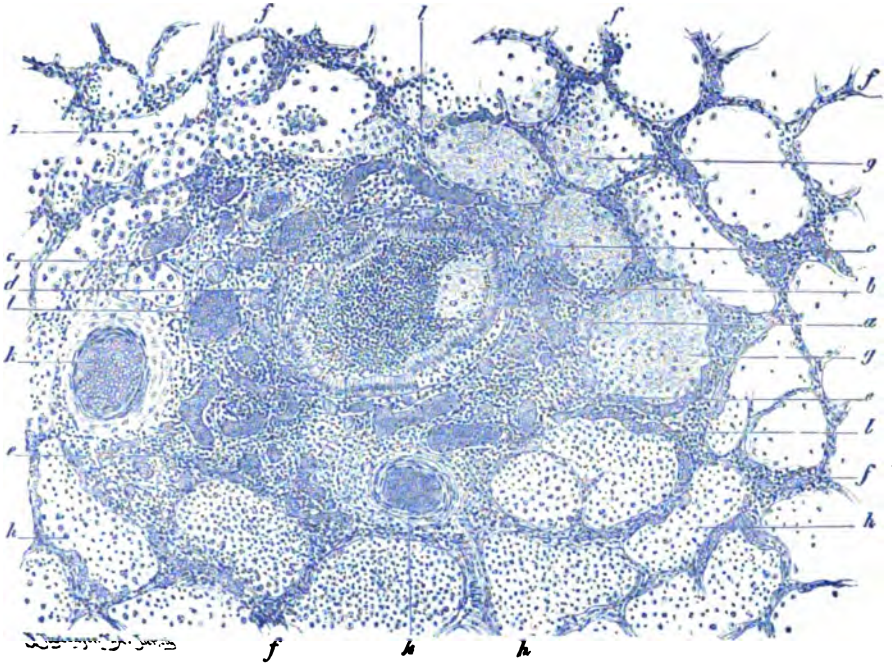

Fig. 364.—Purulent (suppurative) bronchitis, peribronchitis, and peribronchial bronchopneumonia in a child 15 months old. *a*, purulent, *b*, mucoid, bronchial contents; *c*, c_1, bronchial epithelium infiltrated with round cells and partly desquamated, c_1; *d*, bronchial wall containing strongly congested blood-vessels and infiltrated with cells; *e*, cellular infiltrated peribronchial and periarterial connective tissue; *f*, septum between the lung alveoli, partly infiltrated with cells; *g*, fibrinous exudate in the alveoli; *h*, alveoli filled with richly cellular, *i*, with poorly cellular, exudate; *k*, transverse section of pulmonary arteries; *l*, strongly congested bronchial, peribronchial, and intra-acinous vessels. × 45. (After *Ziegler.*)

gray, cloudy fluid. This state of the exudate renders possible complete restitution.

An especial form of bronchopneumonia is that which develops as the result of **aspiration** of solid or liquid material, mucus during anes-

thesia, most frequently vomited food. These foreign substances sometimes enter the lungs so shortly before death that a pneumonic process cannot develop. In this case the lungs in certain localities are saturated with an acid fluid, softened, brownish-discolored, and exhale an acid odor. The same character of material as is present in the stomach is frequently found in the large bronchi. If death does not occur at once, very violent gangrenous processes with ammoniacal decomposition usually develop. (See Pulmonary Gangrene, pp. 725 and 731.)

In other cases, especially on entrance of infectious substances through emboli, in aspiration of thrush masses, aspergillus (*pneumonia mycotica*), etc., lobular bronchopneumonia also develops, which, however, generally goes on to purulent disintegration with formation of a pulmonary abscess.

The transition between pure catarrhal cellular and pure fibrinous pneumonia produces mixed forms in which fibrin as well as large num-

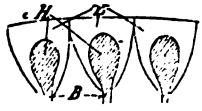

Fig. 365.—*c H*, central hepatization of the lobuli; *B*, bronchi.

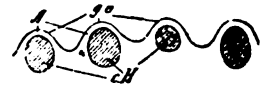

Fig. 366.—*c H*, central hepatization; *A*, atelectatic periphery; *g o*, granular nodular surface.

bers of cells are found in the alveoli. These mixed forms stand between the catarrhal and the fibrinous hepatizations, in so far as they always begin in the form of lobular bronchopneumonia as an extension of bronchitic affections, and pursue a more acute course, and, by confluence of individual lobuli, finally, frequently constitute the transition to the true lobar form of fibrinous pneumonia. These mixed forms occur most frequently in pulmonary consumption, and then generally go on to caseation. On the other hand, caseous hepatization may develop also from pure cellular and pure fibrinous hepatizations. (See Tuberculosis.)

Edema of the glottis (*œdema glottidis*) may develop either from the edges of an ulcer, as erysipelas of external parts extends from a wound, or idiopathicly as an erysipelatoid affection: *laryngitis erysipelatodes*, especially in connection with erysipelas of external parts. Edema of the glottis is almost always an inflammatory edema. Occasionally it develops suddenly in acute and chronic nephritis. The region from Morgagni's crypts to the base of the tongue is generally attacked. The *aditus ad laryngem* is thus so markedly narrowed that asphyxia may occur. The process usually develops very rapidly and, if death does not

occur, may, on further progress, assume a phlegmonous character. In other cases an affection of the larynx, which is phlegmonous from the beginning, develops in a very short time and may produce death within twenty-four hours: *laryngitis phlegmonodes.*

In the course of chronic catarrh of the air passages induration—a connective-tissue proliferation with subsequent atrophy—sometimes develops, *e.g.,* in the pharynx. The mucous membrane thus becomes firmer, denser, smoother, and paler. In the region of the small bronchi the same process begins likewise in the mucous membrane, but soon extends to the submucous tissue and spreads outward to the periphery of the true bronchus. A fibrous bronchitis (*bronchitis fibrosa*) which finally results in complete fibrous obliteration of the bronchus thus develops, which is frequently complicated with fibrous peribronchitis (*peribronchitis fibrosa*). As a result the neighborhood of the bronchus is thickened and always somewhat slate-colored, owing to inclosure of considerable lung-pigment within the cicatrizing connective tissue.

Fig. 367.—*P i,* pneumonia interstitialis fibrosa; *L,* lobuli.

From this are to be differentiated those peribronchial proliferations which occur chiefly or solely in the peribronchial tissue without marked involvement of the bronchi, and result in a whitish-gray, nonslaty thickening in the neighborhood of the bronchus. This fibrous peribronchitis, however, is by no means frequent; it generally occurs whenever the remaining scanty connective tissue of the lung also tends to proliferate, *e.g.,* in fibrous interlobular pneumonia (*pneumonia interlobularis fibrosa*), in which the interlobular connective tissue and always also the contiguous pleural tissue gradually become broader and thicker. This process does not, as a rule, exceed certain limits, so that the lobular markings are usually still recognizable or even very distinct. (See Fig. 367, *P i,* and Fig. 293, p. 555.) In other cases the process begins in the pleura and secondarily extends to the adjacent interlobular tissue. In this instance the retraction, without a strikingly large amount of fibrous tissue being visible, may be so great that, for example, the sharp margin at the base of the lung appears to be lapped over (see Fig. 368, *U R*) and atelectasis finally occurs at this point.

Induration and retraction sometimes occur at one or more points in the pleura in the form of a very smooth, iridescent, cicatrix-like focus,

with indistinct center and radiating bands (see Fig. 369, *P f*), which gradually merges with the normal tissue (*pleuritis fibrosa retrahens*). Here, also, the contiguous lung-tissue is altered very little or not at all. (See Fig. 370, *P i i.*) This radiate cicatricial form arouses the suspicion of syphilis.

When fibrous hepatization has no tendency to undergo retrogressive metamorphosis and assumes a chronic course, the masses in the alveoli may become organized, vascular connective tissue gradually filling the alveoli. The absence of air and the development of the vascular con-

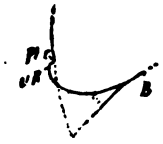

Fig. 368.—*P r*, pleuritis retrahens deformans; *U R*, curled margin; *B*, basis of the lung.



Fig. 369.—*P f*, pleuritis fibrosa; *D*, incision.

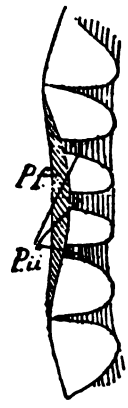

Fig. 370.—Section of Fig. 369 at *D*. *P f*, pleuritis fibrosa; *P i i*, pneumonia interstitialis interlobularis.

nective tissue give to the portion of the lung thus changed the appearance of raw meat. Therefore, this change is called **carnification.** Large numbers of corpora amylacea are not infrequently found in carnified parts. (See Fig. 371.)

According to Nunokawa,[1] the corpora amylacea in the human lung originate as the result of alteration of epithelial or leucocytoid cells which become homogeneous, gradually die, and form the amyloid bodies. In further course the amyloid corpuscles enlarge by apposition of homogeneous, dead epithelia and leucocytes which form a new stratum around the amyloid body. This view is in accord with the finding of carbon pigment which formerly was incorporated in the epithelia and leucocytes and is almost constantly demonstrable in each layer of the amyloid corpuscle. No satisfactory explanation of the radiate structure of the bodies could be

[1] Virchow's Archiv, Bd. 196, p. 221.

found. The genesis of corpora amylacea having a carbon nucleus exceeding the diameter of an epithelial cell or leucocyte, Nunokawa explains by coalescence of several homogenized cells around a large fragment of carbon.

An acute purulent inflammation of the **perichondrium** of the cartilaginous portions in the air passages is usually the result of an affection of the mucous membrane; it is most frequent in the larynx, seldom in the trachea, and rare in the bronchi. Syphilitic, typhoid, and tuberculous ulcerations (see p. 556), by extension into the depth, are the chief causes of acute perichondritis. The perichondrium, like the periosteum, is especially disposed to purulent softening, for suppurative inflammation frequently involves the whole perichondrium without similar alterations of neighboring parts. The results of extensive suppurative perichondritis are complete sequestration and necrosis of the affected cartilage. The dead cartilage then lies in a pus-cavity which is connected with the ulcer of the mucous membrane by a fistulous tract. A suppurative perichondritis frequently develops from unknown cause without demonstrable

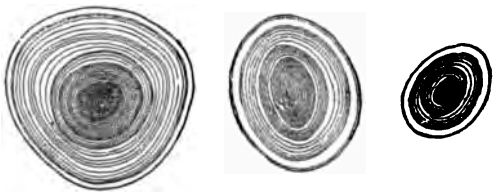

Fig. 371.—Corpora amylacea. (After *Smaus.*)

ulceration or cicatrization in the mucous membrane. This perichondritic abscess may subsequently rupture externally and discharge the pus, so that in this case also a fistulous tract is formed. When the laryngeal cartilages are ossified the process runs the same course, except that instead of the perichondritis a purulent periostitis is present. So violent an inflammatory swelling is sometimes present in the immediate neighborhood, especially in early stages, that there is danger of asphyxiation. In later stages, besides swelling, induration is usually found in the neighborhood of the abscess-cavity. The necrotic cartilage or bone may be expelled by coughing or remain *in situ*. Rupture externally or into the esophagus may occur also in primary or idiopathic purulent perichondritis.

The perichondrium of the arytenoid cartilage (at the *processus vocalis*) is most frequently attacked; next in frequency come the thyroid and cricoid cartilages, seldomer the remaining cartilage.

Ossification of the laryngeal cartilages always begins upon the surface directed toward the mucous membrane, and may be complete. It is an alteration of advanced age, but it occurs earlier also, especially

in chronic inflammatory alterations of the mucous membrane. The tracheal cartilages also sometimes ossify, and less frequently the bronchial cartilages.

Ecchondroses, which also may ossify, occur upon the cartilages of the larynx, trachea, and the large bronchi. Only one or several ecchondroses are usually found in the larynx, while the trachea is often characterized by a multiplicity of these formations. When these grow toward each other from different cartilaginous rings, they may coalesce and form complicated cartilage plexuses. These conditions develop with extreme slowness and are of themselves harmless. They occur almost always in localities in which affections of the respiratory mucous membrane have existed for a long time.

Sacculated and flask-shaped protrusions, with narrow opening, which start from Morgagni's crypts and, as a rule, are directed upward, sometimes form in the larynx. Nothing certain is known as to the etiology of these laryngoceles. Similar formations—ectases—occur in the trachea, but they are almost always multiple. These lie at the posterior portion, often to the right at the junction of the membranous portion and the cartilage rings; they are usually directed toward the esophagus; sometimes, however, they are directed, by inversion, polypus-like toward the trachea. Analogous, but insignificant protrusions are observed in the bronchi between the elastic bands. They are dilated mucous glands which usually still contain mucus and are either more or less cystic or firm, solid, and fibrous. All these are united with the lumen of the trachea by a fistulous tract (the former excretory portion).

True **bronchiectases** are distinguished from these formations by the fact that they always involve more or less large areas of a bronchus. The ectases usually affect many portions of many bronchi of one or both lungs. Cylindric-formed and sacculated ectases are differentiated, according to the external form of the ectatic areas.

The development of these ectases is frequently associated with active processes.

Two forms of bronchiectases may be distinguished: idiopathic and a secondary, which are associated with disturbances in adjacent parts. These are principally processes associated with cicatricial retraction; in order, however, for traction to thus be exerted upon the bronchi, the cicatricial tissue must be fixed. This is most frequently the case in partial slaty induration of the apices of the lungs, when the induration extends to the pleura and, at the same time, flat adhesions of the pleuræ are present. Therefore, this secondary form (cicatricial bronchiectasis, atelectatic bronchiectasis) is found chiefly in the apices of the lungs.

In the idiopathic form there are, as a rule, alterations of the mucous membrane. In most cases a catarrh was at first present, which produced nutritive disturbances in the bronchial walls. Later it is the dilation which favors and sustains the catarrhal processes. As, however, the catarrh usually extends throughout the greater part of the bronchi, while only a portion of the bronchi, *e.g.*, in a circumscribed area of the lung, is ectatic, an especially favorable state must still exist in this region, of the nature of which little definitely is known. The partial or widely distributed dilation often progressively advances, the individual bronchiectases continually increasing in size and the intervening lung-tissue disappearing by atrophy. This state is designated as *phthisis bronchiectatica.* If the dilated bronchi come in contact with each other, confluence and large cavity formation (*caverna bronchiectatica*) may occur. In these cases the lung-tissue suffers secondarily, while in the first-described form the bronchiectasis was the secondary manifestation.

Bronchiectasis is best recognized by the disproportion between the lumen and the thickness of the bronchial wall. The latter is never thickened, but always thinned—strikingly thin. This is due to atrophy of the wall. All portions may be involved in this atrophy, especially the elastic portions and the muscularis. Sometimes, of course, proliferations within the wall can be seen, which may result in new formations. These develop as the result of unequal traction and stretching of the connective-tissue parts. This acts as an irritant and causes proliferation, especially in the adventitia, in the peribronchial tissue, and partly also in the mucous membrane. These phenomena are secondary and are paralleled by proliferations of the intima and adventitia of the vessels in aneurism formation.

In putrid bronchitis and in pulmonary gangrene an acute dilation is always observed throughout the whole extent of the bronchi involved in the putrid process, especially in the region of the medium-sized bronchi. This acute diffuse bronchiectasis, which quite uniformly affects all parts, is apparently dependent upon relaxation of tonicity of the constituents of the wall. The lumen also, in comparison with the thickness of the wall, is too large, or the wall is strikingly thin, in spite of the fact that swelling of the mucous membrane and intense congestion of all vessels are always present.

Chronic bronchiectasis of marked degree is always associated with diminution in the size of the affected lung area.

The conditions for retention and stagnation, with the ordinary sequelæ, are especially favorable in the dilated bronchi. Accumulation of pyoid and also of true purulent and sometimes of caseous, inspissated exudate occurs, as a result of which the sacculated ectasis acquires

a striking resemblance to a lung-cavity produced by ulceration. Bronchiectasis differs from the latter, however, by the presence of mucous membrane. Differentiation is impossible only when the mucous membrane is destroyed by ulceration. In doubtful cases it must be determined whether the mucous membrane of the afferent bronchi can be traced into the cavity or whether constituents of the bronchial wall (*e.g.*, cartilage) are demonstrable.

Bronchiectasis sometimes develops even in fetal life, and is confined either to small areas or distributed over the whole lung (usually over both lungs). In the latter case the whole lung may be occupied by a

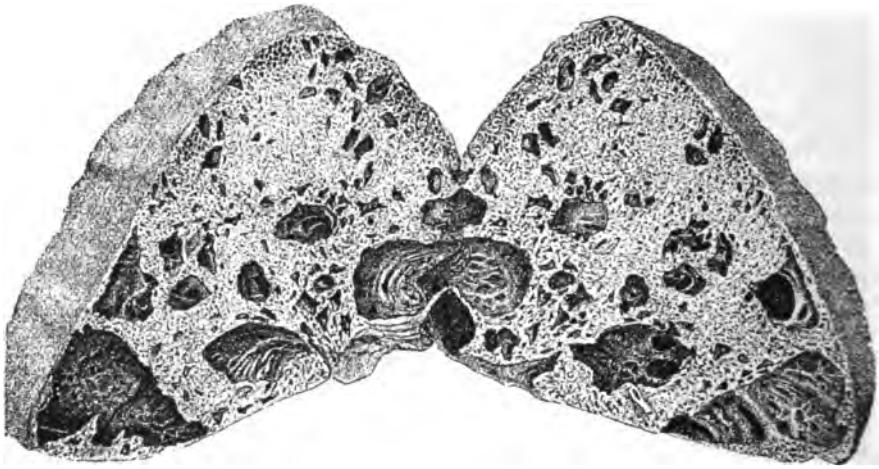

Fig. 372.—Bronchiectasia multiplex congenita in a child born at the eighth month. Natural size. (After *Langerhans.*)

system of cysts of unequal size, which often communicate, in which a more or less cloudy fluid and numerous cylindric epithelia are found. This change is probably always associated with or caused by narrowing of the large bronchi, and, if it is bilateral, results in death at birth, because respiration is impossible.

The blood flows to the lungs in the pulmonary and bronchial arteries, which, in the region of the finest bronchioles and alveoli, communicate with each other by capillary anastomoses. Occlusion of a branch of the pulmonary artery may, therefore, cause blood to be supplied to the affected vascular area by the bronchial artery. The pulmonary artery so divides that an artery (the lobular) finally enters each lobule; this (lobular) artery supplies the whole lobulus, within which it divides into finer vessels and capillaries. When occlusion (*e.g.*, embolism) occurs in a lobular branch of the pulmonary artery, which, as already stated, supplies only one lobulus, the disease focus is lobular, *i.e.*, on section it is sharply defined and polygonal. When a larger branch of the pulmonary artery is occluded, *i.e.*, a branch

which is larger than the lobular branch, several lobuli are involved, each of which is affected *in toto*. The vascular area includes, therefore, *e.g.*, two entire lobuli or five entire lobuli, but not two lobuli and a half! As, aside from the circulatory disturbances, an embolus also frequently causes inflammation (pneumonia) in consequence of the bacteria it may contain, the inflamed area may have lobular limitations (lobular pneumonia, septic pneumonia called also metastatic pneumonia, owing to transportation of bacteria from some part of the body to the lungs). Bacteria, however, may enter the lung with the blood unaccompanied by a large occluding thrombus. These bacteria (bacterial emboli) enter various, often very small, intralobular vessels, remain fixed in these, and produce inflammation (likewise a metastatic pneumonia), which then is variously shaped, often smaller than a lobule: sublobular, intralobular.

Embolism of the pulmonary arteries occurs in thrombosis of the right heart or of the veins of the greater circulation. The effect varies according to the size of the embolus. Very small emboli produce neither visible results nor injurious effects upon respiration; very large emboli cause sudden death by suspension of respiration (pulmonary apoplexy). In this case the effect occurs so quickly that no histologic alterations can be produced.

The conditions are otherwise in embolism of the medium-sized and smaller pulmonary arteries; as these are always terminal arteries, the blood-stream is interrupted and the region supplied by the affected artery, in accordance with the arterial distribution, is infarcted with blood in the form of a more or less distinct wedge. The same process may occur also in injuries and after rupture of a vessel in consequence of very high blood-pressure.

It is doubtful whether all pulmonary hemorrhagic infarcts are due to embolism. Perhaps thrombosis of the vessels sometimes is the cause: thrombotic infarct, and it is possible that even severe congestion originating in the left heart may alone produce a state similar to genuine hemorrhagic infarct due to arterial occlusion, by numerous hemorrhages into the lung-tissue: congestion infarct.

It is generally assumed that typic hemorrhagic infarction occurs only, or with rare exceptions, in connection with congestion of the pulmonary veins or pulmonary capillaries, due especially to lesions of the left side of the heart. When occlusion of a branch of the pulmonary artery occurs in a congested lung, the wedge-shaped area supplied by the branch is first deprived of blood (ischemic). As regards the flooding of the part with blood, Cohnheim assumed that pulmonary venous blood flowed backward (*refluxus venosus*), first filling the vessels of the area and then passing through the vessel walls altered by the antecedent ischemia. This view, however, has not been confirmed by the investigations of von Zielonko, Litten, and others, for it has been shown that infarction occurs also when both the artery and the vein are ligated. Therefore, the blood flowing into the occluded area can come only from adjacent pulmonary capillaries widening into collaterals, or from collateral capillaries between branches of the pulmonary artery and bronchial artery—and this view is most generally entertained; or it comes from new-

formed peribronchial, subpleural, and intralobular vessels from the bronchial arteries, as Grawitz assumes; or it flows backward from the turgid collateral bronchial or peribronchial veins, in which the pressure is high, into the vena pulmonalis.

Various conceptions of the process of infarction have been formed according as one or other possibility of blood-flow to the obstructed area is considered. The two most generally accepted views are:—

1. If **filling of the ischemic area by collateral capillary fluxion** is assumed, the origin of the process is conceived to be as follows: The area belonging to the occluded artery is first rendered ischemic; in the peripheral parts partial stasis occurs, and in the capillaries, venules, and arteries within the infarcted area develop focal hyaline occlusions (thromboses). Small blood-currents are gradually established from the neighboring free collateral capillary area which, in consequence of the stasis and thrombosis, meet with impediments in the channel. The pressure in many capillaries is thus raised to such a degree that blood escapes through the thin and permeable vessel wall (von Recklinghausen). What speaks much in favor of this view is the fact that typic infarction occurs in connection with septic embolism, although no circulatory disturbances of a general nature (congestion) exist in the lungs. In such cases it must be assumed that the embolus itself produces circulatory disturbances at the point of lodgment, and probably less through multiple occlusion with embolic material than by production of fermentation thrombosis in the capillaries and venules which the toxic embolus induces; rapid collateral equalization is thus rendered impossible; the small collateral currents, however, which flow toward the area meet everywhere within the vessels of the latter impediments and cause the blood so strongly to congest that it escapes by diapedesin. Others believe that these septic hemorrhagic infarcts without antecedent ischemia originate as a result of injury to the capillary walls by the septic substances.

2. According to another view (Köster), hemorrhagic infarction occurring after occlusion of a branch of the pulmonary artery in lungs congested by heart disease is referred to backward **flow from the bronchial veins.** It should here be emphasized that in congestion of the pulmonary veins, in addition to ectasis of the alveolar capillaries, the small bronchial and peribronchial veins also are markedly congested, as they empty their blood into the pulmonary veins. Not only in chronic, but also in acute, congestion (*e.g.*, in children who die of cardiac insufficiency) surprisingly numerous turgid vessels are recognizable in the peribronchial tissue, which have been mistaken for arteries (bronchial), but which, from their relations, can be regarded only as bronchial veins. This can readily be demonstrated when such a child's lung is appropriately treated (ligation, hardening in Müller's fluid to preserve the blood, horizontal section). If a branch of the pulmonary artery is now occluded, the pressure in the capillary area belonging thereto as well as in the pulmonary vein emerging therefrom is negative. What is more natural than that the blood from the high-tensioned bronchial veins should enter the empty pulmonary vein and its capillary area? This backward flow does not occur, however, until after some time, during which the vessel walls of the infarcted region suffer in nutrition and become permeable. The blood entering the capillaries by backward flow escapes by diapedesis into the alveoli, where it soon coagulates. So long as it remains fluid it may in part enter the bronchi (hemoptysis).

3. In a certain sense the conceptions mentioned may be united, if it is assumed that hemorrhagic infarction occurs as a **result of circulatory disturbances in**

the lesser circulation. If embolism and a cardiac lesion with congestion exist, as ordinarily is the case, the collaterals the blood from which tends to enter the region meet with impediments; these are in part due to general congestion referable to the reflux established from the bronchial veins into the pulmonary veins or capillaries (the direction of the currents of the collaterals and of the latter are contrary); in part they are caused by local stases and thromboses. Everywhere in front of impediments congestion develops, which finally leads to diapedesis. When it is considered how slight the pressure is in the collaterals—at least at first—and, on the other hand, how high it is in the bronchial veins, it is quite conceivable that the latter preponderates and produces infarction by way of the pulmonary vein and capillaries. The latter assumption is not always necessary, but, as mentioned under 1, infarction can occur also **without** cyanosis of the lungs. For this to occur it is necessary only that numerous small impediments be present in the region of the affected pulmonary arterial branch.

From this it follows that infarction may occur without embolism, when, for example, a substance exciting coagulation produces numerous thrombi in a region. These infarcts are, of course, never so sharply defined and large as those wedge-shaped infarctions accompanying occlusion of an arterial branch (Kaufmann).

In the first stage the infarcted area is strikingly firm; in contradistinction to the adjacent parts, which contract on removal of the lungs, it bulges above the surface and has a blackish-red, slightly moist and, unlike fibrinous pneumonia, smooth-cut surface. In this wedge-shaped area of the lung the circulation ceases and, consequently, also the nutrition. The further changes essentially depend upon whether the embolus contains irritating and infectious germs or not. If the embolus consists only of constituents of the blood—coagulated fibrin, etc.—the whole infarct may gradually be reduced in size by retrograde metamorphosis and the residue become organized (see p. 90); on the other hand, if it contains infectious germs the sequelæ essentially depend upon the nature of the infectious germs. Foci similar to those present in the locality from which the embolus originated usually develop. For example, in puerperal fever a metastatic abscess, which has a certain resemblance to a pneumonia which is undergoing suppuration (see p. 501), develops from the infarct.

These embolic abscesses frequently lie close beneath the pleura and, therefore, are almost always combined with a primarily circumscribed, fibrinopurulent, sometimes a discolored or even ichorous pleuritis, which may extend over the whole pleura, and so soon as a dissecting purulent pneumonia starts in the surrounding healthy lung-tissue acquire a characteristic, sharply defined line of demarkation. In these embolic metastatic abscesses the affected portion of the lung may be expectorated after rupture into a bronchus. On the other hand, the abscess may perforate the pleura and, when the communication with the bronchus is free, cause pyopneumothorax.

In this instance entrance of air into the pleural cavity produces an alteration similar to what occurs on removal of the sternum: the pressure upon the internal and external surfaces of the lung is equalized, and the lung-tissue consequently retracts. In pyopneumothorax, besides air, the pleural cavity always contains pus. (See p. 736.)

In crushing of adipose tissue, bone-marrow, etc. (*e.g.*, by fractures of bone, especially in comminuted and complicated fractures), eclampsia,



Fig. 373.—Fat embolism of the lung after fracture of bone. (Zeiss Apochr., 16; Comp. Ocul., 6. After *Langerhans.*)

also in diabetes mellitus as a result of insufficient saponification of the fat taken up by the blood, and in marked congestion due to valvular lesions of the heart, fat-embolism occurs in the lungs, brain, and kidneys (glomeruli). When a sufficiently large portion of the diameter of all pulmonary vessels is occluded, fat-embolism of the lungs sometimes results in death, which, as a rule, occurs quite slowly. The liberated fat-droplets are extremely yielding and pliant, and penetrate to the capillary area; here they usually are arrested and form sausage-shaped and sometimes dendritic figures. If only a portion of a lung is markedly affected, the region is intensely hyperemic and darker in color than the remaining aërated parts.

The blood in the pulmonary vessels manifests a very slight disposition spontaneously to coagulate. Thromboses are observed only in connection with affections of the surrounding lung-tissue, especially ulcerative processes. These are secondary thrombi following inflammation of the vessel wall. (Compare Tuberculosis.)

Pulmonary gangrene (*gangræna pulmonum*) is a putrid process, characterized by a peculiar, sweetish, pungent, repulsive odor, which is either sharply circumscribed from the beginning or progresses without definite limits (diffuse), and then always manifests a tendency to spread. The involved portions of the lung are soft, flabby, grayish green in color; loosened in consistency, they disintegrate, without sup-

Fig. 374.—Fat-crystal needles, *a*, and rosettes, *b*, and masses of cocci, *c*. × 350.

puration, with the formation of fatty acids, to which, in part, the characteristic fetid, stinking nature of the process is to be attributed. In the foul expectoration are found constituents of the lung, especially elastic fibers, fatty acid crystals, etc. In proportion as the putrid material is expectorated, healing may take place by limitation of the pulmonary gangrene by dissecting purulent pneumonia, a cavity developing which gradually diminishes by shrinkage of the neighboring, partly new-formed tissue. In such a cavity nothing indicating its origin can later be noted. In diffuse gangrene the process, when arrest and demarkation do not occur, extends even to the pleura, and finally terminates in death under severe general septic phenomena.

The cause of the putrid disintegration resides in especial infectious substances, undergoing decomposition or digestion, which enter the lungs from without. The routes by which they may enter are, first, the natural

channels by which substances from without enter the lungs, namely, the bronchi and the blood- and lymph- vessels, and, second, newly developed routes associated with separation of continuity of the pleura, especially penetrating wounds and ulcerations. Gangrene is thus produced in putrid bronchitis; aspiration of particles of food, especially in the insane and paralytics; in destruction of the epiglottis (*e.g.*, by syphilis) and of the aryepiglottic ligaments; in abdominal communication between the digestive and respiratory tracts; in esophagotracheal fistulæ (*e.g.*, from cancerous ulceration); further, in aspiration of gastric contents—vomited matters—in greatly debilitated individuals and in chloroform or ether narcosis; finally, also in aspiration of gangrenous particles derived from gangrenous foci in the oral cavity (*e.g.*, in scorbutus), pharynx, larynx, etc. These gangrenous processes of the pharynx are closely related to the

Fig. 375.—Fat-crystal rosette.

diphtheritic processes and constitute the transition stage between diphtheria and gangrenous phlegmon. This, therefore, is a kind of artificial inoculation through the agency of respiratory movements, and may easily result in the formation of multiple foci.

All substances which reach the lungs by way of the vascular system and produce gangrene enter the circulation from other regions of the body, and manifest their deleterious effects in the lungs. These are, therefore, metastatic foci, usually of embolic nature. The gangrene developing from embolic processes is almost always circumscribed, only the infarcted, usually lobular area becoming hepatized or gangrenous.

Besides penetrating wounds, indirect trauma of the lungs from comminuted fractures of the ribs may be the cause of gangrene.

Putrid bronchitis is an acute inflammation of the mucous membrane, accompanied by catarrh and decomposition of the catarrhal secretion within the bronchi, which may occur in connection with gangrene of the lung or idiopathicly as an independent affection. The bronchial tree of one lung or, when both sides are affected, of both lungs is always

involved. Aside from the characteristic putrid odor, this inflammation is distinguished from others by the enormous vascular congestion (dark-red mucous membrane) and the acute dilation of all portions of the bronchial tree, principally, however, of the medium-sized and smaller bronchi. As in pulmonary gangrene, fatty acid crystals are found in the putrid sputum.

The inflammatory alterations of the pleuræ progress only to a slight degree within the substance of the pleura itself. They are

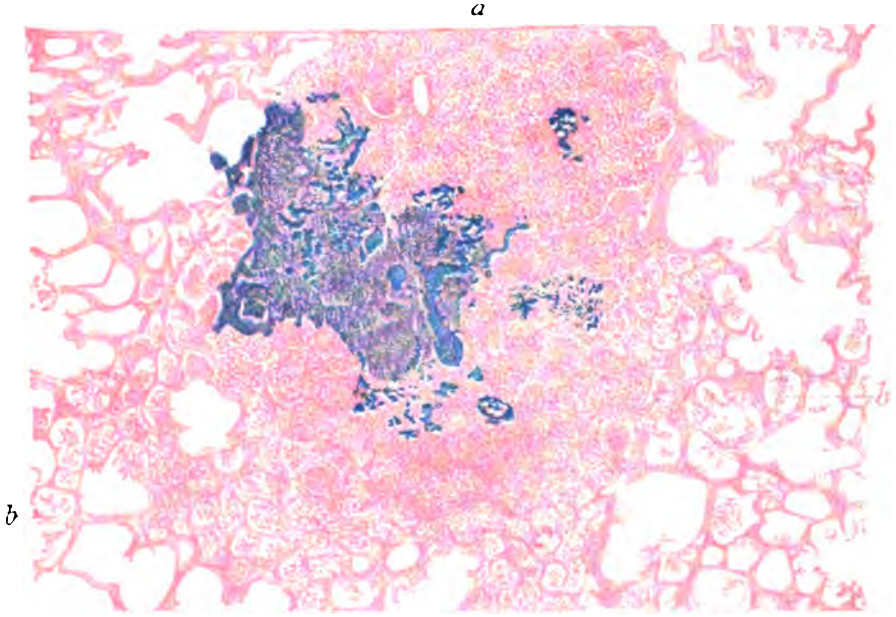

Fig. 376.—Focal metastatic hematogenous streptococcus pneumonia following angina. *a*, pneumonic focus with streptococci (blue inflamed surrounding tissue). × 80. (After *Ziegler.*)

chiefly associated with elaboration of a free exudate. The pleura is characterized by an especial ability to produce fibrin. This is found either in a quite pure state or mixed with watery, hemorrhagic or purulent material.[1] Collections of pure, clear, watery fluid (see p. 96) without any admixture originate in general dropsy (anasarca) due to

[1] Any serous pleurisy which cannot be accounted for is almost always dependent upon tuberculosis.

Pneumonia is said to be the most frequent cause of serous pleurisy. Acute articular rheumatism comes next, then the eruptive fevers, typhoid, influenza, and whooping-cough; observed also in septicemia, pyemia, and even in gonorrhea. In all such cases it may be assumed that the effusion is caused by a pulmonary lesion too small to detect or masked by the pleural lesion.

congestions: hydrothorax. Inflammatory phenomena are lacking here; the surface of the pleura is smooth, moist, refractive, and glistening. A small quantity of fluid is so frequently found that it can scarcely be regarded as a pathologic phenomenon. This slight amount of fluid is probably exuded during the agony.

So-called *hydrothorax lymphaticus* is the transition stage to the inflammatory changes; in this condition the exudate resembles lymph and, like the latter, forms soft, gelatinoid coagula after death, on contact with atmospheric air.

The appearance of the surface of the pleura is characteristic for the true exudative inflammations. It loses its moist, glistening character and becomes roughened, cloudy, or perfectly dry. Often nothing more is to be noted than this peculiar dryness, which cannot be made entirely to disappear by stroking or even scraping with the knife. This *pleuritis sicca* is met in inflammatory changes in neighboring parts, not only of the lungs, but also of the peritoneum, pericardium, etc. When sufficient fibrin is separated to form a distinct and easily recognizable pseudomembrane or an accumulation of loose, pale-gray-yellow, gelatinoid or thread-like flakes of fibrin, peculiar and often very regular wavy lines, which, over the lower lobe, generally run parallel to the sharp border of the lung, develop in consequence of friction between both pleural surfaces. The more fluid is exuded with the fibrin, the more the respiration is embarrassed; in very large exudates the lungs may finally become completely compressed and atelectatic. The mixed, watery-fibrinous exudates correspond to the so-called idiopathic form of pleuritis, and occasionally develop in connection with a "cold."

In very violent inflammatory irritations, besides the fibrinous exudate, blood is present, and sometimes it is so abundant that the whole mass appears to consist almost entirely of blood. The exudate then acquires a certain resemblance to that in **hematothorax**, in which, however, inflammatory phenomena are lacking. Hemorrhagic pleurisy, when not due to neoplasms, is frequently tubercular; occasionally observed in fibrinous pneumonia and bronchopneumonia. Hemothorax consists of an extravasation of blood into the pleural cavity; the cause is either trauma, rupture of an aneurism (usually of the aorta), or hemorrhagic diathesis. (See p. 62.)

In scorbutus the surface of the pleura usually presents the appearance of inflammation. Hemorrhagic pleuritis most frequently develops in carcinoma (particularly metastatic) of the pleura, less frequently in tuberculosis, severe septic processes, etc.

The exudate of **purulent pleuritis**, or **empyema**, is generally not pure pus, but pus and fibrin. The pleura is infiltrated with round-

celled proliferation, thickened, rough upon the surface, and strongly clouded. The fibrinopurulent exudate is loosely attached to the surface in the form of large flakes. The flakes are softer and decidedly looser in structure than pure fibrin, and are markedly cloudy. If the exudate is very abundant, empyema may cause complete compression of the lung. If old adhesions exist, which is not very rare in empyema, these are stretched and, together with the immediately adjacent atelectatic lung-tissue, drawn out in the form of long, slender cords. If large surfaces grow together, there may form between the adhesions sacculated pus-cavities in which gas or air subsequently may accumulate. (See Pneumothorax, p. 736.) Empyema generally develops from fibrinous pleuritis, but sometimes originates after fibrinous pleuropneumonia, most frequently in connection with caseous, purulent, and gangrenous affections of the lungs, rarer after phlegmonous processes in the remaining adjacent structures. In sepsis (puerperal fever) and gangrenous processes in the lungs, the pleuritic exudate may assume a putrid character.

When the pleuritic exudate is so large as almost wholly or entirely to compress one lung, intense collateral hyperemia of the other lung develops and frequently also fatal pulmonary edema, especially if the exudate rapidly increases. If death does not occur and the inflammation subsides, the pleuræ usually become adherent and later grow together to a greater or less extent, the fluid constituents of the exudate being absorbed and the fibrin residue organized. Adhesions of the pleuræ are more frequent and usually flat in the upper portions of the lungs, where the movements are less, while over the lower portions the adhesions, owing to the greater excursions of the lungs, soon become stretched, and finally drawn out into long cords. These cord-like adhesions may contain vessels and nerves. The new-formed vessels are of great importance in progressing destruction of the lung-parenchyma (by phthisical processes) in so far as they lead to communication with the intercostal arteries and unload the pulmonary circulation. The black lung-pigment in alveolar emphysema is carried off from the lungs by the new-formed lymph-vessels present in these adhesions, avoiding the bronchial glands, and deposited in other organs, particularly the liver and spleen. (See Pigment Metastases, p. 93.)

The pleuritic process generally terminates with complete organization of the exudate. The disturbances produced by the adhesions depend, first, upon the size and, second, upon the extensibility and pliancy of the adhesions. In complete obliteration of the pleural cavity the expansibility of the affected lung is decidedly diminished.

Sometimes the pleuritis does not terminate completely with the formation of adhesions, and new inflammatory processes accompanied by

proliferation and exudation which gradually result in the formation of adhesions constantly increasing in thickness occur within the adhesions. These adhesions may be several centimeters thick, extraordinarily firm, hard, and cartilaginous in consistency; they are always associated with retraction, so that the lung is gradually reduced in volume. When these adhesions begin in early life, before growth is ended, the retraction causes flattening of the affected half of the chest, and, finally, also curvature (scoliosis) of the spinal column. These recurrent pleuritides, especially when they are situated at the base or near the lower sharp border of the lung, very frequently cause shortening of the base or overlapping of the lower sharp border downward or upward: *pleuritis deformans.* Very marked deformities and distortions sometimes result.

By **pneumothorax** is understood the entrance of air into the pleural cavity. It may be general or sacculated. In the general form the tension of the air in the pleural cavity is always so marked that the intercostal spaces are obliterated, the diaphragm arched downward toward the abdomen, and on opening of the pleural cavity the air escapes with a hissing sound, and, on opening under water, with the formation of bubbles. The lungs retract toward the hilus in pneumothorax. The air in the lungs is gradually absorbed by the blood and finally disappears. Therefore, even when pneumothorax has existed for only a short time the lung is found at the hilus as a completely collapsed, entirely or almost entirely airless, flabby body. Pneumothorax develops as a result of trauma of the thorax (most frequently in penetrating wounds) and of perforation of the *pleura pulmonalis* from the lung outward in caseous, purulent, or gangrenous processes which extend to the pleura; seldom from emphysema of the mediastinum or of the hilus of the lung or from perforation of an empyema into the lung. The perforation opening is usually very small, especially in perforation from the lung outward, and is often demonstrable only with great difficulty, best by pouring water over the opening and then compressing the lung. A pyopneumothorax generally soon develops from pneumothorax as a result of entrance (with air) into the pleural cavity of substances which excite a violent purulent inflammation.

Primary **tumors** usually develop from the air passages. Carcinoma rarely originates from the true lung-parenchyma, and endotheliomata very rarely from the pleura. Among the primary tumors, carcinoma is most frequent. It develops with especial predilection in the larynx (in the region of the vocal cords, especially epithelioma). Most so-called primary pulmonary carcinomata start from the bronchi. Among them squamous-celled carcinoma (epithelioma) is remarkably frequent, although the bronchi are provided with ciliated cylindric epithelia. It is

assumed that transformation of cylindric into squamous epithelium occurs before the development of these carcinomata.

Metastatic carcinoma of the lungs proper is more frequent than primary carcinoma. It involves chiefly the lymph-channels of the lung and pleura (in primary carcinoma of the breast, the uterus, etc.), and, therefore, appears principally in the true connective tissue, forming either more or less large nodules or, *e.g.*, in the pleura and in the peribronchial and interlobular connective tissue, filling only the lymph-vessels with carcinoma-cells. Secondary carcinoma of the trachea develops as the result of extension of carcinoma of the esophagus or thyroid to the trachea.

In the pleura, carcinoma, especially secondary carcinoma, very frequently progresses under the form of hemorrhagic pleuritis.

Sarcomata of the respiratory organs are rare and almost always metastatic. Most frequently the metastases are melanosarcomata.

Osteomata are rare in the lungs. They should not be mistaken for pulmonary calculi (see p. 140) or for lime metastases occurring after absorption of large masses of bone. (See p. 94.)

Chondromata are somewhat more frequent. Primary chondromata start from the cartilage of the air passages. The lungs appear to be a point of predilection for secondary chondromata or mixed tumors containing cartilage.

Papilloma, papillary epithelioma, or **fibroma,** which develops either spontaneously or as the result of chronic inflammatory processes, is of frequent occurrence in the larynx, particularly upon the vocal cords. It may involve a large area and cause considerable embarrassment of respiration.

Polypi of the mucous membrane (vascular hyperplasia), aside from the rare papillary bronchitis, occur almost solely in the nose, where they are frequently multiple and manifest a great disposition to recur. These nasal polypi are very common, favor catarrhal affections, cause epistaxis, and may almost completely fill the nasal cavities and even the nasopharynx. They very rarely develop into true malignant tumors (sarcoma). Carcinomata (epitheliomata) of the nasal mucosa also are infrequent.

Cysticerci are rare, echinococci somewhat more frequent, and distomum very rare.

THYROID GLAND.

The thyroid gland consists of two lateral lobes, which are usually united by a small bridge: the so-called isthmus. From this extends upward the *processus pyramidalis.* The thyroid gland has a distinctly

lobulated structure, larger and smaller lobuli held together by connective-tissue septa. The smallest lobuli are branched and vesicular follicles which are surrounded by connective tissue containing very numerous and very wide vessels.

The thyroid gland contains a substance which, when injected intravenously into dogs (*a*) lowers blood-pressure and (*b*) increases the pulse rate. The first phenomenon is due to direct weakening of the heart and vasodilation; the latter, aside from direct action upon the heart, principally to irritation of the *n. accelerans* in the medulla oblongata. In rabbits acceleration of the pulse is sometimes preceded by retardation, which soon subsides. This difference is explained by the greater sensitiveness of the cardiovascular nervous apparatus of the rabbit.



Fig. 377.—Section of the thyroid gland of a child. Two complete vesicles and portion of others are represented. The vesicles are filled with colloid, which also occupies the interstitial spaces. In the middle of one of the spaces a blood-vessel is seen cut obliquely, and close to it is a plasma-cell. Between the cubic epithelium-cells smaller cells like lymph-corpuscles are here and there seen. (After *Schaefer.*)

Synchronous injection of small doses of alcohol suspends the thyroidal depression and acceleration; large doses of alcohol increase the depressor action of the thyroid, but suspend the thyroidal irritation of the *n. accelerans* through irritation of the vagus.

The most frequent affection of the thyroid gland is **goiter, struma,** or **bronchocele.** By these terms is not understood every enlargement of the gland, *e.g.,* not the swelling caused by malignant tumors or pus, but the enlargement resulting from local or general hyperplasia or hypertrophy of one or more constituents.

In the growth the follicles—the parenchyma—as well as the interstitial tissue and the vessels, may be especially involved. Accordingly, three principal forms are distinguished:—

1. *Struma follicularis hyperplastica (parenchymatosa).*
2. *Struma fibrosa.*
3. *Struma vasculosa.*

In **follicular struma** the follicle cells increase either uniformly or, what is more frequent, only at certain points, forming solid papillæ, which swell and from which new papillæ develop, which branch more and more. This is the simplest form of goiter formation. The uniform enlargements have a soft, almost fluctuating consistency and a quite smooth, red surface. If individual lobes or lobuli are the seat of proliferation, the organ acquires a lobulated, nodular, knobby character. The interstitial tissue also may increase and cause constriction of individual lobuli. On the other hand, displaced germs of the thyroid also proliferate and result in so-called *struma accessoria.*

In **fibrous struma** the follicles also are always or have been actively involved. These are usually chronic cases in which the connective-tissue proliferations are secondary. Nevertheless, the two forms are to be differentiated, because follicular struma, even after long duration, manifests only a slight disposition to increase of the connective tissue; fibrous struma, on the other hand, is characterized by early proliferation of the connective tissue, which markedly increases and is very firm. This induration generally progresses irregularly, so that in certain localities the follicles atrophy more and more and finally disappear, while at other points they may still continue to grow. With further progress the proliferated interstitial tissue generally gradually undergoes induration, is almost nonvascular, and, finally, is converted by progressive sclerosis into a cartilage-like mass. This form of struma is pronouncedly nodular and lobulated.

The vascularity of the thyroid under normal conditions is very great. To this is due the swelling of the organ during menstruation and pregnancy. More permanent swellings sometimes occur also under other conditions as a result of dilation of the vessels, particularly the veins. In contradistinction to this, genuine **vascular struma** consists in proliferation of the follicle cells with especially marked proliferation of the vessels. Here a *struma aneurysmatica* and a *struma varicosa* are distinguished according as the arteries or veins are more markedly developed. In aneurismatic struma the arteries are uniformly dilated, strongly tortuous, often corkscrew-like; the walls are frequently thickened as a result of the proliferative processes. As a rule, the smaller vessels are unaltered; the larger vessels, however, are greatly dilated. In **varicose struma** not only the large veins are dilated, but the medium-sized and smaller veins within the gland and nodules are also dilated in saccular and wreath-like form.

In **hyperplastic follicular struma** (*struma follicularis hyperplastica*), **cystic goiter**, colloid masses are frequently formed after long duration. These are homogeneous or granular, tenacious, easily compressible masses which are partly or wholly soluble in water. These soluble and insoluble substances are albuminous bodies rich in sodium and sodium chloride; they develop on contact of certain homogeneous masses of the hyperplastic follicle cells with the adhesive fluid, rich in salts, present in the follicles.[1] The homogeneous masses of the follicle cells, which are usually granular, occur either as small, clear foci within the body of the cell or entirely fill the cell-body, so that the latter appears clear and transparent. It is, therefore, a clear, bright substance—an albuminous body soluble in water—which, after a time, exudes from the cells or is liberated by disintegration of the cell. Hence, the colloid masses are concretions.

The greater the amount of colloid material formed in follicular struma, the larger the follicles become and the more the interstitial tissue is atrophied by pressure. Consequently, the follicles gradually coalesce and produce cysts. Later, the colloid material may be transformed by softening into a richly albuminous fluid. In this fluid, particularly in the varicose forms, partly spontaneous, partly traumatic hemorrhages frequently occur, as a result of which the contents of the cysts acquire a yellowish or brownish color. The cells still present die by fatty metamorphosis; cholesterin separates from the fat.

Cystic degeneration occurs also when little or no colloid material is formed, as a result of atrophy of the interstitial tissue and disintegration of the follicle cells by fatty metamorphosis.

On long duration of goiter, lime-salts are deposited in the connective tissue and sometimes even in the vessels. In *struma fibrosa* calcification of the sclerotic and cartilage-like tissue occurs quite early and results in a kind of ossification, the calcification becoming very dense, uniform, hyaline and irregular, serrated cells, resembling bone-corpuscles, becoming manifest within it.

The active formative process occurring in the formation of struma may become inflammatory by intercurrence of an inflammatory irritant. This involves the interstitial tissue and may terminate in chronic interstitial or acute purulent inflammation and abscess formation. The most frequent causative factor is trauma or therapeutic intervention; sometimes the cause is unknown.

The effects produced upon adjacent structures by struma depend partly upon the size of the tumor, partly upon the nature of the muscu-

[1] Here is usually found also calcium oxalate: octahedra and crystals with octahedral ends.

lature covering it. If the musculature atrophies and dies from fatty metamorphosis, the possibility of outward extension of the struma is greater. If, on the other hand, the musculature is intact and strong, the struma more strongly compresses the trachea, esophagus, vessels, and nerves. In consequence of this, disturbances of circulation, innervation, respiration, and deglutition may occur. If goiter is unilateral, the trachea is dislocated, bent, and partly also laterally compressed; if both lobes are involved, marked lateral com-

Fig. 378.—Basedow's disease. (After *Beck.*)

pression frequently develops, whereby the lumen of the trachea acquires the form of a prism or saber-scabbard. Stenosis of the trachea, due to pressure, usually develops slowly, sometimes acutely with manifestations of suffocation, *e.g.*, in the aneurismatic forms.

A goiter which develops behind the sternum presses the trachea against the spinal column, so that disturbances of respiration and deglutition may occur without any external evidence of goiter. Sometimes the thyroid is situated so high that the struma lies behind the angle of the jaw. This is one of the most important forms of congenital struma (*struma congenita*).

Struma cystica may come so near to a surface after atrophy of the wall and of the surrounding tissue that it occasionally bursts and empties its contents into the trachea, pharynx, or esophagus, seldom externally.

From an etiologic standpoint it is to be emphasized that females are more disposed to goiter than males, and that the affection most frequently begins in youth. Struma is not infrequently congenital (richly vascular strumas without colloid material or cyst formation).

A very important fact is that goiter occurs principally endemicly, much more rarely sporadicly. Nothing positive is known regarding the etiology of sporadic goiter; probably it is a primary developmental anomaly. Endemic goiter is said to be due to drinking-water.[1] Hence, not only the natives (and animals) in goiter regions, but also individuals who take up residence in these localities, are affected. It is not impossible that vegetable organisms are the cause of the affection.

The relation of goiter to cretinism is remarkable. Endemic cretinism occurs only in goiter districts and always in the central parts of them. Cretins usually have goiter, but there is no definite relation between the size of the goiter and the cretinic disturbance; indeed, in cretins the goiters may be very small. Probably the same influences which cause goiter, acting at an early stage during the embryonic period of development, may cause cretinism.[2]

Struma exophthalmica, Graves's disease, first actually described by Basedow[3] (Merseburg, 1840), consists in the combination of exophthalmos, cardiac hypertrophy (increased pulse), and struma. The heart is dilated and hypertrophied, especially the left ventricle, although the valves are healthy. The exophthalmos is caused by intense hyperemia of the adipose tissue of the orbits, and, therefore, it disappears readily after death. Sometimes the adipose tissue is hypertrophied. The ocular muscles always suffer after long duration and degenerate by fatty metamorphosis. The enlargement of the thyroid gland is supposedly a secondary phenomenon. The whole

[1] Wien. klin. Woch., 1912, No. 25, p. 82.

[2] That cretinism is a transmissible infectious disease is asserted by A. Kutschera (*Wien. klin. Woch.,* No. 45, 1910). He found two cretin dogs which had shared the bed of their mistress, a semicretin. One dog was completely idiotic, could not bark, reacted to nothing; had dry, brittle, dirty, wooly hair, and milk teeth along with the permanent. After removal of both animals the author placed with the cretin a healthy 4-month-old pup of healthy parents, the rest of whose litter subsequently remained normal in every respect. After three months the dog had a large head (neck 27 cm.); after thirteen months it had become a complete cretin. A second animal of large race, which, therefore, could not occupy the bed with the cretin, developed normally, while three animals reared in bed became cretins. Intimate contact, therefore, according to Kutschera, facilitates transmission.

[3] Named by Trousseau after Graves, who first recognized it in 1835.

symptom-complex probably has a nervous origin, although thus far no definite changes have been found in either the sympathetic or other nerves.[1] *Struma ophthalmica* occurs sporadicly, principally in females during puberty and in the puerperium.

While, according to Claud Bernard, the characteristic symptoms of the affection, namely, dilation of the palpebral fissure and of the pupils, exophthalmos, frequency of the pulse, cardiac palpitation, and struma, are due solely to irritation of the cervical sympathetic, Eulenberg and Oppenheim maintain that they owe their origin not only to irritation, but also to paralysis, of this nerve. In 1864, Gros suggested that Basedow's disease was a vagus affection: the cardiac branch of the vagus and the jugular veins were compressed by the swollen gland; the pressure upon the vagus caused the rapid pulse,[2] tachycardia, and dilation of the vessels, while pressure upon the veins (venous congestion) caused the exophthalmos. In 1887, Moebius advanced the theory that Basedow's disease is due not only to excessive, but also to defective, secretion of the thyroid, which acts principally upon the sympathetic system. The animal experiments of Landström and of Payr and the recent brilliant results of Kocher have confirmed the views of Moebius. In every case of Basedow's disease Kocher was able to demonstrate alterations of the thyroid gland, an increase of the secretion, and a higher iodine content in the secreted fluid. He was able also experimentally to produce Basedow's disease in animals by injecting the expressed juice of the gland, or even the gland alone or combined with iodine. The unfavorable action of iodine in Basedow's disease is thus explained. In the majority of cases Kocher was able to show the etiologic factor to be violent mental and psychic disturbances, infectious diseases, and iodine therapy in existing struma.

Breuer has shown that in many cases of goiter symptoms of Basedow's disease may be induced by iodine treatment (iodine-Basedow's). In these forms iodine administration should, according to Kocher, be sedulously avoided. Basedow's disease may be induced also through administration of thyroid tablets; even in patients without palpable goiter, especially in the obese,[3] iodine administration may sometimes produce severe so-called hyperthyroidism, which often is manifested by uncontrollable diarrhea, rapid emaciation, and fever.

In opposition to the Moebius-Kocher theory of hyper- and dys- thyroidism stands that of v. Cyon and Blum, according to which the thyroid is a detoxicating organ. If the gland cannot neutralize the toxic substances originating in the body, Basedow's disease develops. The chief detoxicating agent is, according to Blum, the iodine contained in the gland. Iodine-Basedow's, and especially the operative results, apparently controvert this theory.

[1] According to Meoni (*Riv. crit. di Clin. med.*, No. 43, 1910; Ref., *Fortschritte der Medizin*, No. 6, 1911, p. 137), Silvestrini reported, in 1903 and 1907, 3 cases of Basedow's disease which were preceded by pleuritis, and concluded that the pleuritis injured the sympathetic nerve and thus caused the Basedow's. In one of these cases Meoni made an exact microscopic study and found a typic neuritis of the sympathetic. In another case observed by Meoni and in 3 cases found by him in the literature, and also in a case discovered in the histories of Basedow patients in the medical clinic at Rome, the disease was preceded by pleuritis. If these findings are confirmed they will offer weighty support of the nervous theory of the etiology of Basedow's disease.

[2] When the disease is established, the pulse may be from 140 to 160 a minute.

[3] In obese diabetic subjects iodine therapy may be injurious.

The theory of the etiology of Basedow's disease now quite generally accepted is the thyreogenic, *i.e.*, that the affection is an autointoxication caused by the enormously increased activity of the thyroid gland with secretion of a toxic substance called thyreoproteid. Although some authors assume a neurologic origin in certain cases, the multiform symptom-complex of Basedow's disease is most satisfactorily explained by the assumption of a toxin which exerts a damaging influence upon all parts of the organism. Thus, a great part of the pathologic phenomena, such as tachycardia, alteration of the pulse and blood-pressure, the vasomotor symptoms, the respiratory and metabolic disturbances and especially the gastrointestinal affections (gastralgia, diarrhea, etc.), may be assumed to be directly caused by the thyreoproteid. Furthermore, as the thyroid gland must be regarded as an organ with an internal secretion which is necessary for the preservation of the organism and the performance of function of certain definite organs, and also as a detoxicating organ, in that certain substances of the gland are supposed to neutralize injurious metabolic products or exogenous toxic compounds (whereby the iodine content of the gland probably plays a certain rôle), it is comprehensible that not only in increase, but also in absence, of thyroid function disturbances in the organism likewise occur which, as is known, find their expression in the thyreopriva affections (myxedema or cachexia thyreopriva), which can be produced also experimentally by thyroidectomy. Accordingly, myxedema and Basedow's disease are opposite affections which result from lack or increase of thyroid gland function. Upon this knowledge has been established the thyreodin and rodagen therapy, serum or milk of myxedematous or thyroidectomized animals being injected into Basedow's patients in order to neutralize the excess of the thyroid secretion. Other sera, in the place of neutralization, have resulted from the idea of immunization, in that they are not derived from thyroidectomized animals, but from animals immunized to hyperthyroidism: *e.g.*, the cytotoxic serum of Rogers and Beebe.

Recent investigations from Kocher's clinic[1] have shown alteration of the blood in this affection, which, according to Kocher, is due to the increased and defective secretion of the gland. The small lymphocytes and large mononuclear leucocytes, sometimes also the eosinophilic cells, are increased, while the polymorphonuclear neutrophilic cells are diminished in number.[2] This finding, designated by Kocher as "toxic reaction," renders diagnosis possible in cases in which the characteristic clinic symptoms are lacking (*forme fruste* of Basedow).

Goiter may persist for years without symptoms. For example, it may appear during the first pregnancy and disappear after parturition; in subsequent pregnancies, however, it gradually increases and symptoms of Basedow's (palpitation, tremor, exophthalmos, etc.) become manifest. Basedow's disease may occur without goiter, and in rare cases the disease may pass into myxedema. The gland, however, may be diseased without enlargement.

Assuming that Basedow's disease is due to defective and increased secretion of the thyroid, the treatment can be operative only. According to Kocher, the mortality is 3.1 per cent., and unsuccessful operative results are due to removal of too little of the gland.

---

[1] Saenger and Sudek, "Ueber den Morbus Basedowii," Münch. med. Woch., No. 16, p. 833, 1911.

[2] The total number of leucocytes is diminished, the polynuclears reduced to about one-half, and the lymphocytes increased to double the normal percentage.

There is also a simple primary, acute inflammation of the thyroid without antecedent formation of struma; this, however, is a much rarer process and occurs after a trauma, as a result of metastases, etc. The acute inflammation may terminate in suppuration and abscess formation or in induration with atrophy.[1] The condition here is essentially an interstitial process. A purulent process—a parathyroiditis[2]—sometimes develops between the trachea and thyroid. This, like *struma perforans,* may rupture into the trachea.

The thyroid generally atrophies somewhat in advanced age. Atrophy is artificially produced by internal administration of iodine.

Amyloid degeneration of the thyroid begins with affection of the small vessels. Amyloid degeneration is frequently associated with an already existing struma; sometimes the amyloid parts form small, isolated tumor-nodules of waxy character. These generally consist of a plexus of intensely thickened vessels.

Primary carcinomata and sarcomata occur in the thyroid. If struma pre-existed, this condition also is designated as *struma carcinomatosa s. sarcomatosa.* Here it is always a question of heterologous and not of simple hyperplastic formations. Metastases, particularly carcinoma metastases, are more frequent than primary tumors.

Occasionally metastases of other organs, particularly of the bones, originate from a struma without any visible evidence of change in the tissue, *i.e.,* without any deviation in the sense of carcinoma, so that apparently not only the metastases, but the thyroid itself, present exactly the structure of ordinary parenchymatous or colloid struma. Sometimes, however, a part which shows a more marked proliferation, forming in a measure a circumscribed tumor, can be seen in *struma thyreoidea,* so that it may be justifiable to assume that the metastases originated from this part. This phenomenon is closely related to the pure forms of adenomata (see p. 307), for, here also, in the thyroid the question is one of a part which, for unknown reasons, suddenly begins to grow and, without deviating from the normal, produces metastases in distant organs. In this regard, it is of interest to know that the product of the follicles of the thyroid constantly enters the circulating blood. If thereby cells possessing the ability rapidly to grow enter the blood, these may be arrested somewhere—perhaps after the manner of emboli—and by proliferation produce metastatic foci: a proof that malignant tumors may develop from cells displaced (transplanted) from noncancerous degenerated parts.

[1] According to anatomic investigations (J. Bauer, *Monatsschr. f. Kinderhlk.,* 1911, Bd. 9, No. 10, p. 560), alterations of the thyroid, in the form of hyperemia and hypersecretion of the colloid, are very frequent in scarlatina. Inflammatory conditions, however, are rare in this affection.

[2] Not to be mistaken for inflammation of the parathyroid.

The **parathyroid glands** (Sandström, 1880) are small, rust-brown or yellow, flat or kidney-shaped, imperfectly lobulated epithelial structures, from 3 to 15 mm. in length, situated posterior to or in the region of the lower border of the lateral lobes of the thyroid, rarer deeper. Usually there are two on each side, loosely connected with the thyroid; occasionally they are observed inside the capsule or even in the parenchyma of the thyroid. Numerous accessory glands also occur. The cells of the gland, which are polygonal, quite large, and have a slightly granular cytoplasm, are arranged either in groups or trabeculæ, between which pass large capillary blood-vessels. Occasionally the glands contain follicles filled with colloid material, which has suggested their origin from the thyroid.

According to Grosser and Betke,[1] extirpation of these glands in animals causes severe and usually fatal tetany, which is the more marked the younger the animals. Iselin found that young rats are more susceptible to the effects of parathyroidectomy than old rats, the former dying from tetany within two days, while the latter live on an average for fifty-four days. The susceptibility is still more marked in the offspring of parathyroidectomized rats, in which death occurs in convulsions within four hours after extirpation of the parathyroids.

That the parathyroids are of vital importance also in the human subject has been shown by effects produced by strumectomy. Erdheim first called attention to the fact that tetany occurring after operations for goiter is not due to the extirpation of the thyroid, but to removal of the parathyroids. This has been substantiated not only by necropsy upon subjects dead of postoperative tetany, but by cure of postoperative tetany by subcutaneous transplantation of parathyroid tissue. Pathologic changes in these organs, especially hemorrhages, are by many regarded as the cause of tetany and of some cases of sudden death in children. Grosser and Betke[2] state that, in every case of unexplained sudden death in children in whom necropsy reveals in the parathyroid tissue destructive changes involving the greater portion of the gland, this destruction may be regarded as the cause of death.

According to V. Pexa,[3] **infantile tetany** is a member of a group of pathologic states to which belong also *asthma thymicum* and eclampsia. All members of this group are correlated by the fact that they all have as a common basis the same constitutional anomaly, namely, the spasmophile diathesis, of which they all are only clinic manifestations. Of the manifold theories as to the nature and origin of infantile tetany the intoxica-

[1] Münch. med. Woch., 1910, No. 40, p. 2077.
[2] *Loc. cit.*, p. 2079.
[3] Archiv f. Kinderhlk., Bd. 54, H. 1-3.

tion, or, better, the autointoxication, theory may be regarded as most probable. Clinic observation has shown that the food exerts a great influence upon tetany and the spasmophile diathesis. According to Finkelstein, cows' milk acts as an excitant in individuals with spasmophile diathesis; Stoeltzer goes further and asserts that the calcium in cows' milk is the

Fig. 379.—Tetany (child 11 months). Characteristic attitude of hands. Slight contracture of feet. (After *Sheffield.*)

substance which induces electric hyperexcitability of the nerves. Investigations by Boyen, Pirquet, and Netter have invalidated this hypothesis; indeed, Sabbatario goes so far as to refer the spasmophilia to lime deficiency of the central nervous system. Pexa's researches show that no increase of the electric excitability in the peripheral nervous system was obtained by feeding young dogs with calcium-free food, and he does not

believe that tetany is due to deficiency of lime. Neither of the two theories which refer infantile tetany to the lime content of the organs is proved. At the present time the tendency is to regard tetany as due to insufficient activity of the parathyroids. According to W. Haberfeld,[1] the oxyphile cells, upon the number of which some investigators lay much stress, have nothing to do with the functional activity of the parathyroids. It has been observed that tetany occurs after strumectomy only when the parathyroids also are removed. Pineles has shown that infantile tetany is clinicly and pathogeneticly identic not only with idiopathic tetany of adults, but also with postoperative and experimental parathyreopriva tetany. According to him, tetany is due to insufficiency of the parathyroids. Hemorrhages, which not infrequently occur in the parathyroids, are not essential for the occurrence of infantile tetany, for the affection may appear in its severest form with anatomicly intact glands. The function of the parathyroids is said to be to neutralize the unknown tetany toxin originated in metabolism. Nevertheless, the origin of infantile tetany is obscure. One thing, however, is known, that tetany usually affects irrational children.

[1] Beibl. z. d. Mitteil. d. Ges. f. inn. Med. u. Kinderhlk., 1910, No. 5.

DIGESTIVE TRACT AND PERITONEUM.

DIGESTIVE TRACT.

THE mucous membranes of the digestive tract are not membranes which necessarily secrete mucus, but such which possess the ability to secrete mucus under certain conditions. Secretion of mucus occurs in localities which are tender and moist and covered with cylindric or squamous epithelium. The true mucus-secreting membranes—stomach, ileum, and colon—are provided with cylindric epithelium.

Mucus, mucin, is a chemic substance, a nitrogenous body which, unlike the albuminates, does not coagulate at the boiling point, but does so on addition of organic acids;[1] while only albuminates containing casein are coagulated by organic acids. Casein is a homogeneous, colloid-like substance which in water is precipitated in fine granules. The mucus precipitate, on the other hand, forms a cohesive, coherent mass which can be drawn out into threads and membranes and is much more tenacious than an albuminate coagulum.

On stronger addition of organic acids the mucin coagulum contracts more and more and is not dissolved, while casein is dissolved in excess of organic acids. This mucin is insoluble in water, but swells strongly.

Mucus is a local surface product, and is elaborated by epithelial elements; also in localities where (*e.g.*, in the urinary and gall- bladder) no true mucous glands are present.

The portions of the digestive tract most disposed to production of mucus are the stomach and next the colon. In **catarrhal gastritis** the surface of the stomach is covered with a more or less thick, tenacious layer of glassy mucus. If this is removed by a stream of water, the mucous membrane is generally found to be reddened and swollen. The folds of the mucous membrane, which are due to contraction of the muscularis, appear strikingly thick, broad, and plump. This change occurs very frequently in general congestion, *e.g.*, as a result of a heart lesion; it may, however, occur also as an independent affection due to thermic (especially too cold drinks) and chemic irritation, and in small children (in pedatrophy) often constitutes the chief change at the necropsy. In this production of mucus, in which the cylindric epithelia are transformed into goblet cells, only the superficial epithelia are involved in the mildest cases. On longer duration (*e.g.*, in congestion) and in

[1] Mineral acids dissolve the coagulum.

severe cases the cylindric epithelia in the excretory portions of the peptic glands also are always involved. Under these conditions mild dilation of the excretory portion of these glands occurs.

When the mucous masses are very tenacious and adhere very firmly to the surface, long duration of the catarrh may result in retention and local accumulation of mucus within the excretory ducts of the peptic glands. The more mucus accumulates in these parts, the more the peptic glands are transformed into small cysts filled with mucus, the transformation of the epithelia into goblet cells progressing gradually toward the depth, *i.e.*, toward the fundus, of the gland. Later, large mucous cysts

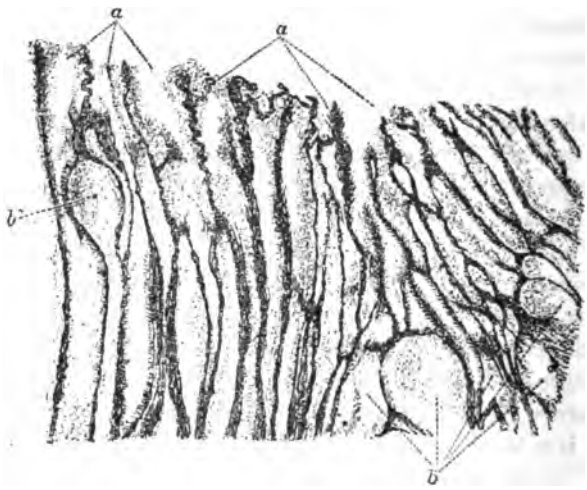

Fig. 380.—Chronic catarrhal cystic gastritis. *a*, dilated excretory ducts filled with mucus; *b*, numerous medium-sized mucous cysts in the middle layer of the mucosa. × 25. (After *Langerhans.*)

may develop by confluence of the smaller cysts. As this process is frequently associated with proliferation of the stroma, *i.e.*, with a secondary proliferative interstitial gastritis due to the irritation exerted upon the interstitial tissue by the cystic dilation of the gland-ducts, individual cysts usually gradually grow above the surface and, under certain circumstances, even assume polypus shape. On the other hand, a primary interstitial gastritis (see p. 764) also may be followed by atresia of the excretory ducts of the peptic glands and retention of mucous masses.

The catarrhal affection of the stomach frequently extends to the beginning of the small intestine, *i.e.*, to the duodenum (**catarrhal duodenitis**), and then readily causes catarrh of the bile-ducts, which is of great importance in that, in the comparatively narrow *ductus choledochus* and

especially in the papilla of the duodenum, it very easily and quite frequently produces swelling of the mucosa and accumulation of catarrhal products which, in turn, cause retention of bile: so-called **catarrhal icterus.** The change which the mucosa of the duodenum and of the *ductus choledochus* undergoes is closely related to that observed in gastric catarrh.

Mucous catarrh of the colon (**catarrhal colitis**), like gastric catarrh, is partly an idiopathic, partly a deuteropathic, change. As an idiopathic manifestation catarrhal colitis is observed in dysentery (see p. 526), in presence of *Oxyuris vermicularis* (see p. 356), in acute gastrointestinal catarrh, especially of children; in cholera nostras, cholera asiatica, and in many poisonings. Deuteropathicly, it occurs in all severe and long-continued circulatory disturbances and as an accompaniment of ulcerative (*e.g.,* tuberculous) affections of the colon. Generally, however, the production of mucus is less abundant than in the stomach, and the mucus is usually less viscid and less adhesive, frequently somewhat flocculent, slightly ropy; only in chronic cases is it sometimes very tenacious, firm, and lamellated. A chronic mucous catarrhal colitis may finally result in complete cystic degeneration of the mucous membrane and formation of polypi, in exactly the same manner as in chronic gastric catarrh. The polypi consist essentially of crypts of Lieberkühn which have become filled with mucus, strongly dilated, and transformed into cysts.

In **membranous colitis** (enteritis membranacea), an affection chiefly of hysteric and nervous women and neurasthenic men, membranous, ribbon-like, or tubular mucous formations, varying from 6 to 20 cm. in length, are discharged at certain intervals, with or without stools, and occasionally accompanied by violent colic (mucous colic). The discharges may be repeated daily for weeks or only a few times a year. Not infrequently constipation exists. The mucous coagula dissolve on addition of caustic potash. This affection is very probably a genuine secretion neurosis, in which the normal mucous secretion is augmented. If sluggishness of the stools and spasmodic peristalsis of the colon also are present, the mucus may be molded between the longitudinal folds of the colonic mucosa into strings, membranes, or even tubular-formed masses.

According to Herman,[1] membranous colitis is in many cases at first constipation in a nervous individual who inquisitively examines his stools. Diarrhea and mucus, results of irritation by the scybala, cause him to visit the physician, who makes the diagnosis. If from the beginning laxatives had been given and personal observation of the feces forbidden, nothing would have been heard of the membranous colitis. Once the patient's attention is directed to his colon, the affection is difficult to cure.

[1] The Practitioner, vol. lxxxiv, No. 5.

In the **ileum** a mucoid mass is easily formed after death if the cylindric epithelia swell and disintegrate. This is a cadaveric change which has nothing to do with true formation of mucus. Desquamation and further changes of the epithelium, with synchronous profuse secretion of fluids, occur in the intestine, however, also during life: ***enteritis catarrhalis.*** In Asiatic cholera, for example, large coherent flakes of epithelium and even villi with their epithelial covering are exfoliated. Desquamation of epithelium occurs also in *typhus abdominalis* and *typhus exanthematicus,* as a result of violent evacuations. The same process is observed in almost every acute gastrointestinal catarrh, in many poisonings, and in every severe congestion due to cardiac lesions. Here, however, true ropy mucus is hardly ever observed in the ileum, but always only gray, soft, flocculent masses, which, under the microscope, prove to be accumulations of loose, somewhat swollen cylindric epithelia (without goblet-cell form!). This is **desquamative catarrh.**

Accordingly, in the gastrointestinal canal it is necessary to distinguish between (1) mucous catarrh, in which an amorphous, structureless mass (mucin) is secreted, and (2) desquamative catarrh, in which the secreted material consists of cells which swell and may assume a mucoid character.

The **tongue** never secretes mucus, but only squamous epithelia, which, however, unlike the cylindric epithelia of the ileum, do not coalesce to form a mucoid mass, but loosely adhere to the usually strongly hyperemic surface as a whitish mass, which can be more or less readily wiped or washed off.

Coating of the tongue, *glossitis catarrhalis,* is due to accumulation of loose epithelial masses which exfoliate. The states of the tongue *per se* do not correspond to those of the stomach, because the stomach has an entirely different epithelial covering; there are local affections of the mouth and tongue without involvement of the stomach; nevertheless, catarrh of the tongue and stomach coexist with preponderating frequency in spite of the difference in the epithelium. Psoriasis of the tongue is a change which consists essentially in circumscribed thickening of the epithelium and inflammatory, small-celled infiltration of the mucous membrane. Erosions and ulcerations very easily develop from this change, and not infrequently carcinoma.

Leucoplakia of the mucous membrane of the cheeks and tongue is closely related to the just-mentioned alteration. This also at first consists of an increase and accumulation of epithelia with quite marked elongation of the papillæ and small-celled infiltration of the membrane. The epithelium, however, assumes another character, the uppermost layer acquiring a resemblance to the horny layer of the epidermis

(epidermization). Later, the papillæ become more and more flattened and the epithelium thinner, and, finally, the whole surface becomes smooth, cicatricial, and covered with horny epithelium.

Noma, or **cancer aquaticus,** is a gangrenous process which generally starts from the angle of the mouth and extends to the lips and cheeks. This process usually begins with watery infiltration and not infrequently is distinctly associated with affections of the mouth, particularly with stomatitis (e.g., *stomatitis mercurialis*), ptyalism, etc. The same process is sometimes observed at the anus and upon the labia majora in little girls.

Aside from the nasopharyngeal space, the changes in which resemble more the affections of the nose, some mucus is secreted by the parts above the pharynx; the chief bulk of the fluids there produced, however, consists of saliva, the product of the salivary glands. This secretion, especially in consequence of the action of drugs (pilocarpine, mercurials), may be so profuse that it is discharged in a continuous stream. This process is called salivation, ptyalorrhea, ptyalism.

A similar phenomenon is *status biliosus,* in which an increased secretion of bile occurs. This is always present in typhus abdominalis. In contradistinction thereto, **acholia** is the term employed to designate complete cessation of bile secretion. Acholia occurs regularly in Asiatic cholera and in acute arsenic poisoning, in which conditions the "rice-water" stools owe their colorless character to the absence of admixture of bile. In *status biliosus*—bilious diarrhea—intensely stained stools occur as a result of polycholia. The chief representative of this is the pea-colored typhoid stool.

In the gastrointestinal canal, two varieties of glands are distinguished: (1) true and (2) false, the so-called lymphatic glands or follicles.

The true glands of the gastric mucous membrane are the peptic glands. The stroma between the glands is composed of blood-vessels, lymphatics, nerves, and the interstitial connective tissue, which, however, is present only in very slight amount and is traversed with isolated strands of smooth muscle-cells. The larger vascular trunks lie in the submucosa and from there send their smaller branches in oblique direction into the mucous membrane. The gastric mucosa is, therefore, much less a mucous than a glandular membrane. The gland-cells, which almost completely fill the interior space of the gland ducts, leaving free only a very small canal, are the chief constituents of the gastric mucous membrane—the parenchyma. Hence, these cells are the chief object of consideration.

In regard to secretion, there are few affections of the stomach in which hypersecretion occurs. **Gastric softening, gastromalacia,** which is found in many cadavers, has no connection with this. Gastromalacia is a strictly cadaveric phenomenon which may occur whenever the gastric content has acquired an acid reaction in consequence of the secretion of the gastric glands during life. This acid content acts unhindered upon the gastric mucosa *post mortem,* when the circulation of alkaline blood has ceased, and produces a change in the mucous membrane which is best compared with the action of freely diluted acetic acid upon fresh microscopic sections. Here swelling and at the same time clearing occur, so that the mucous membrane acquires a glassy, swollen appearance. Hence, no conclusions as to change during life, but only as to the function of the mucous membrane before death, can be drawn from gastric softening. Perforation may occur *post mortem* as a result of gastromalacia, particularly when the stomach is distended by gas.

Two chief forms of gastromalacia are distinguished, namely, colloid and brown. The latter is always preceded by an intense congestion of the vessels before and after death; the dirty, dark-brown color is due to the action of the acid upon the coloring matter of the blood. The ordinary redness of the mucous membrane disappears with the occurrence of death, coincidently with paling of all visible mucous membranes. If for any reason the blood-red does not disappear with the occurrence of death, *e.g.,* in congestion, the acid contents may easily act not only upon the parenchyma of the mucous membrane, but also upon the still congested vessels. Therefore, the finding of "brown softening" always permits the conclusion that hyperemia existed during life. Every gastromalacia begins with swelling of the uppermost layers, which extends gradually in the depth to the muscularis and sometimes to the serosa. The swelling is followed by softening. This chemic process may occasionally extend to neighboring parts, even through the diaphragm and pleura into the lung-tissue **(pneumonomalacia).**

In a large number of gastric affections (*gastritis catarrhalis, parenchymatosa,* etc.) there is hyposecretion. Here the substance of the gland-cells (see p. 134)—the parenchyma of the stomach—is altered.

Lieberkühn's glands of the intestine closely resemble in their arrangement the gastric glands, with the difference only that they are shorter. They are most numerous in the colon; here, however, they lie at a greater distance from each other than in the stomach and have a larger orifice. In the ileum the orifices are smaller; between these are found the villi covered with cylindric epithelium.

In affections of the ileum the state of the villi is of chief importance, since little is known of the function of the glands. Through the activity

of the villi, on the one hand, chyle is absorbed (principally in the jejunum); on the other hand, watery masses may be secreted. The watery secretion is never derived from the glands. In all diarrheas the portion principally involved is the small intestine, which, in the jejunum, besides the villi, is provided with transversely arranged *valvulæ conniventes* or valves of Kerkring; these are duplicatures of the mucous membrane which effect an increase in the surface. The number of these valves varies, being increased by and depending upon contraction of the muscularis and swelling of the intestinal mucosa. The acme of fold formation is reached in intense swelling of the mucous membrane and coexistent contraction of the muscularis. Under certain circumstances, especially in acute inflammatory swelling, the *valvulæ conniventes* extend far beyond the limits of the jejunum, sometimes to the ileocecal valve. The more numerous the folds, the greater the secreting surface. Accumulation of water masses sometimes occurs in the vermiform appendix when the communication of the lumen with the cecum is interrupted by cicatricial contraction or other cause. The appendix may thus be enormously distended, sometimes the size of a hen-egg or a goose-egg and larger. This change is designated as *hydrops cysticus processus vermiformis,* while *empyema processus vermiformis* develops as the result of accumulation of catarrhal-purulent material from retention.

In the **colon,** folds are dependent only upon contraction. The mucous membrane of the colon forms on the whole a smooth, even surface which elaborates the secretions ordinarily occurring. A watery secretion may, of course, be produced from the glands; this secretion, however, contains more albumin than the secretion of the ileum and, therefore, resembles the serous exudates. This is the case particularly in dysenteric processes.

Hemorrhages which either reach the surface (in the form of diapedesis) or remain in the tissues (hemorrhagic infiltration) sometimes originate in the superficial portions of the mucosa. These hemorrhages are generally small, as a rule only punctiform or striate, and occur in all affections accompanied by violent diarrhea (poisonings, etc.) as well as in passive congestion, not rarely in bleeders and in the severer forms of anemia and leukemia. Markedly bloody secretions occur principally in bloody (hemorrhagic) dysentery (bloody flux, see p. 61), thrombosis (see p. 79), and in embolism. (See pp. 89 and 91.)

Blood-pigment (hemosiderin), which is transformed by the action of sulphureted hydrogen into slaty pigment (iron sulphide; see p. 134), is found in the tissues in chronic hyperemic-hemorrhagic processes after solution of the extravasated red blood-corpuscles. This is a frequent occurrence in chronic catarrhal processes, seldom in passive congestion.

Under the microscope the pigment is black in color, granular, amorphous, and arranged in small clumps, usually within cells; sometimes, however, also in the basement substance between the cells. In the stomach and colon the pigment is located in the connective tissue of the stroma, and in the ileum principally in the apices of the villi. In mild degrees of pigmentation these parts have a slightly smoke-gray color, in more marked degrees a slaty to dark-black color. The pigmentation may begin at the cardia and extend to the anus. As a rule, however, only certain portions and not the whole gastrointestinal canal are the seat of slaty discoloration.

Fibrinous exudations (**fibrinous gastritis** and **enteritis**) are rare. A pure fibrinous gastritis is the ordinary result of burning with hot water. Fibrinous enteritis sometimes occurs in children and very rarely in adults from unknown causes.[1] On the other hand, **fibrinous pharyngitis** is a very frequent affection which is always associated with intense swelling of the follicles of the pharynx and nasopharynx, nearly always begins at elevated points, especially upon the tonsils and the uvula, and is either confined to the pharynx or extends to the true air passages. The fibrinous masses can be more or less easily separated from the intensely hyperemic mucous membrane, and, in contradistinction to diphtheria (see pp. 523 and 525), without loss of mucosa. This affection frequently occurs idiopathicly and often sporadicly; it is, however, contagious and, therefore, occurs also epidemicly.

The follicles of the digestive canal are formations consisting principally of small round cells, each with a disproportionately large nucleus, which, in contradistinction to the colorless blood-corpuscles, is visible also without addition of acetic acid. These lymphatic cells lie in a reticulum. Unlike the lymph-glands, the follicles have no external capsule, but the tissue of the follicles merges gradually into the surrounding tissue. Hence, no sharp line of demarkation can be recognized with the microscope. The term follicle signifies really sac, pocket.

The **faucial tonsils** possess pocket-shaped depressions (see Fig. 381, *E*) around which follicles are grouped; all other follicles of the digestive canal form simple, flat swellings of the mucous membrane. (See Fig. 382, *F*.) The intestinal follicles are the most superficial and extend downward into the submucosa. (See Fig. 382, *F*.) The follicles of the stomach are much smaller and never extend to the surface of the mucosa; follicular affections of the stomach are of only slight importance.

The **pharyngeal tonsils** are involved in most affections of the pharynx. At the same time the remaining follicles of the pharynx are

[1] A true **diphtheritic** membrane containing diphtheria bacilli may occur in the **intestine in dysentery** and be expelled with the feces.

usually altered, but in lesser degree than the tonsils. As every fresh affection of the tonsils is accompanied by swelling, which often very markedly narrows the pharynx, and this narrowing, caused by swelling of the tonsils, usually is the most striking feature in simple catarrhal affection of the pharynx, every pharyngitis associated with swelling of the tonsils is frequently designated as **angina** (from *ango:* to narrow, choke, strangle). Every angina, therefore, is really a tonsillar angina. Hence, the simple catarrhal process of the pharynx—catarrhal pharyngitis—also is often designated as catarrhal angina.

The principal constituent of catarrhal secretions is epithelium, which may accumulate as plugs in the crypts—lacunæ—of the tonsils. When these have attained a certain size and protrude from the openings of the lacunæ, they are usually expelled by coughing, during vomiting or simple hawking. When, however, they remain *in situ*, either an intense, sometimes purulent inflammation develops in the neighborhood of the lacunæ

Fig. 381.

Fig. 382.

(*angina lacunaris*), which often may rapidly be relieved by removal or expression of the plugs, or the retained masses putrefy, thus giving rise to *fætor ex ore* (*angina catarrhalis putrida*), or the masses retained for a long time become inspissated and finally infiltrated with lime-salts. This results in the formation of **tonsillar stones**: *calculi tonsillares.*

In chronic granular pharyngitis the follicles in the posterior wall of the pharynx especially are swollen.

Inflammations of the tonsils themselves, namely, **parenchymatous** and **interstitial amygdalitis**, are to be distinguished from these processes. The first, often called **quinsy**, consists of swelling due to acute inflammatory hyperplasia, which either, as in many infectious diseases (*e.g.*, scarlatina, diphtheria, *rabies humana*), subsides after a time, or with frequent recidives results in permanent and gradually increasing enlargement: so-called tonsillar hypertrophy. Interstitial amygdalitis is either a purulent infiltration which, when it involves the whole tonsil, is to be classed with the phlegmonous and sometimes with the gangrenous processes (in diphtheria, scarlatina, etc.), and, when it remains confined to one locality, with the suppurating forms (tonsillar abscess, *amygdalitis apostematosa*), or it is a process resulting in fibrous induration: *tonsillitis*

chronica fibrosa. Fibrous induration with obliteration gives to the tonsil an excavated, dish-shaped appearance with smooth surface.

The purulent form progresses either in the external layer: *tonsillitis apostematosa superficialis,* or it extends into the depth posteriorly (*profunda*), involves the neighboring pharyngeal and retropharyngeal tissue, and results in retropharyngeal abscess Paratonsillar processes, in which the abscess extends to the surrounding

Fig. 383.—Section through one of the crypts of the tonsil. *e, e,* stratified epithelium of surface of mucous membrane, continued into crypt; *f, f,* follicles or nodules of the lymphoid tissue, which is elsewhere diffuse; opposite each nodule numbers of lymph-cells are passing through the epithelium; *s,* masses of cells which have thus escaped from the organs to mix with the saliva as salivary corpuscles. (After *Stöhr.*)

extrafollicular tissue, are the most to be dreaded. Death may result from suffocation or erosion of a blood-vessel in the wall of the abscess-cavity.

The intestinal follicles are sometimes found opened on the surface; this is a purely cadaveric phenomenon, which can artificially be produced by maceration with water; the follicles suck themselves full, as it were, so that rupture of the surface occurs: this condition is favored by decomposition processes.

In general, the changes in follicular affections as such correspond to the parenchymatous processes. The cells of the follicles may migrate into the adjacent tissue, and under certain circumstances, as in the intestine, also to the surface; this is a lymphatic-catarrhal process of the intestine which is called follicular catarrh. In this condition the follicles are enlarged.

During chylification the mucous membrane is hyperemic,[1] the intestinal villi are swollen as a result of distention with chyle (fat emulsion), whitish gray in color, and distinctly recognizable with the naked eye. When the chyle remains for some time in the villi, as a result of disturbance in the flow of chyle, **chyle retention** occurs.

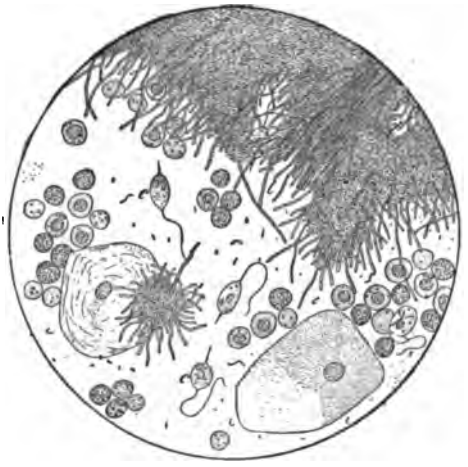

Fig. 384.—Leptothrix, *l*, and cercomonas, *c*. × 350. From a freshly opened tonsillar abscess. (After *Lenhartz*.)

This is generally observed only in isolated villi, in contradistinction to chylification in which all villi are uniformly concerned. The villi in which chyle is retained are larger and, as a result of the complete distention with fat, yellowish white in color. In this condition the minute fat-droplets of the emulsion coalesce to form larger and often very large fat-drops.

Hyperemia of the mucous membrane may be due to inflammation (also chylification) as well as to passive congestions in the venous area; it is frequently observed in cardiac lesions (mitral stenosis, etc.). The congestion may be so intense that the mucous membrane appears bluish red, strongly edematous, swollen, and covered with catarrhal, mucous, or cellular secretions.

[1] Digestive hyperemia is indistinguishable from inflammatory hyperemia.

According to Dunbar,[1] **autumnal or pollen catarrh, hay fever,** occurring in the spring, is almost without exception due to gramineæ pollen; the American autumnal catarrh to the pollen of solidagineæ and ambrosiaceæ, and the hay fever of China to ligustrum pollen.

The symptoms of hay fever are to be regarded as a defensive reaction to the parenteral introduction of the proteid of the pollens named, which is made possible by abnormal permeability of the mucosa and cutis. It is not, however, a pure anaphylactic process in the sense of the definition at present accepted, for it is possible to allay the symptoms by an antitoxic pollen-immune serum, and thus at the same time gradually diminish the individual disposition to such a degree that the paroxysms remain absent without further treatment.

As in inflammation of the tonsils, an acute purulent and a fibrous form of inflammation are differentiated also in the remaining

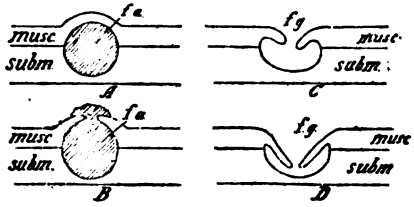

Fig. 385.—*A*, closed follicular abscess, *f a*; *B*, burst follicular abscess, *f a*; *C*, *D*, sinuous follicular ulcer, *f g*.

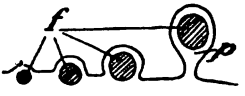

Fig. 386.—*f*, follicle; *p*, polypus.

follicles of the intestinal tract. The former results in follicular abscess, which at first may be covered by a layer of mucous membrane: *enteritis follicularis apostematosa.* In bursting, follicular abscess produces follicular ulcer: *ulcus folliculare*, but not *ulcus folliculi*, or follicle ulcer, for the latter is an ulcer of the follicle in which part of the follicle is still preserved. *Ulcus folliculare*, or follicular ulcer, always signifies that the ulcer originated from inflammation and suppuration of a whole follicle and of the immediately adjacent tissue. Simple catarrh does not result in follicular ulcers; hence, strictly speaking, there is no catarrhal ulceration; but follicular abscesses frequently develop in connection with violent acute and chronic catarrhs, inasmuch as exfoliation of the epithelium in catarrh facilitates the entrance of micro-organisms into the mucous membrane or follicles. Follicular ulcers are particularly frequent in catarrhal dysentery and in chronic intestinal phthisis.

[1] Deutsch. med. Woch., March 30, 1911.

On bursting and discharge of a suppurating follicle (see Fig. 385) a cavity, the walls of which at once collapse, is first formed at the site of the destroyed follicle, so that a depression with a small central aperture develops. If water is poured upon this point, the margins are raised and it can readily be seen that the ulcer has overhanging margins; owing to its resemblance to a sinus (!): such an ulcer is called *ulcus sinuosum profundum*. The area of such a defect is always greater than the original follicle. Follicular ulcers of the large intestine are generally somewhat larger than those of the small intestine.

The **vermiform appendix** is provided with follicles throughout its whole extent. In inflammations of the vermiform appendix, which may be an accompaniment of a general intestinal affection, or, what is comparatively frequent, progress as an entirely local affection, either simple catarrh may be present or follicular ulcerations develop: *enteritis catarrhalis et ulcerosa processus vermiformis*. The most frequent causes of these intestinal affections confined to the vermiform appendix are foreign bodies composed of fecal masses (*cf.* p. 762), which at first produce a chronic catarrhal irritative state and later frequently give rise to suppuration of the follicles and ulceration. As the cause of this process (foreign bodies) does not disappear—foreign bodies are firmly surrounded and retained in the narrow canal by the intense swelling of the mucous membrane—the ulceration extends gradually in depth until the external layers are altered in like manner, or, what is quite often observed, a phlegmonous or gangrenous process of the intestinal wall succeeds the simple follicular ulceration. In both cases an acute inflammation of the serosa develops in connection with the original affection of the mucous membrane, which, especially in ulcerations which slowly extend to the deeper parts, either results in agglutination and adhesion of the neighboring parts (cecum, ileum, *ligamentum latum*, etc.) or—especially in the phlegmonous and gangrenous forms—produces a purulent peritonitis: *perityphlitis purulenta*, even before adhesion by fibrin occurs. The latter not infrequently begins suddenly, at the moment when perforation of the vermiform appendix occurs. In this case peritonitis, or *perityphlitis stercoralis*, quickly results.

The influence of mobility of the cecum (*cæcum mobile*) in the etiology of some cases of so-called chronic appendicitis has been studied by Stierlein[1] upon a series of 61 cases in the Basel Clinic. The disturbances, which sometimes are very violent, are due to kinking and axial torsion of an abnormally long and mobile cecum. A primary or secondary typhlatony or another cause of obstipation present in the colon, especially at the splenic flexure, plays a secondary rôle. The symptom-complex is chronic, usually marked constipation, occasionally

[1] Deutsch. Zeitsch. f. Chir., Bd. 106, p. 407.

associated with diarrhea of brief duration; interval attacks of colic localized in the region of the ascending colon, due to pathologic contractions of the cecum, usually unattended by rise of temperature. Of 9 cases in which appendectomy without cecopexy was done 2 were cured (with persistence of obstipation), 3 were improved, and 5 were uninfluenced. Of 43 cases of cecopexy in which a conclusion as to the permanent results was possible, 75 per cent. were cured, 16 per cent. improved, and 9 per cent. uninfluenced. Of the 52 cases in which cecopexy was done, 25 per cent. were males and 75 per cent. females, and as regards age 67 per cent. were between the 15th and 25th year.

Follicular ulcers heal by filling of the sinuses with fresh granulation tissue; this shrinks and results in cicatrization; a small, slightly elevated knob develops, from which a few striæ radiate. This always causes a certain amount of distortion of the intestine. When several follicular ulcerations coalesce, stricture with dilation of the portion of the intestine above it may result.

On the other hand, follicular ulcers often follow narrowings of the lumen resulting from antecedent ulcerations, particularly those due to syphilis and carcinoma.

Stricture causes accumulation (retardation) of the intestinal content: **coprostasis.**[1] The latter may be produced also by arrest at the point of stenosis of swallowed foreign bodies, most frequently cherry pits or prune stones. Symptoms of volvulus or ileus: complete intestinal occlusion, then occur. Dilation of the intestine occurs in the portion of intestine situated above a stricture as the result of accumulation of fecal masses; the intestinal wall becomes thickened by hypertrophic processes (especially in the muscular coat), owing to the increased efforts of expulsion and of the more intense irritations. Follicular ulcers frequently develop in the mucous membrane of this portion; they are sometimes so numerous that the mucous membrane appears perforated like a sieve. In addition, diphtheritic alterations of the mucous membrane frequently occur.

Coprostasis, however, occurs also without stenosis, most frequently in the insane who refuse food; sometimes it becomes habitual from unknown causes or from habit.

The lassitude and inactivity of many constipated subjects are referred by W. Russell[2] to the inability of the bowel to eliminate the products of metabolism of the muscles. In England "bilious attacks" with the characteristic high blood-pressure have for ages been treated with mercurials, which act not only as cathartics, but also reduce blood-pressure. Russell regards the frequent recurrence and persistence of such bilious states as one of the commonest causes of arteriosclerosis. If this has already developed, the effects of constipation are doubly pernicious. One

[1] *Kopros:* excrement; *stasis:* standing still.
[2] The Practitioner, vol. lxxxiv, No. 5, p. 604.

of the ordinary sequelæ of constipation in young girls is chlorosis, which, as is well known, is not infrequently overcome solely by regulation of defecation.

The less frequent occurrence of constipation in men than in women is attributed by some to the greater disinclination of women to be observed visiting the toilet; as, however, constipation is observed also in children, the question arises whether it may not be regarded also as an example of inheritance of an acquired characteristic. Defecation is not infrequently disturbed by proximity of abnormal internal genitalia: a retroverted uterus or sensitive ovaries.

As in all probability the liver possesses the function of destroying intestinal toxins, the cutaneous manifestations sometimes observed in constipation may be referred, according to Whiting,[1] to defective liver function. Comedones and acne are often referable to constipation, and increase and decrease with it. Eruptions of various kinds are aggravated by constipation; not only those of constipated individuals, but also those in children nursed by constipated mothers. Some persons regularly acquire cutaneous eruptions (erythema, papules, urticaria) about twelve hours after an enema of even pure water or after administration of a brisk cathartic. Apparently, toxins are thus liberated which are dissolved and absorbed. Some cutaneous affections may be overcome only by laxatives and intestinal antiseptics, *e.g.*, lupus erythematosus, urticaria pigmentosa, and ordinary urticaria. Also the well-known employment of yeast in acne and furunculosis probably depends upon cleansing of the intestine. The intestinal toxins, like the alkaloids, probably possess the ability, with slight change of their chemic constitution, to markedly alter their physiologic action, for which reason slight causes may produce marked alterations in the condition of the skin. Thin feces appear to more readily produce cutaneous manifestations than the dense feces of the transverse and descending colon. Whiting inclines to the view that in cutaneous affections due to constipation the skin functionates as an excretory organ. As proof of this possibility he cites urea, which in some persons is observed in powder form upon the skin of the face.

Stagnation (retention) of intestinal contents may occur as a result of peculiar curvatures and displacements of the intestine, especially of the colon, and give rise to *ulcera follicularia*. In all these cases the irritation in ulceration is due to the accumulated feces and the micro-organisms they contain.

Follicular ulcers do not occur in the esophagus; they are very rare in the stomach, quite frequent in the pharynx and oral cavity, and most frequent in the small and large intestines.

Simple swelling of the follicles of the small and large intestines regularly occurs during digestion. It occurs also in many catarrhs, as so-called catarrhal swelling, and in chronic catarrh may lead to the formation of polypi as the result of synchronous hyperplasia of the extrafollicular tissue. (See Fig. 386.) The principal seat of these polypous changes of the follicles is the lower portion of the ileum; less frequently the jejunum and colon and sometimes the whole intestine are involved.

[1] The Practitioner, vol. lxxxiv, No. 5.

The irritation of the mucous membrane in catarrhal processes causes proliferation—formation of new cells—in the intestinal follicles. This is always associated with hyperemia, which, on long duration, results in slaty pigmentation of the follicles. In every marked swelling of the intestinal follicles the adjacent mesenteric lymph-glands also are generally swollen.

In the **gastric mucous membrane,** proliferations which are associated with swelling and gradually impart to the surface a finely granular appearance are observed in the region of the stroma. Constrictions of the gland-ducts, particularly in the surface, in the region of the excretory portion of the peptic glands, occur as the result of proliferation; consequently, dilation and cystic formation of the lower portion of the ducts sometimes develop. The cysts contain a glassy, mucoid material and may project above the surface like vesicles. Exactly the same process is observed also in the large intestine: *colitis prolifera cystica.* When interstitial gastritis terminates, shrinkage of the glands, thinning of the stomach wall, sometimes almost complete atrophy of the mucous membrane develop as a result of retraction. More frequently chronic interstitial gastritis progresses quite insidiously without cystic formation, repeated recidives occurring, so that almost complete atrophic areas of gastric mucous membrane can be seen adjacent to areas which are almost unaltered and, again, other areas in which beginning proliferation or shrinkage can be recognized. Macroscopicly there is often very little to be recognized. When a larger portion of the mucous membrane has already disappeared, the unusual thinness of the mucosa is very marked.

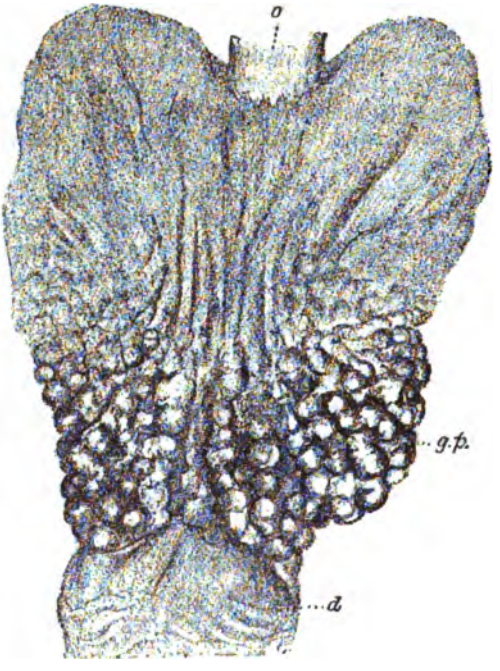

Fig. 387.—Chronic proliferative gastritis in a butcher who daily drank 2 liters of schnapps. *o,* esophagus; *d,* duodenum; *g. p.,* papillæ due to proliferation. ¼ natural size. (After *Langerhans.*)

These chronic processes, ending in atrophy, are best compared with chronic diffuse cirrhosis of the liver; they occur most frequently in syphilis, and sometimes, without any demonstrable evidence of syphilis, in severe pernicious anemia.

In contrast to this chronic interstitial form stands the acute **purulent, phlegmonous** form, which is very rarely observed. Aside from trauma, very little is known of its genesis. Extensive elevation of the mucous membrane from the underlying tissue is sometimes produced by this process.

Small tumors occasionally develop from the chronic proliferating process, especially in the stomach. By progressive increase of the protuberances a condition gradually develops which is comparable with warts: *gastritis verrucosa.* This finally results in the formation of large polypous excrescences: *gastritis polyposa.* The intermediate stage is called *status mammillaris,* "breast-nipple stage," *état mamelonné.* All these formations consist essentially of proliferated interstitial tissue. The gland-cells also proliferate, however, so that the gland-ducts themselves grow, elongate, and branch. New vessels, which not infrequently are the source of hemorrhages, grow into these proliferating masses. Hemorrhage is observed with especial frequency in the polypous and villous excrescences of the mucous membrane of the large intestine, which, next to the stomach, is the principal seat of this change. In the rectum these proliferations occur most frequently in the form of isolated, often numerous, and widely separated polypi of variable size. Frequently they are no larger than a hemp seed or pea; seldom they attain the size of a hazelnut and larger. The larger polypi may be the cause of intussusception (invagination).

Parenchymatous gastritis, or **gastroadenitis,** consists in swelling of the peptic glands. Here the mucous membrane is so cloudy that the submucous vessels are invisible; it is swollen, often granular, especially in the region of the pylorus, and usually pale. When the process has reached its acme and no *restitutio* takes place, retrogressive fatty metamorphosis occurs. Gastroadenitis is observed principally as a concomitant of severe infectious diseases and in certain poisonings, especially phosphorus poisoning. (See p. 328.)

Phlegmonous inflammations develop in the rectum and colon in connection with injuries, *e.g.,* through enema syringes, after examination *per anum* or through swallowing of foreign bodies, such as needles, bones; in connection with syphilitic ulcerations, varices, etc. Submucous (ischiorectal) abscesses, which may cause extensive elevation of the mucous membrane, are not infrequent. Proliferations which completely obscure the abscess sometimes exist in the mucous membrane. Fistulous sinuses

not infrequently develop at the anus as the result of these ulcerous processes. When these sinuses communicate only with the intestinal lumen, they are called **blind** or **incomplete internal rectal fistulæ**; when, however, they open externally, as a rule to one side of the anus, they are named **complete rectal fistulæ.**

Aside from the already-mentioned hemorrhages and congestions, embolic processes occur in the vascular system. **Embolism** of larger vessels, *e.g.*, of the superior mesenteric artery, leads to fatal intestinal hemorrhage without the seat of hemorrhage being demonstrable (*hemorrhage per diapedesin*). The region supplied by the affected artery is, as a rule, dark (bluish) red in appearance, swollen, and markedly succulent. Small emboli in the mucosa are associated with infarction of the mucous membrane with subsequent diphtheria, ulceration, and cicatrization, which sometimes may produce mild phenomena of stenosis. On the other hand, infarction in the gastrointestinal canal is caused also by mechanic influences, such as contusion, occlusion of veins in incarcerations, etc.; by spastic contractions of the musculature of the stomach and intestine, especially in the mucous membrane at the level of the rugæ, and, finally, by hemorrhagic diathesis. A loss of substance occurs in the infarcted portion, because the circulation entirely ceases.

Simple, so-called round gastric or **peptic ulcer** is always referable to a primary affection of an artery or an arterial district. The whole capillary area of the mucosa (and sometimes also of the submucosa) belonging to this artery (which usually runs in the submucosa) becomes anemic or infarcted, dies, and is digested by the acid gastric juice, because the circulation of the alkaline blood has ceased.[1] An at first rounded and later, when the ulcer becomes larger and extends deeper, more oval, almost ovoid ulcer then develops, which has quite sharp margins as though punched out. As with advance of the process the different layers of the stomach wall, from the mucosa toward the peritoneal covering, are attacked to a less extent than the preceding layer, these ulcers usually extend funnel-shaped into the depth, the apex of the funnel directed toward the peritoneal coat. At the deepest portion, corresponding to the apex of the funnel, the diseased artery is distinctly visible, often in the form of a stump. Sometimes the successive layers of the gastric wall are seen as strata or steps in the wall of the ulcer. The typic seat of

[1] In case a focus in the gastric mucosa is the seat of hemorrhage or necrosis, it is digested, because, as stated above, being deprived of the circulation, it is less resistant. In this manner erosion and gastric ulcer develop. Gastric ulcer is, therefore, often called peptic ulcer, because it is due to digestion. The same process occurs in the lower portion of the esophagus and in the upper part of the duodenum. A peptic ulcer may occur also in those portions of the ileum which have been brought into immediate connection with the stomach by operation (gastroenterostomy).

simple round and sometimes, but not always, of perforating gastric ulcer (*ulcus simplex,* in contradistinction to *ulcus carcinomatosum*) is the immediate neighborhood of both curvatures, especially on the posterior surface of the lesser curvature near the pylorus.[1] Sometimes two symmetric ulcers, which may gradually become confluent, develop at both sides of a curvature. The confluent ulcer in pure form has a biscuit-like shape. Generally, only one ulcer is present; not very rarely (7 per cent.), several occur together. Usually they are about the size of a dime, though they may be very large (several inches) in dimensions, or very minute (two lines in diameter). These gastric ulcers almost always pursue a very chronic course. While occurring at all ages, they are most often observed between the 30th and 40th year in males and between the 20th and 30th year in females. As regards sex, the ratio is, according to recent statistics, about 4 males to 1 female. Perforation of a gastric artery and consequent fatal hemorrhage are not uncommon. According to Welch, the mortality in general is about 15 per cent. Open gastric ulcer is observed in from 1 to 2 per cent. of persons dying from all causes. Rarely, cicatrices of old ulcers with whitish, stellate scars are found.

Upon the external surface of the stomach a *perigastritis partialis,* which leads to adhesion of the stomach to the adjacent organs (liver, pancreas, spleen, lymph-glands, etc.), develops over deep gastric ulcers. The pancreas most frequently forms the floor of ulcers perforating on the posterior surface of the stomach. When the ulcer finally perforates, these adhesions often protect against a general peritonitis. Sometimes, however, perforation into the peritoneal cavity occurs, resulting in fatal peritonitis. If the perforating ulcer reaches the splenic artery, fatal hemorrhage from this vessel sometimes results. The result is more or less serious according to the consistency of the adjacent organs toward which the perforation is directed. The least resistant is the spleen; it is often completely excavated. The least altered is the pancreas; as a rule, this organ suffers only partial induration. The ulceration may penetrate the organs and produce abscess (liver), fistulæ (transverse colon: most common;[2] duodenum, lungs, pleural cavity, gall-bladder, gastrocutaneous: very rare), or it may perforate the portal vein, causing simple or suppurative phlebitis. The progressing ulceration generally does not take place under the form of a purulent or gangrenous process; on the contrary, one layer after another very gradually disappears without anything special being observed.

---

[1] According to statistics of Welch, of 793 gastric ulcers, 288 were in the lesser curvature, 235 in the posterior wall, 95 in the pylorus, 69 in the anterior wall, 50 in the cardia, 29 in the fundus, 27 in the greater curvature.

[2] Stercoraceous vomiting may then occur.

Carcinoma frequently follows gastric ulcer, according to Lebert[1] in 9 per cent. of the cases. Exceptionally, in cases of scirrhus, the ulcer may greatly resemble small round ulcer with indurated walls; according to Welch,[2] this fact is to be considered in weighing the statements of those who report cases of carcinoma developing from round ulcer.

Exactly similar **ulcers**—as a rule, however, only one, occasionally (15 per cent.) several together—are observed in the **duodenum** up to the opening of the *ductus choledochus,* i.e., in that portion in which the acid gastric juice still exerts its digestive action. These ulcers have a rounded form, may be very variable in size, and are located chiefly in the upper horizontal portion of the duodenum, near the pylorus of the stomach. In healing, such marked shortening sometimes occurs from cicatricial contraction that the papilla is drawn toward, and in rare cases close to, the pylorus. Duodenal ulcers are much more frequent (3:1) than gastric ulcers and, like the latter, by perforation, which is more frequent than in gastric ulcer, may lead to acute and usually fatal peritonitis.

The degree of acidity of the gastric juice in duodenal ulcer varies. That duodenal ulcer usually exists in cases of so-called functional hyperchlorhydria, as Moynihan states, is by no means true. The conception that the pylorospasm induced by the hyperacid stimulus mechanicly irritates a duodenal ulcer adjacent to the pylorus appears to Kühn[3] to be established. If the spasm is arrested by neutralization of the excess of acid, by belladonna, or by introduction of acid-binding substances, the pain originating from the ulcer generally soon subsides. Direct chemic irritation of the ulcer is possible also through the strongly hyperacid gastric juice coming from the pylorus, and this is favored by an anatomic peculiarity of the duodenum which enables retention for some time of the acid gastric juice in the upper portion of the duodenum. Below the entrance of the ductus choledochus there is a distinct thickening of the circular muscular fibers, which occasionally forms a decided sphincter. Retention of the gastric juice in the duodenum after its passage through the pylorus, and, hence, its thorough admixture with the bile and pancreatic juice, are thus favored. The frequency of vomiting of bile on an empty stomach, and of hematemesis in duodenal ulcer, and likewise the often-observed dilation of the upper portion of the duodenum independent of duodenal ulcer cicatrix, are also thus explained. If the ulcer involves the papilla, icterus may develop.

---

[1] Deutsch. Arch. f. klin. Med., 1877, xix, 545.
[2] Pepper's "Syst. of Med.," ii, p. 360.
[3] Fortschritte der Medizin, 1911, No. 7, p. 146.

Hemorrhagic erosions, like ulcers, begin with hemorrhagic infiltration; they differ genetically, however, from simple gastric ulcer by the fact that they originate in hyperemic states of the gastric mucosa, most frequently in already existing catarrhal conditions and coincident with spasmodic contraction of the gastric and abdominal musculature (*e.g.*, in vomiting), and not as a result of arterial change. Hemorrhagic erosions, therefore, are preceded by affection of the mucous membrane. As a rule, they are numerous, small, flat, frequently only punctiform, seldom hemp-seed-sized losses of substance involving only the uppermost layer of the mucosa, being usually situated upon the top of the folds of the mucous membrane and distributed over the whole gastric surface, and at necropsy are often covered with a slightly brownish deposit. If the mucous membrane is covered with mucus, numerous, fine, brown puncta and striæ can frequently be seen within the mucous layer, which may be traced to the superficial defects in the mucous membrane. As a rule, only small, scarcely recognizable hemorrhages occur from these hemorrhagic erosions, while from true gastric ulcers due to erosion of large vessels fatal hemorrhages often originate. Hemorrhagic erosions heal without leaving macroscopicly visible scars; *ulcus rotundum,* on the other hand, heals with intense cicatricial contraction, which is the stronger the farther the ulcer has extended into the depth. Every intense cicatricial contraction is followed by constriction of the stomach, as a result of which the latter may be divided into two parts, often unequal in size. This deformity is designated as **hour-glass contraction** of the stomach, because the stomach in this state has a certain resemblance to an hour-glass. In rare cases the cicatricial contraction is so intense that the affected portion of the stomach is strongly stenosed (causing gastrectasis) or even impermeable. Occasionally ventricular ulcers develop from hemorrhagic erosions, when these become larger and deeper as a result of recidive.

Tuberculous and **typhoid** ulcers of the stomach are very rare.

Hernias, ruptures, are in great part due to congenital tendency or disposition[1] (*Anlage*); partly they are acquired. Strangulation of hernia is always caused by a disproportion of the *contenta* to the *continens,* which is manifest especially in the region of the neck of the hernial sac. The sequelæ of every internal strangulation are the same as in volvulus and intussusception (obstruction of the intestine by foreign bodies, stricture from cicatricial formation, marked stenosis from tumor; abnormal position, particularly axial torsion, noose formation, kinking): namely,

[1] See Malformations, p. 199.

intestinal occlusion, regurgitation of the intestinal contents into the stomach, and peritonitis.

Congenital hernial apertures may become closed by mild peritonitic states; sometimes they heal when a well-fitting truss is early applied. Frequently, of course, only diminution in the size of the hernial aperture occurs. The aperture is thus rendered less yielding and consequently the danger of incarceration is increased.

The most frequent form of rupture is **inguinal hernia.** It is usual to distinguish an external, or indirect, and an internal, or direct, form; the latter lies nearer the middle line internal to the deep epigastric artery and follows a quite straight and short course through the abdominal covering; the external form enters the internal abdominal ring, has a longer, diagonal canal; both protrude at about the same point.

When ingesta enter an incarcerated portion of intestine, such an alteration of the contents and of the intestine may occur that the contents cannot pass out and the rupture cannot be reduced. The danger of this state consists in an acute peritonitis which starts from the upper part of the intestine in front of the incarcerated portion. Phenomena of strangulation: congestive hyperemia up to hemorrhage (black-red appearance), develop in the rupture, but no gangrene; in this stage the rupture is still viable; soon, however, more or less intense watery secretions (so-called hernia water: *aqua herniosa*) occur from the surface into the intestine and the intestinal wall; hemorrhagic admixtures gradually develop. Bacteria from the intestinal lumen enter the hemorrhagic areas in the mucous membrane and a more or less distinct, always localized diphtheria develops. The real danger begins with mortification, at first within the true line of strangulation, and then also in the whole incarcerated portion. With necrosis the possibility of the penetration of intestinal bacteria and finally of perforation is offered; the whole mass becomes doughy, wrinkled; bacteria penetrate the intestinal wall and produce an acute peritonitis.

Intussusception (invagination) develops as a result of invagination of intestinal loops; this occurs frequently in children during the death agony, usually at a number of points, without any signs of inflammation, and is then always a simple agonal phenomenon. The intussusceptions occurring during life, which, as a rule, are fatal if not relieved by operation, are to be distinguished from this form. A portion of intestine with its mesentery may be forced by intestinal peristalsis so far into the adjoining, usually lower, intestinal segment that marked changes of position may result. The veins are strongly compressed by this invagination, and the lumen of the intestine is firmly closed. An inflammation which leads to agglutination develops at the point of invagination. In a favorable case

the invaginated portion may be cast off by a dissecting inflammation and be expelled with the feces. This is the only mode of spontaneous healing. Usually, however, fatal peritonitis, with or without perforation, results. The mucous membrane of the invaginated portion of intestine is hemorrhagicly infarcted, discolored, and frequently diphtheritic or gangrenous. The greatest changes of position in intussusception are ob-

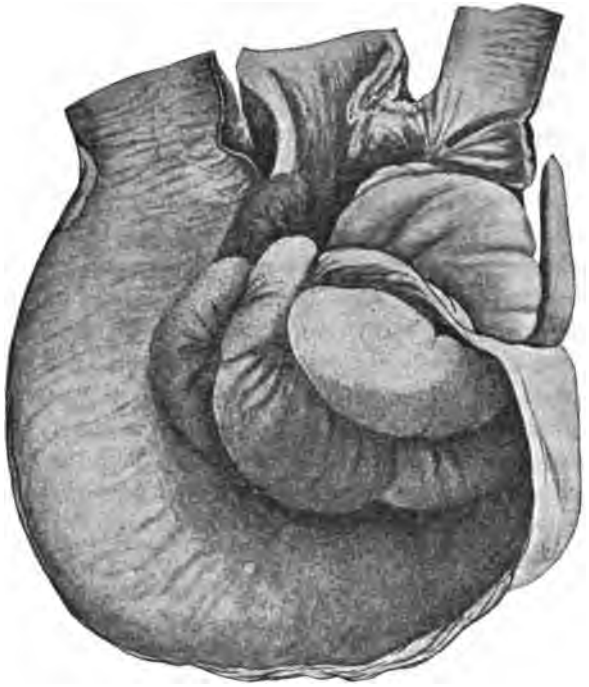

Fig. 388.—Invaginatio ilei in cecum. ⅓ natural size. (After *Langerhans.*)

served at the point of transition of the small intestine into the colon (through the ileocecal valve). (See Fig. 388.)

Axial torsion (volvulus) of the intestine may occur in almost all portions of the intestine, is most frequent in the small intestine and the sigmoid, and is favored by abnormal length or laxity of the mesentery or mesocolon. Torsion in the long axis occurs in the ascending colon and is favored by adhesions. Intense distention of certain segments by gas or feces may easily lead to angular flexion and kinking. Old peritonitic adhesions sometimes act like a hernial aperture, when an empty intestinal loop passes through a small opening and then—frequently under axial torsion—becomes strongly filled.

In **prolapsus ani** the rectum, with the mucous membrane, protrudes externally. This occurs sometimes in chronic catarrhs and in consequence of very violent straining, especially when the sphincter ani is relaxed; furthermore, in large tumors within the small pelvis.

Acute gastric dilation with occlusion of the duodenum by the mesenteric root, called also "duodenal ileus" and "arteriomesenteric occlusion," was first described by Rokitansky in 1863. It almost always begins with vomiting of variable severity. The vomited matter is never feculent, but, owing to reflux of bile into the stomach, consists of watery material which at first is bile-stained, later brown from admixture of blood. Transudation and development of gas in the stomach may attain a marked degree in a short time. Passage of stools and flatus is usually suspended. With a few exceptions there is gradually increasing dilation of the stomach: the upper part of the abdomen is markedly distended, while the remaining portions are still soft and compressible. With further progress general tympanitic distention of the abdomen occurs. In some cases this gastric distention may reach the acme within twenty-four hours. The temperature is usually normal, but the pulse is rapid and small; the patient goes into collapse and dies unless appropriate treatment is adopted. At necropsy the stomach is enormously distended, sometimes extending to the symphysis. There is no peritonitis and no secretion or deposits upon the intestines. The small intestines lie collapsed in the small pelvis, where they have been pushed by the distended stomach, and exert strong traction upon their mesentery. On lifting the stomach the duodenum also is found strongly distended up to the point where the mesenteric root passes over the horizontal segment. Here the duodenum is occluded, the tensely drawn mesenteric root with the superior mesenteric artery constricting the intestinal lumen.

The etiology is a matter of dispute. Most authorities state that the traction upon the mesentery is due to paralysis of the stomach walls, the bowels being secondarily pushed downward out of the abdominal space by the dilated stomach, strangulation of the duodenum finally resulting from traction of the mesentery. Others claim that the duodenum is first strangulated, then dilated, and this is followed by gastric distention. Quite recently C. Weinbrenner[1] has defended the possibility of primary strangulation of the duodenum. This view is comprehensible, he believes, when the anatomic relations at the point of occlusion are remembered. The superior mesenteric artery running in the root of the mesentery arises from the aorta at an acute angle, forming with the aorta a fork, open downward, through which passes the horizontal segment of the duodenum.

[1] Fortschritte der Medizin, 1911, No. 19, p. 433.

This portion of the duodenum, owing to fixation to the spinal column, is incapable of yielding to pressure, and in traction on the mesentery may be so compressed against the spinal column that its lumen is interrupted. If, for example, in the cadaver slight traction is made upon the mesentery above the promontory in the direction of the pelvic axis, the finger introduced through the jejunum into the duodenum will be constricted. While, according to Weinbrenner, it is conceivable that with certain length of the mesentery and an especial arching of the spinal column in dorsal position the weight of the empty collapsed intestines may exert traction which constricts the duodenum to a certain degree, he cannot imagine that this traction would suffice to effect complete occlusion unless the motor sufficiency of the stomach also was decidedly disturbed or some other factors were added which hold the intestines in the pelvis or in another manner continually aid the traction upon the mesentery. Landau and Rosenthal believe that the traction of the intestine hanging in the small pelvis may be aided and increased by the strongly distended urinary bladder lying above the pelvic inlet. In a case observed by Albrecht the strongly distended transverse colon caused pathologic traction of the mesenteric root by encroachment of space, and in a case reported by Haberer the small intestine, which was firmly adherent in a large hernial sac, exerted traction, and by chronic constriction of the duodenum gradually produced a secondary hypertrophy and dilation of the stomach. In Weinbrenner's case a tampon caused fixation and traction upon the mesentery.[1]

While primary paralysis and dilation of the stomach may cause duodenal occlusion, and probably this is most frequently the case, the question arises why, in some cases of the highest degree of gastric dilation, occlusion is absent. Various explanations have been offered, such as lordosis of the spinal column, defective position of the mesentery, especial form of the duodenum, a more horizontal course of the inferior portion of the

[1] The tampon, which was used to check diffuse hemorrhage after adnexa operation and subsequent fixation of the uterus to the abdominal wall, had been passed downward over the posterior surface of the uterus and so fixed a loop of intestine between the uterus and the promontory as to cause traction upon the mesentery in a manner analogous to that described above as occurring in the cadaver. Gastric distention became enormous in a short time; large amounts of bilious, but not feculent matter were vomited; the pulse became small and frequent (142), and rapid decline occurred. In brief, the case was desperate, death appearing imminent within a few hours. When, as a last resort, the patient was placed in the genupectoral position, vomiting ceased at once; after about a minute much flatus was spontaneously expelled through the anus; the intestinal activity was stimulated by enemata, and, after three-quarters of an hour, when the patient was replaced upon the back, the abdomen was flat and soft, the pulse strong, falling within a few hours to 110. Vomiting did not recur; the appearance was favorably changed, and, aside from some eructation, nothing remained in the succeeding days to recall the previous serious state, which without change of posture would have terminated fatally.

duodenum over the spinal column, mesenteric malformation, etc., but all these attempts at elucidation have insufficient anatomic basis to satisfactorily answer the problem.

General dilations involve most frequently the stomach: gastrectasia. The latter is very rarely caused by stenosis of the pylorus; it develops more frequently in habitual overloading of the stomach. The stomach wall becomes thickened by new formation of elements, especially the muscularis, next the mucosa and serosa. The dilation may be so enormous that the greater curvature touches the symphysis. This change sometimes produces the phenomena of intestinal occlusion, when, as a result of the dilation, the upper horizontal branch of the duodenum acquires a perpendicular direction, *i.e.,* forms an acute angle with the descending branch (kinking), or when, as a result of the intense dilation and filling, the lower horizontal branch is compressed at the point of passage through the *radix mesenterii.*

Megacolon is divided by H. Zoepffel[1] into two types: true megacolon (*megacolon congenita idiopathica*), and pseudomegacolon. In the first group no mechanic impediments can be found in the bowel to explain the dilation and hypertrophy; in the second group—pseudomegacolon—hypertrophy and dilation of the bowel are secondary to abnormal length and volvulus of the colon.

Partial dilations, *diverticula,* are more frequent than the diffuse ectases, and are congenital[2] as well as acquired. The *diverticula acquisita* are usually situated in the large intestine and generally form small, multiple sacculations of pea- to hazelnut- size. The acquired diverticula of the esophagus are found in the commencement of the esophagus as circumscribed, sac-like dilations, sometimes even in front of the isthmus; they generally originate as the result of cicatricial contraction (according to Zenker, traction and pulsion diverticula are to be distinguished). In addition, there are more uniform and spindle-shaped dilations above cicatricial constrictions and ectases without constriction. Diverticula of the duodenum are not rare; they are located in the *pars descendens,* in the neighborhood of the papilla, and directed toward the pancreas; they may attain the length of several inches. The *papilla duodeni* may be located beside or within the sacculated distention.

In the **jejunum** and **ileum,**[3] multiple diverticula sometimes occur close to the mesenteric attachment, where, as in the colon, the larger vessels penetrate the muscularis. Gastric diverticula

[1] Virchow's Archiv, Bd. 198, p. 119.
[2] See Diverticulum Meckelii.
[3] See Malformations.

are very rare and, likewise, are situated at the point where the larger vessels pass through the muscularis, *i.e.*, at the curvatures.

Among the **tumors** in the digestive tract, primary carcinomata are most frequent. Their seats of predilection are those naturally narrow localities which usually are subjected to surface irritation (mouth, esophagus, cardia, pylorus, ileocecal valve, cecum, hepatic and splenic flexures of the colon, sigmoid flexure, rectum, and anus). These carci-

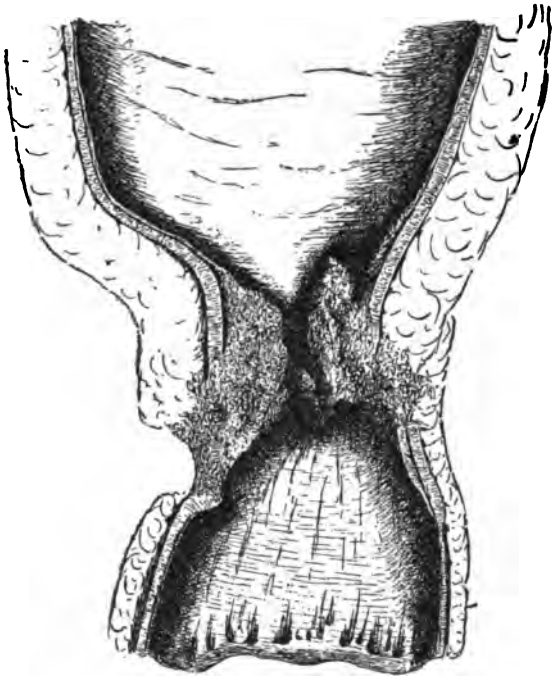

Fig. 389.—Stenosis carcinomatosa recti. ⅔ natural size. (After *Langerhans.*)

nomata very frequently lead to stenoses. In the stomach and intestine, **adenomata** (see Figs. 390 and 391) and **adenocarcinomata**[1] are comparatively frequent. Besides, sarcomata occur upon the tongue and in the stomach, and in the stomach lipomata (in the submucosa), myomata (in the muscularis), and fibromata. At the anus, hemorrhoids are the most frequent change. Metastatic tumor-nodules are

[1] According to S. Livierato (*Centbl. f. Bakt.*, Bd. 55, H. 6), gastric juice of healthy human subjects injected subdurally into healthy guinea-pigs exerts no toxic action even in doses of 1 c.c., while gastric juice of subjects suffering from gastric carcinoma injected in the same manner produces marked toxic symptoms in a dose of 0.1 c.c. If guinea-pigs are first treated with watery extract of mammary carcinoma and subsequently subdurally injected with the minute amount of 0.05 c.c. gastric juice marked anaphylaxis develops.

rare, most frequent in the stomach in carcinoma of the esophagus, in the duodenum in carcinoma of the pancreas, and in the rectum in carcinoma of the uterus.

Gastric carcinoma[1] (see p. 291) is one of the most frequent affections. According to the statistics of Reiche[2] on the mortality from carcinoma in the city of Hamburg in the years 1872-1895, of 4759 carcinomatous affections 2387 (50.2 per cent.) involved the stomach.[3] According to other statistics, 0.5 to 2.5 per cent. of the total deaths are due to gastric carcinoma.[4]

Other neoplasms of the stomach (*e.g.*, sarcomata, lymphadenomata, fibromata) are rare. **Sarcomata of the stomach** are relatively most frequent, Schlesinger[5] and Mintz[6] having collected 43 cases observed anatomicly and clinicly. As to the anatomic character of the sarcomata, most of them were lymphosarcomata, or round-celled sarcomata, though spindle-celled, fibro-, myo-, and myxo- sarcomata have been recorded. Gastric sarcomata may be primary or secondary, most frequently the former. The primary forms originate from the muscularis or submucosa, and do not at first involve the mucosa. With advance of growth, however, the mucosa, owing, no doubt, to tension and mechanic injury by the ingesta, soon becomes the seat of excoriations, which may result in partial disintegration of the neoplasm. The sarcomata usually exceed in size the carcinomata; they may attain very large dimensions, as in a case of myosarcoma observed by Brodowski,[7] in which the tumor weighed 12 pounds.

According to Th. Voeckler,[8] over 100 cases of so-called primary **carcinomata of the appendix** have been reported. The tumors are small, generally situated at the tip, rarer in other localities, and usually manifest the solid alveolar form of carcinoma. Milner has recently combated such an interpretation of the peculiar tumors which usually occur in young subjects and form no metastases. He regards these as neoplasms originating from inflammatory proliferation of the endothelia of lymphatic vessels, or of the epithelium of pathologic ingrowths of the mucous membrane. The cases described as alveolar carcinomata greatly resemble the solitary and multiple tumors of the submucosa of the small intestine, recently described by Oberndorfer, which were composed of epithelial

[1] H. Leo, Sitzungsber. d. Niederrhein. Gesell. f. Natur. u. Heilk. zu Bonn., Nov. 16, 1903.
[2] Deutsch. med. Woch., 1900, p. 135.
[3] See footnote, p. 287.
[4] Ewald, Krankh. des Magens, 3te Auf., p. 303.
[5] Zeitsch. f. klin. Med., 1897, Bd. 32, p. 179.
[6] Berlin. klin. Woch., 1900, p. 708.
[7] Virchow's Archiv, Bd. 67.
[8] Deutsch. Zeits. f. Chir., Bd. 105, p. 304.

cell-nests separated by muscle elements, and histologicly were undoubtedly carcinomata. On the other hand, the fact that these carcinomata, in contradistinction to appendicular carcinomata, attack almost exclusively individuals of advanced years, and that with these small and frequently multiple tumors of the small intestine a tumor has thus far never at the same time been found in the appendix, precludes for the present identification of the tumors. Also, the case described by Lejars as recurrent alveolar carcinoma of the appendix cannot be admitted as established, because the possibility of the existence of a primary carcinoma of the cecum cannot be excluded. Therefore, the question whether the cases

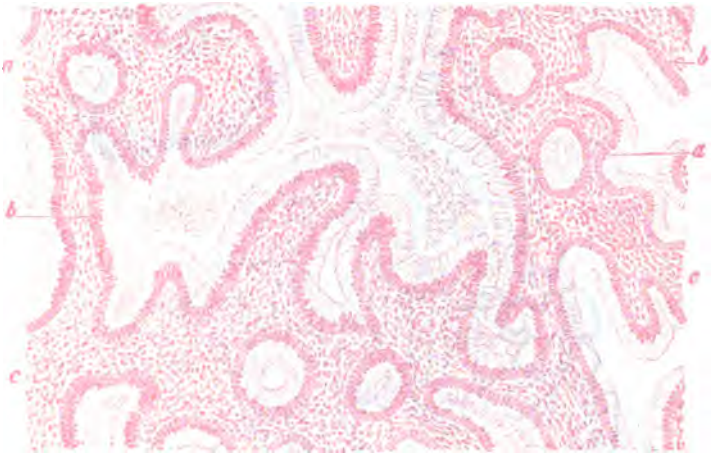

Fig. 390.—Glandular polypus of the intestine. *a*, transverse section of the gland tubules; *b*, longitudinal section of bronchial glands; *c*, richly cellular stroma. × 80. (After *Ziegler*.)

described as alveolar carcinomata of the appendix were genuine carcinomata must be regarded as undecided. Such tumors may, according to Voeckler, be provisionally designated as "carcinoids."

Several cases of **sarcoma of the appendix** have been reported.[1]

Animal parasites remain in the stomach only temporarily. On the other hand, the intestine is the abode of numerous parasites, especially of tape-worms, of the spool-worm (*Ascaris lumbricoides*), of intestinal trichinæ, of the whip-worm, oxyuris, ankylostomum, *Cercomonas intestinalis, Trichomonas intestinalis, Balantidium coli, Amœba coli,* etc. *Balantidium coli* may produce marked intestinal lesions (ulceration), and death may result from perforation. (See Animal Parasites, p. 356 *et seq.*)

Amyloid degeneration occurs quite frequently in the gastroin-

[1] Powers, N. Y. Med. Jour., Jan. 7, 1911.

testinal canal (see p. 146), and is a concomitant of general amyloid degeneration. The small intestine is most frequently affected, next the colon, seldom the stomach, tongue, and esophagus. The affection always begins in the small arteries of the mucosa and submucosa; often these alone show amyloid degeneration. Then the capillaries of the mucosa become involved. The affected portions are, as a rule, pale, often markedly mottled, red, and pale. In marked amyloid degeneration of the intestine the change can be recognized with the naked eye by the strikingly transparent, swollen, somewhat granular and peculiar dull to dry state of the

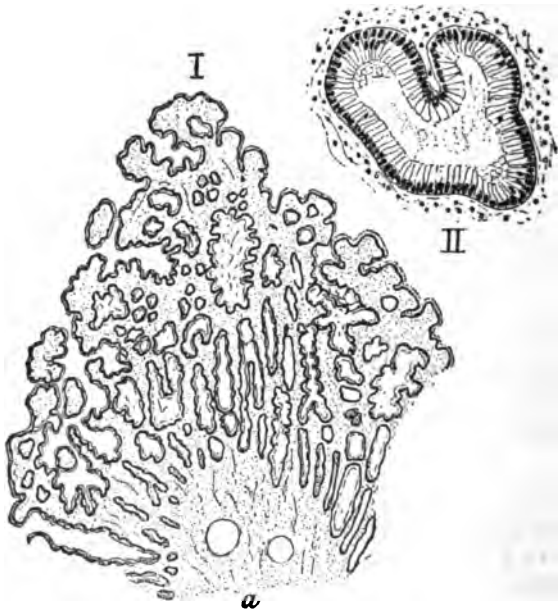

Fig. 391.—Villous papillary fibroadenoma of the rectum. I. Moderate magnification; *a*, submucosa. II. Tubule lined with cylindric epithelium; highly magnified. (After *Kaufmann.*)

mucous membrane. Then not only the vessels, but all the villi, of the small intestine usually present amyloid degeneration. As a rule, however, a specific stain or microscopic examination is required in order to render the diagnosis positive, especially from the pylorus upward. In severe amyloid degeneration the function is very greatly affected; on the one hand, digestion and absorption are diminished, and, on the other hand, there is a tendency to diarrhea.

From an examination of a case of primary pneumococcus phlegmon of the stomach and 30 cases of pathologicly altered stomach, Münter[1] concludes that

[1] Virchow's Archiv, Bd. 198, p. 105.

hyaline material originates in the different organs in various affections from various elements and as the result of various causes. **Hyaline substance** occurs in the stomach and intestine principally in the form of hyaline corpuscles, rarer as hyaline transformation of the walls and contents of blood-vessels. The ordinary hyaline bodies located in the connective tissue of the gastric mucosa originate from acidophile cells and not from plasma cells. The acidophile cells he regards as derivatives of polynucleated leucocytes, probably after incorporation of erythrocytes and utilization of their hemoglobin under the influence of various conditions (infection, thermic influences, defective blood-supply). Direct or indirect transformation of mast-cells after transformation into acidophile cells does not, according to him, occur. The hyaline corpuscles in the stomach, though inconstant and scanty, occur in large numbers with relative frequency in atrophy of the gastric mucosa, especially in cases of pernicious anemia, liver cirrhosis, and in polypi; less constant, although sometimes more profuse increase has been described in phlegmon and carcinoma, and occasionally in ulcers and proliferative inflammation.

PERITONEUM.

The peritoneum should not be considered as an entity. Every peritonitis is originally a concomitant affection of the peritoneum. (See Tuberculosis, p. 460.) If fluids are exuded, these change their position; only such exudates as are firm remain at the point of origin or affection. Inflammatory exudates which tend to coagulate are derived principally from organs which have a peritoneal covering (liver, spleen, ovaries, uterus), while the watery exudations are furnished chiefly by the richly vascular omentum.

In the abdominal cavity, three forms of secretions are distinguished according to the composition:—

1. Watery secretions: ascites. (See p. 96.)
2. Fibrinous secretions, which are characterized by the formation of coagula.
3. Richly cellular secretions:—
   (*a*) Hemorrhages.
   (*b*) Suppurations.

In simple watery secretions (*hydrops frigidus* of the ancients, ascites), no essential changes occur in the peritoneum. The epithelia swell and desquamate freely, especially after death. In fresh cadavers the fluid may be absolutely free from solid constituents. Admixture of solid constituents is generally an indication of the presence of irritation.

Ascites is a passive process which is caused by congestion in the portal vein area. Under certain circumstances, of course, the portal vein may be obliterated without the occurrence of ascites. The portal vein has numerous anastomoses: for example, only part of the vessels of the uterus go to the portal vein, a part to the inferior vena cava. In interruption of the current, the blood may flow from the portal vein by

way of these collateral channels into the inferior vena cava. The same relations are repeated in the upper abdominal region. The collateral channels are of varying width, inasmuch as great variations occur in the vascular apparatus. Congestive processes in the portal vein are chronic in proportion to the changes in the liver.

The alterations of the liver which cause ascites may be primary (protopathic) and secondary (deuteropathic: *e.g.*, in cardiac diseases). In both instances the change of the vena porta is due to the inability of the blood to flow off through the liver. Congestion and dilation occur especially in the splenic vein. Ascites itself originates principally from the omental vessels, secondly, from the intestinal vessels.

Cardiac diseases which cause congestion produce not only ascites, but hydrops of the whole body: anasarca.

An acute hydrops develops in hernias as *aqua herniosa,* hernia water, between the protruded portion of the peritoneum and the prolapsed intestinal loop; here the disturbances in the venous circulation are most strongly manifest in the intestine, owing to constriction of the veins inside of the hernial opening. The hernia water is at first clear; later, it may become red by admixture of blood.

The abdominal cavity belongs to the sacs which in the normal state should contain no fluid. The total exudation of water is said to be so slight that it only moistens the surfaces and facilitates movements of the organs. Every measurable quantity of fluid in the peritoneal cavity is really an ascites.

In *hydrops calidus,*[1] in addition to fluid, inflammatory phenomena are found in the peritoneum; hence, *ascites inflammatorius,* or *peritonitis serosa.* In this condition the omentum is generally altered: omentitis. This *hydrops calidus* occurs as simple peritonitis, in chronic tuberculous peritonitis, and in carcinomatous peritonitis.

Chylous ascites (*ascites chylosus*) is distinguished from the forms already mentioned by the fact that chyle is found in the abdominal cavity. Chyle is an emulsion the fat-droplets of which are so minute that they are barely recognizable as puncta. In *ascites chylosus* chylorrhagia occurs without any demonstrable evidence of an aperture or perforation (just as little as in hemorrhage by diapedesis). As a rule, *ascites chylosus* indicates the beginning of an inflammatory process. This is still more the case in *ascites lymphaticus,* which coagulates spontaneously in the air, but never contains fat in minutest subdivision, as does *ascites chylosus.*

In *ascites chylosus* and *lymphaticus* there are distinct phenomena of

[1] *Calidus:* warm.

irritation, but never fibrin. If fibrin is exuded, this is always evidence of the presence of fibrinous inflammation: *peritonitis fibrinosa.* The latter leads, as a rule, to cohesion and later to firm adhesions. This phenomenon is most marked in the greater omentum: *omentitis fibrinosa adhæsiva.* Part of the omentum may be adherent to the surface of the spleen, uterus, ovaries, or with another portion of the omentum itself. In this event the omentum is frequently pushed upward and lies in folds; the individual folds thus produced become adherent in consequence of the fibrinous exudation. The omentum thus gradually becomes shortened and thickened until it finally lies as a thick, firm cord upon or above the transverse colon. In organization of the fibrin the latter is substituted by connective tissue; this is associated with active vascularization in all parts of the omentum.

These processes are frequently observed in eruption of tubercles and in disseminated carcinoma metastases.

Chronic thickenings of the peritoneum develop principally as the result of chronic or recurrent fibrinous inflammations which frequently are associated with proliferations in the surface or organs. These thickenings are either partial, macular, nodular, or general; they sometimes have a more fibrous, sometimes a more semicartilaginous, consistency: *callus fibrosus* (fibrous callosities). As a rule, diminution in size and disturbance of function are associated with this, *e.g.,* sterility due to superficial fibrous oöphoritis. These are sclerotic processes which do not reach the high degree in hollow organs—in the gastrointestinal canal—as in the other organs. Here the surface of the gastrointestinal canal is sometimes occupied by small growths and fimbriæ: *peritonitis villosa;* these may contribute to increase the exudation. Villous peritonitis is sometimes observed in tuberculous processes.

In **purulent peritonitis** micro-organisms are always present in the pus. These may enter the abdominal cavity through a perforation or through continuity of the tissues. Not rarely in the female sex the Fallopian tubes are the portal of entrance, frequently in gonorrheal salpingitis and in the puerperium. Occasionally perforation may occur without the development of purulent perforative peritonitis, *e.g.,* in perforation by needles when these pass very slowly through the wall, leaving no holes.

Aside from bacteria, animal parasites, especially round-worms, penetrate the intestinal wall and enter the abdominal cavity without discoverable perforation or subsequent purulent peritonitis. In trichinosis—invasion of trichinæ, which likewise make no true openings—irritative states exist in the interior and exterior of the intestine; even fibrinous peritonitis may develop externally.

In deeply extending ulcerative and gangrenous processes of the intestinal wall, vegetable parasites may very easily enter the abdominal cavity in the absence of perforation through the defective intestinal wall and produce **purulent peritonitis.**

In every purulent peritonitis a local point of origin should always be sought; such, however, cannot always be found. The most frequent local affection is perityphlitis (appendicitis); in rare cases chronic diverticula may be the source of peritonitis in a manner similar to the vermiform appendix, when ulcerative destruction and suppuration of the sacculated (diverticulum) portion of the intestinal wall have occurred.

Pure purulent peritonitides are rare; as a rule, the condition is one of mixed, fibrinopurulent exudations: *peritonitis fibrinopurulenta.* In perforative peritonitis occurring in connection with gastric or duodenal ulcer, inflammations of the vermiform process, trauma (crushing, gunshot wound, or stab wound), perforation of the stomach or small intestine by swallowed, sharp-pointed foreign bodies, tuberculous or typhoid ulcers, etc., other masses, especially particles of food or feces, are usually found in the abdominal cavity in addition to the fibrinopurulent exudate. In this case the exudate may have a distinctly fecal odor and sometimes even a fecal color: *peritonitis stercoralis.*

Lennander emphasizes the hopeless prognosis of those cases of peritonitis in which the serosa is reddened and deprived of its endothelium, the intestine paralyzed and distended, and the amount of pus insignificant, as compared with those cases in which the intestinal serosa, although bathed in pus, is pale and smooth. The great danger, according to Lennander, lies in rapid occurrence of alteration in the contents of the ileum and of the intestinal coats, whereby the toxicity of the former is increased and the intestinal walls so altered that they cannot prevent penetration of the micro-organisms. The sequelæ of intestinal paralysis are, therefore, increased general intoxication from resorption of a toxic intestinal content and augmented general infection from migration of intestinal microbes into the lymph- and blood- vessels. Intestinal paralysis may be induced also by intense cooling of the intestine on exposure during operations or in injuries. The most grave peritonitides are the dry forms progressing with severe general symptoms. The general infection (intoxication) dominates the pathologic picture. On the basis of the active resorption an exudate worthy of note cannot form; what is found may be regarded almost as a culture of one or more species of microbes. In dry peritonitis Lennander not infrequently received the impression that the infection and inflammation spread along the subserous lymph-channels, exactly as in erysipelas of the skin, for which reason he designated the process as *erysipelas peritonei.* As a result of the drying, and also of the manipulations at operation, part of the endothelial cells die. It is always important to remember that the bacteria collect upon the serous surfaces; in examination, therefore, tissue scraped from the serosa should be used. As regards the significance of the *Bacterium coli commune,* Lennander is still in doubt, although he recognizes it as virulent and pyogenic. Here it is a question of infection by continuity, the microbes growing along the lymph-channels of the intestinal wall and through the intestine into the peritoneal cavity.

There may be mono- or poly- infection. In the blood of the heart of a case he found a streptococcus and a bacillus resembling the *Bacterium coli commune.* Seliger has shown[1] that, by migration through the intestinal wall, the *Bacterium coli commune* becomes pathogenic and its virulence is increased. According to recent investigations, the colon bacillus is the principal germ, and the development of peritonitis is supported not by inhibition, but by hastening of resorption. Peiser made methodic blood examinations in experimental bacterial infections of the peritoneum, cultures of *Bacterium coli commune* usually being employed, and found a decided inhibition of bacterial resorption four to six hours after infection. If the body is too greatly weakened to retard resorption, the attracted phagocytes and alexins are consumed even in the body (*e.g.*, by the amount of bacteria injected directly into the blood-channels during the experiment); countless increase of the bacteria occurs in the abdominal cavity, and the body succumbs under the manifestations of peritoneal sepsis.

As regards the **central nervous system,** P. Seliger[2] states that the pathologic effects of the colon bacillus may be produced in two ways: either the toxins elaborated by the bacilli penetrate the brain and spinal cord, and there undergo a union with certain cells which is damaging to these structures, or the bacteria themselves migrate to the central nervous system and there manifest their pathologic action. He draws attention to the fact that the colon bacillus very frequently causes disturbances of the central nervous system. Here he raises the disputed question under what conditions the germ, which is almost always saprophytic, becomes pathogenic. He quotes Moll as saying:[3] "Why the *Bacterium coli,* which, as a rule, is an intestinal parasite, produces in certain cases severe affections of the bladder and from there gives rise to severe general infection (colisepticemia) is still obscure." According to Lindemann,[4] protection against the bacterium is provided principally by the living epithelial cells of the intestine. In Wredens's experimental investigations, every injury of the epithelium of the colon in the region of the prostate or higher was followed by cystitis. In infection of the urinary passages the colon bacillus of the intestinal tract plays a rôle, entering the bladder from the colon through the lymphatic current. Penetration of the intestinal wall by the bacteria and their migration into adjacent parts may easily be explained if, either at a circumscribed focus or over a large area of the intestine, alterations exist which cause interruption of the continuity of the intestinal mucosa. Coprostasis, whether due to mechanic causes, volvulus, invagination or inflammatory alterations (*ileus paralyticus*), also is mentioned by Seliger. The pathogenic action of the colon bacillus is referred by Denys and von den Bergh[5] to a lesion of the intestinal tract which makes possible resorption of the toxin; this produces hyperemia and desquamation of the epithelium and thus causes greater resorption of the bacilli or their products. As proof of the affinity of the colon bacillus or its toxins for the central nervous system, Seliger refers to the great frequency of convulsions in intestinal irritation in children and to the presence of colon bacilli in the cerebral serum, and Roskoi[6] mentions the frequent occurrence of eclamptic attacks in connection with coli infection of the urinary passages in children. Semon

[1] Fortschritte der Medizin, 1911, No. 26, p. 607.
[2] *Ibid.*, No. 23, p. 536.
[3] Prager med. Woch., No. 39, p. 501.
[4] Med. Klinik, 1910, p. 1255.
[5] Deutsch. med. Woch., 1910, No. 6, p. 160.
[6] Med. Klinik, 1910, p. 1376.

observed polyneuritis and Korsakoff's psychosis following colipyelitis during gravidity. Moll[1] saw colimeningitis (*Bacterium coli* in pus from the brain) following colicystitis. Lindemann observed in infants a leptomeningitis due to the *Bacillus coli*, and also stupor, delirium, and convulsions in colisepsis. Especially the so-called intestinal convulsions of children, observed in great flatulence and meteorism of the intestine, appear to find explanation here.

An already existing chronic adhesive peritonitis may be converted into a purulent process when the pus collects within the adhesive bands or upon the surface and forms sacculated (encapsulated) foci. These may rupture from without into the interior of the intestine. This, then, is an ulcerative peritonitis perforating from without, in which the external layers of the wall are usually more extensively destroyed than the mucous membrane. This form is often produced by foreign bodies (metals, etc.), which are the carriers of infectious material. Extra-uterine pregnancies also produce peritonitis in the true pelvis (*peritonitis pelvica*) and sometimes terminate in perforation into the intestine, so that macerated fetal parts break through and are discharged with the purulent stools. As intestinal ulcers in general manifest no tendency to suppurate, every purulent stool should arouse the suspicion of the existence of abdominal or extraperitoneal suppuration.

Purulent peritonitis, by gradual and continuous extension, may be followed by malignant pleuritis and finally also pneumonia (*per contiguitatem*), or the infectious germs enter the blood-channels through the peritoneum and produce metastatic abscesses in various localities, *e.g.*, in the lungs.

The chemic, toxic substances derived from the micro-organisms present in purulent peritonitis cause paralytic states of the intestine through action upon the muscularis, so that peristalsis ceases and the intestine becomes strongly distended with gas: tympanites.

The chief point of origin of **perityphlitis** is the vermiform process (appendix). This has a quite variable position and length; sometimes it runs horizontal, sometimes parallel, with the ascending colon; sometimes it extends into the true pelvis, and occasionally it is retrocecal. The normal position is the right iliac fossa.

The vermiform appendix is oftener assumed to be absent than really is the case. Examination during life cannot serve as proof of lack of the appendix, since it may have been completely destroyed in an inflammatory mass; even in a cecum which is neither inflamed nor thickened it may be concealed beneath the serosa, incision of which reveals it. In several instances the appendix has been found intussuscepted into the cecum.

---

[1] *Loc. cit.*, p. 502.

The causes of perityphlitis are variable; usually it is an ulcerative process caused by the presence of concrements (stones, coprolithiasis; see p. 143). As a rule, these stones in the vermiform process are elongated in shape and lamellated in structure (see Fig. 392); they are of the same composition as hard fecal masses (scybala[1]), contain feces, epithelia, and pus-cells, and are bile-stained. Disposition for stone formation is favored principally by undigested ingesta, rarely kernels and stones of fruits which enter the vermiform appendix from the cecum and are there retained by unfavorable position, narrow opening, etc. These stones cause inflammations, afterward ulcers, then perforation, and finally peritonitis. Inflammation, ulceration, peritonitis, and perforation may develop in an entirely similar manner from retained fecal masses or foreign bodies in diverticula of the colon. The essential cause of the

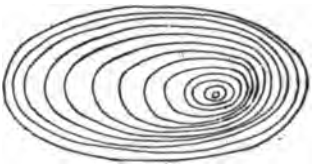

Fig. 392.—Enterolith.

suppurative inflammations are micro-organisms, particularly the *Bacillus coli communis,* streptococci, and staphylococci.

The cecum is not entirely covered by peritoneum, the posterior surface always bordering on retroperitoneal adipose tissue. In perforation of the cecum posteriorly, retroperitoneal phlegmon develops. This not infrequently occurs also in connection with inflammation and perforation of the vermiform appendix.

In simple catarrhal secretions in the vermiform appendix, retention of the catarrhal material, dilation and cystic formation may occur: cystis mucosa. In this condition obliteration of the portion in front of the cyst frequently occurs. On the other hand, the narrowing, which often develops from cicatricial contraction, following ulcerations may be the cause of the retention. When the vermiform appendix is strongly distended by accumulation of mucus and the contents stagnate for a long time, the mucous material usually becomes more watery and liquid in consistency, so that the dilated vermiform process appears to be filled with water. This change is designated as *hydrops cysticus processus vermiformis,* or dropsy of the appendix. (See Dropsy, pp. 97 and 755.)

[1] *Skybalon:* excrement; hard fecal matters dejected in hard lumps.

Hemorrhages develop in the abdominal cavity:—

1. From rupture of the vessels, *e.g.*, ectopic pregnancy, in contusions and penetrating wounds. Rupture of the spleen and liver are especially dangerous, owing to the profuse bleeding. Rupture of an aneurism of the abdominal aorta or other large vessel also generally results in fatal hemorrhage.

2. From inflammations: hemorrhagic peritonitis. The extravasates frequently originate from new-formed vessels. These have a very thin wall and, therefore, rupture very easily on variations in blood-pressure. Large blood tumors: *hæmatoma retrouterinum* and *retrovesicale*, may thus finally develop in the *cavum retrouterinum* in the female and in the *cavum retrovesicale* in the male. Here the peritonitic phenomena are more or less obscured. (See p. 213.)

In the abdominal cavity small fat-lobuli occasionally separate from the surface of the colon (the so-called *appendices epiploicæ*) and omentum, after axial torsion and erosion of the afferent vessels. After a time these **free lipomata** usually possess a thick, hard peripheral layer and a lipomatous nucleus. Cystoid transformation of the fat-tissue frequently occurs in the interior of these bodies as a result of disintegration of the fat-cells and liberation of the fat they contain; on incision the fat then flows out as an oily mass. On long duration this fat may also be absorbed and a cyst develop.

Air sometimes enters the peritoneum at operations and in trauma, uniformly infiltrating, as it were, the tissues. This emphysema is to be distinguished from the cadaveric form produced by putrefaction and from gaseous emphysema due to the *Bacillus aërogenes capsulatus*.

Tumors.—The retroperitoneal adipose tissue often is the point of origin of lipomata, while lymphomata and lymphosarcomata may develop from the retroperitoneal lymph-glands. Pedunculated fibromata, which occasionally attain the size of a hazelnut, also considerably larger (up to the size of a man's head), sometimes develop from the subserosa of the stomach and intestine. Carcinomata of the peritoneum are principally metastatic tumors; primary carcinomata, psammocarcinomata, and endotheliomata, however, also occur. Colloid carcinoma (see p. 285) is frequently primary in the peritoneum.

Of the **parasites** in the abdominal cavity, *Echinococcus* and *Cysticercus cellulosæ* are very rare. Besides these, *Pentastomum denticulatum*, *Oxyuris*, *Ascaris*, and *Filaria sanguinis* have been observed.

LIVER AND SALIVARY GLANDS.

LIVER.

THE liver is a large gland composed of a number of small lobuli (acini) which have the same structure in all parts of the organ, and, exposed to the same influences, all of them frequently present the same pathologic manifestations. Thus, pathologic states often involve the whole organ and always occur in very distinct form in the same portion of the acinus. Also, physiologic fatty infiltration, for example, very commonly is macroscopicly so distinct that, from the experience which teaches that the peripheral zone of the acini is its site of predilection, one might be led to conclude that wherever the characteristic yellow color of fat is observed this indicates the peripheral zone of the acini. True as this often is, there are occasional exceptions, and in these the false conclusion here mentioned as an example would lead to error.

The **vascular system** of the liver is very complex, the great volume of venous blood serving for function being conveyed from the so-called hepatic circulation through the portal vein, while nutrition with arterial blood takes place through the hepatic artery.

After entering the liver the portal vein branches and finally divides into capillaries within the acini. These capillaries penetrate the acinus from the periphery toward the center, where they unite to form the central (intralobular) vein, the blood of which flows to the hepatic vein. The liver-cells within the acini receive blood solely from the portal vein. The hepatic artery, the branches of which possess numerous anastomoses, supplies the walls of the blood-vessels (hepatic and portal vein and hepatic artery), the bile-ducts, and the liver capsule. The blood of the hepatic artery is conveyed through the capillaries and corresponding venous branches into small branches of the portal vein. The blood of the hepatic artery, therefore, enters the capillaries of the acini indirectly, *i.e.*, circuitously, by way of the portal vein; nowhere does the artery directly communicate by its capillaries with the capillaries of the acini. Accordingly, the acini receive blood first only from small branches of the portal vein; the latter, again, receive blood partly from the larger portal vein branches and the trunk of the portal vein, partly from the hepatic artery. When the portal vein is occluded (compression, embolism, thrombosis) blood may be conveyed to the acini by way of the hepatic artery. The anastomoses between the portal vein and the hepatic artery explain why judgment of the sequelæ of occlusion must depend chiefly upon the locality of the occlusion. Occlusion of the smallest portal branches at the point of entrance into the acini, *i.e.*, on the distal side of the anastomoses, precludes collateral blood supply from the hepatic artery.

The **secretion** of the liver is conducted through the biliary channels, which originate within the acini, but soon leave the latter and run between them. Between the acini, usually united with the biliary ducts (see Fig. 393), are located the branches of the portal vein and hepatic artery, so that it may be stated as an axiom that these three vascular systems, included in the term "portal vessels," always are interacinous, the small hepatic veins, on the contrary, intra-acinous.

The portal vessels form common strands which, like a cable, are united by a slight amount of fibrous connective tissue, which is derived from Glisson's capsule and with this constitutes the only connective tissue present in characteristic arrangement in the liver under normal conditions. The hepatic veins (the intra-acinous as well as the large trunks) are not provided with such an adventitial sheath, and in this respect, as well as by the fact that they always are unaccompanied by another kind of vessel, they are distinguished from the corre-

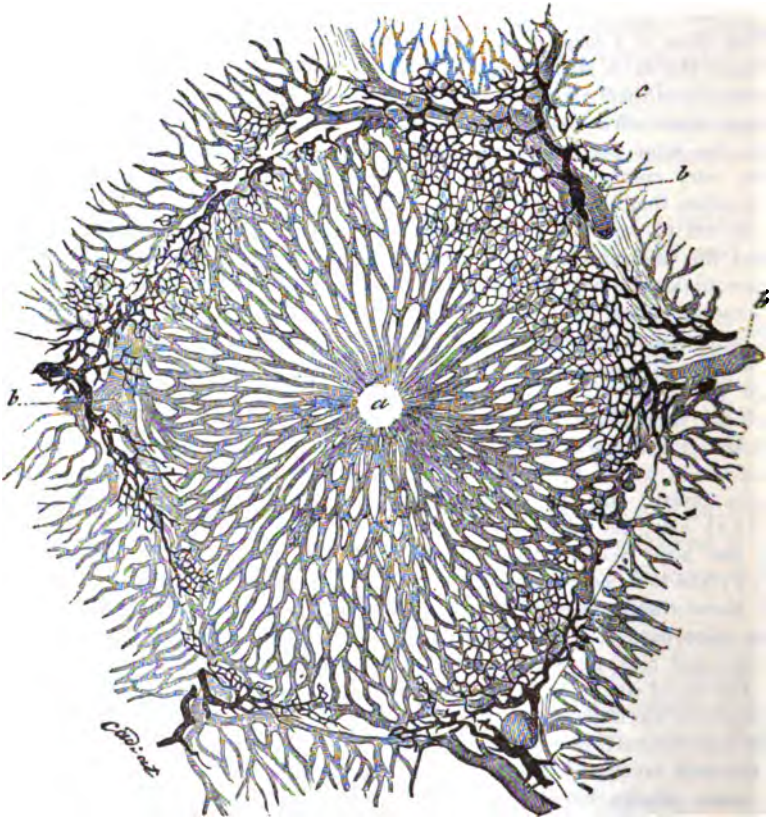

Fig. 393.—Lobule of rabbit's liver, vessels and bile-ducts injected. *a*, central vein; *b, b*, peripheral or interlobular veins; *c*, interlobular bile-duct. (After *Cadiat.*)

sponding portal vessels. Isolated fibers and a scanty number of spindle- and stellate- shaped (so-called Kupffer's) cells are found also within the acini after careful removal (by brushing) of the parenchyma cells, but they never form a fibrillated tissue and, therefore, may ordinarily be disregarded. If, without employment of special methods for demonstration of individual fibers, even a slight amount of fibrous connective tissue is seen within an acinus, this may justly be regarded as abnormal.

If a vessel is found anywhere upon the cut surface of the liver, knowledge of

its anatomic position can be obtained only by determination of the above-mentioned numeric relationship. A solitary vessel belongs to the venous system; two or more, not separated by liver-tissue, belong to the group of portal vessels. The largest vessel of this group is usually the portal vein; on the other hand, the strikingly thick walled artery is much smaller; the biliary ducts not infrequently have a greenish-yellow color, due to cadaveric imbibition of bile.

The larger hepatic veins are further distinguished from the other vascular structures by the fact that their walls appear macroscopicly as though pierced with a fine needle; this is due to the fact that the numerous *venulæ centrales* of the adjacent acini do not first unite to form larger trunks, but enter directly the large vessel. Between are seen the ostia of the larger branches, as in other vessels.

The limitations of the individual acini are noticeable in the normal liver only



Fig. 394.—Section of a portal canal. *a*, branch of hepatic artery; *v*, branch of portal vein; *d*, bile-duct; *l*, *l*, lymphatics in the areolar tissue of Glisson's capsule which incloses the vessel. (After *Schaefer*.)

in certain portions of the cut surface, *i.e.*, when the portal vessels (several openings) are cut through, while the central portion of the acinus, in case it has been cut transversely, is characterized by the vein (solitary vessel!). Good sections of the acini, verticly to the vein, are obtained when incision is made in the direction of a small branch of the portal vein.

In the human liver the individual acini are not separated by septa, as in the liver of the pig. Connective tissue in distinctly recognizable amount is found only in the neighborhood of the branches of the portal vein, as the so-called capsule of Glisson.

The liver parenchyma is composed of the liver-cells.

In diseases of the liver all the acini are generally involved; affections limited to small areas are rare.

Deviations in external conformation are partly congenital, partly acquired. The latter originate essentially as the result of death of certain parts and the persistence of compensatory enlargement of other parts.

When the liver is larger than normal, it is generally called **hypertrophic**; if it is smaller, **atrophic**. Three forms of atrophy are distinguished: **red**, **brown**, and **necrobiotic** atrophy.

Simple atrophic processes in which the whole liver becomes smaller as a result of diminution in the size of the individual liver-cells, and the vessels therefore more congested, present the form of so-called **red** or **simple atrophy.** In this condition the individual acini are small, and quite uniformly red on incision, while in the normal liver only the center of the acini appears red, the periphery grayish yellow as the result of **physiologic fat infiltration.** The smaller and more atrophic the cells, the greater, as a rule, is the congestion of the capillaries,

Fig. 395.—Brown atrophy of the liver. Fresh section. (Zeiss Apochr., 16; Comp. Ocul., 4. After *Langerhans.*)

Fig. 396.—Two liver-cells with brown (in the illustration shown black) pigment from an atrophic brown liver. (Zeiss Apochr., 16; Comp. Ocul., 8. After *Langerhans.*)

the color of the blood obscuring more and more the color of the liver parenchyma.

In **brown atrophy** also the individual liver-cells and, therefore, the acini and the whole liver are smaller. The number of cells, however, is not diminished. The cells contain quite dark-brown, granular pigment, which at first is present only in the center of the acini around the central vein, later also in the intermediate and peripheral zones. In extreme cases the brown pigment imparts to the whole liver a peculiar dark-brown coloration.

In contradistinction to these general atrophies stands that form which often attacks only one part of the organ, the termination of which is necrobiosis of the affected portion of the liver. Here the process is fatty metamorphosis (see Fig. 399) and disintegration of the liver-cells.

The disintegration usually involves only individual areas, but may extend throughout the whole organ, as in acute yellow atrophy of the liver. The fatty metamorphosis is either primary, caused by direct nutritive disturbance, or secondary, which constitutes the sequela of parenchymatous inflammation.

To the partial necrobiotic processes belongs lacing atrophy, due to pressure of a corset. The pressure compresses the vessels and thus leads to direct nutritive disturbances and disappearance of the parenchyma. In consequence of this, a furrow develops at the point of pressure.

Partial atrophy as the result of pressure occurs also in **nutmeg liver** (*hepar moschatum*). The atrophy begins in the center of the



Fig. 397.—Marked congestion of the liver with beginning nutmeg markings. At the junction of the inner with the middle third of the acinus the atrophy of the liver-cells is farthest advanced. Fresh section. (Zeiss Apochr., 16; Comp. Ocul., 4. After *Langerhans*.)

acini and extends slowly toward the periphery. Nutmeg liver owes its name solely to the peculiar coloration of the cut surface, which has a striking resemblance to the cut surface of a nutmeg. (See Fig. 397.) As in the latter, reddish-brown alternates with yellowish-gray markings in peculiar dendritic form. So soon as the return flow of venous blood into the right heart is obstructed, congestion of the hepatic veins occurs. This congestion is accompanied by dilation of the capillaries in the central zone of the acini. The liver-cells are thus encroached upon, and their nutrition is disturbed. They become smaller and finally die by fatty metamorphosis, partly with the formation of brown pigment. The nonatrophied peripheral portions of the acini may remain unaltered or, what is not infrequent, be the seat of fatty infiltration or fat retention. Nutmeg liver, therefore, denotes the condition of striate atrophy with intense engorgement of the vessels.

Slighter degrees of congestion are quite frequently observed in the liver; they occur in all pulmonary and heart affections which result in congestion. (See p. 42.) At first only widening of the capillaries in the central area is noticed as a result of greater engorgement. From this a permanent state gradually develops, so that the relation between the diameter of the capillaries and the width of the liver-cells is altered. The capillaries become wider—double and more times as broad as in the normal state—and the liver-cells gradually become narrower. While ordinarily the capillaries are scarcely as broad as the nuclei of the liver-cells, the capillaries and liver-cells may now be of equal width. The liver-tissue on microscopic examination thus acquires a reticulated appearance, the usually closely arranged liver-cells being widely separated.

The liver is to a high degree capable of taking up fat; the appropriation of fat is always associated with enlargement—swelling—of the organ, because the fat is deposited in the parenchyma. This **fatty infiltration** occurs exclusively by way of the vena porta and generally involves only the cells of the peripheral zones of the acini. In this fatty infiltration of the liver-cells medium-sized and larger fat-drops are found in small number in the cells, while in fatty metamorphosis of the liver-cells only very minute fat-droplets are to be seen, which at first are isolated, but later rapidly increase in number. Under certain conditions a decision as to whether fatty infiltration or fatty metamorphosis is present may be difficult, especially when liver-cells which already are infiltrated with fat die by fatty metamorphosis, or when, as is observed especially in children, under the action of medicinal doses of alcohol, the liver-cells rapidly become filled with fat. In addition to large, isolated drops of fat, the remaining space of the cell is sometimes filled with fat-drops of irregular size and partly with minutest fat-droplets. (See Fig. 399.) In simple, uncomplicated fatty infiltration the fat-droplets manifest a decided tendency to coalesce to form a single large drop within each cell.

After every meal rich in fat a certain degree of fatty infiltration of the liver occurs which, however, under normal conditions, disappears within a few hours. This is, therefore, a physiologic fatty infiltration. The pathologic state begins only when the deposited fat no longer disappears, but accumulates in constantly increasing amount. This state is due to excessive infiltration and retention; here the cells, as the result of a kind of paralytic state, lose the ability to part with the fat. For fat retention occurs not only in very well nourished and very obese individuals, but often, indeed, also in very poorly nourished and greatly emaciated persons, *e.g.*, in consumptives. The highest degrees of fatty liver are characterized by considerable enlargement of the organ in all its dimensions, with rounding of the anterior

sharp border; by smoothness of the surface and very firm consistency, and by a quite uniform, yellowish, smooth, and very opaque cut surface. The acini are enlarged and difficult of recognition; on incision an abundant deposit of oily fat is left upon the knife. This retention is favored by weakening, paralyzing poisons, for example, alcohol, and also by antimony and arsenic. In fatty liver the cells, even when they are filled *ad maximum* with fat, do not die; they may remain in this state for a long time, while in fatty metamorphosis the organic structure is rapidly destroyed.

Fig. 398.—Fresh section of the liver with peripheral (darker) fat infiltration and several (lighter) tubercles in the periphery of the acini. (Zeiss Apochr., 16; Comp. Ocul., 4. After *Langerhans.*)

Fig. 399.—Liver-cells with fatty infiltration and fatty metamorphosis. *a*, large fat-droplets (fat infiltration); *b*, numerous, quite uniform, small fat-droplets (fatty metamorphosis). (Zeiss Apochr., 16; Comp. Ocul., 4. After *Langerhans.*)

In the category of this last process belongs **acute yellow atrophy of the liver.** This is observed most frequently in pregnant women, in severe sepsis and after phosphorus poisoning, seldom in severe icterus (in occlusion of the *ductus choledochus* by gall-stones or tumors), and in syphilis; in some cases the cause cannot be discovered. The process begins with enlargement of the parts, due to accumulation of albuminates, as a result of which the cells acquire a strongly granular appearance. Although every cell is normally granular, it has, nevertheless, a quite clear appearance; not until the granules in the cell bodies become larger, more compact, and, therefore, more cloudy and less trans-

parent, as after phosphorus poisoning, does pathologic "cloudy swelling" begin. In this state parenchymatous hepatitis, the most frequent affection of the liver, the almost constant accompaniment of all severe febrile affections, develops. In acute yellow atrophy of the liver so-called fatty metamorphosis develops from this inflammatory cloudy swelling under partial substitution of the albumin granules by fat-droplets. With this the necrobiotic process begins, principally from the center of the acini. The cells disintegrate; the markings of the acini are effaced; the liver quite rapidly diminishes in size and becomes extremely flaccid. In this stage of the disease the external capsule of the liver is often slightly wrinkled. As this process is always accompanied by icterus, the liver acquires a strikingly yellow, sometimes a pale-green appearance. In simple cloudy swelling, in contradistinction to acute yellow atrophy, fatty metamorphosis is not always a necessary sequela; simple cloudy swelling may disappear by assimilation or secretion of the albuminous material.

Acute yellow atrophy is distinguished from simple cloudy swelling by the fact that it is always followed by fatty metamorphosis; a large portion of the liver disappears completely, and the liver itself is greatly diminished in size. This acute yellow atrophy of the liver, which generally progresses very violently under severe general symptoms (convulsions, delirium, sopor, high fever, hematemesis, bloody diarrhea), may come to necropsy in very different stages. Often, when the course is very rapid, the whole liver is small, flaccid, cloudy yellow. Well-preserved liver-cells are very difficult to find; on microscopic examination, almost all the cells are disintegrated; preserved liver-cells are found only in the periphery of the acini. In the later stage—in more chronic course—the liver is often irregular, rough, and nodular externally. The cut surface shows alternating dark-red and yellowish areas. The former sink in and contain scarcely any remains of liver-cells, while in the yellow areas liver-cells can still be recognized. In these cases the disappearance of the liver-cells has occurred uniformly. At a later stage proliferation of the portal connective tissue and of the epithelia of the bile-ducts, and often also of the liver-cells themselves, starting from remnants of the liver parenchyma, is frequently observed, in addition to disappearance of the liver-cells. Sometimes the cellular proliferation is so intense that tumor-nodules (regeneration, adenoma?) develop.

On the other hand, atrophy of the liver-tissue is frequently the result of chronic inflammatory processes in the interstitial tissue. **Interstitial hepatitis** occurs either only in isolated localities: partial interstitial hepatitis, or it involves the whole liver: universal interstitial hepatitis; it is confined either to the region of the connective tissue proper—Glisson's capsule: portal intersti-

tial hepatitis, or it soon extends to the region of the acini: diffuse interstitial hepatitis. In each instance new connective tissue develops, which, through formation and contraction of fibrillated intercellular substance, leads to partial or general atrophy of the parenchyma. General diffuse interstitial hepatitis results in diminution in the size of the whole organ by shrinkage: contracted liver. Under certain circumstances the result of local connective-tissue proliferation in

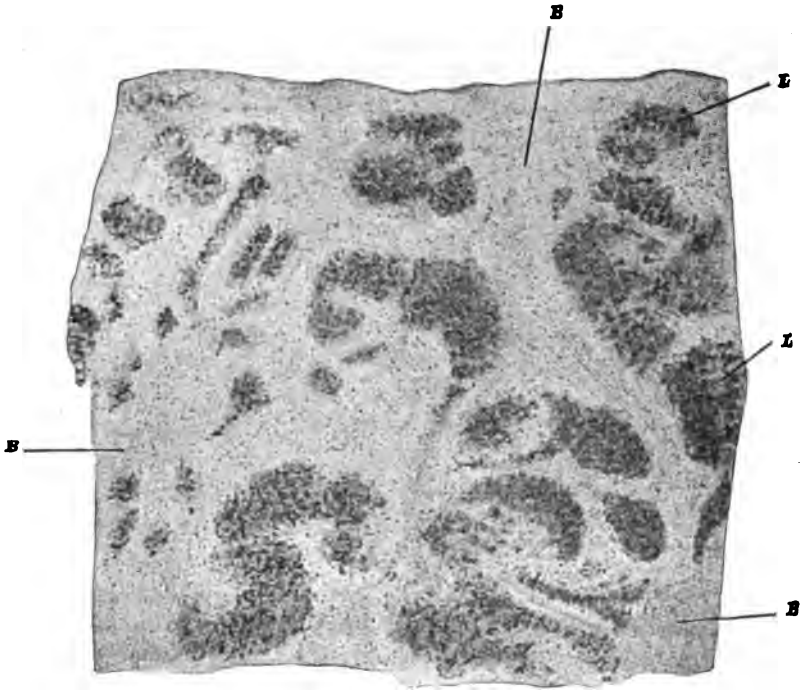

Fig. 400.—Hepatitis interstitialis chronica diffusa (cirrhosis of the liver). *L*, liver-tissue; *B*, newly formed connective tissue in actual connective-tissue stadium, partly with fresh proliferation. Fresh section. (Zeiss Apochr., 2; Comp. Ocul., 4. After *Langerhans.*)

chronic partial interstitial hepatitis is cicatricial retraction. Sometimes such extensive connective-tissue bands thus develop that the liver assumes a lobulated appearance. (See Syphilis, p. 549.) This change almost always originates as a result of syphilis; only in isolated cases is it caused by trauma. Local interstitial proliferations occurring in the neighborhood of foreign bodies, especially of parasites (echinococcus, pentastomum), and of chronic suppurative processes lead to encapsulation of the parasites (see p. 355) and separation of the diseased from the healthy liver-tissue. (See p. 388.)

In shrinkage of the whole liver from general diffuse interstitial hepatitis, both the external surface and the cut surface are more or less granular. This stage is called granular atrophy or **cirrhosis of the liver.** The latter designation, first employed by Laennec, is derived from the color,[1] because the very different sized granules are usually strongly fatty and icteric and, therefore, appear yellow.

The formation of the granules is due to the fact that the interstitial process, which starts in the region of Glisson's capsule, but later is rarely confined to it, extends in various directions in the individual acini and partly through the center of them. When the new-formed tissue has separated into fibrillated intercellular substance and begins to contract, new

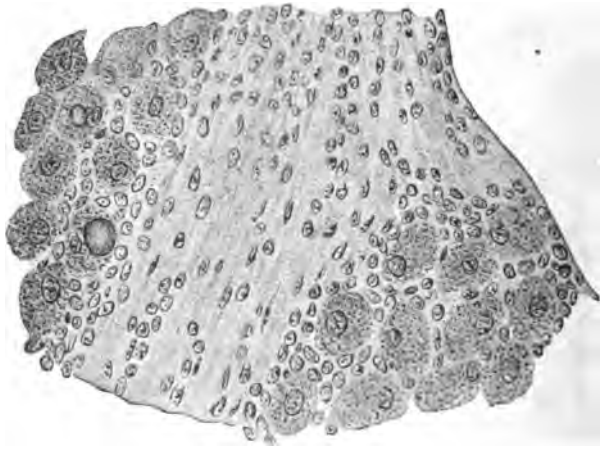

Fig. 401.—Liver cirrhosis, new-formed connective tissue with much striated intercellular substance and fresh proliferation of connective tissue. Fresh section. (Zeiss Apochr., 4; Comp. Ocul., 8. After *Langerhans.*)

liver islands thus originate, which bear no relation to the limits (outlines) of the acini. These newly formed, irregular-sized islands consist either of a number of acini or of portions of several infiltrated acini, or of small remnants of individual acini.

Among the causes of cirrhosis of the liver are said to be intoxications (chronic alcoholism, chronic phosphorus poisoning, intestinal toxins, etc.) and partly also infections. In syphilis, also, a general diffuse interstitial hepatitis is sometimes observed which frequently is recognizable as syphilitic only by the alterations present in other organs. In some cases, of course, the specific cause can be recognized also in this form by the unusual intensity of the process in different portions of the liver. (See p. 551.)

[1] *κίρρος* = yellow.

Portal interstitial hepatitis is a far more frequent process than cirrhosis of the liver, and is very often found *post mortem* without the presence during life of any symptoms pointing to its existence. This form may be met at necropsy in very different stages: either in the first stage—the granulation or proliferation stage—or in the second stage—the true connective-tissue stage—in which the proliferated, round connective-tissue cells grow into spindle-shaped and stellate cells and form fibrillated intercellular substance, or in the third stage—the so-called cicatricial stage—in which the new-formed, fibrillated intercellular substance undergoes cicatricial contraction. The first form is most frequently observed, the second seldom, and most rarely the third.

All these chronic interstitial forms of hepatitis, the portal as well as the diffuse, manifest a marked tendency to recidives, so that very often, in addition to the older proliferation—the connective tissue and cicatricial stadia—fresh proliferation is seen. The pure cicatricial stage, *i.e.*, the result of a fully completed process, is observed only in extremely rare instances. Little definitely is known as to the cause of portal hepatitis. Alterations of the portal vein or of the bile-ducts are usually absent. It appears that the portal form may pass over into the diffuse form, since transition forms are sometimes observed.

With these in general more chronic processes with a tendency to contraction may be classed another interstitial process in which the liver is markedly enlarged. Such a liver has a quite smooth exterior and cut surface and is strikingly firm in consistency; the anterior sharp border is distinctly rounded; everywhere in the region of the portal vein can be seen glassy-gray spots and striæ which macroscopicly correspond to very young interstitial proliferations (granulations): *hepatitis interstitialis recens hypertrophica.* This is a change which has been designated as **hypertrophic cirrhosis of the liver.** In this change neither yellow coloration nor the contraction so characteristic of cirrhosis is seen. The process always involves the whole liver, nowhere leads to the formation of intercellular substance, and is characterized by the excessive proliferation and consequent increased width of the portal connective tissue.[1]

Cirrhosis of the liver generally exists for a considerable time before death occurs. The liver affection itself is not the immediate cause of death: the action is only indirect. Cirrhosis disturbs the circulation of the abdomen, causing marked ascites, *caput medusæ*, etc.; furthermore, icterus occurs, toxic substances enter the blood from the liver and reach the different organs and the heart.[2] The function

[1] It is possible, but for various reasons quite improbable, that this "hypertrophic cirrhosis of the liver" is the first stage of the later "contracted (cirrhotic) liver." Probably, they are two entirely different processes.

[2] It is assumed that the pathologic process in the periportal connective tissue occludes the biliary passages, so that the bile congests in the liver, causing icterus.

of the digestive tract is disturbed, because the portal vein is involved. Death results from degeneration of the myocardium. Cirrhosis of the liver is the indirect, and cardiac paralysis the direct, cause of death. In rare cases one of the dilated esophageal veins entering the portal vein may burst and cause fatal hemorrhage: in this case hemorrhage would be the immediate cause of death.

Suppurative inflammation of the liver (*hepatitis interstitialis acuta*) also begins in the region of Glisson's capsule. It is distinguished from the last-mentioned, fresh interstitial hepatitis by the intense involvement of the vessels, from which an active emigration of leucocytes occurs, and also by the fact that it is connected with changes of the veins, or arteries, or bile-ducts. Purulent hepatitis may run an acute or chronic course. The nearer the equator is approached, the more frequently is the acute form encountered, while in temperate zones, aside from true metastases, the chronic form is more common. (See p. 393.)

Chronic abscess of the liver is always encapsulated by fibrous tissue (partial chronic interstitial infection) which gradually develops in the neighborhood. As a rule, the process is one of multiple abscess formation. In acute abscess there is insufficient time for the development of an encapsulating fibrous hepatitis; the pus comes in immediate contact with the parenchyma, which, in turn, is involved in the process in the form of acute parenchymatous hepatitis. This acute malignant form usually leads to disintegration—to a kind of softening.

Liver abscesses are sometimes observed after severe injuries to the head, frequently in echinococcus hepatitis, and in the tropics (especially in Egypt, Philippines, etc.) in connection with dysentery[1] (amebic dysentery). Infectious processes in the root area of the portal vein also may cause thrombosis of the portal vein, and by detachment of small particles of the infectious, germ-laden thrombus and transportation of the same with the portal blood lead to the formation of metastatic abscess of the liver.

Ruptures of the liver generally occur near the suspensory ligament as the result of traumatic influences. Such a rupture, when it does not immediately cause death from hemorrhage, may favor inflammations and abscess formation; on the other hand, it may heal by cicatrization.

Almost all **hydatids**[2] (aqueous cysts) of the liver are of parasitic nature. Exceptions are certain small **cysts** which originate chiefly at the fetal period. As these are lined with ciliated epithelium, and in the liver only the bile-ducts are provided with ciliated epithelium during the embryonic period, they constitute bile-duct cysts in which the ciliated

[1] Since the Spanish-American war, the number of cases of amebic dysentery in the United States has been considerably increased.

[2] Lat.: *hydatis:* vesicle.

epithelium has been preserved. Here, therefore, the process is a *vitium primæ formationis.* These bile-duct cysts are usually multiple and are of millet-seed or hemp-seed to hazelnut and walnut size; in some cases they attain still larger dimensions. (See p. 809.)

Among the parasitic cysts, echinococcus cysts are most frequent. Cysticerci are rarely observed. Echinococci (see p. 385) form a single large cyst or numerous small vesicles (*echinococcus multilocularis*) and always lead to partial chronic fibrous hepatitis, *i.e.,* to the formation of dense connective tissue, which encapsulates the echinococcus cysts. When suppuration of the echinococcus occurs, the suppurative process always begins inside of the external connective-tissue capsule formed by the chronic hepatitis and later extends to the echinococcus cyst itself. By bursting of the capsule and discharge of the contents, the brood capsules may spread by dissemination. Further extension may occur also by way of the blood; usually, however, echinococcus of the liver remains stationary and forms large vesicles, which may attain the size of a man's head.

Trematodes (see pp. 371 and 373) occur in the portal vein and the larger bile-ducts and lead to circumscribed portal interstitial hepatitis. The parasites themselves are sometimes calcified, so that the nature of the condition is recognized only after the lime-salts have been dissolved.

Amyloid degeneration of the liver is almost always associated with increase of volume. Usually the whole organ is uniformly involved; occasionally certain areas are more strongly affected, so that large amyloid nodules may be found. Amyloid degeneration is always accompanied by condensation, so that the specific gravity is very high. Amyloid substance is waxy, translucent gray in appearance. The process is eminently chronic. In the first stage no alteration is recognizable macroscopicly; at first only the finer branches of the hepatic arteries, *i.e.,* the muscular elements thereof, are affected. The process gradually extends to the capillaries of the acini, the walls of which become thickened and transformed into a highly glistening mass. The swelling is accompanied by narrowing of the lumen of the capillaries and ischemia. Amyloid degeneration is, as a rule, first manifest in that capillary area which lies between the periphery and center, equidistant from the portal vein and hepatic vein, *i.e.,* in the so-called intermediary zone of the acini (see Fig. 402, *i Z*); from here the degeneration advances toward the periphery, the central zone remaining longest intact. The intermediary zone, however, is not always first and most intensely altered; exceptions to this rule are quite frequent; in some acini the central zone is more strongly altered than the peripheral, and in the same acinus the amyloid degeneration may be in part more strongly developed in the peripheral,

but also in part in the central zone. In amyloid degeneration of the intermediary zone, intense accumulation of fat is very often observed in the peripheral zone of the acini.

Of the three zones of the acini the central is most frequently disposed to pigmentation and least frequently to fatty infiltration and amyloid degeneration; the peripheral most frequently to fatty infiltration and least to pigmentation, while the intermediary zone is characterized by an especial disposition to amyloid degeneration.

Of the **tumors**, angiomata are most frequently found, generally several together, seldom only one angioma. These usually attain only pea- to hazelnut- size and are almost always situated in the peripheral portions of the liver, as a rule, immediately beneath the capsule.

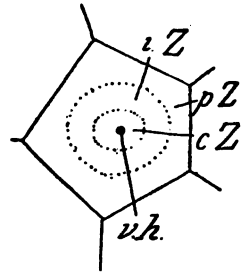

Fig. 402.—*v h*, vena hepatica; *c Z*, central zone; *i Z*, intermediary zone; *p Z*, peripheral zone.

The liver is very slightly disposed to primary tumor formation. Most tumors of the liver are metastatic in nature; therefore, they occur, as a rule, as multiple nodules. Carcinoma metastases are especially frequent, particularly in primary carcinoma of the stomach. **Primary carcinomata** (see Figs. 403 and 404) of the liver are almost always solitary and, on the whole, very rare.[1] They most frequently originate in the region of the gall-bladder, the hilus of the liver, or the bile-ducts (see Fig. 403), and rarely from parenchyma (acini) cells. (See Fig. 405.)

M. Lissauer[2] inclines to the view, held also by others, that cirrhosis or syphilitic cicatrization is the primary affection and carcinoma development secondary. He regards the liver-cells as the point of origin of malignant adenoma, though only because of the marked morphologic similarity of the tumor- and liver- cells. He was unable to observe carcinomatous degeneration of the liver-cells. It is of especial interest that

[1] According to Leichtenstern, carcinoma of the liver is secondary in 80 per cent. of cases (Langenbeck, *Chir. d. Leber u. Gallenblase*, II Thl. Stuttgart. 1897, p. 52).

[2] Virchow's Archiv, 1910, Bd. 202, p. 57.

Fig. 403.—Primary carcinoma of the liver originating from bile-ducts (metastases in all organs).

the tumor-tissue (also in the metastases) retains the ability to secrete bile. The author hesitates to assume a multicentric origin for carcinoma. Hippel[1] reports an adenoma containing cartilage, scattered groups of epithelial cells with central hornifications, and large masses of a pigmentoid body between and in the tumor-cells. This peculiar finding is explained by him as a primary disturbance in the development of the liver Anlage, which led to excessive tumor formation. At the same time these heterotopous tumor elements developed in the tumor by metaplasia. The pigment may be regarded as bile-pigment.

Partial **hyperplasias** of the liver-cells (see p. 307), which frequently are considered and designated as adenomata, are infrequent. As a rule, the cause of these hyperplasias, which lead to the formation of small nodules, is obscure. With these processes apparently may be classed those already-mentioned proliferations of the bile-ducts and liver-cells occurring in acute yellow atrophy, which sometimes also result in the formation of tumor-like nodules and sometimes probably are the starting point of atypic epithelial proliferation and carcinoma. More circumscribed proliferation after loss of liver-cells gives the impression of incomplete regeneration of the liver-tissue. (See p. 794.)

The **bile** is conveyed from the liver by the bile-ducts. Mechanic obstruction of the outflow causes congestion, which is followed by absorption of the bile by the liver-tissue, and, through the agency of the blood-vessels, also by the remaining tissues of the body: **icterus**, jaundice. Through increase of *icterus lævis, icterus gravis*—the state of cholemia—is produced, which is accompanied by parenchymatous changes, frequently also by hemorrhages, and on long duration always results in green icterus: *icterus viridis*. (See p. 135.)

Some authors contrast hepatogenous icterus with a hematogenous icterus, assuming that icterus may occur as a result of rapid destruction and solution of the red blood-corpuscles without participation of the liver or bile (hemolytic, acholytic icterus; see p. 804), but all experimental efforts to induce icterus without participation of the liver have thus far failed. In transfusion of animal blood into the circulation of man, the blood coloring matter is dissolved; no bile coloring matter, however, is produced, but hemoglobinemia and hemoglobinuria. Therefore, true icterus can occur only when bile is secreted. When the liver ceases to secrete bile, as, for example, in Asiatic cholera, the state of **acholia** develops.

Every icterus always begins in the liver, and some time may pass before the remaining organs (among these always first the conjunctivæ, kidneys, and intima of the vessels; next the serous membranes, the

[1] Virchow's Archiv, 1910, Bd. 201, H. 3, p. 326.

skin, etc.) are involved. Hence, at necropsy icterus sometimes is found only in the liver. In parenchymatous nephritis the diseased cells absorb bile coloring matter to a very marked degree. The icterus begins within the liver in the center of the acini and depends upon deposition of bile coloring matter, usually of orange-yellow, diffuse, rarely of granular or needle-shaped pigment: bilirubin. On long duration bilivirdin develops from bilirubin: *icterus viridis,* chronic green icterus. This

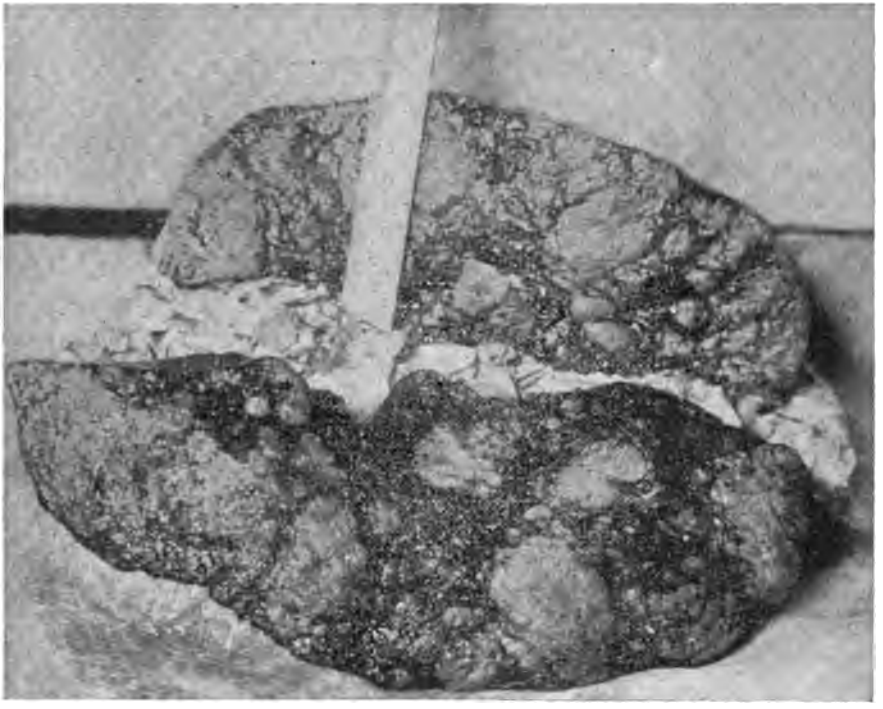

Fig. 404.—Primary carcinoma of the liver originating from parenchyma (acini) cells.

is almost always associated with the formation of concretions within the finest bile-ducts—the so-called bile-capillaries. These **concretions** are homogeneous, strongly refractive, round or sausage-shaped, often branched, at first gold-yellow, later dark-green, very resistant bodies which break on pressure, presenting fracture surfaces resembling those of glass. The catarrhal form of icterus develops from catarrh of the bile-ducts. Here considerable swelling of the mucous membrane of the bile-ducts is always present, which, in conjunction with the tenacious mucous secretions, offers mechanic obstruction to the flow of bile.

Hemolytic, acholytic icterus is a form, described by Minkowski in 1900, which in prognosis and course differs from primary acquired and secondary hemolytic icterus. The secondary form of this affection may be regarded as belonging to the complex of symptoms the sequelæ of malaria, sepsis, carcinoma, and syphilis. Secondary acholytic icterus, which in many of its manifestations is similar to the primary congenital form, differs essentially from the latter by the course and principally by the termination, which is directly dependent upon the primary affection. The primary acquired form of the disease is insufficiently understood and often progresses with manifestations of pernicious anemia.

In 2 cases of primary congenital hemolytic icterus reported by Ignatowski[1] the patients were between 20 and 21 years of age. In 1 case the disease developed at birth; in the other, at the age of 3 years. The patients complained of very little that was characteristic; aside from emaciation in one case, no significant disturbances were observed. Objectively, there was well-defined general icterus without symptoms of biliary intoxication. The urine contained no bile-pigments, but urobilin was constantly present. In both cases splenomegaly existed. The liver was enlarged from time to time and its function, judged by digestive tests with levulose, diminished. Exacerbation of the disease was noted as a result of psychic and physic exhaustion, cold baths, infections, and digestive disturbances.

The **blood** shows decrease of the erythrocytes and corresponding diminution of the hemoglobin; large numbers of macro- and micro- cytes, occasionally polychromatophilia, and rarely hematoblasts. Nine per cent. of the erythrocytes presented peculiar basophilic granulation, visible only in stained living blood. The number of leucocytes is normal and the ratio unaltered. That the disintegration of the erythrocytes is due to congenital frailty of these cells is shown by the fact that they are destroyed by 0.8 to 0.7 per cent. NaCl solution; normally, only 0.45 per cent. solution causes hemolysis. The blood-serum is stained yellow, due principally and perhaps solely to urobilin. The serum contains no isolysins, though it acts more strongly upon washed rabbit blood-corpuscles than does normal serum.

The affection is referred by Ignatowski to the following conditions: Congenital frailty of the erythrocytes resulting in the formation of a quantity of blood-pigment which is converted into urobilin. Urobilin is not destroyed by the liver, but circulates in the organism and, in consequence of functional debility of the liver (defective excretion of levulose) or of excessive accumulation of urobilin, is deposited in the skin. The splenomegaly may be regarded as the result of augmented activity of the

[1] Fortschritte der Medizin, 1911, No. 42, p. 567.

spleen and irritation exerted by fragments of erythrocytes. The cause of congenital diminution of resistance of the erythrocytes is unknown; perhaps it is due to abnormal function of the bone-marrow. The course of primary congenital icterus is of very variable duration. The prognosis *ad vitam* is favorable, though the possibility of the development of acute anemia resulting in death cannot be excluded.

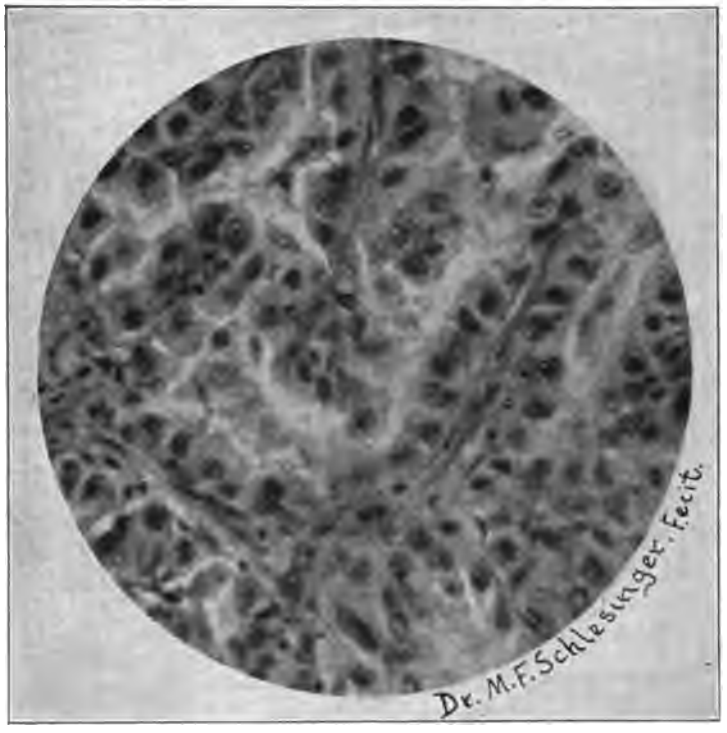

Fig. 405.—Section from liver shown in Fig. 404. (Leitz, No. 6; oc., iv.)

When tumors, gall-stones, etc., render emptying of the bile-ducts impossible for a long time, gradual dilation of the bile-ducts, first of the large and medium-sized, later of the small, bile-ducts, develops in consequence of the congestion of bile. This change is almost always accompanied by intense catarrhal secretions which not rarely assume the character of purulent catarrh: purulent catarrhal cholangitis. In this case the strongly dilated bile-ducts are found filled with greenish, purulent material, so that the process may easily be assumed to be multiple abscess, especially when the bile-ducts lie immediately beneath the capsule, produce bulging of the latter, and form large sacs

filled with pus. If, however, the somewhat mucopurulent masses are removed by a stream of water, the wall of the bile-ducts can usually be recognized without difficulty. Increasing dilation of the bile-ducts is always associated with progressive atrophy of the parenchyma. This change may be followed by multiple purulent inflammation of the true liver-tissue (abscess formation).

Fig. 406.—Same as Fig. 404, external surface.

If icterus is added to fatty liver, the liver is intensely yellow in color, while an ordinary fatty liver is more gray-yellow in color. The designation **saffron liver** has been introduced for icteric fatty liver.

In chronic catarrh of the mucous membrane of the gall-bladder—**catarrhal cholecystitis**—the bile mixes with the secreted, tenacious mucus. The more mucus is produced, the less bile enters the gall-bladder. The tenacious mucous exudate stagnates in the gall-bladder; this becomes strongly filled, until the wall is tensely distended. Later, the bile coloring matter disappears and the tenacious mucous exudate liquefies, the gall-

bladder finally containing a very liquid, colorless, water-clear fluid. This state is called *hydrops cystidis felleæ:* dropsy of the gall-bladder.

Chronic catarrhal inflammation of the mucous membrane of the gall-bladder pursues a very latent course; the wall thereby becomes very gradually thickened. Chronic thickening is always found in long presence of stones, which exert continuous irritation. This chronic irritation exerted by gall-stones is, perhaps, in some cases the cause of primary carcinoma of the gall-bladder; on the other hand, formation of stones may be favored by carcinoma of the gall-bladder.

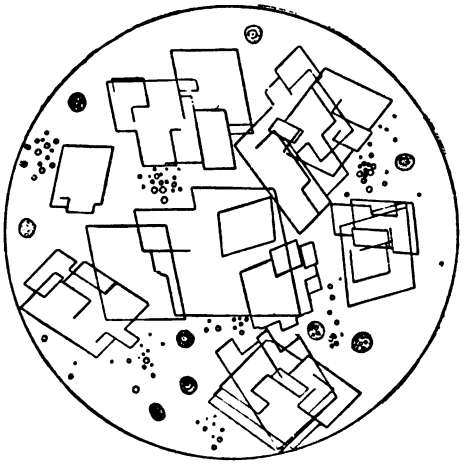

Fig. 407.—Cholesterin plates. × 350.

Gall-stones may be entirely colorless; in the fresh state more hyaline, in the dry state more whitish. These are almost always stones composed of cholesterin crystals. Cholesterin is brought to the liver probably from other organs; it is as constantly present in the liver as is uric acid in the urine. Cholesterin stones grow by the successive deposition of new concentric lamellæ around the nucleus; in spite of this a radiate arrangement is so predominant as a result of crystallization (see Fig. 408) that the concentric lamellation is scarcely perceptible. (See Fig. 410.) These stones are rough and nodular externally (see Fig. 409), due to the superimposed rhombic cholesterin plates which form small external projections. These stones are generally solitary and may become so large as entirely to fill the lumen of the gall-bladder. In this case the stones adjust themselves to the form of the gall-bladder. When pure cholesterin stones occur in large numbers, they are polyhedral and, in consequence of constant attrition, have quite smooth, porcelain-like surfaces. (See Fig. 411.)

According to Aschoff, cholesterin-stones may form in the gall-bladder, independently of inflammatory processes, by precipitation of cholesterin directly from bile as the result of autolysis of the bile due to stasis. With persistence of stasis the epithelial lining of the gall-bladder desquamates (*cholecystitis desquamativa*), which favors infection. In inflammatory catarrhal processes calcium-stones are formed by autolysis and precipitation of lime from the mucous secretion of the mucous glands of the gall-bladder, either with or without precipitation of bile pigments.

The other group of gall-stones likewise originate as a result of secretion of a substance discharged through the bile; these are **pigment stones,** which, as the name indicates, consist essentially of bile coloring matter. At first only soft flakes—exfoliated epithelial cells—are present which gradually grow darker, in that they disintegrate into a granular detritus, becoming more and more imbued with bile (yellow,

Figs. 408, 409, 410.—Section of a solitary cholesterin-stone. (After *Langerhans.*)

green, brown); at the same time the whole mass gradually condenses by a kind of inspissation. In this manner bile-sand or gravel—minute, quite firm, blackish-green gall-stones—is found, which may greatly irritate the mucous membrane, and, therefore, very frequently produces gall-stone colic. For the further growth of these stones, the affinity of the bile coloring matter for lime, especially calcium carbonate, is of importance; in all large pigment stones lime is an integral constituent.

Combination forms are very frequent, a pigment stone developing secondarily around a cholesterin stone as nucleus, and *vice versâ;* indeed, even alternate layers of cholesterin and pigment material may occur. By close grouping of a number of gall-stones, these acquire flattened, faceted surfaces: polyhedral form. Owing to their smooth surfaces, these stones are less irritating and, therefore, may be endured for a long time without great annoyance. On the other hand, stones with finely or coarsely nodular or spiculate surfaces (as a result of irregular development or coalescence of contiguous stones), serrated pigment stones (see Fig. 412), and

the "morning-star" forms (see Fig. 413) are usually very irritating and produce violent colic.

The greater the number of stones present in the gall-bladder (often many hundred to over a thousand), the more they influence one another. Sometimes they are so numerous that the gall-bladder extends to the true pelvis as a large pouch. The stones can then be palpated with great ease during life. If large stones enter the common duct, they are temporarily arrested in this locality or they pass so slowly that they cause icterus. In other cases the stones become impacted and cause inflammatory disturbances, which may finally lead to perforation and expulsion of

Fig. 411.—Polyhedral cholesterin-stones.

Fig. 412.—Serrated pigment-stones.

Fig. 413.—Solitary pigment-stone of morning-star form.

the stones into the duodenum or abdominal cavity, seldom into the colon. Fatal perforative peritonitis may thus be produced. Michel[1] reports the presence of gall-stones in the urinary bladder.

Among the primary tumors of the gall-bladder, carcinoma is most frequent. In addition to cylindric-celled carcinoma, squamous-celled carcinomata (epitheliomata) which start from the gall-bladder, and, seldom, villous carcinoma and colloid carcinoma, occur. Sarcomata are rare. Other tumors (fibromata, myomata) are very infrequent.

In the large bile passages the tumors are almost always carcinomata. Most frequently they develop from the common duct, seldom from the hepatic duct, and very rarely from the cystic duct. L. Plenk[2] reports a solitary cyst in the center of the liver, larger than a man's head, lined with cylindric epithelia, which he regarded as developing from an accessory or aberrant bile-duct. (See p. 798.)

[1] Zentbl. f. Gyn., Jan. 2, 1909.
[2] Virchow's Archiv, 1910, Bd. 201, p. 335.

SALIVARY GLANDS.

Pancreas.

The **pancreas**[1] is an acinous gland of markedly coarsely granular consistency. The small, very firm, pale reddish-gray glandular lobuli are bound together by very loose connective tissue. Through the middle of the elongated, somewhat flattened organ runs in a straight course, from the tail to the head, the chief duct: *ductus pancreaticus;* this, together with the *ductus communis choledochus,*[2] opens as the canal of Wirsung into the vertic portion of the duodenum (in the region of the papilla). On the posterior surface is a lobular fold of the gland, passing trans-

Fig. 414.—Section of the pancreas of the dog. *d,* termination of a duct in the tubular alveoli, *a.* (After *Klein.*)

versely to the left, which is sometimes detached from the rest of the gland and is called the lesser pancreas. The duct of the latter (*ductus pancreaticus minor*) opens into the main duct near the duodenum, but sometimes separately into the intestine at a distance of an inch or more from the termination of the principal duct (Gray).

Like the liver and kidneys, the pancreas is involved in many acute infectious diseases, and in poisonings by cloudy swelling of the parenchyma: parenchymatous pancreatitis. In this process principally the diameter of the gland is increased. Generally, the clouding is not macroscopicly distinct until the stage of secondary fatty metamorphosis, when the acini assume a cloudy, reddish-yellow appearance. Acute idiopathic pancreatitis possesses a hemorrhagic char-

[1] *Pan:* all, and *kreas:* flesh.

[2] Sometimes the pancreatic duct and common bile-duct open separately into the duodenum.

acter: hemorrhagic pancreatitis. Nothing certain is known of the etiology of this affection. It may cause death under violent phenomena.

Acute purulent interstitial inflammation of the pancreas is, as a rule, a metastatic affection, but it occurs also spontaneously. In general, however, the pancreas is characterized by slight disposition to suppuration and ulceration. Even when purulent or ulcerative processes extend from surrounding parts to the pancreas, the latter, in a certain measure, opposes further extension by the development of a partial, firm, interstitial pancreatitis. When, for example, a gastric ulcer advances toward the pancreas after adhesion of the stomach to the surrounding parts and perforation of the gastric wall, a firm, somewhat retracted, whitish-gray, cicatricial area develops in the pancreas, but no suppuration or acute disintegration.

Independent interstitial processes with induration are rare. They are observed principally in syphilis and occur either as isolated foci, especially in the head or tail, or involve the whole organ.

Secondary atrophy is observed in carcinoma of the head of the pancreas, and in stone formation with dilation of the excretory ducts.

Atrophic processes, in contradistinction to interstitial inflammation, progress without induration. The organ becomes smaller in all its dimensions without becoming harder. In this condition the acini are very small, shriveled, yellow-gray; a portion of the parenchyma is always in a state of simple fatty metamorphosis without inflammatory manifestations. This condition is observed principally in very old people and after very chronic exhausting diseases, sometimes quite accidentally. Worthy of mention is the quite frequent, but by no means constant, atrophy of the pancreas in diabetes mellitus. Slight degrees of atrophy are sometimes the result of stasis of the pancreatic juice in the excretory ducts.

In extensive amyloid degeneration of the abdominal organs, the small vessels of the pancreas also are generally similarly affected. As the parenchyma is not involved, this change is inconspicuous and demonstrable only on microscopic examination.

Another disturbance on the part of the vascular system is far more important in so far as it repeatedly produces sudden disturbance of function and sudden, shock-like death. This is large hemorrhages into the pancreas itself and into the immediate neighborhood, without demonstrable disease of the pancreas. Why death occurs has not yet been positively determined. The amount of extravasated blood is insufficient to explain the cause of death. The close proximity of the semilunar ganglion and solar plexus has been provisionally suggested. Just

as little is known of the cause of the hemorrhage. Sometimes it is the result of embolism, sometimes of necrosis of the parapancreatic adipose tissue.

By **ranula**[1] **pancreatica** is understood a more or less intense dilation of the excretory duct; either the whole pancreatic duct is involved, which often results in a rosary-like ectasis, or only that portion in front of the point of union with the *ductus choledochus* is cystic. At first the dilated ducts contain pancreatic juice; later, more mucoid and sometimes hemorrhagic material is present. Here concretions, which at first consist of semisolid, insoluble protein substances, but gradually become firm stones by absorption of lime-salts, are frequently formed. These attain the size of a hazelnut, are partly smooth and round or oval in shape, partly nodular and serrated (see Fig. 415), and are light grayish white, rarely colored.

Fig. 415.—Pancreatic calculus from the pancreatic duct (in the head of the pancreas) in ranula pancreatica. Natural size. (After *Langerhans.*)

The causes of pancreatic ranula are tumors in the region of the head of the pancreas, which press upon the mouth of Wirsung's duct or involve the head of the pancreas itself; furthermore, gall-stones impacted in the papilla of the duodenum, and next in frequency catarrhal affections and cicatricial contraction.

Generally, a few fat-cells or fat-lobuli are found in the connective tissue uniting the lobuli of the pancreas only at certain points in the immediate neighborhood of the vessels. In very obese persons, however, the connective tissue is always gradually transformed by metaplasia into adipose tissue: *degeneratio adiposa pancreatis* or *lipomatosis pancreatis.* In high degrees of fat-tissue development the parenchyma suffers, since fatty metamorphosis of the pancreas cells in the periphery of the acini and diminution in the size of the latter are frequently observed.

A peculiar change, in which the fat-cells die and the oil-droplets within the fat-cells are transformed by decomposition into firm, crystalline fat, not infrequently occurs in the fat-tissue in the region of the pancreas and in the interstitial fat-tissue developed by metaplasia. This process is called **fat-tissue necrosis.** The cells retain their form and position, but as dead bodies excite a reactive, dissecting inflammation

[1] *Ranula,* dim. of *rana:* a frog.

in the neighborhood, so that they become loosened from the living tissue and can be readily removed with the point of the knife as opaque, yellowish-white, quite firm granules, from poppy seed to hemp seed in size. In very obese individuals, fat-necrosis is sometimes found throughout the adipose tissue of the abdomen; even then the region of the pancreas is characterized by the large number of necrotic foci. The more fat-tissue dies in this manner, the more the small foci coalesce to form larger foci, so that finally the greater portion or all the parapancreatic fat-tissue becomes necrotic. The pancreas itself thus becomes sequestered and consequently mortifies: pancreatic necrosis. Under certain circumstances this process may be complicated by suppuration; as a rule, however, formation of pus is absent. As a result of complete sequestration, this dead pancreas then floats, as it were, in a cloudy, thick, grayish-yellow and whitish-gray or, when hemorrhagic products are present, reddish or brownish fluid, which greatly resembles pus, but, aside from a liquid basement substance, consists almost entirely of fatty acid crystals and shreds of necrotic tissue. The acinous structure of the pancreas, however, is still macroscopicly and microscopicly well preserved. Sometimes the newly developed cavity, which contains the pancreas or a portion of it, perforates into the gastrointestinal canal, most frequently into the descending portion of the duodenum. The contents of the cavity then mixes with the bile, particles of food, etc., and its character is altered accordingly. The sequestered pancreas may escape through the perforation opening and subsequently be discharged with the stools.

The etiology of multiple fat-necrosis is as yet only speculative. Fat-tissue necrosis can be produced experimentally by the action of pancreatic juice upon living adipose tissue.

As a rule, the necrotic fat-tissue is quite rapidly permeated with lime-salts. A loose union of fatty acids with lime to form hyaline, fatty acid lime, which is insoluble in hydrochloric acid, thus occurs.

Secondary tumors of the pancreas are very rare. Primary carcinoma, especially of the head of the pancreas, is quite frequent.

Parotid, Submaxillary, and Sublingual.

Inflammation of the salivary glands is quite rare. Acute inflammation is most frequent in the parotid (mumps[1]), rare in the submaxillary, and very rare in the sublingual. An acute phlegmonous inflammation, called Ludwig's angina (*angina ludovici*) or cynanche, invariably begins in the region of the submaxillary, sometimes terminates in suppuration and gangrenous disintegration, and frequently causes death

[1] See Epidemic Parotitis, under Infectious Diseases, p. 574.

under general septic phenomena. Inflammatory swellings of the salivary glands occur secondarily in the acute infectious diseases, such as pyemia, typhoid, diphtheria, cholera, syphilis, etc. Tuberculosis and syphilis are rare.

Stone formations, composed of phosphate and carbonate of lime, at times containing foreign bodies as a nucleus, are observed in both Wharton's and Stenon's ducts. **Cysts,** which may attain considerable dimensions, are met with. Cystic degeneration of the excretory ducts of the submaxillary and sublingual glands (ranula) occurs in the same manner as in the pancreas. (See p. 812.)

Salivary fistulæ, through which saliva constantly is excreted into the oral cavity or externally, sometimes occur after abscesses, wounds, etc.

The most frequent primary **tumors** are enchondromata and mixed tumors,[1] the latter especially in the parotid; chondrosarcomata, and endotheliomata. Angiosarcoma and rhabdomyoma also occur. Pure sarcomata and carcinomata are rare. Epitheliomata frequently originate from the parotid. The parotid is the most frequent site of tumor formation; according to Ziegler, in 74 per cent. of all tumors of the salivary glands; next in frequency comes the submaxillary, and rarer the sublingual.

Achroöcytosis is a peculiar symmetric swelling of the salivary glands, characterized by deposition of small round cells between the glandular acini, which frequently is associated with similar tumefaction of the lachrymal glands. As the process occasionally is associated with other pseudoleukemic or leukemic symptoms, some authors have assumed that it bears a relation to these affections (Ziegler).

Gauslmayer[2] transmitted rabies to guinea-pigs and rabbits by inoculation of an emulsion of submaxillary glands of rabid animals. He was unable, however, to find Negri bodies in either the submaxillary or parotid gland.

---

[1] See Fig. 55, p. 231.
[2] Centlbl. f. Bakt., Bd. 55, H. 6.

UROPOIETIC SYSTEM.

KIDNEYS.

THE kidney is a compound tubular gland, which in man consists of from ten to thirty divisions, designated as *lobi renis*, or reniculi. Originally, the reniculi are very numerous, but subsequently are reduced by coalescence to about fifteen,

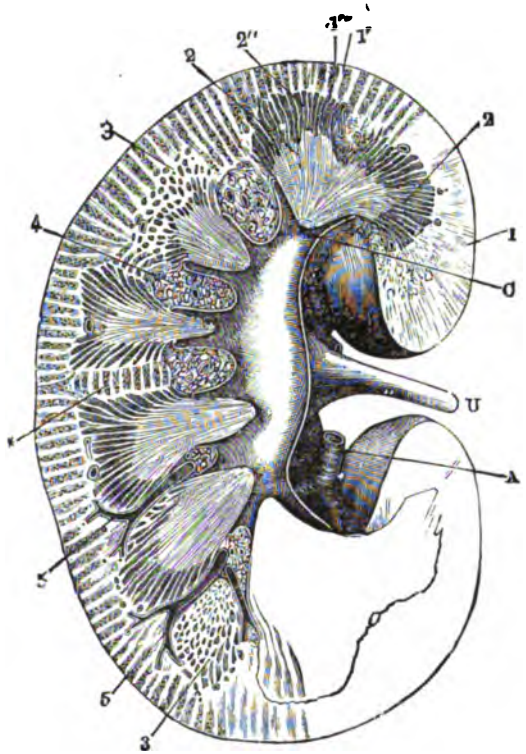

Fig. 416.—Section of kidney. 1, cortex; 1', medullary rays; 1'', labyrinth; 3, medulla; 2', papillary portion of medulla; 2'', boundary layer of medulla; 4, fat or renal sinus; 5, artery; *A*, branch of renal artery; *U*, ureter; *C*, renal calyx. (After *Landois*.)

which are well shown in the newborn. The number of renal papillæ is generally less.

The following table, compiled by Vierordt from various authorities, gives the weights and measurements of the kidneys:—

Weight, right kidney	102 Gm. (E. Bischoff) — 150 Gm. (Blosfeld).
" left kidney	118 Gm. (E. Bischoff) — 150 Gm. (Blosfeld).
Length	108-114 mm. (Luschka).

Breadth	54-63	mm.; at upper part frequently 72 mm.
Thickness	34-45	mm.
Tunica albuginea	0.1-0.2	mm. thick.
Cortical substance	9.0 (Toldt)-10.0	thick.
Medullary substance	16.0.	
In the newborn ....cortex	1.8	mm.; medulla, 8.31 thick.
Child, 3 months old ....cortex	2.8	mm.; medulla, 10.2 thick.
Tortuous uriniferous tubules ..	0.05	mm. diameter.
Straight " " ..	0.045	mm. diameter.
Glomeruli	0.2	mm. diameter.
Pyramidal processes	0.4	mm. thick.
Uriniferous pores of papillæ ..	0.7	mm. deep.
Pelvis of kidney	140-180	mm. wide.
Ureters	320-340	mm. long (Luschka 270), 5-6 wide.
Orificium in the bladder	2.0	mm. long; separated 14 mm. from one another and 180 mm. from internal orifice of the urethra.

On section the kidney is seen to be composed of two substances: (1) the medullary substance (*substantia medullaris*) is poorly vascular and contains the straight portions of the collecting tubules (*tubuli renales recti*), *i.e.*, the loops of Henle and the collecting tubules: (2) the cortic substance (*substantia corticalis*, renal labyrinth), which is richly vascular and contains principally the Malpighian corpuscles and the proximal convoluted tubules. In a normal renal lobe the cortic and medullary substances are divided as follows: In the papillary portion is found exclusively medullary substance (Malpighian pyramids), which sends out a large number of processes toward the surface of the kidney (pyramidal processes, medullary rays, or pyramids of Ferrein). They do not reach the surface of the kidney, but terminate at a certain distance from it. The rest of the renal tissue is cortic substance; between the medullary substance it forms the cortic processes. The portions of the cortic substance separating the reniculi are called the cortic columns, or columns of Bertini (*columnæ renales*, or *septa renis*). Through this portion the arteries and nerves enter, and veins and lymphatics emerge from, the kidney. That portion of the cortic substance extending from one cortic column to the next, intervening between the base of the pyramid and the capsule, is called a cortic arch. (See Fig. 416.)

The secreting portion is composed of definitely and regularly convoluted tubules: renal tubules (*tubuli renales*). In each tubule are differentiated the following sections: (1) the ampulla, or Bowman's capsule (*capsula glomeruli renis*), which surrounds a convolution of blood-vessels (glomerulus) and with the latter constitutes a Malpighian corpuscle; (2) a convoluted portion (proximal convoluted tubule); (3) a loop-shaped portion, known as Henle's loop, composed of a descending and an ascending arm; (4) a second convoluted portion (distal convoluted or intercalated portion), and (5) a straight collecting tubule. Besides these tubules the kidney has a complicated vascular system, a small amount of connective tissue, nerves, etc. (See Fig. 417.)

The character of the cells varies in the different portions of the tubules. In the capsule of the Malpighian corpuscles two portions are distinguished in regard to their relation to the glomerulus. The capsule forms around the glomerulus a

double-walled envelope, one layer reflected over the glomerulus, the other forming the capsule of Bowman. Between the inner epithelium, *i.e.*, that portion covering the glomerulus (glomerular epithelium), and that of the external wall (Bowman's capsule, *capsula glomeruli*) of the envelope is a cleft-shaped cavity which is continuous with the lumen of the urinary tubule. In adults the glomerular epithelium is very flat and provided with nuclei which protrude into the Malpighian space. The epithelium of the outer wall is somewhat higher, but still belongs to the flat form.

The capsule of the glomerulus is connected with the proximal convoluted portion of the urinary tubule by a short, narrow segment called the neck, and its epithelium gradually passes into the cubic epithelium of the neck segment, which is directly continuous with the epithelium of the convoluted tubule. In the latter are found striated epithelium, the markings of which are best seen at the base of the cell, while the nucleus is located in the half directed toward the lumen. In some localities the cells are so intimately connected that the limits are indistinct. The thin (descending) portion of Henle's loop is lined with flat epithelia the nucleated centers of which are thickened and project into the lumen of the tubule. The arched parts of the cells are not situated opposite the same part of the cells on the opposite wall of the tubule, but project into the

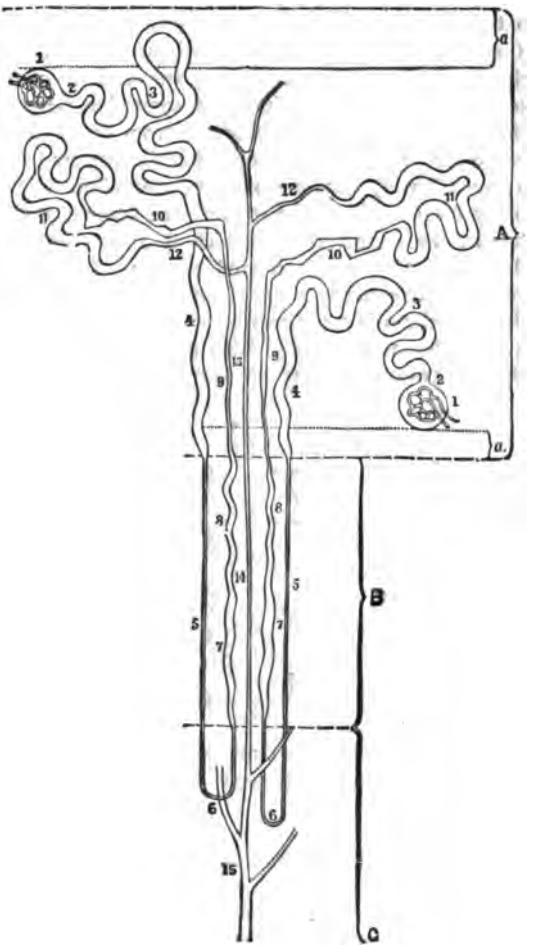

Fig. 417.—Diagram of the course of two uriniferous tubules. *A*, cortex; *B*, boundary zone; *C*, papillary zone of the medulla; *a*, *a'*, superficial and deep layers of cortex, free from glomeruli; 1, Malpighian tuft surrounded by Bowman's capsule; 2, constriction on neck; 3, proximal convoluted tubule; 4, spiral tubule; 5, descending limb of Henle's loop-tube; 6, Henle's loop; 9, wavy part of the ascending limb; 10, irregular tubule; 11, distal convoluted tubule; 12, first part of collecting tube; 13, straight part of collecting tube. (After *Klein*.)

spaces between two protrusions of these cells, so that the elements on one side alternate with those of the other, thus producing a zigzag outline to the lumen. The thick (ascending) arm of Henle's loop is lined with cylindric epithelium similar to that of the proximal convoluted tubules; the striation of the cells, however, is confined more to the basal part. The lumen is somewhat larger than in the descending arm, and the epithelium often is dislodged from the basement membrane on treatment with reagents. The distal convoluted or intercalated portion of the tubule possesses only a few (2 to 4) convolutions; the epithelium is quite high and provided with relatively large nuclei. The intercalated portion passes into a short, straight collecting tubule, the epithelium of which is almost cubic, and the lumen somewhat wider than that of the intercalated portion. The small collecting tubules have a low cylindric, irregularly shaped epithelium. In the collecting tubules of larger caliber the epithelium is more regular and is the higher the wider the tubule. The collecting tubules of one Malpighian pyramid and the adjacent parts of the columns of Bertini gradually unite to form about twenty papillary ducts, lined with high

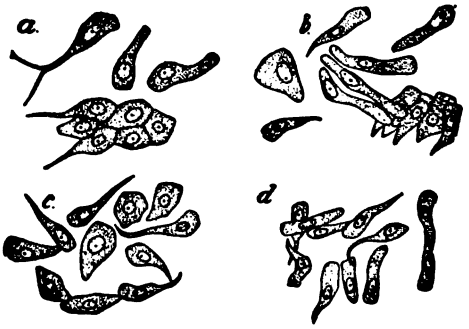

Fig. 418.—Epithelium from the urinary tract (obtained by scraping the mucosa). × 350. *a*, renal pelvis; *b*, ureter; *c*, bladder; *d*, excretory duct of prostate.

cylindric epithelium, which separately open at the apex of the papillæ (*foramina papillaria*).

After the renal artery enters from the hilus it divides and sends off arcade-shaped arteries which run at the junction of the cortex with the medulla, *i.e.*, at the base of the medullary pyramids, the convex side of the arcade directed toward the surface of the kidney. From the convex side of the arcade arise at certain distances smaller arteries (*arteria recti*), which repeatedly divide at a more or less acute angle, approaching the surface of the kidney almost parallel, and in their course giving off branches which enter the Malpighian bodies as the *vasa afferentia*. After entering the capsule of Bowman the afferent vessel divides into a number of branches and capillaries, which form a globular reticulum: the glomerulus. From the glomerulus arise branches uniting to form a return (efferent) vessel, which emerges from the capsule alongside the afferent vessel and breaks up into ordinary capillaries, which are distributed to the cortex and medulla and finally empty into the renal vein. (See Fig. 419.)

The function of the kidneys is to excrete from the blood a great part of the soluble exhausted materials. The excretion itself occurs in

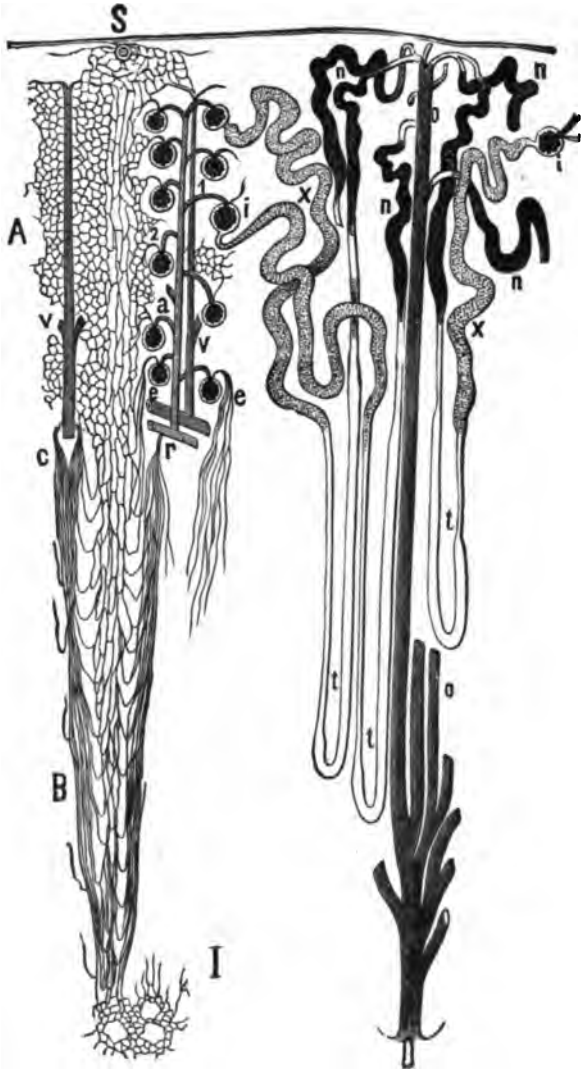

Fig. 419.—Blood-vessels and uriniferous tubules of the kidney. (Semi-diagrammatic.) *A*, capillaries of the cortex; *B*, of medulla; *a*, interlobular artery; 1, vas afferens; 2, vas efferens; *r*, *e*, vasa recta; *c*, venæ rectæ; *v*, *v*, interlobular vein; *i*, *i*, Bowman's capsule and glomerulus; *x*, *x*, convoluted tubules; *t*, *t*, Henle's loop; *o*, *o*, collecting tubes; *O*, excretory tube. (After *Landois.*)

two different portions of the kidneys: first, from the loops of the glomeruli into the capsule of Bowman, and, second, from the renal capillaries into the urinary tubules. The true parenchyma of the kidney, *i.e.*, the glandular epithelium, also is actively concerned. The *membrana propria*—the homogeneous, structureless membrane beneath the epithelium—which is rarely affected except in amyloid and calcareous infiltration, remaining uninvolved in all active and passive processes, is generally considered to belong to the stroma and not to the parenchyma. Aside from this *membrana propria*, or basement membrane, the stroma is composed of vessels, nerves, and a small amount of interstitial connective tissue.

The secretory rôle of the constituents of the renal cortex has not yet been fully established. Many defend the view of Ludwig, according to which the urinary constituents are secreted through the glomeruli, and that the urine, which from there enters the renal tubules in a very dilute state, undergoes no other change during its passage through the tubuli than concentration by absorption of water. Most authorities, however, accept the view of Heidenhain, according to which the specific constituents of the urine (*i.e.*, urea, uric acid, urates, etc.) are elaborated by the secretory activity of the epithelium of the renal tubuli, and that the greater part of the water of the urine is excreted unconcentrated by the glomeruli. The density of the secretion is decidedly greater in the intercalated, looped, and straight portions than in the convoluted portion of the tubules. Secretion of specific substances occurs only in the convoluted tubules of the first order, while exclusively or chiefly absorption of water occurs in the loops, intercalated portions, and collecting tubules. According to the investigations of Nussbaum, sugar and albumin also are excreted by the glomeruli. As regards hemoglobin, the conditions are similar to those operative in the case of albumin, since in experimental hemoglobinuria hemoglobin can be found in Bowman's capsules before it appears in the renal tubules. In markedly diseased organs in which the epithelium is greatly altered or entirely absent, there seems to be no reason to doubt that albumin can enter directly the renal tubuli.

Kryoscopy (κρύος, ice cold), the observation of the freezing-point of the blood, urine, transudates, exudates, cerebrospinal fluid, has recently been extensively employed. Normally, the freezing-point of the blood is about —0.54° C. Insufficient renal function—deficient excretion through the agency of the urine—causes accumulation of substances in the blood and increases the molecular concentration of this fluid, and the freezing-point is greatly lowered (—0.58° to —0.59° C.) : lowering of the freezing-point. When only one kidney is diseased, this method, when applied to the urine, shows whether the other organ possesses sufficient functional capacity.

The processes occurring in the kidneys are usually divided into (1) parenchymatous and (2) interstitial, and (3) such as begin with affection of the circulatory apparatus. The parenchymatous changes are divided into active and passive. The active processes are represented principally by parenchymatous nephritis, which occurs idiopathicly—*i.e.*, as an independent disease—as well as symptomaticly, *i.e.*, as an accompaniment of other diseases. It is present in

all severe febrile infectious diseases, and develops in many intoxications, both chemic and bacterial.

Parenchymatous nephritis is the most frequent form of renal disease. Nearly all the convoluted tubules of both kidneys are involved, while the straight tubules may at first remain entirely unaltered. The first stage (*stadium incrementi*) is that of cloudy swelling, in which the renal epithelia become larger, strongly granular, and clouded as the result of accumulation of albuminous granules. The increase in volume of the individual cells leads to swelling of the whole organ, especially in its anteroposterior diameter. The enlargement is confined principally to the cortex, which, upon section, is remarkably broad in proportion to the medullary pyramids. As the swelling diminishes the space for the blood-vessels of the cortex, anemia occurs in this part, and collateral hyperemia is present in the pyramids. Consequently, the cortex is strikingly pale in contrast to the medullary pyramids. The individual convoluted tubules are enlarged and cloudy. When the cloudy swelling has reached its highest degree—the acme of the process—the cortex sometimes appears to be intensely and uniformly clouded and pale gray, as if the kidney had been boiled.

If the inflammation or toxic action is very intense, hemorrhage occurs: hemorrhagic nephritis (clinicly: hematuria). This is uniformly the case in poisoning with potassium chlorate, cantharidin, etc., and often in scarlatina, malaria, and yellow fever. (See p. 587.) The hemorrhages may take place into the capsular space between the loops of the glomeruli and Bowman's capsule, or into the lumina of the urinary tubules, and rarer into the stroma. Such a kidney is studded with red points; the puncta are upon the surface, where normally no glomeruli, but only convoluted urinary tubules, are present, and are almost always larger than a glomerulus, since very frequently a group of renal tubules is filled with blood. The blood generally is discharged with the urine, or it is retained and transformed into pigment, in which state it may still be found within the urinary tubules as pigment infarct (see p. 843) long after the disease has subsided.

In simple acute, as well as in hemorrhagic parenchymatous, nephritis there is functional disturbance; the epithelia have lost their elective capacity; in addition to the normal urinary constituents, they permit the passage of albumin. If, however, the process does not make further progress, *restitutio ad integrum* is always possible—the epithelia gradually returning to their normal condition through assimilation or excretion of the excessive albuminous material. As soon, however, as the *stadium incrementi*, i.e., the stage of cloudy swelling, is followed by the *stadium decrementi*, i.e., the stage of retrogressive fatty metamorphosis,

in which the albumin granules of the cell-body are substituted by fat-granules or the minutest fat-droplets, an irreparable necrobiotic process begins. In this stage the optic character of the parenchyma is so altered by the strong refraction of the fatty material that it is more cloudy and mottled yellow. As the stroma, which thus far has remained unaltered, also generally suffers in this stage (as a result of partial fatty metamorphosis, etc.), the previously firm and quite dense consistency of the kidney usually diminishes, and, although the organ remains strongly swollen, it becomes soft and flabby. If all the albuminous material of the cortic parenchyma is transformed into fat, the almost bloodless surface of the organ is whitish yellow in color, smooth, and interrupted only by isolated red stars: the *stellulæ verheyenii,* or stars of Ferrein.

There is another affection related to this severe form of parenchymatous nephritis in which the surface of the kidney is likewise smooth

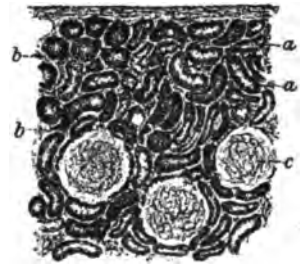

Fig. 420.—Termination of a severe acute parenchymatous nephritis in fatty metamorphosis. *a*, convoluted tubules strongly clouded, in a state of fatty metamorphosis; *b*, stroma; *c*, glomeruli contrast sharply with the urinary tubules by their lighter appearance. Low magnification. (After *Langerhans.*)

and yellow, but in which the whole organ is much more swollen and very firm in consistence. Even externally, pale-yellow points and spots separated by gray, translucent, almost glassy bands can be seen upon the surface. These are observed also on the cut surface of the greatly thickened cortex. The whole cut surface is somewhat dull, sometimes even dry, and, as a rule, the intensely hyperemic, slightly cyanotic medullary pyramids have a translucent reddish color, especially in the neighborhood of the *arcus renales.* This state of the kidneys has been designated as **"large yellow kidney."** There is also more or less intense amyloid degeneration of the vessels, especially those of the glomeruli; great swelling of the parenchyma; usually quite advanced fatty metamorphosis in which even the stroma is often more or less involved; sometimes proliferations in the stroma (*nephritis interstitialis prolifera*) and very often extensive thrombosis of the small and medium-sized veins, as a result

of marked slowing of the blood-current due to amyloid alteration of the vessels and swelling of the parenchyma. The large yellow kidney may occur idiopathicly or deuteropathicly. In the latter case it is most frequently associated with pulmonary tuberculosis, less often with valvular lesions of the heart, malaria, syphilis, and other diseases.

In the large yellow kidney fatty metamorphosis may be followed by disintegration of the altered epithelium into a fatty detritus, in which process the epithelia of Bowman's capsules and of the glomeruli are also involved. As a rule, however, death occurs before this disintegration takes place.

Essential or **unilateral hematuria** (*hematuria sine materia*) is an affection of unknown etiology, described by Sabatier, in 1889, characterized by intermittent hematuria with or without renal pain. Paus[1] distinguishes essential hematuria from, *a*, hematuria due to overexertion, wandering kidney, hydronephrosis, overdistention of the bladder in prostatic disorders, pregnancy, lactation, renal calculus, renal neoplasm, etc., and, *b*, renal hemophilia. The French attribute the affection to the influence of the nervous system; others to vasomotor disturbances in the kidneys: "angioneurotic hematuria," comparing it with vicarious menstruation. Other investigators have found small foci of parenchymatous or interstitial nephritis in the excised kidneys and attribute the hematuria to these diseased areas. It probably always is dependent upon some anatomic change. The prognosis is good, as no patient has died from the disorder.

In so-called **catarrhal nephritis (desquamative nephritis)** the convoluted tubules usually remain intact and only the straight urinary tubules are affected. The change begins in the apices of the medullary pyramids and advances from there toward the periphery of the kidney. The process consists essentially of a desquamation of the epithelium. Before this begins there is always very intense hyperemia of the otherwise only slightly reddened medullary pyramids. The hyperemia is displaced from the calices onward by a gray-white color. In the best examples a gray-white and an intensely reddened zone are seen, and occasionally, in recidives, a duplication of both of these zones occurs. Generally, the gray-white condition is observed only at the apices of the medullary pyramids. This catarrhal nephritis, then, begins with an inflammatory hyperemic stage, which is followed by desquamation and accumulation of the clouded and partly fatty metamorphosed epithelium. The epithelial masses are finally discharged with the urine, partly as single cells, partly in the form of cylinders (casts). Consequently, the termination of the process consists in a loss of parenchyma, which, however, may be readily replaced.

---

[1] Norsk Mag. f. Laegevidensk., lxx, p. 343; Ref. The Med. Chronicle, April, 1910, p. 45.

Severe parenchymatous nephritis, in which fatty metamorphosis of the whole cortic parenchyma occurs without amyloid degeneration, represents in a measure the acutest course of parenchymatous nephritis ending fatally. On the other hand, so-called chronic parenchymatous nephritis[1] begins quite latent and progresses slowly. All parts are not affected at the same time; hence, at necropsy portions of the parenchyma capable of function are found alongside of such which are in a state of fatty metamorphosis, and others which are already completely disintegrated and atrophied. This inequality results in unequal atrophy of the cortex, which acquires a coarsely granular appearance. The surface of such a kidney is distinguished from the surface of a kidney altered by interstitial processes by its coarsely granular appearance, the granula being almost as large as a millet seed. These consist of the best preserved, but in part also fatty metamorphosed portions of the parenchyma, while the depressed portions have retracted as a result of disappearance of the parenchyma. The latter appear red as a result of strong filling and distention of the vessels; the granula, on the other hand, are cloudy or mottled yellow. Within the atrophied and retracted portions secondary proliferative processes sometimes occur in the stroma. This is the termination of a chronic parenchymatous nephritis, which often extends over a period of many years.

Ernberg[2] quite recently has made extensive investigations upon acute nephritis in children and adolescents with especial reference to prognosis, the basis of his research being the examination of 156 clinicly determined cases sixteen to twenty-three years after subsidence of nephritis. The material is divided into two groups: the first including cases of acute nephritis during childhood (1 to 15 years), the second such at ages of from 15 to 30 years. All positive cases without selection were included, among them types clinicly very different (nephritis after scarlatina, measles, diphtheria, angina, acute and subacute nephritis). Exact determinations could be made in 89 cases of the first and in 38 of the second group. The examinations were directed chiefly to the kidneys and vascular system, and, judging from the protocols of the author, were conducted with such care, exactitude of method, and critic analysis that the results offer valuable material in answer to the important question of the fate of juvenile nephritics. In both groups it was shown that the patients sixteen to twenty-three years after their nephritis were, as a rule, free of symptoms of this affection. In only 2 cases where in childhood the diagnosis of "acute nephritis" had been made were there any manifestations of nephritis, and, in these, various conditions indicated that the nephritis of later years originated from other causes and, probably, represented no direct persistence of the acute nephritis of childhood. Accordingly, it would seem that nephritis in childhood does not to any considerable degree predispose to the acquisition of chronic renal affections in later years.

[1] There can be no chronic involvement of the parenchyma without interstitial change also.

[2] Nord. Med. Arkiv, 1911, Abt. II; Ref. Zeitschr. Aerzt. Fortbildung, 1911, No. 10, p. 302.

Symptoms on the part of the **vascular system** were demonstrated in 11 of 127 cases. In 5 cases there were present chiefly mild accidental murmurs which, owing to their frequency, could not, of course, be regarded as connected with the nephritis. In several instances slight increase of blood-pressure was noted. As, however, no symptoms of nephritis were present in these cases there was no reason to assume any connection with the original nephritis. Ernberg, therefore, concludes that acute nephritis in childhood or adolescence is not, as a rule, followed by any dangerous consequences in later life.

The significance that can be assigned to persistence of mild albuminuria after acute nephritis is also discussed by Ernberg. He was able carefully to follow the histories of 15 children who had been discharged with albuminuria after from three to four months in the hospital. In no case did the final examination show pathologic manifestations either in the kidneys or vascular system. On the basis of these findings, Ernberg assumes, with von Noorden, that these albuminurias, provided all other indications of progressive nephritis are absent (blood-pressure), are benign, and he justly draws attention to the fact that such patients, when treated for a long time for nephritis, may be rather injured than benefited.

Finally, Ernberg endeavored to determine whether there is any connection between acute nephritis and **orthostatic albuminuria**, making, with this object in view, serial examinations of the urine in 32 cases. In no case was he able to find orthostatic albuminuria. Although the cases investigated were between 19 and 32 years, and orthostatic albuminuria occurs chiefly in juvenile subjects, Huebner observed this affection after the twentieth year in about 32 per cent. of his cases. Ernberg's investigations, therefore, at least show that acute nephritis does not predispose to chronic orthostatic albuminuria (see below).

Albuminuria.—In the great majority of instances every persistent albuminuria is indicative of disease of the kidney and less often of the urinary tract. Transitory excretion of albumin occurs in fever, venous congestion, nervous disturbances (delirium tremens, epilepsy, cerebral concussion, etc.); also in a number of chronic constitutional and infectious diseases (severe blood affections, diabetes mellitus, tuberculosis, etc.); finally, as a result of obstruction to the flow of urine due to pressure of stones, neoplasms, etc., upon the ureter.

Physiologic, cyclic, orthostatic albuminuria are terms employed to designate an occasionally rapidly transitory excretion of albumin, seldom lasting for months or years, often periodicly intermittent and always slight, in which the most careful microscopic examination of the urine reveals not the slightest deviations, and clinic signs of an acute or chronic affection of the kidneys are lacking. This form of albuminuria is sometimes observed in the absence of any antecedent cause (among others, in the newborn); more frequently, however, only after severe bodily exertion, very hearty meals, cold baths, mental strain, violent emotional excitement, etc. For example, among 119 healthy soldiers, Leube found unquestionable albuminuria in 19—*i.e.*, in 16 per cent.—after long marches. A definitely regular cycle is often unmistakable.

Such cases are designated as **"cyclic albuminuria"** (Pavy). Usually the subjects are youthful individuals in whom the excretion of albumin is induced by change from the recumbent to the upright position: **orthostatic albuminuria.** Indeed, the albuminuria generally is most intense very soon after rising or shortly after prolonged exertion. The decidedly pronounced cyclic character of the excretion occurring under ordinary modes of life can at any time be made wholly to disappear by several days' rest in bed.

As to the justification for assuming the existence of physiologic albuminuria and of its subordinate form, opinion is divided. There is much evidence to warrant the view that, from a practic standpoint, physiologic as well as cyclic albuminuria should be regarded with much skepticism. In fact, many examples of so-called physiologic albuminuria have subsequently proved to be genuine cases of nephritis. It should also be borne in mind that many cases of contracted kidney at times show in the urine no trace of formed elements, and that the other clinic phenomena may be obscured. Senator justly warns against declaring as physiologic even an insignificant cyclic albuminuria in persons at or beyond middle age. In young individuals he considers an albumin content of 0.4 to 0.5 pro mille as the limit beyond which an albuminuria can no longer be regarded as physiologic (Lenhartz-Brooks).

Palpatory pressure in the epimesogastric region (upon the suprarenal aorta or at the level of origin of the renal arteries) may produce disturbance of the renal circulation sufficient to cause albuminuria lasting for from several minutes to twenty-four hours. Compression of the inferior vena cava above the point of entrance of the renal veins also may cause transitory albuminuria. The albuminuria thus produced is referred by Schreiber[1] not to organic lesion, but to lowering of the renal blood-pressure.

L. Piesen[2] examined 147 school children, of from 9 to 15 years of age, to determine the frequency of lordotic albuminuria. After from ten to fifteen minutes standing in the lordotic position, 61 (41.5 per cent.) showed albuminuria; after ten minutes sitting with the arms crossed behind the back, which is a common practice in many schools, but should be forbidden, 28 (19.2 per cent.) showed albuminuria. The disposition to lordotic albuminuria is at the same age, the greater the taller the child; in other respects it increases with age. Furthermore, there is a certain dependence upon mobility of the kidneys.

According to G. Kobler,[3] the urine of numerous patients who suffer with more or less severe constipation contains both albumin and casts. Casts without albuminuria are also not infrequent in this affection.

In contrast to the alterations of the parenchyma, beginning with an active stadium, stand the true passive changes. Destruction of the epithelia occurs also in these.

[1] Deutsch. Arch. f. klin. Med., xcvii, p. 1.
[2] Wien. klin. Woch., 1911, No. 1.
[3] *Ibid.*, 1910, No. 15.

Here belong, first of all, those processes which originate in the stroma of the kidney: **interstitial (productive) nephritis.** These are especially productive inflammations which pursue either an acute or a chronic course. The first form leads to the development of pus. In this case the vascular system especially, and in lesser degree also the interstitial connective tissue, is involved. An active emigration of the colorless blood-corpuscles takes place from the capillaries, and the slight amount of connective tissue proliferates. The intercellular substance disappears proportionately with the increase and accumulation of the cells. This process, which begins in the stroma, soon extends to the true parenchyma, *i.e.,* to the renal tubules; the pus-corpuscles first penetrate between the epithelial cells and enter the lumina of the urinary tubules, which can still be followed as such; the limits of the process, however, then disappear, and the whole focus becomes uniformly infiltrated with pus. Anemia is present within this inflammatory focus, and in the periphery there is sometimes, but not always, intense hyperemia, which surrounds the strongly cloudy, quite sharply defined, grayish-yellow focus proper as a red halo.

These foci are found in the cortex as well as in the pyramids. In the former case they are situated chiefly in the periphery, at the surface of the kidney, and are sometimes slightly elevated. The foci, especially the more recent, frequently have the form of a wedge (corresponding to the ramifications of a small artery), the apex of which is directed toward the pyramid. In the pyramids the foci are spindle-shaped, the long axis running parallel to the straight tubules. Here they are generally trifling in breadth and, consequently, extend over only a few straight tubules.

This form of acute interstitial nephritis occurs in several acute infectious diseases, especially in malignant endocarditis, puerperal sepsis, etc., in which it is the result of embolic metastases. In these instances infectious material, especially cocci, enters the capillaries of the kidney with the blood. The termination of this process is invariably abscess formation. As a rule, a large number of such foci are found. By further extension and confluence of smaller foci, large abscesses may sometimes form which involve the fibrous renal capsule, produce a *perinephritis apostematosa,*[1] lift the capsule from the kidney by large collection of pus, and, finally, totally destroy it, and, penetrating the surrounding adipose tissue, produce a phlegmonous paranephritis. This process occasionally extends to the peritoneum and pleura.

In other cases a reverse course takes place, the purulent process attacking the surface of the kidney from without. In this instance, espe-

[1] *Apostema:* an abscess.

cially in the beginning, the urinary passages, from the renal calices downward, may remain wholly intact.

Finally, purulent nephritis may be preceded by suppurative or diphtheritic inflammation of the urinary tract—of the bladder, ureters, renal pelvis, and calices: **pyelitis.** The latter affection also almost always involves the true renal tissue and produces a

Fig. 421.—Pyelonephritis due to obstruction of the ureter by a calculus. (Case of *Dr. F. M. Barden.*)

pyelonephritis apostematosa. Sometimes, especially in calculous formations and in diphtheritic and tuberculous processes, only the apices of the pyramids are involved; frequently, however, the process penetrates the pyramids to the cortic substance and produces foci quite analogous to those observed in the embolic form, with the difference only that the infectious material enters by way of the urinary tubules.

The pus in the kidney may be discharged externally through the urinary passages, or remain *in loco* and become inspissated, caseous, and

frequently calcified. In this form of nephritis the uninvolved parenchyma of the kidney is always in the state of parenchymatous cloudy swelling. On the other hand, the suppurative form may occur in combination with indurative as well as with amyloid changes. In connection with large abscesses and intense clouding of the remaining parenchyma, aside from a considerable increase of volume, there is usually such pronounced relaxation[1] of the whole organ that it hangs over the finger like a glove or an empty purse, the slightest agitation imparting to it a characteristic trembling motion.

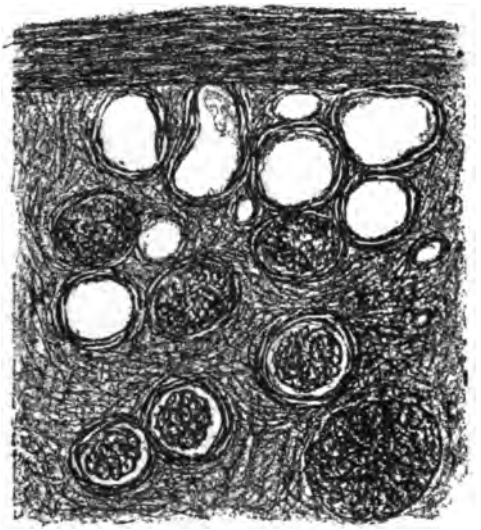

Fig. 422.—Chronic interstitial nephritis with complete disappearance of the convoluted tubules. The glomeruli are so closely arranged that in some parts the capsules are in contact. The glomeruli have in some places fallen out. The capsules are greatly thickened and concentricly lamellated. The parenchyma has completely disappeared. (After *Langerhans.*)

While acute purulent interstitial nephritis is almost always a secondary process, the chronic indurative form occurs idiopathicly as well as secondarily, in focal form, like the acute, and as a diffuse general affection. In every case the point of origin of the changes is the scanty connective tissue of the stroma. The vessels are passively involved. The process begins with proliferation of the connective tissue. **Multiple chronic interstitial nephritis** is most frequently observed in constitutional syphilis. The proliferation is often confined to small areas, but may involve also large portions of the kidney, more than one-half of the organ is sometimes thus altered. Frequently, especially in the case of smaller foci, the cortex only is affected; in other instances the pyramids also are involved. As a result of this connective-tissue proliferation the involved areas are pale, translucent, and light gray in color. The new-formed tissue, by early formation of intercellular substance, manifests a marked tendency to develop into true connective tissue; by cicatricial contraction of the intercellular

[1] *Relaxatio:* looseness; induced by the parts becoming more and more loose in consistency and more movable upon each other.

fibers, into scar tissue, and, the parenchyma undergoing atrophy, finally to form a cicatrix. In this process the parenchyma remains purely passive; it disappears by fatty metamorphosis or necrobiosis, but without preceding inflammatory swelling. This, therefore, is not an active, but a simple passive, atrophic process. The renal tubules first undergo atrophy. The glomeruli are generally more resistant (sometimes they are first affected), and in atrophy of the convoluted tubules are closely approximated (see Fig. 422), so that large cortic areas often consist only of glomeruli and new-formed connective tissue. In the formation of a scar, retraction of the surface takes place, which is to be

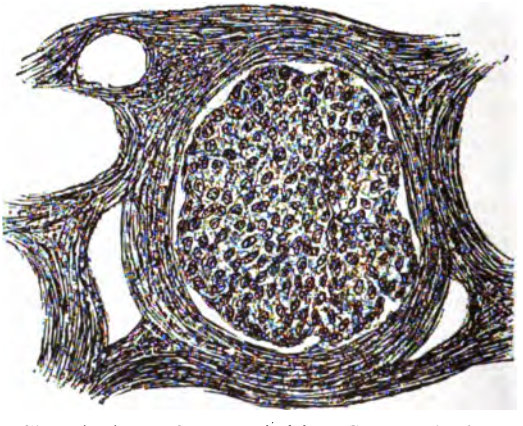

Fig. 423.—Chronic interstitial nephritis. Concentric lamellation of the new-formed connective tissue surrounding a still well preserved glomerulus. (Zeiss Apochr., 4; Comp. Ocul., 4. After *Langerhans.*)

sharply distinguished from cicatrices due to infarction and from renicular markings of the kidney (lobulated kidney), which are quite frequent and date from the time of coalescence of the reniculi to form the kidney, and have no pathologic significance. The renicular markings are always very uniform and correspond exactly to the limits of the individual reniculi.

In **general diffuse interstitial nephritis** the process begins either principally in the connective tissue between the urinary tubules or in the tissue present in the periphery of Bowman's capsules. Generally, after long duration, neither variety is met with in pure form. Mixed forms are most frequently found. In the primary stage the kidneys have a smooth surface, a quite uniform, pale-red color, and are markedly dense in consistency. As soon, however, as intercellular substance develops and retraction begins, the surface acquires a very characteristic red and

exceedingly finely granular appearance[1]: **granular atrophy.** As the granules are about the size of the finest grains of sand and project but slightly above the surface, the term smooth atrophy also is employed to designate this condition. The cut surface of such a kidney is uniformly pale red. The cortic portion on section is narrower, the pyramids shorter, so that, finally, the whole organ appears very much reduced in size. The fibrous capsule of the kidney can be removed only with difficulty, because the connective tissue which accompanies the veins upon the surface of the kidney (*stellulæ verheyenii*) into the capsule increases and results in very firm, intimate union of the capsule with the kidney. The glomeruli are gradually converted into quite refractive, glistening, homogeneous masses in which nothing can be distinguished. In this condition they are frequently the seat of calcareous deposits.

In **contracted kidney** the hilus is very frequently enlarged as the

Fig. 424.—Congenital cystic kidney. ½ natural size. (After *Langerhans.*)

result of overdevelopment—a kind of compensatory hyperplasia—of the adipose tissue in the region of the renal pelvis and calices, so that the kidney, viewed externally, appears to be only slightly or not at all reduced in size.

In many cases of interstitial nephritis the peculiar disposition to excessive formation of connective tissue is very early manifested by the occurrence of isolated **fibromata.** These are small, miliary, translucent, light-gray to whitish-gray, quite hard connective-tissue nodules, occurring especially in the region of the pyramids, and belong in the domain of genuine neoplasms.

Marked contraction in certain portions of the kidney may soon cause constriction of other parenchymatous areas still capable of function. The result is ectasis of the latter from secretion and accumulation of fluid. If the constriction is complete, true **cystic formation** results from increase of the contents. If a number of cysts lie contiguous to each other, erosion of the walls occurs as a result of atrophic processes, and larger cysts thus gradually develop from the communicating smaller cysts.

[1] Cicatrices due to infarction, on the contrary, have a smooth and grayish-white surface.

In **hydrops renum cysticus of the newborn** (see Fig. 424), which is the result of intrauterine acquired nephritis with atresia of the papillæ, and sometimes also of the ureters, a more or less large, compactly arranged conglomeration of small or large cysts up to the size of a pigeon-egg is found, which often has a certain resemblance to a bunch of ripe grapes. These congenital cystic kidneys sometimes attain enormous size. Often both kidneys are altered in this manner; sometimes, however, only one is affected, while the other is perfectly sound. In adults, also, kidneys which are altered in the same manner and very considerably enlarged are sometimes found. The individual cysts vary in size from that of a hemp seed to that of a hazelnut or walnut. According to recent investigations (Nauweck-von Kahlden), some of these cyst formations are due to atypic glandular proliferation, and, in accordance with similar

Fig. 425.—Renal concretions (beginning cystic degeneration). Fresh section. (Zeiss Apochr., 16; Comp. Ocul., 4. Reduced ⅓. After *Langerhans.*)

formations in the ovaries, are designated also as cystomata or adenocystomata. (See Fig. 424.)

While incision of the medulla of the kidney generally heals by connective-tissue cicatrix, according to Ribbert a cyst-like cavity sometimes forms in which urates may precipitate. Renal cysts occurring independently of trauma are, as above stated, usually referred to retention of water due to obstruction or occlusion of the urinary tubules through pressure exerted by contracting connective tissue. So long as the congested water is absorbed from the obstructed tubules, no cysts develop; if, however, the function of the glomeruli continues and absorption ceases, whether from interstitial change (deficiency of lymphatics), long-continued moderate pressure upon the epithelium from congestion, cysts develop. In interstitial nephritis, in which cyst formation is most frequent, the connective tissue undoubtedly contains much fewer lymph channels than normal and, therefore, is less adapted to absorption. The objection that cysts may form also in normal kidneys may be explained by the fact that, while after occlusion of a tubule the greater part of the water is absorbed, a mild congestion occurs, as in hydronephrosis, which on long duration may suffice so to alter the epithelium that it gradually loses its absorbing power.

Cyst formation may occur in the kidney also as the result of previous development of concretions within the lumen of the renal tubules. These concretions are homogeneous, glassy, usually colorless, round, oval or elliptic, inelastic, brittle masses with slightly glistening periphery on microscopic examination, which always completely occlude the lumen of the renal tubules. At first the epithelium is distinct and almost unaltered; later, however, when the concretions become larger by deposition of new lamellæ upon the external surface and appear more or less concentricly lamellated, the epithelium gradually becomes lower and assumes a squamous form, the rounded nuclei also becoming flattened or disappearing entirely. The *tunica propria* is usually unaltered; sometimes, however, it is slightly thickened, sometimes markedly thin. These concretions seldom occur singly. As a rule, the renal tubules of a larger or smaller area of the kidney are quite uniformly altered in this manner, so that in a microscopic section the concretions occur as striæ and flocculi, most frequently accompanied by interstitial nephritis. The point of predilection of these concretions is the region of the *arcus renales;* the alteration is not, however, confined entirely to this locality, but occurs in all portions of the cortex and pyramids. (See Fig. 425.)

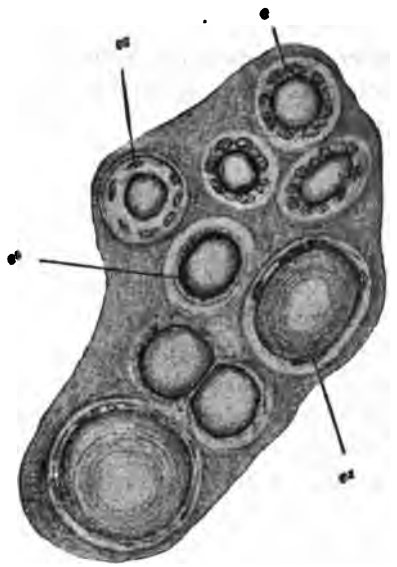

Fig. 426.—Renal concretions (beginning cystic degeneration). *e*, well-preserved epithelium; e^1, atrophic low epithelium, similar to squamous epithelium; e^2, epithelium scarcely recognizable, forms a faint granular layer; e^3, dense, peculiar, glassy epithelial layer. This has the same luster as the concretions. The epithelial ring is recognizable essentially by the nuclei; the epithelia appear to have coalesced. The larger concretions are distinctly lamellated. (Zeiss Apochr., 4; Comp. Ocul., 4. After *Langerhans.*)

When concretions present in adjacent renal tubules enlarge, not only the epithelium, but also the stroma of the kidney, suffers, the vessels being compressed and the stroma disappearing by atrophy. Adjacent concretions thus come in contact and coalesce, and larger concretions gradually develop from smaller ones. (See Fig. 426.) Liquefaction of the hard, brittle masses not infrequently occurs in the larger concretions, so that cysts

scarcely distinguishable from the renal cysts previously described are thus produced. Within the older, larger, distinctly concentricly lamellated concretions, the older central portions are frequently stained yellow to brown, while the younger peripheral lamellæ are almost always colorless.

Chronic interstitial nephritis in pure form is by no means very frequent. It may develop as an entirely independent disease, sometimes occurs in general, far-advanced arteriosclerosis as so-called arteriosclerotic contracted kidney, is a frequent accompaniment of a general gouty affection (gouty kidney), and, finally, it occurs in syphilis and certain poisonings (*e.g.*, lead). Abuse of alcohol, chiefly by disturbance of digestion and consequent formation of toxins in the ingesta, produces a similar disposition to interstitial processes in the kidneys as in the liver.

It now appears to be well established that gastrointestinal disturbances characterized by excessive fermentation and putrefaction induce degenerative arterial changes. There is ample foundation for the belief that the influence of syphilis in the production of scleroses has been exaggerated, and that many arteriosclerotic conditions attributed to this source are in reality due to the prolonged continuous influence of toxins absorbed from the intestinal tract. Indeed, Heubner and Lancereaux deny to syphilis all influence in the production of arteriosclerosis (Roger). The process in intestinal disturbances of the type above mentioned is a true intoxication of the organism. Although the liver is usually the organ most markedly involved (sclerosis), the toxins sooner or later pass the barrier opposed by this gland and act upon other organs, especially the arteries of the principal emunctories, namely: the kidneys. In the latter organs the parenchyma (the epithelial cells) is gradually and insidiously succeeded by fibrous tissue. Individuals suffering from this disturbance usually pass a urine but slightly deviating from the normal as regards specific gravity, color, and amount. Chemicly, however, large amounts of indican and occasionally traces of albumin, and not infrequently small hyaline, finely granular, epitheliated casts and such containing very minute droplets of fat, are found.

Combinations of parenchymatous and interstitial nephritis are quite frequently observed in which it is often impossible to decide which process was primary. These forms are best designated by the simple expression: chronic diffuse nephritis. These mixed forms are sometimes macroscopicly recognizable by the quite unequal involvement of certain large areas, often reniculi, sometimes, however, only by the absence of the characteristic features of granular atrophy resulting from pure parenchymatous or pure interstitial processes.

Very closely related to these combination forms is simple atrophy

of the kidneys, in which almost only passive, but no or only very slight active processes occur. This atrophic form develops in old age and in juvenile senescence. Such kidneys are small, firm or flabby, and pale reddish in color; the cortic and medullary portions are quite uniformly involved in the atrophy, so that on incision the cortex appears small and the pyramids low; the surface is irregular and more undulating than granular in appearance. In this condition small portions of the parenchyma very gradually desquamate, while the remaining parts still retain more or less of their capacity for function. This form of atrophy develops very slowly and latently without producing any clinic symptoms whatsoever.

In youthful individuals, also, atrophied glomeruli or destroyed urinary tubules or isolated epithelia in a state of fatty metamorphosis are found here and there in kidneys which apparently are intact; this is not, however, the expression of an inflammation. When large areas are involved, it is not improbable that a process has occurred in these parts. If, however, desquamation is confined to quite minute areas, *e.g.*, to individual cells, the assumption that even in the kidneys individual cells may occasionally die and be replaced is much more probable. At least, the fact that individual cells in a state of fatty metamorphosis are not infrequently found in perfectly healthy kidneys speaks in favor of this view.

Hypertrophy.—It has been shown that rabbits can live with one-third to one-fourth of the original amount of kidney substance, but only when the remaining kidney-tissue hypertrophies. When one kidney is excised, the other at once assumes the function of the missing one. This is due to the "reserve power" of the kidney, which is called forth only under certain conditions and is sufficient to compensate for the loss of the other kidney. It is also known that the remaining kidney gradually increases decidedly in size. It thus apparently again acquires "reserve power." This reserve power, however, is inconstant and depends undoubtedly upon the age and probably also upon the, for some unknown reason, quicker or slower adaptability of the organism or kidney. The enlargement is due to increase of the epithelia and synchronous elongation of the renal tubules, and enlargement of the glomeruli, *i.e.*, principally to hyperplasia. Hypertrophy is of importance in so far as, after operative removal of one kidney, too great demands should not be made upon the other. Slight amounts of toxic substances which ordinarily would be excreted exert, under these circumstances, injurious effects upon the body in general or upon the other kidney.

In the class of mixed, active, and passive alterations belongs **hydronephrosis**. Interstitial processes, which, however, do not lead to a distinctly characteristic alteration of the surface of the kidney, are

invariably found in this condition.[1] The cause of this process is intense filling and dilation of the renal pelvis and calices as a result of stasis of urine. The strong pressure thus produced renders the pyramids lower and flatter and the cortic substance thinner. In marked hydronephrosis almost all the renal parenchyma finally disappears and a large, thin-walled sac filled with fluid develops. Productive inflammatory processes, which result in enlargement and thickening, also occur in the walls of the renal pelvis and calices.

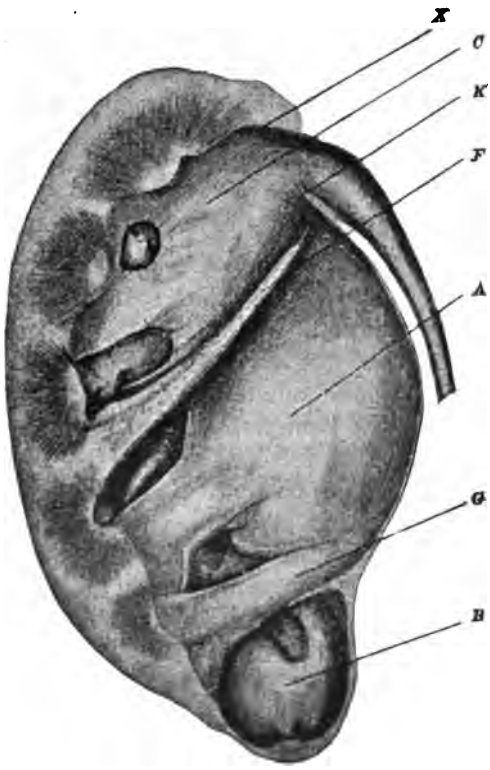

Fig. 427.—Hydronephrosis from too high origin of the ureter at the upper pole of the right kidney of a woman aged 38 years. ¼ natural size. *A*, *B*, and *C* form tripartite pelvis; *A* and *C* are separated by a fold *F*, 7 cm. in height. Communication narrow, scarcely admits one finger. Between *X* and *K* acute-angled origin of ureter; *K* acts as a valve on filling of *A*. (After *Langerhans*.)

Hydronephrosis occurs unilaterally and bilaterally. The nature of the obstruction to the discharge of urine may be very variable. In the female, stasis of urine frequently is the result of diseases which have their origin in the sexual apparatus: especially tumors of the uterus which involve or compress a ureter. Next, displacements of the uterus claim attention, particularly retroversion and *prolapsus uteri* with *inversio vaginæ*. Finally, chronic parametritis and peritonitis, especially when they occur in the region of the promontory at the entrance to the true pelvis, may produce valve-like occlusion of the ureter as a result of traction.

In men, hypertrophy of the prostate (see p. 871) and urethral stricture are the chief causes of mechanic obstruction to the discharge of the urine from the bladder. In chronic cases, dilation of the

[1] This does not, of course, exclude the occasional occurrence of active inflammatory alterations in a hydronephrotic kidney.

ureters and hydronephrosis almost always follow. Urinary calculi arrested in the ureter not infrequently produce more or less complete occlusion. Occasionally a villous growth of the bladder wall or ureter may also cause retention. Furthermore, trauma, cicatricial strictures of the ureters and urethra, displacement of the kidney, paralysis of the detrusor vesicæ, anomalous, *i.e.*, too high or acute-angled, origin of the ureter from the renal pelvis (see Fig. 427), pressure of tumors in the course of the ureters, may cause hydronephrosis.

In all inflammatory alterations of the kidney, but especially in the parenchymatous forms, peculiar masses are found within the urinary tubules which, in contradistinction to the lime and pigment infarcts occurring also in these parts, are called **urinary cylinders** or **casts.** Two chief forms are distinguished: **hyaline** and **granular.** The former have



Fig. 428.—Longitudinal and cross-section of renal tubule, illustrating mode of formation of casts. (Leitz Obj., 6; Comp. Ocul., 4. × 460.)

a clear, homogeneous, sometimes slightly, sometimes quite strongly, refractive appearance resembling fat. They consist of homogeneous albumin in a colloid state, are very soft and flexible, and, consequently, are easily forced onward by the *vis a tergo* of the urine. Granular casts are of the same form and size as hyaline casts and apparently are composed of very fine granules. Hyaline casts to the external surfaces of which intact or, more frequently, strongly granular, fatty metamorphosed, disintegrated epithelia adhere represent transition forms. All these casts are located principally in the straight urinary tubules, but they occur also in the convoluted tubules. Exceptionally, the same masses are observed also between the glomerular tufts and Bowman's capsules. In desquamative processes—so-called acute catarrhal nephritis—casts composed only of desquamated epithelia are not infrequently found in the urine.

It is very improbable that hyaline casts correspond with an aqueous albuminous secretion from the blood or with a fibrinous exudate. They stand on the verge of the mucoid and fibrinous exudates and, as may be concluded from the analogy of other exudative processes, owe their origin

to activity of the gland cells. Hence, they may justly be considered inflammatory products.

Urinary casts or **cylinders,** called also **tube casts** and **renal casts,** are molds formed by entrance into the urinary tubules of a coagulable substance which solidifies, entangling whatever it contains in its liquid state; later contracts, and is forced from the tubules by and voided with the urine. The origin of this coagulable material is unsettled. The view that it is composed of coagulable elements derived from the blood and exuded by the glomeruli, perhaps also by the tubules, is most generally accepted: at least it is applicable to the nature and origin of the majority of casts observed in the urine. Casts are produced in various pathologic states in

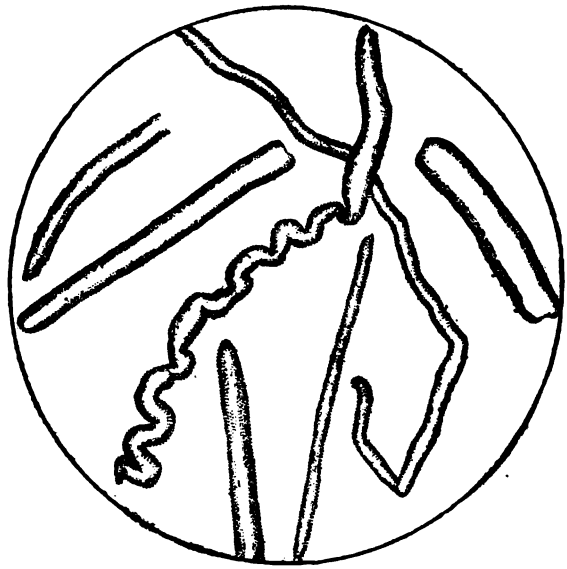

Fig. 429.—Narrow hyaline casts. × 350. (After *Peyer.*)

which the function of the kidneys is altered or disturbed by circulatory changes or toxic or inflammatory influences, and, according to some authorities, the pure hyaline forms may be observed in the urine of healthy subjects. According to Bartels, all states which produce albuminuria may give rise to the formation of casts; hence, whenever albuminuria exists, casts will, in the great majority of instances, be found in the urine. Casts may occur, however, without albuminuria, particularly in interstitial nephritis, and, *vice versâ,* albuminuria may occur without casts.

The most frequent form of urinary cast is that known as the **hyaline** or **true cast,** composed of a very pale, homogeneous, colorless, transparent substance which is rapidly soluble in acetic acid. This hyaline substance also constitutes the basis of most of the varieties of casts designated as "finely" and "coarsely granular," "epitheliated," and "mixed" or "compound" casts described below.

Hyaline casts are cylindric structures of variable length and width, and often so pale that the contour can be made out only with difficulty. Usually the contour is smooth and the thickness the same throughout; occasionally, however, the out-

line is ragged and serrated, which may be due to irregularities of the tubules in which the cast was formed, or more probably to the action of fluid currents within the tubules and to bacteria. While the length usually is about from four to five times the width, it may sometimes exceed very slightly the width (as in diabetic coma), or may be many times the width, and rarely greater than the width of the microscope field. The short casts generally are straight; the longer, while more or less straight, are often distorted and tortuous. As to the width, they may be very small (small hyaline), no more than twice the diameter of a leucocyte, or quite broad (large hyaline), equaling in diameter the width of a large epithelial cell from the bladder. Casts of small diameter are observed chiefly in circulatory (hyperemic) and toxic (ether narcosis, intestinal fermentation, etc.) disturbances of the kidneys, and in interstitial nephritis; those of large diameter are most com-

Fig. 430.—Severe acute (at first decidedly hemorrhagic) nephritis which ended fatally in four weeks. × 350. *h*, hyaline cast; *g*, granular cast; *w*, waxy cast; *e*, epithelial cast; *ep*, free renal epithelia. Also two finely granular, uniformly fatty renal epithelia.

monly observed in chronic parenchymatous processes. Occasionally small casts are observed inclosed within larger (double casts), the former evidently having been formed in a smaller portion of a renal tubule, later being dislodged into a larger portion where new deposit of coagulable material occurred. Usually the ends are rounded, though sometimes, particularly the broad forms, they are dichotomously branched at the ends; frequently they appear to have been fractured, straight or diagonally, and not rarely forms are observed in which one or both ends are sharply or bluntly pointed: an indication that they were dislodged from the point of formation before coagulation was completed. If such casts are short they may assume shapes varying widely from the ordinary cylindric form, appearing as irregular, coagulated masses. Not infrequently one end is oblique and ragged, the other drawn out into a long slender, occasionally tortuous and gradually tapering thread; the ends of such casts sometimes show spiral formation, due, it is said by some authorities, to fixation in the tubules and torsion by the current of urine. Occasionally this spiral structure is observed in the middle of the cast, and often

the spirals are so closely compressed in accordion-like manner that they lie flat upon each other the full width of the cast. Hyaline casts frequently are covered with very fine, almost imperceptible granular matter, which at times makes it difficult to say whether a given cast is hyaline or finely granular.[1] If these granules are abundant, the cast is designated as granular, and according to the size and color of the predominant granules it is designated as "finely granular," "coarsely granular," "dark granular," "pigmented," etc. Occasionally casts are seen which are hyaline at one end and composed of granular and cellular elements at the other. Various cellular elements often are found upon or inclosed in casts (leucocytes, erythrocytes, renal epithelia more or less altered in form and structure). If these cells are the chief or predominant constituents, the cast is called "leucocytic," (pus), "blood," or "epithelial," according to the nature of the cells present, and, if various cells and granula are combined, the cast is called "mixed," or "compound."

Fig. 431.—Chronic Bright's disease (chronic parenchymatous and interstitial nephritis). × 350. *h, g, e, w,* hyaline, granular, epithelial, and waxy casts; *ep,* renal epithelium; *vep,* quite uniformly fatty renal epithelium.

Epithelial and blood casts are not, strictly speaking, true casts, but aggregations of cells in a hyaline or fibrinous matrix. True **epithelial casts** are cylindric aggregations of renal tubular elements thrown off in their natural continuity, and are very infrequent. They occur most frequently in the urine of acute inflammatory processes: desquamative (catarrhal) nephritis. The cells may be macroscopicly unaltered or markedly changed (fatty, granular, or amyloid degenerated), according to the severity and stage of the affection. Casts with hyaline base containing epithelia, red blood-cells, and leucocytes are most often observed.

Blood-casts consist of coagulated fibrin inclosing red blood-corpuscles. They originate in hemorrhage into the renal tubules in which the blood coagulates. Pure forms are rare. While in most instances the individual cells are distinctly recognizable, they often are so closely packed together that the cast appears opaque, dark in contour, and coarsely granular; occasionally the cells are leached. These casts

[1] Indeed, hyaline casts are rarely free from some form of deposit.

usually are accompanied by the presence of numerous free red blood-cells in the urine, though in some cases (uric acid or calcium oxalate crystals, toxic action, etc.) only occasionally free cells may be observed.

Hemoglobin casts may be observed in the urine in extensive burns of the skin. Casts composed of hematoidin and others of detritus occasionally are seen. Urates or uric acid crystals may unite in cast form in the newborn with uric acid infarcts of the kidney. Large casts composed chiefly of bacteria are observed in pyelonephritis.

Waxy casts, owing to their great size in some instances, are often called "giant casts." They may exceed in length the width of the microscope field, and in width excel the normal diameter of the open tubules of the pyramids. They are

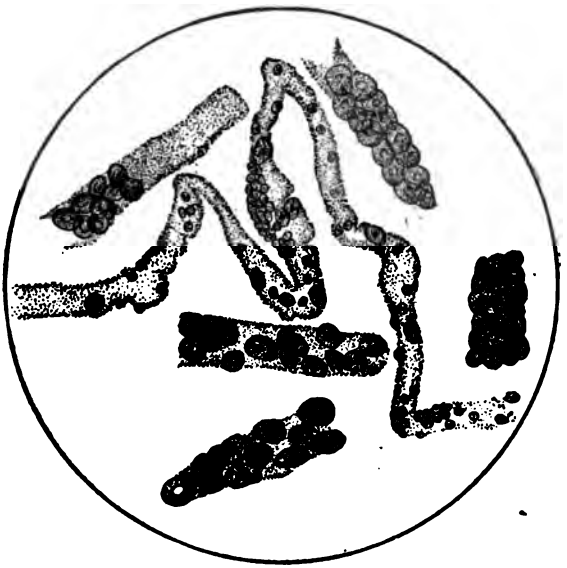

Fig. 432.—Epithelial casts. × 350. (After *Peyer.*)

characterized by their opacity, high refractive index, and pale-yellow or grayish-yellow color. They may contain the same kind of cellular and granular constituents as hyaline casts; usually, however, they present only a punctate clouding. In contradistinction to hyaline casts, they often resist the action of acetic acid and not infrequently stain reddish brown with iodine and a dirty violet (amyloid reaction) after subsequent treatment with sulphuric acid. They usually are observed in chronic nephritis and in amyloid degeneration of the kidneys.

There also occur in the urine under the same conditions as casts structures of considerable length and parallel contour and about the width of casts, which are soluble in acetic acid and, therefore, probably have the same chemic constitution as casts. These structures also may be covered with epithelia, red blood-cells, leucocytes, granula, etc., and are called **cylindroids.** They differ from true casts chiefly by the fact that they are rather bands and not cylinders. Their connection with genuine casts is shown by those examples which are united with and exceptionally are inclosed in casts. Thomas describes forms which presented at both ends

the characters of cylindroids and in the middle the features of a true cast, in which transition from one form to the other was, at both ends of the cast-like structure, a corkscrew-like spiral. Cylindroids are at times difficult to distinguish from true hyaline casts. A striking point of difference is that cylindroids taper gradually at one end into a long, wavy, corkscrew-like tail with longitudinal striations, while true hyaline casts usually are more firm and refractive, rounded at one end or both, or cut off obliquely. At times it is impossible to distinguish between a cylindroid and a given hyaline cast. It seems very probable that these cylindroids come from the renal tubules.

Török and Pollak differentiate these cylindroids from such of extrarenal origin, which are called **pseudocylindroids**. These originate from the secretions of the prostate, Cowper's and Littre's glands, the mucous glands of the bladder, the

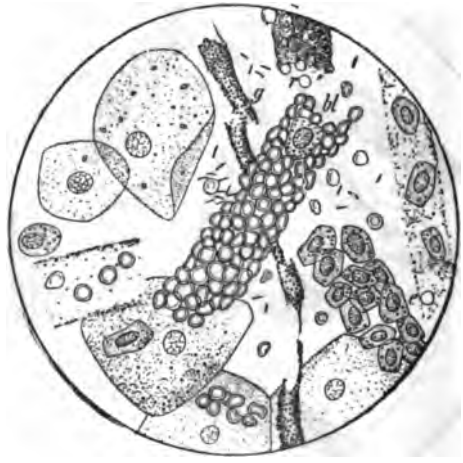

Fig. 433.—Acute hemorrhagic nephritis. × 350. Small and large squamous epithelium, hyaline casts (at the margin). *g*, finely granular cast; *bl*, red blood-corpuscle cast; *e*, tubular epithelium (arranged in cast form). Here and there are blood-corpuscle rings ("shadows" [ghosts]).

uterus and vagina; morphologicly they resemble renal cylindroids, but are insoluble in acetic acid.

The constant presence of casts is an indication of circulatory or secretory disturbance of the kidneys. Anatomic alteration may be lacking not only in slight and transitory, but also, though rarely, in abundant and chronic, albuminuria and cylindruria. Therefore, the diagnosis of parenchymatous nephritis cannot be made on the presence of these two factors without other manifestations of disease, especially when the albuminuria is slight and the casts few in number and chiefly of the hyaline type. According to Thomas, the cylindruria is then not nephritidogenous, but nephroangiogenous. Every urine, however, which contains over a protracted period large numbers of hyaline and especially dark granular casts comes from an inflamed kidney. The nature of the inflammation is revealed by the accompanying cellular elements. The process is acute when abundant pale casts containing chiefly unaltered or only slightly swollen and degenerated renal epithelia

and occasional dark granular, but no waxy, casts are present. Preponderance of dark granular casts and many waxy casts indicate chronic nephritis. Fatty casts occur in subacute and chronic inflammatory processes which lead to fatty degeneration of the kidney parenchyma: large white kidney or contracted kidney with fatty degeneration. The number of casts usually is in proportion to the degree of albuminuria and the severity of the affection. However, numerous exceptions occur here. Not infrequently the casts appear at the beginning of the nephritis before albuminuria is demonstrable, and in healing of an acute Bright's they very commonly persist after the albuminuria has ceased. Shortly before death numerous, very thick and long casts often appear. The number of casts is not infrequently increased also during a uremic attack. A certain diagnostic interest is attached to the casts occurring in diabetic coma. They not infrequently appear even shortly

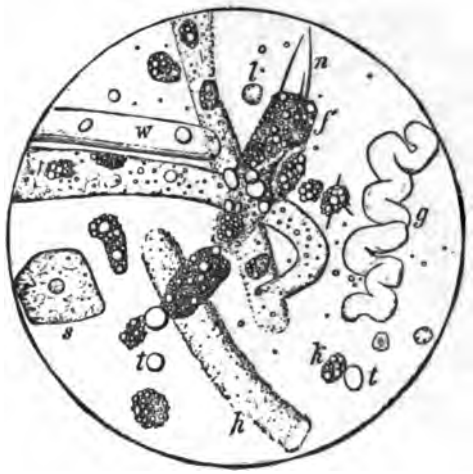

Fig. 434.—Large white kidney. × 350. *h*, hyaline cast; *g*, spiral cast; *w*, waxy cast; *f*, fat-granule cast with *n*, fat needles. Still finer needles of this type upon the neighboring fat-granule spherule; *k*, fat-granule cell; *l*, leucocyte; *s*, vaginal epithelium; *t*, fat-droplets.

before the attack, and constantly and often in large numbers during the coma, in the form of short stumps of hyaline and dull, glistening granular forms. If the attack subsides, which occurs in very few instances, the casts may rapidly and completely disappear. It is worthy of mention that even when large numbers of casts occur the albumin tests may show only slight clouding of the urine.

On the other hand, other substances which are excreted by the renal tubules and are found within them *post mortem* originate directly from the blood. These are the so-called **pigment infarcts** which sometimes fill almost all the urinary tubules, *e.g.*, in attacks of malaria ending fatally within a few hours, or in severe poisoning with potassium chlorate (as methemoglobin). Microscopicly, the pigment (melanin, methemoglobin, etc.) has a certain resemblance to red blood-corpuscles, by the

disintegration of which it originates. It consists of small, polygonal or round, yellow granules which, when present in large amount, impart to the urine a brownish-red or blackish color. On long duration of the disease, these granules, consisting essentially of hemoglobin, coalesce by agglutination into dark, reddish-brown casts which are more readily retained in the renal tubules than hyaline casts, because they form a much firmer and more compact mass. In this condition the glandular cells do not actively participate. Hemoglobinuria or methemoglobinuria occurs on injection of animal and occasionally of human blood into the circulation of man; in certain poisonings (especially by potassium chlorate; furthermore, arseniureted hydrogen, pyrogallic acid, carbolic acid, toadstools, venom of reptiles, etc.); in extensive burns, and in certain infectious diseases such as malaria, etc.



Fig. 435. — Nephritis hæmorrhagica gravis in a case of puerperal sepsis. The black lines correspond to convoluted and straight tubules filled with blood. × 8. (After *Langerhans*.)

In hemorrhagic processes in the kidneys (as a result of infectious diseases, *e.g.*, scarlatina; see p. 561), the extravasate is found within Bowman's capsules and in the renal tubules. After a time granular, amorphous blood-pigment, which may accumulate to a marked degree in certain localities and form pigment infarcts, develops from the extravasates. More rarely crystalline pigment—a **hematoidin infarct**—develops from the extravasated blood.

Most closely related to these pigment infarcts are the infarcts composed of bile coloring matter. The kidney is the organ through which all the bile coloring matter taken up by the blood is excreted. In mild icterus only slight, diffuse icteric staining is observed. In intense and chronic icterus, however, yellowish-red or greenish, granular bile-pigment accumulates in the renal tubules. If parenchymatous nephritis exists, as is always the case in severe icterus, the glandular epithelia are intensely stained; in this condition they are apparently especially dis-

posed to absorb bile coloring matter. The hyaline casts also are slightly bile-stained.

The extremely rare occurrence of so-called **silver infarcts** will briefly be referred to here more for their scientific interest than for their pathologic significance. These occur after prolonged use of silver preparations, always in conjunction with staining of the skin (argyria), and consist in the deposition of minute granules of metallic silver in the *tunica propria* of the renal tubules and especially within Bowman's capsules. When the granules of metallic silver are compactly arranged, the affected part has a light-brown hue. Sometimes the glomeruli are macroscopicly very distinct as a result of this.

Fig. 436.—Uric acid infarct in a gouty subject. Acid sodium urate in small rhombic crystals, partly destroyed. (Zeiss Apochr., 4; Comp. Ocul., 4. After *Langerhans*.)

Uric acid infarcts are of more importance and greater frequency. These occur in two very different forms: on the one hand, as acid ammonium urate in the newborn between the 2d and 14th day of life, and, on the other hand, as acid sodium urate in gout in the later years of life.

Acid ammonium urate[1] is almost always found in great abundance as numerous, reddish-yellow striæ in the collecting tubules of the pyramids. There is no reaction in the surrounding tissue. Ammonium urate consists of small, amorphous clumps and spherules; it is so frequently observed that it probably is more of a physiologic than a pathologic finding, which, however, is of forensic importance in so far as it occurs only after respiration has been established, and, therefore, may be made use of to decide the question whether a child has breathed or not.[2]

On the other hand, infarcts of **acid sodium urate** are of eminent pathologic significance as a concomitant of a general gouty affection. They are recognizable only by careful inspection of the cut surface of

[1] Sodium hydrate dissolves acid ammonium urate. On standing, uric acid is separated in crystalline form.

[2] Acid ammonium urate is sometimes found also in somewhat older children, *e.g.*, at the 5th to 6th month of life.

the kidney as isolated, distinctly chalk-white striæ in various portions of the pyramids, particularly in the middle portions. Acid sodium urate consists of rhombic plates which frequently form very long spicules. These collect in the straight tubules and cause distention of the lumen. Independently of these infarcts, there is present a general interstitial inflammation, which, when the disease is extensive and of long standing, results in induration and contraction of the whole kidney: **gouty kidney.**

Lime infarcts, the most frequent of all infarcts, likewise produce in the pyramids, especially in the papillary apices, fine white striæ, and, therefore, often give rise to confusion with uric acid infarcts. The lime

Fig. 437.—Hippuric acid, *a-c;* sodium urate, *d,* and uric acid in whetstone, dumb-bell, and rod form, *e-h.* × 350.

—phosphate as well as carbonate—occurs in two localities: 1, in the lumen of the urinary tract; 2, in the tissue itself. In the latter case the process is one of lime infiltration of the *tunica propria* of the renal tubules, especially of the collecting tubules within the papillæ. The lime is here deposited in the form of very minute granules at those points deprived of epithelia, without coalescing, as in calcification of glomeruli, to form a homogeneous mass. The impregnation is usually not so complete as to render unrecognizable the otherwise glassy-clear membrane. Lime occurs everywhere within the urinary tract: within Bowman's capsules, between the capsules and glomerular tufts, as well as in the convoluted and straight renal tubules. The lime is frequently found everywhere at the same time. When the lime is located within numerous degenerated glomeruli, the surface of the kidney appears as though sprinkled with chalk. If, however, the lime is in the renal tubules, it is

PLATE XIV

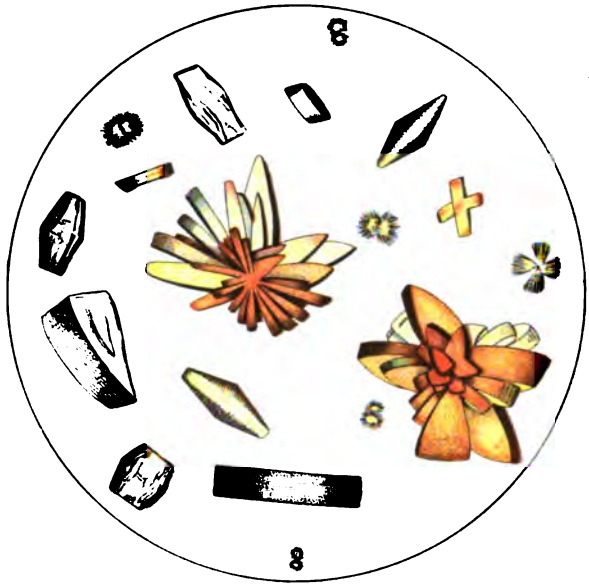

Uric acid crystals. Normal color. × 450. (After *Peyer.*)

Uric acid crystals with amorphous urates. × 450. (After *Peyer.*)

then usually impossible macroscopicly to distinguish true infarct from calcareous infiltration: in both instances delicate white striæ are seen. Lime usually forms coarse granules and clumps within the lumen of the tubules, which coalesce to form sausage-shaped bodies, and generally have a coarsely nodular surface.

In certain poisonings, especially with corrosive sublimate (see p. 326), there is very abundant excretion of lime into the renal tubules without any macroscopic evidence of its presence. If death occurs very quickly, the lime appears microscopicly as a very thin coating upon the epithelia like a layer of sugar. On addition of dilute acetic acid these freshly deposited masses of lime quickly and completely dissolve and the epithelia then appear unaltered. If, however, several days elapse before death occurs, then sausage-shaped clumps of lime, which are also macroscopicly unrecognizable and characterized by slight refractive index and ready solubility, are found in the lumen of the urinary tubules.

Renal calculi, owing to their correspondence with vesical calculi, were discussed under alterations of the bladder. Here it may be stated only that by renal calculi is understood stones occurring in the renal pelvis and calices: that these renal stones occur outside the kidney-tissue, *i.e.*, are really urinary calculi. (See p. 855.)

In severe parenchymatous nephritis fatty metamorphosis is quite frequently found in the region of the capillaries, while in interstitial processes proliferation of the nuclei of the capillaries is observed.

Proliferation and thickening of the walls of the larger vessels, especially of the veins, occur regularly in long-continued congestion of the kidneys; this is always associated with permanent dilation. The vessels, therefore, are markedly wide and gaping. These disturbances develop after all diseases which produce congestion in the area of the vena cava, *i.e.*, after diseases of the heart and lungs, especially in mitral stenosis and insufficiency of the tricuspid and aortic valves, and in chronic pulmonary emphysema. Here a gradually increasing induration of the organ and strong venous, cyanotic hyperemia are observed in the kidney. This condition of the kidney is designated as **red** or **cyanotic induration.** On incision the pyramids are dark red, while the cortex always has a paler, gray-red color—a proof that the congestion must be stronger in the pyramids. The blood of the pyramids is conveyed to the vena cava solely through the vena renalis, while other channels are open to the blood of the cortic substance through the vessels of the renal surface—the *stellulæ verheyenii*—which convey their blood to the lumbar veins. Accordingly, the sequelæ of chronic venous congestion are more strongly marked in the region of the pyramids than in the cortic substance. The pyramids suffer quite early as a result of catarrh of the straight renal

tubules: the catarrhal nephritis already mentioned. Finally, atrophy—primary fatty metamorphosis without antecedent inflammation—occurs also in the parenchyma of the cortex, as a result of the continued faulty nutrition. This fatty metamorphosis may be so extensive that the surface, thickly studded with minute yellow puncta, finally assumes a yellowish-red color. In this state the intercellular substance of the interstitial connective tissue is increased, though without marked cellular proliferation. The surface of the kidney may become somewhat uneven, and often the capsule is somewhat more difficult to strip off than is the case in a healthy kidney.

Arterial hyperemia occurs principally as collateral fluxion of the pyramids in cloudy swelling of the cortex, and in amyloid degeneration of the cortic substance. The existing anemia of the cortex is a pure ischemia. **Amyloid degeneration** of the kidneys (see p. 149) is generally limited to the vessels, rarely extends to the tunica propria of the renal tubules, but never to the true parenchyma, *i.e.*, the gland cells. Amyloid degeneration is found only in kidneys in which other changes—parenchymatous or interstitial processes—also are manifest. The constant occurrence of amyloid substance in the large yellow kidney has already been mentioned. (See p. 822.) The unusually intense fatty metamorphosis of the parenchyma and of the stroma occurring here is partly secondary to the amyloid degeneration itself, inasmuch as the latter causes marked ischemia and nutritive disturbances. Sometimes the cortex, sometimes the medullary substance, is more intensely or solely the seat of amyloid degeneration. Amyloid degeneration is always a concomitant of a general cachexia due to pulmonary and intestinal tuberculosis, syphilis, chronic malaria, severe cardiac lesions, bone suppurations, chronic inflammation of the kidneys, etc.

In amyloid degeneration and coexistent parenchymatous nephritis there is, as a rule, severe local disturbance of the circulation and usually also general circulatory disturbance due to cardiac weakness. Consequently, the already-mentioned **thrombosis** not infrequently develops in the region of the *vena renalis*. This may occur also in other cases; in addition to cardiac weakness, local circulatory disturbance also is always present. The condition, therefore, is one of marantic thrombosis. As a rule, this begins at the vascular arches between the medullary and cortic substance, advances toward the venous trunks, and, finally, may occlude the whole *vena renalis*. In some cases the thrombosis extends even through the vena cava into the right auricle. From this more independent, primary thrombosis of the *vena renalis* is to be distinguished consecutive, secondary thrombosis, namely, thrombosis of the *vena renalis sinistra* in women, in whom the thrombosis originates in the *vena sper-*

matica (this opens on the left side into the *vena renalis*). In this event the danger for the kidneys is not so great, because the thrombi develop slowly and give time for the collateral veins, which convey the blood through the capsule into the lumbar veins, to assume the function. The thrombus may soften or become organized; in the former case large fragments are usually dislodged. These enter the lungs as emboli and produce either pulmonary apoplexy or infarction.

When the renal artery is occluded by an embolus, the circulation suddenly ceases and the kidney dies in a short time, the parenchyma being destroyed by so-called primary fatty metamorphosis. If only one branch of the *arteria renalis* is occluded, so-called **hemorrhagic infarction** is produced. (See p. 89.) In this condition the portion of the kidney rendered functionless is not, however, choked with blood, as might readily be assumed from the designation "infarct,"[1] but anemic, bloodless. True infarction, *i.e.*, intense engorgement of the vessels and escape of blood, occurs only at the junction of the dead part with the adjacent living structures. The center of the dead part, *i.e.*, of the so-called infarct, always remains bloodless. This infarct varies greatly in size; sometimes several small infarcts develop in a single reniculus, apparently as a result of disintegration of one embolus. If the latter consists of infectious material, the *nephritis apostematosa* (suppurative nephritis) already described develops. In the other case the so-called fibrin-wedge originates from the infarct, from which a cicatrix, which is sometimes slightly pigmented, develops by shrinkage. If this cicatrix is not pigmented, it is sometimes very difficult to distinguish from syphilitic cicatrices of the kidney. (See p. 556.) Sometimes the embolus, which in the mean time has become organized or calcified, can be found in the afferent artery.

Displacements of the kidney have already been mentioned under Malformations. (See p. 206.) The semischematic illustration (see Fig. 438) of a case which came to necropsy gives an example of displacement which is of frequent occurrence.

Aside from the fibromata already mentioned as occurring in interstitial nephritis, and the small, flat, yellow, disseminated, suprarenal germinal rests, first correctly interpreted by Grawitz, which generally are situated upon the surface of the kidney, seldom beneath the surface, primary tumors are of rare occurrence in the kidneys. Lipomata, myxomata, and myxolipomata usually produce no symptoms and are rather accidental necropsy findings. Myomata (smooth: leiomyoma, and striated muscle: rhabdomyoma) are found chiefly in small children. *Myoma lævicellulare,* as shown by Eberth, originates from the wide-meshed retic-

[1] *Infarcire:* to stuff.

ulum of smooth musculature upon the surface of the kidney and forms small nodules scarcely as large as a pea, while, according to Cohnheim, *myoma striocellulare renis* is due to a *vitium primæ formationis, i.e.,* to isolation of individual germinal muscle-cells from the primitive vertebral plates (from which part of the musculature of the trunk develops). As a mixed tumor with sarcoma and as rhabdomyosarcoma, myoma striocellulare forms tumors of very considerable dimensions (up to eleven pounds in weight). Aside from rhabdomyoma and the retention tumors above mentioned, tumors recognizable during life are: hydronephrosis, pyonephrosis, and cystic kidneys, including adenocystoma (see Fig. 439); the not infrequent renal carcinoma, and the rare sarcomata. (See Fig. 123.) Among the metastases, chiefly carcinomata and sarcomata involve the kidney substance.

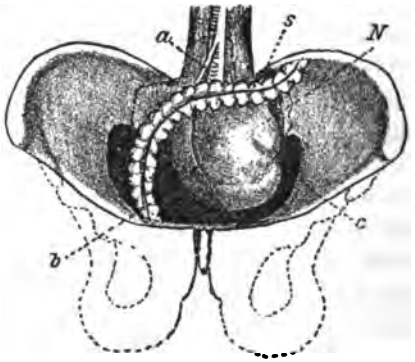

Fig. 438.—Displacement of the left kidney. The kidney lies upon the os sacrum; the sigmoid runs above and to the right of the displaced kidney. The left renal artery arises from the anterior surface of the aorta, 5 cm. below the right renal artery. Pelvis drawn semischematic. *a,* left renal artery; *b,* vein on the anterior surface of the kidney, runs in an arc to the right; *c,* hilus of the kidney outward and laterally; *N,* left kidney; *S,* sigmoid. Greatly reduced. (After *Langerhans.*)

Primary tumors (*strumæ aberratæ suprarenales*)—*heterotope hypernephroma*—not infrequently develop from displaced suprarenal germinal rests, which are sometimes isolated, sometimes multiple, and usually the size of a millet or hemp seed. These are hazelnut- to walnut- sized tumors, which, like *strumæ suprarenales,* reproduce essentially the constituents and the structure of the yellow cortic substance of the suprarenal glands. Not infrequently, however, malignant tumors also originate from these misplaced *strumæ suprarenales.* Then atypic proliferation of the epithelia occurs, these becoming morphologicly somewhat altered and assuming a more indifferent form. These tumors may attain

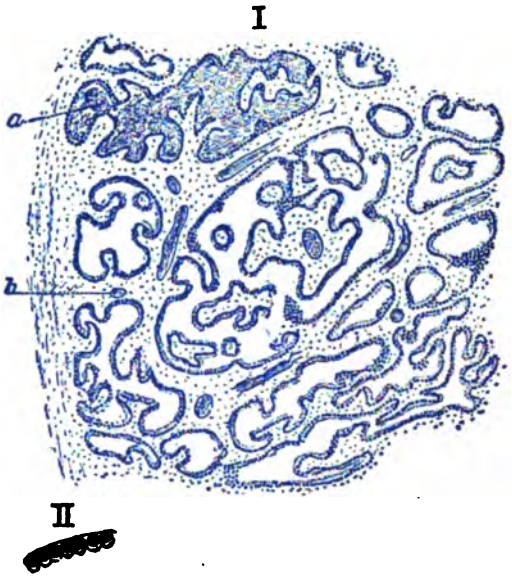

Fig. 439.—Papillary adenocystoma of the kidney. (The tumor was situated in the cortex and was the size of a pea.) I. *a*, glandular tube with papillary excrescences; blood in the tubules; *b*, blood-vessels in the stroma. Low magnification. II. Cell lining of the tubule, highly magnified.

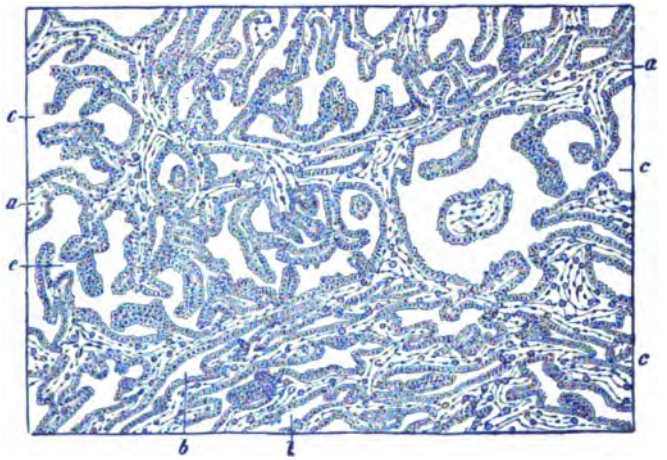

Fig. 440.—Papillary cystadenoma of the kidney. *a*, stroma; *b*, *c*, gland tubes with papillary excrescences. × 30. (After *Ziegler*.)

considerable dimensions, become larger than the fist, and form metastases. They are described in literature under various names. According to the observations thus far made and announced, they are best classed with the carcinomata.

Besides the tumors already mentioned, there is a form of kidney tumor which requires separate consideration in so far as the process is not an atypic proliferation of epithelial cells of the developed kidney, but one in which there probably is development early in life of incomplete embryonic tissue, and, therefore, frequent in childhood. This form of

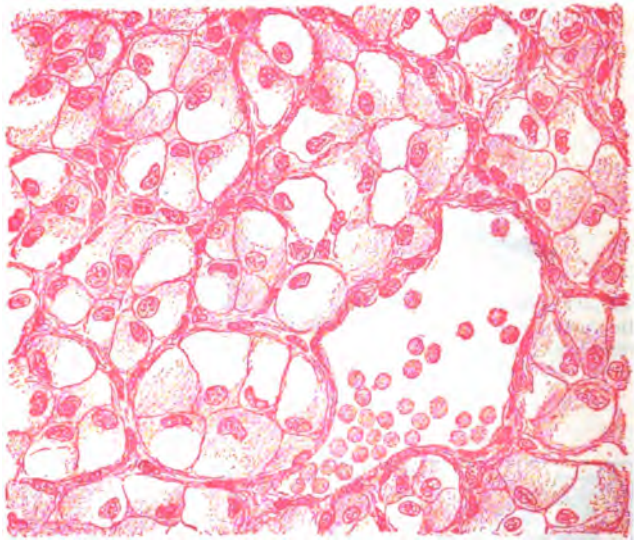

Fig. 441.—Hypernephroma of the kidney. × 500. (After *Ziegler.*)

tumor is degenerated partly as **carcinoma sarcomatodes,** partly as adenocarcinoma. It is characterized by a very richly cellular structure and the combination of glandular elements (with the character of glandular tubules) and very richly cellular, sarcomatoid connective tissue. (See Fig. 123.) It is assumed that the formation of these tumors begins in intrauterine life. Hence, they are sometimes called b l a s t o m a t a .

Except the echinococcus, which is not infrequent and may form cysts of considerable dimensions, e n t o z o a are rare in the kidney. The occurrence of *Dioctophyme renale* (see p. 366) and *Pentastoma* is very rare. In the tropics, *Filaria sanguinis* and *Schistosomum hæmatobium* are frequent. (See p. 375.)

URINARY TRACT.

That portion of the uropoietic system known as the urinary tract includes the renal calices, renal pelves, ureters, bladder, and urethra.

The inflammatory processes of these parts are divided into superficial and deep; the former are the most common processes. Here belong all catarrhal affections. Among these, gonorrhea, "clap" (see Infectious Diseases, p. 495), which in the male has its typic seat in the urethra, to which it usually is confined, is by far the most frequent. Non-infectious catarrhs are extremely rare in the urethra, and then are almost always an accompaniment of a catarrhal process located higher in the urinary tract, *i.e.*, in the bladder, the renal calices, or renal pelves, the result of foreign bodies (especially of calculi, later to be considered), passage of cold sounds, or certain drugs, such as cantharides, etc. According as the irritant is of internal or external origin, the catarrh extends either from above downward or from below upward. The catarrhal secretions are purulent, mucous (usually mixed with cells), or albuminous. All these catarrhs begin with intense hyperemia, which may involve the whole mucous membrane or occur in macular form, *e.g.*, roseola-like in the bladder, and then lead to extravasates: petechiæ in the mucous membrane.[1] By confluence of the small hyperemic spots large macular hyperemia develops, *e.g.*, in typhoid fever. In variola and varioloid, variola-like forms occur, and, on use of pungent resins, cubebs, and copaiba, macular reddening, analogous to macular erythema, which occasionally appears upon the external skin, sometimes develops. Finally, contamination and traumatism through the agency of catheters are frequent causes of long-continued catarrhs and inflammations. In all these states there is either a purulent or a mucocellular catarrh, seldom a fibrinous catarrh. If fibrin coagula form in the upper portions of the urinary tract, considerable interference with the discharge of urine through the urethra is always produced. The latter form is frequent in the tropics, but relatively rare with us, most often after taking cantharides and in the neighborhood of diphtheritic foci.

In the purulent processes those with intact surface and those associated with ulceration may be distinguished. By discharge of a prostatic abscess into the urethra deep ulcerations develop in the urethra; on rupture externally periprostatitis occurs, and when the process extends to the adipose tissue paraprostatitis and purulent paracystitis occur. In a similar manner, ulcerative pyelitis may result from rupture of a renal abscess into the calices.

[1] Intense extravasates, with and without distinct interruption of continuity, are found in trauma, especially in fracture of the pelvis.

Sometimes the pus is not discharged; then the renal pelvis and calices are considerably distended by retention of the pus. After destruction of the walls the pus may rupture externally or, on long retention, undergo fatty disintegration and form a greasy, butter-like mass in which cholesterin and lime precipitates are found. On the other hand, if the pus is discharged, the mucous membrane becomes smooth and the process is arrested, or the inflammation becomes chronic and leads to progressive induration.

The most frequent cause of ulcerative processes in the urinary bladder are diphtheritic processes. These not infrequently occur in the mucous membrane of the urinary bladder (see Diphtheria, p. 525), and are either confined to small areas or involve the whole mucosa. In the latter case total necrosis of the whole mucous membrane of the bladder results. The diphtheriticly infiltrated areas, and in part also the diphtheritic ulcers, are frequently the seat of deposits of urates. In higher degrees of severity the diphtheritic areas may be rough and stony to the touch, as a result of this complication. Healing may take place by cicatrization; this, however, is rare. As a rule, diphtheria in these localities is malignant and finally causes death. The diphtheritic process occurs also in the renal pelvis and calices and may involve the external surface of the papillæ protruding into the calices. In most cases diphtheritic pyelitis develops after diphtheritic cystitis, and sometimes also primarily in stone formation in the renal pelvis, or in infectious diseases, *e.g.*, in cholera or sepsis.

There is a certain connection of thrombosis of the bladder veins, which is not very rare, with diphtheritic affections of the urinary bladder. This thrombosis may result in the formation of phleboliths or become organized. Dilations of the veins at the neck of the bladder produce a condition similar to that observed in the hemorrhoidal veins, which often is accompanied by strangury or ischuria. Thrombosis easily occurs in these varices also. The thrombosis is sometimes followed by inflammation of the walls of the veins—phlebitis, thrombophlebitis—which may extend into the neighboring parts and occasionally also cause diphtheritic or phlegmonous affection of the bladder.

In contrast to this superficial form of thrombosis stands the deeper form. When infectious material is present, this form causes thrombophlebitis and inflammatory swelling in the neighborhood, or even phlegmonous processes. Thrombosis unaccompanied by infectious germs is found principally in cachectic states as marantic thrombosis. These deeply situated thrombi not infrequently furnish material for pulmonary embolism.

Under certain conditions diphtheritic processes develop also after coarse external violence or after introduction of unclean instruments (*e.g.*, catheters), especially in connection with injuries to the mucous membrane, wounds, and vesical calculi.

Malakoplakia (v. Hansemann), *cystite en plaques*, is a rare affection of the urinary bladder occurring in the form of round or ovoid, flat, somewhat fungoid, yellowish-white foci with reddish periphery, varying

Fig. 442.—Oxalate calculi. Schematic.

in dimensions from the size of the head of a pin to that of a dime. The process usually is associated with cystitis. It is a variety of infectious granuloma the foci of which consist of large cells and peculiar spheric lime and ferruginous concrements, the origin of which has been variously interpreted. The etiology is unknown, though it probably is an especial variety of chronic circumscribed cystitis. Similar alterations occur exceptionally also in the ureters and renal pelvis.

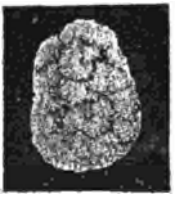

Fig. 443.—Vesic calculus (earthy stone). Natural size.
(After *Langerhans.*)

Vesic calculi are divided into three chief categories:—

1. Earthy calculi (phosphatic stones: phosphate and carbonate of lime, magnesia).
2. Oxalate calculi (oxalate of lime).
3. Urate calculi (uric acid stones).

Cystin calculi are rare.

Although calcium oxalate is colorless, all oxalate calculi are colored: dark brownish yellow to blackish brown. They are characterized by their rough, mulberry-like surface. (See Fig. 442, *A*.) The prominent granules sometimes form long protuberances (see Fig. 442, *B*), which, again,

may branch out (see Fig. 442, *C*), and occasionally are sharply pointed, irregularly spiculated. (See Fig. 442, *D*.) These stones, of course, are very irritating.

Urate stones likewise are colored, similar to the brick-dust sediment, more reddish yellow, between red and light brown. The surface may be smooth; it is sometimes somewhat nodular, resembling a mulberry.

The earthy stones are usually gray-white, amorphous, granular precipitates, which coalesce to form porous, pumice-stone-like masses.

Fig. 444.—Calcium oxalate crystals in urine. × 350.

Of these three groups the oxalate stones are the hardest; next come uric acid stones, while the earthy stones are the least hard.

The uric acid and the oxalate stones are referable to an alteration in the composition of the blood. Uric acid and salts of both uric and oxalic acid frequently occur in one stone. The earthy stones are often composed of many things, so that a large number of categories may be differentiated. Especially the stones composed of triple phosphate originating from alkalinity of the urine must be separated. Under the influence of temporary alkalinity of the urine, triple phosphate forms secondary deposits upon other stones. The lamellated deposits occur as a result of the catarrhal irritation caused by the stones. When, therefore, lamellæ of phosphate of lime or magnesia are found in old stones, it always may be

assumed that these correspond to temporary local irritations. In most cases only one stone of considerable size develops; sometimes, however, several small ones are found, and rarely several large ones.

Fig. 445.—Crystals of triple (ammoniomagnesian) phosphate, *t*, and ammonium urate, *a*. × 350.



Fig. 446.—Feathery crystals of triple phosphate. × 350. (After *Tyson*.)

Ammoniomagnesian phosphate forms characteristic crystals. (See Figs. 445, *t*, and 447, *a*.) Sometimes these become so large, especially in the renal pelvis, that they can be recognized with the naked eye. The very large crystals have, as a rule, blunt corners and sides. Sometimes they assume a feathery shape. (See Fig. 446.)

Ammonium urate does not crystallize, forms the *sedimentum roseum* occurs as very small granules (see Fig. 447, *A*), which coalesce to form small, spheric formations (see Fig. 447, *B*), and sometimes have small spiculate (see Fig. 447, *C*), or large, spike-like (see Fig. 447, *b*[1]) processes. These stones develop by concentric depositions. Sometimes foreign bodies in the bladder, *e.g.*, blood-coagula, pins, etc., are the cause of stone formation.

Calcium oxalate (envelope crystals, octahedra) develops regularly in acid fermentation of the urine.

Cystin calculi are very rare. According to E. Loumeau,[2] only about 50 to 60 have been reported since 1810, when the first stone found in an infant's bladder was examined by Wollaston, who found it to be composed almost wholly of a substance called by him "cystic oxide," for which Berzelius later substituted the name "cystin," a substance rich in sulphur. The occurrence of cystin in the urine and its precipitation in the form of calculi in some portion of the urinary passages are indicative of disturbances in nutrition the nature of which is problematic.

Fig. 447, *a*.

Fig. 447.—Schematic.

Fig. 447, *b*.

According to Loumeau, cystin may be regarded as a transition product between the sulphur-containing albuminous or protein substances and the sulphates which represent the terminal stage of complete oxidation. The sulphates of normal urine are sulphur oxides. If oxidation is such that the initial protein sulphur is not converted into the terminal state of oxidized sulphur, the intermediate product—cystin—is excreted. Hence, cystinuria becomes manifest in an organism with retarded or diminished oxidation, indicative, according to present conceptions, of insufficiency of the liver.

When stones are situated in the renal calices or pelvis, they usually fill the lumen by gradual growth, adjusting themselves to the form of the renal calices and pelvis. Stones in the ureters are least frequent; probably they come from the renal calices and can traverse the ureter only to a certain point.

Tumors of the prostate (see Male Sexual Organs, p. 873) and urethral stricture are the most frequent cause of dilation of the bladder by retention of urine. The result always is trabecular hypertrophy of the bladder. The trabeculæ of such a bladder protrude distinctly into the lumen as an irregular reticulum of flat-round

[1] The illustrations in Figs. 447, *a*, and 447, *b*, are highly magnified.
[2] La Province médicale, 1910, No. 15.

PLATE XV

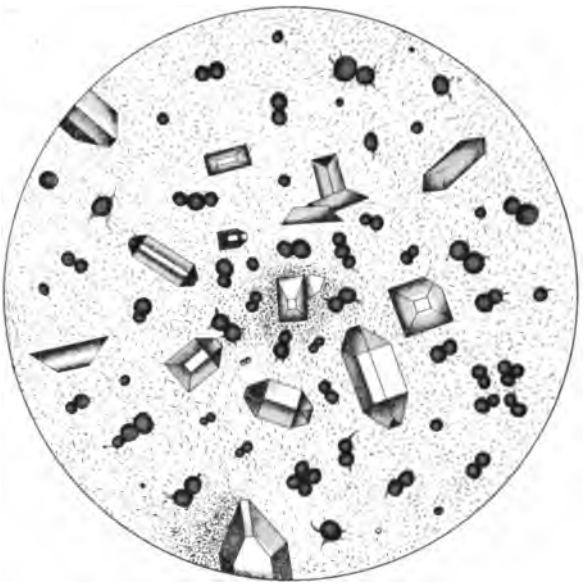

Sediment of alkaline fermentation. Brown crystals, ammonium urate; large prismatic crystals, ammoniomagnesian (triple) phosphate. × 450. (After *Hoffman and Ultzmann.*)



Ammonium urate, showing spherules and thorn-apple-shaped crystals. × 450. (After *Peyer.*)

trabeculæ (ridges), and appear grayish white through the mucous membrane. (See Fig. 448.) Dilation without hypertrophy is observed in paralysis of the detrusor vesicæ.

In contrast to general dilation stands partial dilation, namely, *diverticulum vesicæ urinariæ*. This occurs most frequently as an accompaniment of general dilation and is always situated between the trabeculæ of the wall; it consists either in distention of all constituents of the wall

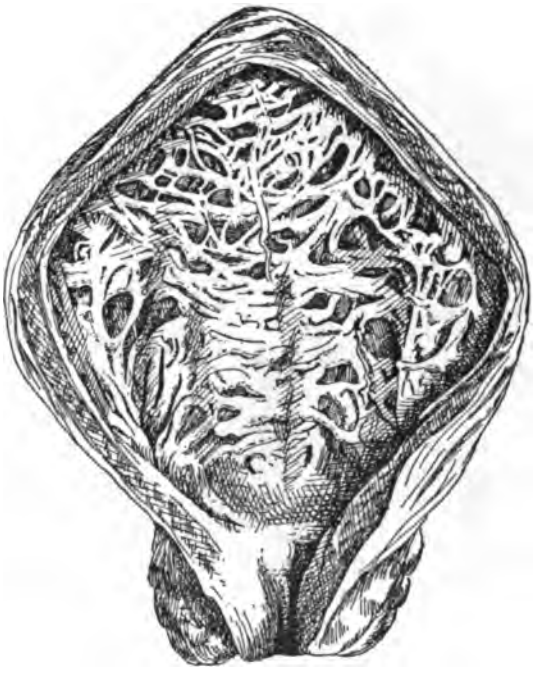

Fig. 448.—Hypertrophia trabecularis vesicæ from prostatic hypertrophy. ⅔ natural size. (After *Langerhans.*)

or only in protrusion of the external (peritoneal) and inner (mucous) layer. These diverticulæ are frequently of hazelnut to walnut size, but under certain circumstances may be considerably larger; they favor calculous formation.

Tuberculosis of the bladder (see p. 474) is almost always secondary to tuberculosis of the kidney.

The experiments of Bauereisen[1] with intravenous injections of emulsions of highly virulent bovine tubercle bacilli into 35 guinea-pigs apparently incontestably confirm Baumgarten's descendance theory of urotuberculosis. The recent investi-

[1] Zeitschr. f. gynäk. Urol., 1910, Bd. 2, H. 3.

gations of Wildholz and Sawamura, as Bauereisen shows, furnished no contrary evidence. It may, therefore, be stated that in an uninterrupted urine stream there is no intraureteral ascending renal tuberculosis. On the other hand, in marked tuberculosis of the bladder, ascending tuberculous infection of one or both ureters may occur by way of the lymphatics, which may finally reach the kidneys. When the flow of urine is unobstructed, even rupture of tuberculous tissue into the lumen of the ureter is not followed by intraureteral ascent of the tuberculous virus; tuberculous infection of the remaining portion of the ureter and of the

Fig. 449.—Cavernous caseous renal tuberculosis with infection of the pelvis and ureter. (After *Burkhardt and Polano.*)

renal pelvis through the stagnated urine stream does not occur until the lumen of the ureter is obliterated by infiltrations. Also with other micro-organisms which, in contradistinction to the tubercle bacillus, possess independent motility and the ability to increase in the secretion, it appears to be the rule that ascending intraureteral infection of the renal pelvis does not occur when the flow of urine is unimpeded. In a later communication[1] Bauereisen reports a second series of experiments upon 21 guinea-pigs, the bladders of which he infected with definite amounts of tubercle bacilli of the human type by means of a blunt catheter. One

[1] *Ibidem,* 1911, Bd. 2, H. 5.

animal killed after three hundred and fourteen days showed only a few caseous foci in the region of the external urethral opening and a few tuberculous glands in the abdominal cavity. One animal lived still longer with unquestionable tuberculosis of the bladder; in 3 animals the process had involved the intramural portion of the ureter. In contrast to several male animals, in none of the 9 female animals could extension of the tuberculosis of the urinary organs to the genital organs be demonstrated. In 11 of 15 cases vesic tuberculosis had existed for a long time, and in none of these were bacilli demonstrable in the renal pelvis, to say nothing of tuberculous tissue alterations. Why tuberculosis of the walls of the ureter and of the vagina advances so slowly, both toward the mucosa (the adventitia and the external muscularis are first infected) and toward the kidney (cases of over three

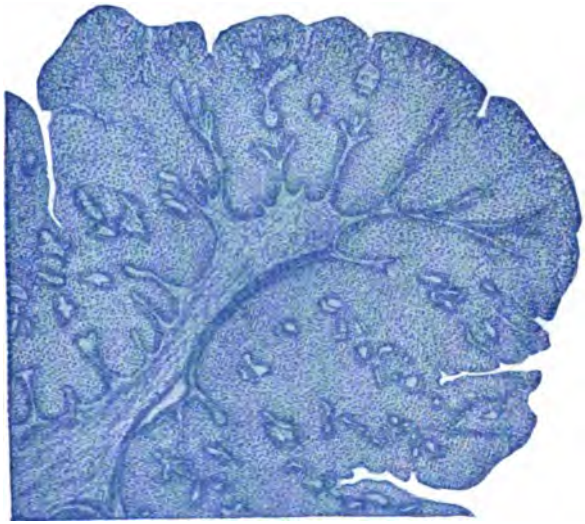

Fig. 450.—Papillary epithelioma of the urinary bladder. Section through a villus. × 35. (After *Ziegler.*)

hundred days), is explained by Bauereisen by the fact that progress occurs against the lymph-stream. The experiments in both series show that the intact vesic epithelium cannot be infected with tubercle bacilli; infection does not occur until large epithelial defects have originated.

The practic significance of Bauereisen's experiments is that the ureters may be catheterized without fear, provided asepsis is observed and no lesions of the ureteral mucosa are produced; in the latter case infection of the ureteral wall may occur, which might extend by the lymphatics to the kidney (see below).

W. Krause and later Bauereisen[1] have shown that the mucosa and submucosa of the human ureter contain a very well developed reticulum of lymphatic vessels, between which and the epithelium and muscularis propria lies a blood capillary reticulum. The efferent lymph-vessels run in diagonal direction through the muscularis to the adventitia and may from there be traced to the lymph-glands.

[1] *Ibidem,* 1911, Bd. 2, H. 5.

The direction of the lymph-current is, therefore, from the mucosa toward the adventitia. The lymph-vessels of the lower third of the ureter communicate with those of the bladder, and those of the upper third with those of the kidney. The kidney and bladder, therefore, stand in much closer relation to each other than has heretofore been assumed. Bauereisen believes he is justified in stating that the kidney is reached by pathogenic germs more easily from the bladder through the lymphatic channels than intraureterally. The anatomic features of vesico-ureteral tuberculosis are thus explained. Starting from the numerous lymph-vessels of the muscularis of the bladder, progress in the ureter occurs in a direction from without inward, but so slowly against the lymph-current that the kidney is reached sooner than the mucosa of the ureter. The migration of the tubercle bacilli is much easier by the route ordinarily taken: from the kidney downward to

Fig. 451.—Papillary fibroma of the bladder. ⅔ natural size. (After *Langerhans.*)

the bladder. Here it migrates by the lymph-current. The fact that the lymphatic capillary reticulum lies directly beneath the basal layer of epithelium of the mucosa renders necessary the greatest aseptic precautions in ureteral catheterization, and even in cystoscopy. Perhaps many postoperative inflammations of the bladder and renal pelvis are referable to lymphogenous infection from parametric wounds, *e.g.*, in cases in which catheterization had never been performed.

In 11 of 17 experiments upon rabbits, Engelhorn[1] observed spontaneous ascent, by way of the mucosa, of carmine deposited in the vagina (in the form of a ball of cocoa-butter mixed with carmine). If the animals were killed some time later the carmine could not be found in the lumen of the uterus, but in the musculature and subperitoneal tissue-spaces. Migration, therefore, occurred against the normal direction of flow of secretion. According to Engelhorn, such migration may occur also with the nonmotile tubercle bacilli, particularly as these, as he has shown, are not killed by the acid secretion of the vagina.

[1] Arch. f. Gynäk., 1911, Bd. 92, H. 3.

The predominating **tumors** of the bladder are the metastatic, especially in the female. Carcinomata of the cervix uteri very frequently extend to the bladder wall by continuity and finally may lead to vesico-vaginal fistula. Much rarer the ureters are involved in a similar manner. Tumors may extend also from the rectum, the ovaries, the retroperitoneal glands, and the *corpus uteri* to the urinary tract. (See also Prostate, p. 873.)

Primary tumors, chiefly **carcinomata,** are found principally in the bladder, rarely in the upper urinary tract. These occur either as a flat, simple swelling of circumscribed area or as a diffuse carcinomatous formation involving the whole urinary bladder, with considerable thickening of the whole wall, or in the form of villous tumor. In the latter

Fig. 452.—Epithelial cells from a portion of a papilloma of the bladder voided with urine. *a*, cells from the inner; *b*, from the middle; *c*, from the deepest layers. × 250. (After *Ziegler.*)

case the formation of the villi is the product of local irritation over the carcinomatous degenerated bladder wall. In addition to these carcinomatous villous tumors, simple villous growths without carcinomatous development in the wall also occur in the bladder: *fibroma papillare vesicæ urinariæ.* The illustration (Fig. 451) is an example of a villous tumor of the bladder without carcinomatous development. In no case has the villous formation itself a carcinomatous structure, but always that of a *fibroma papillare.* The villi are very richly vascular, and, therefore, are often the source of hemorrhage. They may produce very marked disturbance by mechanic obstruction to urination, and cause decomposition of the urine with its consequences. When a purulent cystitis complicates these neoplasms, numerous long and dendritic villi are often found in the purulent urine. If the process is very violent, sloughing of the greater part of the villi and even exfoliation of the whole tumor may

occur. Similar villous formations originate from the renal pelvis, the calices, and the ureters; they are, however, quite rare. Sometimes the urinary passages upon one side are involved throughout down to the bladder by these fibromatous formations.

The *Schistosomum hæmatobium* is found in the bladder, rarer in the ureters and in the renal pelvis, in conjunction with tumor-like swelling or villous hyperplasia of the mucous membrane. This may give rise to repeated and exhausting hemorrhages. Ova and embryos can very easily be found in the blood-coagula voided with the urine. This affection is observed chiefly in the tropics. Sometimes the parasites become calcified in the bladder wall. (See p. 375.)

MALE AND FEMALE SEXUAL ORGANS.

COMMON ORIGIN AND DIFFERENTIATION.

DIFFERENTIATION of the male and female sexual organs, which have a common origin, begins at the end of the second month of fetal life. About this time the genital glands (the later testes or ovaries) lie alongside the lumbar vertebræ, at the anterior and median side of the primitive kidneys (of the later paradidymis or parovarium[1]). From the efferent duct, at the lower end of the primitive kidneys, the so-called inguinal ligament runs straight downward to the inguinal region. In the male, this becomes, as soon as the testes blend with the efferent duct of the primitive kidney (Wolffian duct, the later *vas deferens*), the *gubernaculum hunteri* (testis); in the female, the round ligament of the uterus. At the point where the *gubernaculum hunteri* reaches the inguinal region it blends with the *processus vaginalis peritonei*—an at first solid protrusion of the peritoneum, which originates independently at the beginning of the third fetal month and before descent of the testicles, extends downward as a hollow duct (inguinal canal) through the abdominal wall into the scrotum.

The testes, inclosed by peritoneum, begin to descend in the third month, reach the inguinal canal in the seventh month, and appear in the scrotum at the time of birth. At the same time the ovaries also begin to descend toward the true pelvis, their peritoneal covering gradually becoming the *ligamentum uteri latum.*

Synchronously with the sexual glands, the ducts of Müller, which approach in the middle line, coalesce and open in the urinary canal between the ostia of the Wolffian ducts, develop on the anterior surface of the primitive kidneys. The urinary canal divides into an upper portion, the urethra, and a lower portion, the *sinus urogenitalis* (the later vestibulum in the female or urethra in the male). In the male, Müller's ducts disappear all but a very small remnant—the *vesicula prostatica*—while in the female they become the Fallopian tubes, uterus, and vagina. The coalescence of the ducts to form the uterus is still incomplete at the third month; hence, the uterus is always bicornate at about this time.

[1] The so-called sexual portion of the primitive kidneys subsequently forms an integral constituent of the male genital apparatus—the head of the epididymis—while the remaining portion of the epididymis and the seminal ducts develop from the Wolffian duct.

MALE SEXUAL ORGANS.

Testicles.

In the newborn the *processus vaginalis peritonei* is patent, but closes soon after birth. Then the testes lie in the scrotal sac, inclosed in the *tunica vaginalis propria* (whose visceral layer, or albuginea, corresponds to the primitive peritoneal covering of the testis, and the parietal layer to the *processus vaginalis peritonei*) and the *tunica vaginalis communis*, which is derived from the superficial abdominal fascia.

The *tunica vaginalis propria* behaves in pathologic conditions quite similar to the peritoneum from which it is derived; therefore, two great groups of changes are distinguished, namely, the exudative and those which take place in the substance itself. The latter occur most frequently in connection with exudative processes, rarer without these.

The simplest and most common form of the exudative processes is **hydrocele,**[1] dropsy (*hernia aquosa*) of the **scrotum.** In this condition a clear, very richly albuminous fluid: *hydrops lymphaticus*, which coagulates only on contact with the air, collects between the visceral (albuginea) and the parietal layer of the *tunica vaginalis propria*. The cause of this exudation is an irritative state of the *tunica propria*, which occasionally, especially on long duration of the hydrocele, results in inflammation: **periorchitis.** An acute periorchitis occurs in injuries and occasionally in gonorrhea. Pure watery collections without irritative and inflammatory phenomena occur only in congenital hydrocele, ascitic fluid entering the *tunica vaginalis propria* from the abdominal cavity through the nonobliterated *processus vaginalis peritonei*. This form of hydrocele, therefore, is always due to arrest of development, *i.e.*, to patency of the inguinal canal.

The more fluid accumulates in the *tunica vaginalis propria*, the more the parietal layer is distended and the testis compressed. Consequently, the testis becomes more and more atrophied, so that sometimes only shriveled remnants, which are difficult to recognize, are found upon the inner surface of the large hydrocele sac. Fat-globules and fat-granule cells, from which cholesterin plates very soon separate, are usually present as a result of fatty metamorphosis of epithelia and other cells which have entered the hydrocele fluid. Sometimes these cholesterin crystals are so numerous that they can be recognized with the naked eye. (See Fig. 407.)

The larger a hydrocele becomes, the more it is exposed to trauma; as on long duration the *tunica vaginalis propria* always becomes highly

[1] *Hudor:* water; *kele:* rupture, hernia.

vascularized, hemorrhages readily occur. When these are slight, brown pigment develops, which at first stains only the inner surface of the serous membrane. If, however, stronger hemorrhages occur, the blood mixes with the fluid and imparts to it a yellowish, brownish, or even a chocolate color. In this manner a **hematocele** develops from a hydrocele.

As soon as a hydrocele assumes a more inflammatory character, hyperplastic proliferations always occur in the skin and membranous sheaths, most frequently in the albuginea. From this result either more uniform, diffuse, sclerotic thickenings or semicartilaginous nodules, nodes, and plaques, which, after absorption of lime-salts, occasionally produce the so-called bones of the *tunica vaginalis,* or warts with irregular, lobulated surface, or pedunculated, sometimes dendritic polypi. The latter, by induration of the villi and subsequent atrophy of the pedicle, lead to the formation of the free bodies, from pinhead to cherry-seed size, of the *tunica vaginalis: corpora libera sacci vaginalis testis.* As a rule, the center of the large *corpora libera* is calcified, while the external layers consist of semicartilaginous masses.

The inflammatory phenomena are sometimes accompanied by partial or total adhesions of both layers of the *tunica propria,* so that the ordinary spheric form may be decidedly influenced and altered. Adhesions, however, can occur only when the surface possesses vessels. The semicartilaginous, very poorly vascular parts are incapable of forming adhesions; therefore, when iodine or carbolic acid is injected in such cases with the view of obtaining obliteration by inflammation, as formerly was much in vogue, softening and suppuration, and even gangrene, instead of adhesive inflammation, sometimes develop.

By **cystic hydrocele** is understood a cyst in the course of the spermatic cord (*hydrocele funiculi*). This develops from the *processus vaginalis* as a result of incomplete obliteration, some portion remaining open, the upper and lower portions, however, being adherent. This cyst is strongly simulated in its external appearance by *hydrocele herniosa,* which originates from an old inguinal, sometimes from a crural, hernial sac, partial adhesion occurring, most frequently at the hernial opening. These sacs, when they fill in a manner similar to the *saccus vaginalis testis,* lie alongside of the old *processus vaginalis* in the neighborhood of the external inguinal or crural ring, and, in contradistinction to ordinary hydrocele, are inclosed in a layer of fat.

In its position and form, **spermatocele** presents much similarity to *hydrocele cystica.* It is located almost exclusively at the upper pole of the testis—at the point of transition to the epididymis—as an especial sac external to the albuginea, and develops from cystic dilated canals—

MALE SEXUAL ORGANS.

Testicles.

In the newborn the *processus vaginalis peritonei* is patent, but closes soon after birth. Then the testes lie in the scrotal sac, inclosed in the *tunica vaginalis propria* (whose visceral layer, or albuginea, corresponds to the primitive peritoneal covering of the testis, and the parietal layer to the *processus vaginalis peritonei*) and the *tunica vaginalis communis*, which is derived from the superficial abdominal fascia.

The *tunica vaginalis propria* behaves in pathologic conditions quite similar to the peritoneum from which it is derived; therefore, two great groups of changes are distinguished, namely, the exudative and those which take place in the substance itself. The latter occur most frequently in connection with exudative processes, rarer without these.

The simplest and most common form of the exudative processes is **hydrocele,**[1] dropsy (*hernia aquosa*) of the **scrotum.** In this condition a clear, very richly albuminous fluid: *hydrops lymphaticus*, which coagulates only on contact with the air, collects between the visceral (albuginea) and the parietal layer of the *tunica vaginalis propria*. The cause of this exudation is an irritative state of the *tunica propria*, which occasionally, especially on long duration of the hydrocele, results in inflammation: **periorchitis.** An acute periorchitis occurs in injuries and occasionally in gonorrhea. Pure watery collections without irritative and inflammatory phenomena occur only in congenital hydrocele, ascitic fluid entering the *tunica vaginalis propria* from the abdominal cavity through the nonobliterated *processus vaginalis peritonei*. This form of hydrocele, therefore, is always due to arrest of development, *i.e.*, to patency of the inguinal canal.

The more fluid accumulates in the *tunica vaginalis propria*, the more the parietal layer is distended and the testis compressed. Consequently, the testis becomes more and more atrophied, so that sometimes only shriveled remnants, which are difficult to recognize, are found upon the inner surface of the large hydrocele sac. Fat-globules and fat-granule cells, from which cholesterin plates very soon separate, are usually present as a result of fatty metamorphosis of epithelia and other cells which have entered the hydrocele fluid. Sometimes these cholesterin crystals are so numerous that they can be recognized with the naked eye. (See Fig. 407.)

The larger a hydrocele becomes, the more it is exposed to trauma; as on long duration the *tunica vaginalis propria* always becomes highly

[1] *Hudor:* water; *kele:* rupture, hernia.

vascularized, hemorrhages readily occur. When these are slight, brown pigment develops, which at first stains only the inner surface of the serous membrane. If, however, stronger hemorrhages occur, the blood mixes with the fluid and imparts to it a yellowish, brownish, or even a chocolate color. In this manner a **hematocele** develops from a hydrocele.

As soon as a hydrocele assumes a more inflammatory character, hyperplastic proliferations always occur in the skin and membranous sheaths, most frequently in the albuginea. From this result either more uniform, diffuse, sclerotic thickenings or semicartilaginous nodules, nodes, and plaques, which, after absorption of lime-salts, occasionally produce the so-called bones of the *tunica vaginalis,* or warts with irregular, lobulated surface, or pedunculated, sometimes dendritic polypi. The latter, by induration of the villi and subsequent atrophy of the pedicle, lead to the formation of the free bodies, from pinhead to cherry-seed size, of the *tunica vaginalis: corpora libera sacci vaginalis testis.* As a rule, the center of the large *corpora libera* is calcified, while the external layers consist of semicartilaginous masses.

The inflammatory phenomena are sometimes accompanied by partial or total adhesions of both layers of the *tunica propria,* so that the ordinary spheric form may be decidedly influenced and altered. Adhesions, however, can occur only when the surface possesses vessels. The semicartilaginous, very poorly vascular parts are incapable of forming adhesions; therefore, when iodine or carbolic acid is injected in such cases with the view of obtaining obliteration by inflammation, as formerly was much in vogue, softening and suppuration, and even gangrene, instead of adhesive inflammation, sometimes develop.

By **cystic hydrocele** is understood a cyst in the course of the spermatic cord (*hydrocele funiculi*). This develops from the *processus vaginalis* as a result of incomplete obliteration, some portion remaining open, the upper and lower portions, however, being adherent. This cyst is strongly simulated in its external appearance by *hydrocele herniosa,* which originates from an old inguinal, sometimes from a crural, hernial sac, partial adhesion occurring, most frequently at the hernial opening. These sacs, when they fill in a manner similar to the *saccus vaginalis testis,* lie alongside of the old *processus vaginalis* in the neighborhood of the external inguinal or crural ring, and, in contradistinction to ordinary hydrocele, are inclosed in a layer of fat.

In its position and form, **spermatocele** presents much similarity to *hydrocele cystica.* It is located almost exclusively at the upper pole of the testis—at the point of transition to the epididymis—as an especial sac external to the albuginea, and develops from cystic dilated canals—

remains of the Wolffian ducts—which, on their part, form no spermatozoa, but communicate with the seminal ducts, so that semen can enter from there. The contents of spermatocele are opaque, milk-white, and contain well-preserved or partly disintegrated spermatozoa. Spermatoceles may attain approximately the size of the testicle.

Finally, of the hernias or celes occurring in this region, **varicocele** is to be mentioned. This consists in dilation and varicosity of the numerous veins of the spermatic cord; generally, this varix does not involve the testes.

The acute inflammations of the testes and epididymis are partly traumatic in origin, partly the result of extension, partly metastatic processes. The acute infectious diseases (see pp. 496, 575): gonorrhea, syphilis, mumps, variola, typhoid, etc., are the principal causes of acute inflammation of the testes or epididymis. Gonorrheal inflammations of the urethra, purulent and diphtheritic inflammation of the urinary bladder, tuberculosis, etc., may advance by continuity to the *vas deferens* and beyond to the epididymis and testes. That affections of the mucous membrane (especially gonorrhea) frequently extend only to the epididymis, leaving the testes intact, is apparently due to the fact that the testes are glandular organs, and the epididymis in its structure is closely related to the mucous membrane, and, therefore, is more disposed to affections of the mucous membranes. The testes are affected more frequently by metastasis (lepra, typhoid, variola, mumps, etc.), infectious germs entering with the blood (perhaps also with the lymph). The majority of acute inflammations also lead to acute exudative periorchitis.

Intense swelling, which in most cases disappears after a time, seldom resulting in abscess formation, is characteristic of acute inflammation of the testis. Sometimes, especially in malignant endocarditis, a number of abscesses develop. These always originate in the interstitial tissue, and, if they are not opened, occasionally rupture spontaneously. Abscesses opened artificially or spontaneously often manifest no tendency to heal; then there is a luxuriant development of granulation tissue, which grows out through the opening in fungous form and produces the so-called *fungus benignus* (in contradistinction to malignant tumors). (For tuberculosis of testis see p. 475.)

Besides these abscesses, connective-tissue thickenings with induration develop in purulent orchitis; this is especially the case when the pus is retained. In the neighborhood of the abscess indurations occur which may finally develop into a kind of capsule. The pus then undergoes caseous transformation by inspissation, so that confusion with gummatous and tuberculous processes may readily arise.

Chronic interstitial inflammations which involve the whole testicle, or, starting from the *rete testis,* lead to gradual obliteration of the parenchyma, always arouse the suspicion of syphilis. Gonorrheal epididymitis sometimes—in the opinion of some investigators, very often—causes fibrous nodules in the epididymis.

Compensatory hypertrophy of one testicle has been observed in defective development of the other. Atrophy invariably occurs in cryptorchidism (see p. 200); the testicle is atrophied also when it does not enter the scrotal sac until puberty. Under Hydrocele it was stated that the testicle may be almost completely obliterated by pressure. Otherwise, atrophic processes are observed principally in chronic inflammatory processes involving the testicle itself, and also in advanced age.

Vas Deferens and Seminal Vesicles.

The changes of the seminal vesicles and seminal ducts occur primarily only in connection with trauma. They are usually secondary, *i.e.,* the result of extension of processes closely connected with those already described, to which the reader is referred. Aside from tuberculosis,[1] exudative catarrhal and purulent inflammations: **spermatocystitis (seminal vesiculitis),** catarrhal and purulent, resulting from extension are more frequently observed. On long duration of a purulent catarrh (gonorrhea) a gradual fibrous thickening of the wall occurs: fibrous spermatocystitis, which results in a more or less decided narrowing of the lumen and constriction of small portions of the seminal vesicles: *spermatocystitis obliterans.* As a sequela of this, dilation and cystic formation: *dilatatio et cystis funiculi spermatici,* may occur as a result of retention of secretion. The same change occurs also after abscesses of the prostate, prostatic hypertrophy, strictures, etc. Stones: *calculi spermatici,* which may attain the size of a cherry seed, are sometimes found in the seminal vesicles.

Atrophy of the seminal vesicles occurs in advanced age and also after defect of the testis, or when the excretory duct is completely occluded.

Primary **tumors,** both carcinoma and sarcoma, are extremely rare. Secondary involvement by tumors of adjacent structures (prostate, rectum, bladder) are more frequent.

Prostate.

The prostate[2] is a compound tubuloalveolar gland situated between the symphysis pubis and the rectum and surrounding the beginning of the urethra

[1] See pp. 474 and 475.

[2] προστατής, πρό = before; ἵστημι = to stand.

(*sinus urogenitalis*), the greater portion lying behind this canal. In form it resembles a horse-chestnut, the base directed toward the bladder, the apex resting upon the resistant urogenital diaphragm. Its longest diameter (transverse) is about 1½ inches, the anteroposterior 1 inch, and the thickness ¾ inch. It weighs about 25 Gm. On the posterior surface it is divided by two shallow furrows into three lobes: two lateral lobes and one middle lobe (*lobus medius, pars intermedia,* Home's lobe, accessory prostate, *lobus pathologicus*[1]), which is inconstant. The organ is inclosed by a dense fibrous capsule—a continuation of the contiguous fascia—beneath which are layers of smooth muscle, intermingled with fibrous tissue and elastic fibers, from which trabeculæ pass inward, converging toward the base of the *colliculus seminalis.* These trabeculæ divide the organ into a number of lobuli, lined with short columnar epithelia with eccentric nuclei which occasionally are arranged in several layers. In elderly persons the epithelial cells frequently are pigmented. The proportion of glands[2] to musculature is so variable that normally muscular and glandular prostates are differentiated. The muscle is poorest and the acini best developed in the central lobe. The glandular ducts unite to form two large and a number of smaller (15 or more) excretory ducts lined near their orifices with transitional epithelia, and open laterally to the colliculus seminalis in the posterior wall of the urethra.

Within many of the alveoli are found concentricly laminated concrements, designated as prostatic bodies or concretions, which sometimes stain blue with iodine (*corpora amylacea*). These bodies are most numerous in old men, but they occur also in young men and boys. (See p. 370.)

The prostate contains also the *sinus prostaticus* (*vesicula prostatica, sinus pocularis, uterus masculinus*), a remnant of Müller's duct in the form of a blind sac, which extends backward for 1 to 1.5 cm. into the prostate and opens at the *colliculus seminalis* between the ejaculatory ducts. It is lined with a double layer of stratified epithelium, and at the urethral end contains short alveolar glands. It may occasionally be cysticly dilated.

Cowper's glands are about the size of a pea and lie behind the *bulbus urethræ,* on the posterior wall of the membranous portion of the urethra. They are enveloped in the fibers of the deep transverse perineal muscle. Their excretory ducts run forward in the wall of the urethra, into which it opens.

The glands of the prostate elaborate a clear, glassy secretion (*succus prostaticus*), which is acid in reaction.

The inflammatory processes of the prostate **(prostatitis)** are either the result of extension from adjacent structures (from the urethra, seminal vesicles, bladder, or rectum), or metastatic in septic affections, thrombophlebitis of the paraprostatic veins), or traumatic. The process may be acute or chronic. Acute prostatitis may subside, become chronic, or result in suppuration. Gonorrhea is the most frequent cause of prostatitis; stricture also plays an important rôle in the etiology. Purulent or suppurative prostatitis leads to the formation of abscesses, which may develop insidiously or

[1] So-called because it becomes manifest as a lobe only as the result of enlargement.

[2] According to Walker, the glands constitute five-sixths of the organ.

acutely. These may be arrested and become encapsulated by indurated thickenings, or rupture into the urethra, or result in suppurative paraprostatitis and perforate the rectum, the perineum, or rarely extend to the peritoneum and produce peritonitis. Dislodgment of thrombi of the venous plexus of the prostate may cause general infection. Acute prostatitis sometimes assumes a putrid character. The swelling in prostatitis is often so marked as to cause compression of the urethra, resulting in dysuria or anuria, and not rarely interferes with defecation.

Chronic prostatitis is accompanied by **prostatorrhea**, in which the secretion may be discharged in drops or abundantly during defecation.

Fig. 453.—Spermatorrhea and prostatorrhea. × 350. *s*, spermatozoa; *k*, Böttcher's crystals; *p*, prostatic corpuscles (latter after Bizzozero). (From *Lenhartz-Brooks.*)

It may thus give rise to confusion with chronic gonorrhea or spermatorrhea. A chronic prostatorrhea, which from time to time, especially after frequent coitus, may lead to a thick fluid, purulent discharge, not infrequently remains after subsidence of gonorrhea. This condition rarely exists with spermatorrhea. The discharge contains cylindric epithelia, leucocytes, fat-droplets, and frequently lamellated "amyloid elements," and very numerous Böttcher crystal octahedra (see Fig. 453), which, according to Furbringer, occur only in prostatic fluid and impart to the semen its characteristic odor.

By **hypertrophy** of the **prostate** is understood every enlargement of the organ due to increase of the normal constituents. It is a very frequent affection, sometimes occurring as early as the fortieth year,

occasionally earlier. The gland may be enlarged *in toto*, attaining the dimensions of the fist, or only certain parts are involved, especially the middle lobe (Home's lobe: *lobus pathologicus*. According to Jores, "hypertrophy of the middle lobe" does not originate in the middle lobe, but from proliferation of accessory glands situated beneath the mucosa of the bladder and prostatic portion of the urethra. Kaufmann). In pronounced cases either the connective tissue or muscular proliferation predominates (fibrous or fibromuscular hypertrophy, respectively). In the fibromuscular form either the muscular or fibrous tissue or the epi-

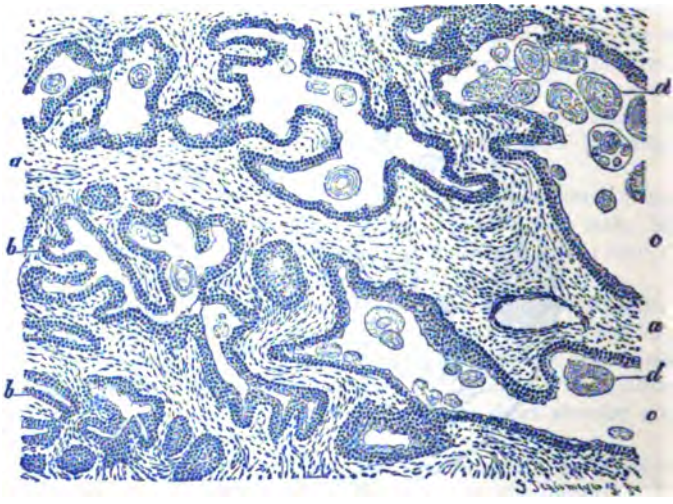

Fig. 454.—Section from a hypertrophied prostate with concretions. *a*, stroma; *b*, glands; *c*, dilated glands; *d*, concretions. × 45. (After *Ziegler.*)

thelial elements (so-called adenomatous or glandular hypertrophy) are chiefly involved. Prostatic hypertrophy may in a measure be caused by dilation of the glands, referable to inflammatory interstitial connective-tissue proliferation. Mixed forms: fibromuscular-glandular, in which all parts are involved in the hypertrophy, also occur. Pure myomatous or fibromatous hypertrophy is rare, as are also fibromata, adenomata, and cystadenomata. Kaufmann reports a case of rhabdomyoma of the prostate. (See Fig. 454.)

Sequelæ of prostatic hypertrophy are stricture and distortion of the prostatic urethra, hypertrophy of the bladder, cystitis, hydronephrosis, constipation, and not rarely pyelonephritis (so-called "surgical kidney"). If the middle lobe is enlarged, it may lie as a lid upon the urogenital sinus. The glandular form must be differentiated from the fibromus-

cular form of hyperplasia.[1] In the first instance the glandular ducts proliferate by the formation of new buds, which, on further growth, become branched. This is always associated with increase of the fibromuscular tissue. French authorities believe that when the glandular structures are chiefly involved the process is the beginning of neoplasm formation (adenocarcinoma).

Intense distention of the glandular ducts and flattening of the epithelium are regularly observed in advanced age. The *corpora amylacea* are partly responsible for this. These bodies are not present in the newborn, but they make their appearance in youth and increase in number and size with age, so that in old men they can readily be seen, even with the naked eye, as small, brown puncta. They frequently impart a light-brownish-yellow color to the whole cut surface. The *corpora amylacea* are concentricly lamellated bodies which owe their name to the reaction (blue coloration) they give with iodine. By progressive growth they cause gradual dilation of the glandular ducts and atrophy of the epithelium. Aside from this **atrophy,** however, general or sometimes more circumscribed diminution of the organ is also frequently observed in advanced age, in castrated subjects, and in youthful individuals greatly emaciated from long sickness (marasmus).

Besides *corpora amylacea,* prostatic calculi, which, in part at least, may develop in conjunction with *corpora amylacea,* occur in the glands and excretory ducts of the prostate. These also may cause atrophy of the epithelium and stroma by pressure. Renal calculi may descend from the kidney and lodge in depressions in the prostate, where they not infrequently attain large dimensions.

Varicose dilations and **marantic thrombosis** are not very rarely observed. Phleboliths and thrombophlebitis are less frequent.

Of the **tumors** of the prostate, **carcinomata** are often marked by great hardness. They manifest only a slight tendency to disintegrate. Prostatic carcinoma may be so small as to be overlooked; the presence of cachexia and metastases in the osseous system may then be the first manifestations.[2] The bladder is attacked by continuity, usually diffusely in the form of small nodules situated beneath the bladder mucosa; the seminal vesicles are often involved, rarely the rectum and urethra. Regional and distant involvement of the lymphatic glands also occurs. Of the **sarcomata,** round and spindle-celled, angio-, myxo-, lymphosarcomata occur in the prostate. Sarcomata may develop even in very young children, attain enormous dimensions, and involve adjacent parts

[1] See Myoma, p. 257.

[2] Among 14 cases of carcinoma of the prostate observed by Kaufmann, metastases occurred in the osseous system in 10, 8 presenting an ossifying character.

by pressure and infiltration, but they rarely form local or distant metastases. Birch-Hirschfeld reports a case of adenosarcoma of the prostate. **Secondary tumors** of the prostate (from the rectum and bladder, very rarely from the seminal vesicles) are rare. Metastatic deposits from distantly situated malignant neoplasms rarely, if ever, occur.

Penis.

Of the changes occurring in the penis, those involving the mucous membrane of the urethra, the external skin, and the *corpora cavernosa* are of chief importance.

By far the most frequent affection is acute specific purulent inflammation of the urethra: gonorrhea. (See p. 495.) This is sometimes accompanied by a purulent catarrh of the whole prepuce, especially when, as in congenital or acquired phimosis, owing to too small an opening, the prepuce cannot be retracted, but constantly covers the glans. In the course of this purulent catarrhal balanoposthitis, excoriations and ulcerations are almost always formed, which either heal by cicatrization or occasionally result in adhesion of apposed mucous surfaces. In rarer cases the glans is constricted by the formation of extensive and deep scars, or atrophy of the prepuce occurs. As a result of the latter, just as in adhesion of the prepuce to the glans, phimosis (*phimosis acquisita*) may develop. When the inflamed prepuce is pushed back over the glans, intense hyperemia and edema of the glans and a portion of the prepuce frequently occur, just as occasionally is observed in congenital phimosis when the foreskin is forcibly drawn backward over the glans. When this artificial constriction of the penis (paraphimosis) is sufficient almost entirely or completely to arrest the outflow of blood through the veins, stasis of the blood-current occurs, whereupon abscess or gangrene usually follows.

In affections associated with general dropsy, the skin of the penis and prepuce may early (almost synchronously with the lower extremities) be the seat of edematous swelling, which is sometimes enormous. This swelling, however, does not result in gangrene, because the blood-stream in the veins is not interrupted.

In so-called **soft chancre** (**chancroid**, *ulcus molle*) a small papule or vesicle with reddened areola is first observed, usually upon the prepuce. By loss of the protecting epithelial covering a small, flat, chiefly circumscribed ulcer with undermined edges develops, which elaborates a grayish, purulent secretion, and manifests a great tendency to spread (so-called eroding character); it then frequently infects those portions of

the skin which come in contact with the moist ulcer surface. The process may assume a phagedenic, gangrenous, or serpiginous character. Soft chancre is unquestionably infectious in nature. A quite thick, nonmotile, Gram-negative bacillus (*Bacillus ulceris cancrosi:* Unna-Ducrey), which often forms long chains and is found in the secretion (free and within the pus-cells) and tissues of the ulcer, is regarded as the specific causative agent. It stains readily with methylene-blue, with which it sometimes shows polar staining. The organism can be grown upon blood-agar and produces chancroid when inoculated into man and monkeys.

In soft chancre, in contradistinction to the primary ulcer of syphilis, a number of ulcers very frequently develop upon the frenulum, prepuce, and glans. On healing they leave flat, soft cicatrices, which, if the ulcers have not been too extensive, almost completely disappear after a time. While syphilitic inflammation of the adjacent lymph-glands seldom results in suppuration, soft chancre quite frequently is accompanied by purulent inflammation of the lymph-glands: **buboes** (*lymphadenitis apostematosa*). In 4 cases of soft chancre of the fossa navicularis urethræ reported by Tschumakow[1] chancroids were present upon the frenulum, whence they had advanced to the urethra by continuity or contiguity, perforating the frenulum (bleeding from the arteria frenuli) or the fossa navicularia (fistula formation). Conveyance of the infectious material is possible also by way of the deep lymphatics. Complications in location of the ulcer upon the frenulum are hemorrhages from the arteria frenuli (sometimes very obstinate), perforation or complete destruction of the frenulum, balanitis, bubo.

In their external appearance the vesicles of **herpes præputialis** have a certain resemblance to the vesicles of soft chancre. They differ from the latter, however, by the fact that from the beginning they occur in larger numbers, and, although they form small excoriations after rupture, they do not assume an eroding character or extend into the depth, but heal quite rapidly without cicatrization.

In **congenital phimosis** friable masses composed of fat, fatty acids, lime, and albuminous material derived from the preputial smegma, etc., by inspissation and desiccation may accumulate in the *sulcus glandis,* especially in filthy individuals. These are to be distinguished from the true preputial stones: *calculi præputialis.* The latter develop as the result of stagnation of urine, and consist of urates and phosphates (calcium phosphate and triple [ammoniomagnesian] phosphate).

In structure the **corpora cavernosa** correspond to vessels, and their changes are connected with affections of the veins. Thromboses and in-

[1] Zeitschr. f. Urol., 1911, Bd. 5, H. 3, p. 217.

flammations of the walls are most frequent. Acute inflammations follow purulent processes of surrounding parts (phagedenic chancre, etc.) and terminate in abscesses. In the neighborhood of these, and on healing, sclerotic connective-tissue cicatrices develop, which may result in a deformity (angular position) of the penis. Partial ossification may occur within the cicatrices.

Forcible flexion of the erected penis (**fracture**), as well as contusions, gunshot wounds, stab wounds, are generally accompanied by considerable hemorrhage.

Luxation of the penis is produced by avulsion of the prepuce from

Fig. 455.—Section of erectile tissue. *a*, trabeculæ of connective tissue, with elastic fibers, and bundles of plain muscular tissue, *c; b*, venous spaces. (After *Cadiat.*)

the glans and stripping of the skin from the whole shaft. Under these conditions the shaft of the penis is displaced into the scrotum or beneath the skin of the thigh.

Tuberculosis of the penis is very rare and usually observed as a result of ritualistic circumcision. There are 16 authentic reported cases of the latter origin in infants. Lehmann reported[1] 10 cases in Russian Poles upon whom a highly tuberculous rabbi, who soon thereafter died of tuberculosis, had performed the act of blood-sucking after circumcision. In adults, tuberculosis of the penis without affection of the remaining portions of the urogenital apparatus has been observed in 8

[1] Deutsch. med. Woch., 1886.

instances.[1] Multiform combinations of tuberculosis of the penis with tuberculous affections of other organs, *e.g.*, the epididymis, kidney, urinary bladder, prostate, etc., have been described. The origin of isolated tuberculosis of the penis is obscure. Hematogenous infection with tubercle bacilli from some occult focus, and also, during coitus, infection with virus from tuberculous ulcers in the female, are possible. All parts of the penis may be involved, and the tubercles may originate either in the surface or in the depth of the tissues. Tuberculous ulcers of the penis have blue, undermined margins and a caseous base. The prognosis is not bad, as the danger of general extension and dissemination of the tubercle bacilli is slight. The form following ritual circumcision in infants, however, is very malignant, all patients dying within a year from generalized tuberculosis. The therapy is excision or amputation.

Among the **tumors** carcinomata are most frequent: epithelioma of the scrotum (especially in chimney-sweeps and paraffin workers) and of the orifice of the urethra; carcinoma of the prostate and of the testes. Besides these, sarcomata and mixed tumors occur in the testes: enchondroma with sarcoma, myxoma, or carcinoma, and also adenocarcinomata. Lipomata sometimes develop from the spermatic cord; myomata, sarcomata, and osteomata sometimes originate from the tunics of the testicle. Carcinoma of the prostate is infrequent, occurs in relatively young individuals, and appears frequently to produce metastases in the bones.

Elephantiasic thickenings of the skin not infrequently develop in the scrotum, and sometimes also in the prepuce. This elephantiasis of the scrotum and prepuce may attain enormous size. In tropic elephantiasis of the scrotum (so-called lymph-scrotum) *Filaria sanguinis* has been demonstrated in the dilated lymph-vessels.

FEMALE SEXUAL ORGANS.

The secretions of the vagina, which anatomicly is more closely related to the external skin than to the mucous membranes, and, therefore, has essentially a cutaneous structure, are chiefly cellular (epidermoidal) in nature: not those of a mucous membrane. Leucorrhea, vaginal catarrh, or *fluor albus,* is connected, on the one hand, with menstruation (*q.v.*), and, on the other, with the lochia; it often becomes stationary, especially after the puerperium, at the *portio vaginalis uteri*: in that portion of the uterus which is covered with squamous epithelium: chronic endocervicitis. The cervix then appears dark

[1] Bruns's Beiträge, Bd. 72; Ref. Zeitschr. f. Aerztliche Fortbildung, 1911, No. 10, p. 301.

red, moist, glistening, and eroded; besides, the squamous epithelium is gradually displaced by the cylindric epithelium of the cervix.

Acute purulent colpitis (vaginitis) is accompanied by intense swelling and redness of the whole mucous membrane, and secretion of a purulent exudate. It is most frequently the result of gonorrheal infection. In the chronic form: *colpitis granularis,* which is caused particularly by foreign bodies and different discharges (in carcinoma of the uterus, vesicovaginal fistulæ, etc.), the mucous membrane is granular and thickened as a result of irregular hyperplasia of the papillæ, partly deprived of its epithelium down to the lowermost layers, and eroded and intensely hyperemic. On long duration of simple catarrhal colpitis the mucous membrane assumes a hard, leathery consistency, in that the surface becomes completely smooth: *colpitis lævis.* In advanced age, sometimes also earlier, especially when erosions or ulcerations had existed, chronic colpitis produces conglutinations and adhesions of apposed surfaces. The lumen is thus considerably narrowed and shortened. Narrowing may occur also as a result of strong retraction of syphilitic cicatrices, particularly at the introitus.

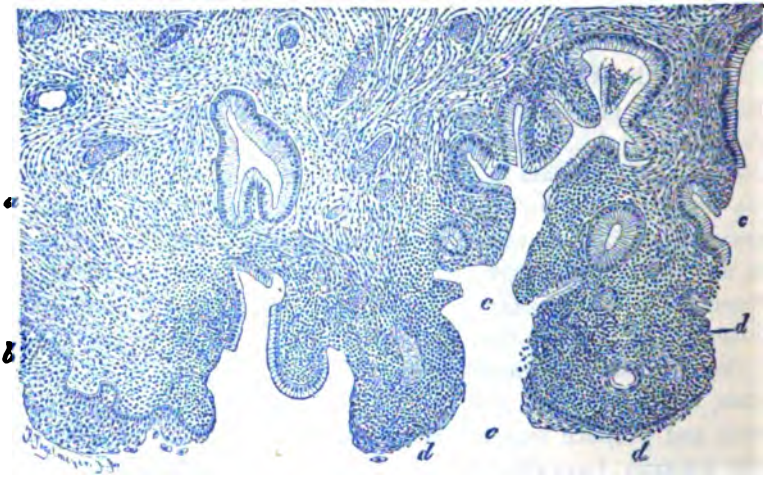

Fig. 456.—Papillary erosion of the portio vaginalis uteri. *a,* connective tissue of the portio vaginalis; *b,* lamellated squamous epithelium; *c,* gaping openings of dilated glands; *d,* dense cellular infiltration of proliferating tissue which is covered only by a single layer of cells. × 45. (After *Ziegler.*)

Inflammatory changes of the vulva are generally associated with those of the vagina. Upon the inner surface of the *labia majora* small, smooth ulcers, which usually heal without cicatrization, develop in catarrhal states resulting from uncleanliness, friction, etc. Large scars

at the *introitus vaginæ* are, as a rule, due to injuries received during parturition; hard, radiate scars are generally referable to syphilis. So-called pointed condylomata: *condylomata acuminata introitus vaginæ* (see p. 547), which may attain very considerable dimensions, develop at the posterior portion of the vaginal opening as a result of intense continued gonorrheal irritation.

Bartholin's glands (*glandulæ vestibulares majores*), which are analogous to the bulbourethral glands in the male, are bean-sized mucous glands opening into the vestibule by pinpoint excretory stomata on each side of the hymen. The chief affection is simple and purulent catarrh (**bartholinitis**), the purulent form occurring most frequently in connection with gonorrhea. The inflammatory process may be confined to the ducts or involve the gland, in the latter instance often resulting in abscess. Cysts may follow inflammatory and cicatricial closure of the ducts. The glands may also be the seat of carcinoma.

In the **cervix uteri** a certain amount of mucus is constantly found, which, compared with the other secretions of the genital canal, is characterized by its unusual viscidity. Sometimes there is intense production of these mucous masses (chronic endocervicitis), which, owing to their tenacious character, especially in elderly individuals, easily remain *in situ*. With this is associated an increasing enlargement and funnel-shaped dilation of the whole cervix, or an increasing constriction develops at the external os, since the chronic catarrh is accompanied by cicatricial retraction of the tissue of the mucous membrane. In this case a barrel-shaped, sometimes spheric dilation of the cervix develops.

In some cases the constriction goes on to complete stenosis, very rarely to complete adhesion (*atresia*). Dilation more frequently follows the puerperium, favoring discharge of the mucus, while constriction occurs particularly at the climacteric and hinders the discharge. The greater the amount of mucus accumulated, the stronger the dilation from pressure of the exudate. The pressure interferes with nutrition and leads to atrophy of the muscular and glandular elements, which is recognizable principally by the gradual thinning and rigidity of the wall.

Retraction of the mucous membrane at the internal os, with constriction and final adhesion, may result in an entirely similar manner from chronic catarrhal endometritis of the body of the uterus. Considerable constriction may be produced also by the so-called Nabothian glands and flexions of the uterus. Accumulation of uterine mucus, which does not possess the viscidity of cervical mucus, but is thin and watery, and dilation of the body of the

uterus with atrophy of the wall: *hydromata,* are present in all these cases. The cervix is not involved in the process.

In the **Fallopian tubes** also chronic catarrh is often associated with retention and dilation. Retention occurs when the abdominal orifice of the tube is closed by adhesive processes. The uterine orifice is sometimes closed in like manner, but not necessarily, because it is so narrow that mucous masses, marked swelling of the mucosa, and valve-like folds alone suffice to obstruct the passage. The exudate consists chiefly of desquamated epithelium, mucus, and a variable number of round cells. Later, the exudate becomes thin and watery, and a state

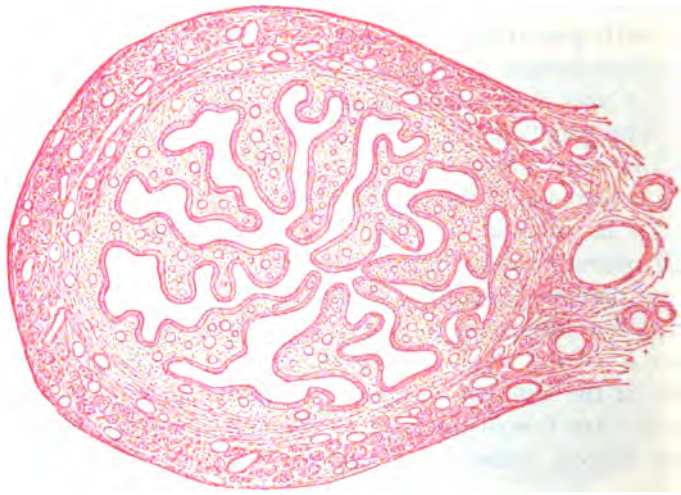

Fig. 457.—Section across the Fallopian tube. (After *Schaefer.*)

which is designated as *hydrops cysticus tubæ,* or hydrosalpinx, develops. By admixture of blood this is transformed into sanguinolent hydrosalpinx. If the hemorrhage predominates, hematosalpinx develops. The blood may be found in the fresh state, or in the stage of transformation into pigment. In the latter case the contents are brownish, sometimes watery, sometimes creamy, and in appearance resemble chocolate. The accumulation of exudate is generally accompanied by displacement of the tube, which is materially influenced by perimetritic adhesions (with uterus, ovary, intestine). Marked distortion, inflammations, and even perforation may be caused by strong dilation.

In the ovary, *hydrops follicularis* or *hydrops folliculorum ovarii* in pregnant females and elderly women, who frequently suffer at the same time from dropsy of the uterus and tubes, corresponds to these catarrhs

with retention. In *hydrops follicularis* usually only a small number of the Graafian follicles are dropsicly degenerated; small cysts develop without marked change in the form and size of the ovary. (See Cystomata, p. 309.)

The **corpora lutea vera** (in pregnancy) **et menstruales** (in menstruation) form on rupture of a Graaffian follicle. In this condition a number of vessels are always opened, which, after discharge of the ripe ovum, pour their blood into the empty follicle. The blood coagulates and in the fresh state forms the *corpus hæmorrhagicum ovarii;* subsequently it undergoes the same changes as does usually a thrombus. The differ-

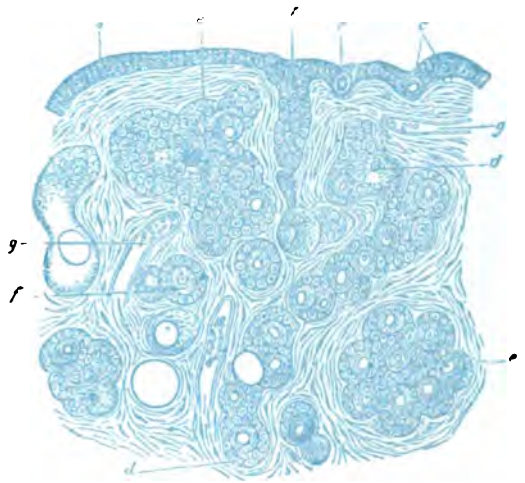

Fig. 458.—Section of the ovary of a newly born child. Highly magnified. *a*, ovarian or germinal epithelium; *b*, formation of an ovarian tube; *c, c*, primordial ova lying in the germ-epithelium; *d, d*, longer tube becoming constricted so as to form nests of cells; *e, e*, larger nests; *f*, distinctly formed follicle with ovum and epithelium; *g, g*, blood-vessels. (After *Waldeyer.*)

ence between *corpus lutea verum* and *menstruale* is solely in the size; the former is about from pea- to hazelnut- size; the latter is smaller. The *corpus luteum verum* is larger, because, at the moment of fecundation, a strong hyperemia of the sexual organs begins, and, therefore, the hemorrhage into the empty follicle is more profuse and of longer duration.

Little is known of parenchymatous inflammation of the ovary (*oöphoritis follicularis*). On the other hand, chronic interstitial oöphoritis is a very frequent process, which sometimes involves the whole ovary, sometimes more the peripheral portion. In the first case the ovary is small, shrunken, very firm, nodular

on the surface, and frequently contains small fibromata within the interior; in the other case the peripheral layer, about 1 mm. thick, is hard, whitish, and fibrous, while the interior appears unaltered. In the puerperium and in purulent processes of the abdominal cavity *oöphoritis erysipelatodes* or *phlegmonosa* sometimes develop; an ovary thus altered is swollen, reddened, strongly succulent, erysipelatous, cloudy, and strongly relaxed (flabby).

A not rare, but infrequently recognized, affection of the ovary is **hematoma.** By this is not to be understood the ordinary Graafian fol-

Fig. 459.—Carcinoma of the ovary. *a*, tubular and papillary; *c*, alveolar carcinomatous tissue; *b*, *e*, *h*, connective-tissue stroma; *d*, anastomosing cell strands; *f*, primary follicles resembling alveoli; *g*, alveoli with wreath-like groups of nuclei. × 100. (After *Ziegler.*)

licles or corpora lutea distended with fluid or coagulated blood, but usually larger cavities, with or without true wall and not always situated near the surface, filled with old brown, oil- or tar- like, partly granular coagulated blood. These formations or the ovary containing them are always adherent to adjacent parts. J. Presscott[1] observed 18 such cases within a year and a half. The majority of the patients were unmarried or childless; the married patients had on the average 1.2 children. The ages ranged from 24 to 53 years. The chief symptom is either occasional or continuous pain in the pelvis. Often dysmenorrhea and myoma

[1] Jour. Obst. and Gyn. of Brit. Emp., Nov., 1910.

also are present. These tumors apparently originate by confluence of Graafian follicles situated too deep in the ovarian tissue to rupture externally and expel the blood contents into the free peritoneal cavity. This would seem to indicate a certain hypofunction of the ovary. The encapsulated blood appears to be readily subject to infection, particularly with the *Staphylococcus albus:* a relatively harmless parasite which leads to the constantly present peritonitic adhesions. On the other hand, if Graafian follicles filled with blood become infected with other bacteria, *e.g.,* the streptococcus or the gonococcus, acute suppuration of the hematoma occurs.

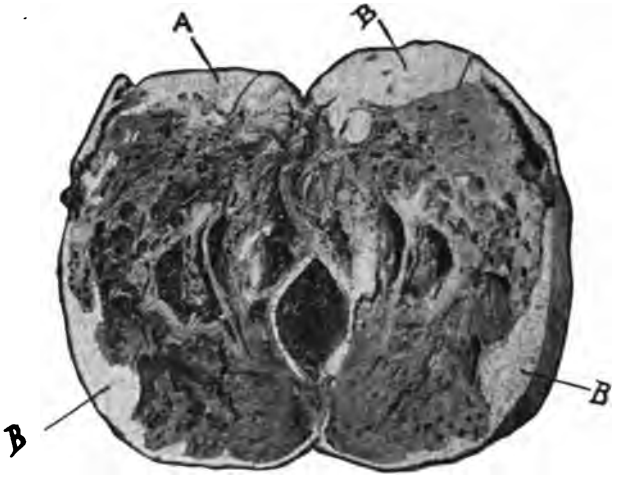

Fig. 460.—Cystocarcinoma ovarii. *A,* area from which section shown in Fig. 461 was taken; *B,* corresponding areas of carcinomatous degeneration.

Aside from the small, insignificant fibromata, the most frequent tumors of the ovary are the cystomata (cystadenomata), which in structure and development are closely related to the carcinomata. Furthermore, the ovary is characterized by the occurrence within them of dermoid cysts. Endotheliomata are frequently recorded; rarer fibrosarcomata and spindle-celled sarcoma; quite rarely adenoma, enchondroma, psammocarcinoma, and pure primary carcinoma; more frequently metastatic carcinomata.

The so-called **Nabothian ovula** are retention cysts of the glands of the mucous membrane of the *cervix uteri,* which generally attain the size of a hemp seed and contain viscid, colloid mucus and cells. They develop in chronic catarrhs and may act as an irritant, and either sustain the catarrh or cause proliferation of the mucous membrane. In the first case, when numerous *ovula nabothi* are present, intense swelling and

active reddening of the cervix with funnel-shaped dilation result. This state has a certain similarity to forms of acne of the external skin, and, therefore, is called also *acne hyperplastica cervicis uteri* (also incorrectly called uterus infarct). (See p. 891.) From the parietal Nabothian ovula develop polypoid mucous cysts of the cervix projecting singly, or in groups more and more above the surface, and finally protruding from the external os as cystic polypi with long pedicles as a result of proliferation of the surrounding (interfollicular) tissue.

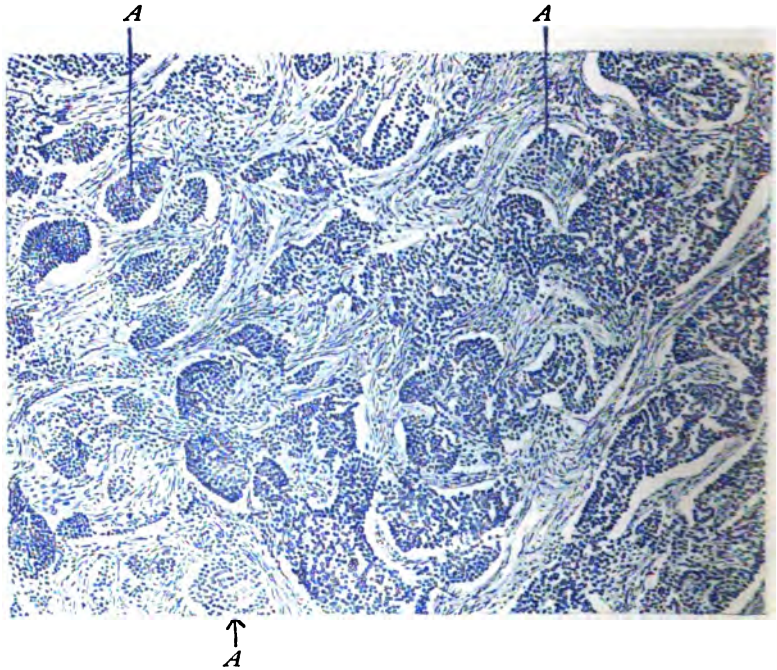

Fig. 461.—Carcinomatous structure of tissue removed from *A* in Fig. 460. *A*, carcinoma cell nest.

In the same manner pedunculated cystic polypi may develop also from the uterine mucous membrane (*endometritis chronica cystica polyposa*), when atresia and cystic dilation of the utricular glands have been produced by adhesion of the mouths of the ducts. On the other hand, cystic degeneration of the glands (*endometritis catarrhalis cystica*) may occur also without polypus formation, when induration and retraction of the whole mucous membrane coexist.

Almost all the polypi have very wide, superficial vessels, and are the source of considerable and frequent hemorrhages; furthermore, like the

ovula nabothi, they favor and sustain the tendency to *fluor albus* and metrorrhagia.

With **catarrhal endometritis** are connected those forms of endometritis which progress essentially in the mucous membrane. Three forms are differentiated: glandular, interstitial, and mixed endometritis. The glandular form consists essentially in hyperplasia of the utricular glands; these become longer and tortuous, and send out lateral prolongations. The mucous membrane is thus thickened; the surface is strongly reddened, and often somewhat uneven and undu-

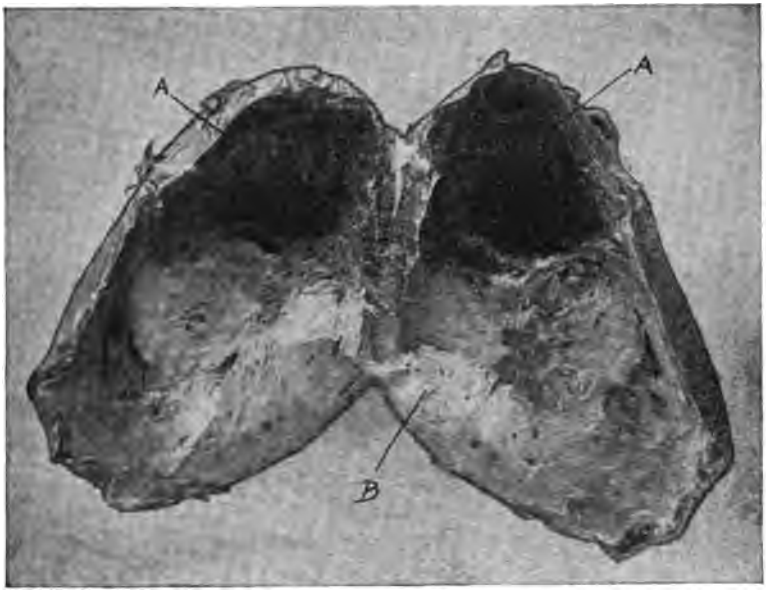

Fig. 462.—Cystic degeneration of fibroid uterus. *A*, cystic degeneration; *B*, fibroid tissue.

lated. The interstitial form of endometritis also is generally at first associated with swelling and hyperemia, so long as the new-formed connective tissue is richly cellular; as soon, however, as formation of new intercellular substance has begun, condensation and retraction, with obliteration of the utricular glands, result. This may progress so far that the mucous membrane is replaced by a hard layer of fibrous connective tissue, which extends directly into the fibromuscular tissue of the uterus. In the mixed forms of endometritis sometimes the glandular, sometimes the interstitial, proliferation preponderates. In some cases the increase of connective tissue is not followed by cicatrization, but by villous formation upon the surface, so that the whole uterine

mucous membrane appears to be covered with delicate excrescences only a few millimeters in length. In this villous endometritis (see Fig. 466) the utricular glands are but slightly or not at all involved.

Acute purulent catarrhal inflammation of the endometrium and mucous membrane of the tubes is caused by noxious influences, acting either from without[1] upon the mucous membrane or from the vascular system, for example, in infectious diseases. The most common cause of purulent catarrhal endometritis is gonorrhea; this purulent affection not infre-

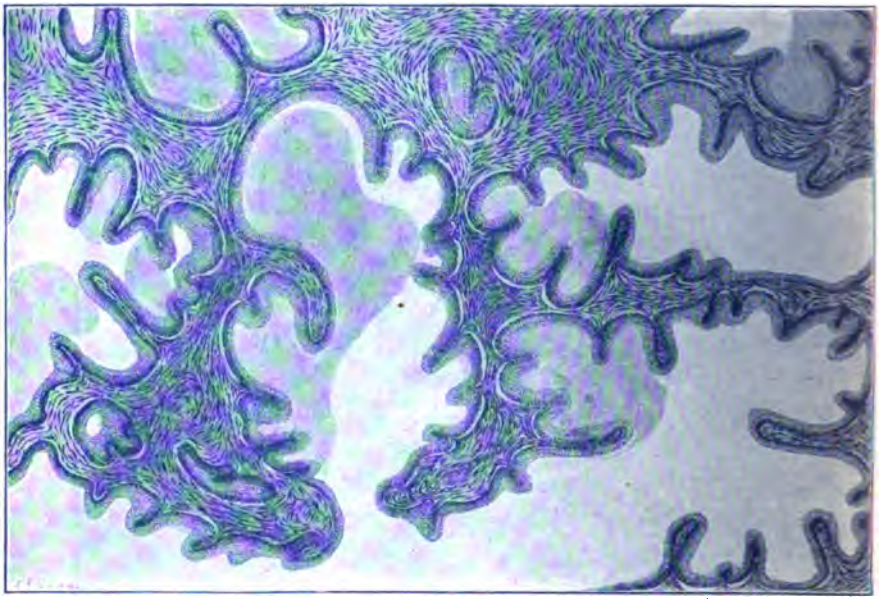

Fig. 463.—Papillary cystadenoma of the ovary.

quently extends to the mucous membrane of the tubes and there produces **purulent salpingitis,** which is always associated with intense swelling of the whole tube, sometimes also with considerable cystic dilation: **pyosalpinx.**

Acute purulent endometritis is often followed by metritis and perimetritis, which results in adhesive processes.

Diphtheritic processes occur in the uterus almost only in the puerperium, and often are the cause of severe puerperal infection; they frequently assume a phlegmonous or gangrenous character (*endometritis diphtherica gangræosa*). Diphtheria of the vagina (*colpitis diphtherica*)

[1] In the endometrium, from the vagina; in the tubes, from the vagina or from the abdominal cavity.

is observed in acute infectious diseases (cholera, small-pox, etc.), in local action of noxious agents (foreign bodies, trauma, ichorous exudates, carcinoma, fistulæ), and in diphtheritic and gangrenous processes of the vulva (noma, carbuncle, phagedenic chancre). Diphtheria of the vulva sometimes is observed coincidently with diphtheria of the pharynx. Gan-

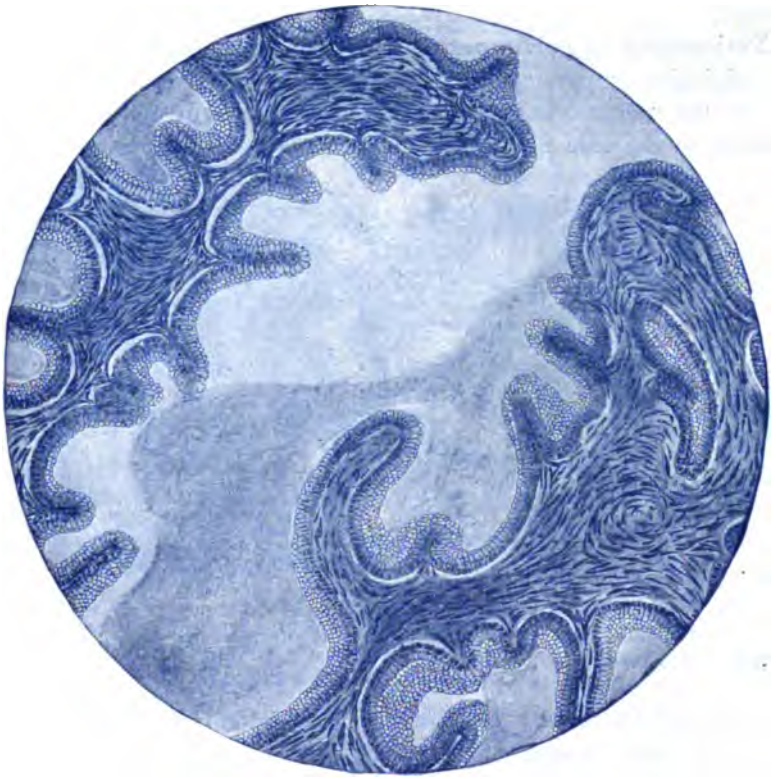

Fig. 464.—Same as Fig. 463. More highly magnified.

grene of the vulva occurs in small, debilitated children who have at the same time noma of the face; in adults it may develop as a result of local infection with anthrax; from furuncles, carbuncles, phlegmons, and in connection with diphtheria, scarlatina, typhoid, cholera, etc.

Deeply extending ulcerative processes, which finally lead to communication of the vagina with the bladder, rectum, or *cul-de-sac* of Douglas, generally develop after contusion during labor or as the result of disintegration of tumors, especially carcinoma of the cervix, seldom from other causes (trauma, foreign bodies retained for a long time, etc.).

Parametritis is always due to an acute purulent inflammation of the endometrium, which most frequently occurs in connection with the puerperium; it sometimes occurs also in carcinoma, gonorrhea, and after gynecologic intervention. Abscesses which pursue a very chronic course and either remain stationary and cause secondary chronic thickening or spread and rupture externally or internally (*cavum peritonei*) are frequent.

Perimetritis or **pelvic peritonitis** (*pelveoperitonitis*) generally follows salpingitis or parametritis, sometimes also metritis, subserous myomata of the uterus, etc.; it almost always results in the formation of adhesions in the true pelvis, seldom in abscess formation, which, after

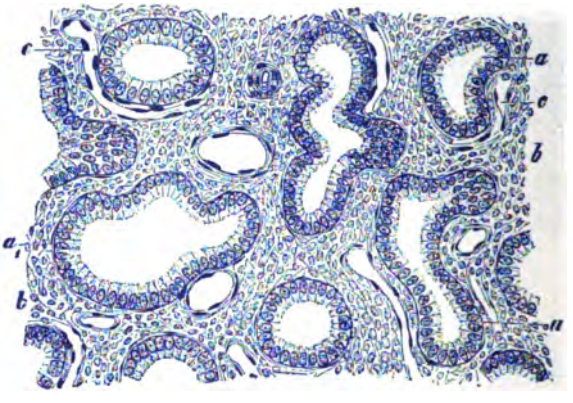

Fig. 465.—Hyperplasia of the uterine mucous membrane. *a*, a_1, transverse section of glands; *b*, connective tissue of the mucous membrane; *c*, blood-vessels. × 150. (After *Ziegler*.)

antecedent adhesion, may rupture into the abdominal cavity, intestine, bladder, or genital canal. Perimetritic processes generally cause backward displacement of the uterus and its appendages and fixation in this position. The normal position of the uterus is about parallel with the sacrum; the cervix and corpus do not run in a perfectly straight line, but in the region of the internal os form with each other a wide angle of a little less than 180 degrees. Laterally, the uterus is fixed principally by the *ligamenta lata* and *rotunda*. The position of the uterus is subject to certain variations according to the filling of the rectum and bladder. Deviations from the normal position occur by approach of the fundus of the uterus to the sacrum or recession from it. In the first instance retroflexion and retroversion, in the second anteflexion and anteversion, occur. In anteversion and retroversion the long axis of the uterus is changed; the relation of the cervix to the corpus is unchanged; hence, in

anteversion the cervix is displaced farther backward than normal, *i.e.*, approaches nearer to the sacrum, and, conversely, in retroversion it is pushed toward the symphysis. In retroflexion and anteflexion the cervix and corpus form with each other an angle which may be almost a right angle or acute angle. Here the position of the cervix to the vagina deviates but slightly or not at all from the normal position. Anteflexion occurs congenitally,[1] and, as in other changes of position, it may be acquired as a result of labor, especially when the uterus is very flaccid. It is still a question whether adhesions favor or produce the false positions.

Fig. 466.—Proliferative villous endometritis in woman aged 25 years. ⅔ natural size. (After *Langerhans.*)

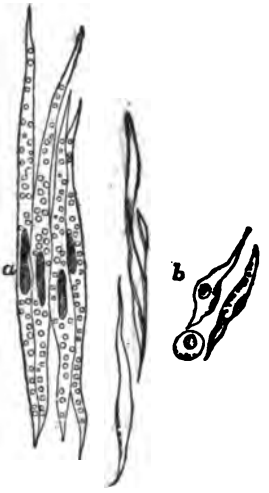

Fig. 467.—*a*, hypertrophy of uterine muscle-fiber cells in pregnancy; *b*, degeneration of fiber cells after delivery.

Prolapse of the uterus (*prolapsus* or *procidentia uteri*) is possible only when the ligamenta (*uterosacral*, accompanied by *latum* and *rotundum*) are relaxed and yielding. Prolapse of the uterus is generally perineal laceration and is accompanied by prolapse of the vagina. An apparent prolapse of the uterus develops from general hypertrophy and elongation of the cervix. In this condition the fundus remains in its natural position, while in true prolapse it descends. In both cases the vagina is everted and the *portio vaginalis* may protrude from the vulva. Three stages of prolapse of the uterus are differentiated. In the first stage—sinking—the uterus has descended into the vagina, but has not yet reached the introitus; in the second stage—incomplete prolapse—the cervix appears in the *rima vulvæ;* in

[1] Usually congenital anteflexion is permanently overcome by pregnancy.

the third stage—complete prolapse—the uterus pushes the whole vagina outward and lies between the thighs in front of the vulva.

Primary prolapse of the vagina is favored by defective position of the uterus (slight retroversion) and by loose connections with neighboring organs. It always develops in connection with labor, through which all parts undergo a certain degree of relaxation, enlargement, and distention, especially when the vagina is deprived of an important support by a perineal laceration which does not heal by primary intention. Partial prolapse of the posterior or (rarer) of the anterior vaginal wall is more frequent. In this condition, as a rule, the lower portion of the posterior or anterior vaginal wall forms a flat to hemispheric, often semi-walnut-sized protrusion into the vagina.

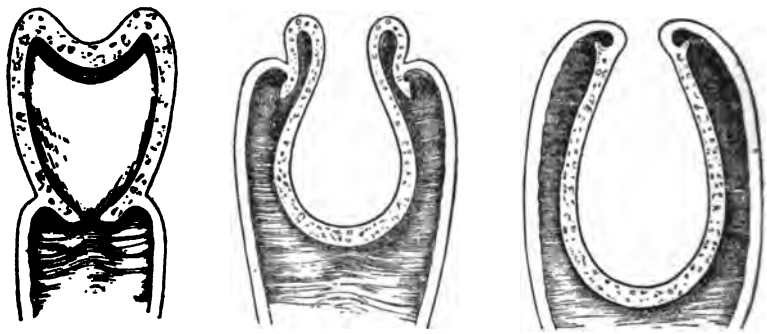

Fig. 468.—Successive stages of inversio uteri. (After *Leishman.*)

Inversion of the uterus signifies inversion of the fundus uteri inward; it may be partial or complete, is very rare, and occurs after labor and in intrauterine tumors which arise from the fundus. (See Myoma, p. 259.)

Hypertrophy of the uterus is a physiologic process in pregnancy. In this condition the smooth muscle-cells are enormously enlarged. (See p. 467.) After parturition the uterus slowly decreases in size, so that after a few weeks it is still possible to diagnosticate an antecedent labor from the thickness of the uterine wall, the very wide, thick-walled, and partly marked tortuous vessels, and the partial fatty metamorphosis (yellow maculæ). The wide and thick-walled vessels never completely return to their former state, but remain visible at a later period as a characteristic sign of former pregnancy. Not infrequently involution of the uterus is incomplete after parturition, especially when secundines are not wholly extruded or endometritis exists; the uterus then remains enlarged and often strikingly hard as a result of interstitial proliferation and condensation. Hypertrophy of the uterus

is observed also in false position, circulatory disturbances, tumors, and in extrauterine pregnancy.

In so-called **uterus infarct** (*metremphraxis*) the uterus is usually in a state of incomplete involution after labor. In this alteration the uterus and the adjoining fibromuscular substance contain unusually wide and strongly congested vessels, so that the inner surface and, on incision, a more or less broad portion of the body of the uterus appear dark red, almost like an infarcted lung area. This affection occurs only after parturition, and is due to incomplete involution of the vessels. Generally it is some noxious influence which, in connection with labor, causes continued hyperemia, so that a permanent condition finally results. (See p. 90.)

Atrophy of the uterus, aside from the small uterus in chlorotic subjects, occurs as senile atrophy in advanced age, in hydrometra, hematometra, *mycosis uteri*, and in connection with the puerperium.

Hematocolpos signifies accumulation of blood in the vagina; it occurs in imperforate hymen. Hematometra develops as a result of accumulation of menstrual blood within the uterus in atresia or constriction of the orifices, or of the upper portion of the vagina.

Hematoma of the vulva may form a swelling the size of the fist or a child's head; it develops as a result of trauma, most frequently during labor.

In Douglas's space—the deepest portion of the abdomen—a locally circumscribed exudative inflammation of the peritoneum is frequently found; the exudate is generally fibrinous. This exudate may be transformed into a richly vascular layer of connective tissue by organization and vascularization. In variations of blood-pressure, small extravasates, which are transformed into pigment and impart to the affected areas a rust-brown appearance, frequently develop from the new-formed vessels. When the hemorrhages are so large that the inflammatory phenomena are obscured, the condition is designated as retrouterine hematoma. (See Tumors, p. 213.)

In the **mammary glands**[1] an acute interstitial mastitis terminating in suppuration: acute purulent interstitial mastitis, quite frequently develops in connection with lactation and small injuries of the nipple. An acute purulent inflammation, starting from the nipples, is often observed also in the newborn, male or female (*mastitis neonatorum*), from about the third to ninth day after birth, occasionally later.

In **obliterating mastitis,** which is comparatively rare, the inflam-

[1] For the chronic forms of mastitis, see Fibroma, p. 219.

mation involves both the alveoli and excretory ducts, the inflammatory infiltration and destruction of the parenchyma varying in intensity in different parts of the gland. While in the alveoli there is more or less extensive degeneration of the epithelium, due to simple pressure atrophy resulting from the surrounding lymphocytic tissue, in the excretory ducts various processes are observed: destruction of the adventitia by lymphocytic invasion, which causes thickening and fibrillation; proliferation of young granulation tissue in the inner wall of this layer, which first excites irritation and proliferation of the epithelium and afterward causes its disintegration. Dilation of the lumen or cyst formation never occurs; on the contrary, narrowing of the lumen takes place *para passu* with the increasing proliferation of the granulation tissue, which finally results in complete destruction of the epithelium and obliteration by adhesion of the margins of the denuded lumen.

Milk cysts: galactocele, may form during lactation as a result of retention of milk in the lactiferous ducts. These sometimes attain considerable dimensions; at first they contain milk, later a butter-like material, which is often mixed with hemorrhagic products. Small cysts, which are easily differentiated from those previously mentioned by their large number, chronic course, and serous contents, are sometimes found in advanced age. These, however, may occur also in earlier life and by confluence develop into large cysts. On long duration, papillary excrescences of the wall and fibrous thickening in the neighborhood appear.

From the milk glands develop principally carcinomata and preponderatingly in the female (98 per cent. in the female and only 2 per cent. in the male). Not rarely the external skin is the matrix of mammary carcinoma. Next in frequency to carcinoma are fibromata and the so-called adenomata (the nonmalignant) and mixed tumors: fibroadenomata and cystic fibroadenoma, which frequently occur in the female breast. The cystic fibroadenomata frequently undergo carcinomatous degeneration, particularly when they assume a papillomatous character. Primary sarcomata, lipomata, and endotheliomata also are observed. Leiomyoma, rhabdomyoma, and chondroma are rare. (For tuberculosis of the mamma, see Tuberculosis, p. 477.)

During **menstruation** the walls of the uterus and tubes are swollen and the mucous membrane thickened, succulent, and hemorrhagicly hyperemic. The excreted menstrual blood is alkaline and coagulates when unmixed with the vaginal mucus, *e.g.*, when it remains for some time within the uterus. The vaginal mucus consists of mucus, epithelia, fat, volatile fatty acids (cause of odor), etc.; it is acid in reaction and prevents coagulation of the blood. During menstruation there is hypersecretion from the vagina; the menstrual blood and vaginal mucus mix and

produce the acid-reacting menstrual fluid. The acute swelling of the mucous membrane and the increased secretions present the clinic picture of acute catarrhal inflammation.

Pseudomenstruation is a hemorrhagic state of the endometrium resembling menstruation and is easily diagnosticated in old persons and children; at the age of sexual maturity, however, it is best recognized by the absence of synchronous ovulation (as in systemic disease, eruptive fevers, etc.). The causes are, on the one hand, inflammatory changes in the mucous membrane in acute infectious diseases; on the other hand, nutritive disturbances of the vessels, *e.g.*, in phosphorus poisoning, and, as it appears in elderly women, very frequently sclerosis of the uterine arteries in consequence of former pregnancies, sometimes also as a concomitant of general arteriosclerosis. In the last case it is probably an agonal or preagonal phenomenon, since older manifestations of hemorrhage are lacking. Also in the climacteric, uncontrollable hemorrhages, which finally necessitate removal of the uterus, the same changes of the arteries, to which the hemorrhage probably is due, are found. (See p. 54.)

In **dysmenorrhea** portions of the mucous membrane are exfoliated and discharged as such with the menstrual fluid (accompanied by intense pain). The mucous membrane is exfoliated because in the interval (between the two periods) it has proliferated, lost the character of ordinary mucous membrane, and assumed a state which sometimes resembles almost exactly the decidua. The detached pieces consist of large decidual cells, have a smooth internal and rough external surface, and, corresponding to the utricular glands, perforated in cribriform manner: *decidua menstrualis.* This membranous dysmenorrhea, therefore, constitutes in a measure a transition to proliferation of the mucous membrane in conception. The latter, as is known, is followed immediately by transformation of the mucous membrane into the decidua, which, according to the position of the ovum, is then very quickly differentiated into the *decidua vera*,[1] *reflexa*,[2] and *serotina*.[3]

Premature interruption of pregnancy occurs: (1) in diseases of the mother: inflammation of the decidua (*endometritis decidualis*), injuries, hemorrhages, intoxications, retroflexion of the gravid uterus with incarceration, etc.; (2) in diseases of the fetus (syphilis), and (3) in false position of the fetus. *Endometritis decidualis* is generally the continuation of pre-existing endometritis; the strongly proliferated vessels exert an unusual irritative action upon the whole surface of the ovum and

[1] Parietal portion.
[2] Developed by intense proliferations, covers the ovum; not parietal portion.
[3] That parietal portion upon which the ovum rests, where the adjacent chorion becomes the placenta.

cause proliferation of the villi. The stronger this is, the more nourishment is withdrawn from the fetus, so that the latter finally dies. The proliferated villi may then continue to develop independently for some time. The uterus is now either freed of its contents by abortion or hemorrhages take place, which frequently recur and form the so-called **blood-moles,** or, when the blood is decolored, flesh, or carneous, moles. These are large, formless masses, which are finally spontaneously expelled and give the impression that they consist only of coagula.

Likewise, in cystic, vesicular, or hydatid mole, ***mola hydatidosa,*** the embryo dies and a mass is expelled which consists essentially of a convolute of millet-seed- to dove-egg- sized vesicles attached by slender pedicles. The process here is a myxomatous hyperplasia of the basement tissue of the chorionic villi. This change may early attack all villi; then, as a rule, an embryo cannot be found; if it occurs later or is only partial, the embryo may be almost completely developed. Here the process is a primary alteration of the ovum. The view that hydatid mole is due to myxomatous hyperplasia is combated by many; some observers consider it probable that the process begins with proliferation of the epithelial layer of the villi, and that dropsic swelling follows.

In abortion due to syphilis of the fetus, the latter usually is born in the so-called macerated state. The fetus is then saturated with dissolved hematin and intensely soaked with fluid; the epidermis separates in the form of large flakes on the slightest touch.

Abortion is generally accompanied by certain dangers which are essentially dependent upon superadded states. In well-conducted obstetric clinics cases of puerperal sepsis after birth at full term are the exception. The dangers which, in contradistinction to normal labor, accompany abortion are due partly to the fact that in many cases premature birth is induced with criminal intention by persons who are insufficiently skilled in the method of performing this interference, and, therefore, do not observe the necessary precautions; partly to the fact that in most cases of premature birth pathologic alterations (of the mother, fetus, or both) already exist, and in great part to the fact that the dangers which attend abortion are underestimated, and, therefore, the necessary precautionary measures are not adhered to. For these reasons puerperal affections are so much more frequently observed after abortion than after normal labor. Puerperal affections (**puerperal fever, puerperal sepsis**) are almost always due to infection of the fresh wound surface of the uterus after expulsion of the ovum. The course of puerperal affections is very variable; in many cases death occurs so rapidly—within the first twenty-four hours *post abortum* or *post partum*—that, aside from the

phenomena of very rapid decomposition and putrefaction of the whole body, no anatomic changes are found, not even tumefaction of the spleen. Neither does the fresh wound surface of the uterus present any characteristic signs; in the blood, however, countless bacteria are found. In other cases the course of the disease is more protracted, lasting from a few days to many months. In these cases anatomic changes are always demonstrable at necropsy, according to which two groups can be differentiated. In the one phenomena of acute peritonitis predominate; in the other metastatic foci (usually quite numerous) of suppuration are present. In all

Fig. 469.—Tubal pregnancy.

cases the fresh wound surface of the uterus is altered; it is either cloudy or covered with distinct purulent, sanguinopurulent masses, or diphtheritic, ichorous, or gangrenous. If general fatal peritonitis develops in connection with these changes in the wound surface of the uterus, it can usually be demonstrated that the process in the uterus has extended through the tubes to the peritoneum. If, on the other hand, metastatic processes (purulent, ichorous) follow the uterine affections, purulent and ichorous thrombophlebitis are generally found in the wall of the uterus and in the parametrium.

In the course of **extrauterine pregnancy** (ectopic gestation), *i.e.*, of defective position of the ovum, there is always found in the uterus, and particularly in the endometrium, proliferation exactly similar to that observed in the beginning of normal pregnancy. Extrauterine

pregnancy is due to the union of the spermatozoa and ovulum in an abnormal locality, and failure of the fecundated ovum to enter the uterus. This is frequently, but not always, due to adhesions and displacements of the tubes and ovaries. According to the location of the ovum, an **ovarian, abdominal,** and a **tubal pregnancy** (see Fig. 469) are differentiated. In each the fecundated ovum exerts such an energetic irritative influence upon the surrounding parts that a placenta is formed. In tubal pregnancy rupture of the tube and death of the mother from internal hemorrhage often occur quite early. Tubal abortion may occur, and occasionally the process goes to full term without rupture. In ovarian[1] and abdominal pregnacy the fetus may develop until the normal end of pregnancy. Then uterine contractions (spurious labor) occur, the decidua is expelled from the empty uterus, and in the most favorable cases the fetus dies as the result of placental hemorrhages. Death of the fetus often occurs earlier. The dead fetus may atrophy or remain *in loco* for years (often for decades) in a quite well preserved state, or undergo calcification: **lithopedion.**

During labor smaller or larger wounds very frequently occur, almost always in the cervix uteri, less frequently at the introitus vaginæ: perineal lacerations, etc., most rarely in the lower segment of the uterus: rupture of the uterus.

Tuberculosis of the female genitalia is not uncommon. Necropsy records show that it occurs in from 18 to 30 per cent. of phthisical subjects, while clinicly it has thus far been demonstrable in only from 4 to 7 per cent.[2] This is explained by the fact that in the majority of cases the process originates in the uterine appendages (Fallopian tubes) and progresses as a more or less painful affection of the adnexa. According to Kroemer, Simmonds observed "true primary genital localization" in 4 of 80 necropsies upon tuberculous subjects. The frequency with which the different portions of the genital system are affected was, in 267 cases collected by Kroemer from the literature, as follows: Fallopian tubes, 222; ovaries, 42; uterus, 67; vagina, 16; cervix, 11. This ratio and a series of negative experiments are the chief reasons why the adherents of Baumgarten do not recognize an "ascending" tuberculosis (see p. 859), that is, secondary to an adjacent or distant tuberculous process, later of the tubes and also of the remaining genitalia. Extension of uterine tuberculous processes to the cervix, vagina, and vulva is extremely rare. Tuberculosis may be transmitted from man to woman by coitus, *e.g.*, Glöckner observed infection of the cervix from tuberculosis of the penis, and Jesionek saw tuberculosis of the penis from tuberculosis of the cer-

[1] This form of pregnancy is denied by many.
[2] Kroemer, Deutsch. med. Woch., June, 1911, p. 1057.

vix. The former case would seem to indicate that tuberculosis of the female genitalia may occur primarily from ectogenous infection and take an ascending course.

Among the malignant tumors of the female sexual organs, uterine carcinoma is by far the most frequent. This usually originates in the cervix, sometimes as villous carcinoma, and generally later involves the body

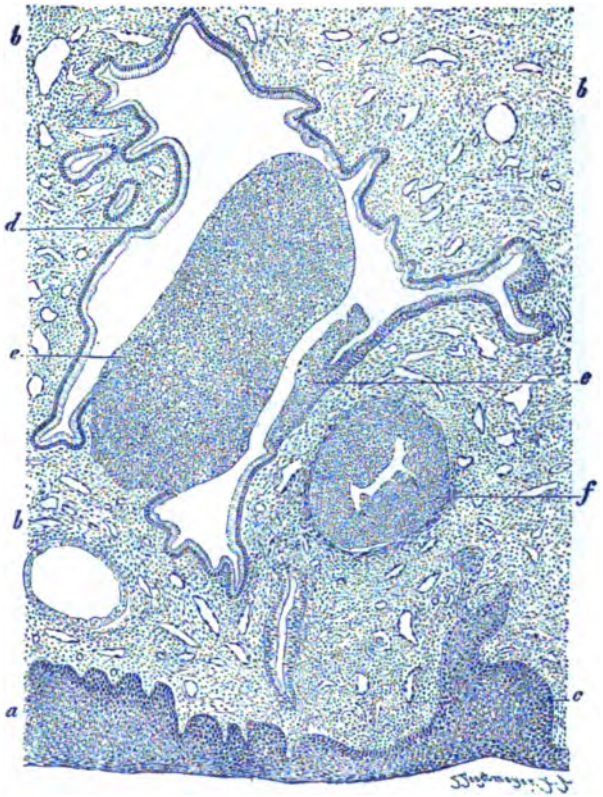

Fig. 470.—Beginning epithelioma of the cervix uteri. *a*, epithelium; *b*, connective tissue; *c*, epithelial cells growing into the depth; *d*, dilated glands; *e*, glandular epithelium, *d*, proliferating in the form of villi; *f*, transverse section of a gland the cylindric epithelium of which has been transformed into flattened epithelium. × 45. (After *Ziegler*.)

of the uterus and vagina, frequently also the bladder or rectum, and not infrequently causes abnormal communication between the genital canal, on the one hand, and the bladder and rectum, on the other. By extension to, or compression of, the ureters, unilateral or bilateral hydronephrosis or hydronephrosis with purulent pyelonephritis quite frequently

develops. These carcinomata generally soon extend to the parametrium and sometimes fill the pelvis with tumor masses. The great majority of them are squamous-celled carcinomata (epitheliomata).

In addition to squamous-celled carcinoma (epithelioma) of the cervix, primary cylindric-celled carcinoma, adenocarcinoma, malignant

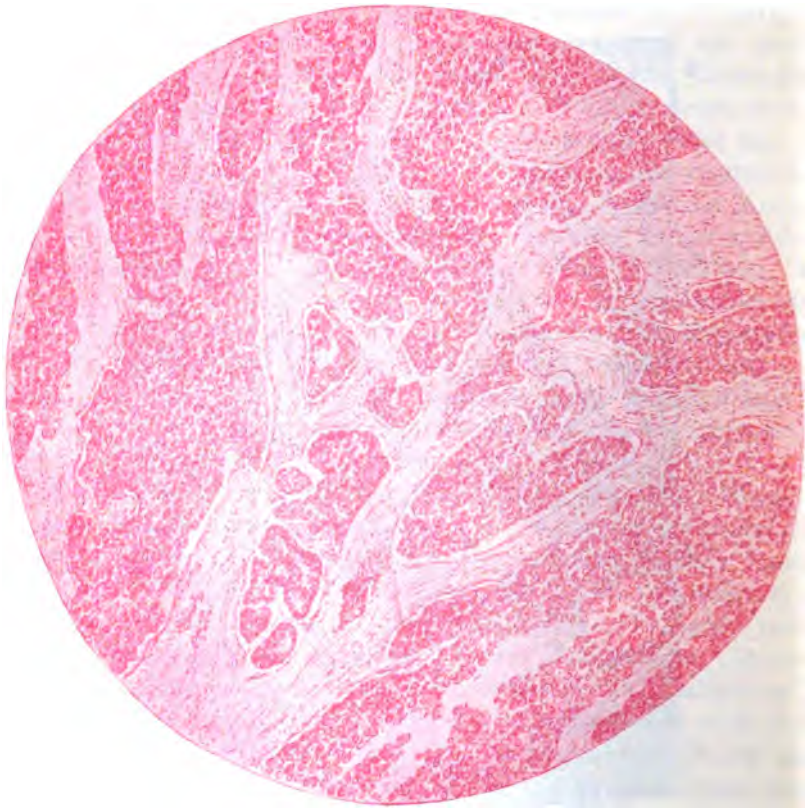

Fig. 471.—Carcinoma corpus uteri. (After *C. Keller.*)

adenoma, chorioepithelioma, and primary sarcoma of the body of the uterus also occur.

Myomata or **fibromyomata** of the uterus are more frequent than carcinoma of the cervix, and sometimes undergo sarcomatous degeneration.[1] (See p. 260.)

[1] The question whether there is any connection between tumors of the genitalia and diabetes is still a matter of dispute. While some authorities deny any connection and advise against operation for fear of diabetic coma, Henkel (*Deutsch. med. Woch.*, Nov. 18, 1909) saw glycosuria disappear in 3 cases after removal of large genital tumors. Henkel, therefore, believes that there is an "intoxication glycosuria"

Simple placental polypi developing from placental remains are not infrequently observed in the uterus after antecedent parturition and abortion. (See Fig. 472.) Next in frequency are so-called destructive placental polypi. These are remains of chorionic villi which proliferate, invade, and destroy the uterine wall and finally may perforate the uterus at the point of former attachment of the placenta. These constitute the transition to *deciduoma* or *syncytioma malignum*, which has only recently been accurately described. Opinions regarding the latter variety of tumor are still at variance, as is shown by the names

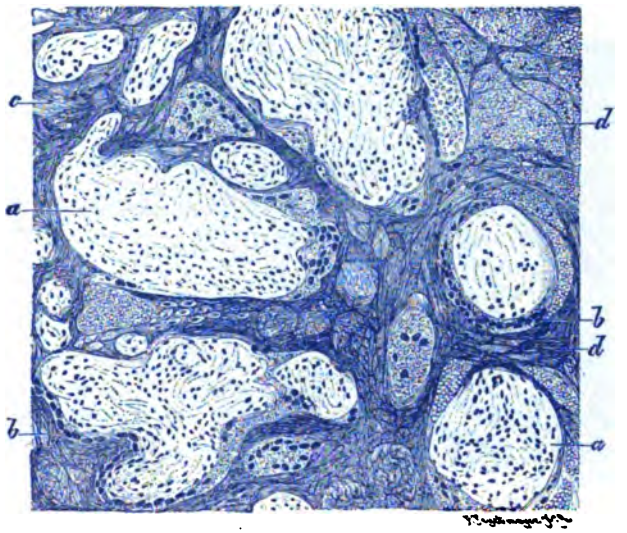

Fig. 472.—Placental polypus six weeks old. *a*, placental villi; *b*, epithelium; *c*, fibrin; *d*, red blood-corpuscles. × 45. (After *Ziegler*.)

employed to designate it, as: *deciduoma malignum, sarcoma deciduocellulare*, destructive epithelial tumor of the site of placental attachment, *syncytioma malignum*, etc.[1] The question

which, without the symptoms of essential diabetes, occasionally is caused by genital tumors. Calmann reports (*Münch. med. Woch.*, 1910, p. 1999) 2 cases which contradict Henkel's assumption; he states that glycosuria is neither an indication nor a contraindication for myoma operation, as was formerly supposed. (For discussion of so-called diabetes of pregnancy, see H. Ehret, *Münch. med. Woch.*, 1911, No. 17, p. 897.)

[1] Veruht (*Virchow's Archiv*, Bd. 196, p. 73) observed in a man aged 30 years a gray-white papillary tumor of the bladder which had formed numerous metastases in the pelvic connective tissue; prevertebral, mesenteric, and cervic lymph-glands, and lungs. Microscopic examination showed that both the primary tumor and the metastases were composed of two different types of cells: (*a*) syncytial elements resembling the syncytia of the chorionic epithelium, and (*b*) large polyhedral cells

here is one of atypic, malignant, epithelial tumors the cells of which correspond partly to the typic stroma cells of the decidua, partly greatly resemble the epithelioid and giant cells peculiar to the *decidua serotina*. The large epithelioid and giant cells are considered by Marchand to be derivatives of the syncytium, because they morphologicly resemble these elements and possess the same relation to the blood-spaces, in which they are observed isolated and in groups. These cells often coalesce and form large trabecular and reticulated bands between the wide blood-spaces. Somewhat smaller, clear, polyhedral cells characterized by a particularly high glycogen content also occur in these tumors.

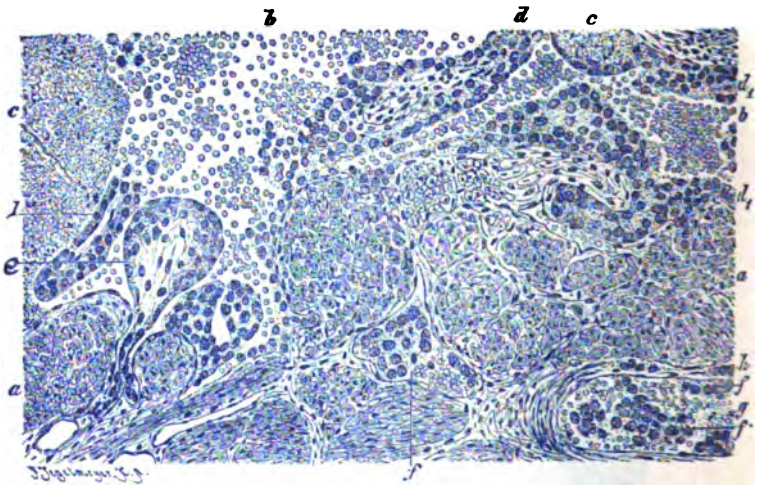

Fig. 473.—Section from a placental carcinoma at the point of transition into the uterine wall. *a*, muscularis of the uterus; *b*, large venous blood-space; *c*, thrombus; *d*, intravascular chorionic villus with proliferated syncytium in a large blood-space opened inward and occupied by thrombi; d_1, epithelial proliferation upon the vessel wall; *e*, proliferating epithelial mass penetrating into a small vessel; *f*, groups of proliferated epithelium within the veins of the uterine musculature; *g*, thrombus; *h*, proliferating cells in the walls of a vein. × 70. (After *Ziegler*.)

Primary carcinomata of the vulva are quite rare; they usually extend to the vagina. The vagina is rarely the seat of primary carcinoma (see Fig. 111, p. 298), but it is frequently secondarily involved

differing only slightly from Langhan's cells. Transitions between both kinds of cells were frequently noted. The greater part of the stroma was highly edematous, producing manifold variations of structure. This case demonstrates that not all tumors morphologicly simulating chorioepithelioma are to be regarded as such geneticly, but rather that abundant formations resembling chorioepithelioma occasionally may occur in a carcinoma manifesting nothing characteristic macroscopicly.

by carcinomata of the cervix uteri and of the vulva. Primary sarcomata of the vagina are rare; fibromyomata are more frequent. Lipomata and fibrosarcomata, fibromata and fibromyomata sometimes develop from the vulva.

Elephantiasis of the vulva is somewhat more frequent, and may involve the labia majora, labia minora, or clitoris. Marked elongation of the labia minora is a frequent result of self-abuse. This condition is designated also as Hottentot apron, because in Hottentots extraordinary development of the labia minora is hereditary.

Kraurosis, or atrophy of the vulva, a condition in which the vulva is shrunken and narrowed, the labia minora and clitoris disappearing, is said to be due to progressive atrophy of the skin and disappearance of the elastic fibers, or to primary affection of the cutaneous vascular reticulum followed by edema and finally atrophy. Repeated scratching, excited by *pruritus vulvæ,* is stated as the cause.

Primary sarcomata and carcinomata of the Fallopian tubes are very rare; fibromyomata also are of rare occurrence. (For tuberculosis of the Fallopian tubes, see Tuberculosis, p. 477.)

BONES, CARTILAGES, AND JOINTS.

Red, yellow, and **colloid** bone-marrow are differentiated. The red corresponds to growing bone, the yellow to the fully developed bone; the colloid is a pathologic marrow, and develops in atrophic, marantic states and in old age.

The red marrow is transformed into yellow only in the tubular bones; wherever spongiosa is present and forms small, narrow spaces, *i.e.*, in the flat bones (ribs, pelvis, vertebræ, etc.), the red bone-marrow persists throughout life. The yellow marrow of the tubular bones consists of fat-tissue; the red or lymphoid is a soft and very vascular round-celled tissue, a granulation tissue. In the process of transformation new cells do not take the place of the granulation tissue, but the round cells themselves become fat-cells by taking up fat. Colloid marrow generally develops from fat-marrow, in that the fat disappears from the cells, the cells themselves become smaller, and the space thus produced is occupied by a soft, mucin-containing, albuminoid intercellular substance.

The yellow marrow cannot without cause be transformed into red; a stimulus is necessary. The transition occurs acutely, so that it is best classed with the inflammatory processes (osteomyelitis). The fat is absorbed, and the fat-cells undergo proliferation. Transformation of the yellow marrow into red marrow is most frequently observed in blood diseases, in pernicious anemia and leukemia; also as a local change in inflammations.

The red marrow of growing bone originates partly through metaplasia from calcified tissue, from the developed, compact bone; on the other hand, in myelogenous ossification, marrow-tissue is converted directly into compact bone substance. Analogous to marrow-space formation, the compact bone substance may be substituted by another, soft tissue (periosteum or granulation tissue), the vessel channels broadening and lacunar absorption of bone occurring on the surface. This process is designated as **osteoporosis.** On removal of the periosteum, the surface of a bone thus altered is rough, finely aërated, porous, like unequally dissolved sugar; very small, fine spicula, which prick the finger, can be felt on careful palpation.

Through progressive transformation of marrow into compact bone substance the bone trabeculæ in the spongiosa may become gradually broader and the marrow-spaces smaller; the spongiosa becomes

denser by thickening of the compact bone substance. This process is designated as **osteosclerosis.** In osteosclerosis in compact bone calcified bone-tissue occurs in place of the Haversian canals. The compact bone thus becomes like ivory: *eburnatio,* assumes a whiter color, and often resembles in its consistency ivory or porcelain.

In the conversion of bone-tissue into marrow, the lime first disappears, leaving the bone-cells and an almost homogeneous, organic basement substance. In place of these appears a fluid which is soon displaced

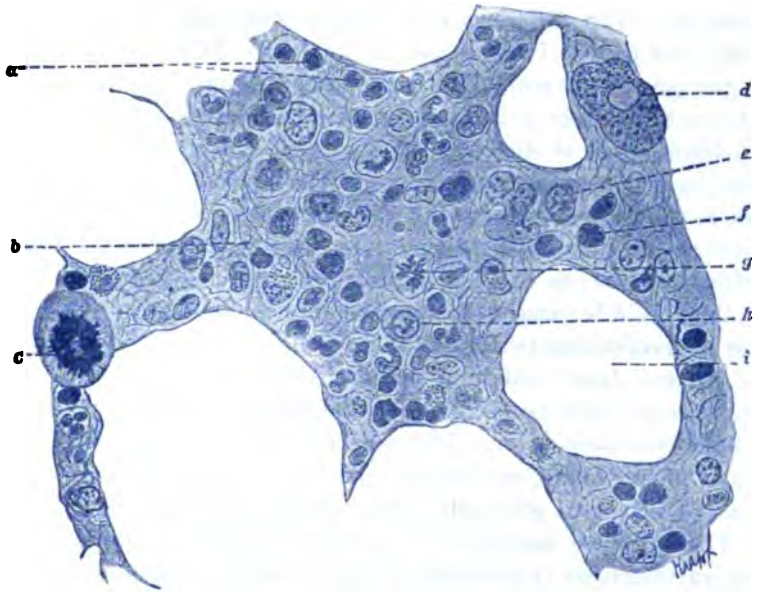

Fig. 474.—From a section of human red marrow. *a,* nucleated red blood-cell; *b,* reticulum; *c,* mitosis in a giant cell; *d,* giant cell; *e,* marrow-cell; *f,* nucleated red cell; *g,* mitosis; *h,* marrow-cell; *i,* space in which there was fat. × 680. (After *Böhm-Davidoff.*)

by cellular proliferation. When, on the other hand, marrow is transformed into compact bone substance, the fat first disappears; the remaining cells undergo proliferation; the new cells, by assuming the form of bone-corpuscles, produce a homogeneous intercellular substance which condenses: **osteoid**[1] **tissue** develops.

In physiologic and pathologic growth of bone the process is exactly the same. Physiologicly, a growth from different

[1] Osteoid tissue: bone-like tissue, *i.e.,* a tissue consisting of bone-corpuscles and homogeneous, but uncalcified basement substance, that is: bone minus lime. Finished bone develops from osteoid tissue by absorption of lime.

parts may be assumed, namely, from cartilage and from periosteum. Growth in width and length are differentiated. In flat bones the flat sides are covered with periosteum; the cartilage is placed marginally. The margins correspond to the cartilage-covered ends of the tubular bones.

Pathologic growth *e membrana* causes thickening. Thickening of the compact cortic layer of a whole bone or of the greater portion is called hyperostosis; if the growth is limited to a small, circumscribed area and assumes a tumor form, the condition is designated as exostosis. The differences are purely external, *i.e.*, quantitative; essentially, the process is the same. It is always the product of stimulation of the periosteum, of a *periostitis ossificans*. The same is true of osteophyte (see p. 236), an extensive, superficial, flat new formation of bone which is distinctly distinguishable from hyperostosis and exostosis by the fact that in osteophyte the line of demarkation of the old bone is still recognizable; in the others they are completely obliterated, bone and new formation merging into each other without demarkation. Osteophytes appear, as it were, superimposed, giving the impression as though they could be separated from the old bone.

During **ossification** two layers of the periosteum can be distinguished: a dense external layer containing numerous elastic fibers, which does not participate in the formation of bone, and an internal softer, richly vascular, and cellular fibrillary layer. The new formation of bone begins with division of the cells lying next to the bone; the new cells are at first round, then become oval, and gradually extend parallel with the surface of the bone. The basement substance becomes homogeneous, more and more compact, cartilaginous (glistening, chondrin- and glue- yielding); the cells become a little smaller, assume the same serrated form as bone-corpuscles, but as yet do not anastomose by their prolongations. This transition stage is designated as osteoid cartilage. Bone develops from this by the quite uniform infiltration of the intercellular substance with lime-salts, and the union with each other of the prolongations of the cells. This is the ordinary process of development of bone from periosteum.

Sometimes deviations occur, the proliferated periosteum being normally transformed into osteoid cartilage and bone only in certain isolated localities, and the area between directly passing over into marrow-tissue. This marrow developed from proliferated periosteum without intermediate stage and metaplasia is called primary marrow. The new-formed bone-tissue thus acquires a spongy character, has very small medullary spaces and very thick trabeculæ, is not exactly spongiosa, but only similar to spongiosa, and, therefore, is called **spongioid.**

This spongioid mass likewise is arranged in lamellæ upon the compact bone. By absorption of lime-salts a pumice-stone-like, chalky substance develops, which, after the manner of sclerosis, condenses and indurates. This is known as **osteophyte.** It occurs very frequently in pregnant women—*osteophytæ gravidarum*—and is generally situated upon the inner surface of the frontal bone. It is found quite frequently also in phthisical persons. By becoming compact it forms *hyperostosis interna.* This compact mass may change into a secondary spongioid mass by the occurrence of marrow-tissue at the place of the ossified bone-tissue. This state is called *hyperostosis spongiosa.*

Parosteal new formations of bone which blend with the hyperplastic periosteal formations and thus may contribute to the bulk of a bone are of heteroplastic nature, because they develop from the neighboring connective tissues (tendons, fascias, ligaments), which serve as a matrix for the tela ossea only under very especial conditions, *e.g.,* in fracture.

Fracture of bone may be total, *fractura completa,* both the periosteum and marrow undergoing a *læsio continui,* or partial, a so-called infraction: *fractura incompleta,* in which either the periosteum or even the bone cortex is uninjured at certain points. Young, flexible bones are more disposed to infractions than older, brittle bones. In all cases the state of the bone, the *causa interna,* is of decided importance. In fracture there is always, however, also a *causa externa,* the effect of violence. Even in spontaneous fracture (*e.g.,* in old age) the bone breaks only as a result of force, be it ever so slight, *e.g.,* on turning in bed. Between *fractura completa* and *incompleta* lies the fissure, *i.e.,* a separation of continuity without displacement of the apposed parts, so that a deformity is not noticeable from without. Dislocation of the fractured ends occurs only in complete fracture. From this an oblique direction, a kind of angular position, generally results, and at the same time shortening of the broken limb. If one end penetrates outward through the soft parts, a compound complicated fracture develops. When several or numerous bone fragments are set free on breaking of a bone, the condition is called splinter (comminuted) fracture, in which, as a rule, decided displacement of the small fragments and of the principal fractured ends occurs. In union of the fractured ends only the surrounding soft parts participate, but not the tela ossea. Reunion (regeneration) occurs through myelogenous, periosteal, and parosteal proliferation. A tissue, **callus,** which sometimes becomes bone: *callus osseus,* sometimes fibrous: *callus fibrosa,* develops. By callus is generally understood bony callus, although callus signifies

callosity. The fractured ends are regularly inclosed completely by callus (see Fig. 475); the opened medullary (marrow) cavity closes by callus formation at the point of fracture. Excessive development of callus produces the condition known as *callus luxurians.*

In every fracture hemorrhage occurs between the fractured ends. The blood coagulates at this point and often interferes with healing. The blood-corpuscles are dissolved; the fibrin hardens and sometimes takes a passive part in the new formation of connective tissue, being substituted by proliferating tissue. That portion of the callus which lies between the broken ends and interrupts the medullary canal is called *callus internus;* that which proceeds principally from the periosteal tissue is called *callus externus.*

Fig. 475.—Five-week-old fracture of the right humerus of a rachitic child 1½ years of age. (After *Langerhans.*)

After a time the callus begins to grow smaller by absorption; this occurs very slowly. The at first spongioid callus becomes more and more dense and assumes the consistency of bone. In the interior a kind of osteoporosis begins; small marrow-spaces occur, which slowly become larger and finally coalesce. Thus, little by little, a continuous medullary space is re-established. If the fracture heals in an angular position, the new marrow canal does not take an angular, but always a curved course, marrow substance developing from part of the old compact bone-tissue.

In amputations first a periosteal, then a myelogenous, callus forms in an entirely analogous manner, which results in closure of the opened medullary canal.

In *callus fibrosus* only fibrous and not bony union of the fractured ends occurs. That is almost always the case in fracture of the patella, because the patella has only a few blood-vessels, and above and below strong tendons which pull the fractured portions asunder. The *ossa innominata* and scapula generally heal by *callus osseus;* on the other hand, fractures and fissures of the skull usually heal by *callus fibrosus;* the bone wounds of *trepanatio cranii* likewise heal by fibrous callus or by an incomplete osseous callus.

Depressions of the skull involve either the external table alone or both the internal and external at the same time. In both cases concussion of the brain may occur.

Fractures of cartilage (of ribs, larynx, intervertebral cartilages) almost always heal by fibrous callus. An external osseous

callus, which develops from the perichondrium, is also frequently formed.

Sometimes a kind of joint develops at the point of fracture, a cleft being produced: **pseudoarthrosis.** This occurs most frequently in fracture of the neck of the femur with marked dislocation of the fractured ends. This fracture of the neck of the femur is very frequent in old people without the action of strong force (spontaneous fracture). The cortic substance of the head and neck of the femur is so brittle in old age, because of weak nutrition, that it frequently can be crushed with the finger.

Fig. 476.—Fracture of the neck of the left femur and trochanter major with dislocation. Woman aged 67 years. ⅔ natural size. (After *Langerhans.*)

In the spongious bones there usually develop not one fracture, but several fractures, which destroy the spongiosa. Healing occurs by approximation and consolidation of the fragments. This form of fracture has its classic seat in the bones of the spine: *fractura vertebrarum.* During life the latter is easily confounded with fracture of the intervertebral disks. This may occur through simple extension of the spinal column; it seldom involves the whole cartilage, usually has an oblique direction, and often extends into the vertebral

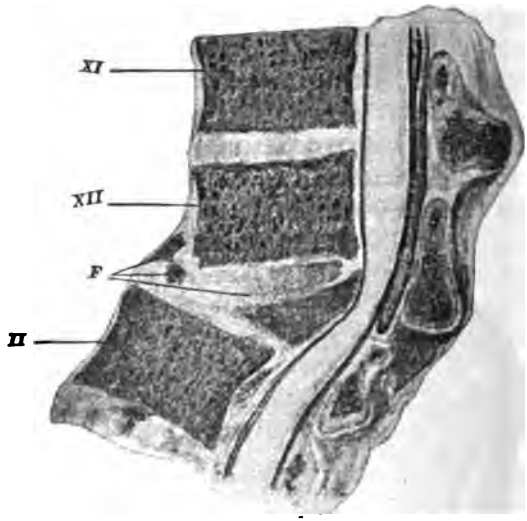

Fig. 477.—Fractura sanata vertebræ lumbalis primæ cum deviatione (connective tissue, nonbony union). Death sixteen months after accident from transverse myelitis at the level of the first lumbar vertebra. *F*, fragment of the first lumbar vertebra; between this is connective tissue. ⅔ natural size. (After *Langerhans.*)

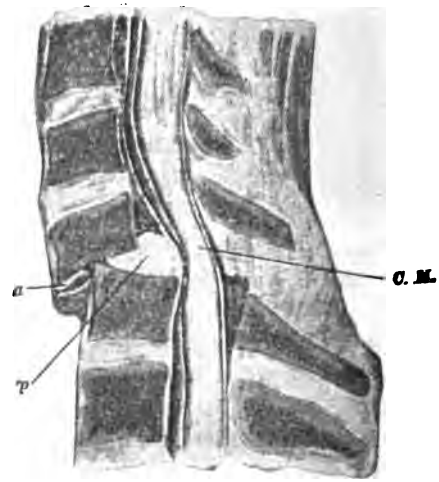

Fig. 478.—Fractura cartilaginis intervertebralis sextæ cervicalis cum deviatione columnæ vertebralis cervicalis. Death from transverse myelitis twelve days after accident. *C. M.*, location of compression myelitis of the sixth intervertebral disk; *a* is the smaller anterior portion; *p*, the posterior. The latter protrudes as a thick ridge into the spinal canal. The upper portion of the cervical spinal column is displaced forward half the width of a vertebral body. As a result the spinous processes of the sixth and seventh cervic vertebræ are widely separated. ⅔ natural size. (After *Langerhans.*)

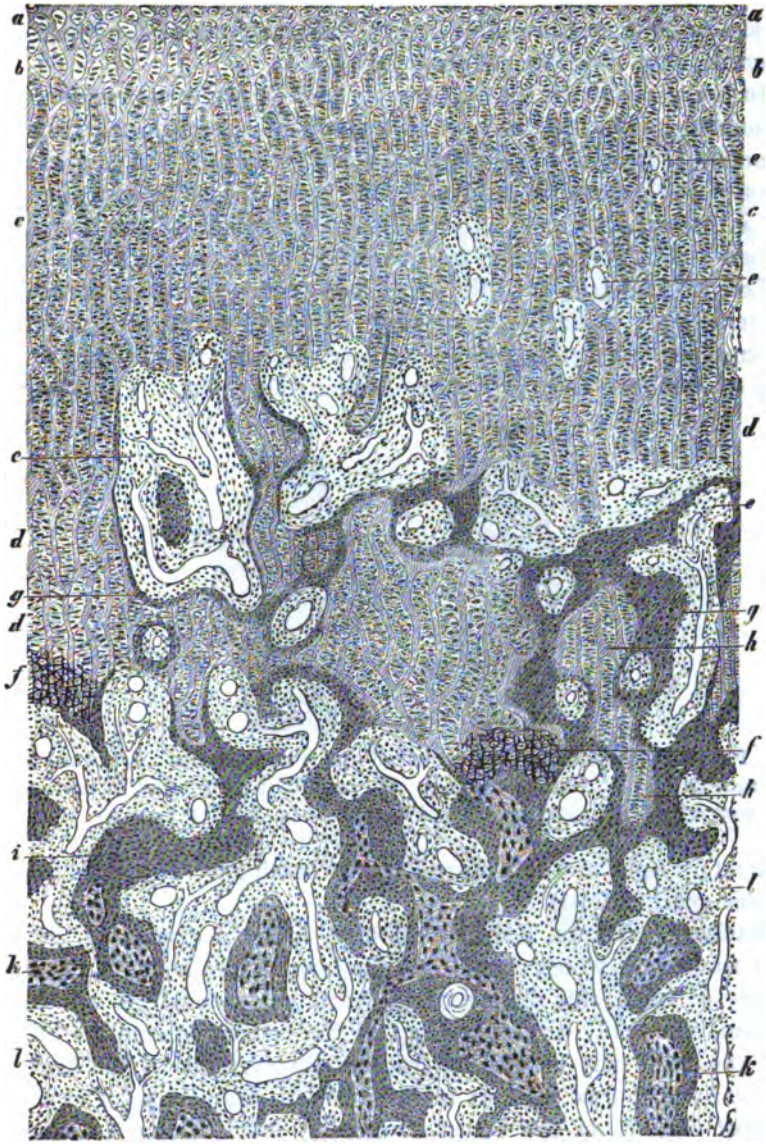

Fig. 479.—Rickets. Longitudinal section through the ossification junction of the upper diaphyseal end of the femur of a 1-year-old child suffering from rachitis of moderate degree. *a*, unaltered hyaline cartilage; *b*, cartilage in the first stage of proliferation; *c*, zone of proliferated cartilage cell columns; *d*, columns of proliferated hypertrophic cells; *e*, vessels located in the cartilage, with fibrous marrow-tissue; *f*, decalcified cartilage-tissue; *g*, osteoid tissue; *h*, remains of osteoid tissue in cartilage-tissue; *i*, trabeculæ of osteoid and fully formed calcified bone-tissue; *l*, fibrocellular marrow-tissue. (After *Ziegler*.)

bodies. As these fractures also ramify, displacements of the whole spinal column develop, most frequently kyphosis.

In every severe fracture of the vertebræ a *fractura comminutiva*, a *conquassatio*, generally develops as a result of several synchronous and continuous fractures. The fragments are compressed; a depression in the anterior segment thus results. In the event of healing by sclerosis there is no external callus formation. Diminution of the size of the vertebræ is always associated with reduction in size of the whole body.

Longitudinal growth of the long bones occurs *per appositionem* from the intermediary and articular cartilage. Growth ceases with destruction or premature ossification of the cartilage. In the pelvis there are five layers of cartilage from which ossification takes place: (1) *symphysis*

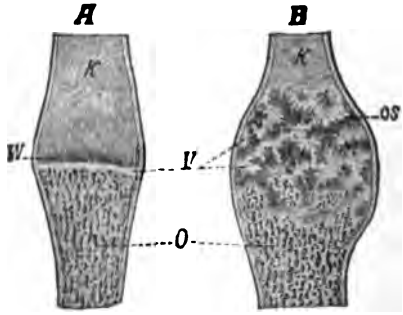

Fig. 480.—Section through a normal and a rachitic rib. *A*, normal rib; *B*, rachitic rib; *K*, resting cartilage; *W*, zone of proliferation of cartilage; *V*, zone of calcification; *os*, osteoid tissue. × 6. (After *Smaus.*)

pubica; (2) right and left sacroiliac synchondrosis; (3) right and left ileopubic synchondrosis.

Rachitis,[1] **rickets, English**[2] **disease,** is not a disease of the bone, but of that tissue which should be transformed into bone. In the great majority of cases, this disease of the early years of life is a local phenomenon, since only certain sections of the osseous system are affected. Thus, the head may be affected without involvement of the lower extremities; the thorax without involvement of the pelvis. The changes are most distinct in the bones developing from cartilage. Here are noticed, for example, at the zone of ossification of the costal cartilages, cartilaginous swellings which are generally only palpable, but in lean children are also visible. This swelling generally extends over all cartilagino-osseous zones of the ribs; therefore, forms, as it were, a chaplet:

[1] Rachitis has nothing to do with ῥάχις (spinal column); it is derived from rickets; is, therefore, written also without h.

[2] So-called because the first observations were made by English physicians.

Fig. 481.—Rachitis. Fresh section from the costocartilaginous junction of a rib. 1, resting cartilage; 2, beginning proliferation; 3, proliferation arranged in columns; 4, coalescence of basement substance; 5, osteoid substance; 6, developed spongiosa mixed with osteoid substance. (Zeiss, a_2; Comp. Ocul., 4. After *Langerhans.*)

the so-called **rickety rosary,** *pater noster rachiticus.* The swollen cartilage consists of young cartilage-cells developed as a result of excessive proliferation, and has a bluish, translucent appearance. The deficiency of intercellular substance is the cause of the flexibility of the cartilage. In the long tubular bones also the epiphyses may be considerably swollen by intense proliferation of cartilage.

In the normal growing bone the following zones are distinguished at the cartilagino-osseous junction:—

1, ordinary articular cartilage;
2, proliferated cartilage;
3, zone of preliminary calcification;
4, mixed zone of bone trabeculæ and marrow: spongiosa.

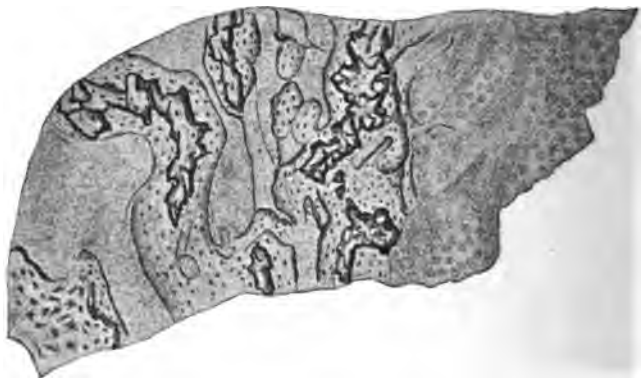

Fig. 482.—Rachitic costal cartilage. Small part from section 6 of Fig. 481. Osteoid substance. Incomplete calcification of the osseous trabeculæ. (Zeiss Apochr., 16; Comp. Ocul., 4. Reduced ½. After *Langerhans.*)

In rachitis, besides excessive proliferation and defective deposition of lime, there are observed retardation of metaplasia and a chronologic, and, accordingly, also a local, irregularity in the transformation of the four normal layers. The sequence of development is not preserved; calcified cartilage parts, marrow parts, and spongiosa lie adjacent to and intermingled with each other apparently without order. The uppermost layer of the spongiosa is very compact, spongioid. Thereupon follows the true spongiosa. The spongioid layer contains very slight amounts of lime-salts; osteoid cartilage has developed out of cartilage.

The same change occurs in transformation of the periosteum into bone-tissue, inasmuch as the external, newly formed lamellæ do not become firm, but consist of osteoid substance. At the same time the compact tela ossea in the tubular bones, owing to progressive formation of

marrow-space, is gradually thinned from within outward, at the junction with the bone-marrow, by transformation of the inner, firm bone lamellæ into bone-marrow tissue. If the externally deposited lamellæ became firm, the bone would acquire its old consistency. The lamellæ do not, however, become firm, are only incompletely provided with lime-salts, remain comparatively soft and flexible; hence, the thickness of the firm

Fig. 483.—Lateral spinal curvature (S-shaped scoliosis). (After *Sheffield.*)

tela ossea gradually diminishes until only a thin, slightly resistant layer remains. Hence, the curvatures which develop are not, as a rule, flexions, but infractions or fractures. (See Fig. 475.) After healing a sharp, prominent, bony ridge, which serves as a support for the bone, is seen on the concave surface.

Upon the thorax there is sometimes found in rachitis an incurvature or depression of the ribs close to the osteocartilaginous junction. This is due to local deficiency of lime-salts in the costal bones (the defi-

ciency of lime-salts is usually most marked alongside of the osteocartilaginous junction externally) and abnormal flexibility: *flexibilitas cartarum,* thus caused. Its occurrence is due to the fact that on movement of the thorax in breathing the flexible parts follow the inspirations less than do the remaining portions of the thorax. This may be explained by the fact that the intercostal muscles increase the thoracic space by elevating the ribs; the air in the chest cavity—the lungs—is thus rarefied so that the pressure in the thorax is less than the external air pressure. The difference in pressure is equalized by flow of air into the lungs (in inspiration). When for any reason, *e.g.,* by a bronchitic exudate, inspiration is rendered difficult or hindered, the difference in pressure is augmented; this favors incurvation of the ribs, since, owing to the stronger

Fig. 484.—Incurvation of the ribs at the costocartilaginous junction in rachitis. ½ natural size. (After *Langerhans.*)

external air pressure, the very flexible and yielding parts of the ribs follow inspiratory movement, elevation of the ribs, and widening of the thorax only to a diminished degree. The incurvation of the ribs is followed by protrusion of the sternum. A deformity of the thorax, which is generally designated as chicken- or goose- breast: *pectus gallinaceum,* is thus produced. In other, rarer cases a funnel-shaped depression of the lower half of the sternum occurs, giving rise to so-called funnel chest.

The rachitic changes in the skull are usually most decided in the region of the points of ossification. The region of the lambdoid suture is generally the most markedly altered. Soft, very vascular periosteal proliferations develop, which correspond to periosteal proliferations of the tubular bones. Since with progressive growth the tela ossea is absorbed from within outward, no new compact bone forming externally, the firm tela ossea finally disappears. If at last the soft, osteoid masses also undergo absorption as a result of pressure (upon the occiput in

dorsal attitude), defects, losses, which are closed only by membranes develop in the cranial vault. These occur first as small fenestra in the region of the *impressiones digitatæ*. This disappearance of compact bone is designated **craniotabes.** Further characteristic changes of the rachitic skull are the wide, open fontanelles and the marked, somewhat prominent bulging of the forehead.

In rachitis of the **pelvis** the *conjugata vera* is shortened, while the transverse diameter is increased, because the *caput femoris* presses upon the iliopubic synchondrosis and (in small children who attempt to walk too soon) produces an incurvation which gradually increases and finally results in narrowing of the pelvis: flat rachitic or, tersely, rachitic pelvis. The sacroiliac synchondrosis pushes the pelvic parts asunder laterally and causes enlargement of the transverse diameter.

Fig. 485.—Rachitic scoliotic skeleton. (*Grandin, Jarman, and Marx.*)

Genu valgum and *genu varum* are in a measure connected with these changes, because they are partly due to rachitis. In normal position of the legs, the hip,- knee,- and ankle- joints lie above each other in a vertic line, the thigh and leg forming a straight line. In *genu valgum* (X-legs, knock-knees) the knee deviates inward from the vertic line, so that the thigh and leg form an angle opening outward. *Genu valgum infantum* and *adolescentium* are differentiated. The former is always caused by rickets; the latter Mikulicz attributes to so-called late rickets. *Genu valgum* is frequently associated with *pes valgus.* In *genu varum* (O-legs, bow-legs) the knee-joint deviates outward from the vertic line and the thigh and leg form an angle opening inward. In most cases this change also is caused by rickets.

As a result of a fetal inflammation of the primordial cartilage: *chondritis fœtalis,* the longitudinal growth of the tubular bones may be interrupted. This change is called **congenital rachitis,** although it slightly resembles rachitis only in outward appearance. The tubular bones are markedly short, thick, and often bowed, the epiphyses swollen through proliferation (but not in chaplet arrangement) of the embryonal

cartilage cells. Between cartilage and bone there is a narrow layer of striated connective tissue which prevents further longitudinal growth. Premature synostoses often occur in the skull. There is marked proliferation of the *panniculus adiposus,* and the skin lies in folds.

Moeller-Barlow's disease (*osteotabes infantum*) is an affection of artificially nourished children, characterized by bloody suffusion of the gums; hemorrhages into the skin, kidneys, mucous membranes, the bone-marrow, and beneath the periosteum; pains and swellings in the lower extremities and occasionally of the skull; arrest of development, porosis; tendency to fractures, infractions, and displacements of the bones, especially at the ends of the epiphyses. A pathologic state of the bone-mar-

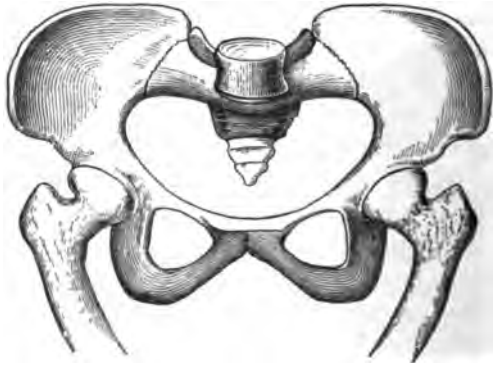

Fig. 486.—Flat rachitic pelvis (mild grade).

row, which is transformed into a finely fibrillated reticular tissue poor in cells and vessels, is the essential change. The thus caused defective formation of bone by osteoblasts and the disturbed endochondrial ossification, due to deficient vascularization, are accompanied by an active resorption, which explains the craniotabes and frailty of the bones.

K. Kasper[1] describes 3 cases of this affection. A milk depot which dispensed milk for infants sterilized the milk once for from twenty to twenty-five seconds at 100° C. All three infants had been nourished for months exclusively with this milk. Microscopic examination of the urine for blood is of importance in diagnosis. If pain and swelling of the epiphyses are predominant, the local findings do not suffice; on the contrary, the child should be thoroughly inspected, for in such cases an erroneous diagnosis of osteomyelitis or periostitis leads to ineffectual operative procedures, the disease steadily progressing. Syphilis produces similar manifestations in the epiphyses of the tubular bones. Liability of confusion with rachitis is very great. The therapy, which must be antiscorbutic regulation of the diet, is very effective in spite of its simplicity.

[1] Die Heilkunde, Nov., 1910.

Oblique (Naegele's) **pelvis** develops independently of rachitis after affections of the lower extremities, *e.g.*, of the knee-joint, and very frequently also after coxitis and is then called coxalgic pelvis. Premature synostosis of the sacroiliac synchondrosis of one side also leads to the formation of oblique pelvis, so-called obliquely contracted pelvis, while premature synostosis of both sacroiliac synchondroses produces transversely contracted (Robert's) pelvis.

Curvature of the spinal column is called kyphosis, gibbus, humpback, when the convexity is directed backward; lordosis when the convexity is directed forward, and scoliosis when the con-

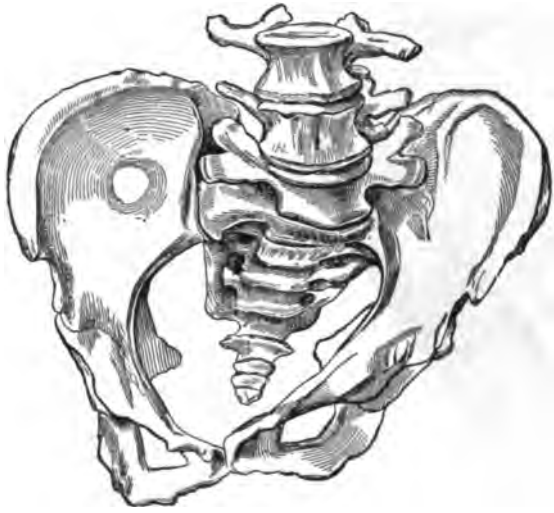

Fig. 487.—Obliquely distorted pelvis of Naegele.

vexity is directed toward the side. The lateral excursions are almost always associated with compensatory excursion toward the opposite side in another portion of the spinal column and frequently also with forward or backward curvatures. The latter condition is called kyphoscoliosis, etc. The origin of kyphosis is generally different from that of scoliosis and lordosis, of which the latter is least frequent.

Kyphosis forms either an arched or an acute angle, most frequently in the region of the dorsal vertebræ. Arch-shaped kyphosis is an increase of the normal curvature of the spinal column, and develops chiefly in advanced age as the result of muscle weakness and atrophy of vertebræ. Acute-angled kyphosis (**gibbus**) is almost always the product of tuberculous spondylitis (*caries vertebrarum*). In this condition portions of the vertebræ or whole vertebræ are often destroyed. If arrest occurs, synostosis of several vertebræ may result. (See Fig. 488.)

Lordosis affects, as a rule, the lumbar region of the spinal column, constitutes a compensatory phenomenon in kyphosis of the dorsal vertebræ, occurs in pelvic changes due to rachitis and in luxation of the heads of the femurs, and is rarely observed as an independent affection.

In **scoliosis** the question is one of rotation of the spinal vertebræ around the long axis of the spinal column. Here there is no question of joints, for there are no joints in the spinal column, but only soft, flexible cartilaginous disks, which, within certain limits, permit axial rotation and shifting. So-called habitual scoliosis is said to result from abnormal positions of the spinal column (in consequence of habit, occupation, exercise, etc.), very gradual change taking place in the form of the spinal bodies. These become lower, especially upon the concave side, and higher and thicker upon the convex side, so that section no longer corresponds to a quadrant, but to a trapezoid with deep indentation upon the shorter side. These changes of form are secondary and referable to new growth (proliferation) and absorption, not to pressure. In persistent superimposition of the vertebræ without cartilaginous interstitial substance, synostosis of the vertebral bodies may occur. Habitual scoliosis begins in the 6th to 8th year. (See below.)

Fig. 488.—Kyphosis of the thoracic vertebral column from caseous tuberculous periostitis and osteomyelitis, in a child of 8 years. Destruction of three dorsal vertebræ. ⅔ natural size. (After *Langerhans.*)

Since the beginning of the present century it has been established, according to M. Boehm,[1] that congenital disturbances of the spine play an important rôle in the etiology of juvenile spinal curvatures. Very frequently congenitally established skeletal defects do not become manifest until later in life. For example, partial congenital defect of the radius with preservation of the ulna, if not very marked, may produce no striking alteration in the form of the lower arm at the time of birth; when, however, the child grows the ulna grows normally in the abnormal arm, while growth of the radius is retarded. The result is a deformity

[1] Der Kinderarzt, May, 1911, H. 5, p. 99.

of the arm and hand, which gradually becomes more and more marked. Compare this with a slight anomaly of the spine, *e.g.*, a congenital adhesion of the arches of two thoracic vertebræ on only one side of the spine. In the newborn such an anomaly is unimportant as regards the form of the thoracic skeleton. Later, however, growth begins, of necessity unequally. The healthy side of the spine develops normally; the coalesced side is retarded in growth. Now function is added (upright posture, weight burden, movements), meeting on one side normal conditions, on the other abnormal resistance: the symmetry of the spine is disturbed.

Fig. 489.—Gibbus from chronic caseous spondylitis. Synostosis of dorsal vertebræ V-VII and of the spinous processes. At * old caseous focus. Woman aged 27 years. ⅔ natural size. (After *Langerhans.*)

Compensatory efforts are established and cause new deviations of the spine, and finally the completed picture of scoliosis is slowly evolved. The primary cause was the congenital unilateral adhesion of the vertebræ: secondarily mechanic agencies entered; both components acted hand in hand with growth and finally produced distortion of the trunk which, in its original insignificance and insidious, symptomless development, remained undetected until, sooner or later, generally in the school period, the scoliosis was discovered by the specialist. The cervic ribs, so frequently observed in scoliosis, are not the direct cause of the congenital scoliosis, but only in a measure a sign that other congenital alterations, which produce the deformity, are present in the thoracic skeleton.

The congenital morphologic anomalies of the spine are not, according to Putti,[1] accidental, but typic, morphologic forms which in the various examples always are repeated with characteristic phenomena, for which reason they must be referred to a primary and constant anlage. This elementary structural design is dependent upon the primitive form of the spine, which is to be regarded as an aggregation of united, but geneticly and morphologicly independent parts. If it is assumed that this or that part or several parts do not develop or are arrested in development, while the others progress toward the definite form, the various morphologic combinations will originate and always correspond to constant types. Putti gives as an illustration of this a "type spine," and further considers, in so far as his personal observations go, the anomalies which may originate from it in the manner stated. He shows that the deformity may affect the vertebræ or their arches. Of the anomalies of the vertebræ and their relation to adjacent parts, Putti gives a schema needing no description. The congenital deformities of the dorsal vertebræ (arches with appendages) could be sketched in a similar manner.

In addition to this group of congenital deviations of the individual vertebræ, recent research has acquainted us with developmental defects which disturb the regional structure of the thoracic skeleton, namely, the phenomenon of so-called numeric variation of the thoracic skeleton (Böhm, 1908). At a certain very early stage the embryo possesses an axial column the individual segments of which are indistinguishable. At a relatively later stage of development (sixth week) the uppermost axial segments have become the cranium, the next seven the cervic vertebræ, the next twelve dorsal, the next five lumbar, etc. In contrast to these typic differentiations of the axial skeleton, deviations may occur. Differentiation may so progress that, *e.g.*, the segment which normally becomes the atlas is included in the skull. In analogous manner the vertebra which regularly represents the seventh cervic vertebra may, for example, be differentiated as the first dorsal. The same holds good for each segment of the spine: they may assume the form which their neighbors, whether cranial or the caudal, normally have. The whole thoracic skeleton can undergo such an alteration and with a certain degree of regularity. We then see a structure of the thoracic skeleton as illustrated in the schemata here given. Whoever is familiar with the developmental history of the thoracic skeleton knows how independent of each other both sides (right and left) of this organ are. Thus, numeric variation also may lead to asymmetric differentiation of the thoracic skeleton, if, for example, the segments upon the left side manifest assimilation with their neighbors—in one or another sense—while the right side remains normal. In such cases the asymmetric structure of the thoracic skeleton may lead to scoliosis in the dorsal or lumbar region. Total metamorphosis of a vertebra (including ribs) into its neighbor, of course, almost never occurs; rather assimilation forms of lower degree (*e.g.*, synostoses of the atlas with the occiput, last cervic vertebra carrying ribs, first dorsal vertebra with ribs) occur. It must be emphasized, however, that not assimilation or transitional vertebræ, but defective structure of the thoracic skeleton or of a section of the same, leads to deformity. The cause of the morphologic anomalies of the individual vertebræ as well as of varying differentiation of the thoracic skeleton is obscure. Putti denies mechanic as well as pathologic explanations for the morphologic anomalies, inclining rather to interpret them on an embryologic and phylogenetic basis. The varying differentiation of the structure of the thoracic skeleton originating through numeric variation has already

[1] Fortschr. auf. d. Geb. d. Roentgenstr., Bd. xiv, xv.

been conceived by Rosenberg as a fluctuation around the normal, as "oscillations" in the line of phylogenetic development. If we add those scolioses which originate through abnormal pressure in the uterus, we have the following groups of congenital curvatures of the spine:—

1. Scolioses due to intra-uterine influences.
2. Scolioses due to morphologic deformity of the individual vertebræ.
3. Scolioses due to variation in differentiation of the thoracic skeleton.

In addition to congenital conditions, **rickets** is of especial importance in the causation of spinal curvature, and may affect the form of the spine in three ways:—

1. By curvature (or infraction) of the vertebræ in a sagittal direction, especially in the middle portion of the spine. The lumbodorsal rachitic kyphosis thus produced is extremely common and is the cause of the great majority of "round" or "flat" backs so frequently observed in school children.

2. The curvature of the rachitic spine may be diagonal instead of sagittal. Here, again, the lower dorsal and upper lumbar portions are principally involved. Examination of a number of school children with right-sided scoliosis in the lower dorsal region has shown that in numerous cases the latter develops from rachitic lumbodorsal thoracic kyphosis.

3. Rachitic softening of a large portion of the spine causes the latter to sink in. Compared with the two first forms of rachitic deformity, in which the process is principally an affection of the vertebræ, this last group is characterized by alteration of the vertebral arches. While in the two first groups there is quite angular scoliosis, generally of mild degree and usually located in the lumbodorsal region, the scolioses resulting from collapse of rachitic vertebræ are arch-shaped and accompanied by marked torsion, and therefore generally induce marked curvatures situated in the dorsal or lumbar region or both.

The conclusions to be drawn from the advance in the teachings of the origin of scoliosis may be briefly formulated as follows:—

Although there is a comparatively small percentage of spinal curvatures the origin of which still is obscure, where roentgenology and anatomic knowledge give us no aid, the elucidation of which, however, is probably not far distant, it may now be stated that vertebral curvatures in childhood are chiefly due either to congenital or rachitic disturbances. So-called habitual or school scoliosis, or the assumption that fixed vertebral curvature, *i.e.*, such due to osseous alterations, originates as the result of the action of purely mechanic conditions in an *a priori* normal and healthy skeleton, can no longer have place in modern orthopedic science.

In **club-foot** (see p. 200) there is a deformity which, viewed externally, gives the impression of mechanic displacement. In this condition the external margin of the foot and, in advanced stage of development, the dorsum of the foot are turned downward: *pes varus*. The displacement of the articulating parts occurs as the result of traction of certain groups of muscles, seldomer as a result of shortening of the ligaments or strong cicatricial retraction. Two stadia are distinguished: (1) change in position of the joints, which is still within physiologic limits; here the configuration of the bones is still preserved, and (2) changes in position associated with alterations in the configuration

of the bones. Only the latter can be considered to be the result of pressure (?).

In **flat-foot,** *pes valgus,* the inner margin of the foot touches the ground; here the dorsum of the foot is turned more upward, and the

Fig. 490.—Top view of the fetal skull showing the anterior fontanelle and the frontal, coronal, and sagittal sutures. *(Grandin, Jarman, and Marx.)*

arched *planta pedis* flattened as a result of relaxation of the ligaments (*pes planus*).

As in *hallux valgus,* subluxation of the great toe (see p. 238), abnormal articulations develop in advanced degrees of club-foot, and also in mild degree in *pes valgus.* In this condition various depressions and marginal elevations develop, which are not to be interpreted

as simple mechanic displacements, but as absorption processes or new formations.

In growth of the flat bones of the **skull** the sutures and both synchondroses at the base in the long axis of the atlas are to be considered. The sutures are, on the whole, of connective-tissue nature, provide the material for the surface growth of the cranial bones; hence, take the place of the synchondroses of the pelvis. The intersphenoidal synchondrosis is closed at birth, while the spheno-occipital synchondrosis remains open until the 20th year. Both synchondroses may, by too early ossification (premature synostosis), constitute an obstacle to the growth of the cranial base. In order to obtain an idea as to the length of the cranial base, the distance of the *foramen occipitale magnum* from the point of junction of the nose with the *sutura nasofrontalis* is noted. If this measure remains too small in consequence of premature synostosis, the peculiar physiognomy of the cretin results. Growth of the flat bones of the cranial vault always occurs perpendicular to the line of the suture. Disproportionate growth of the individual bones, as well as premature synostosis of the sutures, influences the form of the head.

Fig. 491.—Hydrocephalic skull. Widely gaping fontanelles and sutures. ½ natural size. (After *Langerhans.*)

Excessive growth of the suture substance is always due to mechanic conditions. In rapid increase in the size of the cranial cavity, traction is exerted upon the suture substance; this does not lead to simple distention, but acts as an irritant and causes proliferation, increase of the suture substance. The earlier this pressure and traction are exerted, the earlier broadening of the suture substance, diastasis of the bones, develops. In this manner an increase of substance capable of ossification occurs in hydrocephalus. (See p. 614.) In pathologicly dilated fontanelles independent, island-like bone formations frequently occur: *ossa fonticularia,* fontanelle bones, Wormian bones; these are observed also in dilated sutures: *ossa intercalaria,* intercalary bones.

In ossification of the sutures three possibilities must be differentiated: (1) normal synostosis (of the frontal suture, etc.); (2) senile synostosis, *synostosis tarda,* through which the skull is rendered immovable and very rigid, but otherwise uninfluenced; (3) synostoses which prematurely terminate growth at the locality in question, and, hence, correspond to an undoubted pathologic condition. Premature synostosis of the sagittal suture causes narrowing of the skull and compensatory elongation, when the coronary and lambdoid suture is preserved: dolichocephalus, long head. This form, however, occurs also independently of ossification of the sagittal suture as a racial peculiarity, and, therefore, is not always due to premature synostosis. Premature synostosis of the coronary suture causes shorten-

Fig. 492.—Malacosteon pelvis. (After *Leishman.*)

ing and eventual broadening of the head: brachycephalus, short head.[1] Premature synostoses generally begin in the 5th or 6th year. When compensation is not possible, mental derangements usually occur. The normal capacity of the skull varies between 1100 c.c. and 1600 c.c.; smaller and larger dimensions are pathologic.

Osteomalacia is a disease of developed bone and is most frequently observed in connection with the puerperium, sometimes in old age, seldom in young individuals. It is more frequent in females than in males. It consists in a progressive transformation of compact bone-tissue into marrow-tissue, the tela ossea being previously deprived of lime-salts. Accordingly, osteomalacia is a process which possesses a certain resemblance to osteoporosis. The pro-

[1] Other quite frequent anomalies are: plagiocephalus: oblique skull (from unilateral synostosis of the coronary or lambdoid suture); pachycephalus: thick head (synostosis of the lambdoid suture); hypsicephalus or oxycephalus: pointed head (synostosis of the lambdoid suture and of the occipitomastoid suture).

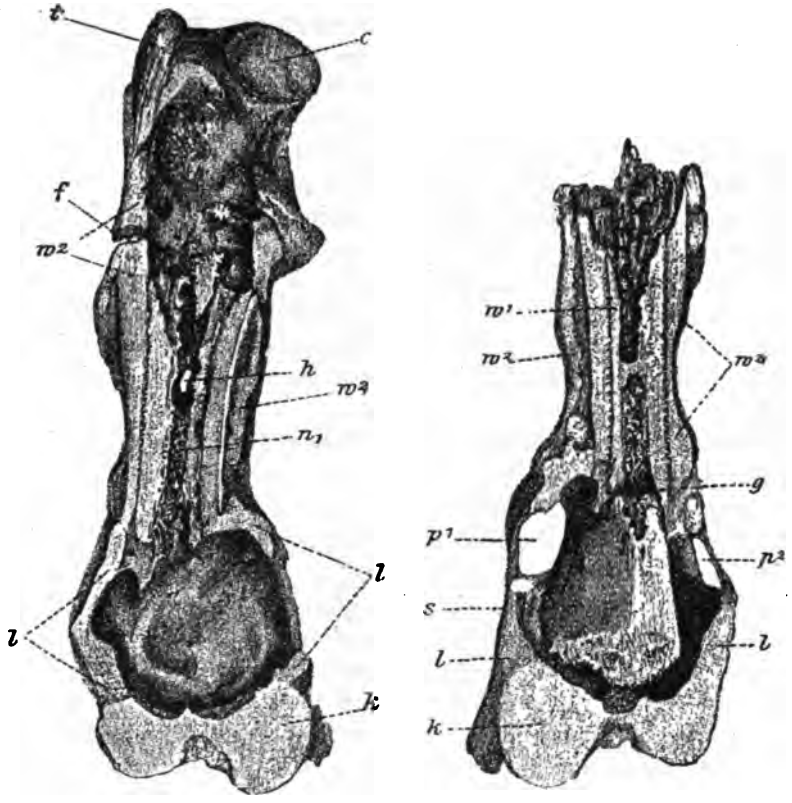

Fig. 493.—Right femur sawed through the middle, from a child 7 weeks old. Natural size. The lower end of the diaphysis forms a sequestrum (*s*) which is loosely connected above with the middle segment of the diaphysis by a granulation layer (*g*). The sequestrum lies in a pus-filled cavity formed by an inner granulation layer, an outer new-formed bony shell (*l*) produced by periosteal proliferation, and partly also by the cartilage (*k*) which is firmly united with the bone (*l*). The bony shell has two large, smooth-walled openings (p^1 and p^2), which communicate with fistulous tracts. In the middle portion of the diaphysis is a small pus-filled cavity (*h*) which on one side communicates with a fistulous tract and on the other with an extensive purulent destruction of the upper third of the femur. The upper third of the femur is almost completely destroyed. The union of the trochanter major (*t*) with the middle third is established essentially by new-formed periosteal osseous proliferation (w^1 and w^2). At *f* is a fracture within the new-formed bone, so that the whole upper third is freely movable against the middle. The head and neck have completely disappeared; the articular cartilage of the head (*c*), comparatively well preserved, is at the same level as the trochanter major. In the middle third of the diaphysis new-formed compact bone lamellæ (w^1 and w^2) are seen upon both inner and outer surfaces of the compact bone. (After *Langerhans.*)

gressive formation of marrow-space leads to increasing diminution of the compact substance; as soon as only a thin layer of bone remains, a high degree of fragility occurs: *fragilitas ossium* (*flexibilitas cerea*). Numerous infractions of the tubular bones, the vertebræ, the sternum, the ribs, and even of the cranial bones develop. When the marrow is red, the process progresses as an inflammatory condition with fever and great pain; when it is yellow, the inflammatory phenomena are lacking and the condition is more of a senile process. In the pelvis the iliopubic and sacroiliac synchondroses are pushed toward the center of the conjugate by pressure of the spinal column and of the thigh, while the symphysis protrudes in beak-shaped form: osteomalacic or malacosteon pelvis. (See Fig. 492.)

Acute purulent processes of the bones start from the periosteum as purulent periostitis or from the bone-marrow: purulent osteomyelitis. The yellow bone-marrow is always transformed into red marrow. In the periosteum the suppuration always begins in the internal layer and rapidly leads to accumulation of pus between the periosteum and bone and to elevation of the matrix from the compact cortic layer. When the pus collects in a closed focus in the bone-marrow, the quite rare bone abscess develops. Such a bone abscess has a separate, smooth wall, which shuts it off from the bone-marrow. This wall is a newly formed granulation layer and, therefore, is called granulation membrane. Periostitis as well as osteomyelitis may occur independently or coexist. Periostitis frequently extends also to the parosteal tissue.

Whenever suppuration destroys the periosteum and comes in direct contact with the compact bone, the bone-tissue dies. If a large portion of bone is deprived of periosteum and thereby of its matrix (of the afferent vessels) by suppuration, the section of bone becomes necrotic *en masse* without alteration of its external form: bone necrosis. A peripheral and an internal, central necrosis are distinguished, according as the dead piece lies at the periphery or at the center.

The term **caries** is likewise employed to designate a necrotic process in bone accompanied by suppuration (*caries purulenta*), in which, however, the dead bone itself or parts of it is not found, because the dead material is at once dissolved, molecularly destroyed, the bone being dissolved in its cell territories under the influence of pus[1] (degenerative ostitis). **Carionecrosis** stands midway between caries and necrosis; in this process small dead-bone trabeculæ and splinters are

[1] *Caries sicca* develops without suppuration, as a result of gummatous proliferation. (See p. 546.)

cast off, for example, in the spongiosa. In its first stages bone necrosis is scarcely recognizable, but when a line of demarkation has formed it offers no difficulties. After long duration the surface of necrotic sections of bone is always smooth, while the carious surface (*caries peripherica*) of living bone is always rough.

In necrosis an ossification layer which becomes an involucrum always develops at the line of demarkation, *i.e.*, when the process has become limited. The dead, completely detached portion of bone is called sequestrum; the pus cavity in which the sequestrum lies, the *cloaca* or *capsula sequestralis*. When the sequestrum is small and located in the depth, it may gradually be absorbed, or a sort of capsule forms. When, however, the sequestrum is somewhat larger or lies more superficially, the pus is discharged externally. In the neighborhood of the

Fig. 494.—Beginning asbestoid degeneration of a costal cartilage. Fibrillation of the basement substance. Fresh preparation. Reduced ⅓. (After *Langerhans*.)

purulent foci new formation of bone always occurs, which may develop from the periosteum as well as from the interior of the bone.

Purulent inflammations of bone develop as the result of the entrance of micrococci (especially streptococci and staphylococci) into the bone (periosteum or bone-marrow).

The changes of the cartilage are active as well as passive; the active are nutritive and formative. The formative are confined essentially to hyperplasia. Exudative processes cannot originate from cartilage, owing to the great poorness in vessels.

The passive alterations are retrogressive metamorphosis. Erosion of the articular cartilage—a flat, superficial loss of substance—originates by fatty metamorphosis of the cartilage cells and gradual softening of the capsules and the true intercellular substance. When this process gradually extends in the depth, it is called ulceration. The difference, therefore, is purely quantitative, not qualitative. When the whole articular cartilage is uniformly altered in this manner, thinning of the whole cartilage results; on the other hand, if only isolated

areas are involved the surface finally becomes uneven. This form of softening is very frequently observed in chronic articular inflammations; it develops also as the result of suppuration and may progress to complete destruction of the cartilage. This destructive process is frequently preceded by proliferation.

In **asbestoid degeneration** the basement substance first segments, becomes filamentous, and finally completely softened, while the cartilage cells proliferate or die by fatty metamorphosis. Fissures or cavities with smooth or nodulated surface, which are filled with fluid contents, thus develop in the synchondroses and costal cartilages. (See Fig. 494.)

Calcification of the cartilage, petrification (see p. 140), begins with deposition of lime-salts in the capsules; the true intercellular substance is not infiltrated with lime-salts until later.

Transformation of the permanent cartilage into bone, ossification (see p. 140), is a quite frequent occurrence, which is observed in advanced age as senile ossification, *e.g.*, in the costal cartilages, and also as a sequela of inflammations as inflammatory ossification. Ossifications of the laryngeal and tracheal cartilages in chronic laryngitis and tracheitis, vertebral synostoses in carious processes and in healing of spondylarthrocace, and synostoses of the cranial bones in inflammatory states of the cranial envelopes not infrequently develop, even in young individuals.

Ostitis deformans (Paget), **osteomyelitis fibrosa** (von Recklinghausen), is a chronic affection generally involving a number of bones (skull, vertebræ, clavicle, femur, etc.), especially the long bones of the leg, most frequently the tibiæ. It usually attacks individuals beyond the 40th year, and is characterized by gradually increasing thickening, due to resorption and hyperplasia, which result in nodular deformity and often bending, the latter affecting especially the bones of the spine and legs. According to Stilling, resorption occurs as in rarefying ostitis, the new formation of bone, which remains uncalcified for a long time, originating from the periosteum and bone-marrow. According to von Recklinghausen, the process begins as osteomalacia with marked destruction of the tela ossea; the fat- and lymphoid marrows are then transformed by an inflammatory process into fibrous tissue: *osteomyelitis fibrosa osteoplastica, endostitis hyperplastica,* resulting in the production of a large amount of noncalcified bone in which focal softening and cyst formation may occur.

B. Vasek[1] describes an example of Paget's disease in a man aged 68 years in whom the disease began in one extremity and produced thickening and protrusion

[1] Fortschritte der Medizin, Dec. 8, 1910, p. 1556.

of the tibia and elongation of the whole leg. Radiographic examination of the whole skeleton and microscopic examination of a piece of bone excised from the tibia led the author to the following hypothesis of the origin of the malady. From some cause or other (*e.g.*, excessive labor) there occurs in the bone an active hyperemia which, owing to obstructed outflow of blood, is converted into a passive hyperemia. As a result, an increased resorption of bone, especially of the compact substance, and transformation into desmoidal connective tissue (analogous to cyanotic induration of the liver or spleen), from which spongiose bone-tissue then develops, occur from the bone-marrow. To compensate for the altered bone structure the organism reacts to the resorption and the resulting softness of the bone by overproduction of bone from the periosteum. In the case cited arteriosclerosis, defective nutrition, and congenital disposition (the patient was the premature child of a consumptive) may have been the cause of the biologic alteration of the bone substance.

Fig. 495.—Arthritis deformans with broadening of the knee-joint surface of the right femur, from a laborer aged 49 years. In addition to erosion of the cartilage, there are proliferations, especially at the margins of the articular surface. ⅔ natural size. (After *Langerhans*.)

In **arthritis deformans** (formerly called *arthritis pauperum*) all constituents of the joints (cartilage, synovialis, ligaments) may be involved; even the adjacent portions of the bone and the surrounding connective tissue are altered. The process often begins passively with erosion and attrition of the cartilage surfaces; irritative and true inflammatory complications always occur later and are often present also from the outset. The cartilage begins to proliferate (see p. 230) and sometimes to ossify, is again eroded until finally the *lamina terminalis* of the bone is laid bare. Then an osteosclerosis begins, which produces a porcelain-like state of the bone. With this are associated bone proliferations, exostoses, which may develop into large tumors and surround the joint surface in wreath form. Villous, lipomatous excrescences develop at

the point of reflection of the synovial membrane, which likewise embarrass movement of the joints. When exudative processes are added these are always indicative of an acute exacerbation, for they not infrequently are the beginning of true adhesive inflammation which finally results in fibrous ankylosis. On the other hand, for example, a condyle may become so small or be so markedly deformed by attrition and atrophy that luxation finally occurs.

In **acute rheumatic articular inflammations** (*arthritis multiplex*) the synovialis[1] is swollen and hyperemic and its viscid secretion often scarcely increased; in other cases the secretion is increased in amount and thinner than usual, or markedly increased and watery: **hydrarthrosis,** or the synovialis is covered with fine, delicate fibrin flocculi: *arthritis fibrinosa, hydrofibrinosa.* In some cases this process is accompanied by hemorrhages into the joint: hemorrhagic arthritis; then, in addition to fibrinous masses, fresh extravasate or also pigment masses are found. The hemorrhagic process has a great tendency to recur, so that besides fresh blood masses and fibrin coagula older vascular adhesions and old blood-pigment also are observed. More frequently, however, the hemorrhagic contents of a joint, **hemarthrosis,** are referable to traumatism. The fibrinous inflammations result in cord-like and flat adhesions of the joint surfaces.

Goadby[2] has studied the etiologic relation of bacteria of the mouth to rheumatic arthritis, and in cases in which such a relation could be assumed the virulence of pure cultures of oral bacteria was tested upon rabbits by intravenous, subcutaneous, and peritoneal injection. Arthritic manifestations were observed, however, only when cultures were injected into the joints or periarthritic tissue of animals which, tested with the patients' serum, showed an alteration of the opsonic index. A few strains caused chronic swellings of the synovial membranes, and in several cases even marked osseous alterations. In 3 cases palpable nodules occurred also in bone which bore no direct relation to the injected joint. In animals which died in from two to three months after injection, the same bacillus could repeatedly be found in the heart-blood. Other modes of injection produced no arthritic symptoms. The strains were a streptobacillus (*"streptobacillus malæ"*) which morphologicly resembled the Ducrey bacillus, but culturally a streptococcus. Vaccination of the patients with the bacillus obtained from the oral cavities produced improvement or cure after primary increase of the articular symptoms. The oral affections which cause rheumatism may originate either from the teeth or be independent of these. Dental caries, which may occur especially in filled teeth; remaining roots, teeth with defective crowns, and bridgework should always be investigated. Prosthesis also may cause inflammation and chronic suppuration or obscure existing suppurating foci. Far more important than diseases of the teeth are suppurative processes of the gums and periosteum, classed under the term *pyorrhœa alveolaris.* Tooth extraction usually does not relieve the suppurative con-

[1] This stands about midway between the serous and the mucous membranes.
[2] The Practitioner, vol. lxxxviii, 1912, p. 107.

dition, because the maxilla itself may be infected beneath the teeth. Goadby therefore recommends vaccine therapy, which is said to be attended by good results.

In the purulent form: **purulent arthritis,** the synovialis is erysipelatous-swollen, opaque, and covered with pus. In this condition the cartilage at first remains passive and in the beginning is also unaltered. The exudate is formed only by the synovialis. In purulent inflammation, however, the cartilage soon changes its ordinary character, in that it is partly dissolved by the direct action of the pus upon the surface and cellular proliferation and disintegration of the intercellular substance, partly transformed into vascularized connective tissue. The softening occurs chiefly at the points of pressure and erosion. Sometimes, especially in very violent, malignant, and putrid cases, the cartilage becomes necrotic and is cast off in larger pieces. Small and large fragments of cartilage are then found in the joint cavity, within the purulent or ichorous exudate.

Joint affections occurring in scarlatina may, according to Fritsch,[1] be divided into two forms: 1. *Arthritis scarlatinosa serosa:* (*a*) a mild inflammation of the synovialis with or without slight, transitory serous effusion; (*b*) inflammations with abundant serous effusion with chronic course. 2. *Arthritis scarlatinosa purulenta,* due to mixed infection. The two first forms are due solely to the unknown scarlatinal excitant, are usually benign, heal spontaneously, and, therefore, rarely come into the hands of the surgeons. The purulent arthritis, on the other hand, is a mixed infection with streptococci upon the basis of an articular synovialis injured by the scarlatinal virus. This form is purely surgic. Arthritides as a complication of rubeola are very rare and present the same features as the scarlatinal forms.

When the cartilage is destroyed and the bone laid bare, attrition, erosion of the terminal compact bony layer and later also of the spongiosa occur. In **purulent coxitis** enlargement of the socket (acetabulum) and diminution of the head of the femur with shortening of the affected extremity, and under certain circumstances also luxation of the diminished head of the femur, thus develop. The purulent process may extend through the pelvis to the peritoneum, or to the gluteal muscles, producing phlegmonous inflammation.

According to Kienböck,[2] at the acme of gonorrheal arthritis in the hand, the X-rays show a marked transparency of the carpal bones, the structure and contour of which are indistinct. According to the distribution of the process, 3 categories are differentiated: *a,* the affection is either confined to the second to fifth carpo-

[1] Bruns' Beiträge, Bd. 72.
[2] Paris méd., 1912, pp. 138-141.

metacarpal joints; or, *b*, all carpal bones and the proximal ends of the second to fifth metacarpal bones, or, *c*, also the lower end of the radius, are involved. The carpometacarpal joint of the thumb and the joint of the pisiform bone are always free, because they have isolated joints. These two joints are also always exempt from an osseous new formation which usually starts from the diaphysis of the radius and extends forward to the carpometacarpal joints. In severe cases there is a distinct transparency of the metacarpal and finger bones which begins in the spongiosa and extends to the diaphyseal cortex. It is caused by atrophy of the affected bones, due partly to inactivity, partly to irritation of the adjacent inflammation. The same deformations occur in other joints. In the knee-joint complete destruction of articular cartilage and synostosis between femur and tibia are very frequent; then two groups of lines, which run from the outer and inner sides of both condyles of the femur, are usually recognizable and consist of new-formed spongiosa. At the same time there is genu recurvatum, due to subluxation of the tibia backward; the patella is thus drawn downward and backward and grows to the under surface of the femur. In children these alterations are usually attended by limitation of growth.

All dislocations between articular surfaces are called **luxations**. These are either entirely (complete luxation) or only partly separated from each other (incomplete luxation). When incomplete luxation occurs slowly, the question is one of subluxation. Every complete and incomplete luxation in a strict sense occurs suddenly, *uno actu*. In complete luxation the articular capsule is always torn. If the luxated part is not replaced, the capsular rent heals by gradual diminution. Three *sedes morbi:* (1) the articular surface of the vacated joint, (2) the articular surface of the dislocated joint, and (3) the new environment of the dislocated joint surface, are thus produced. The surface of the vacated joint atrophies and shrinks, somewhat like, *e.g.*, an empty tooth alveolus; the cartilage gradually disappears, and the whole joint becomes smaller, filled with proliferations. Similar processes occur in the dislocated joint surface. In addition to the atrophy, partial sclerosis is observed. When the dislocated part is surrounded by soft tissue, it acquires a fibrous capsule; if, however, it touches a bony structure, a new, but imperfect articular surface develops which the more closely resembles the true articular surface the earlier the luxation ensued. In so-called **congenital luxation of the hip**, which occurs during birth, the best re-establishment of a new joint is observed. In subluxation also those parts atrophy which have been placed in disuse, while at the new points of attrition a kind of joint is established.

Spastic luxation of the hip-joint. H. Weber[1] examined radiographicly 18 children with hypertonia of the musculature. In one child who had chronic hydrocephalus that had developed in earlier childhood,

[1] Münch. med. Woch., 1911, No. 15.

the chief symptom was spasm of the lower extremities; another child had idiocy with spasms of all extremities; a third, infantile spastic hemiplegia. The remaining 15 had Little's disease. In all these 18 cases there were a very marked number of pathologicly altered hip-joints. Of 30 different joints only 13 were of normal configuration. In the abnormal joints there were 4 complete luxations, 2 subluxations, and a number of less marked alterations which, in addition to the position of the head of the bone, had involved chiefly the bony socket. It is probable that the different degrees of joint changes correspond to different developmental stages of luxation.

Fig. 496.—Osseous ankylosis of the right knee: synostosis femoris et tibiæ. Continuous marrow-space. Woman aged 75 years. *F*, femur; *T*, tibia; F_1, fibula. ⅔ natural size. (After *Langerhans.*)

Ankylosis signifies firm, immobile, organic union of articular surfaces. The union may be by fibrinous tissue: fibrous ankylosis, or by osseous tissue: bony ankylosis, rarely and, as a rule, only partially by cartilage: cartilaginous ankylosis. In all cases ankylosis is the result of inflammatory disturbances, principally of fibrinous arthritis. The fibrinous exudate is produced only by the synovialis and chiefly at the fold or reflection. Therefore, agglutination and adhesion also begin in the periphery of the true articular surfaces. From there, however, the process advances toward the center to the true articular surfaces, the cartilage being partly converted into connective tissue (isolated islands of cartilage are found in almost every fibrous ankylosis). When the adhesions occur early—before puberty—there is always an arrest of development of the affected side, through cessation of growth, in the pelvis, *e.g.*, the synchondroses ossifying prematurely. In adhesion of the acetabulum with the head of the femur, oblique pelvis results. (See Fig. 487.)

In contrast to true ankylosis stands false ankylosis (pseudoankylosis), which consists not in adhesion of the articular surfaces, but only in fixation of the joint by shortening of the articular ligaments, strong cicatricial contractions, etc.

Of the **tumors** which start from bone, two groups may be differentiated according as they develop from the surface—most frequently from the periosteum—or from the inner portions: the marrow and the spongiosa. In the latter, as a rule, the softening of the firm, compact bone substance and synchronous deposition of new lamellæ upon the external surface, through irritation of the periosteum, occur from within outward. The bone may thus increase considerably in bulk (*spina ventosa* of the ancients). The most frequent tumors[1] are sarcomata (periosteal and myelogenous), osteosarcomata, osteomata, chondromata, seldomer myxomata and carcinomata, sometimes fibromata (in the region of the oral cavity and of the nasopharynx as fibrous polypi), seldom angiomata, cysts (probably the result of metamorphosis of myxomata and cartilage islands).

Among the metastatic tumors is to be named first of all carcinoma, which occurs in the form of countless tumor-nodules which are often not recognizable externally, but generally contrast more or less distinctly with the surrounding intact bone-tissue by their difference in color and consistency. In other cases these metastases form large, externally visible nodules with softening of the bone substance. In addition to diffuse carcinomatosis of the bones,[2] in which, as a rule, the primary tumor cannot be found, there is a similarly progressing diffuse sarcomatosis, which is either confined essentially to the bone, especially the bone-marrow, or forms multiple nodules also in the internal organs.

Tumors of the bones, primary and metastatic, are the most frequent cause of so-called spontaneous fracture.

Echinococci not very frequently and cysticerci seldom occur in the bone.

---

[1] Compare Sarcoma, p. 248; Osteoma, p. 235; Chondroma, p. 232; Myxoma, p. 228; Fibroma, pp. 216 and 224; Angioma, p. 264, and Carcinoma, p. 302.

[2] See tumors of the prostate, p. 873.

MUSCLES, TENDONS AND TENDON-SHEATHS, BURSÆ.

In simple muscle irritation, as occurs, for example, in the region of ulcers, there is proliferation of the nuclei in the primitive bundles (of the perimysium), analogous to the increase of nuclei in growing muscle.

Fig. 497.—Zenker's waxy degeneration of the musculature. Fresh fragments from the rectus abdominis muscle of a woman. (Apoch., 16; Comp. Ocul., 4. After *Langerhans.*)

Inflammation of the true muscle substance, *myositis parenchymatosa,* always begins with swelling of the primitive bundles; the muscle in this stage is firmer to the touch, paler in color, and appears homogeneous, lusterless, and compact. When the process is very acute the muscle becomes more opaque and friable, the transverse striations disappear, the primitive bundle disintegrates into irregular, almost homogeneous, frequently somewhat glistening fragments and clods; finally, softening occurs, the perimysium disappearing. This is observed in so-called **waxy degeneration** (Zenker), *degeneratio cerea,* in the region of hemorrhagic infarcts of the musculature, suppurations, and tumors. (See Fig. 497.)

If the process is less acute, the stage of cloudy swelling is followed by fatty metamorphosis. Minute fat-puncta[1] appear, which at first are irregularly distributed, but gradually become arranged in transverse lines corresponding to the transverse striations. By enlargement of the fat-puncta, small fat-droplets develop, which are easily recognizable also without addition of caustic soda, and, corresponding to the course of the fibrillæ, are arranged in longitudinal (rosary-like) rows. In this condition the primitive fibrillæ disappear. The fatty material is absorbed, sometimes after the small fat-droplets have coalesced to somewhat larger drops. The fatty metamorphosis usually begins in the form of maculæ; it may, however, from the beginning extend uniformly over large areas, *e.g.*, in phosphorus poisoning and severe infectious diseases. Such a muscle has a strikingly cloudy appearance and a pale, yellow-red color.

Waxy and fatty metamorphosis are frequently found to coexist in the same muscle. The latter is *in toto* less resistant, and in strong tension, rapid movement, etc., may rupture. Hemorrhage, so-called **muscle hematoma,** then develops. (See p. 214.)

In contrast to secondary inflammatory fatty metamorphosis of the muscle stands the primary form, which is not preceded by a stage of cloudy swelling. Primary fatty metamorphosis is the result of nutritive disturbances and inactivity (*e.g.*, in ankylosis). In place of parts destroyed by fatty metamorphosis fat-tissue or connective tissue appears, which sometimes has a tendinous character: *macula tendineæ* of the muscle substance.

Acute interstitial, purulent inflammation of the muscle starts from the vessels and the interstitial connective tissue. Like by far the great majority of all parenchymatous myositides of a secondary nature, it is a propagated (phlegmonous) or metastatic affection (glanders, sepsis, etc.). In the beginning the muscle parenchyma may be entirely intact; within a short time, however, changes which belong in the category of parenchymatous inflammation (swelling, clouding, fatty metamorphosis, disintegration) are regularly found. Sometimes all the muscular tissue is destroyed over large areas, and a muscle abscess develops. According to the nature of the pathogenic agents (bacteria, etc.), the pus is sometimes creamy, greenish yellow, sometimes more liquid, dirty grayish red, sometimes stinking, putrid in character.

A chronic interstitial inflammation of the muscle with destruction of the parenchyma occurs protopathicly (primarily) only in syphilis; deuteropathicly (secondarily) as a frequent sequela of other affections, and in atrophic changes. It consists in progressive increase of the con-

[1] Owing to the still partly preserved transverse striations, these are distinctly recognizable only on addition of caustic soda.

nective tissue with subsequent cicatricial contraction and atrophy of the parenchyma. This results in the formation of muscle scleroses.

In this category belongs *caput obstipum musculare,* muscular, stiff, or **wry-, neck** (*torticollis*), which is due to contraction of the sternocleidomastoid muscle. The contraction is frequently due to strain and trauma during birth; hence, is most frequently traumatic in origin. An infectious etiology is rarer, though an infectious process is sometimes associated with trauma.

A rare affection of the voluntary skeletal musculature is **myositis ossificans.** In this condition spongiosa-like, partly spiculate bone masses are formed in the intermuscular connective tissue. New formation of bone is preceded by inflammatory phenomena associated with pain in the affected groups of muscles; these are next followed by fibrous degeneration, under the action of which the parenchyma atrophies. Bone formation is always accompanied by shortening of the muscles, so that, *e.g.,* in ossification of the masseter muscles the teeth of both jaws are brought in contact. This disease begins in youthful individuals and has a progressive character, advances with numerous exacerbations, and finally terminates in death.

Tsunoda[1] transplanted finely divided fragments of periosteum into the musculature of the upper extremity and thigh of young rabbits. After two weeks 6 out of the 40 animals employed showed intramuscular formation of cartilage and bone. Independent parosteal bone formation, therefore, may occur in muscles, adipose tissue, etc., from even minute traumaticly displaced fragments of periosteum. In a second series of experiments only the cells obtained by scraping the inner surface of the periosteum were used. As all 40 experiments were negative, it would appear that osteoblasts detached from their matrices are incapable independently to produce either bone or cartilage.

Hypertrophy of the musculature is the result of strenuous work (but not overexertion) and is, therefore, usually designated as labor hypertrophy. (See p. 110.)

Pseudohypertrophy consists in augmentation of the bulk of the musculature, which, however, unlike hypertrophy, is not due to increase of contractile substance, but to interstitial development of adipose tissue. Rows of fat-cells form between the primitive muscle-bundles by metaplasia of the interstitial connective tissue. The stronger this development of fat-cells, the more the true parenchyma suffers and atrophies.

All processes which cause diminution of the contractile substance are designated as **atrophy of the muscle.** The following are differentiated: first, fatty or necrobiotic atrophy (*i.e.,* the above-mentioned fatty metamorphosis after inflammations, in nutritive disturbances and in-

[1] Virchow's Archiv, Bd. 200, p. 93.

activity); second, simple atrophy with diminution in the size of the primitive muscle-bundles (in consequence of defective or temporarily complete cessation of use, *e.g.*, in firm bandaging; in advanced age as senile atrophy), and, third, atrophy in proliferation of the interstitial tissue.

The last form corresponds to the state in progressive muscular atrophy. In this condition two forms can be distinguished: the so-called spinal (in affections of the spinal cord with degeneration of the anterior horns), and that in which no changes are demonstrable in the spinal cord, which begins primarily in the muscle: idiopathic form.

From the interstitial connective tissue of the musculature develop most frequently sarcomata and fibromata, seldom myxomata, lipomata, chondromata, osteomata. Metastatic carcinoma nodules are of frequent occurrence.

Most important of the parasites are trichinæ. (See p. 362.) Cysticerci frequently occur, rarely echinococci.

The affections of the **tendon-sheaths** resemble most the changes of the synovialis. There is a serous, fibrinous, and purulent tendovaginitis. In the fibrinous form the surface is dry and slightly reddened. Purulent inflammation of the tendon-sheaths has a tendency to spread very quickly and usually leads to destruction of the tendon-sheath and tendon. In all cases the inner surface of the tendon-sheath is very slightly reddened and, as a rule, somewhat mottled. The acute exudative forms are sometimes followed by adhesion of the sheath to the tendon. Purulent inflammations of the tendon-sheaths are always propagated or metastatic processes, while the serous and fibrinous forms occur also spontaneously as so-called rheumatic inflammations.

While **tuberculosis** of the tendon-sheaths usually is the result of extension from bone or joint affections, it may occasionally be primary. The process often extends along the tendon for a considerable distance. It may occur in the form of miliary nodules or of diffuse caseating granulations. In tuberculous affection the formation of *corpora oryzoidea* is especially abundant and frequent.

Inflammation of the bursæ (bursitis) is most frequently observed in *hygroma præpatellare* in front of the knee-pan, seldomer in other bursæ, *e.g.*, in that over the metatarsophalangeal joint of the great toe. In front of the knee, fist-sized swellings may develop, which, however, only rarely undergo suppuration.

So-called **ganglion** or **synovial tumor** (*hygroma gangloides*) develops, like the bursæ, as a result of atrophy in localities subjected

to frequent pressure and friction, being preceded by the formation of fissures or spaces in the tissue. A unilocular ganglion may develop from a number of adjacent spaces—*ganglion multiloculare*—by progressive atrophy of the intervening tissue—the partitions and trabeculæ. A fluid which is sometimes thin and watery, sometimes viscid like the synovia, collects in the atrophic spaces and fissures and sometimes slowly, imperceptibly, in the true bursæ, sometimes very rapidly, almost suddenly, in the so-called ganglions, especially upon the back of the hand and foot. The secretion of fluid is always of an irritative nature, *i.e.*, the product of an irritation which, in many cases, is due to external mechanic or traumatic influences. The rapidity of accumulation of the fluid explains why ganglions so frequently are assumed to originate as a result of rupture of the tendon-sheath, or bursa or of protrusion of the synovialis. In fact, there is in some cases a communication between the hygroma and a tendon-sheath or a joint cavity; as a rule, however, this is a secondary phenomenon due to the fact that the hygroma secondarily—*i.e.*, after its formation—communicates with the tendon-sheath or joint cavity. Protrusions of the joint cavities with subsequent constriction of the protruded synovialis may occur also, but are rare. In this case the surface of the constricted sac has the character of the synovialis.

Analogous to *bursa præpatellaris* between the skin and the patella, a *bursa mucosa præossea* frequently forms in amputation stumps in the same manner as in hygroma.

The more slowly the fluid collects in the atrophic fissures, the more viscid it usually is, and, the quicker it accumulates, the more watery its character. After long duration the tissues surrounding the ganglion gradually thicken, so that the fluid finally is inclosed in a very firm and often very thick, frequently smooth-walled capsule. Connective-tissue proliferations (*hygroma proliferans*), which have a very dense, almost cartilaginous consistency, are frequently pedunculated, and then are easily liberated by constriction, sometimes secondarily originate from the walls of hygromata and of the tendon-sheaths, which, moreover, develop in the same manner as *bursa præpatellaris*. These constricted fibrous structures constitute the free bodies (*corpora libera*) or the rice grains (*corpora orizoidea*) of the tendon-sheaths and of hygromata (so called because of the external resemblance to rice grains). The irritative character of hygromata is very distinctly manifest in this proliferating form.

A prepatellar hematoma may develop from a hygroma or a bursa, *e.g.*, prepatellar bursa, as a result of trauma which leads to hemorrhage.

Sometimes ganglions, like the bursæ, are the seat of true inflammation; this may be simple in nature and after a time disappear, or it terminates in suppuration, or becomes chronic.

Besides the fibromata mentioned (*hygroma proliferum*), primary tumors very seldom start from the tendon-sheaths and bursæ. On the other hand, these parts may occasionally become secondarily involved by extension of other tumors from the neighborhood.

THE SKIN.

THE external skin consists of the epithelial layer (epidermis, or scarf-skin), the cutis or corium, and the subcutaneous connective tissue.

In the epidermis the basal layer is composed of a zone of perpendicularly arranged cylindric epithelium. This is followed by the *stratum spinosum,* composed of polyhedral cells held together by delicate protoplasmic processes or spicula, so-called prickle cells. The next layer is composed of flattened

Fig. 498.—Section through human epidermis; the deeper layers of the stratum Malpighii are not shown. × 750. (After *Böhm-Davidoff.*)

cells with granular protoplasm: *stratum granulosum.* The cylindric, spinous, and granular layers constitute the so-called *stratum Malpighii,* or *rete mucosum.* The superficial layer consists of squamous hornified cells, which form the *stratum corneum,* or horny layer.

The corium, or true skin, lies immediately beneath the epidermis and is divided into two layers: the upper, called the *cutis vasculosa* or *stratum papillare,* and the lower, the *cutis propria.* The corium contains sebaceous and sweat- glands and roots of the hairs and their sheaths.

The *cutis vasculosa,* which is composed of a reticulum of collagenous connective-tissue fibers interspersed with elastic fibers, sends papillæ into the epidermis, and is richly supplied with vessels and nerves, particularly in the papillæ. The epithelial prolongations filling the depressions between the papillæ, although they form a reticulum, are called *epidermis papillæ.*

The *cutis propria* is made up of a network of connective-tissue bundles so arranged as to form elongated spaces, the long diameter of which is parallel with the direction of tension of the skin. The connective-tissue bundles are surrounded by a reticulum of elastic fibers.

The epidermis and *cutis vasculosa* are designated by Kromayer as "parenchymatous skin," in contradistinction to the *cutis propria.*

The subcutis, or subcutaneous tissue, consists of collagenous connective-tissue and elastic-tissue fibers arranged in a loose, wide-meshed reticulum, in the spaces of which are more or less numerous adipose-tissue cells.

While up to the middle of the past century cutaneous diseases were usually regarded as symptoms of internal diseases, false blood mixture, etc., Hebra defended the view that, as a rule, they should be interpreted as independent affections originating from external noxæ. Today we again occupy the position that large groups of skin diseases are due to the existence of internal diseases, metabolic anomalies, and disturbances of internal secretion. For example, diabetes may produce disposition to furunculosis; nephritis to eczema. According to Zumbusch,[1] the most interesting cutaneous alteration in diabetes is xanthoma, manifested by the development, which often is very rapid, of small, bright-yellow nodules upon the skin. Their formation is due to the fact that, under certain conditions, normal cells of the skin degenerate and become infiltrated with cholesterin. It is not a neoplasm. Xanthoma has no connection with the excretion of sugar; it is observed also in diabetes insipidus and in liver affections (*xanthoma hepaticum*). While little is known of the influence of uric acid diathesis, uric acid depositions occur in rare instances in the skin. All that has been recorded upon the relation of gout, rheumatism, to skin diseases is hypothetic. In psoriasis joint affections are observed in addition to the exanthema, though these do not correspond to the character of uratic gout, but to the picture of arthritis deformans. In regard to disturbances of internal secretion, which recently have been called upon to explain the origin of certain skin affections (*e.g.,* Addison's disease, scleroderma), Finger[2] advances an opinion somewhat at variance from the prevailing view. He assumes that every gland with "external secretion" elaborates, besides its products, also waste products from the blood, the absence of which function on failure of gland activity must be followed by disturbances in other organs, *e.g.,* also in the skin. Furthermore, experiments recently have been made to explain the long-known *urticaria ex ingestis* as an anaphylactic phenomenon. (See p. 324.) The connection is most clear between cutaneous manifestations and disturbances of the internal constitution in dermatoses

[1] Die Heilkunde, 1911, No. 10.
[2] Wien. klin. Woch., 1912, No. 25, pp. 23-25.

of pregnancy, such as impetigo herpetiformis, etc. It has also recently been found that these severe dermatoses can be cured by injection of serum from normal pregnant women. The nutrition and resistance of the skin are in great measure dependent upon the proper function of the blood-glands: note, for example, the extensive pigmentation in Addison's disease. In diseases or absence of the thyroid gland the thickening and discoloration of the skin known as myxedema originates; scleroderma also is dependent upon disturbances of the thyroid gland. The skin of castrated subjects is thick, flabby, and yellowish. The functions of the female genitalia especially provoke disturbances of various types: *e.g.*, herpes menstrualis, cutaneous pruritus during gestation, urticaria, herpes gestationis, impetigo herpetiformis. Abnormal states of blood are manifested in the nutrition of the skin: lymphatic leukemia and pseudoleukemia may produce cutaneous symptoms (tumors, pruritus, prurigo-like exanthema).

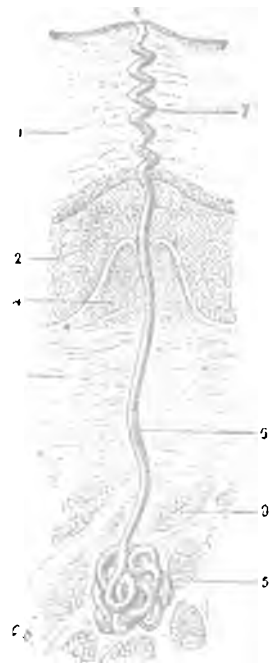

Fig. 499.—Sweat-gland. 1, epiderm; 2, Malpighian layer; 3, derm; 4, papilla; 5, gland folded on itself; 6, duct of gland; 8, opening of duct; 9, subcutaneous tissue. (After *Hedon.*)

Every **hyperemia** of the skin disappears almost completely after death, *i.e.*, it is replaced by anemia. In hyperemia of long duration, increase—hyperplasia—of the epidermis and exfoliation of the hornified epidermis scales occur. Furfuraceous desquamation— bran-like desquamation (in morbilli, pityriasis, prurigo), membranous desquamation—and skin-like exfoliation (in scarlet fever, psoriasis, erysipelas) are distinguished.

Hemorrhages of the skin (hemorrhagic infiltration of the cutis) are recognizable under all conditions, even after death, and, unlike the hypostatic cadaveric maculæ, cannot be displaced by pressure with the finger. Small, punctiform hemorrhages are called petechiæ; striate hemorrhages, vibices; diffuse hemorrhages, ecchymoses and suggillations. The hemorrhages develop as the result of trauma (crushing with rupture of small vessels), in infectious diseases (scarlatina, ulcerative endocarditis), intoxication (phosphorus, iodine), in bleeders, pernicious anemia, scorbutus, etc. Many nontraumatic cutaneous hemorrhages are classed under the name purpura (*morbus maculosus, purpura senilis,* etc.).

Hyperemic and hemorrhagic states lead to the formation of pigment (yellow-brown blood-pigment).

In **hypersecretion** of the sebaceous glands of the skin seborrhea develops—either *seborrhœa oleosa* or *squamosa*. In the latter case the secretion product of the sebaceous glands mixes with desquamated hornified scales and leads to bran-like desquamation, which in some localities, *e.g.*, upon the hairy portions of the head, may be very profuse. This seborrhea of the scalp (*seborrhœa capillitii*) is usually associated with phenomena of irritation, especially swelling and redness and sometimes also exudation, which often results in agglutination of the hairs.

Hyposecretion of the sebaceous glands (in elephantiasis, etc.) renders the skin dry, inflexible, and brittle; fissures (*rhagades*) readily develop.

Comedones, blackheads, develop as a result of increased secretion and retention of epidermoidal cells and fat (sebum) in the upper portion of the hair follicles (*folliculi pilorum*); these are sausage-shaped, quite dry masses which can be expressed, and are stained black upon the proximal end by dust and dirt. Accumulation of these masses in the lower portion of the hair follicles produces milia, skin sand, cutaneous calculi. **Milium** is a small, whitish, sometimes glistening, mother-of-pearl-like, noninflammatory nodule, about the size of a poppy seed, occurring in localities where the skin is thin—*e.g.*, on the eyelids, face, forehead—and possesses fine lana hairs with short hair follicles. Within the milium the epithelial cells are frequently concentricly lamellated. Milia are found in most people (usually elderly individuals). The point of predilection is the nose and its immediate neighborhood. They may undergo calcification and then give rise to the so-called cutaneous calculi.

Atheroma, sebaceous tumor, wen, sebaceous cyst, usually develops from a milium by intense accumulation of epidermis cells and sebaceous material in localities where the skin is especially thick, namely, upon the hairy portions of the head (scalp). Atheromata usually attain the size of a walnut and then are very prominent. The pressure exerted by them upon bones may produce erosion of the latter. The pap-like or gruel-like contents of atheroma (ἀθέρωμα = gruel, pap tumor) are composed principally of epidermis cells, but contain also fat-masses and generally fat-crystals and cholesterin. The fat and the cholesterin crystals formed therefrom are derived partly from the sebaceous glands. Complete occlusion of the hair follicles very frequently occurs in connection with atheromata as a result of inflammatory swellings and retractive processes of the skin. Sebaceous cysts may develop also from portions of displaced skin in the corium or the *panniculus adiposus*. The walls of the latter

have the same structure as the skin, while the first-mentioned atheromata, which develop from the ducts of the sebaceous glands and hair follicles, have a perfectly smooth connective-tissue wall lined with a lamellated layer of flattened epithelium. Atheromata, especially of the scalp, not infrequently undergo ulceration and carcinomatous—epitheliomatous—degeneration, especially if they are constantly subjected to mechanic irritation. Therefore, early extirpation should be urged.

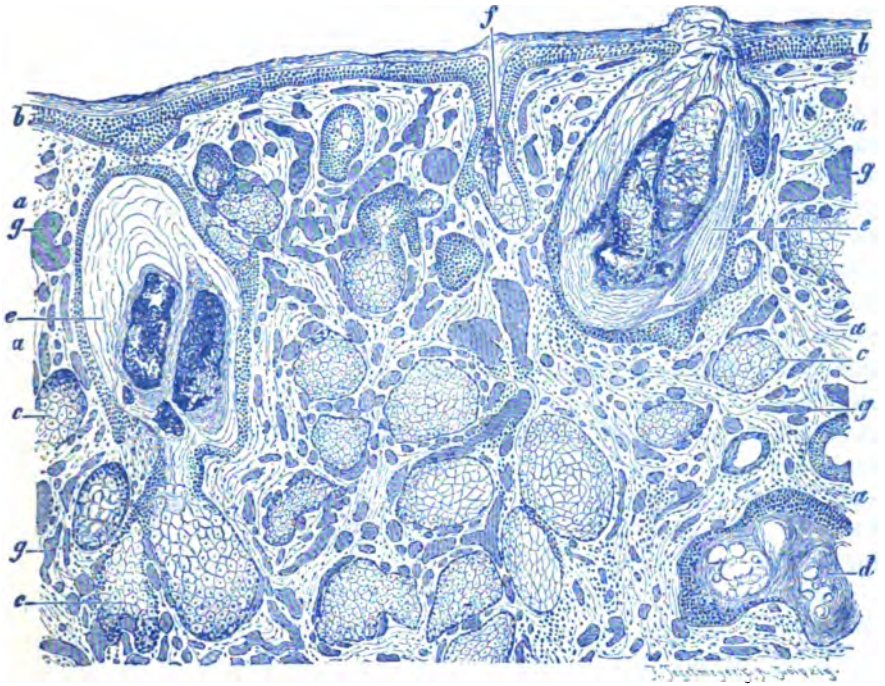

Fig. 500.—Acne rosacea (rhinophyma). Section through skin of the nose. *a*, corium, focally infiltrated with cells; *b*, epidermis; *c*, sebaceous glands; *d*, same containing epithelial squamæ; *e*, dilated excretory ducts of sebaceous glands filled with hornified epithelium and bacteria; *f*, demodex folliculorum in an excretory duct of a sebaceous gland; *g*, filled blood-vessels. × 45. (After *Ziegler.*)

Accumulation of epithelial masses may be accompanied by phenomena of irritation, resulting in inflammation and suppuration of the hair follicles and the sebaceous glands; smaller and larger red nodules and pustules develop, which present the clinic features of **acne** (*acne rosacea* of the nose: Burgundy nose). In *acne rosacea* there is redness and thickening of the skin, resulting from hyperemia due to ectasis of the vessels. Acne occurs also after application of irritant drugs to the skin,

and after ingestion of certain medicaments (iodides, bromides). The inflammation accompanying deeply seated milia is usually attended by a hard infiltration of the skin (*acne indurata*).

A small cutaneous tumor, about 4 mm. in diameter, was found by Sehrt[1] to be a calcified simple dermoid cyst of the skin in the lime masses of which osseous and bone-marrow formation had occurred. Here and in other forms of bone formation in the skin—ossification of calcified retention cysts of the cutaneous follicles, occurrence of true bone formation in tumors (lipomata, lymphangiomata, etc.) of the skin, in chronic inflammatory processes, in so-called adipose-tissue stones—there is always primary tissue necrosis with secondary calcification followed by metaplastic bone formation from connective tissue.

Anasarca, or **hyposarca,** is due to serous infiltration of the subcutaneous tissue. In this condition the skin is swollen and either (1) firm, elastic ("elastic edema") or (2) doughy in consistency and pits on pressure. In the former case the structure of the subcutaneous tissue is loosened (porous) and the fluid can readily be displaced by pressure. Anasarca occurs as congestion edema in general or local circulatory disturbances, and as dyscrasic and fluxional edema. So-called papillary edema occurs in circumscribed form and causes flattened elevations (edematous papules, wheals, *e.g.,* in urticaria) of the skin which gradually slope off to the level of the surrounding parts. Both anasarca and papillary edema may be caused also by local irritation (insect stings, nettles, poison ivy, drugs, and certain articles of diet: shellfish, strawberries, etc.) and reflex nervous influences (*œdema fugax*). Chronic edema may be followed by hyperplastic and indurative states of the skin (elephantiasis).

Inflammatory processes of the skin (dermatitis) are either superficial, involving only the papillary bodies and epidermis, or deep, involving the cutis and subcutaneous tissue, and may be acute or chronic. The causes may be mechanic, thermic, chemic, or infectious or trophic agencies.

Phlegmon of the skin is a suppurative process accompanied by mortification and sloughing of necrotic masses. It runs its course principally in the subcutaneous adipose tissue and generally extends to the fascia; sometimes, however, after penetration of the fascia, it rapidly advances to the periosteum, destroying more or less everything in its way (muscles, tendon-sheaths, tendons, and even bones). Phlegmon very frequently occurs on the finger: **felon,** whitlow, periphalangeal cellulitis (*panaritium*). The lymph-glands of the parts are always swollen; acute lymphangitis often occurs and sometimes also the lymph-glands suppurate. Phlegmon begins as

[1] Virchow's Archiv, Bd. 200, p. 395.

a small, itching or painful red spot or as a small vesicle upon a red base. When the process becomes circumscribed, a small ulcer, which may granulate and cicatrize, develops as a result of sloughing of the necrotic parts.

The terms furuncle, **boil** are used to designate a phlegmonous inflammation which is circumscribed throughout its course; usually dissecting suppuration in the neighborhood of a dead hair follicle. Under certain conditions secondary phlegmons may develop from a furuncle, when circumstances of any nature favor the further extension of the primarily localized affection.

Carbuncle is a localized gangrenous nodule of the skin which may develop as the result of the eruption of a number of furuncles in the same locality. Furthermore, the name carbuncle is employed to designate the gangrenous nodule of the skin caused by the anthrax bacillus. (See p. 488.) It differs from furuncle chiefly by the fact that gangrene occurs early, which process is never observed in simple furuncle.

Vesicular and pustulous inflammations of the skin stand parallel with catarrhal affections of mucous membranes. The hard, firm, horny layer prevents the appearance of the exudate upon the surface; therefore, the horny layer is elevated and the exudate accumulates beneath it. In this manner vesicles and bullæ are produced, which sometimes contain a clear, sometimes a purulent or hemorrhagic, exudate, according to the nature of the process.

Emphysema of external parts is an infiltration of the cutis and especially the subcutis with air. It develops in injuries and wounds of the skin, sometimes in connection with emphysema of the lungs or the air passages, or in connection with operations.

In **herpes** (ἕρπειν = to creep), tetter, groups of small vesicles develop upon a red base, and after a short time desiccate. The location and distribution of these vesicles sometimes correspond to certain nerve areas of the skin, *e.g.*, in *herpes zoster*. *Herpes facialis* occurs most frequently upon the lips as *herpes labialis*, either idiopathicly or symptomaticly in severe, acute infectious diseases.

Bittorf[1] reports a case of renal colic accompanied by herpes zoster in which for six months cutaneous pain always occurred coincidently with the colics. According to Head, zones of the surface of the body (so-called **Head zones**) correspond to a series of internal organs the sensory supply of which arises from the same segment level of the spinal cord through which passes the sympathetic innervation of these organs. In the case in question this zone was in the cutaneous region designated by Head as typic of renal diseases (10 and 12 dorsal segments). In this connection Bittorf also draws attention to other zones, especially on the inner side of the left upper arm and particularly the ulnar side of the forearm and the hand, where, in coexistent aortic sclerosis, paresthesias and pain may occur.

[1] Deutsch. med. Woch., 1911, No. 7.

Miliaria, sudamina, miliary eruption, prickly heat, consists in the rapid eruption of very small vesicles with red areolæ in connection with profuse perspiration. The vesicles occur also in connection with a number of infectious diseases (typhoid, puerperal fever, etc.), particularly upon the torso. The vesicles generally disappear after a short time.

Eczema, moist tetter, humid or **running scall,** is an affection beginning with intense swelling and redness of the skin, papules, vesicles, and pustules in which a reddened, moist surface is produced by rupture of the vesicles. When of long standing the skin gradually becomes thickened. Healing takes place by the development of new epidermis beneath scab formation.

Pemphigus is characterized by the occurrence of large, at least hazelnut-sized vesicles (bullæ). The contents of these large vesicles are serous or purulent, or colored red by hemorrhagic admixture. The vesicles are isolated or in groups. *Pemphigus syphiliticus* forms principally large vesicles upon the palms of the hands and soles of the feet. *Pemphigus chronicus* is characterized by its chronic and often malignant course. The patients finally die from exhaustion: marasmus.

Lichen, papular tetter, is a papular disease in which the papules persist as such and are not further altered, *i.e.,* do not develop into pustules, vesicles, etc. The papules are solid swellings of the skin, about the size of a millet seed, resulting from cellular hyperplasia of the papillæ, which may subsequently undergo cicatrization. In *lichen ruber planus* flat and at first bright-red nodules, with a central depression and covered with epidermis showing white reticulate striations, develop; in *lichen acuminatus* the nodules are small and scaly; in *lichen scrofulosus* flattened nodules, each of which corresponds to a follicular opening, occur the apices of which are covered with fine scales.

In **urticaria** (nettle rash, hives) occur broad, flat, actively itching swellings of the skin (wheals) the centers of which are usually somewhat pale and the periphery bright red. These wheals generally disappear after a short time. Occasionally vesicles form upon the wheals. Nettle rash develops on contact with the stinging nettle, from the bites of insects, and in individuals with an especial disposition thereto after ingestion of certain foods (strawberries, crabs, etc.) and certain medicaments (morphine, quinine, etc.). In rare instances urticaria occurs as a chronic malady, which may persist for years without demonstrable cause.

The term **psoriasis** is employed to designate a chronic affection, localized especially to the region of the knees and elbows, hairy portions of the head and the scrotum, in which dry, white, asbestoid scabs adhere quite firmly to a reddened and sometimes quite smooth, elevated base.

According to the size and form of the efflorescence are differentiated *psoriasis punctata, psoriasis guttata* or *nummularis,* and *psoriasis diffusa.*

Scleroderma begins with hard infiltration and results in board-like induration of the skin, which generally is associated with cicatricial contraction.

Burns and **freezing** (*combustiones et congelationes*) manifest a certain parallelism. (See p. 8.) In both, three different degrees are differentiated according to the changes in the skin. The first degree of burn is that of erythema[1]; the second the bullous stage; the third degree is that of charring, carbonization. In freezing of the first degree redness also is observed: livid color; then complete anemia develops, which leads to the second degree, that of vesiculation. In freezing of the third degree gangrene occurs. This reactive change occurs rapidly on action of high temperature; slowly in freezing. The different degrees are designated as *dermatitis erythematosa, bullosa combustionis,* and *gangrænosa congelationis.* In the first and second degrees of burn the papillary body of the skin is not destroyed; consequently, healing without cicatrization results. Cicatrization after the third degree of burn is accompanied by intense contraction, which in large scars may have the severest consequences.

After freezing of the first degree, especially when the same part is repeatedly affected, so-called **chilblains,** perniones, develop, *i.e.,* inflamed and swollen areas, which often itch severely and sometimes are painful.

Excoriations of the skin, cutaneous abrasions, result from a blow, scratching, etc., extend to a variable depth, but usually involve only the epithelium and then heal by scab formation without cicatrization.

Ulcers (see p. 179), *ulcera cutanea,* differ much in character according to their etiology and evolution. Chronic crural (varicose) ulcer, which occurs in connection with venous congestion, especially varices of the leg, is a very frequent affection, characterized by slight disposition to heal. While there is a tendency to the formation of granulation tissue in the base and margin of the ulcer, this leads only to partial and transitory cicatrization, which in turn disintegrates and thus increases the ulcerated area. The course often extends for years; the margins of the ulcer and surrounding parts gradually thicken, become callous, and then hinder completely the covering of the granulated wound surface with epidermis. Epithelioma not infrequently develops from an old crural ulcer. Crural ulcers usually start from small, insignificant excoriations when these are subjected to continued irritation. As a rule, the

[1] Erythema is a hyperemic reddening uniformly distributed over a large area of the skin, which disappears on pressure with the finger.

scars are strongly pigmented, very thin and delicate, perfectly smooth, and unaccompanied by contraction. Periosteal proliferations and new formation of bone are not rare.

Malum or **ulcus perforans,** called also, from its frequent location, *mal perforant du pied* (Nélaton), is an affection characterized by its painless and progressive course. The process usually occurs upon the soles of the feet, especially in the region of the metatarsophalangeal joints, or the skin of the heel. It begins with suppuration beneath a hornified area of the skin and soon extends into the depth, sometimes destroying the bones and joints. The affection occurs also in children. It is probably of trophoneurotic origin, since it occurs especially in the

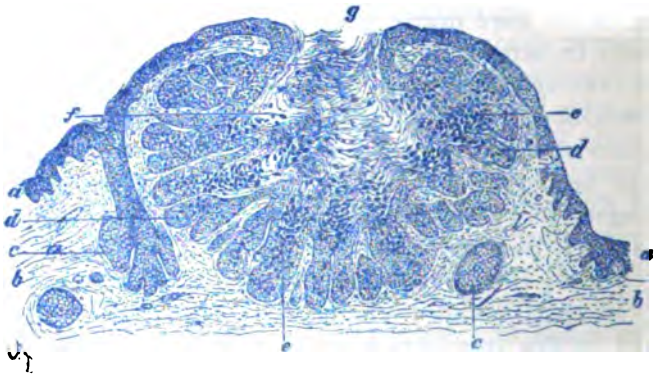

Fig. 501.—Epithelioma contagiosum in long diameter. *a,* epidermis; *b,* connective tissue; *c,* sebaceous glands; *d,* gland-like epithelial proliferations; *e,* parasites; *f,* hornified cells, mingled with "parasites"; *g,* excretory ducts filled with hornified epithelia and parasites. × 15. (After *Ziegler.*)

course of affections of the central and peripheral nervous system (tabes, etc.) and in the nervous form of leprosy. In certain cases atrophy of the nerves and disturbances of sensation (anesthesia, analgesia) and trophic disturbances (hypertrophy of the epidermis) are observed in the region of the ulcer. The affection occurs also in diabetes mellitus, and as a result of obliterating vasculitis (arteriosclerosis).

Epithelioma molluscum (*molluscum* or *epithelioma contagiosum,* cystic condyloma) is a communicable cutaneous affection characterized by the formation of pinhead- to pea- sized, occasionally larger, waxy-glistening, semitransparent, rounded or warty nodules occurring, either isolated or in groups, with considerable frequency, especially in children, upon the face, neck, flexor surfaces of the extremities, penis, scrotum, and labia. The nodules, which are painless, do not itch and have a central depression, persist for weeks, months, or even years, and may spon-

Fig. 502.—Fatal fetal ichthyosis. Case of Dr. Annie S. Daniel. (After *Fischer*.)

taneously disappear. Histologicly, the molluscum nodule consists of a gland-like, epithelial new formation, resembling a hypertrophied sebaceous gland (see Fig. 501), originating from the epithelial layer of the skin. Within the epithelia and central portions of the nodule are found numerous molluscum corpuscles which are regarded by some authorities as protozoa and the etiologic factors.

Callosities of the skin (tylosis, keratoma, tyloma) consist of a hyperplasia of the epidermis. If the papillary body atrophies under pressure of the hyperplastic epidermis, **corns** (*clavus*) develop. Sometimes horn-like and claw-like elevations of the hornified epidermis develop as the result of thickening of the epidermis; such a formation is designated as skin or cutaneous horn (*cornu cutaneum*).

Ichthyosis, fish-skin, is an analogous condition, a diffuse keratosis, in which the skin acquires a certain resemblance to fish-scales. It is essentially an intense thickening and fissuring of the horny layer, usually accompanied by pigmentation and gradually increasing elongation of the papillæ.

In **onychogryphosis** the nail is thickened, attenuated, and bent anteriorly; it gradually assumes the form of a claw and becomes extremely hard. The nail-matrix is always shortened, diminished, and arched; the nail walls are enlarged and often covered with papillæ. Claw-like nails can very readily be lifted from the nail-bed, and develop as a result of chronic inflammation of the nail-matrix.

Onychomycosis is an affection of the nail due to infection with the fungi of favus and herpes tonsurans. **Paronychia** is an inflammation of the nail-bed with termination in suppuration. It may be due to local causes or occur as a manifestation of syphilis.

In advanced age the skin atrophies (senile atrophy), in that it becomes thinner, less elastic, and more deeply pigmented; the hair follicles atrophy and result in loss of the hair (*alopecia senilis*). In a similar manner atrophy occurs in chronic diseases of the skin and in continued pressure, *e.g.*, from tumors.

The scars of pregnancy, *striæ abdominis gravidarum,* develop as a result of stretching of the skin and subcutis with separation of continuity. They are at first red, later white and glistening. The papillary bodies are lacking within the striæ, and the whole cutis is somewhat thinner in these localities.

THE EYE.

THE CONJUNCTIVA.

Anatomy.—The conjunctiva may be compared to a sac extending from the margin of one lid to that of the other, lining the lids, and covering the anterior surface of the sclera. At the lid margins it merges with the skin, where, as under similar conditions in other parts of the body, the junction of skin and mucous membrane is a favorite site for the development of pathologic processes.

The anatomic divisions of the conjunctiva are: 1, *conjunctiva palpebrærum,* which covers the tarsal cartilage and the remaining portion of the lid lined with conjunctiva; 2, *conjunctiva fornicis, i.e.,* the folds of transition, which extend between the palpebral conjunctiva and the eyeball, and, 3, *conjunctiva bulbi,* which covers the anterior portion of the sclera. The region where it meets the cornea is known as the limbus.

Histologicly, the conjunctiva is divided into an epithelial portion and the mucosa. The epithelial portion varies in different parts as follows: The edge of the lid (intermarginal zone) is covered with stratified epithelium which extends for a short distance over the inner tarsal surface. The palpebral conjunctiva is supplied with two layers of epithelium: the superficial, consisting of high, perpendicular cylindric cells with long, oval nuclei the long axes of which correspond to those of the cells. The cells of the deeper layer are smaller in size and placed horizontally. This double epithelial layer exists only on the tarsi, and this arrangement is varied by interposition of extra cells, the number of which increases toward the bulb, where a depth of several layers is attained. Here the superficial layers are flattened. At the limbus the epithelial covering is reduced to three layers.

Throughout the conjunctiva are found peculiar beaker or goblet cells, especially on the bulb and fornix; they are similar to, but not identic with, the goblet cells of the intestine. They furnish mucin and are unicellular mucous glands. The mucosa consists of two layers. The first, lying directly beneath the conjunctiva and known as the *substantia propria,* or adenoid layer, consists of a fibrous reticulum filled with lymphocytes. It varies in thickness in different regions. The second, or deep, layer is thicker than the adenoid layer, and consists of fibrous tissue containing a large number of elastic fibers. On the tarsus it is simply a continuation of the tarsal cartilage. Owing to its density, it is not easily invaded by cells. The blood-vessels and nerves are conveyed through this layer. In the normal conjunctiva, papillæ are found only at the limbus. They are few in number and consist of projecting digitations of the *substantia propria* covered with epithelial cells. More or less undulation always exists in the adult conjunctiva, which is smooth only in infancy before development of the adenoid tissue. Henle mistook the depression between the conjunctival folds for tubular glands, and for topographic reasons these pockets still retain the name of Henle's glands. It is still undecided whether or not true tubular glands exist in the conjunctiva. Krause's glands are accessory lachrymal glands differing histologicly in no way from the

lachrymal gland. They are deeply situated in the conjunctiva of the fornix, although they exist elsewhere. There are 40 or more in the upper and 6 to 8 in the lower lid. At the inner canthus, the conjunctiva forms a fold: the *plica semilunaris.* It is a rudimentary nictitating membrane and may contain cartilage or a racemose gland. The caruncle is a small island of skin at the inner palpebral angle. It contains the structures of both skin and conjunctiva, including goblet cells and glands resembling Krause's glands.

In inflammatory processes the separate, differently constructed portions of the eye present certain peculiarities which are explained partly by the position, partly by the structure, of the tissues involved. Only the cornea and the conjunctiva have a free surface, and of these the *conjunctiva tarsi* and the *conjunctiva fornicis* are covered with cylindric epithelium. The *conjunctiva bulbi* and the cornea are covered with lamellated squamous epithelium. The difference in reaction to inflammatory irritation closely depends upon this difference in the epithelial covering. Thus, in inflammations the *conjunctivæ tarsi et fornicis,* like those portions of the digestive tract provided with cylindric epithelium, are particularly disposed to produce a free catarrhal exudate, while the cornea in its behavior acts more like the external skin. The *conjunctiva bulbi* stands in a measure midway between the cornea and the remaining portions of the conjunctiva.

In mild cases of fresh catarrhal conjunctivitis, the *conjunctiva tarsi* and *conjunctiva fornicis* are principally involved. The catarrhal product is either watery, mucoid, purulent or mixed. It must be remembered that a part of the watery fluid is generally derived from the augmented secretion of the lachrymal glands, because in most cases of catarrhal conjunctivitis, especially when accompanied by profuse exudation, the lachrymal gland also is stimulated to increased secretion. In the mildest type of conjunctivitis the only discharge is lachrymal secretion and a few epithelial cells. In the violent forms of acute catarrhal conjunctivitis the *conjunctiva bulbi* also is involved; this is the so-called **catarrhal** or **purulent ophthalmia.**

Acute conjunctivitis occurs in connection with certain diseases (*e.g.,* measles, *conjunctivitis exanthematica*) as well as independently. In many cases it is caused by the use of drugs (*e.g.,* atropine: atropine conjunctivitis) or by foreign bodies, etc.

Certain clinic types of conjunctivitis are due to the action of specific micro-organisms. Diphtheritic conjunctivitis results from the presence of the Klebs-Löffler bacillus. It is frequently, however, a mixed infection, the associated bacteria being streptococci and staphylococci. The membrane which forms is composed of a fibrinous reticulum infiltrated with leucocytes, and in severe cases extends into the subepithelial tissues. (See p. 523.)

The **gonococcus,** probably, is responsible for all cases of *ophthalmia neonatorum* occurring within three days after birth. Furthermore, patients suffering from gonorrhea may convey the contagion to the conjunctiva (autoinfection). Gonorrheal conjunctivitis is occasionally metastatic,[1] endogenous infection taking place in the conjunctiva, as in the iris and joints (gonorrheal rheumatism). This type is milder than the inoculated form. In this connection it should be noted that gonorrhea is frequently a mixed infection. In inoculated cases the phenomena produced in the conjunctiva by the activity of the gonococcus exemplify blennorrhea in its severest form. The gonococcus is said to penetrate the uninjured epithelium of the cornea, but it is doubtful whether any micro-organism possesses this power. (See footnote, p. 980.)

Streptococci located in the conjunctival sac may or may not cause severe inflammation of the structures in this region. Their exclusion from the subconjunctival tissue depends upon the integrity of the surface epithelium. Dorlan Smith found streptococci in the conjunctival sac in a case of dacryocystitis, but they did not cause severe conjunctivitis. Streptococci have been found in serious types of conjunctivitis, in which instance the preauricular glands were enlarged and iritis was present. In this infection the cornea may be perforated and the eye lost from panophthalmitis. In such cases infection probably occurs through the agency of the discharge from a purulent dacryocystitis. In some cases a membrane is formed upon the conjunctiva. Fatal cases have been reported in children.

Parinaud's conjunctivitis is a severe form accompanied by fever. It is characterized by the presence of granules in the tarsal and retrotarsal conjunctiva. The preauricular glands are enlarged and sometimes break down. This affection is said to be due to streptococcic infection of the conjunctiva, but this view has not been established.

The **Koch-Weeks bacillus** is a common cause of mucopurulent conjunctivitis. The pathologic changes consist of congestion and diffuse round-celled infiltration of the tissues. Follicles do not form in cases of unmixed infection.

The **diplococcus of Morax-Axenfeld** produces a blepharoconjunctivitis with scanty mucopurulent discharge and greatly increased lachrymation. From characteristic redness at the angles of the lids and adjacent skin, it is sometimes called "angular conjunctivitis." It is occasionally accompanied by asthenopia. Infiltration of the periphery of the cornea may be present. By most authorities the disease is considered to be contagious. Stock and Brown Pusey have reported histologic exam-

[1] Axenfeld: "Die Bakteriologie in der Augenheilkunde," Jena, 1907, pp. 118 *et seq.*

inations of cases. They found epithelial ingrowth at the corneal limbus and on the tarsal borders, and epithelial proliferation and desquamation on the tarsal conjunctiva. The bacteria were found between superficial layers of epithelium and in the so-called glands of Henle. Necrosis of central cells in the epithelial ingrowths lead to small ulcers. Involvement of Henle's glands tends to render the case intractable.

Pneumococcic conjunctivitis sometimes prevails as an epidemic. The secretion is usually thin and accompanied by increased lachrymation; occasionally it is mucopurulent or membranous. Small conjunctival hemorrhages are frequent, especially in the upper lid.

Other micro-organisms suspected, but not proved, to be specific causes of conjunctivitis are the *Bacillus influenzæ,* indistinguishable microscopicly from the Koch-Weeks bacillus; the *Bacillus coli communis,* which is considered also to be an occasional cause of hypopyon keratitis; the *Bacillus pneumoniæ,* probably identic with the bacillus of ozena; the *Bacillus pyocyaneus,* and the *Staphylococcus aureus* and *albus,* which are frequently associated with conjunctival and corneal disease. The exposed position of the conjunctival sac and cornea renders it difficult to estimate the influence exerted by these and other common forms of bacteria which are often present in apparently healthy eyes.

The **xerosis bacillus** is found in enormous numbers in xerotic conditions of the conjunctiva. The white film which accumulates upon a xerotic patch is frequently a pure culture of this micro-organism. It is not, however, accepted as the etiologic factor in *xerosis conjunctivæ.* It is the most frequent inhabitant of the normal conjunctiva, and the conditions existing in xerosis are particularly favorable for its development.

The morbid anatomy of acute conjunctivitis is that of inflammation in other parts of the body, varying in degree according to the severity of the attack. If at all marked, the changes consist of increase in the number of goblet cells in the epithelial layer, distention of blood-vessels and migration of leucocytes, serous effusion into the submucosa, excessive proliferation of lymphocytes in the adenoid layer, and the presence of mast-cells and plasma-cells. The acute form of catarrhal conjunctivitis usually subsides, leaving no permanent anatomic alterations. If, however, the catarrh persists or frequent recidives occur, chronic catarrhal conjunctivitis results. The mucous membrane is gradually thickened and thrown into folds,[1] forming papillary elevations and greatly deepening the normal furrows, which, in connection with increased pro-

[1] In elderly persons the mucosa of the eyelid is usually somewhat uneven, velvety—not smooth as in young individuals. This likewise is due to the formation of folds and very gradual accumulation of lymphoid cells, and is generally somewhat inaccurately designated as "papillary condition" of the conjunctiva.

liferation of the surface epithelium, results in a gland-like formation between the papillæ. The goblet cells also are enormously increased in number. Large numbers of lymphoid cells accumulate in the tissue of the mucosa and may form follicles. Cysts may form from agglutination and retention of surface epithelium. In late stages of this condition, especially when associated with ectropion, the epithelium may become cornified.

Follicular Conjunctivitis.—Besides the chronic conjunctivitis which follows acute attacks, which sometimes is attended by the formation of follicles, there is a special form, known as follicular conjunctivitis, which is never a sequela of catarrhal conjunctivitis. It is often mistaken for

Fig. 503.—Granular ophthalmia. (After *T. W. Jones.*)

trachoma, which also is attended by the formation of follicles. Follicular conjunctivitis is characterized by the formation of round, pinhead-sized, pale granules which are elevated above the surface. The most marked development of the granula is in the fornix, where they usually are arranged in rows running parallel with the folds. As a rule, two or three rows are present, although in severe cases the entire conjunctiva may be involved. (See Fig. 503.) The development of the follicles is in response to the action of some irritant—chemic, thermal, or bacterial—upon the conjunctiva. They are a marked feature in cases of atropine and eserine conjunctivitis. Follicular conjunctivitis prevails among children in crowded schools, where the conjunctiva is exposed to the irritant action of foul atmosphere, etc. It is sometimes observed in cases of uncorrected errors of refraction and is then attributed to eye-strain. As a rule, in follicular conjunctivitis the eye is free from irritation even where the granulations are exuberant. Other cases are attended by catarrhal discharge. In the latter case it is probable that bacterial infection has been added to a follicular conjunctivitis. The prevalence of the so-called acute

form in overcrowded asylums is explicable when it is considered that, as a result of environment, nearly all the inmates have follicular conjunctivitis. This, however, offers no protection against bacterial infection; catarrhal or purulent conjunctivitis occurs in eyes previously affected with follicles. When the exciting cause is removed, follicular conjunctivitis subsides, leaving no trace of its existence, differing from trachoma, which results in cicatrization. As in the first stage of trachoma, the follicle consists of an accumulation of lymphoid cells. There is no ground, however, for assuming that the disease is a precursor of trachoma.

Trachoma, granular conjunctivitis (*conjunctivitis trachomatosa: ophthalmia Ægyptica, s. militaria, s. contagiosa*). This form of conjunctivitis was introduced from Egypt at the beginning of the last century. Its similarity to follicular conjunctivitis consists in the formation of follicles in the retrotarsal folds; otherwise, the two diseases differ widely. The disease is highly contagious. Although usually chronic in course, it may assume an acute form. Fuchs regards the acute type always as a superadded infection. It is, however, difficult to accept this conclusion in view of experimental inoculations which have produced active reactions upon human conjunctivæ. According to Frösch and Clausen, the period of incubation in trachoma is about ten days. Wootton has found it to be seven days.

Trachoma is a disease attended by lachrymation, photophobia, great discomfort, and sometimes pain. Usually vision is more or less diminished in all stages. Some ptosis exists from thickening of the conjunctiva and increased weight of the lid, which may be enhanced by closure of the lid from intolerance of light. The conjunctiva of the tarsi and fornices is red and thickened, so that the Meibomian glands can no longer be traced. This is due to the formation in the membrane of both follicles and papillæ. Probably, in all cases of trachoma, follicles and papillæ coexist. The predominance of one or the other, however, has led to the division of the disease into two forms, *i.e.*, the papillary and the granular. The papillary form of trachoma is exclusively a disease of the tarsal conjunctiva, particularly of the upper lid. The size of the papillæ varies; when small they give the surface a velvety appearance; when large they may assume a villous character. In this form granules also are present, but are hidden between the papillæ. The granules grow deeply into the tarsus, and in this situation are pathognomonic of trachoma. The granular form is characterized by the formation of follicles called **trachoma granules.** They are round, gray, translucent bodies, imbedded in the conjunctiva, projecting somewhat above the surface, and presenting a hemispheric appearance. From their translucency they have been compared to grains of boiled sago or frog spawn.

Their favorite site is along the folds of transition, where they exist in great numbers. They end abruptly where the conjunctiva is reflected on to the eyeball—the point where cylindric epithelium ends and stratified epithelium commences. The latter appears unsuited to their development, although in advanced cases, where histologic distinctions are not marked, trachomatous material may be found even upon the cornea. The granules are so thickly crowded together that they sometimes coalesce, forming exuberant masses. This condition has been called **gelatinous trachoma.** Trachoma granules frequently appear on the semilunar fold. Trachoma granules without papillary hypertrophy are seldom if ever observed.

Fig. 504.—Trachoma, showing round, opaque bodies in upper and lower lids. "Sago-grain" type. From a photograph. Frequent type seen in children.

Retrogression of the granules and papillæ is attended by the formation of cicatricial tissue, which appears on the conjunctiva of the tarsus in the form of narrow, whitish lines. In the fornix the cicatrization proceeds as a gradual thinning and absorption of tissue, until the folds have entirely disappeared. The amount of subsequent cicatrization is greatest in cases where the conjunctiva was most hypertrophied. As the disease advances, the limbus and cornea are invaded. Trachoma of the **cornea** is attended by the growth of highly vascular granulation tissue designated as p a n n u s. Superficial ulcers are common in pannus, but do not usually terminate in perforation, owing to the vascularity and consequent increased reparative power of the cornea. Trachoma is very insidious, and if not cured in the early stages it leads to great impairment of vision and even blindness.

Although trachoma has for years been the subject of exhaustive investigation, many points in its etiology, symptomatology, and history are still in dispute. Even its contagiousness is denied. In view of these conflicting opinions, it must be remembered that trachoma is a disease of lymphoid tissue in which reaction to morbific influences is modified by individual idiosyncrasy and environment. It is a matter of observation that under improved sanitary conditions advanced destructive trachoma is less frequent than in former years.

The young trachoma granule is histologicly indistinguishable from the follicle of follicular conjunctivitis. The fully developed **trachoma follicle** consists of:—

1. A capsule of fibrous connective tissue. This is not always present in the early stages. When very marked, it indicates commencing cicatrization.

2. A vascular envelope surrounding the follicle and sending capillaries into the interior.

3. The central, larger portion of the follicle, composed of a fine reticulum the meshes of which are filled with lymphoid elements.

The epithelium of the conjunctiva is thickened. Furrows, epithelial ingrowths, and gland-like formations appear. There is round-celled infiltration of the conjunctiva surrounding the follicle. A variety of cells appear in a trachoma follicle during the different stages of development. The following are constant and characteristic: The predominating cells which make up the central portion are large, mononuclear leucocytes, containing granular nuclei which frequently are very small. Sometimes they assume an epithelioid appearance. These cells exhibit karyokinesis. The peripheral zone of the follicle is largely made up of small lymphocytes with a very scanty protoplasm. Karyokinetic figures do not appear in these cells. Their number is greatly increased in the interior as cicatrization progresses. The conflicting views regarding the character of the corpuscular cells (Körperchenzellen: Leber), phagocytes (Villard, Pick), connective-tissue cells (Addario), epithelial cells (Omeltschenko, Frösch and Klausen), is sufficiently indicated by this list of names. The name suggested by Leber is preferable, inasmuch as it embodies no theory. These cells are scattered throughout the central portion of the follicle, especially in the early stages of its development. They are very large cells with irregular protoplasmic processes and large, round or oval, pale, homogeneous nuclei containing one or more nucleoli. They are particularly interesting from the presence of cell inclusions. The latter vary, but usually consist of pigment granules, red blood-cells, cellular *débris*, and especially peculiar hyaloid bodies of rounded or angular form which have by many been regarded as parasites. Mast-cells are found peripherally, but their presence cannot be considered peculiar to trachoma.

Bacteriology.—Although little doubt exists as to the parasitic nature of trachoma, it has thus far been impossible satisfactorily to establish the identity of the micro-organism. At various times the disease has been attributed to a variety of organisms. Hirschberg and Krause isolated a bacillus; Sattler a diplococcus, etc. Microsporon and protozoa also have been looked upon as etiologic factors. Pigment granules are found in the trachoma follicle; Krudener, observing that they possessed ciliated movement, named them Wimmelzellen. This motion appears previously to have been observed by Leber. Halberstadter and Prowazek found in the epithelial cells of the conjunctiva cell inclusions (small granulations) situated in the protoplasm next to the nucleus, in Javanese and orang-outangs with trachoma. They failed, however, to find these bodies in the interior of the follicle or in advanced cases. Frösch and Clausen, working with Greeff, confirmed these findings

and also found the same or similar bodies inside the corpuscular cells and in the discharge from untreated cases. Their most important discovery was the presence within the corpuscular cell of a barely visible diplococcus surrounded by a zone. These investigators regarded the cell inclusions (granula) as masses of these diplococci. Culture experiments were negative. These findings were invariably absent in control cases of catarrhal conjunctivitis. These so-called trachoma bodies have been found in ophthalmia neonatorum, and in the gonorrheal urethra of both sexes.

Transformation of the young trachoma granulations into scar-tissue always causes a permanent change in the conjunctiva. If the scar-tissue which forms is slight in amount, little or nothing is perceptible externally; only the fold of transition is somewhat shortened, and this may cause slight inversion of the margin of the lid (entropion). This was formerly believed to be due to shortening of the tarsal conjunctiva; at present, however, entropion in trachoma is considered to be the result of tissue changes in the tarsus itself. Central softening and bending or total atrophy with substitution of fibrous or fatty tissue may occur.

In severe retraction of the scar-tissue (**cicatrizing trachoma**) the following changes are observed:—

1. Marked bending of the tarsus,[1] the concavity directed inward.
2. Inversion of the margin of the lid: entropion, thus caused.

In this condition the inner margin of the lid usually disappears and the cilia are directed toward the globe: trichiasis. When the connective-tissue proliferation extends to the Meibomian glands and the follicles of the cilia, the former atrophy and the cilia fall out with advance of cicatrization.

Sometimes erosion and ulceration develop in the acute stage, which, on further progress, are followed by agglutination and adhesion of the apposed conjunctival surfaces.

In very severe cases almost all of the conjunctival sac disappears,[2] and only a more or less small, dry, gray seam covered with hornified epithelium remains between the margins of the lids and cornea. This state is called **xerosis**.[3] When the cornea is similarly altered, the condition is called **xerophthalmia**.

Epitheliosis desquamativa conjunctivæ is an affection described by Leber and v. Prowazek,[4] characterized by swelling of the palpebral and chemosis of the bulbar conjunctivæ, desquamation of the epithelial cells, and later follicular swelling. While the affection greatly resembles trachoma, the above-named authors regard it as a distinct disease. In the early stage the secretion contains chiefly epithelial cells and comparatively few leucocytes. In the second stage the characteristic desquamation ceases and the secretion assumes the character of that observed in chronic catarrhal conjunctivitis. At the end of this stage corneal ulceration and

[1] At first, usually associated with thickening; later, not rarely with fatty metamorphosis.

[2] In this condition the excretory ducts of the lachrymal gland, the tarsal, hair-follicle, and conjunctival glands may completely disappear. All moistening of the conjunctiva then ceases; the mucosa becomes dry and, finally, acquires an epidermis-like appearance.

[3] ξηρός = dry.

[4] Berlin. klin. Woch., Jan. 30, 1911, p. 217.

perforation are particularly frequent, often resulting in leucoma adhærens, corneal staphyloma, and phthisis bulbi. The third stage is that of diffuse smooth white atrophy of the conjunctival epithelium. The cause of the affection is regarded by Leber and v. Prowazek to be peculiar cellular inclusions described by them.

In **purulent conjunctivitis** (*conjunctivitis blennorrhœica s. gonorrhœica;* blennorrhea) the whole conjunctiva is intensely swollen and reddened and the scleral conjunctiva often so strongly involved that it surrounds the margin of the cornea like a steep wall. This intense swelling of the scleral conjunctiva is called chemosis. In this condition severe inflammatory edema of the lids usually exists, the external skin of the lids also being involved. The conjunctival fold, however, is always most intensely altered.

The exudation consists at first in the secretion of a thin, pale-yellow, slightly cloudy fluid, mixed with isolated flocculi, which is richly albuminous and characterized by coagulability. The exudate sometimes assumes a somewhat hemorrhagic character, because the strongly hyperemic mucosa possesses a marked tendency to small hemorrhages (upon the free surface as well as in the parenchyma). This character of the exudate is usually very soon altered, becoming purely purulent within a few days (pyorrhea). Later, when the acute stage subsides, the exudate becomes mixed: mucopurulent. The rapid coagulability of the exudate results in the precipitation of coagula, even in the conjunctival sac.

This form of purulent conjunctivitis is most frequently observed in the newborn on the second or third day after birth (blennorrhea, or *ophthalmia neonatorum*) and is almost always due to infection with virulent vaginal secretion during labor. In many cases the infection is caused by gonococci. This *conjunctivitis gonorrhœica* (see Gonococcus, p. 497), or *blennorrhœa gonorrhœica,* is generally accompanied by most violent phenomena. It is particularly feared because the process very readily involves the cornea and often very soon forms circumscribed, purulent foci of infiltration in the corneal margin. This ulceration may rapidly extend toward the center as well as in the depth, and cause perforation and even complete destruction of the cornea.

Purulent conjunctivitis is not always acute. It occurs also as a chronic affection. In the chronic, and sometimes also in the acute, forms proliferations develop in the conjunctiva, especially in the tarsal portion, which cause finely granular thickening of the mucosa. This chronic form of purulent conjunctivitis is characterized by repeated exacerbations and remissions; it is, therefore, a recurrent inflammation which, in many cases, may likewise cause ulceration and perforation of the cornea.

The type of conjunctivitis characterized by the formation of a fibrinous exudate: **membranous conjunctivitis** (*conjunctivitis fibrinosa*), is generally an accompaniment of other conjunctivitides (particularly the diphtheritic). In very rare cases it is observed as a chronic recurring affection. In this condition the tarsal portion especially is involved.

Aside from the Klebs-Löffler bacillus, membranous conjunctivitis is associated with a great variety of micro-organisms, particularly the pneumococcus, streptococcus, staphylococcus, the Koch-Weeks bacillus, and gonococcus. It may follow the use of escharotics, chemic or thermal. A severe form is produced by the thrush fungus. An unusual form has been observed in connection with a skin disease: *herpes iris*, cultures from which produced a membranous conjunctivitis in the eyes of rabbits.

Diphtheria of the conjunctiva occurs in connection with, as well as without, faucial diphtheria. Like any other form of diphtheria, it is a superficial, necrotizing process with subsequent ulceration after dissection of the dead part. When the diphtheritic process is confined to only a small portion of the conjunctiva, the danger to the cornea is comparatively less than when a larger area, especially the scleral conjunctiva or the whole conjunctiva, is involved. In the latter case the whole cornea is always destroyed in like manner, and if the patient does not die shrinking of the conjunctiva and atrophy of the whole eye result. (See p. 1004.) Superinfection may cause a purulent discharge. In such cases the eye usually is lost.

Phlyctenular conjunctivitis is the most frequent alteration of the scleral conjunctiva. It attacks almost exclusively young individuals up to puberty, particularly scrofulous children. Like all scrofulous affections, it manifests a great tendency to recur and has, therefore, been called *conjunctivitis scrofulosa* or *lymphatica*. A microbic origin for this disease has not been established. It probably depends upon an endogenous poison. Its frequent association with improper feeding is very suggestive of autointoxication. Many of these cases exhibit reaction to the tests for tuberculosis. Notwithstanding this fact, it is difficult to accept tuberculosis as the cause of the affection except in a few instances.

This affection begins with eruption of one or, more frequently, several phlyctenulæ[1]—small, nodular swellings close to the margin of the cornea. It formerly was supposed that after a brief period these were transformed into small vesicles which subsequently ruptured and discharged their contents, leaving small ulcers which healed within a few days without perceptible cicatrization. It has recently been stated that vesicle formation has never been microscopicly demonstrated in phlyctenular conjunctivitis. According to this view, a localized infiltration of mono- and polymorpho- nucleated leucocytes produces a small papule in the conjunctiva, the overlying epithelium separating and breaking down, forming a small

[1] Dim. of *phlyctæna:* a blister, vesicle.

ulcer with indurated and crateriform walls, differing in this respect from the flaccid walls of herpetic vesicles. The palpebral conjunctiva may be unaltered, though it is frequently the seat of a mucopurulent inflammation. This is sometimes so marked that it is the most prominent phenomenon and may then easily give rise to confusion with blennorrhea.

The phlyctenulæ vary in size and number. Generally, the smaller the number, the larger the size. Therefore, two forms are usually differentiated:—

1. The broad phlyctenulæ.
2. The small phlyctenulæ or miliary: *conjunctivitis phlyctænulosa miliaris.*

In the former a few, comparatively large foci of infiltration, about 3 to 4 mm. in size, develop at the margin of the cornea, which sometimes involve the cornea itself; in the latter numerous, very small vesicles develop at the *limbus corneæ* (hence named also marginal keratitis). Whenever the cornea is involved below Bowman's membrane, small, delicate, superficial opaque spots remain upon the cornea: so-called *maculæ corneæ.*

Pinguecula,[1] or **pinguicula** (so-called *pterygium lardaceum,* because it was erroneously supposed to be of a fatty nature). A very frequent change of the *conjunctiva bulbi* at the corneal margin, in the region of the palpebral fissure zone, is referable to local, so-called atmospheric influences (sand, dust, etc.). This is a small, triangular, pale-yellow, slightly elevated, chronic thickening of the mucosa, which, owing to the yellowish color, is called pinguecula. The essential changes which constitute pinguecula take place in the subepithelial portion of the conjunctiva. They consist chiefly in an excessive proliferation of yellow elastic tissue and the deposit of amorphous hyaloid material. The latter results from degeneration of fibrous and elastic tissues. The deposit is at first homogeneous or finely granular, but afterward fuses into large, irregular masses. If pinguecula grows over the cornea it results in pterygium. It contains no fat, as its name would suggest.

Pterygium[2] is a triangular or fan-shaped fold of mucosa, the apex of which grows to the cornea and the base directed toward the inner, or in rare cases the outer, angle of the eye, and merges with the scleral conjunctiva without sharp line of demarkation. The portion adherent to the cornea is called the head; the portion between the head and base, the neck. So long as the pterygium continues to grow, it is called progressive; when, however, the process ceases to advance it is called stationary. Anatomicly, these two forms are distinguished by the fact that fresh or progressive pterygium is very richly vascular (the vessels running in a direction toward the head of the pterygium), while stationary pterygium is quite pale, poorly vascular, tendinocicatricial, the stretched fold of mucosa being transformed into a thin, tendinous membrane. When the vascularity is slight and the hypertrophy incon-

[1] From *pinguis:* fat.
[2] πτέρυξ = diminutive of wing.

siderable, it is called membranous (*pterygium tenue;* see Fig. 505); if the hypertrophy is excessive and the development of vessels great, resembling somewhat muscular tissue, it is designated as *pterygium crassum, s. carnosum, s. vasculosum.* (See Fig. 506.) This affection is observed in elderly individuals whose eyes are frequently exposed to local irritations. The lateral margins are always affected, but not the upper or lower margin, probably because these are better protected by the lids.

Pterygia are classed as true (*pterygium vera*) and false (*pterygium spuria, pseudopterygium*). Fuchs has demonstrated that true pterygium results from a pinguecula growing over the cornea and dragging a fold of conjunctiva after it. True pterygium is progressive, at least up to a certain point. As it ad-

Fig. 505.—Pterygium tenue. (After *Guthrie.*)

Fig. 506.—Pterygium crassum. (After *Guthrie.*)

vances over the cornea, Bowman's membrane is destroyed. Pterygium consists of modified conjunctiva (hypertrophy of the conjunctival and subconjunctival tissue). Tubular glands form upon the surface from reduplication of the epithelial layer. A probe can be passed only a short distance beneath the folded border of a true pterygium. Pseudopterygium results from agglutination of a conjunctival fold to the cornea. It may be due to corneal ulcer, acute blennorrhea, diphtheria, burns, operations, injuries, etc. It is nonprogressive and never extends beyond the original point of attachment. The margin of the cornea usually is bridged by the conjunctival fold and permits a probe to be passed freely beneath it. This is employed as a clinic test to differentiate true from false pterygium.

The mobility of the eye is but seldom perceptibly interfered with by pterygium. As in most affections of the conjunctiva, the chief danger lies in more or less extensive involvement of the cornea. Two or three pterygia may occur on the same eye, covering the cornea with a thick veil and totally obscuring vision. The ancients called this condition panniculus. Pterygium should be distinguished from opacity of the cornea (leucoma) and the cicatricial bands (symblepharon, *q.v.*) which often form between the palpebral conjunctiva and the globe or cornea after burns (hot metal, quicklime, acids, etc.) and trauma of the conjunctiva.

Epitarsus.—Under this name Schapringer has described a congenital anomaly of the tarsal conjunctiva which usually involves the upper lid, and, in the majority of cases, affects both eyes symmetricly. The configuration resembles that of pterygium. In typic cases nothing abnormal is seen until the lid is everted, when a fold of mucosa, having the transition fold as a base, is revealed. The mucosa of the fornix appears as though it had been grasped by a wide-tipped forceps and raised to form a fold with an anterior and a posterior surface, the anterior surface being glued completely, or nearly so, to the posterior (mucous) surface of the lid. This anomaly sometimes causes incomplete development and consequent inversion of the tarsus, which then produces the condition described as "congenital entropion." Schapringer was the

Fig. 507.—Symblepharon. (After *Mackenzie.*)

first to point out that congenital entropion is nothing but a complication of epitarsus. He claims amniotic adhesions to be the cause of this malformation.

Symblepharon[1] is the formation of cicatricial adhesions between the conjunctiva of the lid and that of the globe. (See Fig. 507.) These may result from injuries, operations, burns, and all forms of ulceration, and they frequently follow diphtheritic conjunctivitis. When the adhesion forms a bridge in the anterior portion of the conjunctival sac and does not reach the fornix, it is called *symblepharon anterius.* If it extends to the fornix, so that a probe cannot be passed behind it, it is called *symblepharon posterius.* The latter form is difficult to remedy. A similar condition is caused by obliteration of the fornix from shrinking of the conjunctiva in trachoma and pemphigus. In symblepharon nearly all the conjunctiva of the lid may be adherent to the opposite side of the globe, or only a bridle-like strip may be present. In *symblepharon cum cornea* the conjunctiva adheres to the cornea. This condition may simulate

[1] *Syn:* with, together; *blepharon:* the lid.

pterygium (*q.v.*). Complete adhesion of apposed conjunctival surfaces (*symblepharon totale*) causes blindness. Partial adhesion limits the mobility of the globe and lids, so that sometimes the latter cannot be closed. These cases subsequently become complicated by phenomena of irritation and inflammation of the cornea.

In **xerosis of the conjunctiva** (xerophthalmia; see Trachoma) the surface is dull, lusterless, dry, epidermis-like, thickened, slightly flexible, sometimes somewhat fatty from secretion of the Meibomian glands and fatty metamorphosis of the proliferated epithelia. The lachrymal secretion is not necessarily suspended, but the fluid secreted does not remain upon the surface of the mucosa. Later, the secretion of the lachrymal gland also ceases. Xerosis conjunctivæ occurs after trachoma, seldomer after cauterization, burns, diphtheria, etc., and also as a result of continuous exposure of the conjunctiva, as in incomplete closure of the lids: lagophthalmus, and in ectropion.

Xerosis corneæ is the analogous change of the cornea. In this condition the cornea loses its transparency and subsequently undergoes softening: keratomalacia. (See Cornea, p. 978.)

Vernal conjunctivitis (spring catarrh) is a form of conjunctivitis characterized by annual exacerbations, commencing with the advent of warm spring weather and continuing until the onset of winter. It is usually quiescent during cold weather. In typic cases the tarsal surface of the upper lid is studded with large, flat nodules covered by a bluish film resembling a thin layer of skimmed milk. This is due to proliferation of the epithelial and fibrous layer, and consequent increase of thickness. At the limbus there is thickening of the ocular conjunctiva, which may form a circumscribed tumefaction, or it may surround the cornea. The epithelium proliferates exuberantly also in the deep tissue between the nodules. The conjunctival connective tissues, especially the yellow elastic fibers, proliferate, the fibrous tissue apparently predominating. A peculiar tubular arrangement of the epithelial cells is sometimes observed. Usually in the active periods a marked feature is the dense infiltration of the tissues by eosinophilic leucocytes, which are found in great numbers also in the discharge from the eyes. These cells pass through the walls of the blood-vessels, travel along the lymph-spaces, and reach the surface by squeezing through the interstices of the epithelial cells. Although no specific micro-organism has yet been identified, the affection is supposed to be microbic in origin.

Conjunctivitis petrificans (Leber) is characterized by the formation of small, hard, chalk-white plaques in the bulbar and palpebral conjunctivæ. There is slight accompanying conjunctivitis. Microscopicly, the disease is a degenerative process in which the surface epithelium may be

lost. Active proliferation of fibrous tissue and deposit of calcareous salts take place, and superficial areas of calcification form which may undergo necrosis as a result of hyaline degeneration and occlusion of adjacent blood-vessels. Eosinophilic leucocytes accumulate in great number in the infiltration areas.

Concretions form in the crypts and glands of the conjunctiva, and also in the Meibomian glands. Their formation is accompanied by a mild catarrhal inflammation known as lithiasis conjunctivitis.

Ophthalmia nodosa (pseudotubercular conjunctivitis) results from the presence in the conjunctiva of the hairs from certain species of caterpillars. Nodules form in the conjunctiva, episclera, and iris. The most common site is the ocular conjunctiva below the cornea. Clusters of gray or yellowish, semitranslucent tubercles, from 1 to 2 mm. in diameter, are formed. Microscopicly, they closely resemble true tubercles, but may be differentiated by the presence of the caterpillar hairs.

Amyloid, hyaline, and **colloid degeneration** of the conjunctiva are terms which have been applied to a local affection characterized by the deposit of a homogeneous material in the stroma of the conjunctiva. This nomenclature, based upon the affinity exhibited by the deposits for different dyes, has led to great confusion. It should be remembered that variation in staining properties of the products of degeneration does not necessarily indicate corresponding variation in the original pathologic process which led to the degeneration. It is, therefore, probable that these several names have been applied to one disease. It usually attacks young adults, and, as a rule, is unilateral. The highest development takes place in the loose tissue of the fornices. Histologicly, the epithelium is slightly increased in thickness as a result of edema. There is enormous hypertrophy of the adenoid layer, so that the conjunctival stroma appears to be converted into typic lymphoid tissue composed of a fine reticulum filled with round cells. The products of degeneration—amyloid, hyaline, or colloid—appear first among the round cells, but ultimately replace all the conjunctival tissues. The process terminates in calcification and ossification.

Syphilis.—Primary chancre of the conjunctiva is occasionally observed. Its favorite sites are the fornices and edges of the lids. Gumma may appear also upon the conjunctiva. Microscopicly, the alterations resemble syphilitic lesions in other mucous membranes.

Cases diagnosticated as **chancroid** of the conjunctiva have been described in medical literature (Foster).

Tuberculosis of the conjunctiva occurs as a primary, local infection. It is, therefore, usually unilateral. It follows inoculation with the tubercle bacillus. The bacilli probably cannot penetrate the unbroken

conjunctival epithelium. In advanced cases there is extensive ulceration, which is comparatively painless. Pannus may develop. Sattler's classification of this disease may be epitomized as follows:—

1. Small ulcers, which may caseate, usually situated upon the palpebral conjunctiva and folds of the fornices. The preauricular gland is almost never enlarged in this stage.

2. Gray or yellowish, subconjunctival granules closely resembling the "sago-grain" deposits in trachoma. They manifest little tendency to break down. Sections show giant-cell systems. These are followed by:—

3. Exuberant growth of the papillæ, swelling of the lids, mucopurulent secretion, and some breaking down of the tissues. Microscopicly, the tubercular deposits show caseation.

4. Characterized by cock's comb granulations. The granulations may form "pedunculated polypi," which project beyond the lids. Deep ulceration is present.

The description of class 4 applies to lupus. **Lupus** of the conjunctiva is secondary. It is usually an extension of nasal lupus through the lachrymal passages. Tuberculosis of the conjunctiva may be a mixed infection. Except in the first group of cases, the preauricular and cervical glands are enlarged. They frequently suppurate. It is possible to demonstrate tubercle bacilli in the conjunctival tissues.

In cases of **leprosy** the disease may appear at the limbus, although in the conjunctiva it is usually an extension from the skin.

Pemphigus of the eye may appear only upon the conjunctiva and cornea, or be associated with blebs upon the skin and mucous membranes. Owing to the delicacy of the conjunctival and corneal epithelium, the blebs are very ephemeral and, therefore, seldom observed before rupture. The cases are usually seen during the stage of denudation. The cicatrization which ensues converts the conjunctiva into scar-tissue, the shrinkage of which obliterates the transition folds and terminates in total symblepharon. Cases observed in the latter stage have been reported under the name of "essential shrinking of the conjunctiva." The exact nature of this affection remains to be demonstrated. The destruction of the conjunctival glands and occlusion of the lachrymal ducts by cicatricial contraction deprive the cornea of all moisture, so that keratosis and ulcerative keratitis result, even though no blebs formed upon the cornea.

Hemorrhages of the conjunctiva[1] occur as hemorrhagic infiltration of the episcleral or subconjunctival connective tissue (*ecchymoma subconjunctivale*); they are always limited to the *conjunctiva bulbi,* are partly of traumatic origin (in fractures of the skull, etc.; also in operations), partly the result of violent strain (in whooping-cough, vomiting,

[1] *Sugilatio* (from *subciliatio, sub ciliis*), first used for these subconjunctival hemorrhages, because, on closure of the lid, the hemorrhagic area disappears *sub ciliis.*

sneezing, etc.). Occurring spontaneously in persons over 40 years of age, they usually indicate arteriosclerosis. The hemorrhagic infiltrations form dark-red, sharply defined spots, which frequently extend close to the margin of the cornea and, after a time, completely disappear by absorption.

Nevi occur in the conjunctiva either as flat maculæ or as slightly elevated, red or brownish nodules. They nearly always contain pigment, which is found both within and between the cells of the growth, and also in the surface epithelium. The typic nevus resembles those observed in the skin. They are formed of ingrowing epithelial digitations and fibrous tissue stroma, the spaces of which are filled with the characteristic nevus cells. Nevi are benign growths, but possess an inherited tendency to intense malignancy. It must be remembered that melanotic spots occur normally in the conjunctivæ of colored races. Their presence in Caucasians is suggestive of malignancy. The pigment is deposited in the epithelium, between the cells, and in the subepithelial tissue.

The internal or local use of silver-salts sometimes results in staining of the conjunctiva: **argyrosis conjunctivæ.** The discoloration is principally due to staining of the elastic fibers, although granules of pigment are found free in the tissues.

Among the **tumors of the conjunctiva** are to be mentioned, first of all, the dermoid cysts. Sarcomata and carcinomata are less frequently observed; sometimes lipomata, angiomata, small cysts, etc.

Granulation-tissue tumors are frequent in the conjunctiva. Like most conjunctival growths, they manifest a tendency to become pedunculated. They result from irritation, injuries, operation wounds, imbedded foreign bodies, and, especially, broken-down chalazia.

Papillomata of the conjunctiva are most frequently situated near the inner canthus. They may, however, form in the tarsal folds or upon the bulbar conjunctiva. Histologicly, they are composed of branching stems of fibrous connective tissue covered with stratified epithelium. Although the relative proportion of cells to fibrous tissue varies within the widest limits, the greater part of the growth is usually epithelium. The blood-vessels have extremely thin walls and are situated in the fibrous tissue.

Fibromata are composed of fibrous tissue covered with epithelium. They are usually hard, though their consistency depends upon the compactness of the fibrous tissue. Sometimes they are edematous, and such cases have erroneously been called myxofibroma. They are differentiated from papillomata with excessive development of fibrous tissue by the character of the surface, which is smooth in fibroma and papilliform in papilloma.

Angiomata conjunctivæ (hemangiomata) occur most frequently at the inner angle on the *plica semilunaris* or caruncle, though they may appear upon any portion of the conjunctiva. Although they usually develop before the 20th year, they may be congenital. They consist chiefly of capillary blood-vessels held together by fibrous tissue. The relative hardness or softness of the growth depends upon the amount of fibrous tissue present. If fibrous tissue predominates, the tumor is called angiofibroma. In cavernous angioma, dilation and fusion of the blood-vessels occur. It is evident that angiomata closely approach fibromata. Angiosarcomata are differentiated from simple angiomata by the presence of sarcoma elements.

Fig. 508. — Congenital dermoid. Right eye. (After *Taliaferro.*)

Fig. 509. — Congenital dermoid showing hairs. Left eye. (After *Taliaferro.*)

In leukemic conditions, lymphomatous deposits sometimes occur in the conjunctiva.

Sarcoma of the conjunctiva occurs most commonly near the limbus, and is usually melanotic. The metastases, however, may or may not be pigmented. Sarcomata frequently develop from pigmented spots and nevi, those having the latter origin being very malignant. Melanosarcomata confined to the conjunctiva frequently do not recur after thorough removal. Epibulbar sarcoma grows in the conjunctiva, is freely movable upon the sclera, and rarely perforates the eyeball. The common round- and spindle- celled sarcomata occur here. So-called alveolar sarcomata or endotheliomata are more common. These develop from congenital nevi and consist of a fibrous connective-tissue stroma, arranged to form alveoli which are filled with nevus cells. By many pathologists they are considered to be epithelial in origin. If this view is established, they will be classed among the carcinomata.

The squamous-celled epithelioma is the most common form of **carcinoma** observed in the conjunctiva. It usually appears at the edges of the lids or at the limbus, frequently beginning as a papillomatous growth, and is often melanotic, the pigment being either autogenous or the result of hemorrhage. It generally invades the cornea, and, unlike epibulbar sarcoma, not infrequently perforates the globe, always at the sclerocorneal junction. Histologicly, epithelioma presents nothing characteristic of its location except pigmentation. Adenocarcinoma may develop from Krause's glands or from the glands of the caruncle. Carcinoma of Krause's glands presents the histologic features of adenocarcinoma of the lachrymal gland.

Dermoids (see Figs. 508 and 509) are not very infrequent in the conjunctiva and are often associated with malformations of the eye. Their favorite site is near the outer margin of the cornea. They form yellowish tumors containing the usual dermoid elements, particularly hair, fat, and epidermoidal tissues. They are small at birth, but commence to grow at puberty.

Unmixed fatty tumors of the conjunctiva (**lipomata**) are extremely rare. Congenital tumors which pass as such contain other tissues, particularly fibrous connective tissue. Therefore, they are now classed with the teratomata under the name of dermolipoma. These growths are usually situated a little distance from the cornea, between the attachments of the superior and external recti muscles. They are always congenital, but, owing to their position beneath the upper lid, they may escape observation until puberty, at which time they commence to grow. Girls appear to be more frequently affected than boys.

Epithelial plaques is a term applied to epithelial masses removed from the conjunctiva and cornea. Parsons regards them as the simplest expression of a dermoid, only the epithelial elements being represented.

Osteoma of the conjunctiva occurs in the same situation as dermolipoma. It is congenital and belongs to the teratomata.

Adenoma may develop from any glandular structure of the conjunctiva or caruncle.

Epicanthus is caused by the formation of a crescentic fold of skin, running from the eyebrow to the nose, overlapping the inner canthus.

Cysts of the conjunctiva originate from the lymphatics, surface epithelium, and conjunctival glands. Lymphatic cysts result from dilation of the lymph-vessels and are histologicly indistinguishable from lymphangiectases. They usually are observed upon the conjunctiva bulbi, where they form a rosary-like row of small, transparent vesicles which may coalesce. Excessive dilation of the lymphatics (**lymphangiectasis**) seldom results in the formation of large cysts.

Epithelial Cysts.—If surface epithelium is included in the conjunctival stroma, it may, by subsequent proliferation and degeneration, form either an epithelial tumor or a cyst. (See Fig. 510.) Confinement of surface epithelium in deep tissue occurs in various ways: it may proliferate inward in response to the stimulus of an inflammatory or other irritant; it may grow inward along the track of a wound or be carried in by violence; it may be separated from the surface by apposition and

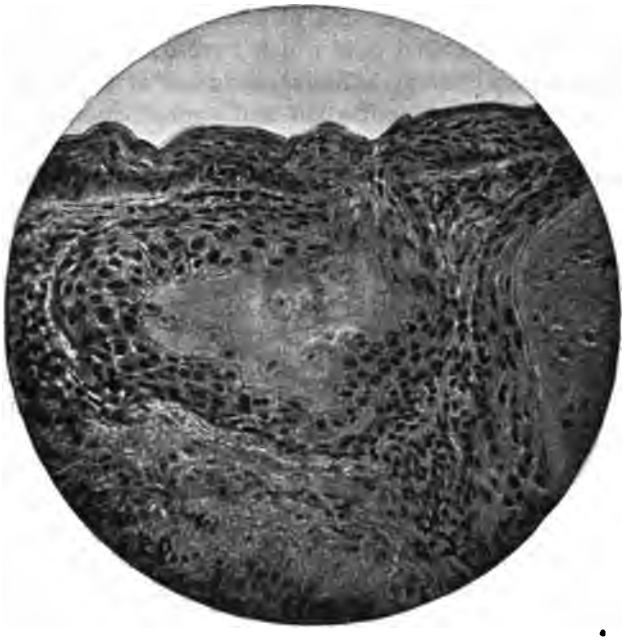

Fig. 510.—Epithelial cystoma of conjunctiva. The cyst is created by mucoid degeneration of the central cells in a mass of ingrown epithelium. (After photomicrograph by *E. L. Oatman, M.D.*)

agglutination of conjunctival folds, as after the operation of trachoma expression. There is reason to believe that epithelial inclusions occur congenitally. When isolated, conjunctival epithelium creates a cyst; the histologic character is determined by the particular form of degeneration which the epithelial cells undergo, such as mucoid, serous, etc. When only slight degeneration of the ingrowing epithelium takes place, the growth may be mistaken for epithelioma. These formations are conveniently grouped under the name of epithelial cystomata of the conjunctiva. Glandular cysts form in the so-called Henle glands and in the accessory lachrymal (Krause's) glands. They result from inflam-

matory or traumatic obstruction of the gland outlets. Cysts may occur in the gland-like conjunctival folds formed in trachoma.

Parasitic cysts occasionally form in the conjunctiva. Those resulting from *Cysticercus cellulosæ* and *filariæ* are most frequently observed. Hydatid cysts of the orbit may extend to the conjunctiva. Cysts may form in pterygia, dermoids, nevi, etc.

Inclusion Cysts.—Under this title Oatman has described a form of epithelial-lined cysts which appear upon the conjunctiva after traumatism, especially after the operation of trachoma expression. Evidently, they develop from epithelial cells which have been segregated from the surface epithelium, either by adhesive occlusion at the mouth of a conjunctival crypt or by approximation and agglutination of conjunctival folds.

Edema of the conjunctiva is usually a symptom, although cases have been described which were supposed to result solely from vasomotor disturbances. Spicer reports a number of cases caused by lymph obstruction. They were associated with tonsillitis and enlargement of the lymphatic glands. Solid thickening of the conjunctiva may occur in myxedema.

Emphysema may appear in the conjunctiva in association with emphysema of the lids, resulting from fractures communicating with the air passages.

LACHRYMAL ORGANS.

The lachrymal organs are composed of the lachrymal gland (*glandula lacrimalis*) and the excretory channels, namely, two lachrymal puncta (*puncta lacrimalis*) at the inner angle of the eye (one each on the free margin of the upper and lower lid), two lachrymal canaliculi (*canaliculi lacrimalis*) originating therefrom, one lachrymal sac at the inner angle of the eye (*saccus lacrimalis*) formed by confluence of both lachrymal canaliculi, and one nasal duct (*ductus lacrimalis*) which opens into the nasal cavity below the middle turbinate.

The canaliculi are lined with stratified squamous epithelium. Their walls are rich in elastic connective tissue and striated muscle-fibers. The lachrymal sac and duct are lined with a double layer of columnar epithelium. The *tunica propria* is mostly adenoid tissue. External to this is a dense venous plexus. The lachrymal sac is partly and the duct entirely surrounded by bone. The mucous membrane of the duct is supplied with acinous glands. It forms several valve-like folds, the largest of which is situated at the nasal outlet and is known as Hasner's valve.

The lachrymal fluid is poor in solid constituents. The secretion is increased by emotional excitation, in irritation of the eye by foreign bodies, and in many forms of inflammation of the eye; it is diminished in cicatrizations of the conjunctiva, with and without adhesions; in xerosis and after removal of the sac. No lachrymal fluid is secreted during the first days of life. The lachrymal fluid is conducted into the lachrymal puncta essentially by nictitation, the

fluid being pressed into the puncta on closure of the lids. In nictitation closure of the lids begins at the external canthus and ends at the internal canthus. The contraction of the orbicularis muscle draws the palpebral ligament toward the eye; this opens the puncta by relaxing and shortening the canaliculi. By the same act the anterior wall of the sac is lifted from its groove, whereby a suction-like action is exerted upon the lachrymal fluid. Probably, the sac always contains a small quantity of fluid. Any excess is forced into the nose by the natural elasticity of the sac walls. Another factor is the gentle compression exerted upon the sac by the dense venous plexus which envelops it. This force equals the normal blood-pressure in the veins; in the lachrymal grooves, where the plexus is interposed between the lachrymal apparatus and the bone, the pressure is exerted wholly against the sac and duct. As only a small amount of fluid is generally secreted, the fatted margins of the lid prevent overflowing. Overflowing occurs, however, when more fluid is secreted than can be carried off through the lachrymal channels, and also when the channels are narrowed or completely occluded. Persistent disturbance in the flow of the lachrymal fluid through the natural channels occurs also in incomplete closure of the lids as a result of paralysis of the orbicularis; in ectropion with eversion of the lachrymal puncta, and in chronic blepharitis with cicatrization and shortening of the lids, because in these conditions the lachrymal fluid can no longer enter the lachrymal puncta.

When the lachrymal fluid is forced through the puncta into the lachrymal channel, but cannot flow into the nasal cavity because the nasal duct has for some cause become obstructed, the lachrymal sac fills and gradually distends. As, at the same time, dust, bacteria, etc., present upon the conjunctiva and cornea also enter the lachrymal sac along with the lachrymal fluid, an **acute purulent catarrh of the lachrymal sac**: *blennorrhœa sacci lacrimalis, dacryocystitis blennorrhœica* or *purulenta,* usually develops.

Narrowing or **occlusion of the nasal duct** is most frequently due to pathologic processes in the nasal cavity: intense swelling of the mucous membrane in coryza; cicatrization in consequence of atrophic rhinitis, scrofulous, syphilitic, and other ulcers; tumors (especially polypi); seldomer varices, bone affections, etc.

Catarrh of the nasal duct is at first accompanied by a purulent exudate; later, when the process has become chronic, which is almost always the case, by a mucoid, and, finally, a more or less thin, watery secretion. The distention of the lachrymal sac, even though the cause of the narrowing in the nasal duct has ceased to exist (either spontaneously or by artificial means), may become purulent: *dilatio sacci lacrimalis* (so-called **atony**). In complete atony of the sac the lachrymal fluid does not pass into the nose, even though the duct is pervious. If the distention attains large dimensions, the condition is called *hydrops sacci lacrimalis.* The distention is sometimes very great. The sac may bulge forward or push backward into the orbit and has been said to displace the eyeball.

Blennorrhea of the lachrymal sac is sometimes followed by an acute purulent inflammation of the surrounding parts, which may extend to and rupture through the external skin: **paradacryocystitis** (also tersely called dacryocystitis). At first the discharge is purely purulent; later, when the acute inflammation has subsided, a watery fluid, *i.e.*, the lachrymal secretion which is pressed through the tear puncta, is discharged. In this manner a **lachrymal fistula** is established.

Sometimes the canaliculi fail to unite, wholly or in part, as the result of congenital abnormalities. In such cases the defective portion is represented by grooves. If the gaps are very small they pass for supernumerary puncta. The grooves may close completely, in which case no puncta exist. The canaliculi may be altogether absent. Very rarely the fetal groove, which develops into the lachrymal sac and duct, fails to close, resulting in congenital lachrymal fistula. A more frequent anomaly is congenital stricture of the lachrymal duct.

Inflammation of the lachrymal gland, **dacryoadenitis**, is very rare. It may be acute or chronic. The acute form may result from injury or infection by conjunctival secretions. It has been observed also in connection with influenza, variola, leukemia, diphtheria, gonorrhea, and mumps. The chronic form may result from trauma or local infection from the cornea or conjunctiva. Dacryoadenitis may terminate in resolution or suppuration. Acute purulent inflammation with rupture externally has occasionally been observed. In general tuberculosis the lachrymal gland is sometimes, though rarely, affected.

Fistula may be congenital or follow abscess.

Cystic dilation of the excretory duct, **dacryops**, is somewhat more frequent than inflammation. It is due to obstruction of outflow, usually to occlusion (by calculus, proliferation).

Hypertrophy usually occurs in childhood, but it may be congenital. It has been known to destroy vision by compression and displacement of the eye and optic nerve. Chronic enlargement of the gland in adults is generally syphilitic.

Atrophy of the lachrymal gland occurs in xerophthalmus, and is said to follow extirpation of the lachrymal sac. The secretion of tears is sometimes abolished in paralysis of the trigeminus and in facial paralysis.

Dislocation of the gland is rare. It may be caused by trauma or retrobulbar abscess, or occur spontaneously.

Tumors seldom develop from the lachrymal organs. They are frequently mixed growths. Carcinoma, sarcoma, myxoma, myxadenoma, myxosarcoma, enchondroma, osteochondroma, osteoma, fibroma,

adenoma, adenoangioma, lymphoma, cylindroma, conglomerate tubercle, and hydatid cysts have been observed.

THE CORNEA.

The cornea merges with the sclera at the *limbus corneæ*, forming, as it were, a continuation of the sclera to the anterior portion of the eye. Unlike the sclera, it is nonvascular (except the marginal plexus). In this respect as well as in the form of the large, branching, anastomosing cells—the so-called corneal corpuscles—it resembles the intima of the aorta. It differs from the intima, however, by the fact that the intercellular substance, consisting of striated, intimately interlacing bundles, is arranged in lamellæ between which the corneal corpuscles are placed, and is united by a cement substance to form an almost homogeneous mass: the *substantia propria*. Both in front of and behind the cornea lie homogeneous membranes: Bowman's (anteriorly) and Descemet's[1] (posteriorly). Upon the cornea are situated anteriorly several layers of squamous lamellated epithelium, and posteriorly a single layer of endothelial cells.

Accordingly, the perfectly transparent parenchyma of the cornea is formed chiefly of the corneal lamellæ and the corneal corpuscles. A stroma composed principally of vessels and connective tissue, as in the kidneys, etc., is absent. This explains in part the variation in the designation of different pathologic processes of the cornea.

The different layers of the cornea correspond embryologicly to other parts of the eye as follows:—

(*a*) The corneal epithelium, to the conjunctiva.

(*b*) The *substantia propria* and Bowman's membrane, to the sclera.

(*c*) Descemet's membrane and the endothelium, to the uveal tract.

This relation of parts is illustrated by the frequent extension of pathologic processes from one of these subdivisions to its analogue.

The corneal epithelium is distinguished by the following peculiarities: (*a*) there are no papillæ; (*b*) the superficial cells are flat and contain oval horizontal nuclei; (*c*) the middle layer is formed of prickle cells, which permit free circulation of lymph; (*d*) the basal layer is composed of sharply contoured cylindric cells, the nuclei of which are distally situated and do not stain more intensely than in the other layers.

The *substantia propria* constitutes the bulk of the cornea. It is composed of delicate, parallel fibers united into bundles, and these are formed into flat lamellæ. The lamellæ run parallel with the surface of the cornea and are arranged in alternating layers crossing each other at right angles. A few bundles running obliquely are called arcuate fibers. The *substantia propria* is traversed by an intercommunicating system of canaliculi and lymph-spaces (lacunæ) containing wandering cells and the fixed corneal corpuscles, which are differentiated connective-tissue cells. The wandering cells are derived from the blood-vessels.

Bowman's membrane is modified *substantia propria* tissue.

Descemet's membrane is a product of the endothelial cells which line the posterior surface of the cornea. The endothelial cells are a continuation of the cells covering the ciliary body, iris, and *ligamentum pectinatum iridis*.

[1] In its chemic and physic characters, Descemet's membrane was formerly supposed to be closely related to elastic tissue. This view, however, is no longer entertained, since it does not give the specific reactions of elastic tissue.

The cornea is nourished by a transudate from a system of minute vascular loops which penetrate the corneal periphery for a distance of from 0.5 to 1.5 mm. This peripheral zone is always preserved, even in the most advanced cases of corneal necrosis. Surrounding the cornea, in the sclera, is a nerve plexus known as the *plexus annularis*. From it branches are distributed to the conjunctiva and cornea, those entering the cornea losing their medullary sheaths and continuing as bare axis-cylinders. They form networks designated, according to their location, as the stroma plexus, subbasal plexus, subepithelial plexus, and intraepithelial plexus. The latter is made up of very delicate nerve fibrillæ, many of which terminate in free ends between the more superficial cells.

Keratomalacia (xerotic keratitis, infantile ulceration of the cornea) occurs chiefly in children affected with marasmus, especially asylum infants. *Torpor retinæ* is usually present. The appearance of extreme dryness presented by the cornea in this disease is due to fatty degeneration of the corneal epithelium, which prevents the lachrymal secretion from

Fig. 511.—Arcus senilis. (After *Canton.*)

adhering to the corneal surface. If life is sufficiently prolonged, ulceration and hypopyon develop. Of the various micro-organisms present, none is regarded as causative.

Histologicly closely related to parenchymatous keratitis is *arcus senilis, malum senile corneæ* (gorontoxon[1]), in which process also there is no cellular increase in the cornea. As the name indicates, **arcus senilis** is an affection of old age and consists in a simple, noninflammatory nutritive disturbance of the corneal corpuscles (usually most marked in the superficial layers), which is said finally to terminate in fatty metamorphosis.[2] This metamorphosis of the corneal corpuscles is always more marked in the upper and lower portions of the cornea, which are usually more or less covered by the lids. The affected portion forms a crescent-shaped area running parallel with the unaltered margin of the cor-

[1] From γέρων = aged person, and τόξον = bow.

[2] It is by no means certain that the granules which cause the opacity in *arcus senilis* are fat, because they fail to give with selective stains the usual reactions of animal fat. Nevertheless, many recent writers adhere to the view that they are fat. Parsons says: "*Arcus senilis* is probably a fatty degeneration of the *substantia propria* . . . the exact chemic nature of the fatty material being undetermined." The entire cornea is encircled by the process. Its relation to fatty degeneration in other organs has not been established.

nea. It is sharply defined and gradually merges with unaltered tissue toward the center of the cornea (see Fig. 511), causing a gray or grayish-yellow opacity of the altered parts.

Congenital opacities of the cornea may result from prenatal inflammation. They do not differ from opacities occurring from the same cause after birth. *Arcus juvenalis* (fetal ring, embryotoxon; sclerophthalmus, when complete) is a noninflammatory congenital opacity of the cornea which extends inward from the sclera, forming an incomplete ring or involving the entire circumference. It varies in degree from a bluish-white cloudiness to a dense, pearly opacity, no clear cornea being present between it and the sclera, in which respect it differs from *arcus senilis.* The condition may occur in eyes otherwise normal or be associated with various malformations. There is a widespread belief in its inflammatory origin, but the absence of blood-vessels and inflammatory changes renders this view improbable. It is more reasonably explained as an arrest of the embryologic process of differentiation which takes place between the cornea and the sclera.

Marginal atrophy and **sclerosis** (Fuchs) usually occur in eyes affected with *arcus senilis,* although a somewhat similar condition is observed also in the young. In the senile type the arcus and transparent circle of cornea between it and the sclera become greatly thinned, forming a peripheral furrow. In advanced cases the furrow yields to intraocular pressure and becomes ectatic. Ulceration does not occur. The single case examined microscopicly was complicated with glaucoma. The pathologic changes were confined to the anterior lamellæ of the cornea, which were largely degenerated. Bowman's membrane was destroyed. The affected area was very vascular, although no cellular infiltration or other evidence of inflammation was present. The external surface was covered with thick layers of conjunctival (not corneal!) epithelium. A similar process has been described by Terrien as *"dystrophie marginale."* Chronic peripheral furrow keratitis (Schmidt-Rimpler) occurs inside of the arcus or corneal opacity.

Keratitis marginalis profunda (Fuchs) usually attacks the aged and, as a rule, is unilateral. The cornea contains a deep-gray or yellow opacity, which involves about one-third, rarely the whole, of its periphery. It extends directly from the sclera into the cornea for a distance of about 2 mm. Vessels from the limbus soon cover the opacity. The corneal surface is dull, but, as a rule, there is no loss of epithelium. Fuchs has very rarely observed small superficial ulcers. The symptoms of irritation subside, but a permanent opacity of the cornea remains. It differs from *arcus senilis* by the absence of transparent cornea between it and the sclera.

Sclerosing keratitis is a term usually applied to an extension of scleritis into the cornea. A similar condition is sometimes seen in tuberculosis of the cornea. The corneal opacity is triangular in form with the base at the limbus. Isolated central opacities and uveitis may also be present. Ulceration does not take place. Recurring attacks may cause general opacity of the cornea. The process is characterized by an infiltration of the cornea by round cells which subsequently undergo organization into fibrous connective tissue. A violent type of combined scleritis, keratitis, and uveitis is described by de Schweinitz under the name of **sclerokeratoiritis.** This may occur as a bilateral disease and terminate in blindness.

Almost all other changes of the cornea, with exception of a small group of superficial processes, are accompanied by cellular proliferations—the so-called corneal infiltrations of ophthalmologists. The proliferation always begins in the neighborhood of the corneal corpuscles between the corneal lamellæ—in the region of the strongest flow of lymph. At present it cannot with certainty be stated in every case to what degree the corneal corpuscles themselves are involved in the cellular increase.

Those processes which result in the formation of pus[1] and purulent softening are usually designated as purulent keratitis; those accompanied by cellular increase are described as nonpurulent or interstitial keratitis. (See p. 985.)

Acute interstitial keratitis, usually called purulent keratitis, occurs independently (after trauma; also without demonstrable cause), and also as a result of other affections (*e.g.*, in blennorrhea, variola, typhoid, etc.), and is probably always due to infection.[2] The

[1] Here so-called wandering cells migrate into the cornea from the corneal margin. These wandering cells, first observed by von Recklinghausen, are not derivatives of the fixed corneal corpuscles. According to Leber, the presence of micro-organisms in the cornea causes a localized necrosis, the toxic products circulating in the cornea acting on the peripheral blood-vessels; vascular dilation and emigration of leucocytes follow, the leucocytes being attracted to the point of injury by positive chemotaxis. The leucocytes accumulate in the lymph-spaces, forming rows of elongated cells extending in every direction. They are known as inflammatory spindles. The changes occurring in the fixed corpuscles are connected with the processes of corneal regeneration.

[2] Hence the designation *keratitis mycotica.* Although a great variety of micro-organisms enter the conjunctival sac, it is doubtful if any of them are capable of penetrating the unaltered epithelial layer of the cornea. The gonococcus and diphtheria bacillus are said to possess this power. It is true that ulcer of the cornea occurs more frequently in purulent (gonorrheal) than in other forms of conjunctivitis. This, however, may be due to the fact that it is the most violent type of inflammation to which the conjunctiva is liable and, consequently, interferes most with the corneal circulation. This lessens the cohesive power of the epithelium, the superficial layers of which may desquamate or be dislodged without the slightest diminution in the transparency of the cornea. The epithelial barrier once removed, bacteria penetrate the cornea without difficulty. As a matter of fact, destruction of the cornea in purulent conjunctivitis depends upon the presence of micro-organisms other than the gonococcus and Klebs-Löffler bacillus. It would appear impossible to demonstrate that, in any given case, the gonococcus had perforated the unbroken corneal epithelium.

first visible changes of the cornea: gray-yellow opacities, are due to gradually increasing purulent infiltration, which either resolves or, what is more frequent, results in purulent softening. In the latter case, if the altered part is superficial, an ulcer develops;[1] if it is surrounded on all sides by intact corneal tissue, a corneal abscess[2] forms, which, after a time, is always converted into an ulcer, the anterior corneal lamellæ gradually breaking down. In the cornea, as elsewhere in the body, inflammatory exudates may be absorbed or progress to softening and tissue necrosis. The margins of a fresh ulcer are sometimes steep, sometimes flat, generally cloudy and infiltrated with pus. Later they may become cleansed, so that the ulcer remains confined in extent, or they manifest a tendency to progressively disintegrate. The ulcer then gradually spreads and an *ulcus corneæ serpens* develops. In corneal ulcer the superficial epithelium and Bowman's membrane are destroyed for some distance beyond its apparent margin. The surrounding cornea becomes edematous and overhanging. The adjacent corneal epithelium undergoes the most active proliferation in the effort to fill in the gap produced by loss of tissue. These proliferating cells may spread over the entire area of ulceration and even penetrate between the corneal lamellæ. They are, however, cast off with the sequestrum. If Descemet's membrane is intact, the concomitant uveitis cannot be attributed to bacterial invasion, but to chemotaxis. When the chemotaxis is intense, large numbers of leucocytes migrate from the vessels of the ciliary body and iris and are carried forward by the aqueous into the anterior chamber, where they gravitate to the most dependent portion, forming hypopyon (*q.v.*, p. 983). Hypopyon occurring in suppurative and many other forms of keratitis must not be confounded with the complex of symptoms constituting serpiginous or hypopyon ulcer. The stage of regeneration is indicated by separation of the slough, disappearance of the gray zone of infiltration, and the advent of blood-vessels upon the cornea, extending from the limbus to the margin of the ulcer.

In **traumatic keratitis** the purulent infiltration generally begins within the injured area in the deeper layers of the cornea. Not every trauma, however, causes keratitis; superficial injuries frequently involve only the epithelium (erosion), the loss being rapidly replaced by new epithelium. Deeper wounds also often heal without the development of keratitis. The danger of every injury depends, firstly, upon infection of the corneal wound, and, secondly, upon perforation of the cornea,

[1] The chief bacterial representative of corneal ulcer is the pneumococcus. Corneal ulcer may be caused also by the *Bacillus fluorescens liquefaciens*, terminating in panophthalmitis; the *Bacillus pyocyaneus*, streptococci, and actinomyces.

[2] According to Horner, true abscess formation with fluid pus does not occur in the cornea.

whether primary or secondary to purulent keratitis. The alterations caused by burns, corrosion, etc., behave in an entirely analogous manner.

When the ulcerative process extends into the depth, perforation of the cornea may result. Before this occurs, the posterior elastic (Descemet's) membrane is sometimes strongly pushed forward and then forms a sort of vesicle: keratocele (from κήλη = hernia).

With occurrence of perforation of the cornea the aqueous generally escapes, so that the iris comes in contact with the posterior surface of the cornea and the anterior chamber disappears. In large perforations, sudden discharge under strong pressure, etc., the iris and lens may reach the exterior with the aqueous: *prolapsus iridis, luxatio lentis.* Under favorable conditions the perforation closes and the anterior chamber is restored, new aqueous being elaborated. Usually, however, adhesion of the iris to the posterior surface of the cornea occurs at the margin of the wound: *synechia anterior* (also *leucoma adherens*). In many cases this is accompanied by bulging of the eye in the region of the corneal wound: corneal staphyloma (σταφυλή = grape). The protrusion involves either the whole cornea: total staphyloma, or only a part: partial corneal staphyloma. In every instance the protruded portion is composed of opaque cicatricial tissue, which develops from the iris (not cornea! hence, more exact, *staphyloma iridis*), and, therefore, is always more or less dark in color (mottled, slaty, bluish). The bulging portion is either rounded in form (*staphyloma sphæricum,* especially in total staphyloma), wedge-shaped (*staphyloma conicum*) or manifoldly constricted (*staphyloma racemosum,* blackberry form). In total staphyloma the anterior chamber is always lacking, owing to complete prolapse of the iris. Adhesions of the prolapsed iris to the margin of the corneal wound with bulging of the cornea (primary staphyloma) do not always occur in staphyloma, but often a flat cicatrization without protrusion is observed. Here also, however, subsequent bulging (secondary staphyloma) occurs in some cases, when the cicatricial tissue is fresh and thin and, therefore, still elastic.[1] On the other hand, under favorable conditions primary staphyloma also may disappear by subsequent cicatricial retraction (secondary flat cicatrization).

After perforation of the cornea, especially after section for cataract or iridectomy, a small fold of iris may remain fixed in the wound. This is quickly covered with epithelium, and, in favorable cases, a firm cicatrix results. At other times the cicatrix is too weak to withstand the intraocular pressure, and a small area protrudes forward. This condition is known as cystoid cicatrix. The ectatic area consists of cicatricial iris tissue covered with epithelium. The increased tension which causes staphylomatous conditions of the cornea is induced largely by the completely prolapsed iris,[2] which obliterates the anterior chamber. The aqueous, therefore, cannot reach the angle of filtration and, consequently, the tension of the eye is raised.

In rare cases a **corneal fistula** develops from corneal perforation when the latter does not close. Corneal fistula is a small opening in the cornea through which aqueous humor constantly flows. According

[1] In increase of intraocular pressure, on great exertion, screaming, sneezing, etc.

[2] According to some authorities, only in prolapse approaching the complete.

to Czermack, fistula follows adhesion of the iris to the edge of a corneal wound. The movements of the iris prevent union by traction upon the point of attachment and upon the wound. Union is interfered with also by the surface epithelium, which extends into a fistulous tract.

After it has become cleansed, a nonperforated corneal ulcer heals by gradual filling of the defect by dense, opaque cicatricial tissue. In small, shallow ulcers the defect not infrequently is only incompletely filled up, so that very small, flat, temporary depressions develop: **plane cicatrices, corneal facettes,** which are not opaque, and, therefore, are recognizable only on focal illumination of the cornea. When the ulcer extends far into the depth, the deep corneal lamellæ with Descemet's membrane are pushed forward by intraocular pressure (*hernia corneæ*). This protrusion may be compensated by cicatricial retraction; in other cases it is permanent; then a condition develops which has a certain resemblance to corneal staphyloma, but differs from the latter by the fact that the protruded parts do not consist of a cicatricial iris-tissue, but of cicatricial corneal tissue: *keratoectasia ex ulcere* (so-called ectatic cicatrix). In every deep corneal ulcer the anterior (Bowman's) membrane disappears throughout the whole area in which loss of substance has occurred, and this may be important in differential diagnosis. In cases due to ulceration the ectasis is limited to the site of the ulcer; if due to interstitial keratitis, the entire cornea is involved. In postulcerative cases the protrusion is opaque, while in keratoconus and keratoglobus (*q.v.*, p. 988) it is usually transparent. Histologicly, the ectasis is composed of thickened epithelium and condensed corneal lamellæ. In postulcerative cases Bowman's membrane has been destroyed and the epithelium rests upon scar-tissue. Descemet's membrane remains intact, but may be wrinkled. Degenerative changes in the *substantia propria* are common. In extreme cases rupture may occur.

Acute purulent keratitis is always accompanied by certain changes in the adjacent tissues. Constant concomitant symptoms are intense ciliary and conjunctival injection and inflammatory edema of the conjunctiva. Far more important are the changes in the anterior chamber and iris, perceptible also *post mortem:* iritis, hypopyon, iridocyclitis.

Hypopyon[1] (ὑπό and πυον = pus) is the accumulation of a purulent exudate in the anterior chamber; the aqueous is thus rendered cloudy. (See Fig. 512.) The purulent exudate is derived from the iris, ciliary body, and, according to certain authors, also from the cornea. It may disappear by absorption, or be deposited upon the surface of the anterior

[1] Because the pus sinks and occupies the deepest, usually the lowermost, portion of the anterior chamber.

chamber, where it may become organized and cause closure of the pupil or anterior synechiæ.

Hypopyon ulcer (serpiginous ulcer) is a severe form of keratouveitis characterized by a tendency of the corneal ulcer to spread over the surface of the cornea, and by the severity of the iridocyclitis. Uhthoff and Axenfeld have shown that typic cases result from a local pneumococcous infection. Atypic forms are due to infection with other organisms. Well-marked cases do not occur in children. The cornea at the margin of the ulcer usually contains a yellow, crescentic- or wedge-shaped infiltrate, which precedes the advancing necrosis. The entire cornea is edematous. Two kinds of striæ are observed in hypopyon ulcer: those consisting of delicate lines that branch or cross each other are due to leucocytic infiltration of the corneal lymph-spaces; the straight, unbranching striæ, according to Schirmer, are produced by wrinkling of



Fig. 512.—Hypopyon, seen from the front, and in section, to show that the pus is behind the cornea.

Descemet's membrane. Masses of pneumococci are found in the necrotic area, particularly beneath the overhanging margin. A mixed infection modifies the history and pathology of the ulcer. The iritis in hypopyon ulcer is violent, and synechiæ form early. It is now generally conceded that the leucocytes constituting the hypopyon are derived from the iris and ciliary body, particularly the latter. Serpiginous ulcer tends to increase in superficial area rather than in depth. Perforation is preceded by the formation of a dense area of infiltration, situated upon the outer surface of Descemet's membrane beneath the surface ulcer, known as the posterior abscess. Early perforation occasionally takes place without the formation of the posterior abscess, especially if the eye is glaucomatous. Panophthalmitis may follow perforation, particularly where the streptococcus is added to pneumococcous infection.

By some authors (Fuchs and others) *keratitis e lagophthalmo*[1] is

[1] By lagophthalmus (λαγώς = hare, because it was believed that hares sleep with open eyes) is designated the incomplete closure of the palpebral fissure on closure of the lids. This incomplete closure occurs in shortening of the lids, ectropium, paralysis of the orbicularis, enlargement and protrusion of the globe (*e.g.*, in tumors, Basedow's disease, etc.).

described as a special form of purulent keratitis. In this condition chiefly the lower half of the cornea is changed, because this portion of the cornea —especially during sleep, when the lids are at rest and the cornea is directed upward—is uncovered, and, therefore, is exposed to evaporation and injury. Ulceration almost always follows the desiccation from this defect in covering.

Closely allied to this form of keratitis is so-called **neuroparalytic keratitis,** occurring in paralysis of the trigeminus, particularly when the Gasserian ganglion is diseased or has been removed. The cornea being insensitive, particles of dust reaching it are not removed by nictitation; neither are injuries noted. The pathologic process is a desiccation rather than an inflammation. The epithelial covering becomes dermoid and is cast off, necrosis of the *substantia propria* following. Majendie and many other authors regard the changes as the result of trophic disturbance (fifth nerve), while others consider them to be due wholly to mechanic injury and dryness following loss of sensation and diminished lachrymal secretion.

Dystrophy of the corneal epithelium[1] is a condition occurring in the aged, usually in females, affecting one or both eyes. The cornea loses sensibility. Superficial opacity develops, especially in the pupillary area. Fine vesicles form upon the surface, which becomes roughened. Glaucoma may or may not coexist, but the condition differs from glaucomatous degenerations of the cornea. The opacity increases and new tissue forms between Bowman's membrane and the epithelium.

Interstitial keratitis[2] **(chronic, nonpurulent)** is characterized by a small-celled proliferation of the middle and deeper lamellæ, which results in the formation of light-gray, ill-defined, opaque spots. The opacities may first appear in the center of the cornea or begin at the margin and extend to the center of the cornea. The *limbus corneæ* is swollen and the episcleral vessels strongly injected. New formation of vessels

---

[1] Arch. f. Ophth., lxxvi, No. 3.

[2] This process is designated by some ophthalmologists as *keratitis parenchymatosa.* This Schweigger considers incorrect, because all processes of the cornea start from the parenchyma. It might, perhaps, be advisable to employ the designation parenchymatous keratitis for the process first observed and thus described by Virchow, because in this condition the same changes can be recognized in the corneal parenchyma as in the parenchyma of other organs (liver, kidneys, etc.) in parenchymatous inflammation. Then the designation interstitial keratitis, entirely analogous to the same changes of other organs, could appropriately be applied to all processes accompanied by cellular proliferation, no matter whether they are of an acute (purulent) or chronic nature (connective-tissue formation). In a part of these processes the homogeneous, transparent character of the lamellæ is lost; they become fibrillar and histologicly indistinguishable from ordinary fibrillated connective tissue. In another portion true vascular connective tissue grows from the margin into the cornea, and in the purulent processes the pus-corpuscles also enter the cornea from the surrounding vessels.

may occur in the parenchyma of the cornea, starting from the corneal margin. This is generally confined to the margin; sometimes, however, it advances to the center of the cornea, imparting to it a reddish, almost fleshy appearance. In the mildest cases new formation of vessels is lacking; then the opacity generally gradually disappears from the margin inward. Severe cases accompanied by new formation of vessels always result in a permanent and more or less distinct opacity, the intercellular substance of the cornea acquiring a striated, fibrillated character.

This affection occurs almost exclusively in young individuals up to the age of 20 years. As a rule, both eyes are involved, though not at the same time. The most frequent cause is said to be congenital syphilis. The course of this disease is always chronic and generally extends over a number of months. Besides the permanent opacity, which results in many cases, there is a certain danger from the accompanying iritis, which may easily cause adhesion of the pupillary margin of the iris to the lens capsule (so-called posterior synechiæ).

Inflammatory changes situated in the deep parenchyma of the cornea, unattended by ulceration, are usually, but not invariably, the result of constitutional syphilis. As the disease is amenable to treatment, opportunities rarely occur to examine the affected corneæ microscopicly. In a case recently examined by Elschnig, the following changes were observed: swelling of the cornea; division of the fixed cells, and appearance in the lymph-spaces of irregular nuclei and a few round cells. The cells were swollen and the nuclei destroyed, while the lymph-spaces were distended with granular detritus. There was some necrosis of lamellæ. Repair took place through proliferation of the fixed cells, with or without formation of blood-vessels. Reparative material and true giant cells accumulate beneath Bowman's and Descemet's membranes. Interstitial keratitis is usually, if not always, associated with inflammation of the ciliary body or choroid. The absence of ulceration may be ascribed to the presence of blood-vessels in the cornea. Tubercular keratitis resembles histologicly the interstitial keratitis of syphilis.

Syphilis of the cornea usually appears as interstitial keratitis. Rarely, however, gummata of the uvea may invade the cornea.

Phlyctenular keratitis. This form is frequently associated with phlyctenular conjunctivitis and consists in a superficial process which begins with an accumulation of small round cells beneath the epithelium. So-called phlyctenulæ are thus produced: slight opaque elevations, the size of a poppy- or millet- seed, upon the cornea. (See *Conjunctivitis phlyctænulosus,* p. 963.) These accumulations of round cells may be absorbed, or, after exfoliation of the epithelium, result in the formation of quite small, flat ulcers, which may heal without cicatrization. Frequently, however, the process extends into the substantia propria, causing true ulceration. These ulcers heal from the margin by vascularization and cicatrization. Occasionally progressive ulceration, hypopyon, and perforations of the cornea follow. This affection, like phlyctenular conjunctivitis, occurs especially in young scrofulous individuals, and, like

scrofulous affections, is characterized by a great tendency to frequent relapses.

When phlyctenulæ develop at the limbus of the cornea, the process is designated as marginal keratitis, or *conjunctivitis phlyctænulosa miliaris.* (See p. 964.)

Another form of chronic keratitis is **keratitis pannosa** (πάνος = rag, cloth). This consists in the formation of a young, delicate, richly cellular and highly vascular granulation tissue, which is always accompanied by an affection of the conjunctiva, and, at first at least, always occurs in the superficial portion of the cornea (*keratitis superficialis*). Those diseases of the conjunctiva which precede pannus are *conjunctivitis trachomatosa* and *conjunctivitis phlyctænulosa.* Accordingly, *pannus trachomatosus* (see p. 959) and *phlyctænulosus* are differentiated.

Whenever phlyctenular keratitis heals by vascularization, *pannus phlyctænulosus* develops, which may result in permanent opacity of the affected parts. When relapses occur, new eruptions very frequently are observed in the region of the scars: cicatricial keratitis.

Pannus always begins at the corneal margin and extends from there to the cornea, that is, toward the center of the cornea as well as into the deeper corneal lamellæ. The surface of the corneal parts thus altered is always somewhat uneven and the seat of a gray or reddish-gray opacity.

In fresh cases, when little or no intercellular substance has as yet formed, complete restoration may take place; later, the possibility of a *restitutio ad integrum* ceases. Numerous spindle cells and fibrillated intercellular substance—whitish-gray connective tissue—are then observed, which cause a permanent opacity of the cornea. The new-formed vessels, which at first may be very numerous (*pannus vasculosus*), later disappear in great part.

The term **pannus** was formerly employed to designate any vascularity of the cornea. At present its use is restricted to: (1) the vascular keratitis of trachoma (*pannus trachomatosus*); (2) a form of phlyctenular keratitis in which the exudate, instead of forming a discrete focus, appears as a continuous plaque of vascular tissue upon the cornea (*pannus phlyctænulosus* or *eczematosus*); (3) a vascular keratitis occurring in a blind degenerating eye (*pannus degenerativus*). By far the most frequent and important of these is *pannus trachomatosus.* This form always appears first in the upper portion of the cornea. Its location is explained by the fact that the upper lid is always in contact with this portion of the cornea, which, consequently, is subjected to constant friction by the trachoma granules. That this results in direct infection of the cornea with trachoma virus is shown by the fact that pannus is not produced by mechanic friction of a lid the tarsal surface of which is roughened or cicatrized from causes other than trachoma. Furthermore, the cornea may exhibit pannus in cases of trachoma with smooth tarsus. Pannus is preceded by trachoma of the limbus. In severe cases the bulbar conjunctiva may contain round-celled deposits resembling trachoma granules. The

progress of pannus is from the limbus toward the center of the cornea. Its advancing margin is always preceded by small, circumscribed elevations distinguishable with the loupe. They consist of cellular accumulations beneath the epithelium, which coalesce, forming a soft cellular tissue analogous to the trachomatous tissue found in the lids. Superficial and even perforating ulcers may form, but the vascularity of pannus usually preserves the cornea from destructive ulceration. Pannus is at first situated between the epithelium and Bowman's membrane. In such cases the cornea may completely recover its transparency. In advanced cases Bowman's membrane is eroded or destroyed and the *substantia propria* infiltrated with cells. In such cases disappearance of the pannus is necessarily followed by a permanent cicatrix.

Pannus degenerativus.—Opportunities for microscopic examination of *pannus trachomatosus* and *phlyctænulosus* rarely occur. Specimens of *pannus degenerativus,* however, are common. The histologic characteristics of the other forms have not as yet been fully differentiated. In *pannus degenerativus* a layer of very vascular granulation tissue grows from any portion of the limbus into the cornea. At first it lies beneath the epithelium of Bowman's membrane. The ingrowth organizes into low-grade connective tissue, which later undergoes hyaloid degeneration. The surface epithelium thickens and proliferates inward into every space and crevice that exists, isolated nests and digitations of degenerating epithelial cells frequently being found in the midst of the pannous tissue. Degenerative changes take place in Bowman's membrane and the *substantia propria. Pannus degenerativus* is frequently found in eyes enucleated for iridocyclitis, glaucoma, etc.

Pannus phlyctænulosus (*eczematosus, scrofulosus*) also may start from any portion of the corneal margin. A layer of vascular tissue grows from the limbus to a phlyctenular ulcer. It is differentiated from the fascicular keratitis by the fact that it does not lie in the trough of an advancing ulcer, but is level with or above the surface. The few microscopic examinations thus far made of this disease show that a layer of granulation tissue grows into the cornea, sometimes above and at other times below Bowman's membrane. The latter may be eroded or destroyed, in which case permanent opacity results.

Keratitis fascicularis (vascular fasciculus, Fisher) is another form of superficial serpiginous ulceration of the cornea. It may commence at any portion of the limbus and originates from a small marginal ulcer or phlyctenula. The ulcer advances slowly across the cornea while its track is repaired by a leash of blood-vessels which follow in its wake. The vessels form a vascular membrane extending from the limbus to the ulcer and persist until complete healing has taken place. It does not usually penetrate Bowman's membrane; consequently, only a faint nebula remains after its disappearance. When the process extends far into the depth, protrusion of the altered portions of the cornea, so-called *keratoectasis e panno,* occurs.

In contradistinction to the keratoectasis always developing upon an inflammatory basis, **keratoconus** and **keratoglobus** are terms employed to designate changes in the external form of the cornea, which, according to different authors, are of noninflammatory origin. Keratoconus (see

Fig. 513) is a gradual thinning of the center of the cornea with conic protrusion. The protruded part is at first perfectly transparent, becoming opaque only at a later stage, cellular proliferation with subsequent metamorphosis of the transparent corneal lamellæ into fibrillated connective tissue occurring behind the anterior elastic membrane. Both eyes are usually affected in the same manner.

While keratoconus is observed in young subjects (between 12 and 25 years) and is especially frequent in females, keratoglobus is an affection which is either congenital or develops in the first years of life. Keratoglobus is always an accompaniment of hydrophthalmus (buphthalmus), in which the whole eye is unusually large. This general enlargement is caused by increased intraocular pressure, which also produces excavation of the optic nerve. Therefore, hydrophthalmus

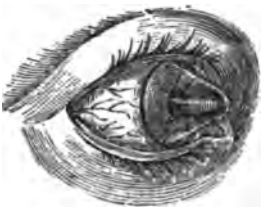

Fig. 513.—Keratoconus.

(buphthalmus) is designated also as **glaucoma of childhood.** In this condition the cornea is enlarged.

Small and large vesicles, which are formed by accumulation of clear fluid between the epithelium and Bowman's membrane, should not be confounded with phlyctenular keratitis. When these water-clear vesicles develop in the cornea of an acute febrile disease they are called *herpes febrilis corneæ.* If, however, the vesicle formation is a concomitant of *herpes zoster ophthalmicus* in the region of the trigeminus, the condition is designated as *herpes zoster corneæ.* The cornea becomes insensitive and intraocular tension is diminished. Owing to the nerve degeneration in zoster, the resulting ulceration is frequently extensive. If smaller or larger vesicles develop synchronously with violent inflammatory phenomena in a cornea already more or less altered by previous affections (*e.g.,* glaucoma), the condition is known as recurrent keratitis vesiculosa or bullosa.

Vesicular keratitis. Vesicles and blebs form upon the cornea from various causes. The histologic peculiarities of the different forms have not as yet been well differentiated. A superficial corneal edema appears to be the dominant factor in their structure. In advanced glaucomatous states, microscopic edematous areas are always found between the

epithelium and Bowman's membrane. They may attain sufficient size to be observed clinicly. They probably result from interference with the lymph circulation of the cornea (Oatman). The vesicles soon rupture, leaving small erosions which, as a rule, are quickly repaired. Occasionally they persist and form extensive superficial ulcers. According to Fuchs, dendritic forms of ulcer originate in *herpes corneæ*.

The term **keratitis bullosa** is applied to the large blebs occurring in eyes which, as a rule, exhibit signs of corneal degeneration. The condition is observed in old glaucoma, recurring iridocyclitis, and in extensive leucomas of the cornea. Their formation depends upon disturbance of the circulation. Relapsing traumatic keratitis bullosa is preceded by a superficial wound or abrasion of the cornea. Weeks or months after apparent recovery from the injury, a small vesicle or large bleb suddenly appears upon the cornea, attended by symptoms of severe irritation. They are very ephemeral and usually rupture before coming under observation. Recovery is rapid, but they continue to recur for years. Corneal vesicles may result from burns, bandaging after operations, and in some cases when no reason can be assigned. In most forms of vesicular keratitis the anterior wall probably consists only of epithelial cells. In bullous keratitis the anterior wall is reinforced by a subepithelial layer of adventitious connective tissue, the product of preceding inflammation. Many of these eruptions undoubtedly are due to trophic nerve disturbance.

"Band-shaped" and "girdle-shaped" keratitis are names applied to a noninflammatory, nonulcerative corneal opacity, from 3 to 5 mm. in breadth, which occupies the region of the center of the cornea. Girdle opacity occurs most frequently in eyes that are undergoing degeneration from intraocular disease, such as iridocyclitis, sympathetic ophthalmia, glaucoma, etc. Very rarely, band opacity develops in the aged as a primary condition in eyes which appear to be otherwise normal. In this form both eyes are affected. Additional opacities may form also in portions of the cornea unoccupied by the band. The process begins on the nasal and temporal sides, extending inward from these points to unite at the center of the cornea. The center, being more recent in origin, is narrower and less opaque than the ends. As in *arcus senilis*, a narrow line of transparent cornea is present between each extremity and the sclera. It may be years in developing. The opacity is due principally to the deposit of lime-salts (probably calcium carbonate and phosphate) immediately beneath the epithelium, and if examined with a lens is usually found to consist of a number of minute dots. In the degenerative type, in addition to the lime incrustation, fibrous connective tissue has been observed in the superficial lamellæ (probably secondary to the lime deposit

on Bowman's membrane), and Bowman's membrane is usually destroyed. Hyaloid masses also are found. Best describes the presence of a fluid exudate beneath the epithelium in the early stage of the affection.

Sometimes, usually after trauma or abrasion of the cornea, fine, thread-like filaments form in the corneal surface: **filamentary keratitis.** They are from 2 to 3 mm. in length, twisted like a rope, and have a knob-like attachment upon their free extremities. They are occasionally seen after cataract extraction, and may be preceded by a vesicular eruption. According to Hess, the filaments rest upon an elevation of corneal epithelium and are composed entirely of distorted epithelial cells. In the terminal knob the cells were greatly degenerated and covered with a thick, mucoid material. The twisted arrangement is probably due to the constant motion of the lids. Another variety of corneal filament, which results from leaking of vitreous through a small corneal puncture, as after discission for cataract, has been described by Hess. These consist of hyaloid material with no epithelial covering.

Aside from the superficial marginal ulcers of phlyctenular and purulent conjunctivitis, the following special forms have been described: Small marginal ulcers with a tendency to recur. They usually attack elderly persons with uric acid diathesis, and manifest no disposition to perforate the cornea (Fuchs). Zur Nedden[1] has isolated a bacillus to which the power of producing a special form of marginal keratitis is ascribed. Two forms of ulceration are said to depend upon its activity: 1. A crescent-shaped (horseshoe) ulcer. 2. Numerous small marginal ulcers accompanied by severe conjunctivitis. The micro-organism resembles the Morax-Axenfeld bacillus, from which it is differentiated only by culture.

Keratitis dendritica (furrow keratitis) is a variety of keratitis in which the ulceration extends over the cornea in the form of superficial, narrow, branching furrows, the end of each furrow terminating in a knob-like infiltration. The ulcers may assume other forms, such as that of a star: *keratitis stellata.* Fuchs describes these ulcers as a form of *herpes febrilis corneæ.* De Schweinitz favors their mycotic origin. Charles attributes them to a terminal nerve lesion. This view is not inconsistent with that of Fuchs, inasmuch as herpes must be regarded as a nerve lesion. A closely allied form of superficial, creeping ulcer is known to be due to malaria. De Schweinitz compares the configuration of the erosions to the skeleton of a lanceolate leaf. Judging from the course pursued by these ulcers, they follow the distribution of corneal nerves.

Rodent ulcer (Mooren), **chronic serpiginous ulcer** (Nettleship). This form of ulcer begins in the upper portion of the cornea and advances slowly over the surface until vision is destroyed. The anterior, progressive border is deeply undermined, while temporary cicatrization takes

[1] Arch. f. Ophth., liv, i, 1902.

place over the necrosed area, resembling in this respect rodent ulcer of the skin. It involves only the anterior layers of the cornea, exhibiting no tendency to perforation. The floor of the ulcer is covered with a thick granulation tissue and proliferating corneal epithelium. It attacks adults and individuals of low vitality. Andrade[1] describes a specific bacillus, but his observations lack confirmation.

Leucomatous Ulcers.—Eyes with old leucomatous cornea are not uncommonly lost from suppuration, which begins in the cicatrix. The subject has been investigated by Dulganoff and Sokoloff.[2] These investigators cauterized the eyes of rabbits and, after cicatrization was completed, experimented on them with virulent cultures of streptococci and staphylococci. They found that when the epithelial covering of the cicatrix was unbroken no infection of the cornea followed introduction of the cultures into the conjunctival sac. They, therefore, concluded that the intact epithelial covering of a corneal cicatrix is an efficient protection against microbic invasion. On the other hand, when the surface epithelium was removed, inoculation of the cicatrix invariably produced a characteristic ulcer with infiltration ring and hypopyon. Such ulcers tended to increase in depth rather than in superficial area, indicating that cicatricial corneal tissue "melts away much more rapidly than normal under the influence of these cultures." In some cases the cauterization was deep enough to destroy Descemet's membrane. If the resulting leucomata were inoculated with the cultures, micro-organisms were found in the anterior chamber while the ulcer was still superficial, which proves that the bacteria penetrate scar-tissue much more readily than the normal cornea. When Descemet's membrane was absent the eye was invariably lost from panophthalmitis. According to the authors mentioned, Descemet's membrane forms an impassable barrier to the micro-organisms, which were never found in the anterior chamber when this membrane was intact, even though the leucoma was otherwise extensive. When a leucoma was inoculated at a point remote from a defect in Descemet's membrane, micro-organisms did not pass into the anterior chamber. In such cases their migration appeared to be limited by the infiltration ring which surrounded the point of inoculation.

So-called hyaline, colloid, and **amyloid** degenerations frequently occur in corneal leucomata and staphylomata, and are followed by deposit of lime-salts: calcareous degeneration. The nature of these products has already been discussed. (See p. 968.) The hyaloid material appears between the connective-tissue fibers of the cornea. The epithelium also is involved, being invaded by subepithelial outgrowths which are later converted into hyaloid material. Similar material is found in the intercellular spaces. Calcareous degeneration is a late stage of hyaloid degeneration. The calcareous material is said to be deposited independently. It occurs in the superficial layers in band keratitis. The deposit of lime-salts on Bowman's membrane results in destruction.

Atheromatous ulcer. The calcareous deposits which form in

[1] Ann. d. Ophtal., xxix, 1900.
[2] Arch. f. Augenheilkunde, Jan., 1903; Arch. of Ophth., 1905, p. 370.

dense corneal leucomata act as a foreign body in the tissues, from which they may be cast off by the process of ulceration. When this occurs, the sequence of events differs from that in other forms of corneal ulcer. First, a space forms between the calcareous mass and surrounding tissues. Into this the surface epithelium promptly proliferates. Granulation tissue springs up, and, by a gradual process of undermining, the sequestrum is finally separated. Infection may take place and extensive necrosis ensue. (See Leucomatous Ulcer, p. 992.)

Aqueous opacities, Quellungstrübung (Leber), *ulcus corneæ internum* (v. Hipple). Leber made an opening in the limbus, passed a blunt probe into the anterior chamber, and injured the endothelium of Descemet's membrane, at the center of the cornea. The cornea absorbed aqueous and became opaque over the point of injury. The experiment demonstrated the permeability of Descemet's membrane when the endothelium is injured. This explains the transient opacities observed after the introduction of instruments into the anterior chamber or when a dislocated lens lies against the cornea. Neul and Cornil have demonstrated that injection of various fluids into the anterior chamber will produce exfoliation of the endothelium. This is followed by opacity of the cornea, which continues until the endothelium is restored.

Ring abscess. This is a highly destructive form of deep keratitis which sometimes follows perforating wounds of the cornea, particularly those made by the entrance of small foreign bodies. It may follow operations. According to Hanke, it is due to infection with a special bacillus. This view, however, is not generally accepted. In a day or two the entire cornea is uniformly infiltrated. In the great majority of cases the eye is lost from panophthalmitis. In ring abscess the cornea is attacked from the rear. The pyogenic bacteria are carried into the eye, where they set up uveitis. The endothelium of Descemet's membrane is destroyed, and posterior infection of the cornea follows. The exudate is always peripherally situated, regardless of the location of the wounds, and commences as an annular accumulation of leucocytes in the layers of the cornea. The lips of the wound may or may not be infiltrated. Morax[1] saw ring abscess in a case of double metastatic (pneumococcic) iridocyclitis. The cornea contained no pneumococci, although they were abundant in the anterior chamber. Morax agrees with Fuchs that ring abscess is caused by the toxins generated by pneumococci in the anterior chamber.

Striate opacities, so-called **striate keratitis.** Incised wounds of the cornea, particularly cataract operations, are sometimes followed by the appearance of fine, parallel gray lines extending from the edges of

[1] Ann. d'ocul., cxxxii, p. 409.

the wound nearly to the opposite margin of the cornea. Between the striæ the cornea is hazy. The lines are supposed to result from wrinkling of the posterior layers of the cornea and Descemet's membrane. Striæ which cross each other in every direction sometimes appear after extraction. This variety is supposed to depend upon distention of the corneal lymph-spaces. Corneal opacities, resembling creases in crumpled paper, may follow the use of very tight bandage. Fuchs and others ascribe them to mechanic distortion of the posterior layers of the cornea. The thread-like (*fädenförmig*) opacities of Schirmer follow injury. The cornea is edematous and contains a central opacity formed by a reticulum of fine dark lines. This condition also is due to folding, and Schirmer considers it as a late manifestation. Striate opacities, due to wrinkles in Bowman's membrane, have been described by Schirmer. They are seen only in phthisical eyes, and the folds are produced by shrinkage of the *substantia propria*.

Family degeneration of the cornea (Fehr), **nodular** or **guttate opacity** (Gronouw, Fuchs), **lattice** or **grill-like keratitis** (Bibber, Haab), **reticular keratitis** (Parsons), are various terms employed to designate a peculiar corneal degeneration which generally attacks both eyes and is attended by interstitial opacities in the form of dots or a very fine reticulum discernible with the loupe. The disease is hereditary, develops at or before puberty, and many members of a susceptible family are usually affected. Small, elevated, central opacities appear, which may coalesce and form irregular figures. The periphery of the cornea is but slightly affected. According to Fuchs, the changes are confined to the superficial layers, Bowman's membrane being destroyed. They consist of edema, swelling of the corneal corpuscles, splitting and disintegration of the lamellæ, and formation of a finely granular amorphous matter which probably is coagulated fluid—changes indicating a mucoid degeneration. Other observers have found urate of soda and hyaline material in the diseased area. The opacities slowly increase during life. There is no irritation unless deposits appear very near the surface. In the case of an old woman, Deutschman saw ulceration. This, however, is very unusual. In an allied condition, described by Gronouw under the name of nodular opacity, elevated spots or patches are distributed over the cornea of both eyes. The condition develops very slowly. Fuchs examined a case microscopicly and found that the epithelium was elevated by edema in the *substantia propria*. Bowman's membrane was absent. The corneal lamellæ were split and the spaces filled with cellular detritus, fluid, and amorphous masses which were regarded as coagulation products.

Disciform keratitis (*keratitis disciformis et annularis*) is a deeply situated, nonsuppurative form of corneal infiltration which usually ap-

pears in middle life. The central portion of the cornea is occupied by a diffuse, disk-shaped opacity, surrounded by a dense, ring-like border, which is never yellow as in serpiginous ulcer. As a rule, the inflammatory reaction is slight. The surface epithelium over the infiltration is seldom affected, although slight ulcers are occasionally seen in late stages of the disease. Hypopyon is absent or very slight. In advanced stages a few vessels may extend from the limbus to the disk. It does not result in abscess or necrosis, but after some months subsides, leaving a permanent opacity. The condition has been studied microscopicly, but it probably results from infection of a corneal abrasion or herpetic vesicle by some species of bacteria the virulent tendencies of which are controlled by a cordon of leucocytes. Schirmer reports a typic case due to infection with vaccine virus (*keratitis post vaccinolosa*). Syphilitic keratitis, congenital and acquired, occasionally assumes the form of diskiform keratitis.

Tuberculosis of the cornea is infrequent. The majority of cases are secondary to tuberculosis of the uveal tract.[1] As a rule, the disease appears as interstitial keratitis, closely resembling the keratitis of constitutional syphilis. It appears also as sclerosing keratitis or as deep, circumscribed opacities. Tubercle bacilli do not thrive in corneal tissue and can seldom be demonstrated; therefore, the diagnosis largely depends upon the presence of uveal tuberculosis and the results of inoculation experiments. In late stages the cornea may be converted into a granulating tubercular mass. The histologic changes reported appear to have been confounded with those of syphilitic interstitial keratitis and are not entitled to much credence, unless associated with tuberculosis of the uveal tract.

In **leprosy** the cornea is, as a rule, involved sooner or later. It is always an endogenous infection. Two forms of the disease appear in the cornea, namely, superficial, and deep. The superficial form, known as *keratitis superficialis nodosa* or *punctata*, begins at the periphery as small puncta. The spots consist of masses of lepra bacilli situated just beneath the epithelium. The nodules cause but slight reaction, and cellular proliferation may or may not be excited. Greeff examined a case in which the cornea appeared perfectly transparent by oblique illumination; nevertheless, microscopic examination revealed numerous bacilli in the lymph-spaces. The deep parenchymatous form is always associated with anterior uveal leprosy. In many of the cases reported, the epithelium was unaffected. Leprosy attacks the anterior portion of the eyeball, no changes taking place in the fundus until the cornea is too opaque to permit ophthalmoscopic examination. Leprosy of the sclera may extend to the cornea and produce large granulating tumors known as l e p r o m a t a .

Keratomycosis aspergillina. Inoculation of the human cornea with the mold fungus, *Aspergillus fumigatus*, produces an atypic hypopyon

[1] Greeff reports a case of tuberculous ulceration of the cornea following auto-inoculation with the finger-nail.

keratitis. Several other varieties of pathogenic fungi (*Penicillium glaucum, Aspergillus nigrans,* and the *saccharomyces*) have been observed. In *Aspergillus nigrans* infection the sequestrum is black (Bull). In the majority of cases reported, the clinic appearance of mycotic keratitis is quite characteristic. A localized superficial infiltration is followed by an ulcer which has a dry, greasy-looking center surrounded by a gray or yellow line of demarkation. Hypopyon is present, but the iritis is mild. In most of the cases reported a history of corneal injury has been obtained. Fuchs has reported the case of a miller who had an attack of *herpes corneæ febrilis* followed by mycotic keratitis. It was assumed that infectious material was conveyed to the abraded cornea by flour-dust. The aspergillus has been found in simple corneal ulcer. It probably occurs more frequently than is generally supposed. The dry center forms a sequestrum, separation of which is followed by repair. Microscopic examination of the sequestrum shows it to be densely infiltrated by a network of mycelium threads. Fructification does not take place in the cornea. Should the fungus become implanted upon a perforating wound, intraocular invasion and loss of the eye may occur.

Drusen on Descemet's membrane, hyaline excrescences, **Henle's warts.** As Descemet's membrane is a product of the endothelium, its structure may be modified through functional activity of the endothelial cells. The known modifications consist in a progressive increase in thickness during life, and, frequently, the formation of hemispheric excrescences upon the peripheral portion of its posterior surface. The formations are arranged in from two to four rows irregularly concentric to the corneal margin, their average height being from 0.003 to 0.006 mm., rarely exceeding 0.01 mm. When exceptionally large and numerous, they are visible to the naked eye and may be mistaken for inflammatory deposits. In rare cases they are scattered over the entire surface. They begin in early adult life, and their growth keeps pace with the thickening of Descemet's membrane. Calcifications which are deposited by the endothelial cells, and are continuous with Descemet's membrane, may occur in old cases. They appear to be identic with the Drusen (colloid bodies) which form on the *lamina vitrea* of the choroid.

Leber and Rindfleisch have reported cases of hyaloid deposits on Bowman's membrane associated with degenerative changes in the cornea. It is improbable that such deposits are identic with the "Drusen" which form upon Descemet's and Bruch's membranes, because the contiguous epithelium takes no part in forming Bowman's membrane, which is composed of condensed *substantia propria.* Elsching reports the case of a man suffering from chronic lead poisoning. Oblique illumination showed irregular surface reflexes. On microscopic examination the external surface of Bowman's membrane was found to be covered with rounded, homogeneous hyaloid deposits. The larger deposits were lamellated, and a line of demarkation was observable between them and the membrane. The sur-

face epithelium was not elevated, the deposits existing at the expense of the basal cells. Elshnig regarded them as a product of the epithelial cells, but Parsons is probably correct in interpreting them as products of exudates.

Melanosis Corneæ (*Pigmentation of the Cornea*).—Congenital pigmentation of the cornea is probably always associated with melanosis of the conjunctiva. Yamaguci examined the two eyes of a pig with melanosis of the cornea and found the pigment distributed among the deep layers of the epithelium. The sclera was free. Iron reaction negative. Setiner observed 2 cases among the Javanese. The first had *nævus pigmentosus* at the limbus and a dark-brown, pigmented spot, 0.5 mm. in diameter, upon the cornea; the second had pigmented nevus of the face, *melanosis conjunctivæ*, and a melanotic spot upon the cornea. A section excised for microscopic examination showed granular pigment distributed among the deep epithelial cells. This condition is to be differentiated from uveal pigment deposited on Descemet's membrane as the result of inflammatory processes. Parsons mentions two cases of corneal pigmentation (apparently nonsarcomatous) associated with diffuse pigmentation of the conjunctiva, one of which was examined microscopicly. As in congenital melanosis, the pigment was confined to the deep layers of corneal epithelium, contained no iron, and was not readily bleached.

Hematogenous discoloration of the cornea has been a subject of considerable discussion. The cornea may absorb a slight amount of blood from subconjunctival hemorrhages or adjacent wounds. Slight hemorrhages into this substance are possible from corneal granulation tissue. Of much greater interest are those rare cases in which the cornea is stained by blood in the anterior chamber. When this occurs, all the cornea, except a narrow line at its periphery, is diffusely stained from greenish black to reddish brown. It closely resembles and may be mistaken for a dislocated, amber-colored lens. Absorption of the discoloration proceeds slowly from the periphery toward the center. Most cases are associated with increased tension. This is generally considered to be the determining factor, but extensive hemorrhage into the closed anterior chamber not infrequently causes increased tension without producing discoloration of the cornea. The opacity depends upon the presence in the lamellæ of numerous colorless, round, rod-shaped or oval granules. Not all investigators consider these granules to be the cause of the opacity. Romer observed a case in which they were absent, and Hipple found pigment granules in the corneal corpuscles. Nevertheless, the granules, when present, must be considered as causative. The granules are derivatives of hemoglobin, but their exact chemic composition is undetermined. According to Collins, a solution of hemoglobin in aqueous humor filters through Descemet's membrane; Weeks thinks that it enters by way of Fontana's spaces. Hyphemia and increased tension are common conditions which not infrequently are combined, while hematogenous discoloration of the cornea is very rare. It would, therefore, appear that some additional factor, not improperly a lesion of Descemet's membrane, is necessary for the entrance of the blood-stained aqueous into the cornea.

Discoloration of the cornea may be due to the presence of various metals, such as iron, lead, silver, copper, etc. A common discoloration results from grains of gunpowder burned into the cornea. In argyrosis, Weeks[1] considers that the silver is deposited as the chloride, subsequently being reduced to the metallic state. Descemet's membrane, from its affinity for silver, stains deeply (Knies[2]). Parsons describes a case of siderosis in which pigment granules were confined to the

[1] N. Y. Infirm. Rep., 1904.
[2] Knapp's Monatsch. f. Augenheilkunde, 18, 1880.

corneal corpuscles. According to Hirschberg,[1] the pigment in the cornea after tattooing for leucoma forms masses between the fibers of the cicatricial tissue, in the walls and lumina of blood-vessels, and occasionally in the connective tissue and epithelial cells.

In conclusion, a brief *résumé* of the different **corneal opacities** may be given. These are partly of inflammatory (in ulcers and infiltrations), partly of noninflammatory (*malum senile corneæ*), origin, and may either disappear (phlyctenular, fresh pannus, *keratitis parenchymatosus*) or remain stationary (connective-tissue pannus, cicatrices, etc.). When the opacities are delicate, translucent, bluish white, they are called *maculæ* or *nebeculæ corneæ;* these have no sharp contour. Stronger, vascular and nonvascular, gray-white or white opacities are generally more sharply defined (leucoma). If the opacity is elevated, the condition is either an ectatic cicatrix (*keratoectasis ex ulcere, e panno, staphyloma*) or a protrusion with subsequent opacity (keratoconus, keratoglobus). Depressions of small areas are always the result of slight superficial losses of substance (corneal facettes); they are not opaque. Flattening of the whole cornea (*applanatio corneæ*) is caused by retraction of cicatricial tissue, and, therefore, is always associated with complete opacity.

Tumors of the cornea. A few cases of true papillomata of the cornea have been reported in medical literature. Bowman's membrane is more or less destroyed, but the *substantia propria* is not invaded. The entire cornea may be covered with the growth. "Horns" are usually formed by hornification of the cells of a papilloma. So-called fibromata of the cornea usually originate in old cicatrices and consist of hyperplastic scar-tissue. True fibroma of the cornea, however, has occasionally been seen. Several cases have been reported as myxoma of the cornea. It is doubtful whether they were true myxomata or edematous fibroid polypi originating in hyperplastic scar-tissue. A dermoid situated at the limbus may rest upon both the conjunctiva and cornea. These growths are rarely, if ever, limited to the cornea. A few corneal growths have been reported which presented the microscopic features of sarcoma. The majority of these were pigmented. Endothelioma undoubtedly occurs in the cornea. In the great majority of cases epithelioma of the cornea originates in the conjunctiva. All cases reported as primary in the cornea have been preceded by corneal injury. Nonmalignant corneal epithelium will proliferate and fill every accessible crevice in the cornea, and when infiltrated throughout a porous wound presents a microscopic picture closely resembling epithelioma.

---

[1] Arch. f. Ophth., 28, i, 1882.

Cysts of the cornea are extremely rare. The principal forms are the epithelial and lymphatic. The most frequent is the epithelial, so called because its cavity is lined with epithelial cells. It usually originates from the epithelium of the conjunctiva engrafted upon the cornea. This may result from the formation of adhesions between a corneal erosion and the overlapping, chemotic conjunctiva. It is generally believed that cysts may be due to traumatic implantation in the cornea of epithelium or fragments of uveal tissue. When cysts follow penetrating wounds, the sequence of events is believed to be as follows:—

(*a*) The epithelium rapidly proliferates and lines the wound with epithelial cells.

(*b*) Instead of uniting from the bottom outward, the wound may close superficially, thereby isolating the epithelium which has extended into the wound.

(*c*) The isolated epithelium may, under favorable conditions, proliferate and form a cyst (Oatman).

Cysts may develop in the corneal portion of a pterygium. Lymphatic cysts are formed in the *substantia propria* from dilation of the corneal lymph-spaces. The corneal structure is too dense to permit any distention of its lacunæ from obstructed circulation; therefore, extensive atrophy of the lamellæ always precedes dilation. The atrophy may be due to malnutrition incident to pathologic changes in the pericorneal capillary system (Oatman); presence of a foreign body in the cornea, as in a case reported by Colburn, or of tumor elements, as in a case of Wintersteiner. Cysts may form in the track of a corneal fistula (Czermak). Wuerdeman has reported an echinococcus cyst of the cornea.

THE SCLERA.

The sclera,[1] like the cornea, is composed of bundles of connective-tissue fibers arranged in equatorial, meridional, and oblique directions. The arrangement, however, is less regular and more compact than in the cornea. The sclera is also rich in yellow elastic fibers. In early life the cornea and sclera possess a uniform structure. The differentiation which normally ensues may be incomplete, whereby portions of the sclera appear to encroach upon the cornea.[2] (See *arcus juvenalis.*) Upon the inner surface of the sclera is a pigmented membrane—the *lamina fusca*—covered internally and externally by endothelial cells. Isolated groups of pigmented cells may occur also in any portion of the sclera. As the sclera is comparatively nonvascular, wounds of this structure are repaired by material furnished from contiguous vascular membranes, namely, the choroid and conjunctiva.

Owing to its very hard, firm, poorly vascular and poorly cellular structure, the sclera is but slightly disposed to inflammatory processes. Adjacent inflammations (*e.g.*, purulent keratitis), therefore, very seldom extend to the sclera. In rare cases an independent inflammation of the sclera: scleritis, is observed, the etiology[3] and nature of which, however, are still but little understood. A superficial form: episcleritis, and a deep form: scleritis, are generally differentiated.

---

[1] σκληρος = dry, hard.

[2] According to Parsons, these cases are inflammatory in origin. While this may be true in some cases, there is no doubt that others are due to arrested development.

[3] According to observations thus far published, syphilis and tuberculosis, and probably also gout and rheumatism, appear to be the most frequent causes.

Episcleritis is characterized by the occurrence of smooth, sharply defined, dark-red, inflammatory maculæ or nodules, about the size of a lentil, in the anterior half of the sclera. The conjunctiva is movable over these dense and usually sensitive nodules. They are composed of round cells, occasionally polymorphonuclear leucocytes, and sometimes extravasations of blood, inflammatory edema existing in the affected areas. The nodules disappear after a few weeks by absorption (never by ulceration), leaving only a slate-colored "cicatrix," which is somewhat firmly bound to the conjunctiva and sometimes also somewhat flattened. This episcleritis frequently recurs, so that the whole cornea may finally be surrounded by a slate-colored zone. Both eyes are usually affected.

Scleritis cannot always be sharply differentiated from episcleritis; the characteristic features are furnished only by the sequelæ and complications occurring in the remaining parts, especially the iris, choroid, and cornea. Scleritis also begins with the appearance of small, slightly elevated, dark-bluish-red spots, which are somewhat less sharply circumscribed. These spots likewise disappear after a time by absorption and also leave colored cicatrices, which, however, in contradistinction to episcleritis, are always associated with permanent bulging, owing to thinning of the sclera. In this manner ectasis of the sclera—so-called scleral staphyloma—is produced. Many cases of scleritis and episcleritis have a tuberculous origin, especially when associated with keratitis. Rarely, scleritis is due to constitutional syphilis.[1]

The complications of deep scleritis are keratitis (so-called sclerosing keratitis—a triangular opacity of the deep corneal layers which, in frequent relapses, gradually results in permanent opacity of the cornea); iritis (with subsequent posterior synechia, sometimes with adhesions of the pupillary margin, but never with hypopyon), and choroiditis (with subsequent opacity of the vitreous). This scleritis also is usually bilateral and frequently recurs. Deep scleritis differs microscopicly from the superficial form only in so far as the cellular exudation is more diffuse and intense. It is doubtful whether the deeper forms ever exist without more or less involvement of the superficial layers.

As the affection is associated with permanent thinning and ectasis of the sclera, relapses finally cause all the cornea in the region of the ciliary body to bulge, the sagittal diameter of the globe being thus increased. This change in the form of the globe is called ciliary staphyloma.[2] After a time, owing to irritative phenomena and increase of intraocular pressure, complete blindness results.

---

[1] Diagnosis confirmed by Wassermann test.

[2] Strictly speaking, the term ciliary staphyloma should be applied to protrusion of that portion of the sclera which covers the ciliary body, and the term inter-

A special form of deep scleritis has been described by Schlodtmann under the name of "gelatinous infiltration of the sclera." Inasmuch as it completely encircles the cornea, Parsons suggests as preferable the term **"annular scleritis."** Although the cases thus far examined show great morphologic variations, they resemble each other clinicly. It is a disease of advanced life. Nodules form and slowly coalesce until the cornea is completely surrounded and ultimately invaded. It is associated with progressive uveal disease, which terminates in loss of vision. Roosa and Oatman have reported a case in a myope. In addi-

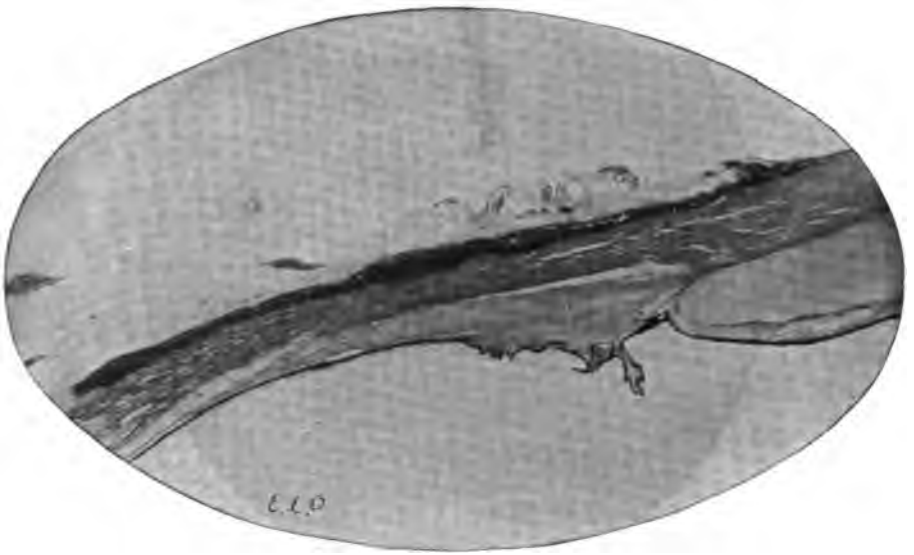

Fig. 514.—Annular scleritis. (After photomicrograph by *E. L. Oatman, M.D.*)

tion to the usual symptoms, there was obstruction of the anterior ciliary vessels, which produced a glaucomatous condition, while invasion of the tendinous attachment of the external rectus muscle and subjacent sclera resulted in extensive equatorial staphyloma. The deposit did not extend backward beyond the *vena vorticosæ*. Histologicly, the deposit resembled young granulation tissue. Calcareous degeneration of the sclera may occur in certain forms of glaucoma aside from other calcareous deposits in the eye. Verhoeff obtained a positive Wassermann reaction in a case of annular scleritis. He also examined two preparations from cases of

callary staphyloma to the bulging which occurs in the narrow zone of sclera present between the ciliary body and cornea. Intercallary staphyloma is observed only where the root of the iris is adherent to the periphery of the cornea. The two forms are most frequently associated.

Schlodtmann, Friedland, Parsons, and Oatman, and concludes that all these cases were syphilitic in origin, and that the lesion is analogous to syphilitic aortitis.

Trauma of the sclera occurs either as the result of the action of blunt force upon the globe: *ruptura scleræ* from contusion, or penetration of a sharp-pointed object (instruments, glass and metal fragments, etc.) into the sclera with and without perforation. In the first case

Fig. 515.—Annular scleritis. At this point the external third of the scleral substance has been supplanted by the deposit. Fragments of disintegrating scleral fibers are scattered through the mass. (After photomicrograph by *E. L. Oatman, M.D.*)

an arch-shaped rupture almost always occurs in the neighborhood of and concentric with the corneal margin.

Every trauma of the sclera, with and without solution of continuity, may be accompanied by marked hemorrhage from the choroid, retina, or ciliary body into the anterior chamber and vitreous.

The further changes in trauma depend essentially upon whether parts in the interior of the eye are displaced (e.g., *luxatio lentis*) or have prolapsed through a perforation, or whether infectious germs have contaminated the wound. If no infectious germs enter the wound, healing

sometimes occurs by primary intention. If internal parts are displaced or have prolapsed into the wound, healing does not progress so quickly and is usually incomplete. Indeed, further disturbances frequently occur; not rarely when healing is apparently completed, retraction of the cicatrix causes traction upon the uvea and may result in iridocyclitis, detachment of the retina, increase of intraocular pressure with excavation of the optic nerve, etc.

Rupture of the sclera from a blow usually occurs in the upper and inner segment, a few millimeters from the margin of the cornea. This

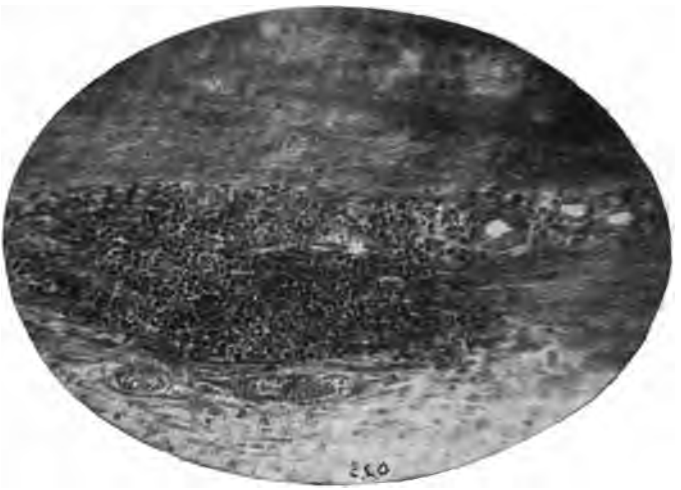

Fig. 516.—Posterior edge of the scleral deposit. The right-hand side of picture shows area of new invasion. The cells appear first in and around the walls of the blood-vessels. (After photomicrograph by *E. L. Oatman, M.D.*) (Bausch and Lomb, Obj., ¼; Ocul., ½.)

point of selection is attributed to impact of the eyeball against the projection formed by the pulley for the superior oblique muscle. Rupture from blunt force may, however, occur elsewhere. Rupture may occur at the junction of the sclera and *lamina cribrosa,* and result in hernia of the retina into the sheath of the optic nerve.

Aside from the thickening observed in *phthisis bulbi,* hypertrophy of scleral tissue may occur from the presence of a foreign body or in response to the irritation of a neoplasm in the orbit. While intraocular growths readily perforate the sclera along the course of blood-vessels, the sclera thickens and offers resistance to invasion of the eye from without. The sclerotic tissue softens and breaks down more readily when in contact with tubercle than with other growths.

Abscess of the sclerotic has seldom, if ever, been observed. Superficial suppuration has been reported in glanders. It is more probable that the abscess developed in the episcleral tissue. In purulent choroiditis, erosion and perforation of the sclera are late events. Gummata may extend from the ciliary body to the sclera. A few cases of gummata limited to the sclerotic have appeared in literature, but no microscopic examination in which other structures were not involved have been made.

If infectious germs enter the wound or the interior of the eye during or after trauma, the sequelæ may be either a violent panophthalmitis ending in suppuration of the whole globe or an exudative iridocyclitis which, as a result of organization and shrinkage of the exudate, causes diminution of the whole globe: *atrophia bulbi.*

Ectases (staphylomata) **of the sclera** involve either the whole sclera (total ectases) or only a part (partial ectases). The latter are divided, according to their location, into anterior (anterior sclerostaphyloma, frequently annular), equatorial (equatorial staphyloma, never annular), and posterior. The latter are located either beneath the posterior pole and consist in a congenital dilation from incomplete closure of the fetal palpebral fissure: posterior scleral protuberance of Ammon (coexistent with coloboma: cleft of the choroid), or they are situated external to the entrance of the optic nerve and consist in thinning and protrusion of the posterior pole, as a result of which the polar axis of the globe is elongated (usually associated with myopia): *staphyloma posticum Scarpæ.* Ectasia occurring over the ciliary body is termed "ciliary staphyloma." When between the ciliary body and cornea: "intercallary staphyloma."

Total ectasis consists in enlargement of the whole globe and occurs only in childhood, when the sclera, as a whole, is still distensible. (See Keratoglobus, p. 988.)

Tumors of the sclera are among the greatest rarities. The primary growths are fibromata, sarcomata, and osteomata. Secondary growths are more frequent and, as a rule, start from the interior of the eye: glioma of the retina, sarcoma of the choroid, etc. A case reported as telangiectasis of the sclera was undoubtedly episcleral.

While the occurrence of tubercle limited to the sclera is doubtful, this membrane is readily invaded by adjacent tuberculous processes. Both scleritis and sclerokeratitis frequently give a local reaction to injections of tuberculin.

In leprosy the nodules may appear in the episcleral tissue and slowly invade the deeper parts.

Cysts of the sclera are unusual.

Coats examined microscopicly a case of posterior scleritis resulting from noninfectious infarction of a posterior ciliary artery. There was necrosis of the inner third of the sclera and of the entire thickness of the retina and choroid throughout the affected area.

THE LENS.

The lens, *lens crystallina,* lies loosely upon the posterior surface of the iris, and, in common with the zonula of Zinn (*ligamentum suspensorium lentis*), separates the anterior chamber of the eye from the vitreous body. The anterior surface of the lens is slightly, the posterior markedly, convex. The lens is orientated as follows: It is said to have an anterior and posterior pole and a polar axis. The junction of the anterior and posterior surfaces is termed the equator. Lines which intersect the poles are the meridians; the vertic and horizontal meridians are the ones most frequently mentioned.

The lens consists of a homogeneous capsule and the so-called lens fibers. It is entirely an epithelial structure formed by invagination of the epiblast. The epithelial surface is directed into a closed cavity; consequently, the epithelium cannot be cast off. The capsule is thickest at the anterior pole and thinnest posteriorly. The embryonic lens capsule is lined throughout by epithelial cells; in fact, it is probable that the permanent capsule is a cuticular formation deposited by the epithelium, as is Descemet's and Bruch's membranes. The epithelia of the posterior half of the capsule elongate and form the lens fibers, leaving this portion without an epithelial lining. The epithelium of the anterior half persists throughout life. At the equator the anterior cells gradually elongate and pass into fibers. This region is known as the transition zone. The lens continues to grow during life, the cells at the zone of transition supplying young fibers, while the old fibers are gradually pressed into the center of the lens, where they coalesce and form the nucleus. The central portion of the lens becomes differentiated at an early age by a greater density and hardness, so that even at puberty a nucleus and cortex can be distinguished. There is no sharp line of demarkation between these, but a gradual transition. As age advances, the nucleus usually becomes larger as the result of progressive sclerosis, and the soft, adjustable cortex diminishes until, finally, in extreme old age, the whole lens sometimes consists of firm, rigid (sclerotic) nuclear substance. This progressive hardening of the lens, which commences in infancy and continues throughout life, is attended by gradual loss of lenticular elasticity and diminution of the power of accommodation. This constitutes **presbyopia.**

The *ligamentum suspensorium lentis* (*zonula Zinnii*) consists of delicate fibers which fix the lens in position. These fibers start from the inner surface of the ciliary body and are inserted at the equator of the lens. The zonular fibers arising from the posterior aspect of the ciliary body pass forward and are attached to the anterior surface of the lens, while those arising in front, from the ciliary processes, pass backward and are attached to the equator and posterior surface of the lens. This crossing of the suspensory fibers creates a triangular space formerly called the canal of Petit.

Under normal conditions the lens continues to increase in size during life. It has been suggested that cessation of growth may be the first step in the formation of senile cataract. The shrinking of the nucleus not being compensated by development of new fibers, it becomes loose in the cortic substance.

Opacities of the lens[1]: **cataracts**, depend upon a usually slowly developing alteration of the optic character of the clear, transparent lens-tissue. Cataract may be stationary or progressive. Progressive cataract is divided into the following four stages:—

1. *Cataracta incipiens:* The light-gray opacity is still limited to certain areas, between which the lens is clear and transparent.

2. *Cataracta intumescens:* The whole lens is swollen, enlarged, and whitish, iridescent opaque.

3. *Cataracta matura:* The swelling has subsided and the lens returned to its ordinary size; it is dull, whitish gray or somewhat brownish in color, and easily removable from the capsule—r i p e for operation.

4. *Cataracta hypermatura:* The lens begins to atrophy, so that in many cases only an opaque membrane (*cataracta membranacea*) finally remains. This offers so little support for the iris that it sways back and forth on movement (i r i d o d o n e s i s).

Comparatively few satisfactory observations have been made upon the pathology of cataract.[2] Histologic investigations have given the following:—

True inflammation does not occur in the lens. The changes are proliferative and degenerative processes confined to the epithelium and degenerations which occur among the lens fibers. The most varied degenerative changes may occur also as a result of surrounding inflammation. Priestly Smith found that at the beginning of lenticular opacity the volume of the lens is diminished. This is due to shrinking of the lens fibers. This stage is of short duration and is immediately followed by increase in volume due to appearance of fluid between the fibers. In rare cases resorption occurs at this stage and the lens regains its transparency. The change next noted is separation of the fibers at the periphery. The interfibrillar fluid coagulates into globules, known as M o r g a g n i a n b o d i e s. Then follows degeneration of the cortic fibers, which break up into spheroid masses resembling Morgagnian bodies, but distinguished from them by their reactions to stains. Albuminous and fatty deposits, cholesterin, fatty crystals, and detritus appear later. Hyaline and calcareous changes are not uncommon. The capsular epithelium may exhibit proliferation or degenerate and disappear. The cells may deposit *Drusen* on the inner surface of the capsule or proliferate and line the posterior half of the capsule. Large vesicular cells are frequently observed. In senile cataract the nucleus usually remains normal.

As degeneration progresses the lens begins to decrease in size from loss of fluid (beginning absorption); the disintegration of the lens fibers progresses, especially in the external portions of the cortic layer, so that the union between lens and capsule is more and more loosened. The further changes vary according as the nucleus of the lens is hard (*cataracta dura*) or soft (*cataracta mollis*); in the latter case, *i.e.*, in young persons before puberty, the whole lens disintegrates to a detritus: *cataracta lactea;* in elderly persons, on the other hand, only the cortex

---

[1] Cataract, from κατὰ and ῥέω, because the ancients believed the opacity in cataract was in front of the lens and developed as the result of exudation of a cloudy fluid from above between the iris and lens (Fuchs).

[2] The greatest difficulty in studying the pathologic changes in the lens are the artefacts produced during preparation of specimens for microscopic examination. These artefacts are often indistinguishable from pathologic alterations. Post-mortem changes also are very confusing.

softens. In course of time the sclerotic nucleus may sink to the bottom: hypermature cataract (*cataracta Morgagni*). In such cases the nucleus may change its position with the movements of the eye. In rare cases in children, all the softened lens may be absorbed, so that, finally, only the empty capsule remains: *cataracta cystica.*

The epithelium is subject to pathologic changes in cataract. Proliferation occurs in anterior capsular cataract, rarely in commencing senile cataract, usually in hypermature cataracts, and occasionally in other pathologic conditions of the eye. Large vesicular cells may form from the epithelium as well as from the lens fibers. Degeneration of the epithelium may be manifested by the deposition of hyaloid bodies (*Drusen*) on the capsule. Complete disappearance of the epithelium has been observed in glaucoma and from the presence of foreign bodies in the eye.

Special forms of cataract. Senile cataract usually affects both eyes successively. As a rule, the nucleus is unchanged until the cataract is hypermature. The early opacities vary in appearance. The most frequent forms consist of (1) radiating lines extending from the equator toward the axis like the spokes of a wheel. They are produced by accumulation of fluid in spaces formed where the lens fibers abut and form the lens star. These radii may be situated in the anterior or posterior section of the cortex. (2) Central cataract is a diffuse opacity appearing immediately around the nucleus. This form is to be differentiated from nuclear cataract, which is confined to the nucleus. (3) An irregular, disk-shaped opacity deeply situated in the cortex. It has a thin, web-like appearance. This differs from posterior cortic cataract. (4) In the very old, a ring-shaped opacity may appear near the equator, which, from its resemblance to *arcus senilis* of the cornea, has been termed *arcus senilis lentis.* Two rings are usually seen: one in the anterior and another in the posterior layers of the lens. This form is comparatively nonprogressive, and, owing to its peripheral situation, interferes little with vision. In rare cases cataract commences in the epithelium of the anterior capsule and extends to the lens.

Punctate cataract (*cataracta senilis prematura punctata*) commences in early middle life (30 to 40 years of age); the spaces (opacities) are isolated in the cortex around the periphery of the nucleus. They contain a finely granular coagulum. The nucleus is normal. Usually the opacity becomes total.

In **black cataract** (*cataracta nigra*) the entire lens has sclerosed, *i.e.*, both cortex and nucleus. Contrary to the popular idea, these cataracts contain no trace of blood-pigment, although a very black cataract may be caused by hemorrhage.

With progressive loss of water, the disintegrating lens becomes more and more inspissated; separation of cholesterin crystals and partial calcification occur. In other cases calcification begins so early that the lens

is in great part or entirely petrified: *petrificatio lentis* (*cataracta calcarea*).

Ossification of the lens occurs very rarely. It is a prerequisite that the capsule should have been opened or absorbed to afford entrance to the bone-corpuscles.

The term **complicated cataract** is used to designate lenticular degenerations due to other disease of the eye which interferes with the nutrition of the lens. They are produced by a variety of diseases, notably iridocyclitis, hypopyon ulcer, glaucoma, retinitis pigmentosa, etc. As a rule, the opacity first develops in the cortex at the posterior pole: posterior cortic cataract. Degeneration of the anterior pole usually follows, and the entire lens ultimately becomes opaque. In these cataracts the entire lens shrinks and becomes distorted. The capsule thickens, while the lens fibers liquefy and are absorbed. In an active pathologic process, such as panophthalmitis, tuberculosis, etc., the capsule may be perforated and the lens invaded.

Toxic cataracts have been caused by ingestion of ergot and naphthalin. They are believed to be produced by nutritive disturbances, because a lens immersed in these liquids does not become opaque. Cataract occurs in a certain proportion of cases affected with *diabetes mellitus*. This is generally attributed to absorption of water from the lens by sugar in the aqueous. Injections of sugar and salt solutions may cause opacity of the lens, but only when the solutions are very much stronger than is ever found in the aqueous. The epithelial cells of the ciliary processes suffer in diabetes and are separated from their attachments. Therefore, the lens may simply become opaque from lack of nutrition, or some unknown toxic material may be developed in the system in this disease which exhibits an affinity for the lens. The pathologic changes in the lens usually commence just beneath the capsule. They are similar to those found in other forms of cortic (soft) cataract. Ordinary senile cataract may occur in a diabetic individual. Diabetic cataract is usually bilateral, occasionally unilateral.

Traumatic cataract is not always preceded by a wound; it develops also after action of blunt force, as well as after lightning stroke or other violent discharge of electricity and convulsions. When the capsule has been injured, the subsequent changes depend upon whether it has been perforated or not. Small, nonperforating injuries usually close and often leave only a minimal opacity. Large, perforating wounds usually result in opacity of the whole lens, owing to the action of the aqueous upon the lens fibers. The latter swell and push their way partly through the capsular wall into the anterior chamber. If they are exposed to the action of the aqueous for a long time, all of the opaque lens fibers are completely absorbed.

Traumatic cataract is not infrequently complicated by inflammations, especially iritis and iridocyclitis, which result in adhesion of the lens to adjacent parts, or panophthalmitis with destruction of the whole eye or plastic iridocyclitis with termination in *atrophia bulbi.*

Juvenile or **congenital cataract** may be partial or complete. Usually they are bilateral. A similar type of cataract develops in early life. The partial variety is called lamellar cataract. The degenerative process is confined to a zone between the nucleus and cortex, *i.e.,* it forms an opaque envelope to the nucleus. In the affected region are spaces filled with granular and hyaline material. The nucleus is usually shrunken. After remaining stationary for a long time, lamellar cataract may subsequently be converted into total cataract.

In general soft cataract the changes are as described above, except that the spaces are larger. Although soft cataracts may develop in children without known cause, nevertheless, lamellar cataracts and an allied form, namely, soft nuclear cataract, are usually associated with dyscrasiæ affecting nutrition, as shown by defects in the osseous structures. There is frequently a history of convulsions. Most of the subjects exhibit evidence of rickets.

Fusiform (coralliform, spindle) **cataract** is a congenital cataract which assumes a coral-like formation. It is usually associated with lamellar cataract. The shape is attributed to adhesions between the nuclear portion of the lens and the anterior and posterior walls of the capsule. The subsequent growth of the lens draws the opaque fibers out into their characteristic form. It has also been ascribed to degeneration of the lens fibers during fetal life, when they pursue an axial direction. The following observations have an important bearing upon the development of congenital cataracts. Hess found in a 5-day-old chick that the lens sac, which at this time should have been closed, was still connected with the skin surface by a narrow canal through which young lens fibers were proliferating. Hess, therefore, argued that, should the lens sac close at this stage and undergo degeneration, the young, central, degenerated fibers would remain as a permanent central opacity. The lens grows by the external deposition of new fiber layers. During growth (in infancy or fetal life) the external layers may become opaque, and new, nonopaque fiber layers may later be formed externally. This has been advanced as the reason why lamellar cataract is limited to a small fiber layer between nucleus and cortex.

Anterior polar cataract. Loosely applied, this term is used to designate any opacity situated at the anterior pole of the lens, either cortic or capsular. Anterior cortic cataract is an opacity in the cortex and appears in complicated cataract (*q.v.*). It occurs also as a result of

capsular cataract. Anterior capsular cataract is sometimes due to persistent pupillary membrane. It is, however, most frequently due to proliferation of the capsular epithelium and corresponding degeneration of the contiguous lens fibers. Some writers consider that the degeneration of the fibers antedates the proliferation of the epithelium. The mass is gradually transformed into a hyaloid substance, or it may resemble connective tissue. The latter appearance is due to the inherent tendency of these cells to elongate and form fibers. In course of time the adjacent epithelium spreads over the posterior surface of the opaque area. They may deposit a cuticular membrane indistinguishable from the original capsule. Anterior capsular cataract is usually caused by prolapse of the lens against a perforating corneal ulcer. It is sometimes congenital. In children it is said to result from transient contact between the unbroken cornea and lens. In adult life this cause is insufficient to produce proliferation of the lens epithelium. In old capsular cataracts, retrograde processes are common, which may terminate in calcareous degeneration. The deposition of iris pigment and inflammatory exudates in iritis is sometimes classed as a form of capsular cataract. The term capsular cataract is, perhaps, a misnomer, inasmuch as the capsule itself is not affected. True opacity of the capsule has, however, been found by Treacher Collins in imperfectly developed eyes.

Posterior polar cataract also may be situated either in the cortex or on the capsule. Posterior cortic cataract is a stellate or rosette-shaped opacity in the posterior portion of the cortex, and occurs in complicated cataracts, *i.e.*, where serious internal eye disease coexists. This is the form that appears also among glassblowers: glassblowers' cataract. Posterior **capsular cataract** consists of a small, white, round opacity upon the posterior surface of the capsule in the region of the posterior pole. This form is always congenital and is due to the fact that the *arteria hyaloidea,* which in fetal life traverses the vitreous from the disk to the lens and supplies the vascular envelope of the fetal lens, has not been completely obliterated, but remains as a permanent opacity upon the surface of the capsule.

The membrane which persists or forms after cataract extraction is termed **secondary cataract.** It may consist of the posterior portion of the capsule, or it may be a new-formed tissue of inflammatory origin. After operation some lens matter usually remains behind in the capsule, but this is mostly absorbed and is not a common cause of secondary cataract. The cells which line the anterior capsule may proliferate and form distorted lens fibers, or they may deposit a hyaloid membrane over the posterior capsule. These formations frequently resemble anterior polar cataract microscopicly and in their pathologic changes.

Opacities due to deposits on the hyaloid membrane of the vitreous have received the name of hyaloid cataract.

False position of the lens is either congenital or acquired. Congenital false position: *ectopia lentis congenita,* is due to unequal development of the suspensory ligament of the lens, so that this is generally longer in the upper part than in the lower, and the poles of the lens lie below the sagittal axis of the eye.

Every acquired false position is a **dislocation.** When there is only slight obliquity or lateral displacement, it is called subluxation; when associated with complete displacement, it is called *luxatio lentis.* Acquired changes of position originate either spontaneously or as a result of trauma. Spontaneous dislocation is the result of softening and disintegration of the suspensory ligament in liquefaction of the vitreous (after choroiditis, etc.), and as a congenital condition from elongated or deficient zonula. It develops also as the result of atrophy of the suspensory ligament in overripe and atrophied cataract. Traumatic luxation occurs principally as the result of action of blunt force by laceration of the *zonula Zinnii.* The lens may thus prolapse into the anterior chamber or commonly the vitreous. Dislocation beneath the conjunctiva or into Tenon's space may also occur. Dislocated lenses may change their position: thus, they may be in the anterior chamber at one time and in the vitreous at another. These are called "wandering lenses." In every instance the iris loses its tension (iridodonesis). The luxated lens becomes opaque in consequence of the altered nutritive conditions. Luxation may subsequently develop from subluxation as the result of traction of the flaccid iris upon the suspensory ligament. The further sequelæ of luxation of the lens are variable. In favorable cases, in dislocation into the vitreous, the lens may gradually disappear by absorption; in unfavorable cases the nonfixed lens causes irritation and inflammation: keratitis, iridocyclitis, increased tension (so-called secondary glaucoma), etc.

Foreign bodies are found in the lens when the capsule has been opened. Iron can be demonstrated in a lens with intact capsule in cases of *siderosis bulbi.* In such instances the metal enters the lens in solution.

The lens may be invaded by extension of adjacent glioma, tubercles, or suppuration.

Rare cases of parasitic invasion of the lens have appeared in medical literature. Filaria, *Oxyuris vermicularis,* trematodes, distoma, monostoma, and cysticercus have been reported. These reports, however, are not accepted by all writers. Nevertheless, among fishes epidemics of blindness occur, due to the presence of a parasite between the lens and its capsule.

Malformations.—Coloboma of the lens appears to be infrequent, although, owing to its peripheral position, it may frequently be overlooked. In more than half the cases there is an associated coloboma of other eye structures: iris, choroid, etc. Usually, the malformation consists of a slight peripheral notch, directed downward. Other forms are a linear defect with a small protuberance, or the lens may be elongated and pointed downward, terminating in a small notch.

Lenticonus is a condition in which there is a protuberance on either the anterior or posterior surface of the lens. This produces unequal lenticular refraction, which is highly myopic through the axis of the protuberance, while other parts may be emmetropic or hypermetropic.

When from any cause the lens has been destroyed, the condition is designated as **aphakia.**

VITREOUS HUMOR.

The vitreous humor (*corpus vitreum*) is the only portion of the human body in which the embryonal mucous tissue is preserved, although in somewhat altered form. The vitreous has a soft, gelatinous consistency, is entirely colorless and clear, and contains only a few branching cells and leucocytes, the latter situated particularly at the outer portion. The supporting tissue consists of a reticulum of long, delicate fibers, attached to the hyaloid membrane (the envelope of the vitreous), which are very numerous at the *ora serrata.* In normal eyes which have been subjected to laboratory methods of hardening, they are frequently seen in great numbers floating out to form the so-called "horse's tail." They were formerly mistaken for inflammatory products constituting the condition known as "fibrillary degeneration." According to Greeff, the only alteration which these fibers undergo is solution. Their absorption liberates the vitreous, which then loses its viscidity. In the anterior portion of the vitreous there is a flat depression—the *fossa patellaris*—which receives the posterior surface of the lens. Through the center of the vitreous runs the hyaloid canal (*canalis hyaloideus*)—the central canal which extends from the papilla of the optic nerve to the posterior pole of the lens. In embryonic life it is occupied by the hyaloid artery. The vitreous is surrounded by a homogeneous membrane—the hyaloid membrane—which is nonvascular[1] and, therefore, dependent for its nourishment upon the surrounding tissues (retina, choroid, ciliary body).

The vitreous plays a purely passive part in the pathology of the eye. The only changes which occur in its structure *per se* are degenerative. Inflammatory material found in the vitreous is always derived from other parts. Leucocytic infiltration usually originates in the ciliary body. (See Cyclitis and Panophthalmitis.) Leucocytes from the choroid cannot pass into the vitreous unless the *lamina vitrea* of the choroid has ruptured or disappeared. Serous transudates, however, may enter either from the retina or choroid. In the plastic forms of cyclitis (syphilis, sympathetic ophthalmia) exudates enter the vitreous and form dense membranes be-

[1] Vascular in the embryo.

hind the lens. The most frequent cause of detachment (so-called shrinking) of the vitreous is contraction of such inflammatory products. Other causes are neoplasms and subhyaloid hemorrhage.

Opacities of the vitreous (*opacitates corporis vitrei*) are due to various causes. Most frequently they consist of round, partly pigmented and fatty granular cells and isolated stellate cells undergoing segmentation. They usually lie in groups, less frequently uniformly distributed. Owing to the coincidence of these phenomena with inflammatory manifestations in the uveal tract, the opacity caused by the presence of cells was formerly called hyalitis, which is now an abandoned term, as the vitreous is incapable of inflammation. Iritis, choroiditis, or retinitis is always present.

Mouches volantes, *myodesopsia,* are entoptic perceptions—shadows—of small bodies in the vitreous, which are of no pathologic significance.

In **prolapse of the vitreous** (*prolapsus corporis vitrei*) through a scleral wound, and in entrance of a foreign body, a purulent inflammation always develops, provided infectious germs enter the vitreous. If this is limited to a portion of the vitreous, abscess of the vitreous develops; if, however, it spreads over the whole vitreous, the purulent process involves also the adjacent parts and results in panophthalmitis.

Sometimes young connective tissue develops from exudates in the vitreous; at first delicate, spindle-shaped, and stellate cells appear, and later slightly striated intercellular substance is formed. When this newformed connective tissue becomes older and contracts, the vitreous degenerates and detachment of the retina from the choroid is thus produced.

Detachment of the retina is observed also after prolapse of the vitreous, when no infection occurs and the prolapse cicatrizes.

Liquefaction of the vitreous: **synchysis,**[1] occurs in chronic retinitis and choroiditis, in advanced age (as an involution phenomenon), in extreme myopia, and in chronic glaucoma; the vitreous then forms a ropy fluid (Fuchs).

Hemorrhage occupies a prominent place in the pathology of the vitreous. Blood in the vitreous may come from the retina, ciliary body, or choroid. Aside from trauma, it occurs in such diseases as lead to vascular degeneration or to altered states of the blood. A class of cases in which the etiology is obscure occurs in young adults.[2] Extensive vitreous hemorrhages appear, which frequently are repeated at regular intervals (recurring vitreous hemorrhages in the young). Some-

[1] From σύν and χέω, to pour.

[2] It is often due to tuberculosis of the retina, ciliary body, or choroid.

times vitreous hemorrhages appear to be connected with menstrual disorders. Panas thinks that in the young the hemorrhage is of venous and in the old of arterial origin. Vitreous hemorrhages usually precede *retinitis proliferans,* and the membranes found in this disease are supposed to be of hemic origin. Small hemorrhages may be absorbed without impairment of vision. Extensive hemorrhages may destroy the vitreous or lead to loss of the eye from glaucoma.

Of the causes and nature of the opacities observed during life in syphilitic chorioretinitis and in glaucoma (vitreous dust, diffuse and dust-like opacity of the vitreous) nothing positive, histopathologicly, is known.

Chemic changes also occur in the vitreous, as is shown by the formation of phosphates, fats, and cholesterin. When cholesterin crystals are present in large numbers they are visible with the ophthalmoscope. This condition is known as *synchysis scintillans.* In some cases this phenomenon is present in otherwise normal eyes with very acute vision, even when the fundus is ophthalmoscopicly completely hidden by the scintillating bodies. Several cases have been reported of microphthalmic eyes in which the vitreous cavity was filled with fat. This was regarded as a metaplasia of the vitreous into fatty tissue. Leber, however, probably is correct in his view that the fat came from the orbit and entered the eye through an open fetal cleft—a condition common in microphthalmic globes. Small accumulations of fat are not uncommonly found in the degenerating contents of phthisical eyes (Greeff).

Intraocular parasites are rare. The cysticercus is the most frequent, particularly in northern Germany. It is usually situated between the retina and choroid, rarely in the vitreous itself. Opacity of the vitreous, retinitis, and choroiditis always accompany the presence of this parasite.

Membranes appear in the vitreous in connection with retinitis proliferans. Granulation tissue from the retina may grow into the vitreous and be converted into cicatricial tissue.

Adventitious tissue formed in the vitreous from the inflammatory products of adjacent parts may calcify or undergo ossification. Such cases have been miscalled "ossification of the vitreous." As a rule, in eyes where this process occurs, the vitreous cavity has been obliterated by total detachment of the retina.

UVEAL TRACT (TRACTUS UVEALIS).

The iris,[1] ciliary body, and choroid[2] form the uvealis, or uvea.[3] Considered together, they represent a colored sphere possessing a certain resemblance to a

[1] *Ἶρις* = rainbow.
[2] *χοριοειδής* = choroid (*χόριον* = membrane around the viscera: *chorium*).
[3] *uva* = grape.

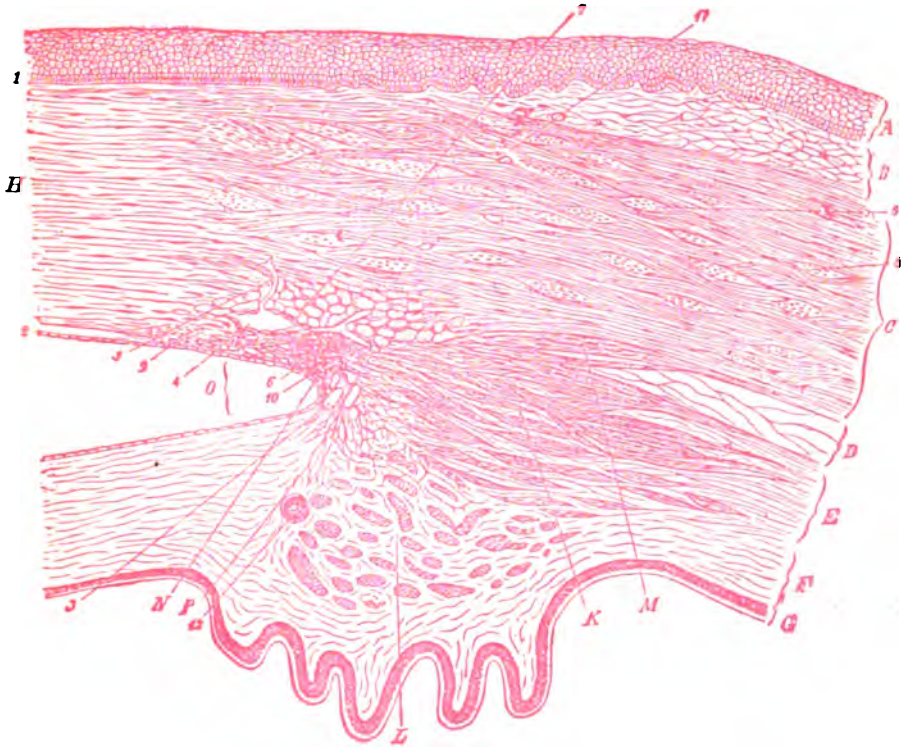

Fig. 517.—Section (from the eye of a man aged 30) showing the relations of the cornea, sclerotic, and iris, together with the ciliary muscle, and the cavernous spaces near the angle of the anterior chamber. (Magnified.) *A*, epithelium; *B*, conjunctival mucous membrane; *C*, sclerotic; *D*, membrana suprachoroidea; *E*, opposite the ciliary muscle; *F*, ciliary processes; *G*, tapetum nigrum and pars ciliaris retinæ; *H*, cornea (substantia propria); *J*, iris; *K*, radiating and meridional, and, *L*, circular or annular, bundles of the ciliary muscle; *M*, bundles passing to the sclerotic; *N*, ligamentum pectinatum iridis at the angle, *O*, of the anterior chamber; *P*, line of attachment of the iris. 1, anterior homogeneous lamina of the cornea (Bowman's membrane); 2, posterior homogeneous lamina (Descemet's membrane), covered with endothelial cells which are continued over the front of the iris; 3, cavernous spaces at the angle of the anterior chamber (spaces of Fontana); 4, canal of Schlemm, with endothelial lining, and with a vessel, 5, leading from it; 6, other vessels; 7, bundles of fibers of the sclerotic having a circular direction, cut across; 8, larger ones in the substance of the sclerotic; 9, fine bundles cut across, at limit of cornea; 10, point of origin of meridional bundles of ciliary muscle; 11, blood-vessels in sclerotic and conjunctiva, cut across; 12, section of one of the ciliary arteries. (After *Waldeyer*.)

grape. Anteriorly is a large, circular opening—the pupil—and posteriorly a smaller one at the point of entrance of the optic nerve. There is no sharply defined line of demarkation between the anatomic divisions of the uvea. They are so blended that a pathologic process starting in one may extend to all.

The internal circulation of the eye is supplied by the ophthalmic branch of the internal carotid. It is divided into two systems: the retinal and the uveal. The **retinal** is derived from the *arteria centralis retinæ,* which enters the eye through the optic nerve; its distribution is limited to the optic nerve and inner layers of the retina. The **uveal** system is supplied by the ciliary arteries, which nourish not only the entire uvea, but also the rod and cone layer of the retina. With the exception of an almost capillary anastomosis around the head of the optic nerve, these two systems do not communicate within the eye. The ciliary arteries which supply the uvea consist of three groups:—

1. The short ciliary arteries, which average from eight to ten. They enter the globe around the optic nerve and are distributed to the choroid.

2. The long ciliary arteries, two in number, which pass obliquely through the sclera anterior to the short arteries, one on each side of the nerve. They pass forward in the horizontal meridian between the sclera and choroid, without branching, to the posterior portion of the ciliary body, which they enter and supply. At the anterior margin of the ciliary body they bend abruptly and anastomose with each other, thereby forming an arterial ring near the root of the iris, known as the *circulus arteriosus iridis major.* From here radial branches enter the iris and anastomose around the pupil, forming a second arterial ring, known as the *circulus arteriosus iridis minor.*

3. The **anterior ciliary** arteries enter the eye from in front. They spring from the muscular arteries which supply the four recti muscles: one from the externus and two from each of the others. They pierce the sclerotic near the limbus and are distributed to the iris and ciliary body, principally through anastomoses with the great arterial circle of the iris. When passing through the sclera, the short ciliary arteries send branches toward the optic nerve, which anastomose and form an arterial circle in the sclera around the head of the nerve, called the circle of Zinn. From this circle branches communicate in the nerve with the central artery of the retina. Frequently, a branch from the circle enters the retina and is distributed (usually) between the nerve and macula. It may supply the macula and thus preserve vision in cases where the central artery of the retina is obstructed. Such arteries are called cilioretinal.[1] Occasionally a branch from the retinal vein passes from the nerve and enters the choroid. These are called opticociliary veins.

The **venous system** of the uvea is peculiar. The arteries of the choroid have no accompanying veins, but the venous blood is gathered into larger and larger choroidal veins, which converge and form (usually) four or five vortices, or whorls, which are situated a little behind the equator. From each of these whorls a large vein—*vena vorticosa*—passes obliquely backward through the sclera. The veins of the iris and ciliary processes pass backward, and also empty into the vorticose veins. Another system of veins from the outer portion of the ciliary muscle pass forward and empty, some into the canal of Schlemm and others—the anterior ciliary—into the conjunctival veins. It is the latter which appear upon the surface greatly distended in cases of glaucoma. The ophthalmic veins, corresponding to the ophthalmic

[1] It is questionable whether these vessels come from Zinn's circle or are branches of the central artery given off far back in the nerve.

artery, finally collect the venous blood from the eye and discharge it into the cavernous sinus. The ophthalmic veins have a very important anastomosis at the inner angle of the orbit with the angular (facial) vein. This communication relieves the circulation of the eye when the cavernous sinus is obstructed.

The root of the iris is attached to the anterior face of the ciliary body near its middle, so that a portion of the ciliary body is within the confines of the anterior chamber. The space between the root of the iris and the "sclerocornea" is filled in with loose trabeculæ of fibrous tissue continuous with Descemet's membrane, known as the *ligamentum pectinatum.*[1] The trabeculæ are covered by endothelial cells similar to those which line Descemet's membrane. The alveoli which exist in the pectinate ligament are called the spaces of Fontana. The tissue of the pectinate ligament is condensed in its outer portion and there forms the inner wall of a very important venous plexus, which drains the aqueous humor from the anterior chamber, known as the *sinus venosus scleræ,* or canal of Schlemm. This peripheral region of the anterior chamber formed by the junction of iris, ciliary body, and sclera is called the sinus of the anterior chamber; also the angle of filtration. The preservation of its integrity is of vital consequence to the eye. The anterior chamber, therefore, is bounded in front by the cornea and sclera, and behind by the ciliary body, iris, and that portion of the lens corresponding to the pupil. Only the pupillary margin of the iris rests upon the lens; consequently, a ring-shaped space is formed between the lens, periphery of the iris and ciliary body, designated as the posterior chamber.

The aqueous, produced by the ciliary processes, appears first in the posterior chamber, passes through the pupil into the anterior chamber, and, filtering through the meshes of the pectinate ligament, enters the canal of Schlemm.[2] Any obstruction to this current subjects the eye to hydrostatic pressure—a condition known as glaucoma. (See p. 1047.)

From the preceding description, it will be seen that the same vessels supply the iris and ciliary body. This explains why both are so frequently affected by the same inflammatory processes. The iris is a discoid membrane, with a nearly central perforation—the pupil—which acts as a mobile diaphragm to regulate the amount of light entering the eye. The stroma of the iris consists of blood-vessels (described above), which have a very thick adventitia and thin media. These are united by numerous, branching, stellate and spindle-shaped cells containing more or less brown pigment and a small amount of delicate fibrous tissue. Near the pupillary margin is an unstriped circular muscle: the *sphincter iridis.* It is attached by delicate processes to the posterior pigmented cells and is said by Szili to be developed from them. The anterior surface of the iris contains numerous depressions or crypts, situated principally along the minor arterial circle and at the periphery. The endothelial cells which line the cornea are continued on to the iris and cover all its anterior surface, but do not enter the crypts. The posterior surface of the iris is covered by two layers of deeply pigmented epithelium: the *pars iridicæ retinæ.* This is the retinal part of the iris and represents, embryologicly, the anterior limit or edge of the secondary optic cup. The

---

[1] Henderson (*Trans. Ophth. Soc.,* 1908) considers the pectinate ligament as an open, nonsclerosed portion of the sclera, and, consequently, the ciliary body takes no part in the formation of the anterior chamber. This view has met with opposition.

[2] On puncture of the anterior chamber, the aqueous humor, the intraocular pressure being diminished, is replaced in a very short time. (See Glaucoma, p. 1047.)

posterior layer of pigmented epithelium consists of large, loosely attached, polygonal cells. The anterior layer consists of small spindle cells, considered to be a direct continuation of the pigment epithelium of the retina. Between this layer and the stroma is a delicate fibrous membrane: a continuation of the posterior limiting membrane of the retina. This membrane has been regarded as the dilator of the pupil. It is a product of the anterior layer of pigmented epithelium, just as the lamina vitrea of the choroid is deposited by the pigmented epithelium of the retina. The same name—Bruch's membrane—is applied to both. Peculiar muscle-fibers—dilators—arise from the anterior portion of the protoplasm of the epithelium and fuse with the membrane, while the nuclei of the fibers remain in the posterior pigmented portion of the cell. The pigment layers of the retina extend into the pupillary space, where they appear as a black ring. The iris is innervated from the ciliary branches of the lenticular ganglion and the long ciliary nerve from the fifth. The *sphincter pupillæ* is supplied by the third nerve through the motor root of the lenticular ganglion, while the *dilator pupillæ* is supplied by the sympathetic fibers of the ganglion.

Wounds of the iris, as after iridectomy, unless exposed, are not followed by the formation of granulation and scar- tissue, but remain open. This fact is supposed to explain the value of iridectomy in some cases of glaucoma, inasmuch as the opened iris-tissue provides an avenue for the escape of aqueous. Incisions of the iris close to the root are followed by the formation of scar-tissue (Oatman).

Inflammations of the iris are always exudative in character. Inflammation of the ciliary body usually, if not always, coexists. Infiltration of the iris-tissue causes thickening, limitation of movement, and narrowing of the pupil. Our knowledge of the intimate changes occurring in iritis is due principally to the investigations of von Michel. In addition to the vascular phenomena characterizing inflammatory processes elsewhere, there is first an exudate of fibrin and cells upon the anterior surface beneath the epithelium. Increase in the amount of the exudate ruptures the epithelium, and fibrinous material appears in the anterior chamber, in the pupillary space, and infiltrates the spongy tissue of the iris. The exudate which now appears in the posterior chamber probably comes from the ciliary body. The process may be purulent in character (*e.g.*, after trauma: presence of foreign body), and the amount of fibrin comparatively small. In the septic form hemorrhages are common. The accumulation of pus-cells at the bottom of the anterior chamber is called hypopyon. The cells of the *pars iridicæ retinæ* are macerated and cast off, many of them entering the iris stroma. If markedly fibrinous, the exudate adheres to the anterior surface of the iris and sometimes also to the anterior surface of the lens capsule. In the latter case a membrane, which closes the pupil, may organize (*occlusio pupillæ*). When the exudate forms upon the posterior surface of the iris (in the posterior chamber), synechiæ of the posterior surface of the iris with the anterior

surface of the lens capsule very easily develop. These are generally at first circumscribed, but when frequent recidives occur, as is very often the case, they may gradually result in complete, flat adhesion (total posterior synechia) or in adhesion of the pupillary margin only of the iris with the anterior surface of the lens (posterior annular synechia), which completely shuts off the anterior chamber from the posterior chamber. This state is called pupillary occlusion (*seclusio pupillæ*). Pupillary occlusion, by blocking the flow of aqueous, is followed by increase of intraocular tension. In annular posterior synechia the pressure of aqueous bulges the iris forward against the cornea: *iris bombe*. This leads to adhesions between the iris and cornea: anterior synechia.

The term **mydriasis** is employed to designate abnormal dilation of the pupils, and myosis[1] abnormal narrowing. These occur bilaterally as well as unilaterally; in the latter case there is difference in size of the pupillary opening: anisocoria.[2] The cause of the abnormal dilation and narrowing may be either spasm (active, spastic) or paralysis (passive, paralytic).

Active or **spastic mydriasis** depends upon irritative states of the nerve-centers (irritation of the sympathetic). The passive form is by far more frequent, and is caused by paralysis of the sphincter pupillæ (paralysis of the corresponding oculomotorius fibers). It develops also as the result of small lacerations of the iris following contusions (*iridoplegia traumatica*); through the local action of various poisons (atropine); after diphtheria, poisoning from ingestion of putrid meat, etc. Mydriasis in glaucoma is ascribed to pressure on the nerves. In total blindness the pupil is dilated, because it is not stimulated to contract by perception of light in the eye.

Active or **spastic myosis** is due to spasm of the *sphincter iridis* (oculomotorius irritation) and is produced by beginning meningitis and by certain poisons (eserine, pilocarpine, opium, nicotine, chloral). Passive paralytic myosis (sympathetic paralysis) occurs after injuries of the cervical sympathetic; in pressure of tumors (most frequently enlarged glands) upon the sympathetic, and, finally, it is an important accompanying symptom of various affections of the spinal cord, particularly of *tabes dorsalis* and progressive paresis. Myosis of spinal origin is frequently characterized by loss of light reaction, but synchronous reaction in accommodation and convergence (**Argyll-Robertson pupil**).

The undue amount of light entering the eye in mydriasis leads to disturbance of vision from dazzling. The frequent accompanying paraly-

[1] μύω = to close.
[2] ἀ priv., ἴσος = equal, and κόρη = girl, pupil.

sis of accommodation causes objects to appear small: micropsia. In myosis, on the other hand, the spasm of accommodation causes objects to appear enlarged: macropsia.

In paralysis of the sympathetic the pupil is contracted (it is best seen in a subdued light); there is a slight ptosis due to paralysis of Müller's palpebral muscle and a slight enophthalmos from paralysis of Müller's orbital muscle. (See p. 1085.) In the early stage the paralyzed side of the face is warmer and the blood-vessels fuller, but later it becomes paler and perspiration is abolished. In irritation of the sympathetic the paralyzed side is pale, perspiration is increased, and the pupil dilated. There is slight elevation of the upper lid and moderate exophthalmos. Most of these phenomena are produced also by instillation of cocaine. Under normal conditions the pupils are in constant, even though slight, motion. Sometimes this motion is abnormally increased and there is marked alternating contraction and dilation. This condition is known as hippus.

Iridodonesis,[1] or **tremulous iris,** is due to insufficient support of the iris. The cause is usually diminution in size or dislocation (luxation) of the lens, the iris thus losing its support.

Hyperemia of the iris may be caused by severe inflammation of the cornea, sclera, conjunctiva, or portions of the uveal tract other than the iris. The pupil is contracted and reacts sluggishly to light. This loss of motility is due to rigidity and dilation of the blood-vessels, and also to irritable spasm of the ciliary muscle. These phenomena may subside, or, on the other hand, increase in severity and proceed to the stage of inflammatory exudation. Iritis is most frequently caused by some systemic dyscrasia, rheumatism, syphilis, gout, etc. Clinicly, it is nearly always associated with inflammation of other parts of the uvea, particularly the ciliary body.

In subacute and acute iritis the endothelial layer is extensively separated from the iris by a finely fibrous exudate, the meshes of which contain large numbers of leucocytes. In the severe cases the exudate fills the stroma and, when the endothelium is destroyed, extends into the anterior and posterior chambers. It also blocks the pupillary space. The infiltrating cells consist of lymphocytes, polymorphonuclear leucocytes, and mast-cells. The exudate in the posterior chamber is probably derived from the ciliary body, which participates in the inflammatory process. Sometimes the posterior pigmented cells of the iris are separated by exudate or blood. Cystic spaces also may form between the two layers. The pigmented cells of the *pars iridica* lose much of their

[1] *δονέω* = shake, tremble.

pigment and are cast off. The exudate causes more or less extensive adhesions between the iris and lens. This is very firm, and, if broken, the pigmented cells remain attached to the lens.

Purulent iritis. Suppurative inflammation of the iris may follow infected wounds of the eye or appear as a metastasis in septic and infectious diseases. When it results from direct infection, it usually exists as a feature of panophthalmitis. The pathologic findings vary according to the stage of the disease. They correspond in a general way with suppurative inflammation of other tissues. The anterior chamber is filled with pus. The blood-vessels contain bacterial and fibrinous thrombi. More or less tissue necrosis takes place. The metastatic form may resolve without breaking down of the external coats of the eye. If the patient survives, atrophy of the globe follows.

The large, irregularly distributed blood-vessels sometimes observed upon the surface of the iris in old cases belong not to the iris, but to the inflammatory membrane which covers its surface.

Chronic iritis. Many forms of iritis may assume a chronic course. Consequently, the greatest variety of morphologic changes are to be looked for, depending upon the character of the inflammation and associated disease in other parts of the eye. Under the name of chronic iritis Michel groups those cases in which acute attacks have left slight discoloration and synechiæ. In certain cases where, to the eye, areas of the iris appeared thickened, iridectomy was performed and the amputated sections examined microscopicly. Quite characteristic changes were found. In the thickened areas were curious nodular formations. The lumina of the small vessels were nearly or completely closed by proliferative changes in the intima. The adventitia contained aggregations of epithelioid cells, which formed round or spindle-shaped nodules. Epithelioid cells were scattered also throughout the stroma. In cases associated with cyclitis there is frequently extensive proliferation of the endothelium. Hyaline degeneration occurs with the formation of homogeneous nodules upon the surface of the iris. A chronic form of iritis is associated with uveitis under the name of plastic iridochoroiditis; more correctly, uveitis.

Recurrent iritis is not infrequently followed by atrophy of the iris. According to Fuchs, atrophy of the iris may be due to the following causes: 1. Long-continued or frequently recurring inflammation. 2. High intraocular pressure exerted upon the blood-vessels, particularly those at the root of the iris. In inflammatory glaucoma atrophy may develop in a few days. 3. Iridodialysis, whereby vessels from the *circulus arteriosus iridis major* are lacerated. 4. Dragging; this occurs when both ciliary and pupillary borders of the iris are fixed and the two

points slowly separated; most frequently observed when the iris becomes attached to a cornea which later becomes ectatic, or when from iritis in childhood the iris becomes attached to the lens capsule. 5. Through extension of resorption, as, when swollen lens fragments rest upon the iris and are slowly absorbed, the portion of the iris on which they lie sometimes disappears. 6. In extreme old age the iris may be so atrophied that the red reflex from the fundus can be seen through it. Gaps in its tissue may also result. The following changes are found in atrophic irides, especially when resulting from long-continued inflammation: The surface of an atrophic iris may exhibit spots either white or black. The black spots are pigmented cells of the posterior layer seen through holes in the iris produced by total absorption of both stroma-cells and stroma. Light-colored spots are produced by circumscribed disappearance of the stroma pigment. Von Müller, working in Fuch's clinic, observed several cases in which numerous white spots existed upon the iris surface (*vitiligo iridis*). All the patients had passed through variola, which, undoubtedly, had produced a spotted atrophy of the stroma of the iris.

The thinnest portion of the iris is its root; consequently, in advanced atrophy spontaneous iridodialysis may take place.

In **atrophy of the iris** resulting from long-continued inflammation, the delicate stroma is replaced by fibrous connective tissue. The blood-vessels are extensively degenerated or completely obliterated. At a late stage the ciliary muscle undergoes hyaloid degeneration. Disappearance of the stroma pigment changes the color of the iris. The plastic exudate covering the anterior surface of the iris organizes into a dense fibrous membrane, the contraction of which shortens the anterior layers of the iris, thereby dragging outward the posterior layers, so that the pupil appears surrounded by a black ring. This condition is called ectropion of the uveal pigment.

The endothelium may proliferate and form *Drusen,* or the entire surface may be covered with a hyaloid membrane which appears as a continuation of Descemet's membrane. Changes in the *pars iridicæ retinæ* vary. It usually persists as a black line when all other parts of the iris have disappeared. Its two layers may separate and form pseudocysts.

Calcareous and **bony degeneration of the iris** are not common. When bone is found it is usually an extension of bony degeneration of the choroid. One case of supposed primary bony degeneration of the iris has been reported by Parsons.

Syphilis of the iris. Michel considers syphilitic iritis as an endarteritis of the smaller vessels, the papules being secondary products of the obstructed circulation. It cannot at present be differentiated microscopicly from simple chronic iritis. Fuchs found the anterior layers of the

iris infiltrated with round cells; according to him, microscopic nodules are always present in syphilitic iritis, although none is visible to the naked eye. The nodules found were thickly infiltrated around the root of the iris; they were composed of round cells in a fine reticulum, and contained large numbers of wide capillaries.

Gumma of the iris usually forms a circumscribed, yellowish-red tumor on the pupillary or ciliary border. It is usually attended by only slight inflammatory reaction. The secondary manifestations of iris syphilis are inflammatory in character. In the tertiary stage there is a tendency to the formation of tumors. The microscopic findings in the few cases of gummata examined were not constant. The following conditions have been reported by different authors: vascular, round-celled deposit; round-celled deposit with caseation and necrosis; cavity containing leucocytes surrounded by tissue composed of round cells, giant cells, and epithelioid cells; tumor consisting of a structureless, granular center with a few round cells possessing a marked tendency to fragmentation of nuclei, the whole surrounded by a capsule of spindle cells.

Tuberculosis attacks the iris under three forms, namely, tubercular iritis, miliary tuberculosis, and conglomerate or solitary tubercle.

Diffuse tuberculous iritis is extremely rare. There is cellular infiltration and great thickening of the iris. Giant cells abound, but tubercle formation is rare. Tubercle bacilli are not easily demonstrated in this form of the disease, the diagnosis being more readily established by experimental inoculations.

In **miliary tuberculosis of the iris** small nodules are scattered over the surface. They are most numerous over the circular arteries and in the lower half of the iris. They are yellowish in color, and blood-vessels are frequently seen upon their surface. The tubercles may increase in size and number until they fuse and fill the anterior chamber and extend to the ciliary body and cornea. *Phthisis bulbi* follows perforation. These cases usually die with general miliary tuberculosis. One form, the attenuated tubercle of Leber, which occurs in young adults, is characterized by the appearance of a number of small nodules near the pupillary margin, which subsequently disappear, leaving posterior synechiæ. In this connection it is well to remember that, months after the disappearance of tubercles from the iris, the patient may develop other manifestations of tuberculosis, particularly meningitis.

Conglomerate tubercle of the iris forms a distinct tumor, frequently surrounded by daughter deposits. The neoplasm is composed of aggregated tubercle systems. Extensive caseation exists, and tubercle bacilli are demonstrable more readily than in the other forms of tuberculous iritis. The direction of growth is outward, and perforation occurs before

the choroid is affected. Caseation and *phthisis bulbi* ensue soon after perforation. Conglomerate tubercle usually occurs in one eye only. In the other forms one or both eyes may be affected.

Tuberculous iritis is a disease of the young. De Schweinitz gives the average age as 12 years. It is a question whether tuberculosis of the iris occurs as a primary disease or is always secondary to tuberculosis of other parts. The subject is complicated by the frequent mistakes made in diagnosticating tubercle. Greeff says: "It is extremely difficult to diagnosticate tubercle from an anatomic preparation alone." Recent experiments in the diagnosis and treatment of plastic iridocyclitis with tuberculin indicate that many obscure cases of this disease are tuberculous in origin.

Leprosy of the iris is a chronic recurrent affection which terminates in destruction of the eye. It occurs as a diffuse inflammatory infiltration of the tissues, closely resembling the rare form of general tubercular iritis. It is usually preceded by leprosy of the ciliary body. Leprosy bacilli are found in large numbers.

Nodular iritis. Many forms of iritis give rise to nodular accumulations of cells around the blood-vessels. They form not only in syphilis, leukemia, leprosy, and tuberculosis, but also in chronic iritis from any cause. The nodules are composed principally of leucocytes, although epithelioid and giant cells are usually present. A special form of nodular iritis is produced by caterpillar hairs which have migrated from the conjunctiva into the iris.

Cysts of the iris. Two kinds of epithelial formations occur in the iris: cysts with fluid or semifluid contents (extension or implantation cysts), and solid epithelial tumors (pearl cysts). They are discussed together, inasmuch as the solid tumors may become cystic. The extension cysts invariably follow perforation of the cornea. The great majority of them are formed from epithelium which has extended to the iris by ingrowth along the track of a corneal wound. It has, however, been demonstrated that detached epithelium implanted in the iris may proliferate and form a cyst. In such manner pearl tumors form around an eyelash which has been carried into the anterior chamber by violence. The walls of an epithelial iris cyst are usually formed of attenuated iris-tissue lined with superimposed layers of laminated epithelium. The cornea and lens may participate in forming the cyst walls. Sometimes the ingrowing epithelium is not circumscribed by iris-tissue, but lines the entire anterior chamber. Such cases are called cysts of the anterior chamber. The cyst contents vary, but usually consist of a turbid fluid, epithelial detritus, and products of epithelial degeneration. If, as in von Graefe's case, the cyst contains sebaceous material and hair, it must be considered as having developed from implanted tissue. The

pearl tumors which form around cilia develop from the epithelium of the root-sheath which remains attached to the hair. They are composed of laminated epithelial cells. Their contents may be hornified or softened and broken down.

Retention cysts (agglutination cysts). Serous cysts not lined by epithelium occur in the iris. They may be congenital. Probably most cases result from superficial agglutination of the mouths of the iris crypts. Their etiology, however, is obscure. The following causes have been assigned for their development: presence of a foreign body, indispensable to their formation (Sattler); fusion of the strands which cross the crypt openings (Schmidt-Rimpler); injury resulting in separation of the pectinate ligament of the iris and separation of the layers of the iris with transudation and hemorrhage into the iris (Everbusch); adhesions between iris folds and retention of aqueous (de Wecker); injury followed by proliferations of endothelium (Greeff). Cysts may occur in connection with coloboma of the iris or other malformations. Dermoids of the iris have been reported. They closely resemble the pearl tumors. Cysticercus cysts occur very rarely. They are accompanied by severe iritis.

Cysts of the *pars iridicæ retinæ*. Small cystoid spaces, situated in the pigmented epithelium on the posterior surface of the iris, are frequently observed in eyes enucleated for various diseased conditions. Probably a combination of factors is necessary to produce a cyst in the *pars iridicæ retinæ*. The shrinking of organized plastic exudates may separate the inner from the outer layer, particularly if the iris is sclerosed and rigid. Perhaps the support afforded the inner layer of cells by an adventitious inflammatory membrane is essential to the formation of a large cyst. Treacher Collins regards obstruction to the lymphatic circulation as the principal cause. Obstruction is certainly promoted by adhesions of the iris periphery to the cornea. Another possible factor is vitiated aqueous humor. This is illustrated in severe cases of diabetes, in which iridectomy may be followed by swelling, softening, and exfoliation of the posterior pigment cells, and also by the formation of large cysts. This condition is attributed to the presence of sugar in the aqueous. The tumors under consideration are not true cysts, but accumulations of fluid beneath the retinal layer of the iris. Their analogy to detachment of the retina is very evident. They sometimes appear in eyes not degenerated, and they have been mistaken for melanosarcoma and the eye enucleated.

Nevus (melanoma). Dark-brown or black deposits are frequent on the anterior surface of the iris. Sometimes they form masses of sufficient size to be regarded as tumors. They occur, as a rule, on or near the pupillary border. Considerable confusion exists regarding the

origin of some of these melanotic growths. Probably they may arise from any of the pigment cells found in the iris, of which there are three varieties, namely, the pigmented stroma cells and the two layers of the *pars iridicæ retinæ*. In the horse large masses of pigmented cells project from the uveal layer into the pupillary space. Similar formations are occasionally seen in man. Melanomata of the iris may be congenital. As a rule, they grow very slowly, although they may give rise to sarcoma.

Vascular tumors of the iris have been reported as angiomata. Doubt as to their genuineness has been expressed by writers, who have regarded some as simple granulomata which bled easily, and others as sarcomata.

Carcinoma and **glioma** invade the iris by a process of extension from other parts. Cases reported as primary carcinoma of the iris are susceptible of some other interpretation.

Primary sarcoma is far less frequent in the iris than in other parts of the uveal tract. When present, it is usually pigmented, although so-called leucosarcoma is known to occur here. Greeff says that melanosarcoma of the iris belongs to advanced life (over 40), while the cases of leucosarcoma occur in the young. As a rule, it develops in the anterior layers of the iris, although a case has been reported which was supposed to spring from the *pars iridicæ retinæ* (Kirschbaumer). It may originate in a *nævus pigmentosus* or from the walls of the blood-vessels (perithelioma). Iris sarcoma is nearly always of the spindle-celled variety. The round- and mixed- celled forms are very unusual. Sarcoma of the iris appears as a small, brown, vascular tumor, which grows very slowly with little accompanying iritis. After a time it grows more rapidly. It usually perforates the globe along the course of the anterior perforating ciliary vessels and appears externally in the anterior portion of the sclera. The site of perforation has some diagnostic importance, inasmuch as tubercle limited to the iris usually perforates at the limbus. Tuberculoma of the ciliary body, however, perforates the sclera posterior to the limbus.

Endothelioma occurs as a primary growth at the angle of the anterior chamber.

Dermoid cysts, melanotic tumors, and telangiectasiæ have been observed.

Coloboma iridis,[1] fissure or cleft of the iris (iridoschisis), is either congenital or caused by iridectomy. In congenital coloboma the pupil has a pear-shaped form, the apex directed downward. Cleft of the

[1] κολοβος = mutilated, maimed, crippled.

iris is often associated with unilateral or bilateral coloboma of the choroid. Coloboma of the iris is either typic or atypic. This defect is generally bilateral. When unilateral, the left eye is usually affected. In typic coloboma the fissure is downward or downward and somewhat inward. Atypic coloboma occupies some other section of the iris. The defect may be partial or extend to the ciliary border, and it is frequently associated with coloboma of the choroid or other arrest of development of the eye or face.

Absence of the iris (irideremia[1]) occurs congenitally and may be acquired by trauma, the iris being torn out or extruded through a perforating wound. More or less of the iris may be lacking at birth: *irideremia congenita* (aniridia). Although no portion may be visible clinicly, some rudiments of an iris can always be found on anatomic examination. Aniridia is frequently associated with other congenital defects, particularly of the lens. It may be present in one eye and coloboma of the iris in the other.

Detachment of the iris from the ciliary body is sometimes caused by contusion, a cleft being visible between both: iridodialysis.[2]

Hemorrhages of the iris are usually caused by traumatism. The extravasated blood enters the anterior chamber, sinks to the floor (hyphemia), and is, as a rule, absorbed after a short time.

Rarely, remnants of the *membrana pupillaris* persist from the fetal period throughout life as delicate, reticulated striæ or plaques in the pupillary region: persistent pupillary membrane (*membrana pupillaris perseverans*). Usually a few threads attached to the anterior surface of the iris pass across the pupillary space, occasionally uniting on the anterior surface of the lens. Unlike inflammatory synechiæ, for which they may be mistaken, they do not interfere with the free movement of the iris.

Corectopia is a term applied to eccentric displacement of the pupil. The pupil may occupy the extreme periphery of the iris. Both eyes are frequently affected. It is an hereditary defect and often appears in several members of a family. Polycoria is an uncommon anomaly. Several apertures may exist in the iris separated from each other by iris-tissue or strands of a persistent pupillary membrane. *Heterochromia iridis*, or difference in color in the two irides, is a common phenomenon. It may be a congenital anomaly or due to cyclitis.

The **ciliary body** (*corpus ciliaris*) extends from the *ora serrata* to the anterior chamber. At the point of origin of the ciliary body the uveal pigment changes from brown to black. Meridional sections of the ciliary body are triangular in shape, the base being directed forward. It is divided into two portions: an

---

[1] ἐρημία = absence, defect.
[2] διάλυσις = separation.

anterior, which bears the ciliary processes—*corona ciliaris,* and a posterior, smooth portion—the *orbiculus ciliaris,* or *corpus planum.* The ciliary body is composed chiefly of unstriped muscle—ciliary muscle,[1] and is richly supplied with blood-vessels and nerves. The ciliary muscle is divided into an external longitudinal or meridionally directed portion: Brücke's muscle, and an internal circular portion: Müller's muscle. The ciliary processes, about seventy in number, are situated internal to the muscle. They are the most vascular portion of the ciliary body, being composed of congeries of blood-vessels held together by connective tissue and branching pigmented stroma cells. The epithelial lining of the iris—the *pars iridicæ retinæ*—is continued over the inner surface of the ciliary body, and the latter portion is known as the *pars ciliaris retinæ.* It consists of two layers of cells, the outer being deeply pigmented, while the inner consists of non-pigmented columnar cells, differing in this respect from those which line the iris. Certain elastic lamina enter into the formation of the ciliary body, which originate as follows: When the *lamina vitrea* of the choroid reaches the posterior point of the ciliary body its two layers separate, one, the elastic membrane, passing forward between the ciliary muscle and sclera, where it splits up to join the pectinate ligament in the angle of the anterior chamber; the second layer from the *lamina vitrea* of the choroid is a homogeneous, hyaline membrane which passes forward between the internal surface of the ciliary body and the pigmented epithelium, and is called the *lamina vitrea* of the ciliary body; a third hyaloid membrane is described as a continuation of the hyaloid membrane of the vitreous over the internal surface of the nonpigmented epithelium. The zonula of Zinn, or suspensory ligament of the lens, arises from this layer. The ciliary body participates in the visual act by regulating the refractive power of the lens: act of accommodation. This is accomplished as follows: When the lens is freed from all attachments it assumes a spheric form, but when *in situ* with its anatomic relations intact it becomes flattened. This flattening is produced by traction exerted upon its periphery by fibers of the suspensory ligament, which fixes the lens to the ciliary processes. Now, when the circular fibers of the ciliary muscle (Müller's muscle) contract, the ciliary processes approach the lens, the fibers of the suspensory ligament relax, and the lens, by its own elasticity, becomes more spheroidal. On the other hand, contraction of the longitudinal fibers (Brücke's muscle[1]) increases the space between the lens and ciliary processes, tightens the suspensory ligament, and thereby flattens the lens. This theory is supported by the fact that in hypermetropia, where vision is improved by increasing the sphericity of the lens, the circular fibers of the ciliary muscle are highly developed, while in myopia, where flattening of the lens is required, they are almost or entirely absent.

As previously stated (see p. 1021), iritis often accompanies cyclitis, iridocyclitis.[2] When the choroid also is involved there is uveitis. Cyclitis may be primary or secondary. In the first case the disease develops in the ciliary body as the result of constitutional dyscrasia or injury; in the second, the inflammation extends to the ciliary body from

[1] Called by Brücke, its discoverer, *tensor chorioideæ.* Subsequently, Müller differentiated internal circular fibers, which portion has since been designated as Müller's muscle.

[2] The term iridochoroiditis, formerly employed to designate this condition, takes no cognizance of the cyclitis, which is the dominant inflammation.

adjacent parts, as in serpent ulcer (hypopyon ulcer) of the cornea. The results of cyclitis vary according to the character and degree of the inflammatory action. Resolution may occur, leaving no permanent injury, or total loss of vision may ensue in one or both eyes. In the beginning of cyclitis the intraocular pressure is usually increased; later it may be normal or diminished.

Acute cyclitis, or *iridocyclitis exudativa,* is the most frequent form of inflammation occurring in the ciliary body. Unless the process is arrested at an early stage, it proceeds to suppuration or to cicatrization. The disease manifests itself first in the ciliary processes, which are swollen and infiltrated with mono- and poly- morphonuclear leucocytes, the latter predominating. They furnish a purulent exudate rich in albumin and fibrin. The exudate fills the posterior chamber and infiltrates the suspensory ligament of the lens. It extends also into the anterior chamber, where, if it is purulent, it forms a hypopyon, but if very rich in fibrin it may coagulate into a rounded mass closely resembling a dislocated lens. The exudate surrounds the lens and invades the vitreous. A condition of endophthalmitis now exists in which the tissues may necrose and form abscess (panophthalmitis) or undergo cicatrization. When the latter ensues the ciliary body, iris, lens, and retina are bound together by a mass of new-formed fibrous tissue called the cyclitic hull. The contraction that ensues drags the ciliary body and retina from their attachments, the vitreous shrinks, the globe softens, *phthisis (atrophia) bulbi* is established, and blindness results. During this process the *pars ciliaris retinæ* proliferates actively and forms long, branching tubules in the cyclitic hull. The lens degenerates, but its capsule remains as a wrinkled membrane. Hyaline, calcareous, and bony degenerations of the ciliary body are frequently found in old cases.

The classification of chronic cyclitis into serous and plastic indicates more the intensity or stage of the inflammatory process than any fundamental difference in their pathologic histology. Chronic inflammation appears under two forms in the ciliary body, *i.e.,* serous and plastic. The first form is known as cyclitis, or *iridocyclitis serosa* (formerly called also serous iritis, descemetitis, *keratitis punctata, aqua capsulitis*). It is characterized by punctate deposits upon the posterior surface of the cornea. These deposits, the significance of which was long misunderstood, are inflammatory products chiefly derived from the ciliary body. The deposits consist of conglomerations of leucocytes, many of which contain pigment from the uvea. This exudate, following the direction of the aqueous current, is deposited upon the lens, iris, and particularly the cornea. The centrifugal action produced by the motions of the eye also is an important factor in their distribution. As a result of gravitation, they tend to settle upon the lower portion of the cornea. They rest upon Descemet's membrane, which remains for a time unaltered; but if the deposits are large or remain long, the endothelium will be destroyed. After absorption of the leucocytes the inclosed pigment granules may

remain permanently upon the cornea or lens. Very large deposits have been termed lardaceous. Treacher Collins considers the disease to be a catarrh of the secretory apparatus of the ciliary body. The inflammatory action is greatest in the processes, the muscular body being but little affected. There are round-celled infiltration, particularly along the blood-vessels, and accumulations of similar cells between the ciliary muscle and pigmented layer of epithelium. The exudate passes through the epithelial layer with little injury to the cells. The histology of chronic plastic iritis in its early stages resembles that of serous iritis, except that the exudate contains a much greater quantity of fibrin. The subsequent course pursued by the disease is similar to that followed by exudative cyclitis.

Gumma of the ciliary body. Tertiary syphilis of the iris is not uncommon. Gummatous deposits in the ciliary body result in extensive destruction. In a case reported by Scherl, cheesy masses appeared in the anterior chamber and upon the lens. The deposit may be diffuse, but more frequently it is localized. Parsons has examined 3 cases, all presenting similar features. He says the inflammation was intense. The ciliary processes were covered with leucocytes. At their tips the pigmented epithelium was bleached. The ciliary body and choroid were detached from the sclera as far back as the equator. The space between the sclera and ciliary body was filled with a pigmented reticulum and an albuminous coagulum. The gumma had perforated the sclera and formed an external ulcer. As in the majority of other cases examined microscopicly, giant cells were absent. Baumgarten considers the presence of giant cells as an evidence of mixed syphilitic and tuberculous infection. In order to establish this diagnosis tubercle bacilli should be demonstrated.

Tubercle of the ciliary body. Primary tuberculosis may attack the ciliary body, or the disease may be an extension from the choroid or iris. Tuberculosis in this situation possesses a great tendency to soften and perforate the sclera. A conglomerate tubercle may supplant the entire thickness of the ciliary body and perforate the sclera without exciting the slightest irritation in the iris. After perforation, mixed infection may produce increased inflammatory phenomena. Tuberculous iridocyclitis probably appears also in plastic form.

Leprosy of the eye frequently appears first in the ciliary body. (See p. 1024.)

Atrophy of the ciliary body is secondary to various intraocular diseases, particularly iridocyclitis and glaucoma. From the gradual destruction of the secretory apparatus and consequent diminished amount of aqueous, the eye softens and *phthisis bulbi* may ensue. All degrees of ciliary atrophy are met in routine examinations of the eye. In light cases the body may be greatly flattened, while the ciliary processes are shrunken or entirely absent. Proliferation of the epithelium is frequently marked, even when the ciliary processes are imbedded in inflammatory

exudates. These atrophic ciliary bodies possess a latent irritability that is easily aroused by slight injury.

Tumors of the ciliary body. Under the stimulus of inflammatory irritation the *pars ciliaris retinæ* frequently proliferates and forms long, branching, epithelial-lined tubules or masses of epithelium, which Parsons describes under the name of hyperplastic epithelial tumors. Both the pigmented and nonpigmented epithelium proliferate. When these formations are imbedded in cicatricial tissue, a microscopic picture may be presented of vagrant epithelium and new-formed connective tissue closely resembling adenoma or carcinoma. A few cases have been reported as adenoma and adenocarcinoma by able observers. Other observers of equal experience have doubted the accuracy of this diagnosis. All cases thus far reported as undoubtedly originating in the ciliary body have followed injury or were discovered accidentally during examination of eyes removed for other conditions. If Treacher Collins's theory holds, namely, that true glandular structure exists in the ciliary process, adenoma and carcinoma are to be expected in this situation. This question, however, is still undecided. Adenocarcinoma does not usually occupy a subordinate pathologic position. If it occurs in the ciliary body, it should occasionally produce metastases and death of the patient. Greeff agrees with Krückmann and Emanual that, with the exception of glioma, it has not as yet been demonstrated that any neoplasm originates from the inner layer of the secondary optic vesicle.

Sarcoma. Only about 9 per cent. (Fuchs) of the cases of uveal sarcoma are primary in the ciliary body. It is difficult to differentiate, clinicly or anatomicly, primary sarcoma of the ciliary body from a peripherally situated sarcoma of the choroid. Sarcoma of the ciliary body rarely assumes the mushroom shape so frequent in sarcoma of the choroid, but usually forms a rounded growth with a broad base. In rare cases it appears as a flat infiltration of the entire ciliary body (annular, or ring, sarcoma). The latter, as well as flat sarcoma of the choroid, are considered by many accurate observers to be not sarcomata, but endotheliomata. It early extends forward into the root of the iris, while, conversely, sarcoma of the iris spreads backward into the ciliary body. The principal direction of growth is inward into the posterior chamber. The lens is subluxated and distorted. Intraocular tension is more frequently normal or diminished in ciliary sarcoma than in sarcoma of the choroid (Devereux Marshall). As a rule, sarcoma of the ciliary body is pigmented. A few cases of leucosarcoma have been observed in this situation. They occur as spindle-celled, round-celled, and mixed-celled sarcomata.[1] Cases have been reported as myxoma and as myx-

[1] For case of perithelioma of choroid and ciliary body, see p. 1041.

osarcoma of the ciliary body. The present tendency of writers is to regard all such tumors as sarcomata. A few neoplasms of the ciliary body have been diagnosticated as endotheliomata, aside from the so-called "ring sarcomata" already mentioned.

Cysts form in the *pars ciliaris retinæ* by separation of the external from the internal layer, and also by separation of both layers from the underlying parts. They occur most frequently in the posterior portion as a senile change. A cyst of the *pars iridicæ retinæ* may continue backward upon the ciliary body. Such cysts usually are associated with atrophy of the ciliary body, particularly cases attended by inflammatory exudation. Greeff describes a case of large cysts found in an atrophic eye enucleated seven years after an unfortunate operation for cataract. It is probable that the majority of such pseudocysts result from loosening of the epithelium and transudation from vascular stasis. An angioma of the ciliary body was found on microscopic examination of an eye by Oatman.[1]

Glioma is known to have originated in the *pars ciliaris retinæ*. It attacks also the ciliary body as an extension from the retina.

Senile degeneration of the ciliary body. In old age degenerative changes in the ciliary body are fairly constant. There is a general increase of the connective tissue. The walls of the blood-vessels thicken and degenerate. There is an increase in size and branching of the processes, thereby advancing the filtration angle in the anterior chamber. This is a causative factor in glaucoma. The nonpigmented epithelium proliferates and may form cystoid spaces. Proliferation of the pigmented epithelium is less frequent. The muscle-fibers shrink, leaving between the bundles, which may be empty or contain fluid, granular matter or fibrous connective tissue.

Sympathetic ophthalmitis. Wounds of the ciliary body are most serious in their results. If the eye is not destroyed by the injury or by suppuration, a low grade of inflammatory iridocyclitis develops, frequently followed by a similar inflammation in the fellow-eye. As a rule, both eyes are destroyed. Almost 80 per cent. of all cases of sympathetic ophthalmia follow perforating injuries of the ciliary body. The reason for this phenomenon is as yet in doubt. (See p. 1038.)

Fuchs calls attention to certain changes characteristic of sympathetic disease. The following description applies to the exciting (injured) eye: The uvea is crowded with mononuclear leucocytes (lymphocytes). In most cases the inner portion of this uniform infiltration contains nodular accumulations of large epi-

[1] The tumor was formed by dilation of the branches of the long ciliary artery as it entered the ciliary body. No connection could be traced between an existing detached retina and the angioma.

thelioid cells, among which giant cells are usually found. These nodules closely resemble tubercle systems. Isolated nodules may be found in the iris, ciliary body, and outer layer of the choroid. In other cases the uvea may be so filled and thickened by the deposit as to nearly or completely fill the globe. Invasion and perforation of the sclera may occur, followed by an external growth. According to Fuchs, these nodules undoubtedly are produced by the presence of some unknown, nonpyogenic micro-organism which causes chronic proliferation of tissue as does the tubercle bacillus.[1] In a late stage of the disease the cellular proliferations are replaced by dense connective tissue. This condition differs essentially from the ordinary plastic or exudative form of cyclitis, which is marked by preponderance of the polymorphonuclear leucocytes and by the appearance of the products of inflammation upon the surface of the uvea. In sympathetic disease, on the contrary, few or no polymorphonuclear leucocytes are present and the inflammation is not exudative, but formative, and occurs within the uvea, from which it escapes by progress of growth. Many cases of sympathetic ophthalmitis exhibit both forms of inflammation, but this is explained by considering that most cases follow perforating injury, whereby a variety of micro-organisms may be implanted. Fuchs was not the first to observe the presence of epithelioid proliferation in sympathetic disease. In 1895 Hirschberg pointed out that the injured eye contained granula closely resembling tubercle, from which he concluded that the disease was caused by a bacillus which excited tissue proliferation, not by a coccus or pyogenic organism.

The theory of reflex nerve irritation has received support from the investigations of Head and Campbell, who have shown that in herpes zoster all the phenomena of exudative inflammation upon the surface of the body are dependent upon disturbance of ganglion cells in the central nervous system. Roemer, experimenting with hemolysins, decides against the nerve-irritation theory.

Choroid.—The choroid is the vascular tunic of the eye. It varies in thickness from 0.08 mm. at the optic nerve to 0.05 mm. at the *ora serrata*. The blood-vessels are arranged in three layers according to their caliber. The external layer consists of the largest vessels, mostly veins. The stroma of this layer contains endothelial and pigmented stellate cells. The latter always possess prolongations. The middle layer is made up from the medium-sized vessels, and contains only a few pigmented cells. The inner layer (choriocapillaris) consists of closely arranged, very wide capillaries. This arrangement of the blood-vessels into layers is peculiar to the choroid. Under normal conditions pigmented cells are never found in the choriocapillaris.

Three membranous layers are connected with the choroid. The first, the suprachoroides, separates the choroid from the sclera. It consists of several delicate membranes lined with endothelial cells. Pigmented stroma-cells are irregularly distributed throughout. The middle, vascular layer is inclosed between two delicate membranes lined with endothelial cells (Sattler's membranes).

The choroid is separated from the pigmented layer of the retina by a third membrane, called the *lamina vitrea*, or membrane of Bruch, which consists of two layers, the inner being a homogeneous product of the pigmented cells of the retina, while the outer is an elastic membrane developed in connection with the choroid.

---

[1] Pseudotubercular formations containing numerous giant cells are so common in chronic intraocular inflammatory conditions that further proof is necessary to establish this theory.

The **pathology of the uveal tract** includes the pathology of the retinal epithelium by which it is lined. This applies no less to the choroid than to the iris and ciliary body. The pigmented epithelium of the retina consists of a single layer of nucleated polygonal cells the protoplasm of which is crowded with pigment granules (rod-shaped crystals). These cells form a close mosaic on the inner surface of the *lamina vitrea.*

The great vascularity of the choroid renders it very responsive to irritation. After comparatively slight disturbance, white blood-corpuscles migrate from the vessels and appear in the intercapillary spaces, which, under normal conditions, are entirely free from cells. The intensity of acute choroiditis varies according to the virulence of the infection. The most common cause is infected wounds of the eye, in which case the choroiditis forms a part of panophthalmitis. Infection occurs also from the presence of morbific elements in the blood (metastatic choroiditis).

Choroiditis. Inflammatory conditions of the choroid are broadly classed as suppurative and nonsuppurative. The suppurative form is an acute purulent process which terminates in panophthalmitis. Nonsuppurative, known also as subacute and exudative, choroiditis includes the varied forms of chronic choroiditis clinicly known as *choroiditis disseminata,* or *diffusa,* or *arcolaris,* etc.

The retina is always involved in subacute choroiditis; therefore, the disease is more accurately known as c h o r o i d i o r e t i n i t i s. Certain pathologic changes are common to all forms of subacute choroiditis, the lesions of which pass through the following stages: 1, exudation; 2, formation of granulation tissue; 3, cicatrization. In the exudative stage the fundus is covered with yellowish-red patches, the color being produced by the red choroidal reflex shining through a yellow exudate. In the cicatricial stage the diseased areas are covered by white scars of the most varied forms, surrounded or covered by masses of pigment. The vitreous may or may not be invaded by the exudates. As a rule, it is transparent in the atrophic stage, unless the ciliary body has participated in the inflammation and led to *phthisis bulbi,* etc. All or any portion of the choroid may be affected, although the most common site is the equatorial region. Unless there is associated cyclitis or iritis, the disease is not attended with pain.

Choroiditis is attended with various subjective symptoms, *i.e.,* photopsiæ which appear as glimmering flashes of light, stars, balls of fire, etc. If the disease is situated at the macula there may be metamorphopsiæ and objects appear distorted. Thus, if the rods and cones are spread apart objects appear too small, or if they are crowded together the objects appear too large. Night blindness—h e m e r a l o p i a—is frequently present. Finally, the affected areas become blind, and scotomata corre-

sponding to the affected areas are demonstrable with the perimeter. These scotomata are characterized by great irregularity of outline. In equatorial choroiditis there is peripheral or ring scotoma; in central choroiditis, a central scotoma, etc. The loss of visual power depends upon the location of the lesion. Thus, a large peripheral scotoma may entirely escape the observation of the patient, while a central scotoma of small size may completely destroy useful vision. The visual disturbances proceed from involvement of the retina. If the inner (nerve-fiber) layer of the retina is destroyed, atrophy of the optic nerve ensues.

Suppurative choroiditis usually follows infection of the retina, although in cases of panophthalmitis inflammatory changes in the choroid appear very early at the *ora serrata* and around the optic nerve. Other routes of invasion are from Tenon's capsule along the sheaths of the perforating vessels, and from the ciliary body along the suprachoroidal spaces. Bacterial emboli naturally lodge in the smaller vessels. Consequently, metastatic infection of the choroid usually appears first in the inner (capillary) layer. Schirmer found, however, that in sympathetic ophthalmia the choroid was infiltrated principally in its outer layers. Greeff points out that inflammatory foci not infrequently appear in the middle vascular layer, where masses of leucocytes accumulate, apparently unable to pass Sattler's endothelial membrane. In some cases of suppurative choroiditis the leucocytes may infiltrate the choroid throughout. In others they collect in masses or completely ensheath the blood-vessels. The leucocytes infiltrate the walls of the vessels. Thrombi are frequently observed. When hemorrhages occur they are due to necrosis. An abundant albuminous exudate is poured out, which, in prepared sections, shows a finely fibrous structure. As the lamina vitrea is very resistant, the exudate accumulates in the suprachoroidal spaces, producing detachment of the choroid from the sclera. Some of the exudate percolates through the lamina, as indicated by localized detachment of the retina. The lamina finally ruptures, and the exudate appears upon its inner surface. The retinal epithelium desquamates, and the cells lose their pigment. As the disease advances, the entire choroid is converted into a layer of granulation tissue in which only the large vessels of the outer layer remain. The granulation tissue may undergo necrosis or organize into fibrous connective tissue (scar).

Septic metastatic choroiditis is infrequent. It occurs in the course of septic conditions, particularly puerperal fever. The infecting organisms known to be causative are streptococci, staphylococci, and pneumococci. The micro-organisms are not readily demonstrated in hardened specimens. Metastatic choroiditis occurring in puerperal fever usually precedes a fatal termination of the disease. If life is sufficiently pro-

longed, perforation of the globe usually takes place. Termination in *phthisis bulbi* is more frequent in surgic than in puerperal septicemia. Although metastatic ophthalmitis is usually classed as choroiditis, there is little evidence to show that the choroid is first or even most severely involved. In the majority of cases it is probable that the disease occurs either in the retina or ciliary body before it reaches the choroid.

A form of metastatic ophthalmitis not infrequently attacks children suffering from acute infectious diseases, particularly meningitis. As a rule, all parts of the uvea develop a low grade of plastic inflammation. Early in the course of the affection the retina is totally detached and covered with exudate. This mass forms a yellowish tumor in the vitreous, which, from its resemblance to a malignant growth, is called **pseudoglioma.** Parsons considers this form to be an exudative process which never goes on to suppuration. Oatman, however, saw a pseudoglioma break down and produce increased tension several weeks after recovery from meningitis. Treacher Collins believes that it is primarily a retinitis, which is not improbable. Involvement of the ciliary body leads to atrophy of the bulb. The affected parts undergo the degenerations characteristic of chronic exudative disease.

In subacute and chronic choroiditis the cellular infiltrate consists almost entirely of mononucleated cells, *i.e.*, lymphocytes. This is the most characteristic and distinguishing feature of the disease. In most cases the cells tend to accumulate in the inner layer of the choroid, and, if Bruch's membrane is perforated, invade the retina. Between the choroid and retina the exudate forms dense deposits, which are subsequently transformed into scar-tissue, firmly uniting the two membranes. In later stages of the disease the outer layers are infiltrated. As a rule, localized foci of disease are distributed throughout the choroid. A diffuse infiltration is less common. In one form, known as nodular choroiditis, the lymphocytes are aggregated in masses around the vessels of the middle layer. Emigration of both the choroidal and retinal pigmented cells and pigment is a feature of chronic choroiditis. The stroma-cells of the choroid move inward and are found in the inner layer. They collect in masses around the areas of infiltration. They suffer degenerative changes, the extent of which depends upon the character of the inflammation, being most pronounced in tuberculosis and syphilis. As the outer layers of the retina depend upon the choroid for nutrition, a choroiditis is naturally followed by retinal inanition. Berlin found that section of the optic nerve in animals was followed by degeneration and pigmentation of the retina. He observed that as the pigment accumulated in the retina the epithelial cells were discolored. This phenomenon was explained by Wagenmann, who pointed out that in performing section

of the optic nerve not only the central artery of the retina, but also the short ciliary arteries, were cut, thereby interrupting the choroidal circulation and wholly depriving the retina of nourishment.

In subacute and chronic choroiditis the pigmented cells of the retina swell and exfoliate. They also discharge their pigment, which is taken up by the leucocytes. The cells appear in the inner layers of the retina, particularly around the vessels. If the *lamina vitrea* is perforated, they appear also in the choroid. Krückmann found that invasion of the retina by the exfoliated pigmented cells depended upon the condition of the external limiting membrane, the cells passing freely inward when this was broken. The pigment is deposited around and in the walls of the blood-vessels. The free pigment may be swept along by the lymph-stream or be taken up and carried by leucocytes.

After choroiditis, regeneration is affected by the common method of granulation-tissue formation and its development into fibrous connective (cicatricial) tissue. The amount of granulation tissue varies. It may grow exuberantly and invade the suprachoroidal space, retina, or vitreous (*choroiditis hyperplastica*). The pigmented epithelium of the retina proliferates actively, filling every inequality in the surface of the granulating mass in the same manner that corneal epithelium covers a wound or an ulcer. The amount of permanent injury inflicted upon the choroid depends upon the extent of the choroiditis, and also upon the presence of associated inflammation of other parts. Many cases of subacute and chronic choroiditis are complicated with concurrent inflammation of the ciliary body and iris. In such cases there may be total detachment of the retina and the final result atrophy of the globe. In simple or localized choroiditis the retina is but slightly elevated by effusion, and the formation of cicatricial tissue firmly unites the retina to the choroid, and both membranes undergo extreme atrophy. These changes are general or local, depending upon the extent of choroid originally involved. The exudates or hemorrhages that may accumulate in the suprachoroidal spaces frequently organize and form an adventitious membrane outside the choroid. When such inflammatory deposits are thick, they may be mistaken for fibromata. The suprachoroidal space may be filled with inflammatory exudates or serum derived from an inflamed ciliary body. By this route infection may be carried to the choroid. According to Fuchs, suprachoroidal membranes do not ossify in calcareous and bony degeneration of the choroid.

That form of exudative ophthalmitis resulting in so-called pseudoglioma has already been considered. (See p. 1036.) Chronic inflammation of the choroid most frequently occurs in the form of numerous, isolated foci of inflammation scattered throughout the fundus. This form of the disease is called *choroiditis disseminata.* In advanced cases the patches coalesce, forming large areas of disease. The histologic changes are those described above. In late stages of the disease the retina and choroid are represented by a thin layer of fibrous tissue. The pigment accumulates in masses around the borders of diseased areas. Syphilis of the choroid, both acquired and constitutional, usually appears in

multiple focal form. It is doubtful if gummata with necrosis occur in the choroid.

Sympathetic choroiditis (nodular choroiditis). In discussing sympathetic ophthalmia (see p. 1033), nodules were described as occurring in the ciliary body, iris, and choroid. In the early stages of sympathetic choroiditis nodular accumulations are superadded to the characteristic changes of chronic choroiditis. The nodules consist of endothelial cells and giant cells surrounded by lymphocytes. They develop in the outer vascular layer along the large vessels, particularly the arteries. In the other forms of choroiditis the cells appear in the inner layer. The nodules are differentiated from true tubercles by the irregular arrangement of the cellular elements and by the absence of caseation and tubercle bacilli. In advanced cases these formations disappear, being replaced by the degenerative changes of chronic choroiditis. Hirschberg and Fuchs consider the nodules of sympathetic disease to be the result of tissue change excited by the presence of a special microorganism.

As stated above, the destruction produced by acute and chronic inflammations of the choroid are repaired by the formation of scar-tissue, which replaces the original choroid. The structure and appearance of this cicatricial tissue appear to be greatly modified by the intraocular pressure. When this is diminished and the eye phthisical, the choroidal exudates form thick, irregular deposits. When, however, the intraocular tension is increased, as in glaucoma, or even remains normal, as in myopia, the choroid is converted into thin lamina or strands of connective tissue.

Sarcoma of the choroid is the most frequent growth that appears in the uvea. The vast majority of cases appear between the ages of 40 and 60 years. It occurs in the choroid as a primary neoplasm. Fuchs says that metastatic sarcoma of the choroid is unknown. Cases reported as such have not been established beyond doubt. The course of the disease is divided into four stages. In the first, or preglaucomatous, stage the eye is free from pain or inflammation. There is a defect in the visual field corresponding to the site of the growth. The overlying retina is detached and separated from the tumor by a thin layer of albuminous fluid. As the tumor increases in size, total detachment of the retina ensues. The duration of this stage is usually from six months to one year. Occasionally it continues for years. The glaucomatous, or inflammatory, stage is characterized by the appearance of a progressive, pernicious glaucoma which soon becomes absolute. This stage is more brief than the first. In the third stage the sarcoma breaks through the sclera. Extrabulbar extension takes place first along the course of some of the blood-

vessels which perforate the sclera or along the optic nerve. Rarely perforation follows along the ciliary nerves. The opening in the sclera relieves the intraocular tension, and pain subsides. Removal of pressure also permits a more rapid growth of the tumor. The fourth stage is that of metastasis and death. The liver is usually the first organ to receive a metastatic deposit. Sometimes a metastasis occurs before the growth perforates the sclera. Metastatic deposits do not necessarily resemble the primary growth, either as regards the character of the cells or the presence of pigment. In rare cases the second, or glaucomatous, stage is followed or superseded by a low grade of plastic iridocyclitis terminating in atrophy of the globe and apparent retrocession of the sarcoma. The existence of such cases has led to the belief that sarcoma is prone to develop in phthisical eyes. It is, however, difficult to determine whether the sarcoma preceded or followed atrophy of the bulb. Parsons, who has investigated this subject, describes 6 cases which he considers as belonging to this class. The growths were of relatively low malignancy. In all of them the characteristic feature was extensive necrosis and hemorrhage. The intraocular blood-clot tended to obscure the presence of a neoplasm, which should always be sought for in intraocular hemorrhage. Parsons considers that all these eyes were in a condition that would have passed into *phthisis bulbi,* and if they had not been enucleated would have formed examples of sarcomata developing in atrophied eyes. Schultz has reported a case of sarcoma terminating in *phthisis bulbi.* The pathologic findings were as described above. In the great majority of cases sarcoma of the choroid assumes the form of a rounded protuberance. In its early stages it is compressed between the sclera and *lamina vitrea,* so that, following the line of least resistance, it spreads laterally. The *lamina vitrea* soon ruptures, and then the sarcoma grows rapidly out into the soft vitreous, assuming the characteristic mushroom shape. A few cases have been reported in which sarcoma of the choroid appeared in a disseminated form (multiple sarcoma). Such cases have been reported by Knapp and Mitvalsky. It is, however, very unusual for local metastases or secondary growths to occur in an eye affected with uveal sarcoma, differing in this respect from glioma of the retina and metastatic carcinoma of the choroid. If a melanosarcoma exists in the uvea, pigmented cells are usually found in the anterior chamber entangled in the meshes of the *ligamentum pectinatum.* Such cells are not tumor elements, but leucocytes which have taken up free pigment and been carried forward by the aqueous current. These cells never establish secondary sarcomatous deposits. Flat or infiltrating sarcomata of the choroid are very rare. Histologicly, they should be classed as endotheliomata. The predominating type of cell

may be spindle shaped or round. Mixed forms of sarcoma, however, are very common. The cells vary greatly in size.

True giant-celled sarcoma in the choroid has not been satisfactorily established. About one-half of all cases are classed as spindle-celled sarcomata. The spindle cells have a large, oval nucleus, and their extremities frequently bifurcate. The round cells are often irregular in shape and possess protoplasmic prolongations. The blood-vessels are usually numerous. They consist mostly of thin endothelial tubes and channels imbedded in cells. As a rule, the round-celled sarcomata are more vascular than the spindle-celled type. The neoplasm may consist almost entirely of cells arranged in the form of thick-walled tubes lined by a thin endothelial membrane and filled with blood. Such growths are called **angiosarcomata.** (See Fig. 75.) Round-celled sarcomata are considered to be more malignant than the spindle-celled.

Alveolar sarcoma (*sarcoma carcinomatodes*) occurs in the uvea as flat or diffuse sarcoma of the choroid and as ring-shaped sarcoma of the ciliary body. They are composed of cells many of which are large and polygonal (endothelial cells). They tend to assume an alveolar or plexiform arrangement. These growths probably arise from the endothelium of the choroidal lymph-spaces and clefts and possibly from the perivascular lymph-channels. They are better classed as endotheliomata.

A common classification of sarcoma of the choroid is according to its color into **melanosarcoma** and **leucosarcoma.** According to Fuchs, about 88 per cent. should be classed as pigmented. Those classed as leucosarcoma always contain some trace of pigment, which is found both in the protoplasm of the cells and as isolated intercellular masses. It is derived from two sources, namely, from proliferation of the chromatophores and from the blood. Cases of choroidal sarcoma have been observed in which the pigmentation was not limited to the tumor. In a case reported by Treacher Collins, a sarcoma was confined to the ciliary body, but the entire uvea and portions of the sclerotic were deeply pigmented.

The majority of sarcomata of the choroid undoubtedly arise from the external or middle layers of the choroid. Knapp has suggested that leucosarcoma arises from the choriocapillaris, which normally contains no pigment. Fuchs states that all choroidal sarcomata, pigmented and unpigmented, arise from the outer layers. Ribbert has recently advanced the opinion that both the pigmented and unpigmented cells are derived from the chromatophores, and if the cells are white it is because they are young and incompletely formed. Sheik, more correctly, says that the choroid is no exception to the rule that sarcoma may develop wherever connective tissue normally exists and, therefore, may arise in the choriocapillaris as well as from the middle and outer layers.

A peculiar type of choroidal sarcoma, known as **perithelioma,** in contradistinction to the common angiosarcoma, has been found in the eye. The cells composing the tumor are of columnar or oval epithelioid type, possessing abundant protoplasm and rounded, often spindle-shaped nuclei. They grow in a radiate manner around the blood-channels in

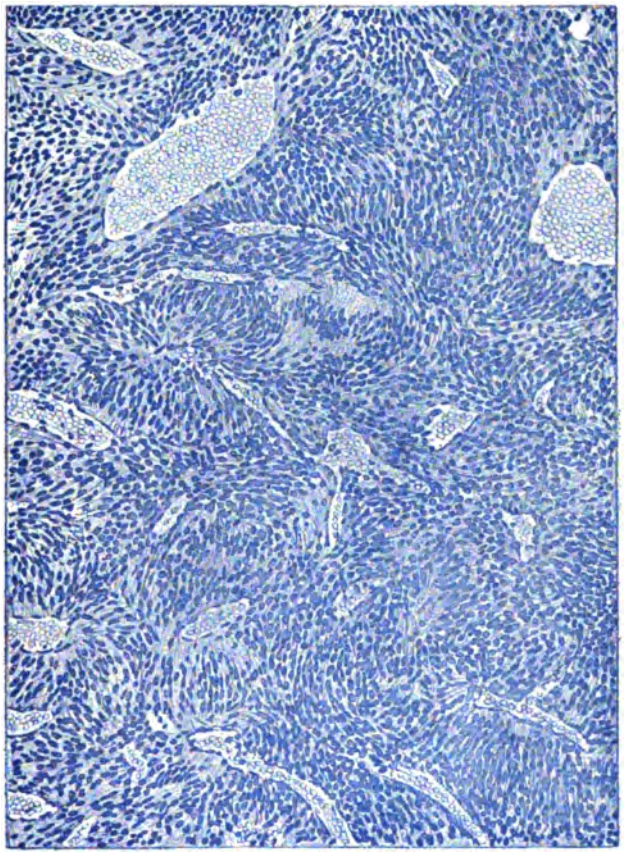

Fig. 518.—Perithelioma of choroid and ciliary body. Walls of blood-vessels formed of columnar cells radiately surrounding the lumen.

immediate contact with the endothelial membrane. Thus, vessels cut in their long axis present a foliate appearance; those cut transversely appear as cellular rosettes bearing a superficial resemblance to those found in glioma of the retina. (See Fig. 518.) The name p e r i t h e l i o m a is applied to these tumors on the supposition that they develop from the perithelium of the blood-vessels. In 1870, C. J. Eberth demonstrated in

the blood-vessels of the brain and cord a single layer of flat endothelioid cells situated between the adventitia and perivascular lymph-sheath. The term perithelioma is applied to growths which from their situation and type of cells presumably spring from this layer. Whether or not this is their true origin, the name perithelioma is of topographic value.

Hemorrhages associated with necrosis are common in sarcoma of the choroid. The occurrence of hemorrhage may determine an attack of glaucoma, or, on the other hand, may lead to phthisis bulbi. Of the degenerative changes observed in these growths, the most frequent is a hyaloid degeneration of the blood-vessels. Myxomatous changes are most frequent in the angiosarcoma and endotheliomata. Glycogen, fat, and calcareous salts have been demonstrated.

Fig. 519.—Metastatic carcinoma of the choroid. Lower half of left eye. Horizontal meridional section, somewhat below the axis. Actual size. (From an original drawing by *E. L. Oatman, M.D.*)

Carcinoma of the choroid. This neoplasm is always secondary (metastatic). Oatman[1] has tabulated 30 cases of probably genuine carcinomata of the choroid, 26 of which were confirmed by microscopic examination. The ages of the patients ranged from 30 to 58 years, the average being 44.37 years. Twenty of the primary growths were situated in the breast, 3 in the lungs, 2 in the liver, 1 in the stomach and liver, 1 in the thyroid, and 1 in a dermoid cyst of the suprarenal body. Twenty-three of the cases were females and 7 males, which probably is due not so much to influence of sex as to the greater frequency of carcinoma of the breast in women. In one male the primary growth was in the breast. Twenty right eyes and 19 left eyes were attacked. Ten of the 30 cases were bilateral, a fact for which no satisfactory explanation can be offered. In every case the deposit commenced in the posterior

[1] American Journal of the Medical Sciences, March, 1903.

Fig. 520.—The carcinomatous growth has reached the ora serrata. Its wedge-like periphery is advancing along the suprachoroidal space. Choroid is lifted and its lymph channels invaded. Retina totally detached; its pigment layer remains on surface of growth. Spherical colloid body beneath pigment. × 100. (From original drawing by *E. L. Oatman, M.D.*)

portion of the choroid over the point of entrance and distribution of some one of the short ciliary arteries. In no case did invasion occur by way of the central artery of the retina. The exact location was described as on the temporal side of the nerve in 18 cases, above the nerve in 1 case, below the nerve in 1, and around the nerve in 2. In all stages of car-

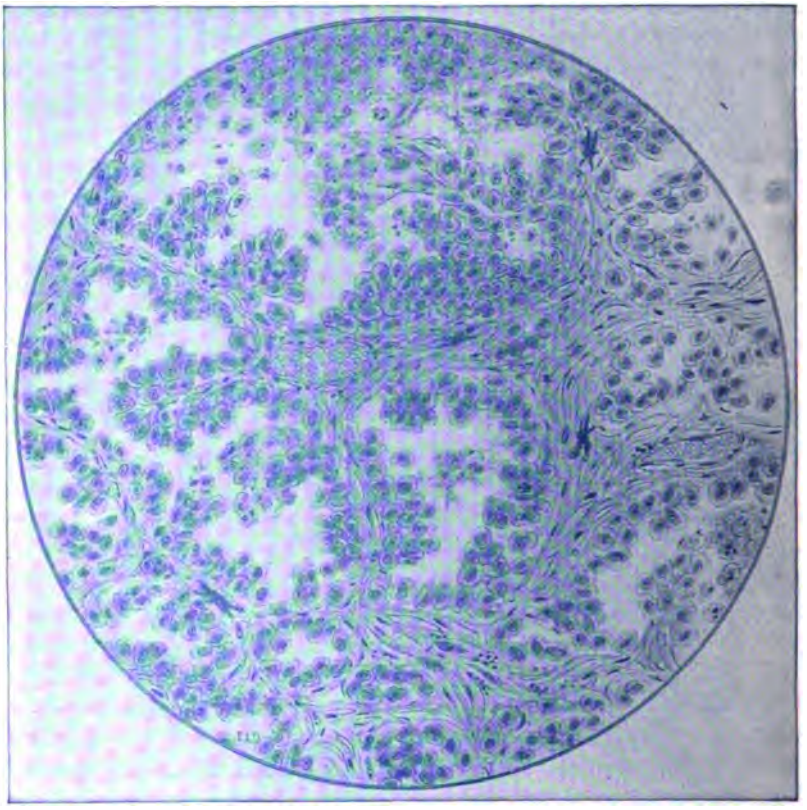

Fig. 521.—Papillary cystadenocarcinoma of the choroid. The stroma contains the blood-vessels and scattered pigment cells of the choroid. The large alveolus above is filled with disintegrating remains of tumor elements. × 500. (From an original drawing by *E. L. Oatman, M.D.*)

cinoma the cells exhibit a marked preference for the lymph channels as a route of emigration; when the disease is far advanced, however, the blood-vessels also undoubtedly serve as channels. (See Fig. 519.) As there are no lymph currents that could convey the cells from an abdominal or thoracic carcinoma to the eye, it may be assumed that they are conveyed by the vascular system. The shape and method of growth of these

tumors are very characteristic. The almost universal type is flat, disk-shaped thickening of the choroid, highest in its center, which usually is in the macular region and sloping to a thin-edged periphery. (See Fig. 520.) The tendency is to spread laterally, thus differing from sarcoma, which grows forward into the vitreous, forming a protuberant mass. Although the development of a choroidal carcinoma is much more rapid than sarcoma, yet, to judge from the reports, a small carcinomatous deposit produces far more extensive retinal detachment than does a central sarcoma of equal size. The explanation for this may be found in the different histologic structure of the two growths, a sarcoma being a connective-tissue neoplasm, while the cells of a carcinoma of the choroid are always of the glandular epithelial type, possessing an abortive function, whose perverted secretion may assist in detaching the retina.

Osteomata (*choroiditis ossificans*) are rare. They are always smooth bone in the surface of the choroid, and follow long-continued inflammation. Isolated plates may form, or the entire choroid may be converted into a bony shell. The bone is deposited external to the *lamina vitrea,* unless the latter has been destroyed. The principal steps in the process appear to be as follows: As the result of chronic inflammation the inner layers of the choroid atrophy and are replaced by a layer of fibrous connective tissue; in this membrane, ossification takes place by the intramembranous method of bone formation. Knapp states that bone formation commences in the choriocapillaris, basing his opinion on the fact that the change occurs first in the inner layers, and the deposit is usually limited to the area covered by the capillary layer.

Tubercles of the choroid are frequent. These are very seldom absent in acute general miliary tuberculosis, and they are often of great differential diagnostic value from a clinic standpoint. Tubercles appear under three forms, namely, as disseminated, or miliary, tuberculosis (which is most frequent), as chronic diffuse choroiditis, and as solitary, or conglomerate, tubercle. According to Bock, the choroid is affected in 82.7 per cent. of all cases of acute general miliary tuberculosis. It seldom occurs in chronic systemic tuberculosis.

No portion of the choroid is exempt, but the tubercles are most frequently found around the disk. Their size varies from 0.4 mm. to 2 mm. Larger formations probably result from confluence of two or more tubercles. They are usually situated in the outer layers of the choroid. Inasmuch as the sclera offers less resistance to the progress of tubercle than the lamina vitrea, the nodules tend to grow outward into the suprachoroid and sclera. It may not be possible to demonstrate the presence of tubercle bacilli, or, on the other hand, they may be present in great numbers.

Diffuse tuberculous choroiditis and solitary tubercle develop as a chronic process. The diffuse form attacks large areas of the choroid, which is replaced by a thick layer of granulation tissue containing tubercles. The deposits may be confined beneath the *lamina vitrea* and finally undergo cicatrization, or the lamina may be perforated and the entire globe be filled with a tuberculous mass. The sclera offers but slight resistance to tuberculous invasion. It is usually perforated at the sclerocorneal margin or along the course of the blood-vessels. Exceptionally, perforation takes place posteriorly.

Solitary, or conglomerate, tubercle of the choroid is rare. It forms a neoplasm which is difficult to differentiate from glioma of the retina, pseudoglioma and sarcoma of the choroid. Its characteristic features are small deposits surrounding the principal growth, early perforation of the sclera, and associated tuberculosis of other parts, frequently the brain. In rare cases the progress of the tubercle is arrested and cicatrization takes place, or, if the process is far advanced, the globe may atrophy.

Telangiectasia (angioma) **of the choroid.** Unmixed angioma of the choroid is rare. Individuals with extensive congenital telangiectases of the lids and conjunctiva frequently have also some malformation of the retina or choroid. This may consist of only a slight vascular enlargement, or, as in a case reported by J. Milles, constitute a nevus of the choroid. The unmixed angiomata of the choroid do not possess a capsule. They may be made up of capillaries or of large, irregular, endothelial-lined spaces. When these formations contain a large admixture of connective-tissue elements, they may be confounded with angiosarcomata.

Dermoids. One case of dermoid tumor of the choroid has been observed (Follin). The growth was situated between the retina and choroid.

Leprosy of the choroid is always an extension of the disease from the ciliary body.

Plexiform neuroma. Treacher Collins has called attention to a condition of the choroid which presents the microscopic appearances of a plexiform neuroma. The eyes in which they were found were buphthalmic.

Alterations in the lamina vitrea and Drusen. Hemispheric excrescences situated upon Descemet's membrane have already been described. Similar formations upon the *lamina vitrea* of the choroid are very common. They are known as "Drusen" of the choroid. They follow chronic intraocular inflammation and are usually present in atrophied bulbs. They occur most frequently as a senile change, being fairly constant after the age of 60. They are, however, not uncommon

after 30. The terms "colloid degeneration of the choroid, *choroiditis gutta,* verrucosities of the choroid," etc., have been applied to these growths. Under the microscope they appear as round, hyaloid drops, 0.5 mm. to 1 mm. in diameter, situated on the inner surface of the *lamina vitrea,* to which they are attached. The fusion of several Drusen may form a deposit of considerable size. It is probable that these formations are a cuticular product of the pigmented epithelium deposited in the same manner as the *lamina vitrea,* although it is possible that Drusen-like masses may result also from degeneration and death of the epithelial cells. They may undergo calcareous or bony degeneration. Coincident with the formation of Drusen the entire *lamina vitrea* thickens and becomes rigid. By their growth, Drusen push aside some of the overlying pigmented epithelial cells, which are frequently seen crowded to one side. Sometimes pigment molecules are enveloped by the Drusen.

Glaucoma. The form of the eyeball is kept constant by the intraocular fluids—the aqueous and vitreous—which fill the globe under a pressure of from 20 to 30 mm. Hg above that of the atmosphere. The maintenance of this condition, known as the intraocular tension (*tonus bulbi*), is largely dependent upon the aqueous humor.[1] Inasmuch as the normal tension of the globe immediately depends upon the relation between the production of aqueous by the ciliary processes and its escape from the eye, it is evident that any obstruction to its outflow, either through Schlemm's canal, Fontana's spaces, or the pupillary area, will cause accumulation of fluid within the eye and increase in the intraocular pressure (*hypertonia*). When this takes place it constitutes the condition known as glaucoma.[2] Long-continued increase in intraocular pressure results in destruction of vision. Why an increase of pressure occurs and equilibrium is not restored is, in many cases, unknown. If increase of pressure occurs without antecedent eye disease, the condition is called primary glaucoma; if, on the other hand, the increase of pressure is the result of certain eye diseases (trauma or exudative inflammation), the glaucoma is called secondary. The former attacks both eyes; the latter, only the previously affected eye.

Primary glaucoma (without antecedent eye disease) occurs either with inflammatory phenomena, as *glaucoma inflammatorium,* or without

[1] The aqueous is produced by the ciliary processes, little or nothing being contributed by the iris. The fluid enters first the posterior chamber, then passes through the pupil into the anterior chamber. From the anterior chamber the aqueous passes into the general circulation by filtering through Fontana's spaces in the pectinate ligament into Schlemm's canal, which really is a plexus of veins encircling the cornea, situated in the anterior margin of the sclera. As the pectinate ligament through which the aqueous escapes is situated in the sinus of the anterior chamber, this region is frequently called the angle of filtration.

[2] γλαυκος = (sparkling, colored light) green; in glaucoma the pupil appears greenish (hence called also green cataract).

inflammatory manifestations, as *glaucoma simplex*. Simple (noninflammatory) glaucoma is by many observers regarded as a disease of the optic nerve. This view, however, is inconsistent with the occurrence of periodic increased tension. Inflammatory glaucoma is more frequent in advanced age, occurring in single, interrupted attacks.

The cause of primary glaucoma has not been definitely determined, no single theory being applicable to all cases.[1] Certain eyes are said to possess a predisposition to glaucoma. In such cases an attack is favored by any irritation of the surface of the cornea or by remote causes, such as violent emotions, pain, operation on the fellow-eye, etc. A common determining cause is the use of a mydriatic, which, by crowding the iris into the angle of filtration, mechanicly blocks the drainage from the eye. A fruitful subject for investigation is the influence of blood-pressure (vascular tension) in the production of glaucoma. If the aqueous be regarded as a filtrate from the vessels, the normal intraocular pressure can never exceed the blood-pressure in the capillaries. Furthermore, should the intraocular pressure greatly exceed the pressure in the ophthalmic artery, the intraocular circulation would be arrested. It is, therefore, evident that local capillary pressure must be increased in cases of high tension. Parsons says of the normal eye: "It is most likely that this is the highest capillary pressure of any organ of the human body when at rest." It has been experimentally demonstrated that intraocular pressure is raised by anything which increases the local or general blood-pressure in either the arteries or veins. Vascular constrictions in distant parts also increase intraocular tension: Thus, stimulation of the abdominal vasoconstrictors drives the abdominal blood into the peripheral vessels and a rapid rise of eye tension follows. On the other hand, section of the cord in the cervic region cuts off the abdominal vasoconstrictors and dilation of the great abdominal vessels causes a decided fall in tension of the eye. Under normal conditions, these variations of pressure are compensated by increased filtration from the eye, but in those suffering from vascular degenerations it is possible that the normal equilibrium between the arterial and venous systems of the eye is sufficiently disturbed to interfere with the proper circulation in the venous system of Schlemm, which drains the eye. Whatever influence these factors have in creating a predisposition to glaucoma is still undecided. A reasonable and generally applicable theory to explain the development of primary glaucoma has been presented by Priestley Smith. It is a matter of common observation that in typic cases of glaucoma the periphery of the iris is applied to the posterior surface of the cornea, thereby obstructing the angle of filtration, and in cases of long duration firm adhesions form between the iris and cornea. Priestley Smith accounts for the advancement of the iris as follows: Although the eye as a whole ceases to enlarge after adult life, the growth of the lens continues, so that at the age of 65 the lens is one-third larger that at 25. Consequently, in course of time the lens becomes too large for the eyeball. The space required to accommodate the enlarged lens is taken from the anterior chamber. The ciliary processes and the root of the iris are pushed forward, thus producing the shallow anterior chamber of old age. If, as in hypermetropia, the globe is below the normal size, the continued growth of the lens advances the periphery of the iris beyond the limit of safety. In such eyes slight swelling of the ciliary processes or dila-

[1] Four conflicting theories (von Graefe, Donders, Stellwag, Knies and Weber) are advanced, all of which are inadequate.

tion of the pupil may bring the iris in contact with the posterior surface of the cornea and block the angle of filtration. Measurements have demonstrated that the glaucomatous eye is usually below the average size. Other theories held to explain primary glaucoma are anterior iridocyclitis, causing peripheral adhesions between the iris and cornea; varying osmotic pressure; hardening of the sclerotic around the nerve, thereby diminishing the outflow of lymph; compression and congestion of the *venæ vorticosæ;* choroiditis; obstruction of the intraocular lymphatic system, etc., all of which lack confirmation. Theoreticly, effusions into the vitreous, which increase its volume, should produce glaucoma by pushing forward the lens and iris. The vitreous, however, appears to accommodate its volume to the space at its disposal, and the mere presence of extraneous matter in its substance does not produce glaucoma unless an effusion has occurred very rapidly, as in severe intraocular hemorrhage, or the composition of the aqueous is at the same time so changed as to render its filtration slow and difficult. It is worthy of mention that, if the pressure in the vitreous exceeds that in the anterior chamber by as much as 1 mm. Hg, the iris is forced against the cornea and the anterior chamber obliterated. Henderson says the causal factor of glaucoma is fibrosis of the trabeculæ and closure of the spaces in the pectinate ligament. At the same time the endothelial cells which line the spaces deposit a homogeneous membrane similar to Descemet's membrane. The fibrosis is further increased by the drag of the ciliary muscle, which is greatest in hypermetropic eyes. He regards the iris as an absorbing surface and an important adjunct to Schlemm's canal in draining the anterior chamber, the benefit derived from iridectomy being due to opening fresh areas of drainage.

Pathologists who examine many cases of glaucoma occasionally encounter those in which the angle of filtration is not blocked by approximation of the iris to the cornea. Von Hipple published such a case in which the trabeculæ of the pectinate were thickened and the spaces filled with pigment. Baques, in a somewhat similar case following hemorrhagic retinitis, found the spaces of filtration as far as Schlemm's canal blocked by mono- and polymorpho- nuclear leucocytes and pigment. He concluded that the hemorrhages into the retina and consequent destruction of retinal tissue produced irritating chemic substances which acted upon the trabeculæ of the pectinate ligament, causing tissue proliferation which closed the spaces. Oatman described 2 cases similar to those of von Hipple and Baques.

High blood-pressure is unfavorable in glaucoma. Cases of this class include those in which glaucoma develops after obstruction of the central artery or central vein of the retina. Probably the process of vascular degeneration which produced these conditions also involves the efferent channels of the anterior chamber. Among the constitutional conditions which favor glaucoma, gout is most prominent. Von Graefe first called attention to the influence of heredity in glaucoma and pointed out the curious fact that in h e r e d i t a r y g l a u c o m a there is a marked tendency for the disease to a n t i c i p a t e, *i.e.,* to appear in a descendant at an earlier age than in the ancestor. Thus, the prodromata which appeared in a grandparent at 60 appear in a grandchild at 30 or 40. Hereditary glaucoma usually, but not invariably, is exceedingly chronic in its course.

Secondary glaucoma is produced by a great variety of conditions, such as dislocation of the lens into the pupillary area or the anterior chamber; swelling of the lens in traumatic cataract or after needling;

the presence of large quantity of lens matter or vitreous in the anterior chamber; extensive anterior or posterior synechiæ; prolapse of the iris; intraocular hemorrhages, either into the vitreous or the anterior chamber; intraocular growths; changes in the composition of the aqueous or the presence of inflammatory products, as in cyclitis; in fact, any mechanic obstruction to the aqueous current.

In glaucoma the cornea is hazy from disarrangement of its parts. The pressure upon the corneal nerves and laceration due to elevation of the epithelium produce loss of sensation and anesthesia of the cornea. There is more or less edema of the corneal epithelium, usually ascribed to percolation of fluid through the cornea. According to Oatman, it is probably due to interference with the circumcorneal circulation. The angle of filtration is usually obliterated by adhesion of the iris to the cornea. In the early stage the iris is pushed against the cornea by swelling of the ciliary processes. In old cases it becomes attached to the cornea. In the early stage there is inflammatory edema of the iris, and later it becomes highly atrophic. The lens advances in acute attacks, but recedes after a fall of tension. It finally becomes cataractous (glaucomatous cataract).

In advanced cases of glaucoma the sclera yields at its weakest part, namely, the sclerocorneal junction and around the anterior ciliary vessels, where it has been weakened by chronic congestion and inflammation. If the bulging occurs over the ciliary body, it is called ciliary staphyloma. If it takes place immediately in front of the ciliary body, it is termed intercallary staphyloma. Equatorial staphyloma, which takes place around the vortex veins, is less common. Flattening of the cornea results from stretching of cornea and sclera at their junction.

The changes in the uveal tract vary according to the stage of the disease. At first there is exudative inflammation, and in advanced cases degeneration and atrophy, in which the choroid becomes very thin. Glaucoma causes excavation of the nerve-head and diminution or destruction of vision. It is generally held that the excavation results from pushing outward of the lamina cribrosa, which is the thinnest portion of the sclera, by the high intraocular tension, the loss of vision being due to stretching and pressure atrophy of the nerve axons as they pass through the spaces in the lamina. This apparently simple explanation does not altogether conform either to the course of the disease or to pathologic findings. Although the scleral fibers are least numerous at the lamina, this region is heavily reinforced by the nerve structure and is by no means the least resistant portion of the eye tunics, as demonstrated by artificially produced pressure from injections of fluid and by cases of secondary glaucoma, such as result from spontaneous dislocation of the lens into the anterior chamber.[1] Atrophy of the nerve-tissue precedes recession of the lamina. In all cases of early glaucoma microscopicly examined by Oatman, pit-like areas, in which the nerve axons had disappeared, but the neuroglia remained, were found on the temporal margin of the disk. The fairly uniform peripheral contraction and the sector-like defects of the visual fields point

[1] Oatman observed 2 cases of spontaneous dislocation of the lens into the anterior chamber in which the scleræ were enormously distended, but no excavation of the optic nerve existed. Such cases of artificially induced glaucoma, in which there is no trauma or disease, clearly demonstrate the influence of pure intraocular pressure upon excavation of the nerve.

to a vascular origin for the retinal atrophy. Compression of the retinal vessels and degeneration of the choriocapillaris produce gradual atrophy of the retina, which begins peripherally on the temporal side and gradually advances until vision is abolished. Atrophy of the nerve axons exposes the lamina cribrosa, which gradually recedes until, in old cases, the excavation of the nerve-head becomes very deep and its borders undermined. This form of excavation differs from that produced by simple atrophy of the nerve. (See p. 1054.) Probably the excavation in glaucoma is brought about by the combined influence of nerve-axon atrophy, inflammation and subsequent contraction of the tissues in the nerve-stem, and intraocular pressure. The excavation sometimes contains a large amount of connective tissue of inflammatory origin. If this tissue is very vascular, it may present an ophthalmoscopic picture simulating papillitis.

Buphthalmus is the glaucoma of infancy. In children the sclera is far more distensible than in adults and yields more uniformly under the influence of increased intraocular pressure. The entire globe is, therefore, enlarged, including the cornea (keratoglobus, *q.v.*). The anterior chamber is very deep. The inflammatory condition so common in other forms of glaucoma is absent in buphthalmus, although the ciliary body is said to exhibit some evidence of chronic inflammation. The iris is stretched and highly atrophic. The lens remains clear until the advanced stages are reached, when it becomes cataractous from malnutrition. Stretching of the zonular fibers leads to their rupture, and more or less subluxation of the lens takes place. The lens failing to support the iris, the latter trembles when the eye is moved: iridodonesis. The retina and choroid are free from inflammatory changes, but undergo atrophy. The refraction is not always myopic, and the myopia, when present, is not usually of high degree. This is explained by the backward displacement of the lens and flattening of the cornea. Buphthalmus is a family disease. It is probably due to congenital abnormality of the angle of filtration. The condition appears to be an arrest of development, whereby the iris remains, as in fetal life, in contact with the cornea at the angle. There is also undue persistence of the fetal pectinate ligament. This or some other abnormality of this region or of Schlemm's canal has been found in the rare cases which have been examined microscopicly. It has been demonstrated that the rate of filtration from buphthalmic eyes is subnormal.

RETINA AND OPTIC NERVE.

From its structure and function, the optic nerve may be considered as a portion of the brain. Between its point of exit from the foramen opticum and its entrance into the globe, the optic nerve is surrounded by a strong connective-tissue sheath, which is an extension of the dura mater and is continuous with the external lamellæ of the sclera. The arachnoid and pia are continued along the optic nerve to its passage through the lamina cribrosa. The periphery of the nerve is occupied

by a dense neuroglia mantle devoid of nerve-fibers. This was formerly looked upon as a special form of degeneration, but is now regarded as normal. The nerve-fibers are medullated, but possess no neurilemma. The medullary sheath is lost at the entrance into the globe, in the region of the *lamina cribrosa* (the inner lamellæ of the sclera). The nonmedullated portion of the nerve, which from the *lamina cribrosa* onward lies within the eye, forms the flat optic papilla (nerve-head): *papilla nervi optici.* Corpora amylacea are a normal constituent of the nerve. The central vessels enter the lower and outer aspect of the nerve, usually about 10 or 12 mm. behind the globe.

Inflammation of the optic nerve (*neuritis optica*) may involve the portion contained within the eye: intraocular neuritis, or the portion external to the globe: retrobulbar neuritis. The intraocular portion may suffer from edematous exudation or from acute inflammation attended by cellular infiltration. Both conditions are manifested clinicly by swelling of the head of the nerve, which is apt to be greater in the passive forms of congestion (choked disk) than in exudative inflammations (papillitis).

The passive form (**choked disk**) is produced by swelling of the tissues at the *lamina cribrosa.* The central vessels are constricted, causing transudation of serum among the nerve-fibers, tortuosity of the veins, shrinking of the arteries, and hemorrhages. The condition is one of congestive edema. The inflammatory form (papillitis) differs but little ophthalmoscopicly from the passive. It is followed in the atrophic stage by the formation of cicatricial tissue, which obscures the *lamina cribrosa* and constricts the retinal vessels, producing the ophthalmoscopic picture known as postneuritic atrophy, differing from that of simple atrophy (tabetic), in which the *lamina cribrosa* is very distinct, the outlines of the disk sharply defined, and the vessels but slightly diminished in size. The nerve-fibers exhibit considerable resistance to the pressure exerted in choked disk, as indicated by retention of good vision during the early stages. Vision is sometimes retained for a year or two. After a time they degenerate, and vision is lost. Swelling and proliferation of the neuroglia occur. Inflammation of the papilla extends more or less into the surrounding retina and backward along the nerve. Slight cases may be followed by recovery, but many go on to atrophy of the nerve.

Optic neuritis due to systemic or intracranial disease is usually bilateral. In brain tumor, when associated with other confirmatory symptoms, it is of the greatest diagnostic importance. When unilateral it does not always appear on the same side as the tumor.

Of the many causes of optic neuritis the most common is tumor of the brain. Other causes include a great variety of acute and chronic infectious diseases: traumatic, tuberculous, and syphilitic meningitis; febrile

diseases, influenza, albuminuria, emphysema of the lungs, multiple sclerosis, diabetes, malaria, syphilis, leucocythemia, pyemia, acromegaly, lead poisoning, sunstroke, exposure, caisson disease, poisoning; diseases of the ethmoid, sphenoid, and frontal sinuses; periostitis and cellulitis of the orbit, intracranial hemorrhage, thrombosis of the cerebral sinuses, brain abscess, injuries, thrombosis of orbital veins, aneurism, etc.

The mechanism of optic neuritis is a subject of controversy. The following are the most prominent theories: increased intracranial pressure transmitted to the fluid surrounding the nerve in the intravaginal space (the most generally accepted view); extension of interstitial edema from the brain to the optic nerve; inflammation excited in the nerve by the presence of irritating toxins in the intrasheath fluid. The disease occurs as a true bacterial metastasis in a certain number of cases.

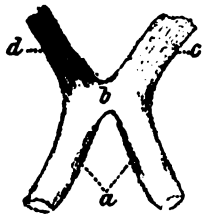

Fig. 522.—Atrophy of the right optic nerve of a man 46 years old who died in April, 1894. The right eye had been enucleated during the war of 1870-71, because of a gunshot wound. *a*, optic tract; *b*, chiasm; *c*, normal left optic nerve; *d*, atrophic, gray, right optic nerve.

In inflammation of the nerve-trunk all its tissues are more or less involved. When the primary or principal change is degeneration of the nerve-fibers, it is classed as parenchymatous neuritis; when proliferation of the sustentacular tissue predominates, the change is designated as interstitial neuritis. In the early stages of the parenchymatous form there is great swelling of the nerve-fibers, proliferation of the neuroglia, and enormous increase in the number of fat-cells. The interstitial form starts from the periphery (perineuritis) or from around the blood-vessels. The early stages are characterized by dense, round-celled infiltration of the nerve-septa. This is followed by newly formed blood-vessels and granulation tissue, which penetrate into the nerve. This granulation tissue is transformed into fibrous connective tissue, the subsequent contraction of which destroys the nerve-fibers. These processes terminate in atrophy and shrinkage of the nerve. Postneuritic atrophy is called also secondary, while the noninflammatory form is designated as primary.

Axial (retrobulbar) neuritis is a term that is employed to designate a disease the clinic manifestation of which is loss of central vision.

It begins either suddenly (acute) or insidiously (chronic) and is believed to be an interstitial inflammation of the papillomacular bundle of nerve-fibers, which, after a time, disappears. Occasionally the disease progresses to the formation of cicatricial tissue and optic atrophy. It develops in nicotine poisoning, in the course of acute infectious diseases, in multiple sclerosis, and in lead poisoning. A common cause is inflammation in the accessory nasal sinuses. The prognosis is better in this than in other forms of optic neuritis.

Retrobulbar neuritis due to suppuration in a nasal sinus may be attended by some edema of the disk, which, in neglected cases, may be pronounced. As a rule, the disease is unilateral. In these cases the axial bundle of fibers in the nerve is affected, indicating that the disease results from the presence of a toxin and not from pressure upon the nerve by inflammatory products.

The optic nerve is involved in a variety of diseases affecting the nervous system. In multiple sclerosis the optic nerve is affected in about 50 per cent. of the cases. Usually, but one side is attacked (unilateral in 75 per cent.—Fleischer). The lesions are irregularly distributed. The axial bundle of fibers is frequently involved. The majority of cases exhibit a slight blurring of the disk, followed by atrophy. Partial recovery of vision is common. The atrophy frequently precedes other manifestations of the disease. The histologic change is disappearance of the myelin sheaths from around the nerve-fibers. The nerve-fibers may split up, but their continuity is not destroyed, and recovery of function is the rule.

Locomotor ataxia is attended by atrophy of the optic nerve in from 10 to 20 per cent. of the cases (Parsons). Frequently it antedates all other tabetic symptoms. Atrophy of the nerve-fibers is secondary to degeneration of the ganglion cells of the retina. It is a pure degeneration; inflammatory processes, when present, are due to complications. The nerve-fibers lose their myelin sheaths, become varicose, and break up. Late in the disease the optic nerve consists principally of proliferated neuroglia and fibrous connective tissue. Both eyes are affected, although one may be attacked before the other. Usually, if not invariably, the disease terminates in blindness if life is prolonged.

In combined atrophy of the lateral and posterior columns of the spinal cord, all the symptoms of tabetic atrophy may be present.

In syringomyelia both papillary edema and optic atrophy occur. These conditions, however, are considered as secondary to distention of the ventricles in the brain or to coincident disease, such as tabes, etc.

In acromegalia and in general paresis, optic neuritis and optic atrophy may ensue.

Optic atrophy occurs as a congenital condition, in which case it may be a collateral inheritance.

In rare instances myelitis is accompanied by optic neuritis. As a rule, both eyes are affected, usually one before the other. In nearly all cases the optic neuritis precedes the myelitis. The majority of cases exhibit some swelling of the disk and tortuosity of the retinal veins. In other cases the ophthalmoscopic findings are negative. If retinal changes exist, they do not relate to the neuritis. Some improvement in vision frequently follows the acute stage. Rarely vision may be completely restored; usually, however, the cases go on to optic atrophy and blindness. Myelitis is an infectious process. In about one-third of the cases syphilitic history can be traced. Myelitis may occur in the course of most infectious diseases. The histologic changes in the optic nerve are the same as found in the spinal cord, and consist of an acute parenchymatous inflammation, sometimes hemorrhagic in type. The optic nerve usually is involved throughout its entire length and breadth. The late changes are those of atrophy.

In *dementia præcox* there is usually a mild optic neuritis manifested by blurring of the disk and distention of the retinal veins (Tyson and Clark). The disproportion between veins and arteries is marked, the veins being three or four times the size of the arteries. Later in the disease optic atrophy ensues.

As the sheaths of the nerve are prolongations of the brain membranes, the intervaginal spaces are in direct communication with the subdural and subarachnoidal spaces of the brain. As a result of this arrangement, heightened intracranial pressure is distributed to the vaginal fluid and frequently leads to an ampulliform distention of the optic ends of the sheaths. This distention may be purely mechanic (hydrops) or be attended by inflammatory phenomena (perineuritis).

Perineuritis is divided into pachymeningitis and leptomeningitis, in conformity with the nomenclature employed in inflammation of the brain membranes. The two forms are usually combined. Perineuritis seldom originates in the sheaths themselves, but develops as an extension from the orbital tissues or from the brain membranes. Perineuritis may be purulent or nonpurulent, acute or chronic, according to the character of the original inflammation. The disease may depend upon tubercle, syphilis, meningitis, cerebral tumors, injuries, orbital disease, etc. Cases of long duration or of severe type may terminate in optic atrophy from contraction of inflammatory exudates around the nerve.

Syphilis. All parts of the nerve are subject to gummatous infiltration, although the intracranial portion, particularly the chiasm, is most

frequently affected. Papillitis may or may not result. Microscopic examination shows interstitial cellular infiltration, development of granulation tissue, destruction of nerve-fibers, and formation of cicatricial tissue. Instead of organizing, the tissues may undergo necrosis. Tabetic atrophy frequently has its origin in an old syphilis. Here the phenomena of inflammation are lacking.

In acute miliary tuberculosis the deposits are common upon the sheaths. The nerve also may be invaded by extension of tuberculous processes from the brain or choroid.

Drusen may form upon the optic papilla. They are frequently associated with some inflammatory or degenerative process. The frequent coexistence of retinitis pigmentosa has been noted. In many cases they are the only abnormalities present in the eye. It is supposed that such formations may be either cellular products or inflammatory deposits. Drusen of inflammatory origin may exhibit a stratified structure. The exact nature of the formations, however, has not been determined. They may undergo calcification.

Tumors.—Strictly speaking, only such growths as develop within the dura should be considered primary tumors of the optic nerve. There is, however, a rare class of extradural growths which develop around the nerve and evidently belong in the same category as those which develop within the dura. The **intradural tumors** mostly begin in early life or are congenital. Out of 85 cases collected by Byers, 52 appeared before the 25th year. They develop very slowly and are of low malignancy. They produce exophthalmos, which usually pushes the eyeball directly forward. Papillitis and atrophy of the nerve generally occur. The atrophy may be postneuritic or simple. As a rule, they extend from the entrance of the central vessels backward, thus leaving 10 mm. to 12 mm. of the optic end of the nerve free. Greeff applies Cohnheim's theory to the development of these tumors. He thinks that when the central vessels and their connective-tissue mantle enter the fetal cleft in the nerve a certain number of cells are carried along, which persist and ultimately proliferate and form tumors.

The growths vary in size from a slight enlargement to the size of an egg. In a large proportion of cases they are connected with an intracranial extension. They are usually elastic or of soft consistency, and frequently contain large, cystic spaces. Histologicly, they belong to the connective-tissue group. The most characteristic nerve tumor is myxoma or myxosarcoma. The endothelial type of tumor also constitutes a large proportion. When these growths contain a large number of chalky concretions, they are called psammomata. Fibroma and fibrosarcoma are very rare. According to Greeff, the so-called gliomata

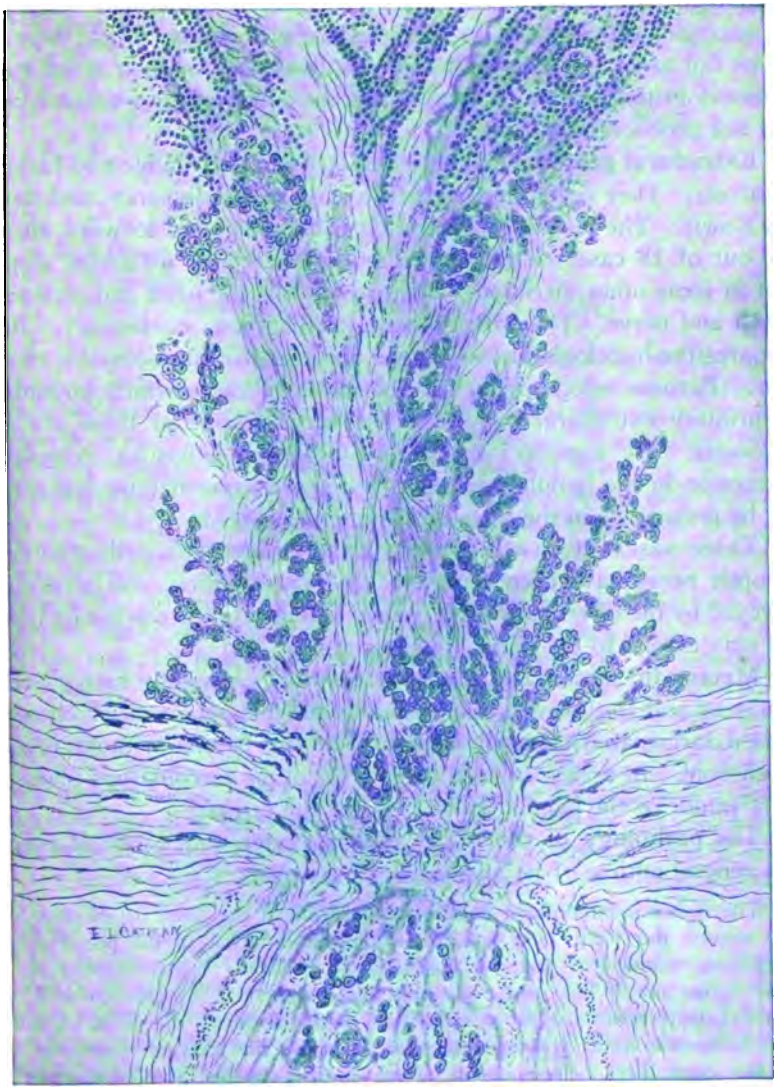

Fig. 523.—Carcinomatous invasion of optic nerve and retina. Degenerated fibers of detached retina form a stroma for the carcinomatous deposit. × 100. (From an original drawing by *E. L. Oatman, M.D.*)

of the optic nerve are connective-tissue growths developing from the septa of the nerve, the neuroglia taking no part in their formation. Proliferating neuroglia should react to the selective glia stains, which these neoplasms fail to do. The term "neuroma" also is a misnomer when applied to tumors in this situation, because the optic nerve is brain-tissue, which does not proliferate.

Extradural growths exhibit a similarity in their clinic and histologic characters. They occur in early life, are of low malignancy, and develop very slowly. The resulting proptosis is usually directed forward, although in 7 out of 18 cases collected by Parsons there was an added displacement in some other direction. The growth fills the orbit and incloses the eyeball and nerve. They are of hard, cartilaginous consistency. Beyers compares the histologic process to the fibromatosis that occurs in elephantiasis. Parsons selects from his collection 12 cases which undoubtedly are primary extradural tumors of the nerve. Nine of these are endotheliomata. He considers the fibromatosis that exists as secondary to obstruction in the lymph-channels. Extensive myxomatous degeneration may be present, as in the intradural tumors.

Three cases of metastatic carcinomatous deposits in the optic nerve have been reported. In none of these was a metastasis conveyed by the *arteria centralis retinæ*. Metastatic carcinoma of the choroid may extend to the nerve.

Metastatic sarcoma of the optic nerve is extremely rare. Schiess-Gemuseus and Roth saw a case of numerous metastases in which a supposed sarcomatous deposit appeared on the papilla without involving the choroid. In a case of Heine's, among other sarcomatous metastases, was a tumor of the papilla which invaded the retina.

The **pathology of the retina** will be better understood if preceded by a general outline of its anatomy.

The retina is interrupted in the *fundus oculi*, at the point of entrance of the optic nerve: the papilla (situated somewhat internal to the posterior pole), and greatly thinned at the yellow spot: *macula lutea*, situated at about the posterior pole. The center of this yellow spot is slightly excavated, forming a flat depression: the *fovea centralis*. In this locality—the point of most distinct vision—the retina is exceedingly thin, because the internal layers are absent, only the cone layer being present. Between the choroid and retina there is a single layer of pigmented epithelium.

The retina extends from the optic nerve, of which it is in part an extension, to the pupillary margin of the iris. The *pars ciliaris retinæ* and the *pars iridica retinæ* participate in the pathologic changes of the iris and ciliary body, to which they are attached. Their morphology has been described when treating of those parts. The *pars opticæ retinæ* extends from the optic disk to the posterior extremity of the ciliary body, where it terminates in a serrated border, known as the *ora serrata*. Aside from the pigment layer, the retina is divided into two general parts:

the internal, or cerebral, layer, and the external, or neuro-epithelial, layer. These layers are subdivided as follows:—

1. Pigment layer.
2. Rod and cone layer,
3. External limiting membrane,
4. Outer nuclear layer,
5. Fiber layer of Henle,

} Neuroepithelial layer.

6. Outer reticular layer,
7. Inner nuclear layer,
8. Inner reticular layer,
9. Ganglion-cell layer,
10. Nerve-fiber layer,

} Cerebral layer.

In addition to the above, an internal limiting membrane is commonly described. These layers are composed of nerve elements supported by a connective-tissue framework of epiblastic origin. The principal portion of this framework is known as the radiating fibers of Müller. They extend from the inner layers of the retina through the layer of rods and cones.

The pigment layer consists of a single layer of low cubic cells, mostly polygonal in form. In the posterior portion of the fundus these cells are of smaller size than those anterior to the equator. The pigment granules are small, rod-shaped crystals. In the dark these crystals lie in the posterior part of the cell around the nucleus, but when subjected to the action of light they push forward and appear among the outer segments of the rods and cones.

The rods and cones are the external portion of the neuroepithelial cells. At the *macula lutea* only the cones are present. In other portions of the retina the rods predominate. The rods and cones are separated from the inner parts of the retina by the *membrana limitans externa*. The rods are divided into: 1, outer segment; 2, inner segment; 3, rod fiber, which extends through the external limiting membrane; 4, the rod nuclei (external nuclear layer), which lie immediately internal to the external limiting membrane; 5, the end granules, which lie free, with no connections, in the outer part of the external reticular layer.

The cones, also, consist of: 1, outer segment; 2, inner segment; 3, cone fiber; 4, cone nuclei; 5, cone foot, which proceeds from a small end fiber and lies free in the external reticular layer.

The rods and cones shorten and contract when exposed to light. They contain a peculiar substance, known, from its color, as visual purple. In the visual act this substance is concerned in converting vibrations of the luminous ether into nerve-stimuli. It is abundant when the eye is in the dark, but is bleached on exposure to light.

The outer nuclear layer consists principally of the nuclear portion of the rod and cone visual cells. The rod nuclei are transversely striated and smaller than those of the cones. Fibers from these cells, known as Henle's fibers, pass inward. The inner portion of the external nuclear layer exhibits radial striations. It is called Henle's layer. This layer is most pronounced in the macular region. In the macular region some nuclei are frequently found outside of the external limiting membrane. They are believed to have been extruded from the nuclear layer.

The outer reticular layer consists of a nerve-tangle derived principally from the bipolar cells of the inner nuclear layer.

The inner nuclear layer contains some large ganglion cells, but is composed principally of small bipolar cells connected with the rods and cones. Other cells also are described in this layer.

The inner reticular layer (neurospongia) consists of a dense

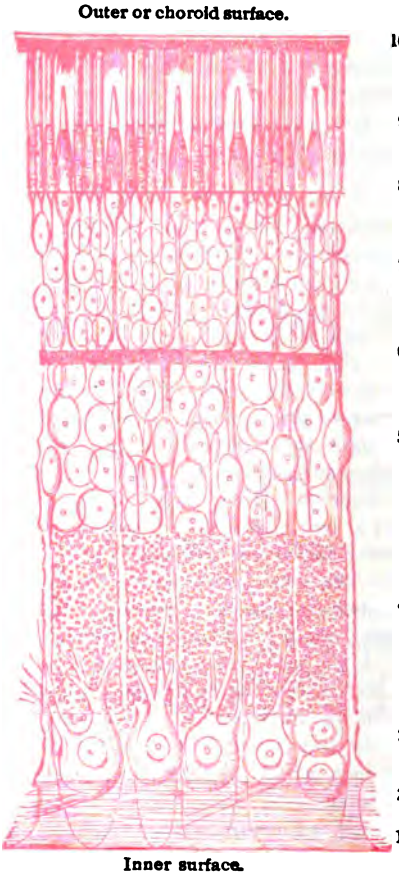

Fig. 524.—Diagrammatic section of the human retina. (After *M. Schultze.*)

network of nerve-fibers from the bipolar and other ganglion cells of the retina supported by a framework of great delicacy.

The ganglion-cell layer (*ganglion nervi optici*), except at the macula, is composed of a single row of large, multipolar ganglion cells, which send one or more branched processes outward into the retina and single, unbranched axis-cylinder processes (axons) centralward, where they form the nerve-fiber layer and optic nerve. Irregularly shaped granules, known as Nissl bodies, situated in the protoplasm of the nerve-ganglion cells, are readily demonstrated by special methods of staining.

The nerve-fiber layer is formed by the nonmedullated axons of the ganglion cells, which proceed to the optic disk, where they pass through the *lamina cribrosa* and acquire a medullary sheath. Medullated nerve-fibers are not infrequently found extending for a short distance from the nerve into the retina. More rarely medullated nerve-fibers are observed in the retina as isolated patches not connected with the medullated fibers of the nerve. The large neuroglia spider cells are found in the nerve-fiber and ganglion-cell layers and in no other parts of the retina. This is of importance in connection with the development of *glioma retinæ*.

The internal limiting membrane is not a true membrane, but is formed by an expansion of the inner ends of Müller's fibers.

The retinal blood-vessels follow, in a general way, the radial course of the nerve-axons. The larger vessels are confined to the nerve-fiber layer. The capillaries do not proceed beyond the outer reticular layer, being absent in the outer nuclear and rod and cone layer.

The only lymph-vessels found in the retina are the perivascular lymph-channels.

Macula lutea and *fovea centralis*. The *macula lutea* varies greatly in size. It may be but little larger than the fovea. It is permeated by a diffuse yellow pigment. In its center is a depression: the *fovea centralis*. In the macula region the following variations exist in the structure of the retina:—

The ganglion-cell layer and inner nuclear layer are greatly increased in thickness from multiplication of their elements. No modification exists in the reticular layer. Of the visual cells only the cones remain. They are somewhat smaller than in other parts of the retina. The fiber layer of Henle is here well marked and formed by the cone fibers only. A group of very delicate axons extends from the optic nerve to the adjacent macula. A coarser group of nerve-fibers passes across the macula, curves around the fovea, and unites beyond it. The retina gradually thins as it approaches the *fovea centralis*. The nerve-fiber layer, except a few fibers, is the first layer to disappear. The other layers gradually fuse and lose their identity. In the center of the depression but little remains except the layer of cones. The yellow stain is confined to the cerebral layers. Therefore, it is absent from the fovea. At the *ora serrata* the retinal layers undergo an analogous thinning and disappearance. The pigment layer persists throughout.

The retina itself is completely transparent;[1] consequently, with one exception, which is always a "congenital anomaly," every opacity recognizable during life may be regarded as a pathologic alteration. In this exception the nerve-fiber layer contains medullated nerve-fibers;[2] these are opaque and form whitish, glistening, asbestos-like wisps, which radiate from the upper or lower periphery of the papilla, in rare cases, however, occurring only at some distance from the papilla.

Retinal disease limited to the outer, or rod and cone, layer originates in the choroid, upon which its nutrition depends. The inner, or ganglion-cell and nerve-fiber, layers, however, are supplied by the retinal system

[1] After death the retina becomes gray-white, opaque, the visual purple, which imparts a purple-red color to the retina during life, changing and disappearing under the influence of light.

[2] Medullated nerve-fibers occurring in the retina are spoken of as a "congenital anomaly," although, as a matter of fact, the medullated sheaths do not form around the optic nerve-fibers until a month or two after birth.

of blood-vessels. The pathologic changes which occur in the inner layers depend largely upon degeneration in the walls of its vessels (angiopathic retinitis). It also is subject to the action of bacterial and chemic agencies.

Chronic retinitis. The chronic forms of retinal inflammation are characterized by proliferative and atrophic changes which permanently destroy the delicate nerve elements. New-formed, delicate endothelial membranes lining the inner surface of the retina are not uncommonly observed in eyes which have been subjected to prolonged low-grade inflammation. The cells sometimes rest upon a hyaloid membrane of considerable thickness. The source of these endothelial cells is obscure, but, as neither the internal limiting membrane nor the hyaloid membrane of the vitreous is an endothelial membrane, Parsons is probably correct in assigning their origin to the adventitia of the blood-vessels.

Granulation tissue may form in and upon the retina. When it is abundant between the retina and choroid, it springs from the choroid. If inflammatory processes are attended by early and abundant effusion of serum beneath the retina, retinal detachment prevents union to the choroid. Where the effusion is slight, the two membranes become firmly united. The granulation tissue organizes into fibrous tissue the subsequent contraction of which may cause extensive folding of the retina. As giant cells are frequent in retinal granulations, masses of folded retina and granulations may resemble tubercle (*q.v.*). Granulation tissue may grow out into the vitreous, where it subsequently organizes into bands and membranes of connective tissue. Where this occurs the condition is known as *retinitis proliferans*. There is some doubt regarding the proliferation of the neuroglia in retinitis. Exudates and granulation tissue may fill the spaces between Müller's fibers normally occupied by the nerve elements. The new-formed connective tissue which results is not readily differentiated from Müller's fibers.

When the choroid, retina, and vitreous are united by plastic exudates, contraction of the vitreous mass may lead to great elongation of Müller's fibers, whereby the thickness of the retina is greatly increased. At a later stage, however, shrinking of the intraretinal inflammatory products leads to thinning of the retina. Müller's fibers more frequently undergo fatty degeneration and break down under the influence of edematous effusion, thereby forming cystoid spaces of varying size. This is common at the periphery (peripheral cystoid degeneration). Cystic areas in the retina are easily torn. Such rents permit a fluid vitreous to pass beneath the membrane and produce retinal detachment.

Degeneration of the retinal blood-vessels occurs both as a cause and as a result of chronic retinitis. In retinæ which have degenerated the blood-vessels are extensively affected by the pathologic processes.

The lumina of both arteries and veins are frequently obliterated. Hyaloid and calcareous deposits exist in the vessel walls. The capillaries also undergo calcification. In general arteriosclerosis the retinal vessels share in the process. The smaller vessels are affected with an endovasculitis characterized by nodular accumulations of round and endothelial cells and by an enormous increase of elastic-tissue fibers. The arteries are principally affected. The veins suffer to a less extent. The vision may not be affected with extensive vascular degeneration. On the other hand, closure may occur in an artery and produce the clinic picture of obstruction, or in a vein and cause the condition known as **hemorrhagic retinitis.**

The pigmented epithelium suffers from inanition if, as is usual, the choroid participates in the degenerative changes. The cells become loosened and, if the external limiting membrane is ruptured, wander into the inner layers of the retina. They become depigmented, and the pigment accumulates in irregular masses. The liberated pigment, which is widely distributed, is transported not only by the epithelial cells, but also by leucocytes and by the lymph-stream. Pigment discharged from the epithelium of the *pars ciliaris retinæ* may lodge also in the retina. The form of the epithelial cells is modified by the inflammatory process. They swell and lose their hexagonal form or become spindle-shaped. They may also proliferate and form masses of irregularly shaped cells. They finally disappear from fatty and other (?) degenerative changes.

The nonmedullated axons of the nerve-fiber layer degenerate at an early stage of chronic retinitis. If the inflammatory process is not too prolonged, the nerve-fibers are still recognizable, although greatly shrunken. As a rule, however, they are destroyed and their place filled by fibers of new-formed connective tissue.

In albuminuric and other forms of chronic retinitis, peculiar cell-like bodies of inconstant size appear in the ganglion and nerve-fiber layer. They present a granular or homogeneous structure and contain refractile, nuclear-like spots. Their origin is obscure. They have been variously regarded as degenerated ganglion or neuroglia cells, so-called varicose nerve-fibers, degeneration of "an extremely fine myelin sheath, known to be present in some nerve-fibers" (Parsons), and as clumps of degenerated leucocytes (Greeff). The latter view, probably, is correct.

The cells of the ganglion-cell layer are very perishable and succumb early to the course of inflammatory conditions. Degenerative change in these cells is regarded also as the cause of loss of vision in toxic amblyopias, the degeneration first appearing as a change in the Nissl bodies. Destruction of a ganglion cell is followed by atrophy of its axon. Of the two nuclear layers the external is by far the most resistant to inflammatory processes. In edematous conditions the rods and cones quickly degenerate. The changes consist of swelling, loss of striation, and conversion into a granular detritus (identic with post-mortem degeneration).

In chronic proliferations, however, the rods and cones may persist when other retinal elements have nearly disappeared.

Albuminuric retinitis, angiopathic retinitis (*neuroretinitis albuminurica*). The ophthalmoscopic changes observed in retinitis affecting the inner retinal layers were formerly supposed to possess peculiar features pathognomonic of the particular systemic diseases (albuminuric retinitis, *retinitis diabetica,* etc.). It is, however, now held that such pathologic changes depend upon degeneration in the walls of the retinal vessels, and that any condition which produces vascular changes may result in this form of retinitis. Wilbrand designates the disease *retinitis angiopathica.* Nevertheless, owing to the prevalence of nephritis and its great tendency to affect the retina, this form of retinitis is rarely observed in connection with other diseases. The ophthalmoscopic changes are varied. They consist of opacity of the retina, retinal hemorrhages, vascular changes, and papillitis. The most characteristic is the presence of white, shining deposits around the disk and macula (*corona ciliaris*). Around the macula they frequently assume the form of radiating lines, the well-known "star figure."[1] Retinitis may occur in any form of Bright's disease, but is most frequently associated with the small atrophic (contracted) kidney, less frequently with the large white kidney, and rarely with the amyloid kidney. It is not very common in albuminuria of pregnancy. When found in this connection it must be remembered that chronic nephritis may have or perhaps always antedated the pregnancy. Except in pregnancy, the prognosis in albuminuric retinitis is always grave; 87 per cent. die within two years (Bull). The pathologic changes are those of chronic retinitis. (See p. 1062.) The vascular degenerations correspond with those found elsewhere. (See p. 1062.) Flat detachments of the retina are common. The choroid may be involved. Michel considers that degeneration of the choriocapillaris is the essential change in albuminuric retinitis. If this were true, the retinal epithelium should exhibit greater disturbances. The white spots are due to exudates which may or may not have undergone fatty degeneration. The star shape of the macular figure is determined by the arrangement of the nerve-fibers in this locality.

Senile degeneration. Certain degenerations of the retina are incident to advanced age. They are manifested macroscopicly by loss of transparency. Probably in all cases the choroid participates in the process, as is indicated by effusions and adhesions between the two membranes. Vascular degenerations are pronounced and undoubtedly bear a causative relation to many of the changes. In the retina there is thick-

[1] Oatman observed a case of albuminuria with marked neuroretinitis in one eye and complete obstruction of the central artery of the retina in the other.

ening of the neuroglia. This change is accentuated by atrophy of the nerve elements which ordinarily conceal the fibers of Müller. There is peripheral cystoid degeneration, and also peripheral degeneration, of the nerve elements and blending of the nuclear layers. The peripheral degeneration explains the senile contraction of the visual field. Fibrous connective tissue forms, especially around the disk, where it is deposited between the choroid and retina. The pigmented epithelium may lose its pigment, thereby rendering the choroidal vessels unusually distinct to ophthalmoscopic view. The macula is frequently affected by senile degeneration. In advanced cases both retina and choroid are highly atrophic.

Two affections of the retina, namely, choroidoretinitis and *retinitis pigmentosa* (pigmentary degeneration), are characterized by the occurrence of irregular pigmentation. In choroidoretinitis, in addition to pigmented spots, pigmented, white cicatrices develop in the retina (see p. 1034); in pigmentary degeneration, on the other hand, these white scars are absent. Cicatrices are to be differentiated from choroidal Drusen (colloid dots), which commonly occur in *retinitis pigmentosa.*

Strictly speaking, the term choroidoretinitis is entitled to a wide application, inasmuch as in most cases of chronic retinitis and choroiditis both membranes are affected. In any case degeneration of the choriocapillaris entails destruction of the outer layers of the retina. Choroidoretinitis is the term applied to those cases which resemble retinitis pigmentosa, but lack of clinic history of that disease. A diagnostic point of importance in favor of choroidoretinitis is evidence of inflammation of the uveal tract, as indicated by floating bodies in the vitreous or existence of synechiæ. The pathologic findings consist of atrophy of the retina and choroid.

Retinitis pigmentosa (pigmentary degeneration of the retina) is a very chronic, progressive disease, which always begins in childhood—perhaps also congenitally—and, as a rule, very gradually terminates in blindness, usually, however, not until late middle life. It is a chronic process with subsequent shrinkage and atrophy and pigmentation of the retina. The disease commences in the outer layers of the retina in the region of the vessels, *i.e.,* that portion nourished by the choroid. The pigmentation commences at the periphery of the eye-ground (equator) and extends slowly over the entire retina, the pigment accumulating in the form of dark puncta and dendritic figures, which closely resemble bone-corpuscles and Haversian canal systems. The pigment is not deposited until atrophy of the retina is far advanced and the nerve elements have disappeared. The line of demarkation between the atrophied and unaffected retina is sharp. This affection begins in the anterior portion of the eye and spreads slowly backward, the macular region being the last to be affected. It is always bilateral, often hered-

itary, not infrequently combined with other formative anomalies (hare-lip, deafness, etc.), and is most frequently observed in children of consanguineous parents. Adhesions form between the retina and choroid and between the choroid and sclera. In areas where atrophy is complete, all the retinal layers are replaced by layers of fibrous connective tissue. The optic nerve gradually atrophies. The retinal blood-vessels become greatly attenuated or even obliterated. The walls of the smaller vessels are thickened and degenerated, and pigment is deposited in the walls of all the vessels. The choroid is affected; the most constant change is in the choriocapillaris.

Atypic cases occur presenting all the clinic features except pigmentation. In other cases the pigmentation is not characteristic or the retina is covered with white dots (*retinitis punctata albescens*). The subjective symptoms are night blindness (hemeralopia) and gradual contraction of the field of vision. The disease is probably a choroidoretinitis, as shown by early atrophy of the external layers of the retina which are nourished by the choroid. In typic cases both the retinal vessels and the choriocapillaris undergo extreme degeneration. It is probable that in those cases unattended by pigmentation only the retinal vessels are affected.

Retinitis proliferans is characterized by the presence in the vitreous of connective-tissue membranes or bands proceeding from the disk and surrounding retina. The frequency of intraocular hemorrhages in these cases has led some authors to regard the membranes as unabsorbed blood-fibrin. In some cases, however, membranes form without previous hemorrhages. Chronic retinitis is present, as indicated by the reports of cases which describe "proliferation of Müller's fibers." Membranes may originate from granulation tissue or from the adventitia of the blood-vessels. It is probable that a variety of causes may, under favorable conditions, produce the phenomena. The membranes are composed of connective-tissue cells. Membranes frequently form after perforating injuries, especially if a foreign body has lodged in the eye.

Amaurotic family idiocy is an hereditary disease occurring in infancy and terminating in death in from one to two years. The fundus changes consist of a whitish area around and including the macula, with a cherry-red *fovea centralis*. The macular picture closely resembles occlusion of the central artery. The pathologic examinations have shown that the disease is a degeneration of the gray matter of the entire central nervous system, including the ganglion cells of the retina (Holden). It is commonly observed in children of consanguineous parents.

The retinal change sometimes observed in leukemia and generally called **retinitis leukæmica** is characterized by the occurrence in the retina of leukemic infiltrations which in every way resemble the same changes seen in the liver and kidneys. Therefore, as Virchow has shown, the process here is a kind of metas-

tasis, not an inflammation in a strict sense. Virchow never confirmed his surmise that leucocythemic tumors might be found in the retina. Pseudotumors, however, occur in this disease, both in and upon the surface of the retina. They are composed of white and red blood-corpuscles which have escaped from the vessels, probably by diapedesis. The nodules of blood-corpuscles show no tendency to organization or vascularization, neither do they undergo degeneration. Retinitis and also thrombosis of the central vein may occur in the course of leukemia.

Chronic inflammation of the retina assumes certain special forms the clinical features of which are fairly constant.

Retinitis circinata, first described by Fuchs, appears ophthalmoscopicly as a ring of white spots or lines encircling the macula. Vascular or retinal degeneration also is usually observed. Hemorrhages into the retina occur in most if not all the cases. It is a disease of the later period of life, although exceptionally it has been observed in young adults. Various theories have been advanced to account for the white spots. One case has been examined microscopicly by Ammann. There was peripheral retinal edema. The sustentacular tissue appeared thickened. In those parts that were clinicly recognized as diseased, the retina was greatly thickened. In the internuclear layer only were numerous hyaline bodies of homogeneous or slightly granular appearance. They were blended with extravasated blood and were evidently derived from degenerated blood-corpuscles. The hyaline deposits were surrounded by large, mononuclear vesicular cells containing fat. The choroidal vessels were sclerosed. The disease is a degenerative process in which a variety of retrograde changes undoubtedly takes place. Arteriosclerosis is so common an accompaniment of the disease that many regard it as the cause.

In the course of a retinal inflammation small hemorrhages are sometimes observed. These hemorrhages are generally situated in the nerve-fiber layer (striate hemorrhages), less frequently in the deeper layers. If the hemorrhages frequently recur or are so extensive as to become the most prominent feature, the condition is called hemorrhagic retinitis (*retinitis hæmorrhagica*). On the other hand, retinal hemorrhages may occur also without inflammation, *e.g.*, as a result of intense hyperemia from compression of the veins in glaucoma and in optic neuritis; further, in general venous congestion due to a heart lesion; in leukemia; occlusion of the central artery and thrombosis of the central vein; in bleeders, etc. They are so frequent among young adults of both sexes that a separate group has been created under the name of recurring vitreous hemorrhages in the young. These frequently depend upon tuberculosis of the ciliary body. Retinal hemorrhages occur partly in the retina itself (infiltrating form, especially in the nerve-fiber layer), partly in the vitreous. In both cases slightly opaque areas and seldomer pigmented cicatrices remain after the very slowly progressing absorption.

Edema:—In edema of the retina resulting from vascular or lymphatic obstruction the fluid is usually abundant. It is poor in albuminous constituents and is readily absorbed when the obstruction is removed. Fluid of inflammatory origin, however, is rich in proteids, which are precipitated by hardening reagents and appear under the microscope either as a finely granular deposit, a fibrinous coagulum or as rounded, hyaloid masses. Such exudates may be removed, or they may be replaced by scar-tissue. They may also pass through the degenerative processes which terminate in fatty or calcareous deposits. In acute inflammation the blood-vessels are surrounded by polymorphonuclear leucocytes, which may wander off into the vitreous or choroid, or the tissues may be infiltrated by lymphocytes. In both acute and chronic retinitis extravasations of blood are common. If the hemorrhage is slight, the blood usually accumulates between the axons of the nerve-fiber layer, where they present the characteristic striated or flame-shaped ophthalmoscopic picture. In more extensive hemorrhage or in hemorrhage from the retinal capillaries the blood follows the direction of Müller's fibers and accumulates in the nuclear layers, forming round or irregular patches. Blood extravasated into the retina does not usually clot. Its removal is slowly accomplished by leucocytes. The hemoglobin may remain and form pigmented deposits.

Acute purulent inflammation of the retina may be exogenous or endogenous. Exogenous infection is common after perforating wounds of the eye or corneal ulcers. Purulent retinitis forms a part of panophthalmitis. As infection usually occurs in the anterior segment of the globe, purulent infiltration of the retina appears first at the ora serrata, and also around the optic nerve, the latter location being reached via the hyaloid canal. The swelling of the retina from inflammatory edema is very great. The accumulation of fluid quickly produces complete detachment. The entire retina is infiltrated with leucocytes, which ensheath the vessels, particularly the veins. From the retina the purulent process passes to the vitreous and choroid. The contents of the eye may undergo necrosis and be discharged as pus, or organization of exudates may eventuate in *phthisis bulbi.*

Purulent endogenous or **metastatic retinitis** presents the microscopic appearance of the exogenous form. It occurs in the course of sepsis, particularly in cases of puerperal infection. It is probable that many cases regarded as metastatic choroiditis really begin in the retina. It appears to develop from a general bacterial infection of the retinal capillaries. Both eyes are commonly affected.

Considerable confusion has resulted from the application of the term "septic retinitis" to a condition which differs from purulent metastatic retinitis. It occurs in the course of various septic and other conditions and is characterized by the appearance (ophthalmoscopicly) of white spots around the disk, but not on or very near the macula. Hemorrhages also occur. Usually there is no inflammatory reaction manifested externally. The pathologic findings are not constant, the most

common being the so-called varicose nerve-fibers and areas of exudates. Similar ophthalmoscopic appearances are observed in a variety of dyscrasiæ, such as leukemia, carcinomatosis, scurvy, anemia, albuminuria, diabetes, etc.

The presence of blood-vessels in the retina renders it susceptible to inflammatory processes, both acute and chronic. In considering its pathology, however, it should be borne in mind that the retina is a highly specialized portion of the central nervous system in which many of the most destructive changes are secondary to disturbances of nutrition. The retinal blood-vessels form a terminal system, having no anastomoses with the choroidal or other vessels, while the only lymphatics are those which accompany the vessels. Therefore, any obstruction in the circulation is quickly manifested by transudation of serum into the retina. The cause of stasis may be remote, as in pressure upon the brain or along the course of the optic nerve; it may result from obstruction of the central artery or its branches by an embolus or thrombus, from the presence of foreign bodies or growths, and from injuries, direct or indirect. Detached retinas become edematous both from stasis and absorption of fluid. The early stage of inflammatory processes is, of course, marked by edema the extent of which depends upon the intensity of the process. Edema of the retina manifests itself first in the nerve-fiber layer, which is the region of the larger blood-vessels. The nerve-fibers are separated by fluid, the inner layers being lifted up at the expense of the vitreous space. Transient edema of the nerve-fiber layer subsides without permanent injury to the retina. When the edema is long continued and in the edema of chronic degeneration, the fibers swell and lose their outlines. The ganglion-cell layer participates in edema of the nerve-fiber layer. Transient stasis may not injure these cells, but they are the least resistant of the retinal elements. In edema of the nuclear layers the cells are separated into vertic columns. This configuration is determined by the arrangement of the fibers of Müller. Edema is manifested particularly in the internuclear (external reticular) layer. Large spaces may form of sufficient size to be called cysts. The delicate fibers of the internal reticular layer are unable to withstand an extensive edema, and irreparable damage follows their rupture. The external limiting membrane offers considerable resistance to pressure, but finally ruptures, and the granules of the external nuclear layer are forced in considerable numbers into the layer of rods and cones. Nuclei found in this layer under such conditions are not to be confounded with the extruded nuclei found in normal retinæ. Although the rods and cones are very resistant to true inflammatory processes, they are readily dissolved by the serum of simple edema. Frequently after a severe contusion of the eyeball there is a transient loss of vision and the retina presents a grayish-white opacity. The condition has been called *commotio retinæ*. It is now known that the whitish discoloration is an exudation of serum between the choroid and retina. It is supposed to come from the choroid and to depend upon paralysis of the walls of its blood-vessels. Edema of the retina may lead to the formation of cystic spaces of large size. Such spaces are frequent in old detachments. They are due to separation of the layers of the retina. Similar cysts have been observed as a congenital condition. Under the name of peripheral cystoid degeneration of the retina (Ivanoff's edema) has been described a condition characterized by the existence of spaces in the retina situated at its periphery behind the *ora serrata*. These are almost constant in eyes of persons over 50 years of age and may be present in

early life. In advanced cases the nerve elements have usually disappeared, the spaces being formed by the distended sustentaculum of the retina. They are common in inflammations of contiguous tissues, but no special origin can be assigned to them. The spaces may contain serum or any of the products of inflammation or degeneration.

Endophlebitis and thrombosis occur in the central vein and its branches, and cause enormous venous hyperemia, which is usually followed by intense, even recurrent hemorrhagic infiltrations. These finally terminate in complete destruction of the retina. Thrombosis is more frequently observed in advanced age; it may, however, at any age follow an inflammation which extends to the wall of the vein.

Obstruction (embolism) of the central artery of the retina or of its separate branches is immediately followed by complete loss of vision, due to acute ischemia throughout the area supplied by the vessel. The ophthalmoscopic picture is characteristic of the condition. The retina presents a milk-white opacity, which appears within a few hours. The opacity is greatest around the macula and optic disk. The *fovea centralis* appears as a cherry-red spot in the midst of the opaque retina. Unless circulation is quickly restored, the retina perishes and later undergoes extreme degeneration. In 1859 von Graefe diagnosticated such a case as embolism of the central artery, and this was confirmed two years later by necropsy. For many years embolism was supposed to explain all cases presenting the appearance of obstruction. Recent investigations, however, indicate that the great majority of such cases depend upon obstructive disease in the vessel walls, which may or may not result in the formation of a thrombus. Post-mortem examinations of these cases do not throw as much light upon the subject as might be expected, because the fibrous and degenerative changes occurring after vascular obstruction mask the original cause. The opacity of the retina is due to degeneration of the ganglion cells and nerve-fibers. The cherry-red spot seen in the macula is the normal red of the choroid contrasted with the now white retina. The choroid is visible at the macula because this area contains no nerve-fibers, being composed only of the layer of cones.

If the embolus contains infectious germs, an acute purulent retinitis results, which usually quickly terminates in panophthalmitis. On the other hand, purulent retinitis may be the result of extension of a purulent process from adjacent parts (frequently after trauma). Finally, it is always an accompaniment of panophthalmitis originating from other causes.

Detachment of the retina from the choroid, upon which it only loosely rests, may be caused by changes in the vitreous, by escape and

prolapse of the vitreous in injuries, by shrinkage, by exudates or extravasates from the choroid, by tumors of the choroid and retina, and by the cysticercus. Retinal detachment is usually partial at first, but later increases in extent, and, finally, becomes total.

When the retina remains adherent only at the papilla and the *ora serrata* it is thrown into folds and in total detachment assumes the form of a funnel. Sometimes laceration (*ruptura retinæ*) is observed; the vitreous may then escape through the rupture and enter between the retina and choroid.

Glioma of the retina (Virchow) is the only tumor positively known to originate in the retina. In the rare examples of other supposed primary retinal growths, the diagnosis has not been established beyond doubt. Glioma occurs only in children, usually before the 6th year, and probably in a large proportion of cases it is congenital. It is frequently bilateral and manifests a tendency to affect several members of one family. The presence of the neoplasm is usually discovered before the third year of life. It may cause detachment of the retina as well as detachment of the choroid from the sclera, and, as a rule, forms metastases only when the sclera is perforated. It passes through the same stages as sarcoma of the choroid. Metastatic deposits, however, occur much sooner than in sarcoma and show a preference for the bones of the face and skull, the brain, and the lymphatic glands, particularly the preauricular.

Intraocular metastases—daughter deposits, which are almost unknown in sarcoma of the choroid—occur in all cases of *glioma retinæ;* in fact, this is the principal method of extension.

Under the name **"cryptoglioma"** Schöbel has called attention to certain rare cases of glioma which undergo temporary retrogressive metamorphosis. There is an accompanying chronic iridocyclitis. The glioma degenerates and the eye shrinks, thus producing the picture of **pseudoglioma.** Sooner or later the glioma begins to grow again. Probably permanent spontaneous cure of *glioma retinæ* is unknown. Temporary recession without existing intraocular inflammation has been observed (Scott Wood).

Glioma retinæ is highly malignant and invariably terminates in death, unless the eye is enucleated before the stage of extraorbital extension. As a rule, glioma grows outward into the subretinal space, less frequently inward into the vitreous cavity. This has led to a gross classification into *glioma exophytum* and *glioma endophytum.*

In its structure glioma of the retina resembles angiosarcoma of the choroid, but possesses a more complex organization. The tumor is formed by convoluted blood-vessels surrounded by a thick mantle of cells. These cellular tubes are sep-

arated from each other by wide areas of necrotic cells. The cells which compose the vascular sheath are arranged in the form of tubules, cylinders, circles, and radiately around stems of connective tissue. This description applies to the early stage of development. In advanced cases, as the result of hemorrhages, necrosis, and pressure, the details of structure are difficult to trace. The cells are embryonic in type, the majority being small and round or cylindric, with large nuclei and very scanty, homogeneous protoplasm. Many possess short prolongations. Glioma cells never contain pigment; any pigment present in the tumor is displaced uveal or retinal pigment or due to hemorrhage. Wandering leucocytes may contain pigment. In those cases where the cells form tubules, transverse sections of the latter appear under the microscope as small rosettes. The rosettes consist of closely and regularly packed cells of pyramidal form arranged around the lumen of the tubule. The cell nucleus is situated at its periphery. The cell protoplasm extends inward and unites with that of adjoining cells to form the membranous lining of the tubule. This structure in a tumor is pathognomonic of *glioma retinæ*. The cells are supposed by Wintersteiner to be due to proliferation of the rods and cones. Ganglion cells and neuroglia cells also are present. According to Greeff, neuroglia spider cells predominate. The intercellular substance is scanty and is said to consist largely of cell processes.

Glioma is supposed to arise from the nuclear layers of the retina, most frequently from the inner (3 to 1). In common with other malignant growths, *glioma retinæ* undergoes necrotic and degenerative changes, especially calcific, which occur much earlier than in sarcoma. The metastases of *glioma retinæ* resemble sarcoma. The metastatic deposits appear to excite proliferation of the connective-tissue cells among which they lodge.

The name "glioma" is based upon its supposed origin from the neuroglia of the retina (Virchow). Greeff believes that it develops from misplaced neuroglia spider cells, while Wintersteiner attributes its origin to misplaced rods and cones (Cohnheim's rests). He, therefore, adopts Flexner's term "neuroepithelioma" as preferable to glioma. Treacher Collins considers *glioma retinæ* to be composed of embryonic retinal cells, being analogous in this respect to sarcoma of other parts. The close resemblance of gliomata to angiosarcoma, especially perithelioma, suggests that these tumors are of vascular origin.

Syphilitic retinitis. Many of the retinal and choroidal changes previously described, such as disseminated choroiditis, chorioretinitis, etc., are of syphilitic origin. Owing to the lack of microscopic examinations of early cases, it has not been determined whether the changes observed in the fundus in diffuse syphilitic retinitis are primary in the retina or secondary to choroiditis. In the late stages of such cases, both retina and choroid are involved. There is certainly no reason to believe that retinal vessels are exempt from primary syphilitic disease, or that vascular changes in the retina could not antedate those in the choroid. In the cases examined the walls of the blood-vessels are greatly thickened and imbedded in round cells. The vascular degenerations correspond to those found in syphilitic lesions elsewhere; nevertheless, they cannot be considered pathognomonic.

Tuberculosis of the retina, with rare exceptions, is secondary to tuberculosis of the uveal tract. Exceptionally, tubercle appears on the papilla and extends to the adjacent retina. In the most probable case (O'Sullivan and Story) the diagnosis of tubercle was made before enucleation. A retinal growth was found surrounding the disk, but separated from the choroid by an abundant effusion. It presented the anatomic structure of tubercle. The patient was an apparently healthy young woman. Tubercle bacilli were not demonstrated.

In the great majority of cases **leprosy** attacks the eye through the ciliary body. The disease exhibits no predilection for the retina. The changes which have rarely been noted consist of inflammatory thickening and the presence of lepra bacilli.

THE ORBIT.

The globe lies in the orbit enveloped in an abundant layer of fat-tissue. Alterations of the wall of the orbit are generally connected with diseases of the bones, to which the reader is referred. (See p. 902.)

The shape of the orbit approximates a quadrilateral pyramid the apex of which is the optic foramen. The inner walls of the two orbits are nearly parallel; consequently, their outer walls are highly divergent. The orbit is formed by the frontal, the sphenoid, the malar, the superior maxilla, the palate, the lachrymal, and the ethmoid bones. A portion of the inner orbital wall, made up by the lachrymal bone and *lamina papyracea* of the ethmoid, is extremely thin. At the border of the external opening the bones are greatly thickened to form a protecting ring, called the margin of the orbit. A depression in the upper outer wall of the orbit, known as the lachrymal fossa, contains the lachrymal gland. In the posterior portion of the orbit are three important apertures: 1, the optic foramen, which transmits the optic nerve and ophthalmic artery, the artery lying below the nerve; 2, the superior orbital fissure, which lies between the greater and lesser wings of the sphenoid and transmits the nerves to the extrinsic muscles, and also the ophthalmic division of the trigeminus; 3, the infraorbital fissure, formed between the greater wings of the sphenoid and the superior maxilla, which transmits the superior maxillary division of the trigeminus. This fissure is peculiar in that the fascia by which it is closed contains large numbers of smooth muscle-fibers: the *muscularis orbitalis* of Müller, innervated by the sympathetic.

The size of the orbit is proportioned to the size of the eyeball. At 5 years of age it is nearly as large as in adult life. The size of the two orbits may differ in the same individual from imperfect development of the bones, as when an eye has been enucleated or *phthisis bulbi* has occurred in childhood. In such cases the corresponding orbit ceases to grow or even diminishes in height so as to form a fissure-shaped opening.

The orbit contains the eyeball, optic nerve, lachrymal gland, ocular muscles, nerves, and blood-vessels. These structures are imbedded in adipose tissue and held together by a closely united system of fibrous ligaments and fascia, a strong membrane which is attached to the margin of the orbit and the tarsi. The eyeball is suspended in a fibrous envelope, called the capsule of Tenon, containing

openings for the cornea and optic nerve. The space between the eyeball and Tenon's capsule is lined with endothelium, constituting a synovial sheath for the globe. The tendons of the extrinsic ocular muscles pierce the capsule and receive sheaths from it.

The eyeball is situated in the anterior portion of the orbit, so that the apex of the cornea will, in most cases, just touch a vertic line drawn between the upper and lower margins of the orbit. This rule, however, varies considerably within normal limits.

The orbits participate in **congenital malformations** of the skull. Thus, in double-faced monsters they may be absent, while in hemicephalics with markedly prognathous skulls they may be abnormally enlarged. In microcephalus, acephalus, and cyclopia the orbit is usually very small and the optic foramen frequently absent. In some cases of optic atrophy associated with congenital deformities of the cranium, the optic foramen has been found to be very small. In these cases it is uncertain whether the atrophy is due to narrowing of the foramen or both conditions proceed from a common cause.

Among other congenital anomalies may be mentioned: (*a*) fissures in the orbital surface of the superior maxilla, and also in the *lamina papyracea* of the ethmoid; (*b*) intercallary bones in the roof of the orbit, and also a form of osteophyte (*cribra orbitalis*), are sometimes found; (*c*) the orbital opening may be displaced by a bony arch formed below the supraorbital ridge; (*d*) defective development of bones in the anterior portion of the upper and inner angle, which causes hernia of the meninges (meningocele) or of the cerebral substance (encephalocele).

Acquired distortions of the orbital walls may be due to pressure from adjacent facial or cranial cavities. Some authors have attributed cases of myopia to irregularities on the bony walls of the orbit which interfered with the natural movements of the globe. Cases of divergent strabismus also have been supposed to depend upon excessive separation of the orbits.

The most important affection observed in the orbital adipose tissue is acute inflammation, which is either circumscribed and terminates in abscess formation[1] or spreads over a more or less large area as diffuse phlegmon.[2] This acute inflammation is either an extension from an adjacent process,[3] or a metastatic affection,[4] or the result of injuries with immediate or subsequent infection of the wound. Inflammation of Tenon's capsule (tenonitis) may be idiopathic or the

[1] Orbital abscess, usually retrobulbar abscess.

[2] Retrobulbar phlegmon, orbital phlegmon.

[3] Facial erysipelas, periostitis, caries, empyema of neighboring cavities, *arachnitis cerebrospinalis*, etc.

[4] In septic processes, puerperal fever, bone suppurations, etc.

result of trauma. The symptoms of tenonitis vary according to the severity of the inflammation. Usually, there is moderate exophthalmos; chemosis, either diffuse or localized over the attachment of a muscle, and moderate edema of the lids. It may occur in gout, rheumatism, infectious diseases, and sepsis, and is not an unusual sequela in tenotomy.

An extensive extravasation of blood into the orbit is nearly always due to trauma and frequently is observed in fracture of the orbit. In rare cases it is due to vascular degeneration, and has followed also violent coughing. Sometimes the hemorrhage is so intense (in rupture of a large vessel) that the globe is forced completely out of the orbit: *luxatio bulbi traumatica.*

Emphysema of the orbit is always due to fracture communicating with the nasal passages.

Exophthalmos (proptosis, "goggle-eyed") signifies protrusion of the globe from the orbit. Exophthalmos may be of various degrees. In the mild degree closure of the lids is still possible; in the intense forms, however, this can no longer take place, so that further and severer changes occur in the cornea, etc. Exophthalmos is usually produced by diminution in the size of the orbit or increase of its contents, generally the latter; for example, it is caused by acute inflammations of the orbital adipose tissue from nasal-sinus disease, etc.; extensive hemorrhages into the orbit, including those of the optic nerve, and orbital tumors (exostoses of the orbital wall, lipoma, sarcoma, carcinoma of lachrymal gland, angioma); aneurism of the ophthalmic or carotid artery; thrombosis of the ophthalmic vein in connection with sinus thrombosis, etc. Finally, exophthalmos is a nearly constant symptom of Basedow's disease. (See p. 742.)

In excessive exophthalmos the ocular muscles are put on the stretch, so that they are unable to move the globe, thus causing diplopia. The S-shape of the optic nerve permits considerable displacement of the eyeball without impairment of its integrity. The proptosis may, however, be great enough to cause optic neuritis and subsequent atrophy, especially if the displacement develops very rapidly. The neuritis and atrophy accompanying cellulitis are of toxic or circulatory origin. If the protrusion is sufficient to prevent closure of the lids (lagophthalmos), the cornea becomes dry, particles of dust which cannot be removed by winking adhere to its surface, and ulceration ensues (*keratitis e lagophthalmos,* q.v.). The pressure of the eyeball from behind upon the lower lid produces ectropion. Exophthalmos is observed also in some cases of paralysis of the extrinsic muscles after ill-advised tenotomies.

Pulsating exophthalmos is applied to a condition presenting a complex of symptoms, the most prominent being marked proptosis, a compressible tumor of the superior inner angle of the orbit; swelling and vascular stasis of the conjunctiva, lids, and brow; pulsation of the lids

and globe, loud bruit heard over the head and ceasing instantly on compression of the common carotid, dilation and pulsation of the retinal veins, and sometimes neuroretinitis. In the majority of cases pulsating exophthalmos is of intracranial origin, and results from aneurismal varix between the internal carotid artery and the cavernous sinus, the arterial blood being pumped into the sinus under high pressure and thence into the ophthalmic veins. Other reported causes for this condition are aneurism of the internal carotid, and also of the ophthalmic artery at its origin. The rare cases of orbital origin have been attributed to telangiectatic tumors and aneurisms.

Intermittent exophthalmos is a rare condition in which the eye protrudes at irregular intervals, usually when the head is lowered. It has been supposed to depend upon varicose veins in the orbit. Exophthalmos due to the presence of tumors and inflammatory exudates in the orbit are considered under their appropriate titles.

Abnormal retraction of the eyeball into the orbit is called **enophthalmos.** It may be due to loss of orbital fat from injuries and operations, or its absorption in progressive facial atrophy, and in extreme emaciation. The majority of cases of enophthalmos follow blows in the orbital region. When enophthalmos immediately follows injury, it is probably due to fracture which has led either to enlargement of the orbital cavity, loss of orbital fat, or dislocation of the globe. According to Lang, the lesion is fracture communicating with the antrum of Highmore. Enophthalmos may occur weeks or months after injury of the orbital region, and it not infrequently is associated with paralysis of the inferior oblique muscle. The following explanations have been presented to account for this late paralysis: fracture of the floor of the orbit (Lang); paralysis of the orbital muscle of Müller (Schapringer); trophic disturbance from lesion of the nerves, particularly the sympathetic (Baer); cicatricial contraction (Gessner); injury to Tenon's capsule (Schoonmaker). In certain cases of defective motility of the eye, recession of the globe occurs in adduction. The exact cause of this phenomenon is not accurately determined, although it probably depends upon shortening or rigidity of the externus, whereby it acts as a check on the internal rotation of the globe. Enophthalmos occurs in paralysis of the sympathetic nerves, in myelitis of the cervical cord (involvement of the sympathetic), and after the subsidence of pulsating exophthalmos.

Periostitis of the orbit may be due to injury or to constitutional dyscrasiæ, *i.e.*, syphilis and tuberculosis. The disease may subside or go on to suppuration. Abscess and fistula, which persist for years, are common sequelæ. When the process is deeply situated in the orbit, retrobulbar abscess may be expected.

In subperiosteal gumma of the orbit, there is extensive bone necrosis. Sequestra may be retained in the orbit for years, their final expulsion being followed by extensive loss of tissue and deformity. Certain forms of periostitis, especially of syphilitic origin, may cause great thickening of the orbital bones. Osteitis not infrequently extends to the orbit from adjacent cavities.

Phlegmon (retrobulbar abscess or cellulitis) **of the orbital tissues** may result from injuries, foreign bodies in the orbit, infection during operations; abscess in adjoining cavities,[1] especially the ethmoid, and from disease of the alveolar process of the superior maxilla. It may be associated with dacryocystitis, pharyngitis, parotiditis, and erysipelas. As a metastasis, it occurs in various infectious diseases. After evacuation of the pus, prompt healing usually ensues. The vision, however, is frequently impaired or destroyed through inflammation and atrophy of the optic nerve or thrombosis of its vessels. Other complications of orbital cellulitis are inflammation of the uveal tract, detachment of the retina, panophthalmitis, and occasionally meningitis or cerebral abscess.

Thrombosis of the cavernous sinus in its early stages may simulate retrobulbar abscess (cellulitis). The orbital and ocular symptoms in this disease are due to stasis in the ophthalmic veins, which discharge into the cavernous sinus. Thrombosis of the cavernous sinus is usually of septic origin and arises from carious or purulent foci about the head and neck.

Trichinosis of the orbital muscles has been described. (See p. 366.) There is edema of the lids, conjunctival hyperemia with ecchymoses, and sometimes neuroretinitis with retinal hemorrhages. Subjective symptoms are tenderness on pressure, painful motion, and diplopia.

Tumors in the orbit connected with the optic nerve have already been described. (See p. 1056.) Dermoid cysts are the most common of all growths originating in the orbit. They are always congenital, although they may be so small at birth as to escape notice. Later in life they may attain large size. The great majority of orbital dermoids are situated in the anterosuperior portion near the external or internal angle, although they may occur elsewhere. Located, as a rule, in front of the globe, they do not cause exophthalmos, differing in this respect from other tumors of the orbit. Although the main tumor is situated superficially, its processes may extend very deeply into the orbit. A

[1] Babes and Mironescu describe (*Centbl. f. Bakt.*, Bd. 55, H. 2) 2 cases of abscess, one retrobulbar, the other of the cheek, in which black granules were formed and discharged with the pus from a fistula. The granules and black masses originated from connective-tissue fibers and were caused by a thread fungus.

dermoid of large size usually exerts sufficient pressure upon the bones to create an artificial fossa. Dermoids are not infrequently mistaken for sebaceous cysts, from which they are differentiated by their epithelial lining and the presence of dermoid elements, *i.e.*, hairs, sebaceous glands, sweat-glands, etc. Secondary cysts may develop from these glands within the original cyst. Dermoids of the orbit are subject to various degenerative changes. As the result of internal ulceration of its walls, the cyst may contain large masses of granulation tissue remarkable for the presence of great numbers of enormous giant cells. These cells are of the "foreign body" type, and have been attributed to the presence of hairs in the granulations. If sebaceous glands predominate in the tumor, the secretion from them may result in the formation of an oily cyst. In dermoids containing few or no sebaceous glands the accumulation of cast-off epidermis and hairs may form an atheromatous cyst.[1]

Considering the large amount of adipose tissue normally present in the orbit and its wide variations within physiologic limits, the diagnosis of **lipoma** situated in this locality must be accepted with caution.

Fluid in Tenon's capsule may simulate a cyst. Similar accumulations of serum may form on the tendons of the muscles, usually the *levator palpebræ superioris,* and on the superior oblique, where it passes through its pulley. Pseudocysts may result also from degeneration in the center of a blood-clot.

Hydatid cysts usually occur in young people, two-thirds of all cases occurring between the ages of 11 and 21 years (Neisser).

Cysticercus cysts of the orbit are very rare. When they occur they are not, as a rule, deeply situated.

Granulations and **polypi** found in the orbit are usually connected with disease of the bone, either in the orbit or in some of the adjoining cavities.

Primary exostoses of the orbit usually spring from the upper and inner angle. They may, however, grow from any portion of the bony wall. The great majority of these growths consist of a smooth, thick, knobby shell of extremely dense, hard bone containing a center of spongy bone (ivory exostosis). In rare cases the spongy bone may predominate, or they may be partly cartilaginous. As a rule, osteoma of the orbit is of extremely slow growth, exceptions being the spongy and cartilaginous varieties. When they are situated in the sphenoidal fissure, the

[1] Sperber has reported (*Centb. f. Augenhlk.*, May, 1907) a case of "mucous cyst in the orbit with oily contents," which he concludes developed from either a conjunctival pouch or from inclusion of the nasal mucosa. The author certainly has failed to demonstrate that the growth was not a true dermoid.

optic nerve is compressed and atrophy results. Osteoma may invade the orbit from without. Such cases should be carefully differentiated for the reason that primary tumors situated superficially are not difficult of removal, whereas considerable danger to life attends operation upon those which have extended to the orbit from the facial cavities.

Simple hemangioma, or **telangiectasia,** and **cavernous hemangioma** both occur in the orbit. Telangiectases are congenital growths situated in the lids, whence they extend into the orbit. Cavernous angiomata develop in the orbit. While the telangiectases are not usually encapsulated, the cavernous hemangiomata possess a thick, fibrous capsule lined with endothelium, from which trabeculæ extend into the tumor, the structure being that of erectile tissue. This form sometimes contains phleboliths. Spontaneous fibrous degeneration may take place in these growths (angiofibroma). That they undergo sarcomatous degeneration is difficult to prove, inasmuch as such neoplasms may have been malignant from the beginning. Bruit and pulsation do not belong to the history of these tumors, cases of pulsating exophthalmos reported as dependent upon hemangiomata being open to doubt.

Lymphangiomata of the orbit are rare.

Doubt has been expressed as to the occurrence of **fibromata** in the orbit. They may grow from the periosteum, sheaths of tendons, and dural sheath of the optic nerve. In diagnosticating fibroma of the orbit the tendency of other growths, especially angiomata, to undergo fibrous hyperplasia must be borne in mind.

Lymphomata occur in the orbit. They may be divided into: 1, leukemic and pseudoleukemic deposits, both of which are associated with diseases of the blood and blood-forming organs; 2, round-celled growths resembling sarcomata, but apparently nonmalignant.

True neuromata, *i.e.,* growths consisting of newly formed nerve elements, and also neurofibromata, have been observed in the orbit. Plexiform neuroma (*elephantiasis neuromatodes,* cirsoid neuroma) occurs in the orbit very rarely. In the majority of cases the site of the disease is the temporopalpebral region, and in about 12 per cent. of these the orbit is involved. But 2 cases have been reported in this country: 1 by de Schweinitz and 1 by Beard and Brown. Histologicly, these growths exhibit "consecutive whorls of loose fibrous connective tissue containing many nuclei, and in their centers medullated nerve-fibers, sometimes intact and sometimes destroyed by fatty degeneration" (de Schweinitz). Parsons describes a case as consisting of "coiled and convoluted nerves of the most various sizes, surrounded by dense fibrous tissue fading off imperceptibly into the orbital fat. Curious bulbs were found resembling end-organs." Beard and Brown's case was encapsulated. Brown describes pearl nests of closely packed, fusiform and epi-

thelioid cells. Ziegler regards the growth as true neuroma associated with fibromatosis. He is impressed by its close resemblance to elephantiasis. Plexiform neuromata are of extremely slow growth. They are regarded as nonmalignant; nevertheless, they recur after operation unless thoroughly removed. They are said occasionally to undergo sarcomatous degeneration (secondary malignant neuroma of Garré).

Primary carcinoma of the orbit does not occur. Carcinoma may invade the orbit from the skin, conjunctiva, lachrymal gland, and from metastases deposited in the choroid.

Sarcoma may develop primarily in the orbit, although in the great majority of cases it is an extension or metastasis from sarcoma of the choroid. All varieties of sarcomata, including **endotheliomata,** have been reported as developing in the orbit. These reports, however, are of small statistic value, owing to the difficulties experienced in accurately differentiating the primary from the secondary growths.

Glioma of the orbit, which histologicly is sarcoma, is always an extension or metastasis from glioma of the retina.

The prognosis from operation in orbital tumors is far more favorable when the tumor is encapsulated than when it is diffuse.

THE LIDS.

The frame of the eyelids consists of condensed fibrous tissue, which forms a plate—the tarsus—situated in the posterior portion of the lid. The inner surface of the lid is lined by the closely adherent *conjunctiva palpebrarum;* the outer surface is covered by very thin skin. Except at the lower margin, where it unites with the tarsus to form the ciliary border of the lid, the skin is quite loosely bound to the other parts by lax areolar tissue, poor in fat, and, therefore, is freely movable. Close contact between the tarsus and skin is attained by fibers from Müller's muscle, which pass through the orbicularis to the skin. Pigmented cells are usually scattered through the skin of the lids, especially at the inner canthus. Mast- and plasma- cells also are present. Between the palpebral conjunctiva and the external skin is the ciliary border or intermarginal seam, limited by an anterior, somewhat rounded and a posterior, quite sharp lid margin. Especially differentiated hairs—the cilia—grow from the anterior free margin of the lid. These hairs, which are very large, are supplied with sebaceous and sweat-glands of correspondingly large size. The sebaceous glands are known as the glands of Zeiss. The sweat-glands, known as the glands of Moll, discharge their secretion into either the hair follicles or ducts of Zeiss's glands. Throughout the substance of the tarsus is a closely set vertic row of greatly elongated sebaceous glands, designated as the Meibomian glands. The openings of these glands are in front of the posterior margin of the lid. The secretion (sebum) of these glands lubricates the ciliary border and thus prevents overflow of the lachrymal fluid. Serous glands similar to the glands of Krause (see Conjunctiva, p. 953) are occasionally found near the upper portion of the tarsus. They are known as Waldeyer's glands.

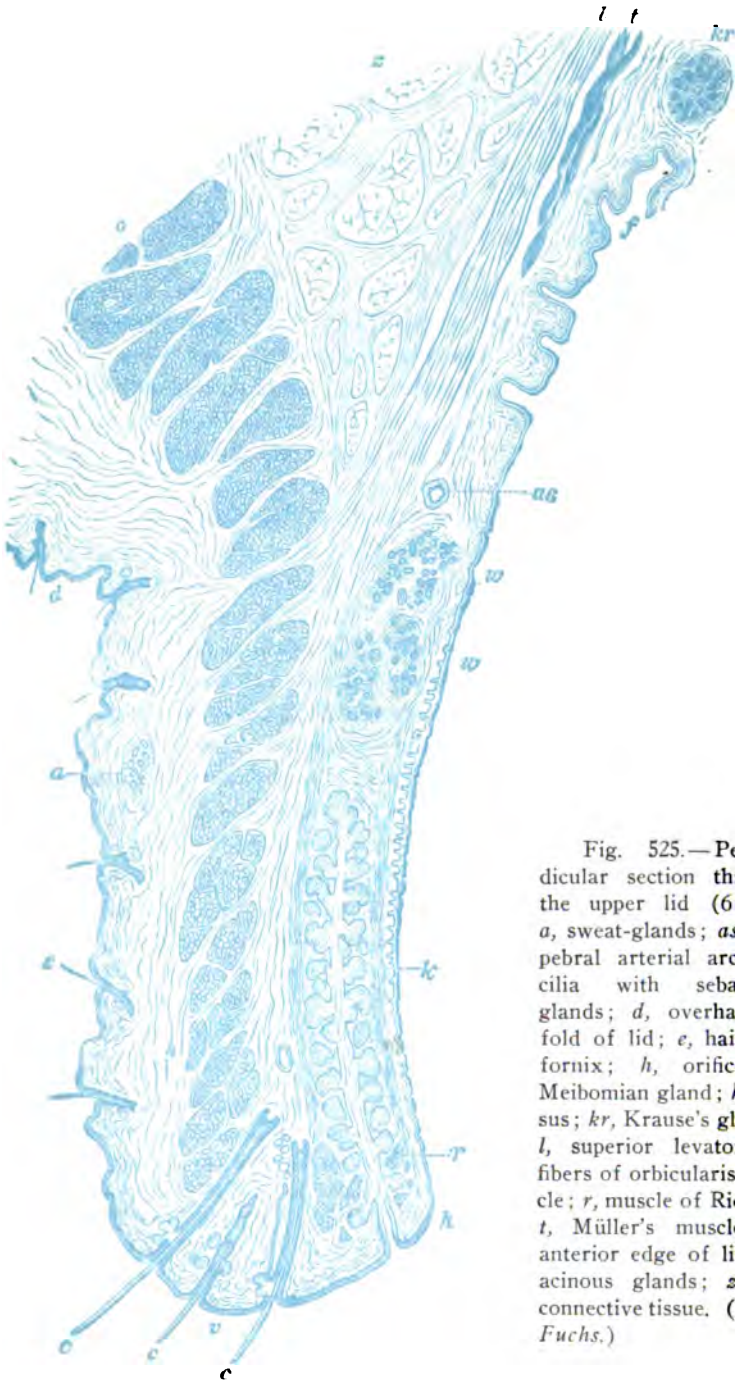

Fig. 525.—Perpendicular section through the upper lid (6 × 1). *a*, sweat-glands; *as*, palpebral arterial arch; *c*, cilia with sebaceous glands; *d*, overhanging fold of lid; *e*, hairs; *f*, fornix; *h*, orifice of Meibomian gland; *k*, tarsus; *kr*, Krause's glands; *l*, superior levator; *o*, fibers of orbicularis muscle; *r*, muscle of Riolani; *t*, Müller's muscle; *v*, anterior edge of lid; *w*, acinous glands; *z*, lax connective tissue. (After *Fuchs.*)

The striped muscles of the lids are the *orbicularis palpebrarum,* which closes them, and the *levator palpebræ superioris,* which lifts the lid. The muscle of Riolan is a narrow strip separated from the inner margin of the orbicularis by the row of cilia. Its fibers inclose the ducts of the Meibomian glands. Bands from the tendons of the superior and inferior recti and inferior oblique muscles are attached to the tarsi, so that the palpebral aperture tends to follow the movements of the eyeball. The unstriped muscles are the superior and inferior muscles of Müller, which are attached to the proximal edges of the tarsi. By the action of this muscle the tarsus and skin of the upper lid are drawn into the upper sulcus when the eyes are opened.

The changes in the external skin of the lids are in general the same as in the rest of the skin. Therefore, only those alterations which in some way are injurious to the eye will be discussed here.

Owing to the loose connection between the skin and tarsus, **edema of the lids** readily results from inflammation or traumatism. It is usually marked in hordeolum and following the sting of insects. It is a secondary manifestation in a great variety of morbid conditions, such as severe conjunctivitis, panophthalmitis, dacryocystitis, suppuration in adjacent sinuses, and in periostitis of the orbit. It appears early in general edema. It results from any local obstruction to the circulation of the blood- or lymph- currents, as in thrombosis of the cavernous sinus, aneurisms of the internal carotid arteries, orbital cellulitis, tumors behind the eyeball, and in the obstinate blepharospasm of phlyctenular keratitis. In connection with the nervous system it appears as recurrent neurotic edema and in exophthalmic goiter, and it is mentioned as a symptom of sympathetic ophthalmitis. It may appear without assignable cause. It is among the symptoms of trichinosis in the orbit and is also a manifestation of arteriosclerosis.

Acute circumscribed edema of the lids. According to Schreiber,[1] all the forms described below, except the purpuric (4) and cyclic (5) form, resemble each other and are due to hypersensitiveness of the stomach or body to certain foods, drugs, or serums acting on an arthritic or nervous constitution: in other words, to anaphylaxis. (See p. 322.) 1. Arthritic edema, which appears as a white edema of sudden onset, affecting chiefly the face and eyelids, and may give rise to ephemeral nodules. 2. A sudden, acute edema of the lids occurring usually in hysteric subjects with alimentary disturbances. 3. Quincke's disease, which is noticed in arthritic adults and often is hereditary. It affects by preference the face and uncovered parts; very often it is associated with gastrointestinal troubles, and may lead to edema of the larynx and necessitate tracheotomy. 4. Purpuric edema, affecting young neuroarthritic subjects, resulting from fatigue or overexertion; associated with purpuric spots upon the lower extremities. 5. Acute cyclic: infectious phenomena with fever, neuralgic pains; observed only in the eyelids. Deviation of the tongue, facial paresis, abolition of tendon-

[1] Arch. d. med. des enfants, April, 1911.

reflexes, lymphocytosis of the cerebrospinal fluid are observed. 6. Serum edema, frequently seen after the use of diphtheria antitoxin, particularly in the lids.

Emphysema of the lids may follow fractures of the orbit communicating with the nasal passages. The normal skin of the adult eyelid does not contain fat, although a certain amount is present in infancy and childhood. In cases of obesity fat may be deposited in the eyelids in such quantity as to be mistaken for lipoma. (See p. 1078.)

In exophthalmic goiter the upper lid does not, as a rule, follow the movement of the eye downward. This is called **Graefe's symptom** and is attributed to spasm of Müller's muscle, which is innervated by the sympathetic. In paralysis of this muscle a pseudoptosis ensues from separation between the skin and tarsus.

Hypertrophy of the lids may be associated with orbital disease. It occurs also in *elephantiasis arabum* and *elephantiasis lymphangioides.* In *elephantiasis neuromatodes,* which occurs in the upper lid, the hypertrophy is excessive, principally upon the conjunctival side, causing great ectropion. In myxedema the lids are always affected. Hypertrophy of the lid may take place in cases the pathology of which is very obscure.

Atrophy of both the white and elastic connective tissue of the lids occurs as a senile change. Cases of extreme atrophy of the lid have been designated as blepharochalasis by Fuchs. The condition follows long-continued or frequently recurring edema. All parts are atrophied, the skin hanging in numerous fine wrinkles. Atrophy and distortion of the tarsus have been described in connection with trachoma. (See p. 961.)

In *herpes zoster frontalis sive ophthalmicus* small, at first clear, later cloudy vesicles develop in the region of the frontal, sometimes of the nasociliary, nerve after violent trigeminal neuralgia accompanied by swelling and redness of the skin, which on healing leave small cicatrices. Almost synchronously, but usually somewhat later, a similar eruption of small groups of water-clear vesicles occurs upon the cornea: *herpes corneæ.* This affection attacks principally elderly persons, especially males.

Eczema appears as *blepharitis ulcerosa.* In children an eczema of the lids (with and without eczema of the face) is not infrequently observed, which in chronic cases, particularly when blepharitis coexists, may cause ectropion by shortening of the lids.

Small, water-clear vesicles, the size of a poppy seed, not infrequently develop upon the ciliary border, which usually disappear after a short time and produce slight symptoms of irritation by pressure upon neighboring parts.

Inflammation of the margins of the lids: blepharitis, in its mildest form is confined to certain portions of the lid margins. These are reddened and covered with scales. The lachrymal secretion is usually increased. In the more intense grades of blepharitis the whole lid is always altered; erosion and even flat ulcerations then develop, especially in the region of the roots of the cilia. Severe forms are complicated with conjunctivitis. Inflammation of the margins of the lid is very often chronic, and, therefore, gradually results in further changes: the cilia fall out (**madarosis**) and are replaced by new, feebler hairs, which almost always grow in an irregular direction; the ciliary margin is rounded and thickened, and the inner edge of the lid gradually disappears. The affection extends over the anterior margin of the lid to the external skin and there causes hyperemia, desquamation, and excoriation. Then the cutaneous surface of the lid becomes harder and begins to shrink, the deeper parts also being involved. The tear puncta are thus directed outward and cease to functionate, so that the lachrymal fluid constantly flows over the inflamed lid margin and the cutaneous surface of the lids (epiphora), thus supporting and even increasing the inflammatory changes. Consequently, the shrinkage becomes more intense, the external edge of the lid, which is still barely recognizable by the few markedly altered cilia, disappears, and the ectropium becomes more and more pronounced. The palpebral fissure can no longer be closed, and corneal affections result. The Meibomian glands are very early involved in the blepharitis and secrete an increased amount of sebaceous material: *seborrhœa s. blepharitis squamosa.* In the severer forms and on long duration, if erosions, ulcerations, and cicatrices have already developed, the ostia of the glands disappear more or less completely, the secretion being diminished or entirely suspended, and the lachrymal fluid, owing to insufficient lubrication of the ciliary border, flows over the edges of the lids.

Hordeolum externum, or **stye,** is a circumscribed, acute, suppurative inflammation of the margin of the lid in the neighborhood of the cilia, which develops from a sebaceous (Zeiss) gland or the root of a hair, forming an intensely red swelling the size of a millet or hemp seed. It is usually due to infection with staphylococci. It either subsides after a short time (disappears by absorption) or goes on to suppuration and opens upon the external edge of the lid. This affection, particularly in the beginning, is usually accompanied by considerable tumefaction of the whole lid. Frequently several styes occur in succession. This is probably due to the fact that every stye contains infectious germs, which easily give rise to metastases or recidives in the immediate neighborhood.

Suppuration of a Meibomian gland is termed *hordeolum internum.*

Moll's glands may become obstructed and form small, translucent granules upon the border of the lids. They may be regarded as miliaria. Proliferation of the walls of these little cysts or of the epithelial lining may produce solid granules. (See Tumors of Lids.)

In erysipelatous and phlegmonous processes the lids, owing to their loose and flaccid structure, are usually markedly involved, so that the palpebral fissure is obliterated by the very intense swelling. Purulent[1] and gangrenous processes sometimes cause large defects of the conjunctiva, in the cicatrization of which shortening of the lid occurs, resulting in lagophthalmos, or ectropion. The same results follow those defects of the skin of the lid caused by external injuries (cauterization, burns, etc.) and by lupus, leprosy, and syphilis.

The term **trichiasis** is employed to designate false direction of the cilia toward the globe. In distichiasis there is a double row of cilia, the inner row situated near the inner edge of the lid and likewise directed toward the globe. Trichiasis and distichiasis frequently follow blepharitis; furthermore, trichiasis exists in every case of entropion.

The false positions of the lids are ectropium, entropium, and ptosis. In ectropium the margin of the lid is lifted from the globe and the palpebral conjunctiva more or less removed from the *conjunctiva bulbi*. This defective position is always acquired and is due either to affection of the lids with shortening of the integument of the lid,[2] inflammation of the palpebral conjunctiva,[3] tumors of the orbit, spasmodic contraction of the orbicularis in very intense synchronous swelling of the palpebral conjunctiva (*ectropium spasticum*), or, finally, to paralysis or weakness of the orbicularis (*ectropium paralyticum, senile*).

The exactly opposite position of the lids, namely, inversion of the lid margin, is called entropium. This is the result either of cicatricial contraction of the palpebral conjunctiva and tarsus after trachoma (*entropium cicatriccum*) or of spasmodic contraction of the orbicularis in violent inflammatory irritations, or when the integument of the lid—as in old people—is very lax and folded (*entropium senile* or *spasticum*). Entropium is always associated with false position of the cilia (trichiasis).

Ptosis,[4] incomplete elevation of the upper lid, may be congenital (*ptosis congenita*) or acquired. Ptosis is acquired as the result of chronic conjunctivitis with swelling and thickening of the upper lid, adhesions of the conjunctival surfaces (symblepharon), injury of the *levator palpebræ* muscle, and oculomotor disturbance.

[1] Phlegmon, abscess, furuncle, anthrax pustule.
[2] Chronic blepharitis; scars after burns, cauterization, etc.
[3] Acute and chronic purulent conjunctivitis.
[4] πίπτω = to fall, drop.

Congenital ptosis is due to defective action of the *levator palpebræ* muscle or to congenital redundance of skin, which hangs down over the margin of the lid.

Coloboma palpebræ (palpebral fissure) is either congenital (usually associated with other anomalies) or acquired through injury.

Of the **tumors** observed in the lids, those especially worthy of mention are chalazion and xanthelasma. Furthermore, retention tumors, warts, angioma, lipoma, atheroma, dermoid cysts, epithelioma, sarcoma, enchondroma, and elephantiasis occur.

The Meibomian glands are particularly subject to a chronic disease called **chalazion,** which results in the development of a granuloma histologicly closely resembling tubercle. Numerous giant cells of the true Langhans type are always present. That it is not true tubercle is evident from its benign course. Furthermore, tubercle cannot be produced by inoculation with chalazion material, neither have tubercle bacilli been found in the growths. A great variety of micro-organisms has been found in chalazion, the most frequent being the xerosis bacillus. None, however, has been accepted as causative.

Small retention tumors containing fat and infiltrated with cholesterin and sometimes lime develop as the result of retention of the secretion of the Meibomian glands. When these retention tumors cause inflammation of adjacent structures, so-called *chalazion acutum*—a circumscribed purulent inflammation—may develop.

Xanthelasma palpebrarum, or *fibroma lipomatodes* (Virchow), is a flat, elevated, yellowish growth which forms upon the external surface of the lid in elderly persons. It develops as the result of proliferation of the connective tissue and subsequent fatty metamorphosis.[1]

Papillomata are frequent upon the lids, especially in old age. When very hard, they may form horns: *cornu cutaneum.*

Fibromata occur upon the lids as soft, vascular growths. Cases reported as myxomata probably were edematous fibromata. The small, pearly white sebaceous tumors, known as milium, are very frequent on the lids. The ordinary sebaceous cysts of the skin occur here as in other parts. True retention cysts of the Meibomian glands have seldom been observed. In addition to the small cysts of Moll's glands already described, Waldeyer has reported a case in which these glands were the seat of a papillary cystadenoma.

Adenomata have been reported as having developed in all the glands connected with the eyelid. Adenoma of a Meibomian gland may attain the size of a hen-egg (Panse).

---

[1] From the fact that the nuclei of the fat-cells found in xanthelasma stain well, it is inferred that the fat is an infiltration rather than a degeneration.

The congenital tumors—nevi, dermoids, etc.—may be found in the lids. Among other growths occurring here may be mentioned lymphoma, lymphangioma, and hemangioma.

Malignant tumors are not uncommon upon the lids. Carcinoma of the skin in this region may present the features of either squamous-celled epithelioma or rodent ulcer, more frequently the latter. Adenocarcinoma may develop in any of the glands connected with the lids, particularly the glands of Krause and the Meibomian glands. Sarcoma of the lids is uncommon; nevertheless, all varieties of this neoplasm, including the endotheliomata, may occur. They may originate from any of the connective-tissue parts, and also from nevi. Extension of the growth from contiguous parts is more common than primary sarcoma of the lid.

Molluscum contagiosum is common on the lids. When it occurs in children's asylums, a large proportion of the inmates usually are affected. The microscopic appearance is striking and characteristic, consisting of wedge-shaped lobules separated by fibrous septa. The lobules consist of an outer layer of columnar epithelium and inner layers of rounded epithelium in various stages of the peculiar degenerative process which characterizes these tumors, the result being the formation of rounded, homogeneous masses: molluscum bodies. The character of the degeneration is doubtful. The material resembles keratin (white) more than hyaloid or colloid matter. The degeneration occurs in the prickle cells of the rete mucosa. The disease appears to be contagious; nevertheless, no specific organism has been demonstrated. (See p. 950.)

Ringworm and **favus** occasionally appear in this locality. Blepharitis may be caused by the presence in the hair-follicles of the *Demodex folliculorum.*

Lice are sometimes found among the cilia (*Phthiriasis palpebrarum*). The parasite is nearly always the crab-louse (*Pediculus pubis*), very rarely the head-louse (*Pediculus capitis*).

Canities, or bleaching of the cilia, may take place in leucoderma and sympathetic ophthalmia.

Syphilis of the lids may appear as the initial lesion or in the tertiary form. Chancre, which occurs at the ciliary margin, probably always originates in the conjunctiva. In the tertiary form—*tarsitis syphilitica*—the lid is greatly enlarged. Microscopicly, the vessels are highly degenerated and the tarsal tissue replaced by round-celled deposits resembling granulation tissue. Fragmentation of nuclei is pronounced. The connective tissue which forms readily undergoes hyaloid and calcareous degeneration.

ORGANS OF HEARING.

Anatomicly considered, the organs of hearing are divisible into three portions: the **external, middle,** and **internal** ear. The latter portion comprises the membranous labyrinth, inclusive of the surrounding bones; the middle portion includes the tympanic cavity, the air-containing spaces of the mastoid process, and the Eustachian tube; the external portion includes the drum membrane (tympanum), the external auditory canal (meatus), and the auricle.

THE EXTERNAL EAR.

THE auricle consists in great part of elastic cartilage, and, like the external auditory canal, is lined with skin. The pathologic changes involve most frequently the skin,[1] seldom the perichondrium[2] and the cartilage itself. Therefore, in order to avoid repetition, previous chapters in which the changes observed in these tissues are discussed may be referred to.

Among the tumors of the auricle are to be mentioned, first of all, othematoma[3] and fibroma. The latter not infrequently develops from the cicatricial tissue formed as a result of piercing the lobe of the ear (for earrings).

The tympanum is formed of a dense, fibrous membrane, which is composed of two layers: an external layer, in which the fibrous tissue has a radiate arrangement (directed from the tendinous ring toward the handle [manubrium] of the malleus), and an external layer, in which the fibers have a circular arrangement. This fibrous membrane on the external surface—*i.e.,* that portion directed toward the external auditory canal—is covered with cutis (but without papillæ) and epidermis; on the internal surface it is covered with a very thin layer of mucous membrane and a single layer of squamous epithelium.

As a rule, the pathologic alterations of the drum membrane are secondary in nature, *i.e.,* they follow either changes of the external auditory canal or affections of the middle ear. Independent primary affections are almost exclusively referable to trauma; primary inflammation of

[1] The most frequent alterations are eczema, erysipelas, furuncles, and phlegmons. With few exceptions, all furuncles are situated at the entrance of the auditory meatus.

[2] Perichondritis of the auricle develops as a result of trauma, in connection with cutaneous affections, etc.

[3] See p. 213.

the tympanum: myringitis,[1] from other causes (usually a "cold" is asserted as a cause) is rarely observed.

All affections of the external auditory canal, in which the external surface of the drum membrane is always more or less involved in the same manner, are designated tersely as **external otitis.** In general, these processes may be classed with cutaneous affections. Therefore, only those conditions will be briefly referred to here which develop in connection with foreign bodies which have entered or been forced into the external auditory canal and are generally classed with the traumatic form of external otitis,[2] and those in which fungous accumulations[3] are met in the external auditory canal: *otitis externa mycotica.* According to the course are distinguished an acute and a chronic form. Recurrent chronic inflammations kept up by fungous accumulations usually are accompanied by marked degeneration of the epithelium: desquamative catarrh, "keratosis." In other cases there is more or less profuse exudation: otorrhea,[4] which is sometimes watery, sometimes purulent, in character. The skin of the external auditory meatus itself is swollen, infiltrated with numerous young round cells; as a rule, the epithelium is preserved, but it may be thrown off in part or even extensively, resulting in excoriations.

This should not be confused with the deeper purulent inflammations, which, if they are circumscribed, form a furuncle, and when diffuse possess a more phlegmonous character. The furuncles originate most frequently from purulent inflammation of a hair-follicle.

Since the membranous covering lies close to the bone, and also takes the place of the periosteum, the deeper purulent affections occurring in the bony portion of the external auditory canal are periostitic processes which, on destruction of the periosteum, lead to bone necrosis. If the upper wall of the bony canal is altered in this manner, the process may extend to the dura mater.

In consequence of frequent recidives of external otitis (especially the furunculous form) and after chronic eczema of the auricle, the skin of the external cartilaginous portion is more and more thickened, so that a more or less pronounced narrowing (stenosis) of the auditory canal or of the meatus occurs. On contact and adhesion of apposed excoriated or ulcerated surfaces, complete occlusion (atresia) may develop. In involvement of the periosteum, bony

[1] μυριγξ = membrane.

[2] Trauma may be due to a puncture, shot, gash; in intense traction on the auricle, deep lacerations in the external auditory canal are sometimes observed.

[3] *Aspergillus fumigatus, niger,* and *flavescens; Mucor corymbifer, septatus; Penicillium minimum, Oïdium albicans,* and others.

[4] Compare otorrhea after otitis media.

narrowing or occlusion, instead of connective-tissue stenosis or atresia, may occur as a result of progressive ossifying periostitis. The external auditory canal may be more or less narrowed also by cicatricial formation following trauma, by polypous proliferation of the soft parts of the external auditory canal, and by exostoses of the bony portion. Narrowing is rarely observed as a congenital malady—then usually in addition to other malformations.

Polypi of the external auditory canal usually develop in connection with chronic otorrhea. In contradistinction to polypi of the middle ear, they are always covered with squamous epithelium.

In acute, purulent processes in the external auditory canal and in the middle ear, ulcerations of the tympanum (*myringitis ulcerosa*), which generally result in perforation, develop with extraordinary frequency. If an external otitis was originally present, the inflammatory process, after perforation, generally extends to the middle ear; on the other hand, if a purulent inflammation of the middle ear was the primary affection, the drum membrane formed no sharp line of demarkation even before perforation; on the contrary, the deeper portions of the soft parts of the external auditory canal are usually quite early involved in the process.

The ulcerative perforations of the tympanic membrane, which may be very variable in extent, are generally characterized, like pure traumatic perforations, by a marked tendency to heal, the tympanic membrane being extraordinarily capable of regeneration. Distinctly visible scars usually remain; cicatrization is subsequently unrecognizable by the naked eye only when the perforation was insignificant. Traumatic perforations consist of rents (fissures), which frequently run parallel with the handle of the malleus. They develop in fracture of the skull (especially at the base), on blow upon the ear with the fist or flat of the hand, as a result of explosions, in whooping-cough, through the action of foreign bodies (sounds, penholders, knitting-needles, etc.). Here, as a rule, a small extravasation of blood occurs, which, after a time, is absorbed; rarely, fracture of the manubrium is observed.

In chronic processes in the external auditory canal and in the middle ear, thickening of the tympanic membrane is observed as a result of proliferation: chronic proliferative myringitis. In this case the external surface is dull and hazy. In the course of this chronic myringitis partial resolution through fatty metamorphosis, and not infrequently also calcification, occur.[1] True ossification is of very rare occurrence.

[1] Partial calcifications are found also within the cicatricial tissue after ulceration and traumatic perforation.

Thinning of the tympanic membrane as a result of atrophy is a rare phenomenon, which is due either to accumulation of exudate in the middle ear or to shortening of the tendon of the tensor tympani muscle and the abnormal tension of the tympanic membrane thus caused. In the first case the tympanic membrane bulges outward; in the second case there is abnormal retraction. Partial thinning of the tympanic membrane is more frequently observed; it is due to scar formation after ulceration and perforation, and creates a certain disposition to rupture.

Thus far, tuberculous and gummatous processes (*myringitis tuberculosa, gummosa*) have very rarely been observed in the tympanic membrane itself.

Of the tumors of the external ear, the small polypi of the external auditory canal have already been discussed. Still to be mentioned are telangiectases (*angioma simplex*) and epithelioma of the external ear, which are tumors of more frequent occurrence.[1]

THE MIDDLE EAR.

As in other mucous surfaces covered with cylindric epithelium, inflammations of the mucous membrane of the middle ear are associated with catarrh, namely, the secretion of a liquid exudate, which in the mild cases is thin, more watery or mucoid, and in severe cases purulent or sanguinopurulent, in character. The milder inflammations generally develop in connection with catarrhal affections of the nasopharynx and are observed with great frequency in very small children during the first year of life. In many cases the change may be traced through the Eustachian tube into the middle ear. This form of inflammation, which either disappears after a short time (without serious results) or creates a certain disposition to recidives, is generally designated as "simple, acute catarrh of the middle ear (*otitis media catarrhalis simplex*)."

In contrast to this form stands the far more important purulent form called purulent otitis media, or, tersely: otitis media. This is the most important affection of the whole auditory organ, in so far as it not only occurs very frequently, but also causes severe disturbances of the middle ear and the neighboring parts, and not infrequently results in death by extension to the meninges and the brain. The mucous membrane of the middle ear is intensely swollen, dark red, and more or less covered with pus. The mastoid cells, which freely communicate with the tympanic cavity and have the same mucous membrane lining as the latter, are almost always involved in the changes in the same manner as the tympanic cavity.

[1] Othematoma, p. 213; osteoma, p. 235.

Purulent inflammation of the middle ear may occur as an independent affection. As a rule, however, it is the result of extension from the nose, nasopharynx, or oral cavity, and may follow almost all acute and subacute (seldom chronic) processes of these surfaces. It occurs very frequently in small children, and is a very frequent manifestation in measles.

The sequelæ of chronic, recurrent, simple and acute, purulent inflammations of the middle ear are very variable; almost all produce more or less decided interference of function.

In the purulent form, perforation of the tympanic membrane occurs early in most cases (not in all) as a result of ulceration advancing from within outward. Perforation is sometimes prevented by thickening of the drum membrane as a result of antecedent chronic inflammation, which renders it more resistant. In many cases perforation is followed by spontaneous healing at the point of perforation, the purulent catarrh disappearing after discharge of the exudate. In other cases regeneration does not occur, because the perforation is too large, or parts of the perforated drum membrane are agglutinated and adherent to the labyrinth wall, or the long limb of the incus, or the head of the stapes, etc. The remaining portions of the tympanic membrane then usually become thickened and sometimes also calcified. Suppuration may cease or continue with open perforation; in the latter case there is a permanent purulent discharge from the ear: chronic purulent otitis media with otorrhea. If the suppuration ceases in non-healed perforation, frequent recidives usually occur, since new noxæ easily enter the middle ear from without through the external auditory canal.

In chronic purulent and recurrent simple otitis media, small, polypous excrescences covered with cylindric or ciliated epithelium: *otitis media chronica prolifera polyposa,* sometimes develop as a result of hyperplasia of the mucous membrane. If the swelling of the mucous membrane is very intense and the apposed surfaces are in contact, firm, flat or band-like adhesions may occur: *otitis media adhæsiva.* In the flat adhesions, which are observed chiefly in the course of purulent otitis media, small cysts (*otitis media adhæsiva cystica*) frequently develop in the form of fissures and spaces, since small areas between the apposed and adherent surfaces do not take part in the adhesion. These cysts are lined with cylindric or ciliated epithelium. The adhesions may cause firm (immovable) fixation of the auditory ossicles: ankylosis, as well as false position: luxation. The same influence is exerted upon the ossicles by another sequela of recurrent (chronic) simple catarrh of the middle ear, namely, so-called "sclerosis" of otologists. This consists in gradual, progressive shrinkage of the mucous membrane, an interstitial indurative process (*otitis media chronica indurativa, sclerotica*).

This form of chronic otitis media is often followed by changes in the bone, leading, as a result of chronic periostitis, to the formation of hyperostoses and less frequently to very small exostoses. The point of predilection of these changes is the region of the window; the niches of the fenestra are thus narrowed, and the base of the stapes is firmly fixed: stapes ankylosis. This process is usually a true synostosis, seldomer a calcareous deposition in the annular ligament or a proliferation of the cartilaginous covering.

In inflammation of the tympanic mucous membrane the **Eustachian tube** is almost always involved, at least in its bony portion. The mucous membrane is swollen, the cells are increased in number, and a catarrhal exudate is secreted. In the same manner, though by far more frequently, the tube is affected in connection with acute catarrhal affections of the nasopharynx. In most cases the exudate is mucous, seldom purulent or fibrinous (in variola, scarlatina, diphtheria, etc.), in character. Every swelling of the tubal mucous membrane, as well as every adhesive exudate, produces narrowing or complete occlusion of the tube. The *ostium pharyngeum tubæ* is very frequently narrowed also by hyperplasia of the tonsils and of the other follicles in the mucous membrane of the nasopharynx. All these narrowings act injuriously upon the middle ear by hindering the circulation of air through the tube, thus leading to variations in pressure in the tympanic cavity, which may give rise to further disturbances (hyperemia, etc.). On the other hand, catarrhal affections of the tube are favored and supported also by narrowings of the tube.

Diphtheria of the tube is a rare manifestation, and always follows a like change in the nasopharynx. Specific inflammations—gummous, tuberculous, variolous, etc.—are observed at the *ostium pharyngeum tubæ* (rarer in the course of the tube) without the middle ear always being involved. In healing after ulcerations dilation as well as narrowing or occlusion of the *ostium pharyngeum* may develop as the result of retraction due to cicatrization. The same changes have been observed also in consequence of shrinkage after hyperplasia of the follicular apparatus. In rare cases annular strictures (*e.g.*, in syphilis) have been observed within the tube.

In chronic suppuration of the middle ear with perforation of the drum, when the discharge is not arrested by appropriate treatment, tuberculosis should be suspected.

The pathologic changes of the bony parts have in part already been mentioned. In general, they belong with the processes described in the chapter on the bones, to which reference may be made. However, attention must be called to certain changes, because they are of especial importance. Here belong **exostoses** of the external auditory

canal. These are due to irritative disturbance of the normal development of bone and originate by excessive proliferation in localities which advance to ossification. They are flat, rarely pedunculated, mostly flat-rounded upon the surface, generally ivory-hard, rarely spongy. The point of predilection is the posterior walls, where the bony part of the external auditory canal joins the cartilaginous portion. They develop very gradually, are rare in youth, occurring mostly in advanced age, and often upon both sides. Sometimes they are hereditary. Virchow has drawn attention to the frequent occurrence of these exostoses in the ancient Peruvians.

In purulent processes of the middle ear after measles, scarlatina, diphtheria, typhoid, scrofula, tuberculosis, diabetes, etc., especially in the chronic form, caries, rarer necrosis of the bony parts, often develops, chiefly of the auditory ossicles (handle of the malleus, head of the malleus and incus, rarer of the base of the stapes); next of the mastoid cells and of the spongy substance of the mastoid process, of the posterior upper auricular wall, and of the *tegmentum tympani*. Firm, compact bony parts, *e.g.*, of the labyrinth, usually break down, or, what is more frequently observed, sequestrate *in toto* only in chronic suppuration. All carious processes in the ear are characterized by their great tendency to putrid decomposition; they do not occur until the mucous membrane of the tympanic cavity—the deeper layers of which also form the periosteum—is destroyed by deep, purulent, ulcerative processes and the bone, therefore, is laid bare.

In a comparatively large percentage of those cases in which the mastoid cells are involved in the caries, concentricly arranged lamellæ of hornified epidermis cells are found within them, regarding the origin and significance of which opinions are greatly at variance. Virchow is of the opinion that these lamellated epidermis cells in the mastoid cells always belong to a **margaritoma** (see p. 281), and that caries of the mastoid process is due to the growth of this tumor, and, therefore, is a secondary phenomenon. In opposition to Virchow a number of otologists (von Tröltsch and others) believe that the hornified epidermis cells originate by metaplasia from the cylindric epithelial cells which are present, these being transformed into flat epithelial cells under the action—pressure—of the purulent exudate. Others (Habermann, Politzer, Bezold, and others) are of the opinion that, after perforation of the drum membrane, the epidermis of the external auditory canal grows into the tympanic cavity and further in the mastoid cells, and the desquamated hornified cells remain there and accumulate.

In suppuration and caries of the tympanic cavity and mastoid process, destruction may be so extensive that rupture externally or internally

occurs. Perforation externally occurs either at the external surface of the mastoid process or in the region of the *fissura mastoidea squamosa,* rarer at the apex or on the inner surface of the mastoid process.[1] Perforation internally may occur in two localities: either in the region of the middle cranial fossa, at the anterior superior, or in the region of the posterior cranial fossa, at the posterior superior surface of the petrous portion of the temporal bone. In the first case either purulent or putrid arachnitis or abscess of the temporal lobe results; in the second case either purulent or putrid thrombophlebitis of the transverse sinus or cerebellar abscess develops. In most cases the dura manifests only very slight alterations (inconsiderable thickening, slight deviation in color, little exudate); in very rare cases a purulent inflammation of the external, periosteal surface of the dura—so-called extradural abscess—develops.

Meningitis following suppurative otitis is generally due to the *Diplococcus intracellularis* and *pneumoniæ* and the *Streptococcus pyogenes* and *mucosus.* Mixed infection occurs in about 20 per cent. The inflammation is more or less diffuse, the exudate rarely, if ever, being limited to the convexity; in a few cases it occupies the base exclusively, and it often is found uniformly distributed over the base and focally on the convexity. The process affects both the brain and spinal cord, infiltration of the pial spaces being particularly abundant in the sulci, especially in the region of the causative focus. While the exudate may be serous or serofibrinous, in the majority of cases it is serofibrinopurulent with large numbers of polymorphonuclear leucocytes and a limited number of macrophages.

Haymann[2] reports the anatomic findings in experimentally produced **acute suppurative otitis media,** embodying 73 experiments upon 14 animals (guinea-pigs). The infectious materials employed were the various pyogenic agents: staphylococci, streptococci, diplococci, diphtheria and pyocyaneus bacilli, and, for purpose of definite comparison, a series of other bacteria. The experiments gave an abundance of noteworthy findings of which several are emphasized, accompanied by corresponding microscopic preparations.

The inflammatory process sometimes spread irregularly: in addition to severely altered, intact or almost unaltered areas of mucosa were found. In relatively similar, almost identic, middle-ear inflammations the tympanum may present entirely different appearances: in relatively slight middle-ear alterations it may be markedly altered—*e.g.,* thickened—and in severe processes present slight alterations, even when rupture into the labyrinth coexists. In the experiment animals large tympanic perforations, which otherwise occur only in definite middle-ear suppurations, were observed, and also marginal perforations. Involvement of the ossicles in affection of the mucosa covering them was manifest, particularly in the new formation of bone, which finally led to fixation to the adjacent bony margins by new-formed osseous nodes.

Disintegration of bone at the cell walls occurred chiefly under the form of softening by resorbing connective tissue. This was the case also in large per-

[1] Gravitation or congestive abscess in the neck sometimes follows.
[2] Der Kinderarzt, Sept., 1911, p. 196.

forations which permitted outflow of pus. In those caused by *Streptococcus mucosus* peculiar osseous destructive processes were observed. In a number of cases rupture occurred into the labyrinth through both windows, but especially through the round window. In the labyrinth the most varied stadia of the inflammatory processes were found. States from the initial stage up to complete filling of the interior of the labyrinth with bone and connective tissue were observed. There were great differences in regard to locality and time distribution of the inflammatory process in the labyrinth.

For extension of the inflammatory process from the labyrinth to the meninges are to be considered especially the acoustic, then both aqueducts. In marked purulent labyrinthine alterations the aquæductus cochleæ is often found free, probably because adhesions formed early. In one case a typic saccus empyema was observed, which, owing to its purity, is possibly of especial importance for the whole question. Definite differences could be noted also in the anatomic picture of the different media produced by various exciters.

In advanced age carious processes of the petrous portion of the temporal bone are often favored by osteoporous, progressive marrow-space formation of the compact bone.

In chronic processes of the periosteum, especially also in the course of chronic otitis media, progressive sclerosis of the mastoid process sometimes occurs.

THE INTERNAL EAR.

As there are but few exhaustive and reliable observations upon the changes occurring in the internal ear, it is difficult to offer a satisfactory description of the pathologic processes. The best observations are upon hemorrhages into the internal ear[1] (ecchymoses and large blood extravasates) in trauma (with and without fracture or fissure of the osseous parts); in acute infectious diseases, leukemia, pernicious anemia, etc.,[2] and upon the secondary inflammatory processes occurring in connection with meningitis, otitis media, diphtheria, measles, mumps, and the pyemic processes (*e.g.*, osteomyelitis). Only in rare and, as it appears, not wholly unassailable cases has a primary *otitis interna* been said to exist.

Meningitic processes appear to extend in the course of the acoustic nerve and through the *aquæductus cochleæ* into the labyrinth.

The alterations of the internal ear which thus far have accurately been observed consist in suppuration: purulent exudate (fill-

[1] Experimentally produced in dogs and rabbits by large doses of quinine and salicylic acid.

[2] A hemorrhagic exudate in the vestibule and the semicircular canals (without further changes) was first observed by Ménière in a young girl who, after a severe cold contracted during menstruation, under symptoms of dizziness and vomiting, suddenly became deaf and died on the fifth day (Ménière's symptom-complex).

ing of the spaces and canals with pus), purulent destruction of the soft parts, and caries and necrosis of the osseous parts (the cochlea, etc.), already mentioned. In chronic course of *otitis interna,* new connective-tissue masses, adhesions, osteophytes, and hyperostoses (of the cochlea and semicircular canals), and atrophy of the nerves develop. The latter change (atrophy of the nerves) has been observed also in acute inflammations and in *tabes dorsalis.*

Grünberg[1] found *Spirochæta pallida* in sections of the petrous bone in a fetus of 7 months. The spirochætæ were present in enormous numbers in the trunk of the cochlearis and vestibule, in the facialis, in the nerve trunks of the tympanic plexus in the tympanic cavity, in the internal carotid plexus, etc.; also in the wall or neighborhood of the vascular branches of the middle ear and in the medulla of the ossicles. On the other hand, there were no spirochætæ in the region of the vessels and nerve-endings of the internal ear, nor in the labyrinthine cavities.

[1] Der Kinderarzt, xxii, H. 9, 1911, p. 195.

INDEX.

Abdomen, air in, 786; clefts of, 198; malformations of, 187, 188, 189, 198, 199; dropsy of, 464, 780, 779; parasites of, 786; tumors of, 786.
Abdominal pregnancy, 895, 896.
Abnormal position of intestine, 206, 769.
Abortion, 893, 894.
Abrachius, 188.
Abrasions, 949.
Abrin poisoning, 316.
Abrus precatorius poisoning, 316.
Abscess, 173, 181, 719; bone, 926; burrowing, 173; cerebellar, 1095; cerebral, 436, 500, 501, 599, 1095; cold, 447; congestion, 173, 479; corneal, 981, 984, 993; corporis cavernosi, 876; Dubois's, 700; embolic, 729; encapsulated, 181; extradural, 1095; follicular, 760; gravitation, 173, 479, 480; hepatic, 178, 181, 501, 795, 798, 799, 806; of lung, 181, 501, 542, 719, 729, 735; Metastatic, 92, 93, 181, 719, 729; muscle, 501, 936; myocardial, 181, 501, 634; orbital, 1074; prevertebral, 479; pulmonary, 181, 501, 542, 719, 729, 735; renal, 181, 827, 828; retrobulbar, 1074, 1077; retropharyngeal, 758; retrotracheal, 716; ring, of cornea, 993; scleral, 104; testicular, 868; thymus, 700; tonsillar, 757; vitreous, 1013.
Abscessus vasorum, 651, 652.
Absorption, 104, 118; of fat, 118; of nutriments, 3, 104.
Acanthia lectularia, 352.
Acardiacus, 186.
Acarina, 352.
Acarus folliculorum, 352, 353.
Accidens, 5.
Accommodation, act of, 1028.
Acephalus, 187.
Acetabulum, atrophy of, after luxation, 120.
Acetic acid poisoning, 318.
Acetoacetic acid, 343.
Acetonemia, 343.
Acetonuria, 343.
Achelia, 188.
Acholia, 753, 804.
Achorion schönleinii, 418.
Achroöcystosis, 814.
Acid, acetic, 318; acetoacetic, 343; arsenious, hemorrhage from, 60, 328; carbolic, poisoning by, 319; carbonic, poisoning by, 314; diacetic, 343; fatty, crystals of, 129; helvellic, poisoning by, 315, 336; hydrochloric, poisoning by, 318; oxalic, poisoning by, 319; prussic, poisoning by, 314; succinic, in echinococcus cyst, 385; sulphuric, poisoning by, 318; uric, infarcts of, 845; valerianic, in gangrene, 126.
Acid intoxication, 699.
Acidophile cells, 779.
Acidosis, 340.
Acids, biliary, 135.
Acne, 884, 945; of cervix uteri, 884; indurata, 946; rosacea, 945.
Aconite poisoning, 332.
Acormus, 187.
Acrania, 187.
Acromegaly, 201, 1054; optic neuritis in, 1054.
Actinomycosis, 425, 483, 981.
Actio, 4.
Activity hypertrophy, 110.
Adaptation, of tissue, 108.
Addisonian anemia, 678.
Addison's disease, 131, 137, 344, 478, 621, 942.
Adenocarcinoma, 284, 307, 775; gastric, 775; intestinal, 775; mammary, 295; uterine, 297, 298, 897 (see also Carcinoma).
Adenoma, 307, 775, 972; conjunctival, 972; destruens, 307; gastric, 775; intestinal, 775; mammary, 218, 221, 222.
Adenosarcoma, 251.
Adermia, 187.
Adhesions, 162, 180; tubercle in, 466.
pericardial, 180, 465, 624.
peritoneal, 180, 462.
pleuritic, 180, 465, 735.
Adipose tissue, brown atrophy of, 114; hypertrophy of, 107, 111.
Adipositas, 107, 156.
Adolescents, nephritis in, 824.
Adrenals, hyperplasia of, 619; structure of, 619.
Adrenalin, 345, 619.
Aërobes, 426; facultative, 426.
Affluxus, 54, 120; in menstruation, 39, 67.
Agaricus muscarius poisoning, 315, 335, 336.
Agchylostoma duodenale, 60, 367, 864.
Agglutination, 21, 517.
Agglutinins, 25.
Agglutinophore, 26.
Aggressins, 31, 175.
Aglossia, 188.
Agnathia, 187.
Air, anastasis of, 52; embolism, 84; in abdomen, 786; in blood, 84, 685.
Akamushi mite, 354.
Albinism, 131.
Albu, 401.
Albumin, in dropsic fluids, 95, 96.
Albuminuria, 45, 98, 825, 826; cyclic, 825, 826; lordotic, 826; orthostatic, 825, 826; physiologic, 825; transitory, 825.
Alcohol poisoning, 332.
Alcoholic fermentation, 423.
Alcoholism, 332, 796.
Aleukemic myelosis, 252.
Alexins, 20.
Alkali albuminates, 151.
Alkalies, cauterization from, 127, 316.
Alkaloids, cadaveric, 338; vegetable, 337.
Allergin, 322.
Allergy, 322.
Alopecia, 419, 952; senile, 952.
Alpine scurvy, 576.
Alterations, quantitative, 4.
Alveolar endothelioma, 304.
exostosis, 238.
sarcoma, 247, 971.
Amanita bulbosa, poisoning by, 336.
cæsarea, 335.
muscaria, 335.
phalloides, 315, 336.
Amaurosis, 91, 1066.
Amaurotic family idiocy, 1066.
Amboceptor, 22, 321.
Amelus, 188.
Amenorrhea, epistaxis in, 61.
American typhus, 586.
Amitosis, 402.
Ammonia, formation of, in moist gangrene, 125; poisoning by, 319, 340.
Ammonemia, 340.
Amnion, adhesion of, 186, 197.
Amœba coli, 392; dysenteriæ, 393, 529; histolytica, 393.

Amorphus, 186.
acardiacus, 186.
Amphigony, 401, 404, 405.
Amphistomum hominis, 371.
Amputation callus, 905.
neuromata, 261, 618.
Amyelia, 188.
Amygdalitis, 255, 757; apostematosa, 758; fibrinous, 756; fibrous, 758; gangrenous, 757; interstitial, 757; parenchymatous, 757; phlegmonous, 757.
Amyl nitrate poisoning, 315.
Amyloid degeneration, 37, 46, 49, 75, 144, 545, 657; of blood-vessels, 657; of intestine, 778; of kidneys, 848; of liver, 799; of lymph-glands, 697; conjunctival, 146, 968; in ecchondroses, 229; in tumors, 146; of pancreas, 811; reaction, 144, 148; of spleen, 693; of suprarenals, 620.
Amyotrophic lateral sclerosis, 606.
Anaërobes, 426; facultative, 426.
Anal fistula, 766.
Anaphylatoxin, 322, 324.
Anaphylaxis, 32, 322, 324, 942, 1082; antitoxin, 324; echinococcus, 324; eosinophilia in, 664; familial, 322; inherited, 322; passive, 322.
Anaplasia, 108.
Anasarca, 96, 780, 946.
Anastasis, 52, 84.
Anastomosis, terminal, 87.
Anchylostomum duodenale, 367.
Anemia, 46; acute, 47, 68; Addisonian, 678; aplastic, 680; arterial, 50; atrophy from, 51, 113; brickmakers', 367; cerebral, 608; chronic, 47, 69, 684; Egyptian, 367; essential, 678; gangrene from, 124; general, 47; in atelectasis, 704; local, 47, 86; local, in embolism, 86; miners', 367; organic, 46; passive, 47; pernicious, 48, 679; pseudoleukemic, 673; spastic, 46, 49; simple primary, 677; simple secondary, 678; splenic, 673, 680; tonic, 46; trophic, 367; tunnel, 367; venous, 50 (see also Ischemia).
Anencephalia, 188, 621.
Anesthesia, 333; from embolism, 92.
Anesthetics, poisoning from, 333.
Aneurisms, 34, 59, 79, 553, 596, 608, 633, 646, 653, 657, 658, 659; arachnoidal, 596; arteriovenosum, 267; cardiac, 633, 646; carotid, 1083; cirsoid, 268; dessecting, 59, 653, 659; cerebral, 596, 608; embolic, 92; formation of, 34, 92; miliary, of brain, 596, 608; per anastomosin, 267, 659; racemose, 268; sinus Valsalvæ, 649; serpentine, 268; spurium, 267, 659; thrombosis in, 75, 77, 78, 79, 633, 646; valvular, 648.
Angina, 523, 525; catarrhal, 255, 757; diphtheritic, 128, 523; gangrenous, 523; lacunar, 757; Ludwig's, 813; malignant, 523; putrid, 523; scorbutic, 523; scrofulous, 448; spirochetobacillary, 529; tonsillar, 757; ulceromembranous, 529; Vincent's, 529, 573.
Angioma, 262, 263; anastomoticum, 267; auricular, 263; buccal, 263; cavernous, 262; cerebral, 266; conjunctival, 971; cutaneous, 263; false, 267; diffuse, 263; external, 263; fissural, of face, 263; glandular, 264; hepatic, 800; internal, 263, 800; iris, 1026; labial, 263; lipogenous, 263; muscular, 264; of central nervous system, 266; osseous, 264; palpebral, 263; phlebogenous, 264; racemose, 267; retroauricular, 263; simplex, 264; spuria, 267; subcutaneous, 263; telangiectatic, 264; varicose, 34.
Angiofibroma, 1079.
Angiomyoma, 257.
Angiosarcoma, 266, 304.
Angle, filtration, of eye, 1017, 1047, 1049.
Anguilluia intestinalis, 370.
Anhydremia, 683.
Aniline poisoning, 315.
Animal parasites, 348.
Aniridia, 1027.
Anisocoria, 1019.
Anisocytosis, 675.
Anisohyperleucocytosis, 669.
Anisohypoleucocytosis, 669.
Ankylosis, 105, 109, 156, 480, 933; atrophy of muscles in, 105, 113, 156; bony, 993; of aural ossicles, 1093; cartilaginous, 933; false, 932; fibrous, 930, 933; pseudo-, 932; after tuberculosis, 480; stapes, 1093.
Ankylostomum duodenale, 60, 367.
Anlage, pathologic, 6.
Anomalies, simple, 186.
Anopheles, argyrotarsus, 401; barbirostis, 401; bifurcatus, 401; claviger, 401; costalis, 401; culicifacis, 401; funestus, 401; Lutzii, 401; maculipennis, 401; paludis, 401; quadrimaculata, 401; rossi, 401; sinensis, 401; superpictus, 401; pseudopictus, 401; theobaldi, 401.
Anophelinæ, 401.
Anorchia, 189.
Antagonism, corporeal, 430, 431; bacterial, 32.
Anteflexion, uterine, 889; from myoma, 260.
Anterior poliomyelitis, 601.
Anteversion, uterine, 889.
Anthracosis, 138, 709.
Anthrax, 488; symptomatic, 126.
Antianaphylaxis, 323.
Antibody, 21, 322, 432.
Antigen, 21, 322.
Antitoxin, 24; anaphylaxis from, 324; poisoning, 325.
Antivenene, Calmette's, 320.
Antrum, of Highmore, catarrh of, 712.
Anuria, 69, 316, 507.
Anus, atresia of, 199; carcinoma of, 775; fistula of, 766; malformations of, 190, 192, 196, 199, 200; noma of, 128, 753; prolapse of, 772; varices of, 65, 265.
Aorta, aneurism of, 59, 193, 646, 656, 659; angusta, 650; atheroma of, 59; calcification of, 655; fatty metamorphosis of, 119, 653; hypoplasia of, 193; incontinence of, ostium of, 656; primitive, 190; size of, 651; stenosis of, 635, 641.
Aortic valves, 59, 646, 656, 659; incontinence of, 656.
Aphakia, 1012.
Aphasia, from embolism, 91.
Aphonia, from syphilis, 548.
Aphthæ, 421.
Apoplexy, 69, 610; anemic, 69, 610; cerebral, 596, 610; cordis, 610; embolic, 610; hemorrhagic, 69, 610; hyperemic, 610; nervous, 610; pulmonary, 727; sanguinea, 69, 133, 610; serous, 103, 608, 610.
Appendices epiploicæ, lipoma of, 226.
Appendicitis, 485, 761, 782; actinomycotic, 485; chronic, 761; ulcerative, 761.
Appendix, vermiform, absence of, 784; carcinoma of, 776; catarrh of, 761; dropsy of, 215, 755, 785; empyema of, 755; inflammation of, 485, 755, 761, 782; inversion of, 784; perforation of, 761, 782; sarcoma of, 777; ulceration of, 761, 782.
Applanatio corneæ, 998.
Apron, Hottentot, 901.
Aprosopus, 187.
Aptera, 349.
Apus, 188.
Apyrexia, 183, 502.
Aqua herniosa, 780.
Arachnitis, 466, 540, 593, 594, 595; cerebrospinal, 594; fibrinopurulent, 540, 594; fibrous, 594; gummous, 554; ossificans, 594; profunda, 595; purulent, 540; tuberculous, 466; verrucous, 594.

Arachnoid, angioma of, 266; carcinoma of, 616; cholesteatoma of, 283, 616; cysticercus of, 349, 381, 616; edema of, 98, 197, 593; lipoma of, 226, 616; melanoma of, 240, 616; osteoma of, 239; Pacchionian bodies of, 220, 594; pearl tumor of, 281, 616; syphilis of, 554; tubercle of, 466, 616.
Arachnoidea, 352.
Arcus senilis, 119, 978; juvenile, 979.
Argentum nitricum poisoning, 7, 94, 139, 685, 845, 970, 997.
Argyl-Robertson pupil, 1019.
Argyria, 7, 94, 139, 685, 845, 970, 997; corneal, 997; conjunctival, 970.
Arneth theory of leucocytosis, 668.
Arrosion, of vessels, 55, 56, 67.
Arsenic poisoning, 60, 328.
Arsenicism, chronic, 328.
Arsenious acid, hemorrhage from, 60.
Arseniureted hydrogen poisoning, 133, 675, 844.
Arteria recti, of kidney, 818.
Arterial anemia, 50.
Arteriectasis, 34, 657.
Arteries, amyloid degeneration of, 146, 657; calcification of, 140, 141, 142, 655; end, 88; inflammation of, 651; hypoplasia of, 193, 678; ossification of, 141; terminal, 88.
Arteritis, 651; purulent, 76, 81, 651.
Arteriocapillary fibrosis, 636.
Arteriomesenteric occlusion, duodenal, 772.
Arteriosclerosis, 33, 46, 59, 83, 110, 127, 130, 140, 142, 431, 596, 634, 636, 762, 1063; cardiac hypertrophy in, 110, 634; causes of, 762; congestion from, 42; thrombosis from, 74; cerebral, 596; gangrene from, 127, 130, 656; general, retina in, 1063; syphilitic, 431.
Arthralgia, lead, 327.
Arthritis, adhesive, 930, 931; deformans, 108, 230, 232, 929; fibrinous, 930; fungous, 480; caseous, 480; gonorrheal, 497, 931; hemorrhagic, 930; hydrofibrinous, 930; multiple, 930; nodosa, 237; pauperum, 929; purulent, 501, 931; rheumatic, 930, 931; rubeolar, 931; scarlatinal, 931; serous, 931; tuberculous, 480; urica, 143, 343.
Arthrocace, 480.
Arthroliths, 226, 230, 232.
Arthropoda, 349.
Arthrospores, 426.
Asbestoid degeneration, 928.
Ascaridea, 357.
Ascaris lumbricoides, 357.
Ascites, 96, 98, 100, 101, 779, 780; chylous, 779, 780; inflammatory, 100, 779, 780; lymphatic, 780; sequelæ of, 101, 102, 103; tuberculous, 464.
Asiatic cholera, 505.
Aspergillus flavus, 417.
fumigatus, 417, 996; in hypopyon, 996.
niger, 418, 996.
Aspermia, syphilitic, 552.
Asphyxia, 69, 314, 708.
Aspiration, death from, 314; pneumonia, 129, 290, 299, 314, 607, 719, 732.
Assimilation, 3, 104.
Asthenia, 705.
Asthma, 201, 256, 699, 714, 715, 716, 749; bronchial, 714; Charcot-Leyden crystals in, 715; eosinophilia in, 716; thymicum, 201, 256, 699, 746.
Astomia, 200.
Asturian leprosy, 576.
Atavism, 11, 205.
Ataxia, locomotor, 604.
Atelectasis, 101, 178, 704, 734; acquired, 101, 178, 704, 734; compression, 69, 101, 178, 704, 734; congenital, 704; edema in, 704; from hematothorax, 69; red, 178, 704, 705.
Atheroma, 59, 944; aortic, 59, 83, 113, 655; cutis, 118, 215, 944; vascular, 59.
Atheromatous cysts, 118, 1078.
Atheromatous ulcer, 655, 993.
Athletes' heart, 637; tobacco, 335.
Atlas, luxation of, 601; spina bifida of, 197.
Atony, vascular, 34.
Attenuation, 432.
Atresia, 199; ani, 188, 199, 200; of aortic orifice, 190; cordis congenita, 190; of external auditory meatus, 200, 1089; of eyelids, 188; of Fallopian tubes, 119; of hymen, 200; of intestine, 199; of nose, 188, 199; oris, 188, 200; of os uteri, 887; of pulmonary orifice, 190; of pylorus, 199, 774; of urethra, 119, 188; of ureters, 199; of uterus, 119, 878, 879; of vagina, 199, 200; of vulva, 200.
Atria mortis, 123.
Atrium of disease, 6.
Atrixia, 11.
Atrophia fusca, 115.
lævis, 122, 177, 496, 548.
simplex, 113, 114, 116.
Atrophy, 51, 105, 113, 122, 158, 181, 327, 796, 824, 831; amyloid, 147, 148; anemic, 51, 113; brown, 114, 115, 116, 138, 626, 693; cardiac, 626; causes of, 113; from chemic substances, 121; compression, 121; corneal, 122, 979; cyanotic, 45, 122, 790; from dropsy, 101, 113; embolic, 87; etiology of, 113; of female genitalia, 120, 177, 901; functional, 113; ganglionic, 115, 603; granular, 121, 122, 158, 181, 327, 796, 824, 831; hepatic, 122, 790; inactivity, 120; inanition, 113, 116; iodine, 121; lacing, 791; lead poisoning, 121, 327; mammary, 120; marantic, 121; muscular, 107, 114, 603, 938; necrobiotic, 51, 105, 113, 116, 627; neurotic, 122, 603, 618; nutritional, 113; organic, 121; of parietal bone, 121; physiologic, 119; pigment, 113, 114, 122; pressure, 121; progressive muscular, 603, 938; red, 122; renal, 834; retinal, 1065; senile, 121, 603, 952; simple, 113, 114, 116; smooth, 122, 177, 496, 548; spinal, 603; splenic, 693; from deficient stimulation, 113; thymus, 106; toxic, 121; of vagina, 177; vulvar, 901; yellow acute, 791.
Atropine, conjunctivitis from, 1019; mydriasis from, 1019; poisoning by, 334.
Attraction theory, 71.
Auchmeromyia luteola, 350.
Auricle, angioma of, 263; defects of, 190; fibroma of, 1088; hematoma of, 213, 1088; tophi of, 143; tumors of, 213, 1088.
Autointoxication, 339, 346; gastrointestinal, 346.
Autolysis, 538.
Autosite, 203.
Axial torsion, of intestine, 201, 769, 770, 771.
stream, in inflammation, 164.
Axis, luxation of, 601.

Bacilli, 423; carriers, 433, 516, 528, 603.
Bacillus, aërogenes capsulatus, 571; anthrax, 488; botulinus, 339; chancroid, 875; colon, 519, 571, 782, 956; comma, 425, 505; Ducrey, 875; dysenteriæ, 520; enteritidis, 339, 518; Friedlaender's, 533; fluorescens, 981; fusiformis, 530, 572; glanders, 491; influenza, 522, 956; Klebs-Loeffler, 528, 954, 963; Koch-Weeks's, 955, 963; leprosy, 530; malignant edema, 573; mallei, 491; Morax-Axenfeld, 991; paratyphoid, 339, 515; phlegmonis emphysematosæ, 571; plague, 498; pneumoniæ, 956; proteus, 571; pyocyaneus, 956, 981; Shiga-Kruse, 520, 569; tetanus, 492; tuberculosis, 438; typhoid, 507; Unna-Ducrey, 875; Vincent's, 530, 572; xerosis, 956.
Bacon spleen, 148, 693.
Bacteria, 423; aërobic, 426; anaërobic, 426; arthrospore, 426; distribution of, in body, 430; facultative, 426; fission of, 425; motility of, 425; multiplication of.

Bacteria (*concluded*).
425; non-pathogenic, 427; pathogenic, 427, 429, 434; purpurin, 424; putrefactive, 125; pyogenic, 498; specific, 434.
Bacteriolysis, 21, 26.
Bacteriopurin, 424.
Bacterium coli, 519, 571, 782, 783, 956.
lactis aërogenes, 520.
Balanitis, 874.
Balanoposthitis, 874; adhesive, 874; catarrhal, 874; ulcerative, 874.
Balantidium coli, 414, 777.
Banti's disease, 680.
Barbers' itch, 419.
Barlow-Moeller's disease, 63, 976.
Bartholinitis, 879.
Basedow's disease, 340, 741; blood in, 744; iodine, 743.
Basidia, 416.
Basilar meningitis, tuberculous, 439, 467.
Bedbug, 352.
Bee stings, 320.
Beer drinkers' heart, 637.
Belladonna poisoning, 334.
Benzol molecule, 22.
Beriberi, 581; acute, 585; etiology of, 585; pernicious, 585.
Berlin blue reaction, 132.
Bertini, columns of, 816.
Bile, 94, 689, 803; in blood, 94, 689, 803; pleiochromatic, 135.
Bile-ducts, carcinoma of, 299; catarrh of, 805; concretions of, 805.
Bilharzia hæmatobia, 60, 375, 864.
Biliousness, 762.
Bilirubin, crystals of, 132, 135, 693, 805; infarcts, 135.
Biliverdin, 136, 805.
Biochemic factors in immunity, 19.
Birds, tuberculosis in, 438.
Birth marks, 131, 264.
Bites of poisonous reptiles, 124, 127; wounds from, 124, 127.
Biting flies, 395.
Bitter almond oil poisoning, 314.
Black death, 497.
Blackheads, 944.
Black leg, 126.
Black vomit, 586, 587.
Black-water fever, 133, 407, 676.
Bladder, gall-, carcinoma of, 299.
urinary, carcinoma of, 298, 863; catarrh of, 177, 828, 853, 863; defect of, 189; dilation of, 858; diphtheria of, 828, 854, 855; diverticula of, 859; fibroma of, 220, 863, 864; fissures of, 196, 198, 297; fistula of, 863, 888; hemorrhage from, 68, 823, 853; hemorrhoids of, 854; hypertrophy of, 110, 858; malformations of, 189, 198, 206; parasites of, 864; phlegmon of, 854; stone in, 144, 828, 855, 856, 857; syncytioma of, 899; thrombosis of, 854; tuberculosis of, 474, 859; tumors of, 863, 864; ulceration of, 854.
Blastoma, renal, 852.
Blastomycetes, 423.
Blastomycosis, 423.
Bleeders, 62, 684.
Bleeding; see Hemorrhage.
Blennorrhea, 495, 853, 874, 931, 955, 962, 975; conjunctival, 962; gonorrheal, 495, 853, 874, 931; of lachrymal sac, 975; neonatorum, 955, 962.
Blepharitis, 1083, 1084.
Blepharochalasis, 1083.
Blindness, 1, 91; from embolism, 91.
Blood, air in, 84, 685; amount of, 661; in Basedow's disease, 744; bile in, 94, 689, 803; coagula as emboli, 82; coagulation, stages of, 70, 73, 682; corpuscles of, 661; constitution of, 661; distribution of, after death, 51; dust, 663; fat in, 83, 684; foreign substances in, 684; in urine, 68,
Blood (*concluded*).
823; human, transfusion of, 321; leucocytes of, 661; lime in, 685; megaloblasts of, 675; megalocytes of, 675; menstrual, 67, 892; microcytes of, 675; moles, 894; normoblasts of, 675; normocytes of, 675; parasites in, 60, 686; pigments, 70, 132, 686; plasma, 682; platelets, 76, 662; poikilocytes of, 675; poisons, 312, 681; post-mortem coagulation of, 74; red cells of, 674; silver-salts in, 685; spitting of, 458; stagnation, 71; stasis, 71; tumor, 68, 212; uric acid in, 684.
Blood-current, axial, in inflammation, 164.
reversal of, 83.
Blood-forming organs, tumors of, 253.
Blood-pressure, 36, 37; capillary, 58; increased, as cause of hemorrhage, 57; relative, increase of, 59.
Blood-vessels, alteration of walls of, in hemorrhage, 59; atony of, 34; dilation of, 34, 41; paralysis of, 34; action of poisons on, 59; syphilis of, 553; tonus of, 34.
Blue disease, 44, 649, 683.
Body, antidotal, 22, 321; fluids, proteid percentage of, 98; intermediate, 27; protective mechanism of, 15.
Boil, 947; oriental, 397.
Bone, abscess of, 926; absorption of, 902; angioma of, 264; capsule, 238; carcinoma of, 302; cyst, 238; "drill," 239; enchondroma of, 233; "exercise," 142, 239; fracture of, 905; growth of, 106; myoma of, 228; necrosis of, 123, 926; "riders," 142, 239; sesamoid, 239; spongioid, 904; syphilis of, 545; tuberculosis of, 479; tumors of, 228, 233, 253, 934.
Bone-marrow, colloid, 902; degeneration of, 107; red, 902; tumor of, 253; yellow, 902.
Bottom yeast, 423.
Botulin, 339.
Botulism, 339; bacillus of, 339.
Boucardia, 633.
Bow-legs, 915.
Bowman, capsule of, 816; membrane, 977, 996.
Brachycephalus, 924.
Brachycera, 350.
Bradycardia, 630.
Brain, abscess of, 599, 1095; anemia of, 608; aneurism of, 596; edema of, 608; glioma of, 616; gliosarcoma of, 616; hemorrhage of, 608; psammoma of, 240; red softening of, 611; sand, 616; sarcoma of, 250; sclerosis of, 604; softening of, 611; syphilis of, 554; telangiectasis of, 611; tuberculosis of, 469, 616; vascularity of, 608; weight of, 597; white softening of, 613; yellow softening of, 613.
Break-bone fever, 521.
Breast gland, carcinoma of, 295; colloid carcinoma of, 295, 296; fibroma of, 218, 221, 222; involution of, 119; myxoma of, 229; papilloma of, 221; tuberculosis of, 477.
Bright's disease, 565 (see also Nephritis).
Bromine poisoning, 316.
Bronchi, carcinoma of, 117, 300, 736; catarrh of, 177, 453, 712; chondroma of, 737; endothelioma of, 736; dilation of, 724, 725; polypi of, 737; supernumerary, 205; tuberculosis of, 452.
Bronchiectasis, 43, 724, 725, 726; congenital, 726; cystic, 215.
Bronchitis, acute, 45, 314, 522, 539, 561, 712; caseous, 453; catarrhal, 177, 453, 561, 712; croupous, 714; cyanotic, 45; ether, 333; fibrinous, 539, 714; fibrous, 720; gummatous, 555; hemorrhagic, 63; influenzal, 522; malleolosa, 491; membranous, 523, 525, 713; obliterating, 177, 453; papillary, 714, 717, 737; in poisoning, 314, 316, 319, 320; purulent, 177, 453, 712; putrid, 129, 179, 725, 732; syphilitic, 555; tuberculous, 452; variolar, 560.

Bronchocele, 738, 740, 742, 1083.
Bronchopneumonia, 314, 522, 540, 717, 719; apostematosa, 719; catarrhal, 177, 319, 712; fibrinous, 523, 525, 539, 714; fibrinocatarrhal, 319, 454; nodosa, 719; resolution stage of, 719.
Bronzed skin, 137, 478.
Brood capsules, echinococcic, 385, 386.
Brown atrophy, 114, 138; of adipose tissue, 114; of ganglion cells, 115; of liver, 114; of myocardium, 626; of spleen, 693.
Brownian molecular movement, 425.
Bruch's membrane, 1018, 1033.
Brücke's muscle, 1028.
Brush molds, 415.
Buboes, 498, 545, 549, 696, 875; plague, 498; in soft chancre, 874; syphilitic, 549.
Bubonic plague, 497; bacillus of, 497.
Pudding fungi, 423.
"Buffy coat," 53, 74.
Bufidin poisoning, 320.
Buhl's disease, 677.
Bulbar paralysis, acute, 611; progressive, 122, 603.
Bullæ, 948.
Buphthalmus, 1051.
Burdach, columns of, 606.
Burgundy nose, 945.
Burns, 8, 128, 844, 949.
Bursa, preosseous, 215, 938.
Bursitis, 938; tuberculous, 478.

Cachectic hydrops, 99.
Cachexia, 41, 114; in tumors, 211; malarial, 407; miners', 367; strumipriva, 345; thymopriva, 699; thyreopriva, 345.
Cadaverin, 338.
Caisson disease, 7, 84.
Calabar-bean poisoning, 337.
Calcification, 139; cardiac, 631; pulmonary, 140.
Calculi, cutaneous, 944; cystin, 858; hepatic, 807; intestinal, 143; pancreatic, 140, 143, 812; pigment, 808; preputial, 875; prostatic, 140, 143, 873; pulmonary, 140, 143, 737; renal, 140, 847, 854; salivary, 143, 814; spermatic, 869; tonsillar, 757; uterine, 142; venous, 80, 140, 873; vesical, 144, 855.
Callosity, 223, 952.
Callus, 160, 905, 906; externus, 160, 906; fibrous, 160, 694, 781, 905, 906; internus, 160, 906; luxurians, 160, 239, 906; myelogenous, 906; osseous, 160, 905, 906; peritonei, 781; spongioid, 906.
Calmette, antivenene of, 320; reaction, 439.
Calor, 170.
Canal, auditory, exostoses of, 1093; polypi of, 1090; stenosis of, 1089; suppuration of, 1090.
hyaloid, of vitreous, 1012.
lachrymal, 974.
Petit's, 1005.
Schlemm's, 1017.
Canalization, of thrombi, 80.
Cancer, definition of, 271; aquaticus, 128, 753; atrophic, 277; cachexia in, 211; chimney-sweepers', 273, 281; clay-pipe smokers', 273; milk, 274; paraffin workers', 273, 281; retrahens, 277; smokers', 273; villous, 277, 863 (see also Carcinoma).
Cancroid epithelioma, 279; pearls, 280.
Canine madness, 569.
Canites, of eyelids, 1087.
Cantharidin poisoning, 316, 320.
Capillaries, dilation of, 264, 611, 704, 1046; embolism of, 87, 93; formation of, 161; hyperemia of, 35; stasis in, 71.
Capillary hyperemia, 35.
Capsula sequestralis, 927.
Capsule, Glisson's, 789; Tenon's, 1073.
Capsules, suprarenal, hyperplasia of, 619; Capsules, structure of, 619; tuberculosis of, 478; tumors of, 850 (see also Suprarenal Glands).
Caput medusæ, 79, 797.
obstipum musculare, 937.
succedaneum, 212.
Carbolic acid poisoning, 316, 319, 844.
Carbon dioxide poisoning, 314.
monoxide poisoning, 314.
Carbonic acid poisoning, 314.
Carbonization, 949.
Carbuncle, 128, 489, 498, 947; anthrax, 488; plague, 497.
Carcinoma, 268; appendix, 776; alveolar, 285; alveoli of, 269; atrophic, 277; bile-duct, 299; bladder, 298, 863; bone, 302; branchiogenous, 278; breast, 295, 296; bronchial, 300; cachexia, 211; cauliflora, 227, 863; cell-nests of, 269; cells, character of, 289; colloid, 285; conjunctival, 872; contact, 209; cutaneous, 280; cylindric-celled, 284; cystic, 298; definition of, 271; dissemination of, 288; endothelial, 304; epidermoidal, 279; esophageal, 290; etiology of, 272; extension of, 288; fat-granule cells in, 117; gall-bladder, 299; gastric, 291, 768, 775, 776; gelatinous, 285; glandular, 284, 300; hemorrhage in, 291; hepatic, 301, 800; intestinal, 286, 295; kidney, 300, 850; laryngeal, 300; location of, 287; lung, 300; malignancy of, 287; mammary, 295, 298; medullary, 269; metastasis in, 288; myxadeno-, 300; ovarian, 298, 883; papillary, 277, 863; pharyngeal, 290; prostatic, 302, 873; psammo-, 290; pulmonary, 117, 300, 736; pyloric, 775; retracting, 277; salivary gland, 300; sarcomatodes, 247, 852; scirrhous, 277; of serous membranes, 303; smooth, 277; squamous-celled, 278; stomach, 291, 768, 775, 776; stroma of, 268; testicular, 301; thyroidal, 302; tracheal, 302; transitional-celled, 277, 285; uterine, 297, 298, 897; vaginal, 298; villous, 277, 863.
Caries, dental, 238, 430, 448; purulent, 926; sicca, 546; tuberculous, 479, 480, 917; vertebral, 479, 480, 917.
Carionecrosis, 328, 480, 926.
Carnification, pulmonary, 178, 540, 722.
Caro luxurians, 180.
Cartilage, articular, ecchondrosis of, 230; asbestoid degeneration of, 928; calcification of, 928; fracture of, 906; erosion of, 927; hyaline, fibrous degeneration of, 108; laryngeal, ossification of, 723; petrification of, 928.
Cartilaginification, 140.
Caruncle, 954; adenocarcinoma of, 972.
Caseation, 124; of tubercle, 443.
Casein, 749.
Casts, renal, 158, 837.
Cataract, 1006; anterior polar, 1009; black, 1007; capsular, 1010; central, 1007; complicated, 1008; congenital, 1009; coralliform, 1009; cortic, 1008; cystic, 1007; diabetic, 1008; dura, 1006; fusiform, 1009; glassblowers', 1010; glaucomatous, 1050; green, 1047; hard, 1006; hyaloid, 1011; hypermature, 1006, 1007; incipiens, 1006; intumescens, 1006; juvenile, 1009; lactea, 1006; lamellar, 1009; mature, 1006; membranous, 1006; mollis, 1006; Morgagnian, 1007; nigra, 1007; posterior polar, 1010; punctate, 1007; secondary, 1010; senile, 1007; soft, 1006; spindle, 1009; toxic, 1008; traumatic, 1008.
Catarrh, autumnal, 760; bronchial, 177, 453, 561, 712; colonic, 751; conjunctival, 954, 956; desquamative, 752; duodenal, 750; follicular, 759; gastric, 749; mucous, 712; nasal, 712; pollen, 760; urethral, 496; uterine, 855; vaginal, 877, 878; vesical, 854, 863.

Causa externa, 6, 7; interna, 6, 8; morborum, 8, 210; occasionalis, 210; predisponentes, 8, 210.
Caustic poisons, 316; gangrene from, 127.
ulcer, 317.
Cauterization, 7, 72, 124, 316.
gangrene from, 124, 127.
hemorrhage from, 55, 60.
stasis in, 72.
Caverna bronchiectatica, 725; ulcerosa, 456.
Cavernitis, 876.
Cavernous sinus, thrombosis of, 1077.
Cecum, mobile, 761.
Cells, adventitial, in inflammation, 166; carcinoma, character of, 289; division of, 159; epithelioid, 167; fat-granule, 117; function of, 104; giant, 167, 436; granular, 117; granulation, 166; leucocytoid, 167; lymphoblastic, 167; multinucleated, 168; plasma, 167; syncytial, 437; wandering, 167.
Cellulitis, periphalangeal, 946.
Cement exostoses, 238.
Central nervous system, angioma of, 266; glioma of, 243, 616; myxoma of, 228.
Cephalhematoma, 212.
Ceratophyllus fasciatus, 395.
Cercomonas hominis, 394.
intestinalis, 394.
Cerebellum, abscess of, 1095.
Cerebral abscess, 1095.
nerves, glioma of, 242.
Cerebrospinal meningitis, epidemic, 568.
Cerebrum spurium, 197 (see also Brain).
Cervix uteri, acne of, 884; atresia of, 879; carcinoma of, 297, 897; dilation of, 879; erosion of, 878; polypi of, 884.
Cestodes, 337.
Chain cocci, 424.
Chalazion, 1086.
Chalicosis, 132, 138, 679, 709.
Chancre, of eyelids, 1087; hard, 545, 547; soft, 874; sporotrichotic, 487.
Chancroid, 874, 968; bacillus of, 875; conjunctival, 968.
Charbon, 488; symptomatique, 126.
Charcot-Leyden crystals, 671; in asthma, 715.
Cheese poisoning, 337.
Cheilognathopalatoschisis, 197.
Chemic factors in immunity, 19, 50.
Chemosis, 1080.
Chemotaxis, 28, 174, 670; negative, 28; positive, 28, 670.
Chicken breast, 914.
Chicken-pox, 560.
Chigger, 354.
Chilblains, 946.
Childhood, cataract in, 1009; glaucoma of, 989.
Children, cataract in, 1009; colon bacillus infection in, 783, 784; convulsions in, 783, 784; glaucoma in, 989; malaria in, 407, 411; nephritis in, 824; tuberculosis in, 439, 467; tuberculous meningitis in, 467.
Chill stage of fever, 182.
Chimney-sweepers' cancer, 273, 281.
Chloasma, 131, 137; alum, 131; uterine, 137.
Chloral hydrate poisoning, 332.
Chlorine poisoning, 316.
Chloroform poisoning, 332, 333.
Chloromyeloma, 253.
Chlorosis, 48, 61, 677, 763; anomalies in, 193; hemorrhage in, 62, 611.
Choked disk, 1052.
Cholangitis, 805.
Cholecystitis, 516, 525, 805, 806, 808; catarrhal, 805; diphtheritic, 525; typhoid, 516.
Cholelithiasis, 299, 807.
Cholemia, 94, 340, 347, 686, 803.
Cholera, Asiatic, 505; infantum, 568; morbus, 568; nostras, 435, 568, 751.
Cholesteatoma, 281, 282.
Cholesterin crystals, 118, 385, 817, 866, 1014; in echinococcus, 385; in fatty degeneration, 118.
Cholesterin stones, 807.
Cholin, 341.
Chondritis fœtalis, 915.
Chondrocarcinoma, 232.
Chondroma, 229, 232, 234; osteoid, 232, 234; sarcomatous, 234.
Chondrosarcoma, 234.
Chorioretinitis, syphilitic, 1014.
Choroid, anatomy of, 1033; angioma of, 1046; carcinoma of, 1042; dermoids of, 1046; drusen of, 1046; leprosy of, 1046; melanosarcoma of, 248; neuroma of, 1046; osteoma of, 1045; perithelioma of, 1041; pseudotubercle of, 1033; sarcoma of, 1037; syphilis of, 1014, 1037; telangiectasis of, 1046; tubercle of, 1045.
Choroiditis, 1000, 1034; areolar, 1034; diffuse, 1034; disseminate, 1034, 1037; hyperplastic, 1037; metastatic, 1036; nodular, 1036, 1038; ossificans, 1045; suppurative, 1035; sympathetic, 1038; syphilitic, 1014, 1037; tuberculous, 468, 1045.
Choroidoretinitis, 1014, 1034, 1065.
Chromaffin systems, 345.
Chromatophores, 137, 1040.
Chromatophroma, 241.
Chyle retention, 155, 506, 759.
Chylemia, 684.
Chylification, 759.
Chylorrhagia, 780.
Chyluria, 60, 358.
Chyme resorption, disturbance of, 114, 149.
Cicatrices, cerebral, 70, 133, 611, 613; stellate, of syphilis, 547, 548, 556; typhoid, 512.
Cicatrix, cystoid, 982.
Cicatrization, 70, 133, 180, 181, 512, 547, 548, 556, 611, 613.
Cilia, bacterial, 425; of mold spores, 415.
Ciliary body, 1027; adenoma of, 1031; atrophy of, 1030; carcinoma of, 1031; cysts of, 1032; degenerations of, 1029; glioma of, 1030; gumma of, 1030; leprosy of, 1030; perithelioma of, 306; sarcoma of, 1031, 1040; senile degeneration of, 1032; staphyloma of, 1000, 1004, 1050; tubercle of, 1030; tumors of, 1031.
Cimex lectularius, 342.
Circle, arterial, of iris, 1016.
of Willis, 595; embolism of, 86, 596.
of Zinn, 1005, 1011, 1016.
Circulatory disturbances, atrophy from, 113; gangrene from, 124; from struma, 739.
Cirrhosis of liver, 44, 45, 47, 58, 98, 181, 691, 796, 797; hemorrhage from, 58.
Cirrus, of tapeworm, 378.
Cladothrix, 425; actinomyces, 483.
Clavus, 223, 952.
Clefts, abdominal, 198; bladder, 198; cranial, 197; intestinal, 199; of jaw, 197; of lips, 197; of palate, 197; of skull, 197; spinal, 197; thoracic, 198.
Climacteric, hemorrhage at, 54.
Clitoris, hyperplasia of, 201; malformations of, 199, 201.
Cloacæ formations, 196, 199.
Clots, 53, 73; organization of, 80; post-mortem, 53; varieties of, 53 (see also Thrombus).
Cloudy swelling, 39, 44, 154; in congestion, 44; in hyperemia, 39.
Club-foot, 200, 921.
hand, 200.
Coagula, 53, 73, 682 (see also Thrombus).
Coagulation, 53, 70, 73, 682 (see also Thrombosis).
necrosis, 124, 443.
Coagulin, 73.
Coagulum, 53, 70, 73, 682; organization of, 70 (see also Thrombus).
Cocaine poisoning, 334; effect of, on eye, 1020.
Coccidia, 397.
Coccidium, bigeminum, 398; cuniculi, 398; hominis, 398; oviforme, 398.

Coccyx, tumors of, 262.
Cochlea, necrosis of, 1097.
Cockgrass poisoning, 337.
Coefficient, urotoxic, 343.
Cohnheim's theory of carcinoma, 273.
Colchicum poisoning, 336.
Cold, effects of, 8, 50, 949.
Cold abscess, 447.
Coldness, in congestion, 44; in fever, 182.
Colds, 576.
Colic, mucous, 751.
Collemia, 520, 783, 784.
Colitis, 134, 176, 178, 256, 326, 508, 520, 526, 751, 764; catarrhal, 178, 751; cystic, 178, 764; diphtheritic, 326, 528; fibrinous, 178, 756; follicular, 751; hemorrhagic, 393, 520, 526; membranous, 751; from mercury poisoning, 326; mucous, 751; pigmentary, 134, 756; polypous, 256, 763; purulent, 177; typhosa, 508.
Collapse, cardiac, 629; temperature, 183.
Collateral circulation, 36, 40; hyperemia, 36.
Colloid carcinoma, 285, 293.
degeneration, 139, 151.
Coloboma, 1004; of choroid, 1027; of iris, 1026; of lens, 1012; palpebral, 1086.
Colon bacillus, 519, 571, 782, 783, 784, 956; in children, 783, 784; in conjunctivitis, 956; in convulsions, 783, 784.
Colon, hemorrhage of, 393, 520, 526, 755 (see also Colitis).
Colotyphus, 508.
Colpitis, acute purulent, 878; catarrhal, 878; chronic, 878; diphtheritic, 887; granular, 878; emphysematous, 571; lævis, 496, 878.
Columella, 416.
Columnæ renales, 816.
Columns, of Burdach, 606; of Goll, 605; posterior, of spinal cord, 605.
Coma, 344, 347, 699; diabetic, 344; thymicum, 699.
Combustion, 28, 128, 949.
Comedones, 215, 353, 944.
Comma bacillus, 425, 505.
Commotio cerebri, 7, 612.
Communicability, 433.
Complement, 26, 321, 322; fixation of, 321.
Complementophore, 27.
Complication, 5, 183.
Compression, retention cysts from, 215; of vessels, 36, 40, 47, 75.
atelectasis, 69, 101, 178, 704, 734.
myelitis, 600.
Conception, alteration caused by, 34, 54, 111, 112, 137; node, of malarial parasite, 403.
Conceptional infection, 428.
Concrements, 137, 151, 740, 805, 968.
Concretions, biliary, 137, 805; colloid, in goiter, 740; conjunctival, 968; renal, 140, 151, 847, 854; salivary, 143, 814; spermatic, 869; tonsillar, 757; uterine, 142; venous, 80, 140, 873; vesical, 144, 828, 855, 856, 857.
Condensation, of coagulum, 70.
Condyloma, 221, 223, 547, 879; acuminate, 223, 879; follicular, 221; latum, 547; subcutaneum, 221.
Congelation, 28, 128, 949.
Congestion, 40, 44, 45, 51, 98, 122, 710, 791; abscess, 173, 479; atrophy in, 45; causes of, 40; cyanosis in, 44; dropsy in, 45, 98; edema from, 98; frigidity in, 44; functional disturbances in, 45; general, 40; heat in, 40; hemorrhage in, 45, 57; hypostatic, 42, 51; induration in, 45; liver in, 44, 122, 791; local, 40; lungs in, 43, 710; passive, 98; secondary phenomena of, 44; symptoms of, 44; thrombosis in, 45; venous, 35.
Conglomerate tubercle, 469, 470, 471, 616; of brain, 616; of liver, 470; of spleen, 470.
Conglutination, 77.
Conium poisoning, 337.
Conjunctiva, adenoma of, 972; amyloid degeneration of, 968; anatomy of, 953; angioma of, 971; argyrosis of, 970; carcinoma of, 972; chancroid of, 968; colloid, degeneration of, 968; cysts of, 972, 973; dermoids of, 972; dermolipoma of, 972; desquamation of, 961; edema of, 974; emphysema of, 974; endothelioma of, 971; epithelial plaques of, 972; epithelioma of, 972; epitheliosis of, 961; essential shrinking of, 969; fibroma of, 970; gonorrhea of, 497, 955, 962; gumma of, 968, 1086; hemorrhage of, 969; hyaline degeneration of, 968; hydatid of, 974; leprosy of, 969; lipoma of, 972; lupus of, 969; myxofibroma of, 970; nevi of, 970; osteoma of, 972; papilloma of, 970; parasites of, 974; pemphigus of, 969; sarcoma of, 971; syphilis of, 968, 1086; tumors of, 970; xerosis of, 956, 967.
Conjunctivitis, angular, 955; catarrhal, 954, 956; diphtheritic, 954, 962; exanthematic, 954; follicular, 957; gonorrheal, 497, 955, 962; lithiasis, 968; lymphatic, 963; membranous, 963; metastatic, 955; Parinaud's, 955; petrificans, 967; phlyctenular, 963; pneumococcic, 956; purulent, 954, 962; scrofulous, 963; syphilitic, 968; trachomatous, 958; tuberculous, 968; vernal, 967.
Connective tissue, simple atrophy of, 116.
Conorhinus megistus, 396.
Constipation, 762; effects of, 763.
Constitution, 6, 9.
Consumption, galloping, 455; pulmonary, 452.
Contagion, 428.
Contagium vivum, 432; cellular, in tumors, 288.
Contre coup, 612.
Convalescence, 183.
Convulsions, colon-bacillus, 783; intestinal, in children, 783, 784.
Coprostasis, 762.
Cor biloculare, 190.
bovinum, 633.
triloculare, 190.
villosum, 624.
Corectopia, 1027.
Corium, 941.
Corn, 223, 952.
Cornea, abscess of, 981, 984, 993; amyloid degeneration of, 992; anatomy of, 977; argyrosis of, 998; atrophy of, 122, 979; calcareous degeneration of, 992; colloid degeneration of, 992; cysts of, 998; dermoids of, 998; dystrophy of, 979; endothelioma of, 998; epithelial dystrophy of, 985; epithelioma of, 998; facettes of, 983; family degeneration of, 994; fatty degeneration of, 199; fibroma of, 998; fistula of, 982; flattening of, 998; hematogenous discoloration of, 997; hernia of, 983; herpes of, 989; horns of, 998; hyaline degeneration of, 992; infiltration of, 980; leprosy of, 995, 996; leucomatous ulcer of, 992; melanosis of, 997; mycosis of, 996; myxoma of, 998; opacities of, 979, 993, 998; papilloma of, 998; perforation of, 962, 981, 982; pigmentation of, 997; posterior abscess of, 984; ring abscess of, 993; sclerosis of, 979; staphyloma of, 982; syphilis of, 986; trachoma of, 959; tuberculosis of, 995; ulcer of, 962, 981, 984, 986, 991, 992.
Cornu cutaneum, 952, 1086.
Corona ciliaris, 1027, 1064.
Coronary arteries, embolism of, 532.
Corpora amylacea, 145, 456, 605, 616, 870, 873, 1052; in lungs, 722; in prostate, 873.
arenacea, 239, 610.
cavernosa penis, 875.
libera, 226, 230, 232, 867, 939.
lutea vera, 881.
menstrualis, 881.
mobilia, 226, 230, 232, 867, 939.

Corpora orizoidea, 938, 939.
Corpulency, general disposition to, 107.
Corpus alienum, 4.
  callosum, lesions of, 604, 613.
  ciliaris, 1027.
  irritans, 4.
  luteum, 881.
  planum, 1027.
  vitreum, 1012.
Corpuscles, blood-, 661; Negri, 570; red, of blood, 674.
Corrosion, 7, 55, 317.
Corrosive sublimate, hemorrhage from, 60; poisoning by, 325.
Coryza, 8, 575.
Cover-shame poisoning, 337.
Coxitis, purulent, 931.
Craniopagus, 202.
Cranioschisis, 197.
Craniotabes, 915.
Cranium, blood-tumor of, 212; exostoses of, 237.
Crescents, malarial, 402, 406.
Cretinism, 187, 742.
Crisis, 182.
Croton-oil poisoning, 337.
Croup, membranous, 523, 525, 713.
Croupous pneumonia, 532, 713.
Cruor, 74; lymphaticus, 74; red, 74.
Crusta granulosa, 74; phlogistica, 74.
Cryptococcus cerevisiæ, 423.
Cryptogams, 414.
Cryptogenetic septicemia, 499.
Cryptoglioma, 1071.
Cryptorchidism, 200, 869.
Crystals, bilirubin, 135; calcium oxalate, 856; Charcot-Leyden, 715; cholesterin, 118, 866; fatty acid, 129, 731; hematoidin, 70; triple phosphate, 857; tyrosin, 502.
Cul-de-sac, Douglas's, 887, 891.
Culex, 401; fasciatus, 586.
Curschmann's spirals, 715.
Cutis anserina, 52.
Cyanmethemoglobin, 314.
Cyanosis, 44, 649, 683.
Cyclitic hull, 1029.
Cyclitis, acute, 1029; plastic, 1029; serous, 1029.
Cyclopsia, 187.
Cylinders, urinary, 158, 837.
Cylindroids, urinary, 841.
Cylindroma, 305.
Cynanche, 813; parotidæa, 574.
Cystic goiter, 740, 742.
  sarcoma, 249.
Cysticercus cellulosæ, 379, 380; of eye, 974, 1014, 1025.
  bovis, 384.
  mediocanellata, 384.
Cystin calculi, 858.
Cystis mucosus, 785.
Cystitis, catarrhal, 177, 828, 854, 863; diphtheritic, 854; fibrinous, 854; gonorrheal, 863; hemorrhagic, 823; phlegmonous, 854; purulent, 177, 828, 853, 863; tuberculous, 474, 859; ulcerative, 854.
Cystoma, ovarian, 883; renal, 832 (see also Cysts).
Cystomata, 309.
Cystopyelitis, 520.
Cysts, appendicular, 215, 755, 785; atheromatous, 118, 1078; bone, 238; cerebral, of ciliary body, 1032; conjunctival, 972, 973; corneal, 998, 999; cutaneous, 118; daughter, 388; dermoid, 312, 972, 998; echinococcus, 385; endocervical, 879; of endometrium, 884; epithelial, 973; gastric, 764; hydatid, 385, 1078; inclusion, 974; of iris, 1024, 1025; lymphatic, 972; milk, 892; orbital, 1077; renal, 832; of sclera, 1004; sebaceous, 944; splenic, 694; suprarenal, 621.
Cytase, 28.
Cytolysins, 26.
Cytolysis, 21.
Cytorryctes lues, 544.

Dacryoadenitis, 976.
Dacryocystitis, 975.
Dacryops, 976.
Daltonism, 11.
Dandy fever, 521.
Darnel poisoning, 337.
Datura poisoning, 337.
Dauerspores, 45.
Death, anaphylaxis and, 325; distribution of blood after, 51; from drowning, 708; local, 123; somatic, 123; spots, 52, 711; sudden, 325, 699; thymus, 699.
Decidua menstrualis, 893.
  reflexa, 893.
  vera, 893.
Deciduoma malignum, 899.
Decubitus, 102, 129; profundus, 130; superficialis, 130.
Defervescence, 182.
Defluvium capillorum, 419, 952.
Degeneratio, fusca, 138.
Degeneration, 138, 139; albuminous, 154; amyloid, 144, 693, 697, 799; calcareous, 139; colloid, 151; fatty, 117, 154, 625; granular, 681; hyaline, 150, 779; mucoid, 151; parenchymatous, 154; waxy, 150, 935; Zenker's, 150.
Delhi sore, 397.
Dementia præcox, optic neuritis in, 1055.
  senile, 603.
Demodex folliculorum, 352, 353.
Dengue, 521.
Dental caries, 238, 430.
  osteomata, 238.
Dentes proliferi, 238.
Depression, 5.
Dermacentor occidentalis, 566.
Dermatitis, 423, 946; blastomycotic, 423; bullous, 125; erythematous, 943; gangrenous, 125; pustular, 173, 947; scrofulous, 447, 481; vesicular, 125.
Dermatocele adnata, 201.
Dermoid cysts, 312; of choroid, 1046; conjunctival, 972; corneal, 998; of iris, 1025; orbital, 1077.
Dermolipoma, conjunctival, 972.
Descemet's membrane, 977; drusen on, 996.
Descemetitis, 1029.
Desiccation, 124, 125.
Desmon, 27.
Desquamation, 39, 943; branny, 39; furfuraceous, 39, 943; in hyperemia, 39; membranous, 39, 943.
Dextrocardia, 192.
Diabetes mellitus, blood in, 684; cataract in, 1008; iris in, 1025; pancreas in, 811; suppuration in, 175; uterine, 899.
Diapedesis, 55.
Diarrhea, 414, 422, 520, 568; bilious, 510; bloody, 393, 520, 526; infusorial, 414; mycotic, 422; summer, 520; watery, 506.
Diastasis, of bones, 923.
Diathesis, 1, 2; general hemorrhagic, 62; local, 65.
Dibothriocephalus cordatus, 391.
  latus, 390.
  mansoni, 391.
Dicephalus, 202.
Dicrocœlium lanceatum, 373.
Digestive tract, 749; carcinoma of, 286, 290, 291, 295, 768, 775, 776; tuberculosis of, 459 (see also Intestine, Stomach, Duodenum).
Digitalis poisoning, 335.
Dilation, cardiac, 635; gastric, 346, 772, 774; of cerebral ventricles, 615; of tear-duct, 975; vascular, 34.
Dioctophyme renale, 366.
Diphtheria, 523; bacillus of, 528, 954, 963; of bladder, 854; croupous bronchitis in, 714;

Diphtheria (*concluded*).
of Eustachian tube, 1093; intestinal, 326, 528; in small-pox, 560; malignant, 523; ocular, 963; pharyngeal, 128; toxin of, 338, 523; uterine, 887.
Diplococci, 424.
Diplococcus gonorrhœæ, 495.
intracellularis, 568.
lanceolatus, 532.
meningitidis, 568.
Morax-Axenfeld, 955.
Diprosopus, 202.
Diptera, 349.
Dipygus, 202.
Dipylidium caninum, 379.
Disease, abortive, 3; acme of, 5; acute, 2; atypical, 2; biologic causes of, 8; bleeders', 62, 684; bronzed-skin, 478; chemic causes of, 7; chronic, 2, 61; contagious, 428; decline of, 5; definition of, 2; English, 910; foot, 581; foot and mouth, 492; hookworm, 367; intra-uterine acquired, 9; Iodine-Basedow's, 743; mechanic causes of, 7; pearl, 441; physic causes of, 7, 8; physiologic causes of, 8; subacute, 2; subchronic, 2; sun, 578; termination of, 3, 5; thermic causes of, 8; transmission of, 10; typic, 2; woolsorters', 489.
Addison's, 131, 139, 344, 478, 621, 942.
Banti's, 680.
Barlow-Moeller's, 63, 976.
Basedow's, 340, 741, 742, 744, 916; blood in, 744; iodine, 743.
Brill's, 565.
Buhl's, 677.
Dubois's, 700.
Erb's, 700.
Geisbock's, 683.
Graves's, 742.
Heine-Medin's, 601.
Hodgkin's, 253, 255, 674.
Katayama, 376.
Moeller-Barlow's, 63, 976.
Paget's, of bone, 928; of nipple, 296.
Pott's, 479.
Quincke's, 1082.
Raynaud's, 128.
Vaquez's, 683.
von Recklinghausen's, of bone, 928.
Werlhoff's, 63.
Winckel's, 677.
Diseases, hereditary, 8, 10; infectious, general remarks on, 435.
Disposition, general, 9; local, 9, 10; organ, 9.
Dissemination, 95; of carcinoma, 288; in tumors, 209.
Distichiasis, 1085.
Distoma conjunctum, 374.
japonicum, 373.
pulmonale, 373, 376.
sibiricum, 373.
spathulatum, 373.
Distomum, felineum, 373.
hæmatobium, 375.
hepaticum, 372.
lanceolatum, 373.
rathouisi, 372.
Diverticula, intestinal, 200, 774.
Diverticulum coli, 774.
duodeni, 774.
ilei, 774.
esophageal, 774.
Meckel's, 200.
ventriculi, 774.
vesicæ urinariæ, 215.
Dochmius duodenalis, 367.
Dolichocephalus, 924.
Dolor, 170.
Dracunculus medinensis, 358.
Drill bone, 239.
Dropsy, 45, 96, 96, 581, 807; appendicular, 215, 755, 785; cardiac, 98; epidemic, 581; of gall-bladder, 807; in congestion, 45.
Drowning, 708; lungs in, 708.
Drugs, immunizing influence of, 33.
Drusen, of choroid, 1046; of Descemet's membrane, 996, 1007; of optic papilla, 1056.
Duchenne's paralysis, 604.
Ducrey, bacillus of, 875.
Duct, lachrymal, 974; nasal, 974, 976; ovi-, 261, 477, 880, 901; seminal, 869.
Ductless organs, 344.
Ducts, villous tumors of, 222.
Ductus botalli, 191.
choledochus, duplication of, 205.
thoracic, occlusion of, 96, 660.
Duodenitis, catarrhal, 750.
Duodenum, arteriomesenteric occlusion of, 772; diverticulum of, 200, 774; tuberculosis of, 459; ulcer of, 768.
Dura mater, endothelioma of, 304; hematoma of, 213; hygroma of, 591; osteoma of, 591; psammoma of, 240; relations of, 589; sarcoma of, 303; syphilis of, 553.
Dysentery, 393, 520, 526; amebic, 393; bacillus of, 520; liver abscess in, 393.
Dysmenorrhea, 893; membranous, 893.
Dyspnea, 714.
Dysthyroidism, 743.
Dystrophy, corneal, 979.

Ear, external, furuncle of, 1089; hematoma of, 213, 1088; inflammation of, 1089; mycosis of, 418; tophi of, 143.
middle, catarrh of, 1091.
Eburnation, 903.
Ecchondroses, 229; laryngeal, 229, 724; tracheal, 229.
Ecchymosis, 54, 211, 943; conjunctival, 969; cutaneous, 61, 943.
Echinococcus, brood capsules of, 385, 386; of liver, 799; multilocularis, 388, 799; polymorphus, 385; unilocularis, 385.
Echinorhynchus gigas, 367.
Eclampsia, 324, 341; gravidarum, 341.
Ectasis, ampullar, 659; arterial, 34; bronchial, 724; cardiac, 635; sacculated, 724; scleral, 1004; simple, 658; of spinal medulla, 615, 1054; stomach, 346, 772, 774; tracheal, 724; venous, 59, 659; ventriculorum cerebri, 615.
Ectopia cordis, 189, 198, 206.
lentis, 1012.
vesicæ urinariæ, 198.
Ectopic pregnancy, 895, 896.
Ectropion, 1075, 1083, 1084, 1085; of uveal pigment, 1022.
Eczema, 296, 419, 948; carcinomatous, of breast, 296; marginatum, 419; palpebrarum, 1083.
Edema, 95; arachnoidal, 593; arthritic, 1082; cerebral, 608; circumscribed, 1082; congested, 946; conjunctival, 947; cyclic, 1082; durum, 102; dyscrasic, 946; elastic, 946; fluxional, 946; fugax, 99, 946; in gangrene, 102; glottis, 100, 720; Ivanoff's, 1082; laryngeal, 100; lymphatic, 102; malignant, 573; neurotic, 1082; painful, 99; palpebral, 1069, 1082; papillary, 946; pulmonary, 96, 101, 103, 539, 705, 710; purpuric, 1082; renal-pulmonary, 103; retinal, 1068, 1069; serum, 1083; tactile, disturbances in, 101.
Ehrlich, immunity theory of, 22; side-chain theory of, 21.
Ehrlich-Hata, "606" remedy, 329.
Eimeria stiedæ, 398.
Electricity, action of, 8, 50.
Elephantiasis, 103; acquired, 218; arabum, 216; congenital, 217; fusca, 217; hard, 217; lævis, 217; nigra, 217; nodosa, 217; papillary, 217; scrotal, 216, 358; soft, 217; teleangiectodes, 218; tuberous, 217; ulcerative, 217; verrucous, 217; vulvar, 901.
Elimination, 2, 104.
Emaciation, 114, 327.

Emboli, air, 84; bland, 85; composition of, 85; entozoa as, 84; fat, 83, 685; foreign bodies as, 85; infectious, 85; gas, 84; nature of, 82; occluding, 85; organ cells as, 83; riding, 86; size of, 87, 91.
Embolism, 58, 81; air, 84; capillary, 87; of circle of Willis, 596; collateral hyperemia in, 86; of coronary arteries, 632; fat, 83; as cause of gangrene, 127; intestinal hemorrhage in, 766; local anemia in, 86; multiple, 86; pulmonary, 727; retinal, 1070; septic, 728; sequelæ of, 85, 91; symptoms of, 92.
Embolus, definition of, 81.
Embryotoxon, 979.
Emigration, leucocytic, 55, 164.
Emphysema, alveolar, 706; bullous, 708; conjunctival, 974; cutaneous, 947; interstitial, 706; orbital, 1075.
Emphysematous gangrene, 126, 570.
Empyema, 174, 540, 712; pericardial, 624; pleuritic, 734.
Emulsion stadium, in fatty degeneration, 117.
Encephalitis, congenital interstitial, 598; syphilitic, 564.
Encephalocele, 1074.
Encephalomalacia, 90.
Encephalomeningitis, 595; tuberculous, 468.
Encephalopathy, lead, 327.
Enchondroma, 232; albuminosum, 232; gelatinosum, 233; molle, 233; myxomatodes, 228; mucosum, 233.
Endoaortitis, 655; deformans, 655.
Endoarteritis, 657.
Endocarditis, 639; adhesive, 641; chronic, 641; malignant, 646; in typhoid, 515; ulcerative, 648.
Endocardium, atrophy of, 638; sclerosis of, 639; thrombi of, 645; tumors of, 649.
Endocervicitis, chronic, 879.
Endochorion, 227.
Endometritis, catarrhal, 885; cystic, 884; decidual, 893; diphtheritic, 887; fibrous, 556; gonorrheal, 496; glandular, 885; interstitial, 885; purulent, 887; syphilitic, 556; tuberculous, 477; villous, 886.
Endosmosis, 3, 104.
Endospores, 426.
Endostitis hyperplastica, 928.
Endothelioma, 303; alveolar, 304, 306; of ciliary body, 1031; conjunctival, 971; hemangio-, 304; hyaline, 305; of iris, 1026; lymphangio-, 305; orbital, 1080; ovarian, 883; of palate, 306; of parotid gland, 305; submaxillary, 305.
Endotoxins, 20, 175, 429.
English disease, 910.
Engorgement, 40; pulmonary, 536.
Engoulement, 536.
Enophthalmos, 1076.
Enostosis, 238.
Entamœba coli, 392.
  dysenteriæ, 393.
  histolytica, 393.
  mitis, 392.
  tetragena, 393.
Enteritis, catarrhal, 752; fibrinous, 756; membranous, 751; pigmentosa, 134; polypous, 256; tuberculous, 459; ulcerative, 760.
Enterocatharsis, 568.
Enteroliths, 143.
Enterophthisis, tuberculous, 459.
Entozoa, 348; as emboli, 84.
Entropion, 961, 966, 1085.
Enzymes, proteolytic, 175.
Eosinophilia, 29, 664; as sign of anaphylaxis, 664; in asthma, 716.
Eosinophilic cells, in asthma, 716; in conjunctivitis, 967.
Ependyma, glioma of, 614.
Ependymitis, 614; granular, 241, 595.
Ephelides, 131, 137.
Ephemeron poisoning, 336.
Epicanthus, 972.
Epidemic dropsy, 581.
Epidermis, 941; spheres, 280.
Epidermization, 108.
Epididymitis, 868; tuberculous, 475.
Epigastrius, 203.
Epignathus, 203.
Epilepsy, Jacksonian, 237.
Epiphora, 1084.
Epiphyte, 430.
Episcleritis, 999, 1000.
Epispadias, 198.
Epistaxis, in amenorrhea, 61; in heart disease, 61.
Epitarsus, 966.
Epithelial onions, 280; pearls, 280.
Epithelioma, 279, 280; cancroid, 279; of cervix uteri, 297; contagiosum, 950.
Epitheliosis conjunctivæ, 961.
Epithelium, metaplasia of, 108.
Epitoxons, 23.
Epizoa, 348.
Epulis, 248.
Equator, of crystalline lens, 1005.
Equatorial staphyloma, 1050.
Equinia, 490.
Erb's disease, 700.
Erectors, of hairs, 52.
Ergot gangrene, 128; poisoning, 332.
Ergotin poisoning, 332.
Ergotism, 128, 332.
Erosion, of cervix uteri, 878; hemorrhagic, of intestine, 769; of vessels, 55, 56, 67.
Erysipelas, 493; in gangrene, 127; peritoneal, 782.
Erythema, 943, 949.
Erythroblastoma, 253.
Erythroblasts, 675.
Erythrocytes, destruction of, 133; in malaria, 410.
Erythromyeloblastoma, 253.
Eserine poisoning, 337.
Esophagus, carcinoma of, 290; tuberculosis of, 459.
Esthiomene, 482.
Estivoautumnal fever, 406.
Ether poisoning, 333.
Ethyl-bromide poisoning, 333.
Etiology, general, 6.
Eugastrius, 203.
Eustachian tube, diphtheria of, 1093; occlusion of, 1093; syphilis of, 1093; tuberculosis of, 1093.
Eustrongylus gigas, 366.
Excoriations, 949.
Exercise bone, 142, 239.
Exitus lethalis, 5.
Exochorion, 227.
Exophthalmia, 243, 742, 1075, 1083; fungosa, 243.
Exophthalmic goiter, Graefe's symptoms of, 738, 1083.
Exophthalmos, 742; in Graves's disease, 742; intermittent, 1076; pulsating, 1075.
Exosmosis, 3, 104.
Exostosis, 217, 235, 929; articular, 238; alveolar, 238; apophytic, 238; of auditory canal, 1093; discontinuous, 238; eburneæ, 237; ivory, 1078; subungual, 238; supracartilaginary, 237; tendinous, 238.
Exotoxins, 429.
Extrauterine pregnancy, 895, 896.
Extravasate, inspissation of, 70; organization of, 70; pigmentation of, 70; softening of, 70.
Extravasation, 54; tumors, 211.
Exudates, 98; catarrhal, 176; croupous, 178; diphtheritic, 178; fibrinous, 178, 713; hemorrhagic, 67, 178; mucous, 176, 713; pseudomembranous, 178; putrid, 179; serous, 178.
Exudation tumors, 211.

Eye, 953; cysticercus of, 974; diseases of, 953 *et seq.*; hydatid of, 974; melanosarcoma of, 247; syphilis of, 555 (see also Cornea, Conjunctiva, Choroid, Lens, Retina, Sclera, Vitreous).
Eyeball, luxation of, 1075.
Eyelids, adenomata of, 1086; angioma of, 263, 971; chancre of, 1087; cilia of, 1080; cysts of, 1086; eczema of, 1083; edema of, 1080; emphysema of, 1083; fibroma of, 1086; glands of, 1080; hypertrophy of, 1083; molluscum contagiosum of, 1087; papilloma of, 1086; parasites of, 1087; syphilis of, 1086.

Facettes, corneal, 983, 998.
Facies hippocratica, 629.
Fagopyrism, 580.
Falling of hair, 419, 952.
Fallopian tubes, carcinoma of, 901; catarrh of, 880; myoma of, 261; tuberculosis of, 477.
Farcy, 490.
Fascia, tuberculosis of, 478.
Fasciculus, vascular, 988.
Fasciola hepatica, 372.
Fasciolopis buski, 372.
Fastigium, 182.
Fat, absorption of, 118; in blood, 684; embolism, 83, 685, 730; depot, 156; granule cells, 117; labile, 157; necrosis, of lipomata, 225; retention, 118; stabile, 156; tissue necrosis, 124, 141, 813.
Fatty acid crystals, 129, 731; in pulmonary gangrene, 731.
Fatty degeneration, 155; of aorta, 119; emulsion stage of, 117.
metamorphosis, 116; of cornea, 119; of pulmonary exudate, 719.
Favus, 418; of lids, 1087.
Febris undulans, 521.
Feces, stagnation of, 762.
Felix-mas poisoning, 336.
Felon, 946.
Femur, fracture of, 907.
Ferment, fibrin, 73.
Ferrein, pyramids of, 816; stars of, 822.
Fetal ring, 979.
Fetus, bronchiectasis in, 726; dead extrauterine, 124; in fetu, 203.
Fever, 181; African, 503; aseptic surgical, 181; black-water, 133, 407, 676; breakbone, 521; chill stage of, 182; continued, 183; dandy, 521; enteric, 507; estivo-autumnal, 406; famine, 502; gas exchange in, 184; hay, 760; hospital, 565; initial stage of, 182; intermittent, 183; jail, 565; malarial, 133, 400; Malta, 521; Mediterranean, 521; paratyphoid, 515, 518; petechial maculated, 565; puerperal, 894; putrid, 565; quartan, 409; quotidian, 407; recurrent, 502; relapsing, 502; remittent, 184; Rocky Mountain, 566; ship, 565; splenic, 490; spotted, 565; tertian, 408; tick, 503, 566; tropic, 406; typhoid, 507 (see also Typhoid); typhus, 565; yellow, 586.
Fibrin ferment, 73; wedge, 90.
Fibrinogen, 73.
Fibrinoplastic substance, 73.
Fibroblasts, 166.
Fibroendothelioma, 304.
Fibroma, 216; of breast, 221, 222; of cornea, 998; diffusum, 218; of gall-bladder, 220; heteroplastic, 224; interstitial, 218; intestinal, 775; intracanalicular, 221, 222; of kidney, 219; mammæ, 218; mucosum, 224; of liver, 220; ossium, 224; ovarian, 220; papillary, 219, 221; petrificans, 224; renal, 834; of sclera, 1004; simplex, 224; of spleen, 220; of synovia, 220; testicular, 220; tuberous, 223; of urinary bladder, 220; villous, 219.
Fibromyoma, calcification of, 142; ovarian, 261; uterine, 898.
Fibroneuroma, 261.
Fibrosarcoma, 250, 251.
Fibrosis, arteriocapillary, 636.
Ficus, 223.
Fig wart, 223.
Filaria, bancrofti, 358; diurna, 360; loa, 358; medinensis, 358; oculi, 358; perstans, 360; philippinensis, 360; sanguinis hominis, 60, 538.
Fire-mark, 264.
Fish, poisoning by, 337; skin, 952; tuberculosis, 438.
Fission fungi, 423.
Fissura vertebralis, 197.
Fistula, 173; anal, 766; corneal, 982; lachrymal, 976; rectal, 766; salivary, 814; seminal, 476; tracheal, 198.
Fixative, 27, 28.
Flagella, bacterial, 425.
Flagellata, 393.
Flat-foot, 922.
Flea, 349.
Fluke rot, 372.
Flukes, 372.
Fluor albus, 877.
Fluxion, 35, 36; collateral capillary, 728; secondary, 37.
Fly agaric, poisoning by, 315.
Fly, storm, 395; tsetse, 395.
Fly fungus, poisoning by, 335.
Foamy organs, 571.
Follicles, intestinal, polypous hyperplasia of, 256; trachoma, 960.
Fontana, spaces of, 1017.
Foot disease, 581.
Foot and mouth disease, 492.
Foot vapor, 581.
Foramen, optic, 1073; ovale, patent, 82.
Foreign bodies, as emboli, 85.
Fovea centralis, 1058, 1061.
Foxglove poisoning, 335.
Fracture, bony, 905; cartilaginous, 906; comminuted, 910; spontaneous, 905, 934.
Frambesia, 588.
Freckles, 131, 137.
Freezing, 128, 949.
Frigidity, in congestion, 44.
Frost-bite, 128.
Function, 3; organic, 104.
Fungi, achlorophyllous, 414; budding, 423; fission, 423.
Fungus, benignus, 476, 868; cerebri, 197; duræ matris, 250; hematodes, 243.
Funnel chest, 914.
Furuncle, 947; of ear, 1089; malignant, 488.

Galactocele, 892.
Gall-bladder, carcinoma of, 299; dropsy of, 807; fibroma of, 220; tumors of, 809.
Gall-stones, 299, 807; in hepatic carcinoma, 299.
Galloping consumption, 455.
syphilis, 558.
Gametes, 397, 402, 410.
Ganglion, 938.
Ganglion cells, atrophy of, 115, 603; calcification of, 141.
Gangræna humida, 125; nosocomialis, 572; putrescentia, 125; sicca, 125.
Gangrene, 46, 123; black, 102, 127; causes of, 124, 656; circumscribed, 126; cold, 123; colorless, 127; diffuse, 126; dry, 125; embolism in, 127; emphysematous, 126, 570; ergot, 128; in erysipelas, 127; fatty acid crystals in, 731; gaseous, 126, 570; hospital, 128, 525, 572; hot, 123; intoxication in, 127; marasmic, 130; moist, 125; pharyngeal, 128; pulmonary, 127, 129, 540, 542, 719, 725, 731; senile, 130, 656; symmetric, 128; valerianic acid in, 126; vesicles, 125; white, 102, 127; yellow, 127.

Garotillo, 523.
Gas emboli, 84; poisoning, 314.
Gaseous emphysema, 570.
  gangrene, 126, 570.
  phlegmon, 570.
Gastrectasis, 769, 772, 774.
Gastritis, catarrhal, 749; fibrinous, 756; interstitial, 764; parenchymatous, 765; phlegmonous, 765; verrucous, 765.
Gastroadenitis, 765.
Gastrodiscus, hominis, 371.
Gastrointestinal canal, amyloid degeneration of, 149.
Gastromalacia, 754.
Geisbock's disease, 683.
Generalization, of tumors, 209.
Generation, asexual, of malaria parasite, 405.
Generative organs, female, atrophy of, 120.
Genu valgum, 915; varum, 915.
German measles, 564.
Gestation, ectopic, 895.
Giant cells, 167; foreign body, 1078; in sympathetic ophthalmia, 1033; in tubercle, 436; varieties of, 437.
Gibbus, 917.
Gigantism, 201.
Gingivitis, 577, 930.
Gland, pineal, 616; pituitary, tumors of, 616.
Glanders, 490.
Glands, carcinoma of, 284; Henle's, 953; hypertrophy of, 111; Krause's, 953; lachrymal, 974; Meibomian, 961, 1080; Moll's, 1080; surface section of, confusion with carcinoma nests, 270; palpebral, 1080; Waldeyer's, 1080.
Glanduiar carcinoma, 284; organs, atrophy of, 121.
Glaucoma, 1017, 1047; of childhood, 989, 1051; etiology of, 1048; gout and, 1049; hereditary, 1049; of infancy, 1051; inflammatory, 1047; iridectomy in, 1049; primary, 1047; secondary, 1049; simplex, 1048.
Glioma, 241; of cerebral nerves, 242; durum, 241; endophytum, 1071; ependymal, 614; exophytum, 1071; myxomatodes, 228; orbital, 1080; retinal, 243, 1071; suprarenal, 620.
Gliosarcoma, of brain, 616; retinal, 243.
Glioneuroma, 261.
Glisson, capsule of, 789.
Glomeruli, renal, 817; fat embolism of, 84.
Glossina, furca, 395; morsitans, 395; pallidipes, 395; palpalis, 395.
Glossitis, catarrhal, 752.
Glossy skin, 120.
Glottis, edema of, 100, 495, 720.
Glycogen, 145.
Glycosuria, intoxication, 898.
Goiter, cystic, 740, 742; endemic, 742; exophthalmic, 738; Graefe's symptoms of, 1083.
Goll, columns of, 605.
Gonococcus, 955, 963.
Gonorrhea, 495, 853, 874, 931; arthritis in, 497, 931; neonatorum, 497, 955, 962.
Goose breast, 914.
  skin, 52, 180.
Gorontoxon, 978.
Gout, 94, 143, 342, 684, 1049; glaucoma and, 1049.
Graafian follicles, 882, 883.
Graefe's symptom, 1083.
Grafting, 162.
Granular cells, 117.
Granulation tissue, 166, 179.
Granulations, basophilic, 681; Pacchionian, 594.
Granules, trachoma, 958.
Granuloma, Hodgkin's, 253, 255.
Gray degeneration, of spinal cord, 604.
Green sickness, 677.
Gregarinida, 398.
Gruber-Widal reaction, 517.
Guinea-worm, 358.
Gumma, 547; choroidal, 1014, 1037; of iris, 1023, 1030; of optic nerve, 1055; orbital, 1077.

Hairiness, abnormal, 201.
Hairs, erectors of, 52; falling of, 952.
Hallux valgus, 922.
Haptophore, 22, 27.
Harelip, 197, 198.
Harvest bug, 354.
Hasner's valve, 974.
Hassall's bodies, 106.
Hay fever, 760.
Head-louse, 351.
Head zones, 947, 1033.
Healing, 6, 162; of wounds, 162.
Heart, aneurism of, 622, 633; athletes, 637; atrophy of, 138; block, 630; beer drinkers', 637; brown atrophy of, 138; calcification of, 631; in general congestion, 42; dilation of, 635; embolism of, 632; fatty, 107, 110, 119, 625; state of, after death, 52; hypertrophy of, 634, 637; hypoplasia of, 193, 678; insufficiency of, 629; lesions of, hemorrhage in, 57; paralysis of, 52, 628; rhabdomyoma, 256; rupture of, 631; syphilis of, 634; tumors of, 638; valvular lesions of, 640; weakness, 43.
Heart disease, dropsy in, 98; epistaxis in, 61; significance of, 644.
Heart-lesion cells, 57.
Heat, effect of, 8.
Heine-Medin's disease, 601.
Helvella esculenta poisoning, 315, 321, 336.
Hemangioma, 265; conjunctival, 971; orbital, 1077.
Hemangiosarcoma, 304; endothelioid, 304.
Hemarthrosis, 930.
Hematemesis, 67, 68.
Hematocele, 867.
Hematoidin, 132; crystals, 70; infarcts, 844.
Hematoma, 212; auricular, 213; of dura mater, 213; of muscle, 214, 514; ovarian, 212, 882; prepatellar, 939; retrouterine, 213, 891; suprarenal, 212, 213; in typhoid fever, 514; uterine, 214; vaginal, 212; vulvar, 212, 891.
Hematocolpos, 891.
Hematometra, 891.
Hematopoietic organs, 688.
Hematosalpinx, 880.
Hematothorax, 734.
Hematozoa, 348.
Hematuria, essential, 823; unilateral, 823.
Hemeralopia, 1034, 1066.
Hemlock poisoning, 336, 337.
Hemicrania, 187.
Hemiptera, 351.
Hemochromatosis, 134.
Hemoconia, 663.
Hemofuchsin, 134.
Hemoglobinemia, 133, 315, 675.
Hemoglobinocholia, 676.
Hemoglobinuria, 133, 315, 407, 676; intermittent, 676; paroxysmal, 676.
Hemolysins, 26, 320.
Hemolysis, 320, 676.
Hemolytic system, 321.
Hemopericardium, 622.
Hemophilia, 63, 684; cause of, 64; renal, 64.
Hemoptysis, 458.
Hemorrhage, 54; abdominal, 785; amount to cause death, 68; arterial, 56; in Barlow's disease, 63; capillary, 56; causes of, 55; cerebral, 608; in chronic disease, 61; at climacteric, 54; compensation in, 69; conjunctival, 969; in congestion, 45; per diabrosin, 55; per diæresin, 55; per diapedesin, 55; external, 66; forms of, 68; free, 66; functional disturbances from, 69; in hemophilia, 63; in hemorrhoids, 65; in hyperemia, 39; in acute infectious dis-

Hemorrhage (*concluded*).
eases, 60; internal, 66; internal ear, 1096; intestinal, 769; latent, 66; in leukemia, 62; mode of arrest of, 71; during ovulation, 54; pancreatic, 811; parenchymatous, 56; in pernicious anemia, 62; pulmonary, 56, 458; punctiform, 66; purpuric, 63; retinal, 62; per rhexin, 55; from Schistosomum hæmatobium, 60; scorbutic, 62; in scurvy, 62; unilateral renal, 65; vascular changes in, 59; venous, 56; vitreous, 1013; in Werlhof's disease, 63.
Hemorrhagin, 320.
Hemorrhoids, 265; hemorrhage in, 65.
Hemosiderin, 132, 133.
Hemosporidia, 398.
Hemozoin, 675.
Henbane poisoning, 337.
Henle's fibers, 1059, 1061; glands, 953, 973; loop, of kidney, 816; warts, 996.
Hepar moschatum, 791.
Hepatitis, diffuse, 550; hypertrophic, 797; interstitial, 798; parenchymatous, 794; portal, 797; syphilitic, 549.
Hepatization, caseous, 454, 540; caseous, of lung, 454; pulmonary, 454, 536, 540, 555, 718; red, 536; white, of lung, 555.
Heredity, 8, 9, 10.
Hermaphroditism, 193.
Hernia, 198, 199, 769, 770; congenital, 199; inguinal, 770; peritoneal, 199; strangulated, 769; umbilical, 198.
Herpes, corneal, 989, 1083; febrilis corneæ, 989, 996; facialis, 947; iris, 963; labialis, 947; ophthalmic, 989; preputialis, 875; tonsurans, 419; versicolor, 420; zoster, 947, 1083; Head zones and, 1033.
Heteradelphia, 201.
Heterochromia iridis, 1027.
Heterophyes heterophyes, 374.
Hexacanth, 377.
Highmore, antrum of, catarrh of, 712.
Hip, congenital luxation of, 932; spastic luxation of, 932.
Hippus, 1020.
Hirsuto adnata, 201.
His, bundle of, 630.
Histolysis, 175.
Hives, 948.
Hodgkin's disease, 253, 255, 674.
Hook-foot, 200.
Hookworm, 367, 368.
Hordeolum, external, 1084; internal, 1084.
Hormones, 344.
Horns, cutaneous, 950, 1086.
Horseshoe kidney, 193.
Hospital fever, 565; gangrene, 128, 525, 572.
Hottentot apron, 901.
Hour-glass stomach, 769.
Humpback, 917.
Hunger, 116.
Hyaline cartilage, fibroid degeneration of, 108.
Hyaline degeneration, 150; intestinal, 779.
Hyalitis, 1013.
Hyaloid canal, 1012.
membrane, of vitreous, 1012.
Hydatid cysts, 385, 1078; of eye, 974.
Hydrarthrosis, 930.
Hydremia, 98, 99, 982; marantic, 99.
Hydrocele, 886; cerebral, 197; cystic, 867.
Hydrocephalocele, 197.
Hydrocephalus, 923; acquired, 614; acute internal, 468; congenital, 614; chronic, 595, 614; fluid of, 98; internal, 614.
Hydrocyanic acid poisoning, 314.
Hydrogen, sulphureted, poisoning by, 126, 315.
Hydromeningocele, 197.
Hydromyelocele, 197.
Hydronephrosis, 835.
Hydropericardium, 622.
Hydrophobia, 569.
Hydrops, 95; appendiceal, 755, 785; aqueous, 96; cachectic, 99, 102; calidus, 100, 780;
Hydrops (*concluded*).
cause of, 98; change of organ position in, 101; chylous, 96, 666; cysticus felleæ, 807; ex vacua, 593; free, 95; frigidus, 100, 779; gravitation, 99; inflammatory, 100; lymphatic, 96, 99; paralytic, 99; renum cysticus, 831; spurious, 95; symptoms of, 100; true, 95; of vermiform appendix, 755, 785.
Hydropsic fluids, constituents of, 96.
Hydrorrhachis externa, 593.
Hydrosalpinx, 880.
Hydrothorax, 734; lymphatic, 100, 734.
Hygroma, 214; of dura mater, 591; ganglioid, 938; prepatellar, 938; proliferans, 939.
Hymen, anomalies of, 190; atresia of, 199; hemorrhage from, 63.
Hymenolepis, murina, 380; nana, 379.
Hyoscyamus poisoning, 337.
Hypalbuminosis, 683.
Hyperalbuminosis, 683.
Hyperemia, 34; active, 35, 58; arterial, 35; capillary, 35; collateral, 36; causes of, 36; desquamation in, 39; elevation of temperature in, 39; in embolism, 86; hemorrhage in, 39; hypostatic, 711; irritative, 38; passive, 35; pulsation in, 39; swelling in, 39; venous, 35.
Hyperinosis, 682.
Hypernephroma, 850.
Hyperostosis, 217, 236, 904, 905.
Hyperplasia, 105; thymus, 256, 699; true, 253; tumor-like, 253.
Hyperpyrexia, 182.
Hyperthyroidism, 743, 744.
Hypertonia, 1047.
Hypertrichiasis, 201.
Hypertrophy, 105, 109; active, 110; of adipose tissue, 111; cardiac, 634, 637; compensatory, 110; compensatory, of organs, 160; glandular, 111; kidney, 835; of lungs, 111; of milk glands, 112; muscular, 110; myelin, 113; of nerves, 113; prostatic, 112, 836; renal cardiac, 635; tonsillar, 255; trabecular, 110; uterine, 890.
Hyphæ, 415.
Hyphemia, 1027.
Hyphomycetes, 415.
Hypinosis, 682.
Hypoderma bovis, 350; diana, 350.
Hypoleucocytosis, 663.
Hypophysis, 616; tumors of, 616.
Hypoplasia, 113; in chlorosis, 678.
Hypopyon, 981, 983, 1018; aspergillus in, 996; saccharomyces in, 996; ulcer, 984.
Hyposarca, 946.
Hyposecretion, sebaceous, 944.
Hypostasis, 42, 51; pulmonary, 711.
Hypostatic pneumonia, 711.
Hypsicephalus, 924.

Ichthyosis, 952.
Icterus, 94, 803; acathectic, 135; acholytic, 800; catarrhal, 751; diffusion, 135; gravis, 340, 347, 803; green, 804; hemolytic, 800; hepatogenous, 804; lævis, 803; in lead poisoning, 326; neonatorum, 135, 136; in phosphorus poisoning, 327; pleiochromicus, 135; in pneumonia, 542; toxic, 135; viridis, 804, 805.
Idiocy, amaurotic family, 1066.
Idiosyncrasy, 2, 12.
Idiotia thymopriva, 699.
Ileotyphus, 508.
Ileum, catarrh of, 752, 755; diverticula of, 774.
Ileus, duodenal, 772; paralytic, 783.
Immune body, 26, 27, 321.
Immunity, 9, 12, 430; absolute, 9, 12; acquired, 12, 29, 411; active, 14; artificial, 29; biochemic factors in, 19; chemic factors in, 19; Ehrlich's theory of, 22; familial, 13; forms of, 15; hereditary, 9; individual, 13; local, 9; natural, 12, 411;

Immunity (*concluded*).
partial, 12; passive, 14, 31; permanent, 13; racial, 13; relative, 9, 12; side-chain theory of, 21; tissue, 449; transient, 13.
Immunization, 19.
Inanition, 116.
Inclusio fœtalis, 203.
Incontinence, cardiac, 42.
Induration, 45, 139, 180, 458, 709; brown, of lungs, 45; in congestion, 45; slaty, 139, 458, 709; slaty, of lungs, 458, 709.
Infantile paralysis, 601.
tetany, 746.
Infants, beriberi in, 585; convulsions in, 783; glaucoma of, 1051; summer diarrhea of, 520.
Infarction, 58, 88; hemorrhagic, of posterior ciliary artery, 1005; of kidney, 124, 143, 821, 849; pulmonary, 90, 727; myocardial, 653; renal, 124, 143, 821, 849; splenic, 90, 691; of stomach, 58; uterine, 41, 891.
Infarcts, bilirubin, 135; anemic, 90; concrement, 90; congestion, 727; hematoidin, 844; lime, 143, 846; methemoglobin, 60; pigment, 821, 843; silver, 845; thrombotic, 727; tuberculous, 471; uric acid, 845; white, 90.
Infection, 14, 175, 427; conceptional, 428; self-limitation of, 19; septic, 501.
Infectious diseases, 435; acute, hemorrhage in, 60; protection against, 15.
Infiltration, 52; fatty, 791, 792; hemorrhagic, 66; hydropsic, 96, 101; leukemic, 672.
Inflammation, 158, 162, 163; adhesive, 162; difference from degeneration, 158; essentials of, 169; exudative, 172; parenchymatous, 171; productive, 180; purulent, 173; sequelæ of, 179; signs of, 163.
Inflammatory spindles, 980.
Influenza, 522.
Infusoria, 414; diarrhea from, 414.
Inguinal hernia, 770.
Injection, vascular, 38.
Inoculation, protective, 432.
Insane, othematoma in, 213; progressive paralysis of, 595.
Insecta, 349.
Insects, poisoning by, 320.
Inspissation, 124; in dropsy, 102.
Insufficiency, cardiac, 628.
Intermarriage, influence of, 2.
Intermediate body, 27.
Intermittent fever, 133.
Intestine, amyloid degeneration of, 778; carcinoma of, 286, 295; cleft of, 199; diphtheria of, 507; diverticula of, 774; follicular hyperplasia of, 256; invagination of, 770; myiasis of, 351; stenosis of, 444; strangulation of, 770; stricture of, 762; torsion of, 771; tuberculosis of, 459; ulcer of, 768.
Intima, fatty degeneration of, 119.
Intoxication, 7, 763; acid, in thymectomy, 699; fecal, 763; in gangrene, 127; serum, 325.
Intumescentia opaca, 154.
Intussusception, 770.
Invagination, intestinal, 770.
Involucrum, 927.
Iodine-Basedow's disease, 743.
Iridectomy, in glaucoma, 1049.
Irideremia, 1027.
Iridochoroiditis, 1021.
Iridocyclitis, 1028; metastatic, 993; pneumococcic, 993.
Iridodialysis, 1021, 1027.
Iridodonesis, 1006, 1011, 1020, 1051.
Iridoplegia, 1019.
Iridoschisis, 1026.
Iris, absence of, 1027; angioma of, 1026; atrophy of, 1021; calcareous degeneration of, 1022; carcinoma of, 1026; coloboma of, 1026; cysts of, 1024; dermoids of, 1025; endothelioma of, 1026; glioma of, 1026;
Iris (*concluded*).
gumma of, 1023; hemorrhage of, 1027; hyperemia of, 1020; leprosy of, 1024; nevus of, 1025; perithelioma of, 1026; sarcoma of, 1026; sphincter of, 1017; syphilis of, 555, 1023; tremulous, 1020; tuberculosis of, 1023; wounds of, 1018.
Iritis, 1000, 1018; acute, 1020; chronic, 1021; leprous, 1024; nodular, 1024; purulent, 1021; recurrent, 1021; syphilitic, 1023; tubercular, 1023.
Irritamentum, 4.
Irritation, 4.
Ischemia, 47, 49; capillary, 49; causes of, 49.
Ischiopagus, 202.
Isohyperleucocytosis, 669.
Isolysis, 321.
Itch, 353; barbers', 419.
Itch mite, 352.
Ivanoff's edema, 1069.
Ixodes redivius, 354.

Jaborandi poisoning, 337.
Jacksonian epilepsy, 237.
Janiceps, 202.
Jaundice, 94, 803 (see also Icterus).
Jejunum, diverticula of, 774.
Jimson-weed poisoning, 337.
Joint mice, 226, 230, 232.
Joints, corpora libera of, 226, 230, 232; tuberculosis of, 480.
Juniper poisoning, 337.

Kakke, 581.
Kala-azar, 396.
Karyokinesis, 159.
Karyomitosis, 159.
Karyosome, 402.
Katayama disease, 376.
Kedani mite, 354.
Keratitis, annular, 995; band-shaped, 990; bulbous, 990; cicatricial, 987; dendritic, 991; disciform, 995; fascicular, 988; filamentary, 991; furrow, 991; gonorrheal, 497; grill-like, 994; interstitial, 990, 985; lattice, 994; leprous, 995; marginal, 987; mycotic, 980, 996; neuroparalytic, 985; nodosa, 995; nodular, 994; pannosa, 987; parenchymatous, 985; phlyctenular, 986; post vaccinolosa, 995; punctate, 995; purulent, 980, 983; recurrent, 989; reticular, 994; rodent, 991; sclerosing, 980; stellate, 991; striate, 994; superficial, 987; syphilitic, 995; traumatic, 981; tuberculous, 995; vesicular, 989; xerotic, 978.
Keratocele, 982.
Keratoconus, 988.
Keratoectasis, 983; e panno, 988.
Keratoglobus, 988.
Keratoma, 952.
Keratomalacia, 967, 978.
Keratomycosis, 996.
Keratosis, 1089.
Kidney, abscess of, 827; adenocystoma of, 832; amyloid, 149, 848; atrophy of, 158, 834; calculi of, 847; carcinoma of, 300, 850; circulation of, 818; cloudy swelling of, 821; concretions in, 832, 847; contracted, 831, 834; cortex of, 816; cyanotic induration of, 847; cystoma of, 832; dimensions of, 815; fatty degeneration of, 158, 219; fibroma of, 834; function of, 818; glomeruli of, 817; gouty, 834; granular atrophy of, 158, 824, 831; hemangioma of, 265; hemophilia of, 64; horseshoe, 193; hypertrophy of, 835; infarction of, 124, 143, 821, 849; labyrinth of, 816; lime infarcts in, 143; lipoma of, 226; medulla of, 816; pigment infarcts of, 843; pyramids of, 816; red induration of, 847; renculi of, 815; retinitis in contracted, 1064; structure of, 816; syphilis of, 556; thrombosis of, 848; tuberculosis of, 471;

Kidney (*concluded*).
tubules of, 816; tumors of, 849; urates in, 845; weight of, 815; white, 158; yellow, 822, 848.
Klasmatocytes, 167.
Klebs-Loeffler bacillus, 528, 954, 963.
Knock-knees, 915.
Koplik's spots, in measles, 563.
Kranioschisis, 187.
Kraurosis, of vulva, 901.
Krause's glands, 953, 972, 973.
Kreatoxismus, 337.
Kryoscopy, 820.
Kyphosis, 910, 917.

Labia majora, ulcers of, 878.
Labium liporinum, 198.
Labyrinth, ear, 1096; renal, 816.
Labyrinthine vertigo, 1096.
Lachrymal gland, atrophy of, 976; dislocation of, 976; hypertrophy of, 976; tumors of, 976.
organs, anatomy of, 974.
Lagophthalmus, 967.
La grippe, 522.
Lamblia intestinalis, 394.
Lamina cribrosa, 1052.
vitrea, 1012, 1028, 1046.
Landry's paralysis, 607.
Langhans, giant cells of, 436.
Laryngitis, catarrhal, 712; erysipelatous, 100, 495, 720; fibrinous, 713; phlegmonous, 720; syphilitic, 548; tuberculous, 453.
Laryngocele, 724.
Larynx, carcinoma of, 300; ecchondrosis of, 229, 724; ossification of, 723; papilloma of, 737; tuberculosis of, 453.
Lead poisoning, 139, 326; icterus in, 326; macies in, 327.
Leiomyoma, 257.
Leishmann-Donovan bodies, 397.
Lens, crystalline, anatomy of, 1005; coloboma of, 1012; equator of, 1005; false position of, 1011; foreign bodies in, 1011; luxation of, 1011; opacities of, 1006; ossification of, 1008; parasites in, 1011; regeneration of, 160; sclerosis of, 1007; trauma of, 1008; wandering, 1011.
Lenticonus, 1012.
Lentigo, 137.
Leontiasis, 236.
Lepra mutilans, 128.
Lepromata, 995; corneal, 995.
Leprosy, 530; Asturian, 576; of ciliary body, 1036; of choroid, 1046; conjunctival, 969; corneal, 995; of iris, 1024; of sclera, 1004.
Leptomeningitis, 593; optic, 1055.
Leptothrix bacillus, 425, 428.
Leucocytes, 666; emigration of, 164.
Leucocythemia, 671.
Leucocytoid cells, 167.
Leucocytosis, 663; agonal, 664; Arneth theory of, 668; cachectic, 664; digestion, 663; eosinophilic, 664; functional, 666; inflammatory, 664; pathologic, 664; physiologic, 663; pregnancy, 663; puerperal, 663; significance of, 666; terminal, 664.
Leucoderma, 131.
Leucoma, 965, 982; corneal, 998, 992.
Leucopenia, 663.
Leucoplakia, 752.
Leucorrhea, 877.
Leucosarcoma, 1040.
Leukanemia, 673.
Leukemia, 670; conjunctival deposits in, 971; hemorrhage in, 62; lymphatic, 254, 671; lymphoid, 671; medullary, 254; mixed, 671; myelogenous, 255, 671; retinitis in, 1066.
Lice, 351, 1086.
Lichen, 948.
Ligament, of crystalline lens, 1005; lateral, myoma of, 260; pectinate, 1017.
Ligation, of vessels, 75.
Lightning, effect of, 8.
Lime infarcts, in kidney, 846.
metastases, 94, 685.
Linguatula rhinaria, 355.
Linguatulidæ, 355.
Lip, carcinoma of, 273.
Lipochromes, 134.
Lipoids, 157.
Lipoma, 224; arborescens, 226; colloid, 225; capsulare, 226; conjunctival, 972; durum, 225; fibrous, 225; intestinal, 775; molle, 225; ossificans, 225; petrificum, 225; polyposum, 226; teleangiectodes, 225.
Lipomata, 224; abdominal, 786; abscess of, 225; hyperplastic, 224, 225; heteroplastic, 224, 226.
Lipomatosis, 107, 156; cardiac, 625; pancreatic, 812.
Liquor sanguinis, 96.
Lithiasis, 140, 143; conjunctival, 968.
Lithopedion, 94, 896.
Liver, abscess of, 798, 806; acini of, 788; amyloid, 148, 799; atrophy of, 114, 122; brown atrophy of, 114, 796; carcinoma of, 800, 809; cirrhosis of, 44, 796, 797; congestion of, 122; echinococcus of, 385, 799; fatty infiltration of, 791; fibromata of, 220; flukes of, 372; granular atrophy of, 122, 796; hyperplasia of, 803; lobulated, 550; nutmeg, 46, 791; red atrophy of, 790; regeneration of, 803; rot, 372; saffron, 806; sarcoma of, 809; secretion of, 787; secretory disturbances of, 347; simple atrophy of, 790; structure of, 787; syphilis of, 549; trematodes of, 799; tuberculosis of, 470; tumors of, 800; vessels of, 787; yellow atrophy of, 791, 793.
Livores, 52.
Lobar pneumonia, 532.
Locomotor ataxia, 604; optic neuritis in, 1054.
Locus invasionis, 6.
minoris resistentiæ, 4.
Lolium poisoning, 337.
Lordosis, 917, 918.
Louse, body-, 351; crab-, 352; clothes-, 351; head-, 351; pubic, 351.
Lucillia macellaria, 350.
Ludwig's angina, 813.
Lues venerea, 543; hereditary, 545.
Lumpy jaw, 484.
Lungs, abscess of, 542, 719, 729; accessory, 205; anemia of, 702; anthracosis of, 709; apoplexy of, 727; in asphyxiation, 708; atelectasis of, 704; atrophy of, 708; brown induration of, 45, 710; carcinoma of, 117, 300; carnification of, 540, 722; caseation of, 454; chalicosis of, 709; congestion of, 43; corpora amylacea in, 722; in drowning, 708; edema of, 96, 103, 539, 705, 710; embolism of, 727, 730; emphysema of, 706; enchondroma of, 234; fat embolism of, 730; fat-granule cells in, 117; gangrene of, 127, 129, 540, 542, 719, 725, 731; hemorrhage from, 56; hepatization of, 454, 555, 718; hyperemia of, 702, 711; hypertrophy of, 111; hypostasis of, 711; infarction of, 89, 90, 727; mycosis of, 418, 422; myxoma of, 229; osteoma of, 239; parenchyma of, 703; pigmentation of, 709; red induration of, 710; in renal disease, 103; siderosis of, 709; slaty induration of, 458, 709; splenization of, 706; stroma of, 703; syphilis of, 555; thrombosis of, 731; tuberculosis of, 452; tumors of, 736; white hepatization of, 555.
Lupus, 481; conjunctival, 969; erythematosus, 482.
Lutein, 134.
Luxations, 200, 932; congenital, 200, 932; spastic, 932.
Lymph, 686.

Lymph-glands, amyloid, 149; anatomy of, 694; endothelioma of, 306; psammoma of, 240; syphilis of, 549; tuberculosis of, 446.
scrotum, 358.
Lymphadenitis, 695; suppurative, 875; syphilitic, 549; tuberculous, 470.
Lymphangioma, 268; orbital, 1079.
Lymphangitis, 216, 659; acute, 946; tuberculous, 460.
Lymphatic tumors, 254, 672, 697.
Lymphemia, 671.
Lymphoblasts, 167.
Lymphocytes, 166; large, 662; small, 662.
Lymphoma, 697; leukemic, 672.
Lymphomata, 254, 672, 697; orbital, 1079.
Lymphomatosis, 674.
Lymphosarcoma, 251.
Lysis, 182.
Lyssa, 569.
Lytta vesicatoria poisoning, 320.

Macies, 114.
Macrocephalia, 201.
Macrodactylia, 201.
Macrogametes, 397, 402, 403.
Macroglossia, 201, 256.
Macrophages, 28, 411.
Macrosomia, 201.
Macrotia, 201.
Macula lutea, 1058, 1061.
Maculæ cœruleæ, 352; emortualis, 52, 711.
Madarosis, 1084.
Madura foot, 485.
Maidism, 576.
Malakoplakia, 855.
Mal de Caderas, 396.
la Rosa, 577.
perforant du pied, 128, 950.
Malaria, 398; in children, 407; chronic, 407; double quartan, 410; double tertian, 410; estivoautumnal, 406; destruction of erythrocytes in, 410; frequency of, 410; acquired immunity from, 408, 411; mixed infection in, 410; mortality from, 408; pernicious, 405, 408; pigment formation in, 133; quartan, 409; quotidian, 407; acute spleen tumor in, 412; tertian, 408; triple quartan, 410.
Male-fern poisoning, 336.
Malformations, 186, 201.
Malignancy, accidental, of tumors, 208; carcinoma, 287.
Malignant edema, 573.
endocarditis, 646.
syphilis, 557.
pustule, 488.
Malpighian corpuscles, of kidney, 816; of spleen, 688.
Malta fever, 520.
Malum senile corneæ, 998.
perforans, 950.
Mammæ, fibroma of, 218; carcinoma of, 295; inflammation of, 892; involution of, 119; tuberculosis of, 477 (see also Mastitis).
Manubrium, 1090.
Marasmus, 41, 114; sinus thrombosis in, 592.
Margaritoma, 281, 1094.
Mastitis, interstitial, 218, 892; lobularis, 219; obliterans, 892; tuberculous, 477; tuberous, 219.
Mastoid, caries of, 1094.
Mastoiditis, 1095.
Mastung, 156.
Maxillæ, mercurial necrosis of, 326; osteoma of, 235.
Mbu, 401.
Measles, 563; German, 564; Koplik's spots in, 563; otitis media in, 563.
Meat poisoning, 337, 338.
Meckel's diverticulum, 200.
Mediterranean fever, 521.
Megacolon, 774.
Megaloblasts, 675.
Megalokaryocytes, 437.
Megastoma entericum, 394.
Meibomian glands, 961, 1080; adenoma of, 1086; concretions in, 968; suppuration of, 1084.
Melæna neonatorum, 65, 67.
Melanemia, 675, 686.
Melanin, 132, 137, 412; in malaria, 400.
Melanocarcinoma, 241.
Melanoma, 240; of iris, 1025.
Melanosarcoma, 241, 1040.
Melanosis, 131; conjunctival, 997; corneal, 997.
Melanuria, 137, 675.
Melasma, suprarenal, 478.
Membrane, Bowman's, 977, 996; Bruch's, 1018, 1033; Descemet's, 977, 996; hyaloid, of vitreous, 1012; pyogenic, 173, 456; Sattler's, 1033.
Membranous colitis, 751; croup, 523, 525, 713.
Ménière's symptom-complex, 1096.
Meninges, syphilis of, 553; tuberculosis of, 439, 467.
Meningismus, 592.
Meningitis, basilar, 439, 467; cerebrospinal, 568; epidemic, 568; purulent, 591; tuberculous, 439, 467.
Meningocele, 197, 1074.
Menorrhagia, 61.
Menstruation, 39, 67, 892; blood of, 67, 892; vicarious, 61.
Mentagra, 419.
Mercurialism, 326.
Mercury poisoning, 325.
Merozoites, 397.
Mesoarteritis, 652.
Mesophlebitis, 652.
Mesothelioma, 304.
Metagenesis, 377, 405.
Metaglobulin, 73.
Metamorphosis, caseous, 443; fatty, of aorta, 119; fatty, of cornea, 119, 978.
Metaplasia, 105; lymphoid, 667; myeloid, 667.
Metastases, 93; blood pigment, 133; carcinoma, 288; embolic, 93; lime, 94, 685; silver, 94, 685; tumor, 83, 207, 209.
Metatypia, 108.
Metchnikoff, phagocytosis theory of, 28, 428.
Methemoglobin infarcts, 60.
Methemoglobinuria, 315.
Metorchis truncatus, 373.
Metremphraxis, 891.
Metritis, 887, 888; gonorrheal, 496.
Metrorrhagia, 884.
Microbrachius, 188.
Microcephalus, 187.
Microchelia, 193.
Micrococci, 424.
Micrococcus catarrhalis, 712.
gonorrhœæ, 495.
melitensis, 521.
Microcytes, 675.
Microgametes, 397, 403.
Microgametocytes, 397, 403.
Microglossia, 193.
Micromelus, 188.
Microphages, 28.
Micropus, 188.
Microrchidism, 200.
Microsomia, 192.
Microsporon furfur, 420.
Middle ear, cholesteatoma of, 282; disease of, in scarlatina, 562.
Miliaria, 948.
Milium, 944, 1086.
Milk glands, atrophy of, 120; carcinoma of, 295; hypertrophy of, 112; inflammation of, 892 (see also Mammæ).
Milzbrand, 490.
Mirbane-oil poisoning, 314.
Mite, Akamushi, 354; gooseberry, 354; grass, 354; hair-sac, 353; harvest, 354; itch, 353; Kedani, 354.

Mithridatism, 333.
Mitosis, 159, 402.
Molds, 415; brush, 415.
Mole, blood, 894; cavernous, 894; flesh, 894, hydatid, 227, 894; placental, 227; racemose, 227; vesicular, 227.
Moll's glands, 1089; obstruction of, 1085.
Molluscum contagiosum, 960, 1087.
Monas pyophilia, 394.
Monobrachius, 188.
Monopsia, 187.
Monopus, 188.
Monorchia, 189.
Monsters, double, 201; triple, 204.
Monstra duplica, 201; per defectum, 186; per excessum, 201; per fabricam alienam, 205; triplica, 204.
Morax-Axenfeld, bacillus of, 991.
Morbilli, lævis, 563; papulosi, 563.
Morbus Addisonii; see Addison's disease; cæruleus, 649; complicatus, 5; compositus, 5; maculosus, 63; multiplex, 5; simplex, 5; suffocatorius, 523.
Morel poisoning, 320.
Morgagnian bodies, 1006.
cataract, 1007.
Morphine poisoning, 333.
Morchella-esculenta poisoning, 315, 336.
Mortification, 53, 123.
Mosquito, in malaria, 400.
Mother cyst, of echinococcus, 385; marks, 264.
Mouches volantes, 1013.
Mucin, 152.
Mucoid degeneration, 151.
Mucor corymbifer, 416; mucedo, 417; rhizopodiformis, 416.
Mueller, ducts of, 194; fibers of, 1066; muscle of, 1028, 1082.
Multiple formation, 201; sclerosis, 604.
Mummification, 125.
Mumps, 574, 813.
Mures articulares, 226, 230, 232.
Muscle, abscess of, 936; angioma of, 264; atrophy of, 107, 114, 937, 938; hematoma of, 214, 514; hypertrophy of, 110, 937; necrobiosis of, 119; ossification of, 937; progressive atrophy of, 938; pseudohypertrophy of, 156; syphilis of, 552; tuberculosis of, 478; waxy degeneration of, 935.
Musculi arrectores pilorum, 52.
Myasthenia gravis, 700.
Mycelium, 415.
Mycetoma, 486.
Mycoderma cerevisiæ, 423.
Mycosis, corneal, 996; otitic, 418; pulmonary, 418; uterine, 891.
Mydriasis, 1019.
Myelemia, 671.
Myelin, 113, 157; hypertrophy of, 113.
Myelitis, compression, 600; optic neuritis in, 1055; transverse, 600.
Myelocytoma, 253.
Myeloma, 253.
Myeloplaxes, 437.
Myelosarcoma, 253.
Myelosis, aleukemic, 252; leukemic, 252.
Myiasis, 350.
Mylacephalus, 187.
Myocarditis, fibrous, 634; interstitial, 633; parenchymatous, 627; segmentaire, 631; suppurative, 634; syphilitic, 552.
Myocardium, 625; alterations of, 632; anemia of, 637; aneurisms of, 633; atrophy of, 626; fatty degeneration of, 625; infarction of, 638; lipomatosis of, 625; tumors of, 638; venous congestion of, 637.
Myodesopsia, 1013.
Myoma, 256; cavernous, 260; cystic, 260; hemorrhagic, 260; intestinal, 775; intraparietal, 259; of kidney, 849; lævicellulare, 257; submucous, 258; subserous, 258; striocellulare, 256; telangiectatic, 257, 260; uterine, 898.
Myosarcoma, 260; cystic, 260.
Myosis, 1019.
Myositis, gummous, 552; ossificans, 142, 239, 937; parenchymatous, 935; purulent, 936; tuberculous, 478.
Myringitis, 1089; proliferative, 1090; purulent, 1090; syphilitic, 1091; tuberculous, 1091.
Myringomycosis, 418.
Myxedema, 154.
Myxoenchondroma, 228.
Myxofibroma, conjunctival, 970.
Myxoma, 226; of breast, 229; of brain, 228; cartilaginous, 227; cystoid, 227; fibrous, 227; gelatinous, 226; heterologous, 226; homologous, 226; hyaline, 226; lipomatodes, 227; of lungs, 229; medullary, 227; of peripheral nerves, 228; placental, 227; of salivary glands, 229; telangiectatic, 227; testicular, 229.
Myxoneuroma, 261.
Myxosarcoma, 251.
Myxosporidia, 251.

Nabothian ovula, 883.
Naegele's pelvis, 917.
Nanosomia, 192.
Nasal duct, catarrh of, 975; occlusion of, 975.
Nasopharynx, polypi of, 224.
Necator americanus, 368.
Necrobiosis, 105, 113, 123, 155; muscular, 119; termination of, 118.
Necrobiotic atrophy, 105, 113, 116; cause of, 117.
Necrosis, 105, 123; anemic, 90; bone, 926, 927; coagulation, 124; fat-tissue, 124, 141, 813; in lipomata, 225; pancreatic, 813; from salvarsan, 329.
Negri bodies, 570.
Nematelminthes, 356.
Neoplasis, 106.
Nephritis, cardiac hypertrophy from, 635; catarrhal, 823, 848; in children, 824; desquamative, 823; chronic diffuse, 834; hemorrhagic, 561, 821; interstitial, 827; diffuse interstitial, 830; multiple interstitial, 829; parenchymatous, 821; acute parenchymatous, 824; of pregnancy, 341; scarlatinal, 561; suppurative, 827; syphilitic, 556; uremia in, 341; urica, 143 (see also Kidney).
Nephrolysins, 26.
Nephrophthisis, 472.
Nerve, optic, 1051; atrophy of, 1053, 1055; sarcoma of, 1058; syphilis of, 1055; tuberculosis of, 1056; tumors of, 1056.
Nerves, hypertrophy of, 113; myoma of, 228.
Nervous system, action of bacterium coli on, 783.
Nettle rash, 948.
Neuritis, axial, 1053; interstitial, 618; optic, 1052, 1055; peripheral, 581; retrobulbar, 1052.
Neuroepithelioma, 1072.
Neuroma, congenital, 262; hereditary, 262; orbital, 1079; plexiform, 262.
Neuromata, 261; amputation, 261; heteroplastic, 261.
Neuromatosis, hereditary, 262.
Neuroretinitis, albuminuric, 1064.
Neuroryctes hydrophobiæ, 570.
Neurotoxin, 320.
Nevi, 13, 264, 997.
Nevus, conjunctival, 970; flammeus, 264; lipomatodes, 264; pigmented, 137, 1025; varicose, 264; vascular, 264; venous, 264.
Newborn, cranial hematoma in, 212; hydrops renum cysticus in, 831; sudden death in, 325.
Nicotine poisoning, 335; effect of, on optic nerve, 1054.
Night blindness, 1034, 1066.

Nightshade poisoning, 337.
Nipple, Paget's disease of, 296; supernumerary, 11, 205.
Nissl bodies, 1063.
Nitrobenzol poisoning, 314, 315.
Noguchi-Wassermann serum test, 322.
Noma, 128, 753.
Normoblasts, 675.
Normocytes, 675.
Nose, Burgundy, 945.
Nosology, 1.
Nutmeg liver, 46, 122, 791.
Nutriments, absorption of, 104; elimination of, 3, 104.
Nutrition, disturbances of, 104.

Obesity, 107.
Occlusion, arteriomesenteric, of duodenum, 772.
Ochronosis, 134.
Odontoma, 238.
Oestreich, on development of carcinoma, 270.
Oïdium albicans, 420.
  lactis, 421.
Oil, mirbane, poisoning by, 314; mustard, poisoning by, 316.
O-legs, 915.
Oleum sinipis poisoning, 316.
Oligemia, 47, 683.
Omentitis, 780, 781.
Omphalocele, 198.
Onchospheres, 377.
Onychogryphosis, 952.
Onychomycosis, 952; favosa, 419.
Oöcyst, 397, 403.
Oökinet, 403.
Oöphoritis, fibrous, 781; follicular, 881; phlegmonous, 882.
Opacities, aqueous, 993; corneal, 993, 995; lens, 1006; striate, 994; vitreous, 1013.
Ophthalmia, catarrhal, 954; contagious, 958; Egyptian, 958; granular, 958; neonatorum, 955, 962; nodosa, 968; purulent, 954; sympathetic, 1032.
Ophthalmitis, metastatic, 1036; sympathetic, 1032; giant cells in, 1033.
Opisthorchis felineus, 373.
  noverca, 374.
  sinensis, 373.
Opium poisoning, 333.
Opsonic vaccination, 30.
Opsonins, 28.
Optic foramen, 1073.
  nerve, 1051; atrophy of, 1053, 1054; sarcoma of, 1058; syphilis of, 1055; tuberculosis of, 1056; tumors of, 1056.
  neuritis, in acromegaly, 1054; in locomotor ataxia, 1054; in myelitis, 1055; in general paresis, 1054; in syringomyelia, 1054.
Ora serrata, 1058.
Orbiculus ciliaris, 1027.
Orbit, abscess of, 1074; carcinoma of, 1080; cysts of, 1077; endothelioma of, 1080; emphysema of, 1075; exostosis of, 1075, 1078; fibroma of, 1078; fissures of, 1073; fistula of, 1076; glioma of, 1080; gumma of, 1077; lipoma of, 1078; lymphoma of, 1079; malformations of, 1074; neuroma of, 1079; osteitis of, 1077; periostitis of, 1076; phlegmon of, 1074; sarcoma of, 1080; size of, 1073; structure of, 1073; trichinosis of, 1077, 1078.
Orchitis, 868; parotitic, 575; syphilitic, 552; tuberculous, 475.
Organ cells as emboli, 83.
Organ disposition, 9.
Organization, of coagulum, 70; pathologic, 161.
Organoid tumors, 268.
Organozoa, 348.
Organs, absence of, 188; displacement of, 206; ductless, 344; reconstruction of, 109; vital manifestations of, 104.
Oriental boil, 397.
Ornithodorus moubata, 355, 503.
Os pubis, ecchondrosis of, 230.
Ossa præpubica, 239.
Ossicles, aural, ankylosis of, 1092; caries of, 1094; luxation of, 1092.
Ossification, 140, 904; of larynx, 723.
Osteitis, deformans, 928; degenerative, 926; syphilitic, 545; tuberculous, 479.
Osteochondritis, syphilitic, 546.
Osteoclasts, 437.
Osteoenchondroma, 233.
Osteoid tissue, 160, 903.
Osteoma, 235; choroidal, 1045; conjunctival, 972; cutaneous, 946; dental, 238; of dura mater, 590; fracturæ, 239; heteroplastic, 239; of sclera, 1004.
Osteomalacia, 924.
Osteomyelitis, 546, 902; fibrous, 928; gummous, 546; purulent, 926.
Osteophytes, 236, 905; of skull, 589.
Osteoporosis, 902.
Osteosclerosis, 903.
Osteotabes infantum, 63, 916.
Othematoma, 213, 1088.
Otitis externa, 1089.
  media, 562, 600, 1091; acute suppurative, 1095; adhesive, 1092; chronic polypous, 1092; purulent, 600; rubeolar, 563; scarlatinal, 562; sclerotic, 1092.
Otomycosis, 418.
Otorrhea, 1092.
Ovary, carcinoma of, 298, 883; cystoma of, 310, 312, 883; dropsy of, 880; endothelioma of, 883; fibroma of, 220; fibromyoma of, 261; hematoma of, 212, 882; internal secretion of, 346; neuroma of, 261; sarcoma of, 883.
Ovula Nabothii, 883.
Ovulation, hemorrhage during, 54.
Oxycephalus, 924.
Oxyuris vermicularis, 356.

Pacchionian granulations, 220, 594.
Pachycephalus, 924.
Pachydermia, 216.
Pachymeningitis, hemorrhagic, 56, 58, 133, 213, 590; internal fibrinous, 56, 58, 133, 213, 590; optic, 1055; ossifying, 590; purulent, 591; spinal, 593; syphilitic, 553.
Paget's disease, of bone, 928; of nipple, 296.
Pain, in inflammation, 164.
Palate, cleft, 197; endothelioma of, 306.
Pallor, in anemia, 50.
Panaritium, 946.
Pancreas, 810; accessory lobes of, 205; amyloid degeneration of, 811; anatomy of, 810; atrophy of, 811; calculus of, 140, 143, 812; carcinoma of, 299; cysts of, 812; fatty degeneration of, 107, 812; hemosiderin of, 133; in diabetes mellitus, 811; internal secretion of, 343; lipomatosis of, 107, 812; necrosis of, 813; ranula of, 812; siderosis of, 133; tuberculosis of, 478; tumors of, 813.
Pancreatitis, 810, 811; hemorrhagic, 811; interstitial, 811; parenchymatous, 810; purulent, 811.
Panniculus adiposus, 146, 154, 225, 238, 264, 358, 450, 965; amyloid degeneration of, 146; angioma of, 263, 264; enchondroma of, 234; filaria of, 358; hemorrhage of, 60; lipoma of, 225; mucoid degeneration of, 154; tuberculosis of, 450.
Pannus, 959, 987; eczematous, 987; degenerative, 988; phlyctenular, 988; scrofulous, 988; trachomatous, 987; vasculosus, 987.
Panophthalmitis, 984, 1029; pneumococcic, 984.
Papilla, of eye, 1058.
Papillitis, 1052.
Papilloma, conjunctival, 970; of eyelids, 1086; laryngeal, 737; of urinary bladder, 863.

Papules, cutaneous, 948.
Paracholia, 135.
Paracystitis, 853.
Paradacryocystitis, 976.
Paraffin workers' cancer, 273, 281.
Paraganglia, 345.
Paraglobulin, 73.
Paragonimus westermani, 373.
Paralysis, cardiac, 52, 628; Duchenne's, 604; infantile, 601; of insane, 595; intestinal, 784; Landry's, 607; of lungs, 52; progressive bulbar, 603; respiratory, 52; vascular, 38.
Paramecium coli, 414.
Parametritis, 836, 888, 895.
Parametrium, carcinoma of, 897; thrombophlebitis of, 895.
Paranephritis, phlegmonous, 827.
Parapedesis, 135, 347.
Paraphimosis, 874.
Paraproctitis, 549.
Paraprostatitis, 853, 871.
Parasite, fetal, 203.
Parasites, 348; abdominal, 786; animal, 348; blood, 398; intestinal, 348, 349, 350, 360; vegetable, 423.
Parathyroid glands, 746.
Parathyroiditis, 745.
Paratyphoid fever, 515, 518; bacillus of, 339, 518.
Parenchyma, 154.
Paresis, 69, 91, 92, 1054; from cerebral hemorrhage, 69; from embolism, 91, 92; optic neuritis in, 1054.
Paronychia, 952.
Parotid glands, 810; calculi of, 143, 814; carcinoma of, 814; cysts of, 814; enchondroma of, 814; endothelioma of, 305; ranula of, 215, 814; tumors of, 814; tuberculosis of, 450, 478.
Parotitis, epidemic, 574, 813; metastatic, 575; phlegmonous, 575; tuberculous, 450, 478.
Paroxysms, febrile, 183, 400.
Pars optica retinæ, 1058.
Patella, absence of, 188.
Pater noster rachitis, 912.
Pathologic anatomy, general, 1; special, 1.
Pathology, definition of, 1.
Pearl cysts, of iris, 1024.
  disease, of cattle, 441.
  tumor, 281.
Pearls, cancroid, 280; epitheliomatous, 280.
Pectus gallinaceum, 914.
Peculiarities, racial, 11.
Pediculus capitis, 351.
  pubis, 351.
  tabescentium, 351.
  vestimenti, 351.
Peliosis rheumaticus, 63.
Pellagra, 576; sine pellagra, 578.
Pellarella, 577.
Pelveoperitonitis, 213, 500, 784, 786, 836, 870, 888, 891.
Pelvis, malacosteon, 926; Naegele's, 917; oblique, 933; ossification of, 910; osteomalacic, 926; rachitic, 236, 915; Robert's, 917; spinosa, 236.
Pemphigus, 948; chronicus, 948; conjunctival, 969; leprous, 532; syphilitic, 948.
Penis, absence of, 189; carcinoma of, 877; chancre of, 874; chancroid of, 874; deformity of, 876; fracture of, 876; hypoplasia of, 193; luxation of, 876; malformations of, 189, 193, 198, 201; stricture of, 110, 496, 837; tuberculosis of, 875; tumors of, 877.
Pennicillium glaucum, 416; in keratitis, 996.
Pentamethylendiamin, 338.
Pentastoma denticulatum, 355.
  tænoides, 355.
Pentastomum constrictum, 355.
Perforation, appendicular, 761, 782; of bladder, 863, 888; corneal, 962, 982; of gall-
Perforation (*concluded*).
  bladder, 809; in tuberculosis, 461, 782; in typhoid fever, 512; intestinal, 444, 456, 459, 760, 768; of sclera, 1003; of stomach, 287, 291, 768, 782; of tympanum, 1090, 1092.
Periarteritis, 652.
Periarthritis, 238.
Peribronchitis, fibrous, 556, 720.
Pericarditis, 522, 622; adhesive, 180, 624; callosa, 624; exudative, 180, 624; fibrinous, 624, 625; fibrinopurulent, 623, 624; hemorrhagic, 62, 622, 624; hydrofibrinous, 623; ichorous, 624; purulent, 174, 624, 634; recurrent, 465, 625; sicca, 623; tuberculous, 465, 625.
Pericardium, 180, 622; abscess of, 723; adhesions of, 180, 624; hemorrhage into, 62, 622, 624; hydrops of, 96, 103, 622; maculæ tendineæ of, 180, 622, 624; obliteration of, 465, 624; pneumo-, 625; tuberculosis of, 465, 625.
Perichondritis, auriculæ, 213; chronic, 723; gummous, 548; laryngeal, 514, 548, 722, 723; pulmonary, 722; purulent, 548, 722.
Perichondrium, deposits of urates in, 143; aural, 1088.
Perigastritis, 767.
Perihepatitis, 551.
Perimetritis, 887, 888; adhesive, 836, 888, 891; gonorrheal, 497; fibrinous, 214; hemorrhagic, 213, 786, 892; purulent, 895.
Perimetrium, adhesions of, 836, 888, 891 (see also Perimetritis).
Perinephritis, purulent, 827.
Perineum, injuries of, 896.
Perineuritis, 618; leprous, 532; optic, 1055.
Periorchitis, 866, 868; adhesive, 496, 867; fibrinous, 868; fibrous, 868; gonorrheal, 469; hemorrhagic, 67, 867; proliferative, 867; purulent, 868.
Periostitis, 236, 480, 545, 904, 926; caseous, 480, 917; gummous, 545; ossifying, 236, 328, 479, 480, 545, 904; purulent, 123, 479, 926; spinalis interna, 593; tuberculous, 480, 917.
Periostoses, 236.
Peripheral nerves, atrophy of, 618.
Periphlebitis, 652.
Peripneumonia, 539.
Periproctitis, 549, 853.
Periprostatitis, 853.
Perisplenitis, adhesive, 693; callosa, 180, 694; fibrinous, 693; fibrous, 694; ichorous, 693; nodosa, 694; purulent, 693.
Perithelioma, 304, 306, 1026, 1041; choroidal, 1041; of ciliary body, 306; of iris, 1026.
Peritoneum, adhesions of, 180, 761, 781; carcinoma of, 285, 293, 786; colloid carcinoma of, 285, 293; cysticercus of, 786; echinococcus of, 389, 786; endothelioma of, 303, 786; hemorrhages of, 60, 61, 70, 213, 786; lipoma of, 786; parasites of, 786; pentastomum of, 355, 786; psammocarcinoma of, 240, 290, 786; trichinosis of, 361, 781; tuberculosis of, 462, 463, 464, 781; tumors of, 786.
Peritonitis, adhesive, 180, 761, 693, 781; callosa, 781; carcinomatous, 293, 780, 786; acute, 781; colon bacillus in, 782, 783, 784; fibrinopurulent, 782, 871; fibrinous, 178, 464, 465, 781, 782, 871; fibrous, 781; gonorrheal, 497; hemorrhagic, 213, 303, 786; hydrofibrinous, 462, 780; in gastric ulcer, 768; in strangulated hernia, 770; in typhoid fever, 512; pelvic, 213, 500, 761, 784, 786, 836, 870, 888, 891; perforative, 285, 293, 461, 781, 785, 786, 871; purulent, 177, 389, 761, 781, 782, 784, 871; putrid, 298, 299; serous, 780; stercoral, 761, 782; tuberculous, 462, 463, 464, 781; ulcerative, 785; villous, 781.
Perityphlitis, 466, 782, 784; adhesive, 693, 781; purulent, 178, 761, 782, 784; stercoral, 761, 782.

Periurethritis, gonorrheal, 496.
"Perlsucht," of cattle, 441.
Pernicious anemia, 48, 678; hemorrhage in, 62.
malaria, 405; mortality from, 408.
Perniones, 949.
Perobrachius, 188.
Perodactylia, 188.
Peromelus, 188.
Peropus, 188.
Pertussis, 564.
Pes calcaneus, 200.
equinovalgus, 200.
equinovarus, 200.
equinus, 200.
planus, 200.
valgus, 200, 915, 922.
varus, 200, 921.
Pest, bubonic, 497; bacillus of, 498.
Petechiæ, 63, 64, 565, 943; cutaneous, 63, 64, 943; in typhus fever, 565; of urinary bladder, 853.
Petit, canal of, 1005.
Petrification, 140, 723, 928; of cartilage, 928; of crystalline lens, 141, 1008.
Petrous bone, Spirochæta pallida in, 1097.
Pfeiffer's reaction, 517.
Phæchrome, 345.
Phagocytes, 28, 167, 428.
Phagocytosis, 28, 30, 168; theory of, 428.
Phagolysis, 29.
Phallin poisoning, 315.
Pharyngitis, catarrhal, 128, 255, 713, 757; diphtheritic, 127, 128, 178, 525, 526, 560, 561; fibrinous, 178, 525, 756; follicular, 255, 756; granulosa, 448, 757; in poisoning, 317; in typhoid fever, 514; lævis, 717; leprous, 531; mycotic, 421; scarlatinal, 526, 561; syphilitic, 548; tonsillar, 255, 525, 757; tuberculous, 450, 454; variolous, 526, 560.
Pharynx, carcinoma of, 290; diphtheria of, 128, 525; malformations of, 189; thrush fungus of, 421; syphilis of, 548; tuberculosis of, 450, 454.
Phimosis, 874, 875; acquired, 874; congenital, 190, 875.
Phlebitis, 651; purulent, 76, 81, 651, 652.
Phlebectasis, 34, 657.
Phleboliths, 80, 140, 873; prostatic, 873.
Phlegmasia alba dolens, 78, 99, 102, 103.
Phlegmon, 127, 128, 173, 429, 500, 785; cutaneous, 946; gaseous, 570; gastric, 765, 778; orbital, 1074, 1077; retrocecal, 785; retroperitoneal, 785; woody, 687.
Phlogosis, 163.
Phlyctenular conjunctivitis, 963.
Phocomelus, 188.
Phosphorescence, of bacteria, 427.
Phosphorus poisoning, 59, 327, 425; hemorrhage in, 59, 327, 435.
Phrynin poisoning, 320.
Phthirius pubis, 352.
Phthisis, black, 139; bronchiectatic, 725; bulbi, 1029, 1030, 1034, 1036, 1039; florida, 455; galloping, 455; laryngeal, 453; nigra, 139; heart hypertrophy in, 110, 635; pigmentosa, 139; acute pulmonary, 455; tuberculous, 455; ulcerative, 444, 456.
Physalides, 229.
Physostigmine poisoning, 337.
Pigeon tick, 354.
Pigment cells, 131, 1040.
defects, 131.
infarcts, renal, 843.
marks, 264.
metastases, 133, 843.
retinal, 1063, 1065.
stones, 808.
tumors, 240, 1025.
warts, 137.
Pigmentation, 130; cutaneous, 131, 137, 344, 478, 621, 942.
Pigments, blood, 70, 131; foreign, 138, 686; foreign, in blood, 686; hematic, 131, 132; metabolic, 131, 138.
Piles, 65, 265.
Pilocarpine poisoning, 337.
Pineal gland, 345, 616; sand grains in, 239.
Pinguecula, 946.
Piroplasma hominis, 566.
Pituitary gland, tumors of, 616.
Pityriasis versicolor, 420.
Placenta, infarcts of, 90; myxoma of, 227; polypi of, 899; sanguinis, 73; syphilis of, 11.
Placentoma, 899.
Plagiocephalus, 924.
Plague, bubonic, 497; bacillus of, 498.
Plaques, conjunctival, 972; epithelial, 972; jaunes, 133, 613.
Plasmocytoma, 253.
Plasmodium malariæ, 409; præcox, 405, 407; vivax, 408.
Platyelminthes, 371.
Plaut-Bernheim ulcer, 529, 573.
Plethora vera, 683.
Pleura, adhesions of, 43, 180, 458, 735; hemorrhages into, 60, 61, 62, 67, 69, 303, 734, 737; carcinoma of, 117, 303, 734, 735, 736, 737; endothelioma of, 304, 306, 736; osteoma of, 239; sarcoma of, 737; syphilis of, 555; tuberculosis of, 446, 465, 466, 734.
Pleuritis, 127, 458, 465, 539, 540, 722, 733, 734, 736; adhesive, 43, 180, 458, 735; callosa, 458, 736; carcinomatous, 300, 303, 735; deformans, 721, 736; fibrinous, 74, 178, 446, 465, 539, 734, 735, 784; fibrosa retrahens, 556, 722; gangrenous, 127, 719; hemorrhagic, 69, 303, 734, 737; hydrofibrinous, 734; ichorous, 127, 729, 735; purulent, 174, 540, 729, 734, 784; putrid, 127, 729, 735; serous, 733; sicca, 734; tuberculous, 446, 465, 466, 734.
Pleuropneumonia, fibrinous, 533, 539.
Plexus annularis, of cornea, 978.
vesicalis, thrombosis of, 854.
Plica semilunaris, 964.
Plumbum aceticum, poisoning by, 326.
Pneumathemia, 84, 685.
Pneumatosis cystoides, 571.
Pneumaturia, 520.
Pneumobacillus, 533.
Pneumococcus, 533; in conjunctivitis, 956, 963; in keratitis, 981; in panophthalmitis, 984, 1035; in lobar pneumonia, 533.
Pneumonia alba, 555, 719.
apostematosa, 127, 729, 735.
aspiration, 129, 290, 299, 314, 607, 719, 732.
broncho-, 717.
catarrhal, 177, 717.
central, 719.
circum tuberculs, 446, 465.
croupous, 532, 713.
embolic, 129, 714, 729.
fibrinous, 74, 178, 446, 465, 532, 539, 713, 721, 784.
fibrous, 556, 719, 721.
gangrenous, 129, 719, 729.
gonorrheal, 497.
hemorrhagic, 63.
hypostatic, 45, 711.
ichorous, 127, 729, 735.
interlobular, 556, 721.
interstitial, 556, 721.
lobar, 67, 532, 713; age and, 536; albuminuria in, 542; bacillus of, 533; clinical symptoms of, 541; complications of, 542; crisis in, 541; fever in, 541; icterus in, 542; lysis in, 541; micrococcus of, 533; morbidity of, 535; mortality in, 542; predisposing causes of, 535; pulse in, 541; resolution stage of, 538; sex and, 535; site of, 541; stadia of, 536; tuberculosis in, 542.

Pneumonia, lobular, 727.
metastatic, 727.
mycotic, 418, 422, 718.
nodosa, 719.
pleuro-, 533, 539.
purulent, 729.
resolution of, 538.
septic, 727.
spuria, 705.
syphilitic, 555, 556.
tuberculous, 455, 542.
Pneumonokoniosis, 132, 138, 709.
Pneumonomalacia, 719, 754.
Pneumonomycosis, 418, 422, 718.
Pneumopericardium, 625.
Pneumothorax, 735, 736.
Pneumotoxin, 535.
Pock, anthrax, 490; variola, 558.
Poikilocytes, 49, 675.
Poikilocytosis, 675.
Poisoning, 7, 313; abrus, 316; acetic acid, 318; agaric, 335; alcohol, 332, 796; ammonia, 319; anesthetic, 333; antitoxin, 325; arsenic, 60, 328; arsenlureted hydrogen, 133, 675, 844; atropine, 334; belladonna, 334; bufidin, 320; calabar bean, 337; cantharidin, 320; carbolic acid, 316, 319, 844; carbonic oxide, 314; carbon dioxide, 314; caustic alkali, 316; cheese, 337; chloral hydrate, 332; chlorine, 316; chloroform, 333; cocaine, 334; cockgrass, 337; colchicum, 336; conium, 337; croton oil, 174, 337; darnel, 337; daturia, 337; digitalis, 335; ergotin, 128, 332; eserine, 337; ether, 333; ethyl bromide, 333; felix mas, 336; fish, 337; fly fungus, 335; foxglove, 335; helvella, 315; hemlock, 336, 337; henbane, 337; hydrochinon, 315; hydrochloric acid, 318; hydrocyanic acid, 314; hyoscyamus, 337; illuminating gas, 314; insect, 320; iodine, 315, 743; Jimson weed, 337; juniper, 337; laughing gas, 332; lead, 139, 326; lolium, 337; lytta vesicatoria, 320; male fern, 336; meat, 337, 338; mercury, 60, 325; morel, 321; morphine, 333; morchella, 315, 336; muscarin, 315; nicotine, 335, 1054; nitric acid, 318; nitrobenzol, 314; oleum sinipis, 316; opium, 333; oxalic acid, 319; ozone, 315; phallin, 315; phosphorus, 59, 327; phrynin, 320; physostigmine, 337; pilocarpine, 337; potassium chlorate, 60, 843; potassium cyanide, 314; potassium oxalate, 319; potato, 337; prussic acid, 314; pyrogallol, 315, 844; quinine, 335; ricin, 316; saffron, 336; salicylic acid, 316; santonin, 337; sausage, 337; savin, 337; secale cornutum, 50, 128, 332; serpent, 320; silver nitrate, 7, 94, 316; spotted parsley, 337; stinkweed, 337; stramonium, 337; strophanthin, 337; strychnine, 334; sulphureted hydrogen, 315; sulphuric acid, 318; thorn apple, 337; tobacco, 335, 1054; turpentine, 174; vegetable, 337, 339; vermuth, 336; zinc chloride, 316.
Poisons, 313; action of, on blood-vessels, 59; animal, 320; blood, 313, 315, 320, 681; corrosive, 316; heart, 332, 699; nerve, 332; mineral, 314; vegetable, 334, 337, 339.
Polioencephalitis, 611.
Poliomyelitis, acute, 601.
Polyblasts, 167.
Polycholia, 510.
Polychromatophilia, 682.
Polycoria, 1027.
Polycythemia, 683; splenomegalic, 683.
Polydactylia, 11, 204.
Polyemia, 683.
Polyglobulism, 683.
Polymastia, 11, 205.
Polymelia, 204.
Polyneuritis epidemica, 581.
Polypi, aural, 1090; of cervix uteri, 884; of endometrium, 59; gastric, 765; intestinal, 256; laryngeal, 737; nasal, hemorrhage in, 59; nasopharyngeal, 224; placental, 899; uterine, hemorrhage in, 59, 884.
Polysarcia, 107, 217, 625.
Polythelia, 11, 205.
Polyuria, 33.
Ponfick's shadow, 676.
Porencephalus, 604.
Porocephalus constrictus, 355.
Porri, 223.
Port wine mark, 264.
Post-mortem coagulation of blood, 74.
spots, 52, 711.
Posterior spinal sclerosis, 604.
Potassium chlorate poisoning, 60, 315; hemorrhage from, 60.
cyanide poisoning, 314.
oxalate poisoning, 319.
Potato poisoning, 337.
Pott's disease, 479, 917.
Precipitins, 21, 25.
Predisposition, 6, 310; acquired, 8; congenital, 8; inherited, 8; local, 9, 310.
Pregnancy, abdominal, 896; eclampsia in, 341; ectopic, 784, 895, 896; hyperemia on advent of, 54; hypertrophy of mammæ in, 112; interruption of, 893; leucocytosis in, 663; nephritis in, 341; ovarian, 896; scars, 952; thyroid tumor in, 743; tubal, 896; uterine changes in, 110, 111, 260; vascular dilation in, 34, 658.
Prepuce, absence of, 189; adhesions of, 874; atrophy of, 874; calculi of, 875; edema of, 874, 875; elephantiasis of, 877; excoriations of, 874; herpes of, 875; paraphimosis of, 874; phimosis of, 874, 875; stones of, 875; ulcers of, 874, 968; tuberculosis of,
Presbyopia, 1005.
Pressure, blood-, cause of, 37; intraocular, 1000, 1047, 1049; atrophy, 121; vascular, 41.
Prickly heat, 948.
Processes, active, 4; constructive, 3; formative, 3; functional, 3; nutritive, 3; passive, 4; physiologic, 3.
Procidentia uteri, 889.
Proctitis, 870; diphtheritic, 526; syphilitic, 549; ulcerative, 549.
Proglottides, 377.
Prognosis, 3.
Prolapsus, of anus, 772; of iris, 532; of rectum, 772; of uterus, 260, 889; of vagina, 108, 890; of vitreous body, 1013.
Proliferation, 3, 180.
Proptosis, 1058, 1075.
Prosopothoracopagus, 203.
Prostate, abscess of, 870; adenoma of, 309; atrophy of, 873; calculi of, 140, 143, 873; carcinoma of, 302, 873; corpora amylacea of, 145, 873; hypertrophy of, 112, 836, 871; hypoplasia of, 193; myoma of, 256; phleboliths of, 873; tuberculosis of, 474; tumors of, 873.
Prostatitis, 870; apostematosa, 870; fibrous, 872; gonorrheal, 496; tuberculous, 474.
Prostatorrhea, 871.
Protection, postinfectious, 19; vaccine in typhoid fever, 517.
Proteins, bacterial, 175.
Proteolysis, 175.
Prothrombin, 73.
Protozoa, 392; metastases, 93.
Proud flesh, 180.
Prurigo, 943.
Prussic acid poisoning, 314.
Psammomata, 142, 239; of optic nerve, 1056.
Psammocarcinoma, 240, 290.
Psammosarcoma, 240.
Pseudoankylosis, 934.
Pseudoarthrosis, 907.
Pseudocylindroids, urinary, 842.

Pseudoencephalocele, 187, 197.
Pseudocysts, 1078.
Pseudoglioma, 1036, 1071.
Pseudohermaphroditism, 193.
Pseudohyperplasia, 253.
Pseudohypertrophy, 109; muscular, 156, 937.
Pseudoleukemia, 253, 674; gastrointestinal, 256; myeloid, 252.
Pseudomegacolon, 774.
Pseudomelanosis, 134.
Pseudomenstruation, 54, 893.
Pseudopodia, 393.
Pseudopterygium, 965.
Pseudotubercle, of choroid, 1033.
Psittacosis, 712.
Psoitis, 479.
Psoriasis, 948; of tongue, 752.
Psorospermia, 414.
Pterygium, 964.
Ptomaines, 338.
Ptomatropin, 339.
Ptosis, 1085; congenital, 1086.
Ptyalism, 753.
Ptyalorrhea, 753.
Puerperal fever, 894.
sepsis, 501, 894.
Puerperium, struma in, 743.
Pulex irritans, 349, 379.
penetrans, 349.
serraticeps, 379.
Pulsation, in hyperemia, 38, 39.
Pulse, venous, 630.
Pupil, 1017; Argyl-Robertson, 1019; paralysis of, 1019; synechiæ of, 984.
Purple, visual, 1061.
Purpura, 62, 63, 68, 943.
Pus, 174; laudable, 174.
Pustule, 173; anthrax, 128, 488; bubonic, 497; malignant, 488, 490; variola, 558.
Putrefaction, 53, 125; toxins of, 338.
Putrescin, 338.
Putrid softening, in edema, 102.
Pyarthros, 174, 177.
Pyelitis, 177, 828; catarrhal, 828, 853; diphtheritic, 828, 854, 855; fibrinous, 854; purulent, 828, 854; tuberculous, 471, 828, 860; ulcerative, 853.
Pyelonephritis, 177, 828.
Pyemia, 501; icterus in, 136.
Pylorus, atresia of, 199; carcinoma of, 287, 293; stenosis of, 774; ulcer of, 768.
Pyogenic membrane, 173, 599.
Pyopagus, 202.
Pyopneumothorax, 729.
Pyorrhea, alveolar, 930; conjunctival, 962.
Pyosalpinx, 886.
Pyramids, of Ferrein, 816.
Pyretogenetic substances, 181.
Pyrogallol poisoning, 315, 844.

Quartan fever, 409.
Quarter evil, 126.
Quincke's disease, 1082.
Quinine, in malaria, 411; poisoning by, 335.
Quinsy, 757.

Rabies, 569.
Race, influence of, 9, 11; peculiarities of, 11, 131.
Rachitis, 11, 233, 236, 910; congenital, 915; pater noster, 912.
Radius, absence of, 188.
Rainey's tubes, 414.
Ranula, pancreatic, 215, 812; parotid, 215, 814; sublingual, 215, 814; submaxillary, 814.
Raphania, 50, 128, 332.
Rauschbrand, 126.
Ray fungus, 483.
Raynaud's disease, 128.
Rays, medullary, of kidney, 816.
Reaction, 427; agglutination, 21, 517; Berlin-blue, 132; Calmette, 439; Gruber-Widal, 517; leucocytic, 664; Pfeiffer's, 517;
Reaction (*concluded*).
tuberculin, 439; von Pirquet's, 439; Wassermann-Bruck, 321, 330.
Receptors, 22.
Recidive, 3; of tumors, 209, 288.
Rectum, carcinoma of, 286, 295; diphtheria of, 526; fistula of, 776; prolapse of, 772; stricture of, 549; syphilis of, 549; tuberculosis of, 444, 450, 459; varices of, 65, 265.
Recurrent fever, 502.
Regeneration, 158, 261, 618, 803, 905, 906; pathologic, 158; physiologic, 159.
Relapse, 3.
Relatives, influence of repeated intermarriage of, 2.
Remission, of fever, 184.
Remittent fever, 184.
Renal disease, pulmonary edema in, 103 (see also Nephritis).
Renes arcuati, 193.
Renicull, of kidneys, 815.
Reproduction, 158.
Resolution, in pneumonia, 178, 538, 719.
Resorption, of bone lacunæ, 902; chyle, disturbance of, 114, 149; of extravasates, 69; of fat, 118; of hydropsic fluid, 103.
Respiratory system, anatomy of, 701 (see also Lungs).
Restoration, 158.
Retention, fat, 118; of testes, 200, 210, 233, 869; of milk, 892; of teeth, 238; of tumors, 215; of urine, 69.
Retina, 1051; anatomy of, 1059; angiopathic, 1064; atrophy of, 1065; blood-vessels of, 1062, 1069; cystoid degeneration of, 1062, 1069; detachment of, 1070; edema of, 1068, 1069; glioma of, 243, 1071; gliosarcoma of, 243; hemorrhage of, 62; in general arteriosclerosis, 1063; infarction of, 89; neuroepithelioma of, 1072; pathology of, 1058; pigmented epithelium of, 1063; rupture of, 1071; senile degeneration of, 1064; syphilis of, 1072; thrombosis of vein of, 1070; tuberculosis of, 1072.
Retinitis, albuminuric, 1063, 1064; circinata, 1067; chronic, 1062; diabetic, 1064; hemorrhagic, 1063, 1067; leukemic, 1066; metastatic, 1068; pigmentary, 1065; proliferans, 1062, 1066; punctate, 1066; purulent, 1068, 1070; septic, 1068; syphilitic, 1072; tuberculous, 1072.
Retraction, of chordæ tendineæ, 640; of heart valves, 640; of scar-tissue, 180.
Retroflexion, of uterus, 888.
Retropharyngeal abscess, 758.
tumors, 224.
Retrotracheal abscess, 716.
Rhabdomyoma, 256.
Rhachipagus, 203.
Rhachischisis, 197.
Rhagades, 217, 944.
Rheumatism, articular, 930; gonorrheal, 497.
Rhexin, hemorrhagia per, 56.
Rhinitis, 575; acute, 178, 563, 711, 712; catarrhal, 177, 563, 564, 711, 712; fibrinous, 178; in measles, 563; purulent, 177; putrid, 179, 448; sicca, 177.
Rhinoscleroma, 573.
Rhizopoda, 392.
Ribs, actinomycosis of, 485; fracture of, 906; malformations of, 187, 188, 189, 205.
Rice bodies, 456, 938, 939; of tendon sheaths, 938, 939; in pulmonary cavities, 456.
Rice-water stools, 506, 329; in arsenic poisoning, 329; in cholera, 506, 753.
Ricin poisoning, 316.
Rickets, 236, 910; cataract in, 1009 (see also Rachitis).
Rickety rosary, 912.
Rictus lupinus, 197.
Riders' bone, 142, 239.

Rigor mortis, 51, 52, 650; of arteries, 51, 650; of heart, 52.
Ringworm, 420; of eyelids, 1087 (see also Tinea).
Riolan, muscle of, 1082.
Robert's pelvis, 917.
Rocky Mountain fever, 565.
Rods and cones, retinal, 1059.
Roethein, 564.
Rosary, rickety, 912.
Rose, 433, 434, 493.
Roseola, syphilitic, 547.
Rostellum, of tapeworm, 382.
Rot, 372.
Rotz, 491.
Round worms, 356.
Round-celled sarcoma, 246.
Round ligament, adenoma of, 309.
Rubella, 564.
Rubeola, 563; arthritis in, 931.
Rubor, in inflammation, 170.
Rupture, of aneurisms, 59, 622, 658, 734, 786; of aorta, 59, 622, 658, 734, 786; of Fallopian tubes, 896; of heart, 622, 631; of intervertebral disks, 907; of liver, 786, 798; of muscle, 61, 936; of retina, 1071; of spleen, 694, 786; of sclera, 1003; of uterus, 896; of varices, 659; of vessels, 55, 59, 622, 658, 734, 786.

Saber legs, 915.
Saber-sheath trachea, 741.
Sac, lachrymal, 975; atony of, 975.
Saccharomyces cerevisiæ, 423.
ellipsoides, 423.
in hypopyon, 996.
Sacrum, tumors of, 262.
Saffron liver, 806.
yellow, poisoning by, 336.
Sago spleen, 148, 693.
Salicylic acid poisoning, 316.
Salivary glands, 810; calculi of, 143, 814; carcinoma of, 300; endothelioma of, 305; myxoma of, 229; tuberculosis of, 450, 478.
Salivation, 326, 391, 753.
Salpingitis, catarrhal, 880; gonorrheal, 496, 781; purulent, 496, 781, 886; tuberculous, 477.
Salvarsan, 329; toxic action of, 330.
Sanatio, 5; incompleta, 5.
Sand, brain, 616; flea, 349; granules, 142, 239, 616; tumors, 142, 239, 616.
Santonin poisoning, 337.
Saprophytes, 428.
Sarcinæ, 424; ventriculi, 428.
Sarcoma, 243; adeno-, 251; alveolar, 247; amyloid change in, 146; angio-, 266, 304; annular, 1031; appendicular, 777; choroidal, 1038; conjunctival, 971; cystic, 249; deciduocellulare, 899; endothelial, 303; fasciculatum, 249; fibro-, 251; fusocellulare, 246; gastric, 776; giant-celled, 248; glandular, 251; globocellulare, 246; intestinal, 775, 777; lympho-, 251; melano-, 247; myelo-, 249, 253; myxo-, 250, 251; orbital, 1030; osteo-, 248; ovarian, 883; parosteal, 249; prostatic, 873; reticular, 246; retroperitoneal, 250; ring, 1031; round-celled, 246; of sclera, 1004; spindle-celled, 246; of stomach, 776; tubular, 305; uveal, 1014; varieties of, 246; of vessel walls, 250.
Sarcoptes scabiei, 353.
Sattler's membrane, 1033.
Sausage poisoning, 337.
Savin poisoning, 337.
Scabies, 353.
Scall, humid, 948; running, 948.
Scapula, absence of, 188.
Scarification, sequelæ of, 102, 127.
Scarlatina, 8, 39, 61, 160, 433, 435, 526, 561, 562, 691, 696, 745, 821, 931, 943; arthritis in, 931; desquamation in, 39, 561; diphtheria in, 525, 561; hemorrhage in, 61, 821, 943; lymphadenitis in, 696; nephritis in, 561, 821; thyroid in, 562, 745; spleen tumor in, 691.
Scarlet fever, 561 (see also Scarlatina).
Scars, radiate, in syphilis, 547, 548, 556; of gravidity, 952; cutaneous, 101, 952.
Scheele's green, poisoning by, 328.
Schistoprosopus, 187.
Schistosomum cattoi, 376.
hæmatobium, 60, 864.
japonicum, 376.
mansoni, 375.
Schizogony, 397, 400, 404, 405.
Schizomycetes, 423.
Schizont, 397.
Schizotrypanum cruzi, 396.
Schlemm, canal of, 1017, 1048, 1049.
Scirrhous carcinoma, 277, 292 (see also Carcinoma).
Sclera, abscess of, 1004; anatomy of, 999; cysts of, 1004; ectasis of, 1004; hypertrophy of, 1003; leprosy of, 1004; rupture of, 1003; sarcoma of, 1004; syphilis of, 1000; trauma of, 1002; tubercle of, 1004; tumors of, 1004.
Sclerema neonatorum, 102.
Scleritis, 999, 1000; annular, 1001; syphilitic, 1000; Wassermann test in, 1000, 1001 (see also Sclera).
Scleroderma, 942, 949.
Sclerokeratoiritis, 980.
Sclerophthalmus, 979.
Sclerosis, amyotrophic lateral, 606; diffuse, 604; multiple, 604; posterior spinal, 604.
Scolex, 379, 380, 384, 974, 1014, 1025.
Scoliosis, 917; habit, 918.
Scorbutus, 62, 130, 732, 734; hemorrhage in, 62.
Scorpion poisoning, 320.
Scratch test, 441.
Scrofula, 446, 696; ulceration in, 447.
Scrofulosis, 49, 436, 446, 447, 696.
Scrotum, elephantiasis of, 215, 358; epithelioma of, 273, 281; white gangrene of, 102, 127; hydrocele of, 866; lipoma of, 226; lymph, 216, 358; myoma of, 257.
Scurvy, hemorrhage in, 62; alpine, 576 (see also Scorbutus).
Scutula, 419.
Sebaceous cysts, 944, 1086; of eyelids, 1086; tumors, 944.
Seborrhea, 944, 1086; oleosa, 944; squamosa, 944.
Secale cornutum, gangrene from, 128; poisoning, 50, 128, 332.
Secretions, hemorrhagic, 67; internal, 343.
Secretin, 344.
Sedes morbi, 6.
Semicircular canals, hemorrhage into, 1096.
Seminal duct, atresia of, 200; absence of, 189; calculi of, 869; catarrh of, 869; dilation of, 869; lipoma of, 877; obliteration of, 869; tuberculosis of, 475; varicocele of, 658.
fistula, 476.
vesiculitis, 475, 869; catarrhal, 869; fibrous, 869; gonorrheal, 496; obliterating, 869; tuberculous, 475.
Senescence, 41, 121; juvenile, 41, 121.
Senile atrophy, 41, 121, 603, 1064.
degeneration, 41, 121, 603, 1064; retinal changes in, 1064.
gangrene, 127, 130, 656; cause of, 656.
Sensation, disturbance of, in anemia, 50; in congestion, 38, 44, 45; in hyperemia, 44, 45.
Sensibilisators, 27, 581.
Sensibilization, 27, 580, 581; endogenous, 581; exogenous, 580.
Sensitization, serum, 322.
Sensitizers, 27, 332.

Sepsin, 338.
Sepsis, 60, 427, 499, 501, 894; general, 427; hemorrhage in, 60, 611; puerperal, 501, 894.
Septicemia, 60, 427, 499, 501, 894.
Septicopyemia, 499, 502; cryptogenetic, 499.
Septum defects, of heart, 190; of nose, 187, 188.
Sequelæ, 5.
Sequestrum, 123.
Serous membranes, adhesions of, 162, 180, 624, 735, 761, 781; carcinoma of, 117, 300, 303, 734, 736, 737, 786; corpora arenacea of, 239, 616; endothelioma of, 304; hemorrhage of, 60, 61, 62, 63, 70, 133, 622, 623, 786; inflammation of, 127, 439, 458, 465, 467, 497, 512, 539, 540, 568, 591, 722, 733, 734, 736, 768, 770, 781, 786, 888; sarcoma of, 251, 737; tuberculosis of, 462, 465, 467.
Serpent poisoning, 127, 320.
Serum, cytotoxic, 744.
  edema, 1083.
  intoxication, 32, 324, 325.
  sensitization, 322.
  sickness, 32, 324, 325.
Sesamoid bones, 239.
Shiga-Kruse bacillus, 569.
Shock, 610.
Siamese twins, 203.
Sickle spores, 404.
Sickness, serum, 32, 324, 325; sleeping, 394, 396.
Side-chain theory of immunity, 21.
Siderin, 70.
Siderosis, 133, 138, 709, 1011; of bone-marrow, 133; bulbi, 1011; hepatic, 133; pancreatic, 133; renal, 133; pulmonary, 132, 709; splenic, 133.
Signa mortis, 4.
Silver infarcts, 845.
  salts, in blood, 685; in tissues, 7, 94, 139, 685, 845, 970, 997 (see also Argyria).
Simulium reptans, 580.
Sinus, cavernous, thrombosis of, 1077.
  longitudinal, thrombosis of, 58.
  thrombosis, 58, 592, 1077.
  venosus scleræ, 1017.
Siren formation, 188.
Sitotoxismus, 337.
Situs inversus, 192.
  transversus, 206.
Sizy coat, 74.
Skin, angioma of, 263; atheroma of, 118, 215, 944; atheromatous cysts of, 118, 1078; atrophy of, 952; carcinoma of, 280; effect of constipation of, 763; hemorrhage of, 943; hyperemia of, 943; myoma of, 257; osteoma of, 239, 946; papules of, 948; regeneration of, 160; sand, 944; structure of, 941; syphilis of, 547; tuberculosis of, 481; vagabond's, 351.
Skull, capacity of, 598; depression of, 906; fracture of, 906; growth of, 923; hyperostosis of, 236; ossification of, 923; osteophytes of, 589; premature synostosis of sutures of, 597; rachitic, 914.
Sleeping sickness, 394, 396.
Slough, 72, 123, 127, 510.
Small-pox, 558; black, 560; hemorrhagic, 560.
Smokers' carcinoma, 273, 335.
Snake bites, 127, 320.
Softening, of brain, 611; of coagulum, 70; of stomach, 754.
Somatic death, 123.
Soor fungus, 420, 422; pneumonia from, 422.
Sparganum proliferum, 390.
Spasmi clonici et tonici, 3.
Spastic anemia, 46, 49.
Sperm cells, of malaria parasite, 403.
Spermatocele, 215, 867.
Spermatocystitis, 475, 496, 869; catarrhal, 869; fibrous, 869; gonorrheal, 496; obliterans, 869; tuberculous, 475.
Sphacelus, 72, 123, 127, 510; typhoid, 510.
Spherobacteria, 424.
Spiders, bites of, 320.
Spina bifida, 197, 214; anterior, 197; atlantica, 197.
  ventosa, 480.
Spinal cord, atrophy of, 601, 604; gray degeneration of, 604; syphilis of, 554.
Spindle-celled sarcoma, 246.
Spine, curvature of, 913, 917; tuberculosis of, 473, 913, 917.
Spirals, Curschmann's, 715.
Spirilla, 425.
Spirillum choleræ asiaticæ, 505.
  Obermeieri, 503.
  Vincent's, 529, 573.
  recurrent fever, 503.
Spirobacteria, 425.
Spirochæta berbera, 505.
  Duttoni, 505.
  Obermeieri, 503.
  pallida, 11, 543, 544, 558, 1097; distribution of, 11; in petrous bone, 1097.
Spirochætæ, 11, 425, 503, 505, 530, 543, 544, 558, 573, 1097.
Spirotrichosis, 502; African, 505; Egyptian, 505; syphilitic, 11, 543, 544, 558, 1097.
Spleen, abscess of, 692; accessory, 160; amyloid, 148, 693; anatomy of, 688; angioma of, 264; atrophy of, 115, 121, 693; bacon, 148, 693; brown atrophy of, 693; cicatrices of, 692, 694; cysticercus of, 693; cysts of, 694; echinococcus of, 385, 693; embolism of, 58, 89, 691; fibroma of, 220; hemosiderin in, 134, 412, 692; hemorrhage of, 58, 61, 89, 90, 694, 786; hyperemia of, 690; hyperplasia of, 254; hypoplasia of, 193; icterus of, 135, 693; induration of, 45, 691; infarction of, 86, 90, 691; lobulated, 692; malarial, 412, 690; metastases in, 93, 139, 693; parasites in, 385, 693; pigmentation of, 115, 133, 139, 692; regeneration of, 160; rupture of, 694, 786; sago, 148, 693; siderosis of, 133; supernumerary, 160, 205; syphilis of, 556, 693; tuberculosis of, 450, 470; acute tumor of, 412, 690; tumors of, 693.
Splenic fever, 490.
Splenitis, 691, 692, 693; apostematosa, 692; lobular, 562, 691, 692; purulent, 692.
Splenization, of lungs, 706.
Splenolysins, 26.
Splenomegaly, tropic, 396.
Spondylitis, tuberculous, 473, 913, 917.
Spongioid bone, 904.
Spontaneous fracture, 905, 934.
Sporangium, 416.
Spores, fungous, 415; lasting, 415; sickle, of malaria parasites, 404; swarm, 415.
Sporogony, 397, 401, 404, 405.
Sporotrichemia, 487.
Sporotrichosis, 486.
Sporotrichum Schenkii, 486.
Sporozoa, 397.
Sporozoites, 397, 404.
Spotted parsley poisoning, 337.
  fever, 565.
Spring worm, 356.
Sputum, rusty, 67, 91, 533.
St. Anthony's fire, 493.
Stadia, 4.
Stadium adipositas, 699.
  decrementi, 5.
  incrementi, 5.
  invasionis, 5.
  latentiæ, 5.
Stagnation, of blood, 71, 72; fecal effects of, 763.
Staphylococci, 174, 424, 459, 499, 956, 963.
Staphylococcus albus, 174, 499.
  aureus, 174, 499, 956; in pulmonary tuberculosis, 459.
  citreus, 174, 499.

Staphyloma, 532, 982, 1000; ciliary, 1000, 1004, 1050; corneal, 982; equatorial, 1050; intercallary, 1004, 1050; scleral, 1000, 1004.
Starvation, 116.
Stasis, of blood, 71; inflammatory, 72.
Status, 2; biliosus, 753; gastricus, 2; lymphaticus, 256, 700; mammillaris ventriculi, 765; menstrualis uteri, 893; præsens, 2; pseudomenstrualis uteri, 54, 507, 893; thymicus, 256, 700.
Stegomyia calopus, 586.
fasciata, 586.
Stellulæ Verheyenii, 822.
Stenocardia, 190.
Stenon's duct, stone in, 814.
Stenosis, aortic, 192, 635, 641; carcinomatous, 276, 292; cardiac, 42, 190, 191, 192; esophageal, 317, 548; gastric, 548; intestinal, 127, 762, 770; laryngeal, 548; of os uteri, 879; pulmonalis, 191; tracheal, 548, 741; urethral, 110, 496, 834.
Sterigmata, 417.
Sterility, from fibrous oöphoritis, 781; from syphilis of testes, 552.
Sternum, fissure of, 198.
Stimulus, 31.
Stinkweed poisoning, 337.
Stokes-Adams symptom-complex, 630.
Stomach, autodigestion of, 58; carcinoma of, 287, 291, 768; catarrh of, 749; dilation of, 346, 772, 774; diverticula of, 774; erosions of, 58; hemorrhagic infarction of, 58; hour-glass, contraction of, 769; mycosis of, 422; myiasis of, 351; myoma of, 257; digestion of walls of, 58, 126; perforation of, 287, 291, 768, 782; phlegmon of, 778; polypi of, 765; sarcoma of, 776; softening of, 754; stenosis of, 287, 291, 548, 768; tuberculosis, 459, 769; typhoid ulcer of, 769; ulcer of, 766, 769.
Stomatitis exudativa, 421.
hemorrhagic, 62.
mercurial, 326.
ulcerative, 573.
Stomoxys calcitrans, 395.
Stones, calcium, 140, 855; cholesterin, 807; cutaneous, 944; cystin, 858; fecal, 140, 143, 785; gall-, 140, 299, 807; hepatic, 140, 299, 807; intestinal, 140, 143, 785; kidney, 140, 847, 854, 858; lung, 140, 143, 737; oxalate, 855; pancreatic, 140, 143, 812; phosphatic, 140, 855; pigment, 808; preputial, 875; prostatic, 140, 143, 873; pulmonary, 140, 143, 737; salivary, 143, 814; spermatic, 869; tonsillar, 757; urate, 855; uterus, 142; vein, 80, 140, 873; vesical, 144, 855.
Stools, bilious, 510, 753; black-vomit, 587; bloody, 61, 67, 326, 527, 528, 755; in arsenic poisoning, 329; in dysentery, 61, 67, 326, 527, 528, 755; in phosphorus poisoning, 60, 327; rice-water, 326, 329, 506, 526; typhoid, 510; watery, 506.
Storm fly, 395.
Stramonium poisoning, 337.
Strangulation, gangrene from, 127; intestinal, 127, 770.
Strangury, 854.
Streptobacillus malæ, 930.
Streptococci, 174, 424, 498, 955, 963; in panophthalmitis, 1035; in pulmonary tuberculosis, 459.
Streptococcus erysipelatis, 493.
longus, 500.
mucosus, 500, 591, 1096; in meningitis, 591.
putridus, 500.
pyogenes, 174, 500, 592; in meningitis, 591, 592.
viridans, 500.
Streptothrix, 425; actinomyces, 483; asteroides, 488; maduræ, 485.
Striæ cutaneæ, 101.
gravidarum, 952.
Stricture, intestinal, 127, 444, 762, 770; urethral, 110, 496, 834 (see also Stenosis).
Stroma, 180, 208, 268; of carcinoma, 268.
Strongylidea, 356.
Strongyloides intestinalis, 370.
Strophanthin poisoning, 337.
Struma accessoria, 739; aneurysmatica, 739; carcinomatous, 745; congenita, 741; cystic, 742; exophthalmic, 738, 742; fibrous, 739, 740; follicular, 739, 740; gelatinosa, 151; ophthalmica, 743; perforans, 742, 745; pineal, 617; pituitary, 616; sarcomatous, 745; sporadic, 743; suprarenal, 620, 850; thyreopriva, 744; thyroidea, 620, 738, 739, 745; varicose, 739; vascular, 739.
Strychnine poisoning, 334.
Sty, 1084.
Sublimate, corrosive, poisoning by, 60, 325.
Sublingual glands, 814; cysts of, 814; ranula of, 814.
Subluxation, 238, 932.
hallucis, 238, 922.
lentis, 1011.
Submaxilla, alterations of, 813, 814; endothelioma of, 305.
Substance sensibilatrice, 27.
Sudamina, 948.
Succinic acid, in echinococcus, 385.
Sucking worms, 371.
Suffusion, 66.
Suggillation, 132, 943.
Sulphureted hydrogen, 125; poisoning by, 315.
Summer diarrhea, 520.
Sun disease, 578.
Suprarenal glands, 212, 345, 478, 619, 850; hematoma of, 212; hyperplasia of, 619; hypoplasia of, 345; secretin of, 345, 619; structure of, 619; tuberculosis of, 478; tumors of, 850.
Surra, 395.
Susceptibility, 2, 12, 430.
Sutures, cranial, ossification of, 924; premature synostosis of, 187, 597, 923, 924.
Swarm spores, 415.
Swelling, cloudy, 154.
in congestion, 44.
in dropsy, 96, 100.
in hemorrhage, 66, 69.
in hyperemia, 39.
in inflammation, 163.
in thrombosis, 79, 100.
Sycosis parasitaria, 419.
Symblepharon, 965, 966, 969, 1085.
Sympathetic ophthalmia, 1032.
paralysis, of pupil, 1020.
Symphysis, malformations of, 198.
Symptomatic anthrax, 126.
Symptomatology, 1.
Sympus, 188.
Syncephalus, 202.
Synchondroses, chondromata of, 229.
Synchysis, 1013; scintillans, 1014.
Syncope, 629.
Syncytial cells, 437.
Syncytioma malignum, 899; of bladder, 899.
Syncytium, 279, 437.
Syndactylia, 188.
Synechiæ, of cardiac valves, 641, 643; of fetal head with amnion, 186, 187; pupillary, 984, 986, 1019.
Synostosis, 187, 217, 597, 923, 924; cranial, 597, 923; premature, of cranial sutures, 187, 597, 923, 924; senile, 924; tarda, 924; vertebral, 918.
Synotia, 187.
Synovialis, fibroma of, 216, 220; exudative inflammation of, 176, 923; tuberculosis of, 478, 480; urate deposits in, 94, 143.
Synovitis, adhesive, 930, 933; fibrinous, 177, 930, 933; purulent, 174, 177, 501, 926; tuberculous, 478, 480 (see also Arthritis).

Syphilis, 11, 49, 149, 543, 552, 894; abortion from, 894; amyloid degeneration in, 149; anemia in, 49; arteriosclerosis in, 431; of ciliary body, 1030; choroidal, 1014, 1037; congenital, 11, 546, 552; conjunctival, 968; of cornea, 986; of eyelids, 1087; of fetus, 894; galloping, 558; of heart, 634; hemorrhage in, 61; of iris, 1023; laryngeal, 548; malignant, 557; Noguchi reaction in, 322; of optic nerve, 1055; orbital, 1077; pharyngeal, 548; placental, 11, 894; retinal, 1072; tuberculosis and, 431; Wassermann-Bruck reaction in, 321, 330.
Syringomyelia, 615, 1054; optic neuritis in, 1054.

Tabanidæ, 395.
Tabes, 114, 604; dorsalis, 604.
Tænia, africana, 384.
canina, 379.
confusa, 384.
cucumerina, 379.
echinococcus, 385.
frequency of, 379.
inermis, 383.
lata, 390.
mediocanellata, 383.
nana, 379.
saginata, 383.
solium, 380.
varieties of, 378.
Tachycardia, 630; in Basedow's disease, 743.
Tactile disturbances in edema, 101.
Talipomanus, 200 (see also Pes).
Tapeworm, 377; beef, 383; pork, 380 (see also Tænia).
Tarantula bite, 320.
Tarsitis, 1087.
Tarsus, 1080.
Tattooing, 139, 687.
Tear ducts (see Lachrymal Duct).
Teeth, atrophy of, 121; caries of, 238, 430, 448; chattering of, in fever, 182; coalescence of, 238; extraction of, hemorrhage in, 56; retention of, 238.
Tela choroides, 614; tubercle of, 468.
Telangiectasis, 264, 611, 704, 1046; cerebral, 611; choroidal, 1046.
Telectasis, 704.
Temperament, 2.
Temperature, agonal increase of, 183; body, in various states, 50, 182; collapse, 183; in hyperemia, 39; in inflammation, 164; lowering of in anemia, 50.
Temporal bone, caries of, 1096.
Tendon-sheaths, tuberculosis of, 938.
Tendons, tuberculosis of, 478.
Tendovaginitis, 478, 938; adhesive, 933; fibrinous, 930; gonorrheal, 497; purulent, 501, 926; tuberculous, 478, 938.
Tenon, capsule of, 1073.
Tenonitis, 1074.
Tension, intraocular, 1000, 1047, 1049; vascular, 57, 58, 59.
Terata anadidyma, 202.
anakatadidyma, 203.
katadidyma, 202.
Teratoid tumors, 311.
Terebinthina poisoning, 174.
Tertian malaria, 404, 408; development of parasite in, 404.
Test, Noguchi, 322; scratch, 441; tuberculin, 441; Wassermann-Bruck, 321, 330 (see also Reaction).
Testes, atrophy of, 869; carcinoma of, 301; fibroma of, 220; hypertrophy of, 111, 869; hypoplasia of, 193; inflammation of, 868; malformations of, 189, 193, 194, 200, 201; leprosy of, 532; myxoma of, 229; neuroma of, 261; pearl tumor of, 281; retention of, 200, 210, 233, 869; sarcoma of, 877; syphilis of, 552; tuberculosis of, 475.
Tetanus, 492.
Tetany, 340, 346; infantile, 746; postoperative, 746.
Tetragenus, 424.
Tetramethylendiamin, 338.
Tetter, 947; moist, 948; papular, 948.
Thallophytes, 414.
Thallus, 415.
Theory, Arneth's leucocytosis, 668; attraction, 71; Cohnheim's carcinoma, 273; phagocytosis, 28, 428; side-chain, 21; vaccine, 29, 517; Virchow's carcinoma, 274; Welch's microbic resistance, 32; Wright's opsonic, 28.
Thoracoabdominopagus, 203.
Thoracopagus, 203; parasiticus, 203.
Thorax, malformations of, 187, 188, 198.
Thorn-apple poisoning, 337.
Thrombi, 53.
Thrombin, 73.
Thrombogen, 73.
Thrombophlebitis, 652; purulent, 952; uterine, 985.
Thrombosis, cardiac, 646; causes of, 74; of cavernous sinus, 1077; compression, 75; congestion, 45; dilation, 75; endocardial, 645; ferment, 76; of kidney, 848; of longitudinal sinus, 58; lymph, 659; prostatic, 873; pulmonary, 731; retinal, 1070; secondary, 92; sinus, 58, 592, 1077; traumatic, 75.
Thrombus, arterial, 78; autochthonous, 77; bland, 77; calcification of, 140; canalization of, 80; changes in, 79; continuous, 77, 82; cylindric, 78; globular, 78, 645; hemispheric, 78; hornification of, 80; hyaline metamorphosis of, 80; infectious, 77; inspissation of, 80, 645; lamellated, 77; lateral, 77; mixed, 77; obstructing, 71, 77; organization of, 80, 161; parietal, 77; polypoid, 78, 645; primary, 77; progressive, 77; puriform softening of, 81, 645; purulent softening of, 81, 645; red, 77; secondary, 77, 87; softening of, 81, 645; traumatic, 75; valvular, 77, 645; vascularization of, 80; venous, 78; verrucous, 78, 645; white, 77.
Thrush fungus, 420.
Thymectomy, 699.
Thymus, 698; abscess, 700; death, 699; hemorrhage, 700; hyperplasia, 256, 699; hypertrophy, 699; metamorphosis of, 106; persistens, 698, 700; in status lymphaticus, 256, 700.
Thyreoproteid, 744.
Thyroid, 205, 302, 345, 478, 562, 737, 744; accessory, 205; carcinoma of, 302; in scarlatina, 562; gland, 345; tuberculosis of, 478.
Thyroidectomy, effects of, 744.
Thyroiditis, 745; scarlatinal, 562.
Tick, dog, 354; harvest, 354; ornithodorus, 503; pigeon, 354; wood, 354.
fever, 503, 566.
Tinea favosa, 418.
tonsurans, 419.
versicolor, 420.
Tip-foot, 200.
Tissue, adaptation of, 108; granulation, 166, 177; regeneration of, 158, 159.
Tobacco poisoning, 335.
Tongue, carcinoma of, 273, 335; catarrh of, 752; coated, 176, 752; hyperplasia of, 201, 257; leprosy of, 531; leptothrix of, 425, 428; leucoplakia of, 752; malformations of, 201, 256; psoriasis of, 752; smooth atrophy of, 122, 548; syphilis of, 548; tuberculosis of, 459.
Tonsillitis, 255, 757.
Tonsils, abscess of, 757; calculi of, 757; faucial, 756; hypertrophy of, 255, 757; pharyngeal, 756.
Tonus bulbi, 1000, 1047, 1049.
vascular, 34.

Top yeast, 423.
Tophi, 143; aural, 143.
Torticollis, 937.
Toxalbumins, 338.
Toxenzymes, 338.
Toxins, 21, 175, 338, 763; bacterial, 175; endo-, 175; intestinal, 763.
Toxoid, 22.
Toxons, 23.
Toxophore, 22.
Trachea, carcinoma of, 300; ecchondrosis of, 229; ectasis of, 724; fistula of, 198.
Trachectasis, 215.
Tracheitis, catarrhal, 712, 716.
Trachoma, 958; cicatrizing, 961; etiology of, 960; follicular, 960; gelatinous, 959.
Transfusion, of human blood, 321.
Transmission, of disease, 10.
Transplantation, 162; of tumors, 209.
Transport, retrograde, 95; of tumor-cells, 83, 207, 209; of emboli, 93.
Transposition, of organs, 206; of vascular trunks, 192.
Transudates, 98.
Trauma, abscess after cranial, 600, 798; arachnitis from, 594; articular, fracture of cartilage in, 232; cardiac, 622, 631, 648; cerebral abscess from, 600, 798; cerebral hemorrhage from, 611; cerebri, 133, 594, 611, 612, 613, 798; cutaneous, hemorrhages from, 943; defect from, 158; enchondroma after, 233; endocarditis from, 648; of epididymis, 868; exostoses from, 237, 238; ganglion-cell calcification from, 141; gangrene from, 124; heart rupture from, 631, 632; hematoma from, 214; hematothorax from, 734; hemorrhage from, 44, 55, 56, 622, 943; intestinal infarction from, 766; intestinal perforation from, 782; of liver, 795, 798; liver abscess after, 798; macroglossia from, 257; middle-ear changes from, 1089; muscle hematoma from, 214; of nerves, 618; neuroma from, 262; pericardial hemorrhage from, 622; pneumopericardium from, 625; pulmonary gangrene from, 732; pyopneumothorax from, 736; sarcoma from, 244; of spleen, 694; of testes, 868; thrombosis from, 75; of vagina, 887; vascular changes from, 652; vitreous osteoma from, 239; of vulva, 878, 887, 891.
Trematodes, 371.
Trepanatio cranii, 906.
Treponema pallidum, 11, 543, 544.
Trichiasis, 961.
Trichina spiralis, 360.
Trichinella, 360.
Trichiniasis, 363, 366, 781, 1077, 1082.
Trichinosis, 363, 366, 781; orbital, 1077, 1082.
Trichocephalus dispar, 366.
Trichodectes canis, 379.
Trichomonas intestinalis, 393.
pulmonalis, 393.
vaginalis, 393.
Trichophyton tonsurans, 419.
Trichotrachel'dea, 356.
Trichiurus trichiura, 366.
Triple phosphate, in urine, 140, 855.
Trismus, 492.
Trombidium tlalsahaute, 355.
Tropic ulcer, 397.
Trypanosoma brucci, 395.
cruzi, 396.
diorphon, 396.
equinum, 396.
equiperdum, 395.
evansi, 395.
gambiense, 396.
lewisi, 395.
theileri, 396.
Trypanosomiasis, 394, 396.
Truncus arteriosus communis, 190.
Tsetse fly, 395.
Tubercle, 436; brain, 616; caseation of, 443; conglomerate, 469, 471; giant cells of, 436; miliary, 443; solitary, 469, 471, 616; structure of, 437; submiliary, 443.
Tubercles, rabic, 569.
Tuberculin reaction, 439; character of, 440; diagnostic significance of, 440; specificity of, 440.
Tuberculosis, 436; adhesive, 466; aërogenous infection in, 452; ascites in, 464; avian, 438; bacillus of, 438; bladder, 474; bone, 479, 917; bovine, 438; brain, 469, 616; of breast, 477; bronchial, 452; of bursæ, 478; cavity formation in, 456; cerebral, 469, 616; of ciliary body, 1030; congenital, 442; conjunctival, 968; corneal, 995; cutaneous, 481; of digestive tract, 444, 459; of epididymis, 475; excretion, 472; of Fallopian tubes, 477; fish, 438; gastric, 769; hematogenous, 452; hemorrhage in, 458; heredity and, 442; in birds, 438; in cattle, 441; in children, 439; inoculation, 439; intestinal, 444; iris, 1023; joint, 480, 938; laryngeal, 453; of liver, 470; lobar pneumonia in, 542; lymphatic, 446, 460, 470; lymphogenous, infection in, 452; meningeal, 467; mixed infection in, 459; mode of invasion in, 438; muscular, 478; of nerves, 478, 1056; of optic nerve, 1056; pancreatic, 478; of parotid, 450, 478; of penis, 876; pericardial, 465; peritoneal, 462; pharyngeal, 450, 454; pleuritic, 465; pneumonia in, 454, 542; primary, 450; prostatic, 474; pulmonary, 438, 452; renal, 471; of salivary glands, 478; scleral, 1004; scrofula and, 446, 448; secondary, 450; of seminal vesicles, 475; of spleen, 470; stenosis of intestine in, 444; syphilis as predisposing cause of, 431; of tendon-sheaths, 938; testicular, 475; thyroidal, 478; ulceration in, 444, 456; ureteral, 474; urogenital, 474; uterine, 477, 896; vesical, 474, 896.
Tubes, Fallopian, 477; absence of, 189; carcinoma of, 901; catarrh of, 880; dilation of, 880; gonorrhea of, 496, 781; hypoplasia of, 193; malformations of, 193; myoma of, 261; pregnancy in, 896; rupture of, 880, 896; sarcoma of, 901; suppuration of, 496, 781, 886; tuberculosis of, 477; tumors of, 897.
Miescher's, 414.
Rainey's, 414.
Tubules, renal, 816.
Tumor, in inflammation, 170; pearl, 281.
Tumors, 207; benign, 207; cachexia in, 211; cartilaginous, 229; combination, 216; contagium of, 209; dilation, 215; etiology of, 210; extravasation, 211; exudation, 211; generalization of, 209; growth of, 208; heterologous, 207; heterotopous, 207; homologous, 207; lymphatic, 254; malignant, 207; mucoid, 226; organoid, 268; proliferation, 215; pulmonary, 736; regional metastasis in, 209; retention, 215; systematoid, 311; teratoid, 311; transplantation of, 209; villous, 222, 737, 863, 970, 1086.
Turpentine poisoning, 174.
Tussis convulsiva, 564.
Tyloma, 952.
Tylosis, 952.
Tympanites, 784.
Tympanum, of ear, 1088; atrophy of, 1091; perforation of, 1090, 1092; trauma of, 1090.
Type, of disease, 3.
Typhoid fever, 150, 507, 517; vaccine treatment in, 517; waxy degeneration in, 150.
Typhus, abdominal, 507; ambulatorius, 514; American, 586; exanthematicus, 565; famine, 502; fever, 565; icteroides, 588; infantum, 513; mitior, 513; pellagra, 577; yellow, 588.

Tyrosin, in septicemia, 502.
Tyrosis, 173.

Ulcer, annular, 459; atheromatous, 992; carcinomatous, 274; condylomatous, 548; corneal, 962, 981, 992; crural, 949; cutaneous, 949; diphtheritic, 526; duodenal, 768; follicular, 527, 760; gastric, 126, 693, 766; hypopyon, 981, 984; intestinal, 444, 456, 760; marginal, of cornea, 991; peptic, 766; perforating, 950; phagedenic, 179, 547; Plaut-Bernheim, 529, 573; rodent, of cornea, 992; round, 766; scrofulous, 447; serpiginous, of cornea, 981, 984, 992; syphilitic, 547; tropic, 397; tuberculous, 444, 456; typhoid, 512; varicose, 949.
Ulcera syrica, 523.
Ulceration, 179, 274, 444, 447, 456, 526, 760.
Ulcus cruris, 281.
  durum, 547.
  molle, 874.
Uncinaria americana, 368.
  duodenalis, 367.
Uncinariasis, 367.
Uratemia, 684.
Urates, 855; in kidney, 845.
Uremia, 69, 341.
Ureters, occlusion of, 837; tuberculosis of, 474.
Urethra, gonorrhea of, 496; stricture of, 110, 496, 834.
Urethritis, specific, 496.
Uric acid, 684, 845; in blood, 684; infarcts, of kidney, 845.
Urine, acetone in, 343; albumin in, 825, 826; diacetic acid in, 343; renal casts in, 837; retention of, 69; sugar in, 343; toxins in, 343; typhoid bacilli in, 508.
Urotoxic coefficient, 343.
Urticaria, 948; ex ingestis, 942.
Uterus, anteflexion of, 260; atrophy of, 981; bicornis, 196; calculi of, 142; carcinoma of, 297, 897; diphtheria of, 887; displacements of, 888; duplex, 196; duplication of, 195; fœtalis, 196; fibromyoma of, 257, 898; hematoma of, 214; infantile, 196; infarct of, 41, 891; inversion of, 890; involution of, 890; mycosis of, 422, 891; myoma of, 257, 258, 898; myosarcoma of, 260; position of, 888; prolapse of, 889; puerperal, 501, 894; rupture of, 896; sepsis of, 501, 894; septus, 196; syphilis of, 556; thrombophlebitis of, 895; tuberculosis of, 477, 896; unicornis, 196.
Uvea, anatomy of, 1014; arteries of, 1014; sarcoma of, 1014; veins of, 1014.
Uveitis, 1021.

Vaccination, 29, 432; opsonic, 30; typhoid, 517.
Vaccine theory, 29.
  treatment, in typhoid, 517.
Vagabond's skin, 351.
Vagina, atresia of, 199; atrophy of, 177; carcinoma of, 298, 900; diphtheria of, 525, 887; catarrh of, 177, 495, 877, 878; duplication of, 195; epidermization of, 108; gangrene of, 887; gonorrhea of, 495, 877; hematoma of, 212; hypersecretion of, 892; inversion of, 890; malformations of, 193, 194, 195, 196; myoma of, 260, 901; prolapse of, 890; sarcoma of, 901; secretions of, 877; septa, 196; thrush fungus of, 421; tumors of, 212, 260, 298, 900.
Vaginitis, 877, 878; mycotic, 421; acute purulent, 878.
Valerianic acid, in gangrene, 126.
Valvula fenestrata, 638.
Valvular lesions, cardiac, 136, 640, 643; causes of, 643; icterus in, 136.
Vanquez's disease, 683.
Varicella, 560.
Varices, 34, 59, 79, 262, 658.
  hemorrhages from, 56, 59, 659.
  thrombosis in, 75, 79.
Varicocele, 268, 658.
Variola, 432, 558.
Varix, 34, 268; racemosus, 268.
Vas deferens, 869.
Vascularization, 35, 161.
Vasoconstrictors, 34.
Vasodilators, 34.
Vegetable parasites, 414.
  poisoning, 337.
Veins, compression of, 40; dilation of, 41; calculi of, 80, 140, 873; thrombosis of, 78; varicose, 659.
Velum choroides, 614.
Vena cava inferior, thrombosis of, 79.
  magna Galeni, compression of, 615; thrombosis of, 611.
  portarum, thrombosis of, 79.
  subclavia, thrombosis of, 96.
  vorticosæ, 1016.
Venena corrosiva, 316.
Venesection, 73.
Venous anemia, 50.
  pulse, 630.
Ventricles, defects of, 190; cerebral, dilation of, 615.
Veratrin poisoning, 332.
Vermes, 356.
Vermicelli, in epithelioma, 281.
Vermiform appendix, ulceration of, 761 (see also Appendix, Vermiform).
Vermuth poisoning, 336.
Vernix caseosa, 118.
Verrucæ, 223, 244; cutaneous, 223, 244.
Vertebræ, caries of, 917; exostoses of, 237; fracture of, 907; synostosis of, 918; tuberculosis of, 473, 913, 917.
Vesica bipartita, 205.
Vesicles, gangrene, 125.
  seminal, 869.
Vesiculitis, seminal, 475, 869.
Vessels, blood-, atony of, 34; budding of, 161; coagulation in, 73; ligation of, 75; organic alterations of, 34.
Vestibule, hemorrhage into, 1096.
Vibices, 943.
Vibrio, 425, 505; choleræ asiaticæ, 505.
Vincent's angina, 529, 573; bacillus of, 572; spirochæta of, 573.
Virchow, carcinoma theory of, 274.
Virus, "fixed," 569; "street," 569.
Vis a tergo, 75.
Visual purple, 1061.
Vita propria, of cells, 123.
Vital nucleus, 22.
Vitia primæ formationis, 10.
Vitiligo, 131; iridis, 1022.
Vitreous, abscess of, 1013; anatomy of, 1012; chemic changes of, 1014; dust, 1014; fibrillary degeneration of, 1012; hemorrhage of, 1013; humor, 1012; hyaloid membrane of, 1012; liquefaction of, 1013; opacity of, 1013; ossification of, 1014; prolapse of, 1013.
Volume, of cells, alteration of, 104, 105.
Volumen pulmonum auctum, 708.
Volvulus, 771.
Vomer, congenital absence of, 187.
Von Pirquet reaction, 439.
Vulva, atresia of, 199; atrophy of, 901; carcinoma of, 900; chancre of, 887; cicatrices of, 878; condyloma of, 879; defect of, 189; diphtheria of, 887; elephantiasis of, 901; fibroma of, 901; fibromyoma of, 901; fibrosarcoma of, 901; furuncle of, 887; gangrene of, 127, 525, 887; hematoma of, 212, 891; kraurosis of, 901; lipoma of, 901; noma of, 128, 753, 887; phlegmon of, 887; trauma of, 887; tumors of, 900; ulcers of, 878.

Vulvitis, catarrhal, 878; diphtheritic, 887; ulcerative, 878 (see also Vulva).

Waldeyer's glands, 1080.
Walking typhoid, 514.
Wandering cells, 167.
Warts, 137, 219, 223; fig, 223; flesh, 223; hard, 223; Henle's, 996; pigmented, 137; venereal, 879.
Wassermann-Bruck reaction, 321, 330; in scleritis, 1000, 1001.
Water-fright, 569.
Waxy degeneration, 61, 139, 150, 935; of muscle, 61, 139, 150, 214, 935.
Weakness, cardiac, 629.
Welch, microbic resistance theory of, 32.
Wen, 944.
Werlhof's disease, 63.
Wharton's duct, stone in, 814.
jelly, 152.
Whip-worm, 366.
White blood-corpuscles, 661; emigration of, 164.
Whitlow, 946.
Whooping-cough, 564, 969; conjunctival hemorrhage in, 969.
Wildfire, 493.
Wild flesh, 180.
Willis, circle of, 595; embolism of, 86, 596.
Wind-pox, 560.
Wine yeast, 423.
Winckel's disease, 677.
Wolf, 481.
Wolf's jaw, 197.
Wolffian ducts, 194.
Wooden tongue, 484.
Woody phlegmon, 687.
Woolsorters' disease, 489.
Wormian bones, 204.
Worms, 356.
Wounds, diphtheria of, 525; healing of, 162; hemorrhage from open, 55, 56, 622, 943; infection of, 175 (see also Trauma).
Wright, opsonic index of, 28; theory of, 28.
Wry-neck, 937.

X-legs, 915.
Xanthelasma, palpebral, 1086.
Xanthoma hepaticum, 942.
Xerophthalmia, 961, 967.
Xerosis, 961, 967; bacillus of, 956; conjunctival, 961, 967; corneal, 967.

Yaws, 588.
Yeasts, pathogenic, 423.
Yellow fever, 586.
spot, 1058.

Zeiss, glands of, 1080, 1084.
Zenker's degeneration, 150, 935.
Zinc chloride poisoning, 316.
Zinn, zone of, 1005, 1011, 1016, 1028.
Zone, marginal, in inflammation, 164.
Zones, head, 947, 1033.
Zymophore, 25.
Zymoplastic substance, 73.